

Thermic dehorning and ear tagging as atypical portals of entry of *Clostridium tetani* in ruminants

Thermische onthoornen en oormerken als atypische intredeplaatsen van Clostridium tetani bij herkauwers

¹B. Valgaeren, ¹P. De Schutter, ¹B. Pardon, ²V. Eeckhaut, ²F. Boyen, ²F. Van Immerseel, ¹P. Deprez

¹ Department of Internal Medicine and Clinical Biology of Large Animals

² Department of Pathology, Bacteriology and Avian Diseases,

Faculty of Veterinary Medicine, Ghent University, Salisburylaan 133, B-9820 Merelbeke, Belgium

bonnie.valgaeren@ugent.be

ABSTRACT

This paper describes two infections with *Clostridium tetani* (*C. tetani*). One outbreak occurred after dehorning of calves, the second infection happened after ear tagging of a goat. In the first case 3 young Holstein Friesian calves showed generalized stiffness, severe lock-jaw and bloat two weeks after dehorning. The thermal dehorning wounds were identified as the infection sites of *C. tetani* by bacterial culture and PCR. The second case was a three-year old male castrated goat, with generalized stiffness. The animal had been ear tagged one week prior to the onset of the symptoms. *C. tetani* could be cultured from pus on the ear tag. Treatment was attempted in two calves and the goat. Wounds were debrided and disinfected, penicillin and anti-tetanus serum were administered and polyionic perfusions provided. In addition, the goat was vaccinated against tetanus. The goat and one calf fully recovered after 36 and 8 days respectively. To the authors' knowledge a tetanus outbreak in association with thermal dehorning has not been described previously. Also ear tagging as a possible cause for *C. tetani* infection has not been described in goats.

SAMENVATTING

In dit artikel worden twee infecties met *Clostridium tetani* beschreven. Een eerste uitbraak ontstond na het onthoornen van kalveren, de tweede infectie na het oormerken van een geit. In de eerste casus vertoonden drie jonge holstein-friesiankalveren veralgemeende stijfheid, een trismus en tympanie twee weken na het onthoornen. De wonden na de thermische onthoornen werden geïdentificeerd als de infectieplaatsen van *Clostridium tetani* door middel van bacteriële cultuur en PCR. De tweede casus betrof een mannelijke gecasteerde geit van drie jaar oud met veralgemeende stijfheid. Een week vóór het begin van de symptomen werden oormerken geplaatst. *C. tetani* kon geïsoleerd worden uit de etter verkleefd aan het oormerk. Twee van de drie kalveren en de geit werden behandeld. De wonden werden schoongemaakt en gedesinfecteerd en penicilline, antitetanus-serum en polyionisch infuus werden toegediend. De geit werd bijkomend gevaccineerd tegen tetanus. De geit en één kalf herstelden volledig na respectievelijk 36 en acht dagen.

Voor zover bekend werd er nog nooit een tetanusuitbraak geassocieerd met thermisch onthoornen, beschreven. Ook het oormerken werd nog niet beschreven als een mogelijke oorzaak van een *C. Tetani*-infectie bij geiten.

INTRODUCTION

Tetanus is a life-threatening toxico-infection caused by the neurotoxin of *C. tetani*. Typical symptoms are increased general muscular rigidity evolving to a complete tetanic state, frequently with a fatal outcome (Linnenbrink *et al.*, 2006). Although tetanus is described in all domestic animals, small ruminants and horses are known to be the most susceptible species (Aslani *et al.*, 1998; Driemeier *et al.*, 2006; Wernery *et al.*, 2004). Tetanus usually affects a single animal, but outbreaks have been sporadically described in farm animals, especially in association with serial injections (Barbosa *et al.*, 2009; Driemeier *et al.*, 2007). Infection occurs as a result of contamination of wounds with spo-

res of *C. tetani*, which desporulate to the vegetative form and produce tetanus toxin when anaerobic conditions are present. The most frequently described infection sites in farm animals are castration, shearing and injection wounds (Aslani *et al.*, 1998). As less frequent infection sources surgical contamination, snake bites, umbilical infections and ear tagging have also been described in animals (Aslani *et al.*, 1998; Linnenbrink *et al.*, 2006; Poudel *et al.*, 2009). This case report describes two tetanus cases with an atypical portal of entry, the first being an outbreak of tetanus in dairy calves, shortly after thermal dehorning and the second in a three-year old goat, after ear tagging.

CASE 1

Case history

In May 2011 three Holstein Friesian calves, between 3 and 5 months of age, were referred to the Veterinary Clinic in Merelbeke with complaints of stiffness, recumbency, ruminal bloat and lock-jaw. The symptoms had started 2 to 7 days before presentation. At the farm, all animals were housed in the same pen together with thirteen other calves. Fourteen days before admission, eight of these calves were thermally dehorned. Seven days before admission, one of the recently dehorned calves was found dead. No previous symptoms were noted by the owner, and no necropsy was performed. The animals were vaccinated against IBR, but not against clostridial diseases.

Clinical examination and ancillary diagnostics

All calves showed stiffness in all four limbs, markedly increased muscle tone, pricked ears, lifted tail and bloat. One calf was still able to lie down and get up without assistance and to ingest small amounts of feed and water, whereas the other two calves could not bend their legs, had severe lock-jaw and were unable to eat or drink. The dehorning wounds had a thick crust with pus underneath. No other wounds were detected. Temperature, respiration and heart rate were normal in all calves.

Standard hematology, biochemistry and blood gas analysis only showed a mild to severe dehydration in all calves. The crust was removed from the dehorning wounds and cultured for *Clostridium tetani*. The crust was suspended in sterile phosphate buffer solution (PBS) and heated at 80°C for 20 minutes. Of this suspension, 100 µl was cultivated at 37°C for 24 hours on a blood plate in an anaerobic chamber (Ruskinn Technology) with 84% N₂, 8% CO₂ and 8% H₂. A pure culture of a hemolytic gram-positive rod with terminal spores was obtained (Figure 1a). The final identifica-

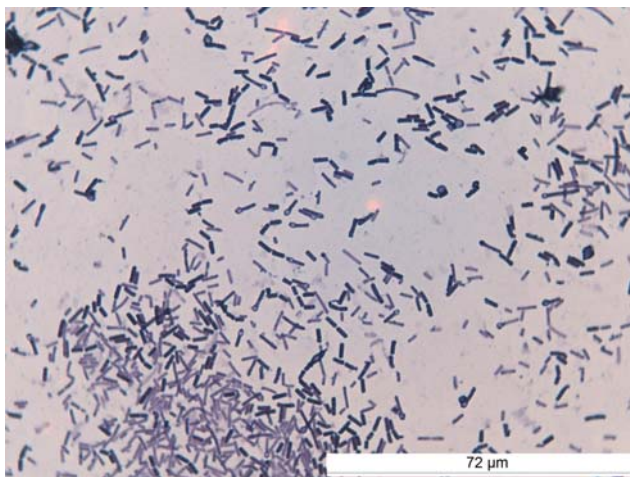


Figure 1a. Spores and bacteria of *Clostridium tetani* with a typical drum-stick shape isolated from the crust of the dehorning wounds in case 1 (gram-staining-1000x).

tion of *C. tetani* was done by PCR (Akbulut *et al.*, 2005).

Treatment and further evolution

One calf was euthanized immediately at arrival due to the graveness of the symptoms and the bad prognosis. The dehorning wounds of the remaining calves were thoroughly cleaned with H₂O₂. The calves received IV 10 ml of anti-tetanus serum® (Intervet), daily injections with procaine benzylpenicillin (10 mg/kg, IM, Duphaphen, Pfizer A.H.) and thiamine (10mg/kg, IV, tid) for 6 days and polyionic perfusion with 10% glucose. A second calf was euthanized 2 days after arrival in the clinic due to worsening of the symptoms. In the third calf, which showed the best clinical condition at arrival, the symptoms gradually improved and the patient could leave the clinic 7 days after presentation with minimal signs of stiffness.

CASE 2

Case history

In June 2011, a castrated male goat of 3 years of age was presented at the clinic with symptoms of apathy, generalized stiffness, dysphagia and reduced ruminal sounds. At home, the veterinarian suspected indigestion or ruminal acidosis and treated the animal with butylscopolamine (Buscopan®, Boehringer Ingelheim BV), flunixin meglumine (Bedozane®, Eurovet), a bicarbonate perfusion and supplementation with vitamins and minerals. The animal was kept in a hobby setting on pasture together with 5 apparently healthy other goats. Although all animals were officially registered since birth, their ear tags had only been placed a week before presentation at the clinic. The animal had been vaccinated once against *C. tetani* before castration at 6 months of age, but without continuation of the vaccination program.

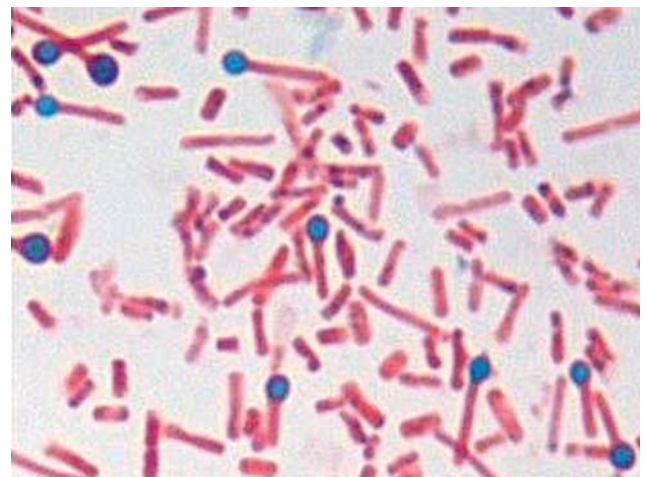


Figure 1b. Spores and bacteria of *Clostridium tetani* with a typical drum-stick shape isolated from the ear tags in case 2 (Malachite Green – 1000x).

Clinical examination and ancillary diagnostics

Upon admission, the goat showed obvious stiffness of the limbs and was alert. Rectal temperature, pulse and respiration rates were normal. Elevated abdominal tension, pricked ears, elevated tail and subtle ruminal bloat were present. The uptake of food and water was impossible due to severe lock-jaw. The animal could still defecate and urinate in a normal way.

The goat was slightly dehydrated. No other deviations were found on standard blood examination. The ruminal fluid had a normal macroscopic aspect and a pH of 7.3 (normal values 6-7). Multiple living protozoa were detected on microscopic examination (10x magnification). Standard parasitological examination resulted in a strongyle count of 8100 eggs per gram feces and an *Eimeria* spp. count of 450 oöcysts per gram faeces. Of the detected oöcysts roughly 10% belonged to the virulent species *Eimeria ninakohlyakimovae*. The ear tags were removed after permission of the official authority responsible for food animal identification. From pus sticking to the ear tags, an anaerobic culture was performed as described in case 1 and *Clostridium tetani* could be cultured. Further identification was done as described in case 1. A smear of the purified colonies was stained with Malachite Green and safranin and the typical drum-stick shaped rods were visible, as demonstrated in Figure 1b.

Treatment and further evolution

The crusts were removed and the wounds were disinfected with H₂O₂. The goat received 4 ml of anti-tetanus serum® (Intervet), and daily injections with procaine benzylpenicillin (10 mg/kg, IM, Duphaphen, Pfizer A.H.) and thiamine (10mg/kg, IV, tid) for 6 days and a polyionic perfusion with 10% glucose. Additionally the goat was vaccinated with Covexin 10® (Pfizer AH) containing a minimum of 4.9 IE *C. tetani* toxoid. A mixture of beet pulp and moistened concentrates was offered by syringe in the animal's mouth. Three days after referral to the clinic, the animal was found in lateral recumbency with severe ruminal bloat, worsened jaw-lock and stiffness of the limbs. Most probably the animal had fallen during the night and had been unable to stand up by itself, resulting in ruminal bloat. Because of the degree of excitation, the animal was mildly sedated (midazolam, 0.25 mg/kg, Dormicum, Roche). The bloat was relieved by rumen puncture with a 16G catheter after surgical preparation. The ear wounds were debrided again and 2 ml of penicillin was locally administered. The symptoms stabilized over the next days and the animal gradually recovered. Eight days after admission, when the animal was able to eat unaided, it was discharged. The remaining symptoms (stiffness of the limbs) continued to decrease and 5 weeks after submission in the clinic, the animal had fully recovered. New ear tags were placed after recovery.

DISCUSSION

Tetanus is a fatal toxico-infection, caused by toxins of *Clostridium tetani* (Poudel *et al.*, 2009). This bacterium is able to produce two important toxins, namely tetanolysin and tetanospasmin. The first has the ability to lyse cell membranes, causing tissue damage and stimulating the development of an anaerobic environment. The latter is responsible for the neurological symptoms by inhibiting the release of inhibitory neurotransmitters, causing generalized muscle spasm and alterations of autonomic control. Because the toxin is slowly transported retrograde from the peripheral nerves to the central nervous system, incubation periods of 3 to 18 days are described (Driemeier *et al.*, 2006; Linnenbrink *et al.*, 2006). *C. tetani* produces very resistant spores that can survive boiling temperatures for several minutes (Dixit *et al.*, 2005; Linnenbrink *et al.*, 2006). In order to desporulate to a vegetative form, the spores need an environment with low oxygen tension, typically generated under the crust of penetrating wounds (Linnenbrink *et al.*, 2006). Although the advanced symptoms might resemble those seen in traumatic reticuloperitonitis, white muscle disease, grass tetany, meningitis, cerebrocortical necrosis, lead intoxication, strychnine-intoxication and to a lesser extent laminitis, poly-arthritis, esophageal obstruction and other causes of ruminal tympany (Stöber, 2002). However, in the case of tetanus the symptoms quickly evolve to the pathognomonic tonic-clonic cramps of the antigravitational muscles, protrusion of the third eye lid, stiff ears and a raised tail base. Although tetanus typically is an individual problem, outbreaks have been described in several animal species and humans, due to very different entry routes. Most famous are human outbreaks in intravenous drug users due to the use of contaminated needles (Sun K., 1994; Gormley *et al.*, 2004). Also in ruminants multiple outbreaks have been described following injections with contaminated needles, for example after injection with anthelmintics in sheep and cattle or after rabies vaccination in buffalo's (Driemeier *et al.*, 2006; Barbosa *et al.*, 2009). Although goats and sheep are more sensitive than cattle, (Aslani *et al.*, 1998) outbreaks have more frequently been described in young cattle, possibly due to the more frequent application of mass injections in calves (Driemeier *et al.*, 2006).

The present case report describes an outbreak of tetanus in three animals of the same herd, following thermal dehorning. Since the ban on chemical dehorning in 2008, thermal dehorning is the standard dehorning method for calves of 4 to 8 weeks of age (Nantier, 2009). The dehorning iron is heated to 600-700 degrees Celsius and is then placed upon the horn stumps, burning the epithelium and surrounding tissue and resulting in permanent removal of the horn stumps. After 1 to 2 days a thick impermeable crust is formed which encloses the dehorning wounds (Nantier, 2009). The temperature reached on the iron is kept for several minutes and is probably lethal to spores. Therefore, it is unlikely that the iron itself serves as a vector for *C.*

tetani (Dixit *et al.*, 2005). Environmental contamination of the dehorning wound with faecal material and dirt from the stable environment seems a more likely infection route (Driemeier *et al.*, 2006; Linnenbrink *et al.*, 2006). Additionally, the thermal treatment also causes the perfect circumstances for the creation of an anaerobic environment by destroying the blood vessels and creating a thick impermeable crust. These factors predispose to the growth and toxin production of *C. tetani* (Nitzschke *et al.*, 2008). Burning wounds are a well known risk for tetanus in humans whereas no reports in animals were found (Cassel *et al.*, 2002). This is the first time thermal dehorning is described as a cause of a tetanus infection. As this method is nowadays the standard dehorning procedure in Belgium and since most calves are not vaccinated against *C. tetani* for economical reasons, a higher incidence of tetanus outbreaks in future years might be possible.

Although the insertion of ear tags is routinely done in young ruminants, including goats, only one outbreak of tetanus in lambs following ear tag insertion at 7 to 8 days of age has been described (Aslani *et al.*, 1998). It is not clear whether the older age of the animal was a risk factor for the occurrence of tetanus. However, permethrin-impregnated ear tags are relatively frequently administered in cattle and small ruminants at older age and no cases of tetanus have been reported. Therefore, the occurrence of tetanus associated with ear tagging in this adult goat is likely an unfortunate incident.

A solid vaccination scheme for tetanus is the most effective preventive measure, both for adults as through maternal immunity in newborns (Gall *et al.*, 2011). Vaccination is advisable in highly susceptible species such as small ruminants and in animals with high economical or emotional value. Double primo-vaccination at minimally 8 and 12 weeks of age followed by yearly boosters provide a lasting protection later in life. Performing dehorning and ear tagging as clean as possible and local administration of antimicrobial sprays might decrease the risk. Inspection of the wounds a few days later and disinfection when necessary are advisable. The preventive application of antitetanus serum might be an option when ear tagging or dehorning valuable unvaccinated animals.

These cases illustrate the importance of a continued alertness when executing routine invasive interventions as ear tagging and dehorning. Although small ruminants are more sensitive than cattle and although extra attention should be given to tetanus prophylaxis when working with goats or sheep, tetanus may also occur in young cattle.

REFERENCES

Akbulut D., Grant G.A., McLauchlin J. (2005). Improvement in laboratory diagnosis of wound botulism and tetanus among injecting illicit-drug users by use of real-time PCR assays for neurotoxin gene fragments. *Journal of Clinical Microbiology* 43, 4342-4348

Aslani M. R., Bazargani T. T., Ashkar A.A., Movasaghi

A.R., Raoofi A., Atiabi N. (1998). Outbreak of tetanus in lambs. *Veterinary Record* 142, 518-519

Barbosa J.D., Dutra M.D., Oliveira C.M.C., Silveira J.A.S., Albernaz T.T., Cerqueira V.D. (2009). Outbreak of tetanus in buffaloes (*Buballus bubalis*) in Pará, Brazil. *Pesquisa Veterinaria Brasil* 29, 263-265

Cassel O.C.S., Fitton A.J., Dickson W.A., Milling M.A.E. (2002). An audit of the tetanus immunisation status of plastic surgery trauma and burns patients. *British Journal of Plastic Surgery* 55, 215-218

Dixit A., Alam S.I., Dhaked R.K., Singh L. (2005). Sporulation and heat resistance of spores from a *Clostridium* spp. RKD. *Journal of Food Science* 70, 367-373

Driemeier D., Schild A.L., Fernandes J. C. T., Colodel E.M., Correã A. M. R., Cruz C. E. F., Barros C. S. L. (2007). Outbreaks of tetanus in beef cattle and sheep in Brazil associated with disphenol injection. *Journal of Veterinary Medicine* 54, 333-335

Gall S.A., Myers J., Pichichero M. (2011). Maternal immunization with tetanus-diphtheria-pertussis vaccine: effect on maternal and neonatal serum antibody levels. *American Journal of Obstetrics and Gynecology* 204, 334

Gormley K., Gutowski N. (2004). Current outbreak of tetanus in intravenous drug users. *Journal of Neurology* 251, 157

Linnenbrink T., MacMichael M. (2006). Tetanus: pathophysiology, clinical signs, diagnosis, and update on new treatment modalities. *Journal of Veterinary Emergency and Critical Care* 16, 199-207

Nantier G. (2009). Dierenbelang vs economie. *Veeteeltvlees* 7, 6-9

Nitzschke A., Doll K. (2008). Tetanus in a heifer. *Tierärztliche Praxis* 36, 84-98

Poudel P., Budhathoki S., Manandhar S. (2009). Tetanus. *Kathmandu University Medical Journal* 7, 315-322

Stöber M. (2002). Tetanus. In: *Innere Medizin und Chirurgie des Rindes*. 4th Edition, Parey Buchverlag im Blackwell Verlag GmbH, Wien, 1068-1071

Sun K.O. (1994). Outbreak of tetanus among heroin addicts in Hong Kong. *Journal of the Royal Society of Medicine* 87, 494-495

Wernery U., Ul-Haq A., Joseph M., Kinne J. (2004). Tetanus in a camel (*Camelus dromedarius*) – A case report. *Tropical Animal Health and Production* 36, 217-224