

Accepted Manuscript

Right-sided representational neglect after left brain damage in a case without visuo-spatial working memory deficits

Jean-Philippe van Dijck, Wim Gevers, Christophe Lafosse, Wim Fias



PII: S0010-9452(13)00087-7

DOI: [10.1016/j.cortex.2013.03.004](https://doi.org/10.1016/j.cortex.2013.03.004)

Reference: CORTEX 1001

To appear in: *CORTEX*

Received Date: 1 June 2012

Revised Date: 1 December 2012

Accepted Date: 17 March 2013

Please cite this article as: Dijck J-Pv, Gevers W, Lafosse C, Fias W, Right-sided representational neglect after left brain damage in a case without visuo- spatial working memory deficits, *CORTEX* (2013), doi: 10.1016/j.cortex.2013.03.004.

This is a PDF file of an unedited manuscript that has been accepted for publication. As a service to our customers we are providing this early version of the manuscript. The manuscript will undergo copyediting, typesetting, and review of the resulting proof before it is published in its final form. Please note that during the production process errors may be discovered which could affect the content, and all legal disclaimers that apply to the journal pertain.

Running head: representational neglect and working memory

RIGHT-SIDED REPRESENTATIONAL NEGLECT AFTER LEFT BRAIN DAMAGE IN A CASE
WITHOUT VISUO- SPATIAL WORKING MEMORY DEFICITS

Jean-Philippe van Dijck¹, Wim Gevers², Christophe Lafosse³ and Wim Fias¹

¹Ghent University, Belgium

²Unité de Recherches en Neurosciences Cognitives, Université Libre de Bruxelles, Belgium

³Scientific Unit Rehabilitation Centre "Hof ter Schelde", Belgium

Corresponding author:

Jean-Philippe van Dijck
Faculty of Psychology and Educational Sciences

Department of Experimental Psychology

Henri Dunantlaan 2

B-9000 Gent

Phone: +32 9 264 64 33

Fax: +32 9 264 64 96

E-mail: jeanphilippe.vandijck@ugent.be

Abstract

Brain damaged patients suffering from representational neglect fail to report, orient to, or verbally describe contra-lesional elements of imagined environments or objects. So far this disorder has only been reported after right brain damage, leading to the idea that only the right hemisphere is involved in this deficit. A widely accepted account attributes representational neglect to a lateralized impairment in the visuospatial component of working memory. So far, however, this hypothesis has not been tested in detail. In the present paper, we describe, for the first time, the case of a left brain damaged patient suffering from right-sided representational neglect while imagining both known and new environments and objects. An in-depth evaluation of her visuospatial working memory abilities, with special focus on the presence of a lateralized deficit, did not reveal any abnormality. In sharp contrast, her ability to memorize visual information was severely compromised. The implications of these results are discussed in the light of recent insights in the neglect syndrome.

Keywords: Representational neglect, attention, spatial working memory, visual working memory, Corsi block tapping task

1. Introduction

Hemi-spatial neglect is a condition of attentional imbalance that is commonly observed after right brain damage. Patients suffering from this disorder have difficulties to report, respond and orient to stimuli in the contra-lesional left side of space (e.g. Driver and Mattingley, 1998), making hemi-spatial neglect a deficit strongly interfering with daily life activities. Since the seminal work of Bisiach and Luzzatti (1978), it is known that hemi-spatial neglect is not confined to the perceptual domain, but also extends to the domain of mental representations. This observation is called representational neglect (RN) and typically manifests when the patient describes familiar scenes (e.g. memorized picture, Beschin et al., 1997; famous squares, Bisiach and Luzzatti, 1978; Bisiach et al., 1979; the map of France, Rode et al., 2004), compares mental images of objects (e.g. a clock face, Grossi et al., 1989) or mentally navigates through topographic maps (Guariglia et al., 2005).

Albeit to a lesser degree and often less long lasting, hemi-spatial neglect has been observed in left brain damage (LBD) as well in which case it affects the right side of space (see Beis et al., 2004, for a quantitative and qualitative comparison). To our knowledge, however, only deficits in the perceptual domain have been reported in LBD patients and a detailed screening in a large group of LBD patients didn't find any patient establishing a right-sided RN (Bartolomeo et al., 1994; Halsband et al., 1985). The lack of convincing cases of right-sided RN in LBD, led to the generally accepted view that RN is a condition uniquely associated with right brain damage (e.g. Palermo et al., 2010b).

Despite these negative findings, there are good theoretical reasons to believe that right-sided RN after LBD might exist and that its diagnosis may have been missed. First, several neuroimaging studies in healthy subjects clearly support the idea that both left and right hemispheres are involved

in mental imagery as areas in both hemispheres show increased activation when people perform tasks that require the construction or inspection of mental images (e.g. Formisano et al., 2002; Kosslyn, 1987; Sack et al., 2005). Furthermore, it has recently been shown that even the mere short-term retention of spatial locations (an important prerequisite in mental imagery, Baddeley and Lieberman, 1980) involves the contribution of both hemispheres, with areas in the ventrolateral prefrontal cortex of each hemisphere responding to contralateral spatial positions (Rizzuto et al., 2005). This means that, in theory, brain damage lateralized to the left or the right hemisphere can give rise to representational problems for information that is presented in the contra-lesional visual field. Third, most tasks used to investigate RN (mainly variants of the scene description task) heavily draw upon verbal resources, which are typically compromised in the LBD patient population, especially in the acute phase when the neglect symptoms are most prominent. This makes it possible that RN remained unnoticed. Thorough screening for the presence of RN in a LBD patient suffering from chronic (perceptual) neglect with only mild linguistic impairments can be an interesting path to search for the existence of RN in LBD.

A widely accepted idea in the domain of mental imagery is that perception and mental imagery draw upon overlapping functional and neural resources (Ganis et al., 2004; Kosslyn et al., 1997). However, double dissociations between RN and perceptual neglect have been repeatedly observed (e.g. Beschin et al., 2000; Beschin et al., 1997; Cocchini et al., 2006; Coslett, 1997; Guariglia et al., 1993; Piccardi et al., 2008) clearly demonstrating that perceptual and RN can occur independently. Several accounts for RN exist. For example, RN has been attributed to a lateralized bias in exploring mental images (Grossi et al., 1989) or to problems in the processing of topographic information (Guariglia et al., 2005). These accounts, however, cannot easily explain the above-described dissociation between RN and perceptual neglect. An influential account that successfully deals with the double dissociation, places RN in the context of visuospatial working memory (VSWM; Beschin et al., 1997; Della Sala et al., 2004; Denis et al., 2002; Ellis et al., 1996).

According to the proponents of this account, there is a strong relationship between processes involved in mental representation and those involved in working memory. Following this idea, RN reflects a lateralized deficit in the visuospatial component of working memory which can occur independently from the attentional imbalance that affects the processing of perceptual space (Della Sala et al., 2004).

VSWM typically refers to the ability to maintain the location of different objects over time (e.g. Logie, 1995) and it has recently been proposed as an important factor in the neglect syndrome (Malhotra et al., 2005; Wojciulik et al., 2001). For the evaluation of VSWM, the Corsi block tapping task (CBT) is considered to be the prototypical task (e.g. Zimmer, 2008), also in clinical populations (see Berch et al., 1998 for a review). In the CBT task, subjects are required to observe and replicate the sequence of spatial locations tapped out by the examiner. Despite being considered as one of the most useful tools to evaluate VSWM (especially with “standard” forward-recall; e.g. Vandierendonck et al., 2004), the CBT task has rarely been used in the study of neglect patients because it is believed that the presence of neglect might have a negative effect on performance and therefore artificially underestimate VSWM capacity. Malhotra et al. (2005) circumvented this problem by using a vertical version of the CBT task. They observed that the majority (but not all) of the RBD neglect patients showed a reduced performance compared to control subjects in the vertical variant of CBT. This clearly suggests an important involvement of VSWM in the neglect syndrome. Yet, the functional role of VSWM in RN is to our knowledge not yet tested in detail. The few attempts that have addressed the issue focused on the capacity of VSWM but did not evaluate the existence of lateralized deficits in the keeping visuospatial information in working memory (e.g. Beschin et al., 1997; Palermo et al., 2010a; Piccardi et al., 2008). This is unfortunate because the presence of a lateralized deficit is crucial if VSWM is to be taken as the determining factor underlying RN. Furthermore, the isolated occurrence (i.e. dissociated from perceptual neglect) of a VSWM deficit in the context of RN, has to our knowledge never been reported, probably because RBD often gives rise

to a joint deficit in spatial attention and VSWM (Malhotra et al., 2005). From this perspective, the observation of RN after LBD would be a unique opportunity to shed further light on the functional relationship between VSWM and RN, because after LBD it is less likely to find a VSWM deficit.

In the present study we describe the investigation of GG, a 52-year-old right-handed woman who suffered from chronic right-sided perceptual neglect after LBD. Despite her extensive left-sided lesion, her language abilities were largely spared (with the exception of verbal working memory). Her preserved language production and comprehension skills make her an ideal candidate for detailed testing of the presence of RN. Because RN can manifest itself differently for mentally constructed environments and objects (Palermo et al., 2010a; Piccardi et al., 2008), a battery of RN tasks including scene description and the mental comparison of familiar and unfamiliar objects was administered. Furthermore, her VSWM capacity and the presence of selective problems in the maintenance of left and right-sided locations were investigated in detail. To do this, several computerized variants of the CBT were developed.

2. Patient GG

GG (°1955), a retired saleslady with 10 years of formal education had a sudden onset of neurological deficits in July 2007. CT scans (depicted in Fig. 1) revealed an ischemic left hemisphere lesion due to an obstruction of the left middle cerebral artery. General neuropsychological assessment revealed that GG had mild impairments in executive functioning and more pronounced and long lasting difficulties in verbal working memory (for an overview see Table 1). Interestingly, GG also showed pronounced deficits in visual working memory. On the Visual Patterns Test (VPT; Della Sala et al., 1999)), where she was asked to reproduce random patterns of colored squares on an empty grid of the same size as the one containing the to-be-memorized patterns, she could only reproduce the patterns of 2 by 2 grids (i.e. the lowest possible score for patients understanding the instructions). Additionally, she showed mild but chronic right-sided perceptual neglect in visual search,

cancellation and line bisection. Language was largely spared, as were her perceptual abilities. She showed 100% right-hand preference on the Dutch handedness questionnaire (Van Strien, 2002) and confirmed having been right handed all her life. Before participation, an informed consent form was signed. All investigations were approved by the local ethical committee and administered between October 2007 and June 2008. Importantly, the investigations on RN and working memory took place in parallel, ruling out the possibility that different recovery rates for both cognitive functions can explain the observed pattern of results.

===INSERT FIGURE 1 HERE ===

===INSERT TABLE 1 HERE ===

3. Experimental investigation 1: Representational neglect

To assess RN, four different tasks were administered. Two measured RN on what Piccardi et al. (2008) described as “cognitive maps of environmental space” and the other two measured object-based RN. For each category of task, one taps on knowledge that is acquired before the onset of the lesion and the other taps on newly acquired information.

Throughout the paper, we used the two-tailed significance test [*ST*] to compare GG’s individual scores to those of a small normative sample (Crawford and Howell, 1998). To evaluate the significance of the left/right asymmetries observed in GG, these scores were transformed into a laterality quotient (LQ; Bartolomeo et al., 1994) by means of the following formula:

$$LQ = 100 * \frac{\text{correct (or amount) on left side} - \text{correct (or amount) on right side}}{\text{correct (or amount) on left side} + \text{correct (or amount) on right side}}$$

In this way, a positive value is obtained when more elements on the left (compared to the right) are mentioned or correctly responded to. The LQ of GG was compared to that of healthy

controls (HCs). We recruited different groups of HCs in the different experimental investigations. Specifications of each group are given in the method section of the corresponding tests.

3. 1. Methods

3.1.1. Imaging map of Flanders

GG and 11 HCs (8 females; range: 50-72 year; average: 60; all living in the same province as GG) were asked to mentally imagine the map of Flanders as if they could see the map in front of them. They were asked to remember the map as presented during the weather forecasts on TV and in newspapers, with Brussels located at the bottom of the map. The instructions were to name as many towns or villages they could “see” within two minutes. No instructions were given on how to mentally scan the map (for a similar task see Rode et al., 2004).

3.1.2 Description of a novel scene from memory

GG and 8 HCs (8 females; range: 55-64 year; average: 58) received a picture of a previously unseen bedroom (aligned to their body midline), were asked to give a detailed description and were requested to memorize it. During this period, the named objects were recorded and categorized as belonging to the left or the right side of the room. After the participant indicated to be ready (no time limit was imposed), a retention interval of 10 minutes was initiated. Afterwards, the participants were encouraged to generate a mental image of this picture and to describe it from memory (for a similar task see Denis et al., 2002). As GG suffered from RN, we compared the amount of initially named objects (and not the actual amount) located on the left and on the right side of the room with the amount of left and right-sided items mentioned during recall. Both her performance and her LQ were compared to that of the HCs. In addition, GG also completed the task with a mirrored copy of the same picture 6 months later.

3.1.3 *O'clock task*

GG and 13 HCs (13 females; range: 52-64 year; average: 56) were asked to imagine clock faces of pairs of orally presented times and to report for which time the clock hands made the largest angle (see Grossi et al., 1989 for a similar task). Stimuli involved full and half hours. In half of the 32 trials, both hands of the clock were located in the right hemifield (e.g. 1:30 and 5:00) and in the other half they were located in the left hemifield (e.g. 11:30 and 8:00).

3.1.4. *Bisiach Ogden task*

GG and 10 HCs (10 females; range: 52-59 year; average: 55) completed this task which consisted of a same-different decision on two sequentially presented patterns (for a similar task see e.g. Bisiach et al., 1979; Ogden, 1985). The patterns were red geometric objects (approx. 7 by 7.5 cm) that moved centrally from right to left over the screen (velocity: 5.5cm/sec). To increase the need to build up a mental representation, the patterns were only partly visible as they moved along a slid (a central vertical portion of the screen of 4.5cm wide). Complete crossing of a single pattern took 1 to 1.5 seconds. The second pattern moved in the same direction and started after an inter-stimulus interval of 3 seconds. In total, 64 trials were presented. In half of the trials, the two patterns were different and those differences were located either on the left or the right side of the pattern an equal amount of times. We decided not to include a condition with patterns moving from left to right. This was done for two reasons. First, in the original study by Bisiach et al. (1979), this factor did not change the overall pattern of responses. Second, and more importantly, participants in Bisiach's study (1979) showed a strong positive recency effect, meaning that differences that are presented later are better detected. Hence, the right to left movement direction used in the current study should give rise to a recency effect for the right part of the patterns, thereby counteracting the presence of RN. In other words, if GG would show more difficulties in detecting right-sided differences, this would be strong evidence for the presence of RN. The instruction encouraged to postpone responding

until the second pattern had disappeared completely. GG and eight of the HCs performed the task twice while two of the HCs completed the task only once.

3.2. Results

3.2.1. Imagining map of Flanders

In total, GG mentioned 10 cities or villages, while the HCs on average 20.82 (SD=5.15) [$ST:p=.072$]. Interestingly when inspecting the geographic distribution, GG demonstrated a remarkable asymmetry. She reported 3 places from the left, 7 from the middle and no places from the right part of the map (see Figure 2). In contrast, HCs mentioned on average 4.91 (SD=2.66), 7.36 (SD=3.23) and 8.55 (SD=2.11) left, middle and right-sided places [$F(2,20)=5.75, p=.011$]. A direct comparison revealed that GG only differed from the HCs in the amount of right-sided places [$ST:p=.003$]. Further evaluation of this left/right asymmetry showed that her LQ was significantly different from that of the HCs (100 vs. -30 (SD=25)) [$ST:p<.001$]. To ensure that the right-sided omissions were not due to deficient long-term knowledge, she was asked to locate 44 geographical “entities” (towns, villages, rivers, regions; equally distributed over the map and matched in terms of salience) on a scheme of the map. Care was taken that the map was presented outside her neglected visual area. Here, no asymmetries were found (16/22 left-sided and 17/22 right-sided places were correctly located), supporting the conclusion that the described asymmetry reflects the presence of right-sided RN.

3.2.2. Description of a novel scene from memory

During the description of the picture GG and HCs mentioned about an equal number of elements (35 and 39.5 respectively; SD=10.81) [$ST:p=.706$]. During the memory phase, however, GG only recalled 63% (i.e. 22) of those elements whereas the HCs on average 82% (SD=9%)

[$ST:p=.087$]. Importantly, further analyses revealed that this lower overall recall was due to a reduction in the recall of right-sided elements. Whereas her left-sided performance was (with 13 of the 16 elements recalled) comparable to the HCs (81% vs. 81% (SD=0.11)) [$ST:p=1.00$], GG recalled only 47% (i.e. 9 of the 19) of the described right-sided elements whereas the HCs 83% (SD=12) [$ST:p=.025$]. Evaluation of this left/right asymmetry showed that her LQ of 26.34 was significantly larger compared to that of the HCs (-0.94; SD=9.18) [$ST:p=.026$], further confirming the presence of right-sided RN.

In the mirrored condition GG mentioned a total of 36 elements during the memorization phase. Again during recall her performance was asymmetrical as she recalled 70% (i.e. 16 of the 23) left-sided items and only 54% (i.e. 7 of the 13) of the right-sided items. Thus when taking both conditions together, her recall performance for the same side of the picture was much higher when it was presented on the left (81% and 70%), compared to the situation where it was presented on the right (47% and 54%). Importantly, overall this discrepancy between left and right was significant [$Chi^2(1),p=.034$].

3.2.3. O'clock task

For the hours with the clock hands on the left, 11 out of 16 trials were correctly answered by GG, whereas only 7 out of 16 trials were correct for the times with the hands on the right side of the clock face. Both for the left as for the right side, her performance was lower compared to the HCs [$both\ ST's:p<.021$] who on average responded 14.15 (SD=1.14) and 14.69 (SD=1.25) of the left and right-sided hours correctly. Importantly, GG's LQ was 22.22. A statistical comparison with the LQ of the HCs further confirmed the presence of right RN as her LQ was significantly larger compared to the average of the HCs (-1.84 (SD=5.75)) [$ST:p=.002$].

3.2.4. Bisiach Ogden task

For the identical pairs GG's performance was within the normal range (GG: 91% vs HCs: 95% (SD=6%)) [$ST:p=.550$], indicating that she was able to perceive the entire objects properly (for a discussion about the potential influence of perceptual neglect in this task see Bisiach, 1993; Bisiach and Rusconi, 1990). For the pairs containing a difference, GG was correct in 81% of the cases, a score which was lower compared to the HCs (96% (SD=4%)) [$ST:p<.003$]. Again an asymmetry was observed when the accuracy for trials differing on the left and right side were evaluated separately. Whereas her left-sided performance was comparable to the HCs (88% vs. 96% correct (SD=4%)) [$ST:p=.089$], her performance was worse on the trials differing on the right side (75% vs. 96% correct (SD=5%)) [$ST:p=.002$]. Evaluation of this left/right asymmetry showed that her LQ of 7.69 was significantly larger compared to that of the HCs (0.02 (SD=2.58)) [$ST:p=.020$], indicating the presence of right-sided RN.

==INSERT FIGURE 2 HERE ==

4. Experimental investigation 2: Visuospatial working memory

During the general neuropsychological evaluation conducted just before the onset of the experimental investigations, GG obtained a normal score on the traditional horizontal Corsi block tapping task (CBT). To have an up to date estimation of GG's VSWM capacity, she and 11 age and sex matched HCs (range: 52–58 years; mean: 53) completed a computerized version of the (horizontal) CBT (see van Dijck et al., 2009 for a similar task) halfway the period of investigations. Her VSWM span was again within the normal range (5 vs. 4.55 (SD=0.69) for the HCs) [$ST:p=.549$].

As mentioned in the introduction, however, evaluation of the role of VSWM in the context of RN should not be limited to capacity estimation. Because RN reflects a lateralized deficit, it should

also be tested whether her ability to retain visuospatial information is different for elements located on the left or on the right side of space. For this purpose, we developed two computerized variants of the CBT, a probe recognition task and a position recall task¹.

4.2. Methods

4.2.1. Probe recognition

GG and the same 11 HCs who participated in the CBT (see above) were instructed to memorize series of spatial locations successively presented on a screen for 1000 msec with 500 msec between successive locations. Spatial locations were indicated by black squares (3 by 2.5 cm) presented on an imaginary matrix encompassing the entire computer screen (14 inch). Depending on the individual span level, this matrix could have 5 to 7 columns and 5 rows. To indicate the locations to be remembered, a square appeared in a randomly selected cell of every column. To disentangle presentation order from spatial location, the spatial sequences were presented from left to right in half of the trials or from right to left in the other half of the trials (intermixed during the experiment). Upon completion of the sequence, a 2000 msec interval elapsed, allowing for rehearsal. Subsequently, a probe location appeared and the task was to determine whether it was part of the memorized sequence (in 50% of the cases) by pressing a left or right mouse button (response mapping was counterbalanced across subjects; GG pressed the left button when the probe was part of

¹ One concern for the use of Corsi-like tasks is that they easily can be solved by means of verbal strategies. We believe however, that GG's extreme low verbal working memory capacities makes it very unlikely that GG adopted such strategy (for detailed description her verbal working memory capacity see van Dijck et al., 2011).

the memorized sequence). Furthermore, each presented probe was selected from each column with equal probability. Both GG and HCs performed this task at span + 1 (GG: span level=5; 72 trials, HCs: average span=4.55; SD=0.69; 60-72 trials). For all subjects, accuracy was stressed and no time constraints were imposed. The midpoint of the screen was aligned to the body midline of the subjects.

4.2.2. Recall of spatial positions

The experimental setup of this task was identical to that of the spatial recognition task with the exception that a digit replaced the probe. This digit referred to a position in the memory sequence and the aim was to manually indicate (with the mouse) the location corresponding to this position on the screen. In case the presented sequences consisted of an odd number of positions, the middle position was additionally requested with the question to indicate the midpoint of the sequence. GG performed this task with sequences of five items (span level; 30 trials; a larger sequence length resulted in chance level performance) while 10 age and sex matched HCs (range: 52-58 years; average: 55 years) performed the task at span + 1 level (average span=4.6; SD=0.52; 30-48 trials).

4.3. Results

4.3.1. Probe recognition

Overall GG responded correctly in 67% of the trials, a performance comparable to that of the HCs who were on average correct in 74% (SD=16%) of the trials [*ST*:*p*=.686]. To identify possible asymmetries in the retention of visuospatial information, the data were collapsed as a function of the location on the screen (left or right). In case the sequence had an odd amount of elements, the middle element was not included in the analyses. As illustrated in Figure 3, GG correctly recognizes 61% of the left-sided and 56% of the right-sided match probes and correctly rejected 72% of the left-sided

and 78% of the right-sided no-match probes. A comparison with the HCs did not reveal any difference in performance [*ST: all p's > .300*] as they correctly recognized on average 72% (SD=18%) of the left-sided and 75% (SD=17%) of the match probes and correctly rejected 75% (SD=13%) of the left-sided and 76% (SD=12%) of the right-sided no-match probes. Thus, even in the case where GG had to remember sequences exceeding her VSWM capacity, no remarkable or consistent asymmetries were found in her recognition performance.

4.3.2. Recall of spatial positions

Overall GG responded correctly in 25 of the 30 trials². Again, the data were collapsed as a function of the location on the screen: left, middle or right (10 trials each). She correctly recognized 8 of the left-sided items, 8 of the middle and 9 of the right-sided items. This pattern of performance was very similar to that of the HCs. On average they responded correctly in 77% (SD=9%) of the trials. For both the left- and right-sided locations, they responded correctly in 81% (SD=9%) of the trials, while their performance on the middle locations was 68% (SD=13%); 81% (SD=9%). Thus again, GG didn't show any remarkable deficiency or asymmetry when recalling positional information from spatial working memory.

=== INSERT FIGURE 3 HERE ===

5. General Discussion

We describe the investigation of a right-handed woman who suffered from right-sided representational neglect (RN) for mental environments and objects after a CVA of the left hemisphere. Disconfirming the idea that RN is caused by a deficit in visuospatial working memory (VSWM; e.g. Della Sala et al., 2004), detailed investigations of these abilities with variants of the Corsi block tapping task (CBT) did not reveal any abnormality with respect to VSWM capacity nor

² No statistical comparisons were reported since the task administered in the HCs was not matched in sequence length.

was any left-right asymmetry detected in her VSWM. Importantly, GG showed a reduced capacity of verbal working memory mainly affecting the initial elements of verbal sequences (see van Dijck et al., 2011 for a detailed report of these findings). Given that the initial elements of a working memory sequence are associated with left and end elements with right (van Dijck and Fias, 2011), this directional asymmetry in verbal working memory is opposed to the side of her RN, making interpretations that assume a non-spatial origin of her RN unlikely. Furthermore, GG's RN was also present in tasks drawing upon knowledge that was available before lesion onset (i.e. map description and o'clock task), making it unlikely that her RN was caused by symptoms of perceptual neglect encountered during learning of such new spatial information.

While right-sided perceptual neglect after left brain damage has been reported before (LBD; see Beis et al., 2004 for a review), right-sided RN was not. Contradicting the common conception that (contralesional) RN is a symptom uniquely associated with RBD (e.g. Palermo et al., 2010b), the present study is the first to describe right-sided RN after LBD. Previously, some LBD patients with indications of RN have been reported, but none of them can be considered as decisive evidence. For example, Caramazza and Hillis (1990) reported a LBD patient suffering from right-sided neglect dyslexia (in writing, spelling and reading) who also omitted right-sided elements when drawing objects from memory. Likewise, Pia et al. (2009) described a LBD patient showing right-sided neglect for the mental number line, who also omitted right-sided elements when assessed with similar drawing tasks. Recent studies, however, indicate that phenomena like neglect dyslexia, mental number line neglect and lateralized deficits in drawing from memory are not necessarily good indices of RN. For example a lateralized deficit in drawing can result from the interplay between representational and perceptual difficulties which are difficult to disentangle (Chokron et al., 2004) and neglect dyslexia and neglect for the mental number line can have a pure non-spatial origin (Aiello et al., 2012; Greenwald and Brendt, 1999; van Dijck et al., 2011). Finally, in a group study including 4 left brain damaged patients, Ogden (1985) investigated the presence of RN with the

“Bisiach Ogden” task and reported that they showed relative neglect for the right side. A careful look at the data, however, reveals that at the group level, the laterality quotient (LQ) of this group didn’t differ significantly from the LQ of the HCs. At the individual level, the data of one of the patients could be indicative for the presence of right-sided RN, but unfortunately not enough statistics are provided to evaluate the performance of this patient with the appropriate (more recently developed) single-case analyses methods (e.g. Crawford et al., 2003). The only study reporting a LBD patient with a lateralized asymmetry in “classic” RN- tasks was provided by Cocchini et al. (2006). Contrary to what would be expected from the location of the lesion, however, this patient suffered from ipsi-lesional (left-sided) as opposed to contra-lesional neglect. Against the background of the studies reported above, GG is the first clear case of a patient showing contra-lesional RN after LBD in tasks that are considered as “classical” RN tasks.

At this point, it is difficult to determine why we made such an observation, while other attempts (e.g. Bartolomeo et al., 1994) failed to do so. In LBD, neglect symptoms are most prominent in the acute phase, and often disappear with time (e.g. Beis et al., 2004). LBD also commonly results in severe language difficulties, again most prominent in the acute phase. So a possibility could be that the language deficits hinder proper measurement of RN during the phase that the RN symptoms are present. After all, in the typical RN tasks instructions and responses are given verbally. In this respect, our patient GG might be rather unique in that she suffered from LBD and long lasting neglect, but did not show severe difficulties in language production and comprehension, so that she could easily understand the instructions and formulate her responses at the time the neglect symptoms were present.

Besides a demonstration of the existence of RN in a LBD patient, the present study also provides evidence that VSWM, as operationalized by the CBT, is not functionally involved in GG’s RN. Indeed, despite difficulties in detecting right-sided differences and describing right-sided details of mental images, GG performed normally when asked to memorize sequences of spatial locations.

Of course, the observation of a normal capacity does not tell anything about her premorbid level (which could have been higher). But, the lack of left-right asymmetries, even when the working memory load exceeded her capacity, suggests that a decrease of premorbid levels of capacity is not an alternative explanation. Together, these findings contradict the hypothesis that RN is the result of a deficit in VSWM (e.g. Della Sala et al., 2004) and urge for prudence to use the CBT as an operationalization of VSWM. After all, it is difficult to see how information can be mentally “visualized” without the need of some kind of visuospatial short- term retention system.

If deficient VSWM is not at the origin of GG’s RN, the question remains what could have caused it. Recently, Palermo et al. (2010) investigated the nature of imagery deficits in two patients suffering from RN. The first patient showed RN in the o’clock task but showed symmetrical performance when describing a familiar geographical location, whereas the second patient performed normally in the o’clock task, but showed RN in the description of a geographical location. To investigate the differential nature of the RN in both patients, they developed a battery of visual imagery tests to assess the different aspects of the imagery process. They found that the first patient showed impairments in the mental generation, inspection and manipulation of objects, while he performed normally on tasks addressing the mental generation, inspection and manipulation of environments. The second patient showed impairments in the mental generation, inspection and manipulation of environments but not of objects. Based on these findings it was concluded that environments and objects can be mentally represented separately and can thus also be selectively affected by brain damage. Similarly, Piccardi et al. (2008) described a RBD patient with pure left-sided RN (i.e. without neglect for physical space) when describing familiar scenes from memory but not in the o’clock task. Because in their patient, RN was only observed in scene description, a task where a topological map needs to be generated, they attributed the RN to difficulties in (perceptual) navigation, a domain in which this patient also showed severe difficulties. Interestingly, both the patients described by Palermo et al. (2010) and by Piccardi et al. (2008) obtained a normal score on

the CBT, but as mentioned earlier the presence of left-right asymmetries in recall was not evaluated. Although we didn't test GG's navigational abilities or her different skills in mental imagery, she showed RN for both objects and environments. This would mean that in her case, both the "imagery systems" for environments and objects are damaged. Importantly, further investigations are needed to understand how this account can explain the lateralized deficit typically observed in RN.

Another alternative explanation for RN was recently proposed by Cocchini et al. (2006). To explain the ipsi-lesional left-sided RN after LBD in their patient, RN was attributed to a deficit in building up mental images in working memory (rather than to difficulties in the exploration of it). Indeed, theories on mental imagery (e.g. Kosslyn, 1994) posit that the left hemisphere is involved in the generation of mental images (Farah, 1984; Farah et al., 1988) whereas the right hemisphere is engaged during the manipulation or exploration of these images (Kosslyn, 1987). Interestingly, in line with the idea that rehearsal and maintenance of visuospatial information draws upon visual attentional mechanisms (the attention based rehearsal account, see Postle et al., 2004), GG's intact performance on the CBT (both in terms of capacity and the spatial distribution of resources) suggests that she can adequately encode (i.e. perceptually) and mentally explore both left and right sides of the memorized visuospatial layout. This leaves open the possibility that in GG, RN is caused by a generation rather than by an exploration deficit in working memory. Importantly again, it remains unclear how damage to the left hemisphere can give rise to a lateralized rather than a general deficit in the generation of mental images.

When directly comparing the nature of the CBT and the RN tasks used in the present study, it becomes clear that in the CBT, the to-be-memorized information is sequential in nature, while in the RN tasks, a picture-like (of scenes or objects) mental image needs to be built up and explored. This difference is reminiscent to the subdivision made between spatial working memory and visual working memory, where spatial working memory reflects the ability to maintain (sequential) spatial locations, and visual working memory the ability to remember (simultaneous) visual, picture-like

content. Although most often observed together, damage to either of these WM components can occur in isolation (e.g. Della Sala et al., 1999). Whereas GG's sequential (Corsi like) spatial working memory was preserved, she performed weakly when simultaneously presented dots had to be recalled as in the Visual Pattern Test (i.e. the Visual Pattern Test; Della Sala et al., 1999). Within the context of the working memory account for RN (e.g. Della Sala et al., 2004), this might indicate that her RN is attributable to a deficit in visual rather than spatial working memory. Of course also for visual working memory (VWM), a reduced capacity does not demonstrate the presence of a lateralized deficit and is insufficient as evidence for the causal involvement of VWM. Unfortunately, given that this hypothesis was raised after experimentation, no systematic screening for the presence of such asymmetries was done. We believe, however, that the current set of data contains some hints with regard to this issue. From all the RN tasks used in this study, the Bisiach Ogden task is conceptually most similar to a visual working memory task because visually presented unfamiliar shapes need to be kept active in working memory before being compared with subsequent ones. In this task, she also missed more right-sided compared to left-sided details. We acknowledge this limited empirical proof and the hypothetical nature of our explanation, but we believe that the interpretation of RN in the context of VWM as a refining of the existing WM account for RN deserves further empirical investigation. Promising in this respect are recent findings from an fMRI study in healthy subjects that showed that similar to spatial attention, also VWM shows an hemispheric gradient with the right hemisphere being more specialized in the retention of visual information of the left and right visual field, and the left hemisphere for visual information in the right visual field (Sheremata et al., 2010).

A potential point of concern could be the atypical lateralization of function in GG. It is common to refer to the right hemispheric dominance for spatial attention (e.g. Corbetta and Shulman, 2002) and left hemispheric dominance for language (e.g. Ojemann, 1991). Deviations from this pattern are possible, mostly in left handed subjects (e.g. Floel et al., 2001). Evidence for atypical lateralization in GG is mixed. Aspects in favor of atypical lateralization are the finding that she didn't

suffer from clear language deficits and showed long lasting neglect (Beis et al., 2004), despite her left-sided lesion comprising frontal, temporal and parietal areas. On the other hand, GG's profile of working memory impairments is in line with what could be expected from a typically lateralized brain. She showed impairments in verbal and visual working memory, which both rely on left hemisphere areas, while her SWM, which primarily activates the right hemisphere, is within the normal range (Henson, 2000; Smith et al., 1996). Specially developed behavioral tests (e.g. dichotic listening) or functional imaging will be needed to draw final conclusions about her lateralization. We are convinced, however, that this concern only restricts the interpretation of the anatomical-functional mapping of our results. From a cognitive point of view, atypical lateralization may offer a unique opportunity to investigate whether certain cognitive processes, that otherwise share anatomically neighboring neural substrates (which are often affected together in case of brain damage), are strictly necessary for specific tasks. In this perspective, it is well possible that it is precisely GG's potential atypical lateralization that has helped us to draw the conclusions at hand.

In conclusion, we believe that the present study offers the first description of clear right-sided representational neglect after left brain damage. Furthermore, it showed that the working memory account for representational neglect (e.g. Della Sala et al., 2004) needs refinement, and that prudence is desirable to consider the Corsi block tapping task as the only operationalization of visuospatial working memory. Furthermore we propose that a deficit in visual working memory can be at the base of representational neglect, but acknowledge that further empirical work (preferentially in group studies) is needed to further support this idea.

6. Acknowledgments

We wish to thank GG for her outstanding enthusiasm and motivation to participate in the study. In addition we like to express our gratitude towards Massimo Silvetti, Anand Ramamoorthy and Paolo Bartolomeo for their useful comments and discussions during the writing of the manuscript. This

work was supported by the Ghent University Multidisciplinary Research Partnership “The integrative neuroscience of behavioral control” and by grant P7/11 from the Inter University Attraction Poles program of the Belgian federal government.

7. References

Aiello M, Jacquin-Courtois S, Merola S, Ottaviani T, Tomaiuolo F, Buetti D, Rossetti Y, and Doricchi F. No inherent left and right side in human "mental number line": Evidence from right brain damage. *Brain*, 135 (8):2492-2505, 2012.

Albert ML. A simple test of visual neglect. *Neurology*, 23:658-665, 1973.

Baddeley AD and Lieberman K. Spatial working memory. In Nickerson R (Ed.), *Attention and Performance, vol. VIII*. Hillsdale: Lawrence Erlbaum, 1980: 521-539

Bartolomeo P, Derme P, and Gainotti G. The relationship between visuospatial and representational neglect. *Neurology*, 44 (9):1710-1714, 1994.

Beis JM, Keller C, Morin N, Bartolomeo P, Bernati T, Chokron S, Leclercq M, Louis-Dreyfus A, Marchal F, Martin Y, Perennou D, Pradat-Diehl P, Prairial C, Rode G, Rousseaux M, Samuel C, Sieroff E, Wiart L, Azouvi P, and Gerin G. Right spatial neglect after left hemisphere stroke - qualitative and quantitative study. *Neurology*, 63 (9):1600-1605, 2004.

Benton AL, Varney NR, and Hamsher KS. Visuospatial judgment. *Archives of Neurology*, 35:364-367, 1978.

Berch DB, Krikorian R, and Huha EM. The corsi block-tapping task: Methodological and theoretical considerations. *Brain and Cognition*, 38 (3):317-338, 1998.

Beschin N, Basso A, and Della Sala S. Perceiving left and imagining right: Dissociation in neglect. *Cortex*, 36 (3):401-414, 2000.

Beschin N, Cocchini G, DellaSala S, and Logie RH. What the eyes perceive, the brain ignores: A case of pure unilateral representational neglect. *Cortex*, 33 (1):3-26, 1997.

Bisiach E. Mental representation in unilateral neglect and related disorders - the 20th bartlett memorial lecture. *Quarterly Journal of Experimental Psychology Section a- Human Experimental Psychology*, 46 (3):435-461, 1993.

Bisiach E, Luzzatti C. Unilateral neglect of representational space. *Cortex*, 14 (1):129-133, 1978.

Bisiach E, Luzzatti C, and Perani D. Unilateral neglect, representational schema and consciousness. *Brain*, 102 (SEP):609-618, 1979.

Bisiach E and Rusconi ML. Break-down of perceptual awareness in unilateral neglect. *Cortex*, 26 (643-649), 1990.

Buschke H and Fuld PA. Evaluating storage, retention, and retrieval in disordered memory and learning. *Neurology*, 24:1019-1025, 1974.

Caramazza A and Hillis AE. Spatial representation of words in the brain implied by studies of a unilateral neglect patient. *Nature*, 346 (6281):267-269, 1990.

Chokron S, Colliot P, and Bartolomeo P. The role of vision in spatial representation. *Cortex*, 40:281-290, 2004.

Cocchini G, Bartolo A, and Nichelli P. Left ipsilesional neglect for visual imagery: A mental image generation impairment? *Neurocase*, 12 (3):197-206, 2006.

Corbetta M and Shulman GL. Control of goal-directed and stimulus-driven attention in the brain. *Nature Reviews Neuroscience*, 3 (3):201-215, 2002.

Coslett HB. Neglect in vision and visual imagery: A double dissociation. *Brain*, 120:1163-1171, 1997.

Crawford JR, Garthwaite PH, and Gray CD. Wanted: Fully operational definitions of dissociations in single-case studies. *Cortex*, 39 (2):357-370, 2003.

Crawford JR and Howell DC. Comparing an individual's test score against norms derived from small samples. *Clinical Neuropsychologist*, 12 (4):482-486, 1998.

Della Sala S, Gray CD, Baddeley AD, Allamano N and Wilson L. Pattern span: A tool for unwinding visuo-spatial memory. *Neuropsychologia*, 37 (10):1189-1199, 1999.

Della Sala S, Logie RH, Beschin N, and Denis M. Preserved visuo-spatial transformations in representational neglect. *Neuropsychologia*, 42 (10):1358-1364, 2004.

Denis M, Beschin N, Logie RH, and Della Sala S. Visual perception and verbal descriptions as sources for generating mental representations: Evidence from representational neglect. *Cognitive Neuropsychology*, 19 (2):97-112, 2002.

Doricchi F and Tomaiuolo F. The anatomy of neglect without hemianopia: A key role for parietal-frontal disconnection? *Neuroreport*, 14 (17):2239-2243, 2003.

Driver J and Mattingley JB. Parietal neglect and visual awareness. *Nature Neuroscience*, 1 (1):17-22, 1998.

Ellis AX, DellaSala S and Logie RH. The bailiwick of visuo-spatial working memory: Evidence from unilateral spatial neglect. *Cognitive Brain Research*, 3 (2):71-78, 1996.

Farah MJ. The neurological basis of mental-imagery - a componential analysis. *Cognition*, 18 (13):245-272, 1984.

Farah MJ, Hammond KM, Levine DN, and Calvanio R. Visual and spatial mental-imagery - dissociable systems of representation. *Cognitive Psychology*, 20 (4):439-462, 1988.

FEPSY. *The iron psyche. Manual*. Nederlands Insituut voor Epilepsiebestrijding: Heemstede, The Netherlands, 1995.

Floel A, Knecht S, Lohmann H, Deppe M, Sommer J, Drager B, Ringelstein EB, and Henningsen H. Language and spatial attention can lateralize to the same hemisphere in healthy humans. *Neurology*, 57 (6):1018-1024, 2001.

Formisano E, Linden DEJ, Di Salle F, Trojano L, Esposito F, Sack AT, Grossi D, Zanella FE, and Goebel R. Tracking the mind's image in the brain i: Time-resolved fmri during visuospatila mental imagery. *Neuron*, 35 (1):185-194, 2002.

Ganis G, Thompson WL, and Kosslyn SM. Brain areas underlying visual mental imagery and visual perception: An fmri study. *Cognitive Brain Research*, 20 (2):226-241, 2004.

Gauthier L, Dehaut F, and Joanette Y. The bells test - a quantitative and qualitative test for visual neglect. *International Journal of Clinical Neuropsychology*, 11 (2):49-54, 1989.

Graetz P, De Bleser R, and Willmes K. *Akense afasietest*. Swets & Zeitlinger: Lisse, 1992.

Greenwald M, and Brendt R. Impaired encoding of abstract letter order: Severe alexia in a mildly aphasic patient. *Cognitive Neuropsychology*, 16 (6):513-556, 1999.

Grossi D, Modafferi A, Pelosi L, and Trojano L. On the different roles of the cerebral hemispheres in mental-imagery - the o'clock test in 2 clinical cases. *Brain and Cognition*, 10 (1):18-27, 1989.

Guariglia C, Padovani A, Pantano P, and Pizzamiglio L. Unilateral neglect restricted to visual-imagery. *Nature*, 364 (6434):235-237, 1993.

Guariglia C, Piccardi L, Iaria G, Nico D, and Pizzamiglio L. Representational neglect and navigation in real space. *Neuropsychologia*, 43:1138-1143, 2005.

Halsband U, Gruhn S, and Ettliger G. Unilateral spatial neglect and performance in one half of space. *International Journal of Neuroscience*, 28:173-195, 1985.

Heaton RK, Chelune GJ, Talley JL, Kay GG, and Curtiss G. *Wisconsin card sorting test manual: Revised and expanded (wcst)*. Psychological Assessment Resources (PAR): Odessa, FL., 1993.

Henson R. Neural working memory. in: Andrade J (Ed.), *Working memory in perspective*. Psychology Press: Hove, 2000. pp. 151-174.

Kaplan E, Goodglass H, and Weintraub S. *The boston naming test*, 2nd ed. Lea & Febiger: Philadelphia, 1983.

Kosslyn SM. Seeing and imagining in the cerebral hemispheres - a computational approach. *Psychological Review*, 94 (2):148-175, 1987.

Kosslyn SM. *Image a brain*. MIT Press: Cambridge MA, 1994.

Kosslyn SM, Thompson WL, and Alpert NM. Neural systems shared by visual imagery and visual perception: A positron emission tomography study. *Neuroimage*, 6 (4):320-334, 1997.

Lezak MD. *Neuropsychological assessment*, 3rd ed. Oxford University Press: New York, 1995.

Logie R. *Visuo-spatial working memory*. Lawrence Erlbaum: Hove, 1995.

Malhotra P, Jager HR, Parton A, Greenwood R, Playford ED, Brown MM, Driver J, and Husain M. Spatial working memory capacity in unilateral neglect. *Brain*, 128:424-435, 2005.

Ogden JA. Contralesional neglect of constructed visual images in right and left brain-damaged patients. *Neuropsychologia*, 23 (2):273-277, 1985.

Ojemann GA. Cortical organization of language. *Journal of Neuroscience*, 11 (8):2281-2287, 1991.

Palermo L, Nori R, Piccardi L, Giusberti F, and Guariglia C. Environment and object mental images in patients with representational neglect: Two case reports. *Journal of the International Neuropsychological Society*, 16:921-932, 2010a.

Palermo L, Piccardi L, Nori R, Giusberti F, and Guariglia C. Does hemineglect affect visual mental imagery? Imagery deficits in representational and perceptual neglect. *Cognitive Neuropsychology*, 27 (2):115-133, 2010b.

Pia L, Corazzini LL, Folegatti A, Gindri P, and Cauda F. Mental number line disruption in a right-neglect patient after a left-hemisphere stroke. *Brain and Cognition*, 69 (1):81-88, 2009.

Piccardi L, Bianchini F, Zompanti L, and Guariglia C. Pure representational neglect and navigational deficits in a case with preserved visuo-spatial working memory. *Neurocase*, 14 (4):329-342, 2008.

Postle BR, Awh E, Jonides J, Smith EE, and D'Esposito M. The where and how of attention-based rehearsal in spatial working memory. *Cognitive Brain Research*, 20 (2):194-205, 2004.

Reitan RM and Wolfson D. *The halstead-reitan neuropsychological test battery: Theory and clinical interpretation*, 2nd ed. Neuropsychology Press: Tucson, AZ., 1993.

Riddoch MJ and Humphreys GW. *The birmingham object recognition battery (borb)*. Erlbaum: London, 1993.

Rizzuto DS, Mamelak AN, Sutherling WW, Fineman I and Andersen RA. Spatial selectivity in human ventrolateral prefrontal cortex. *Nature Neuroscience*, 8 (4):415-417, 2005.

Rode G, Rossetti Y, Perenin MT and Boisson D. Geographic information has to be spatialised to be neglected: A representational neglect case. *Cortex*, 40 (2):391-397, 2004.

Sack AT, Camprodon JA, Pascual-Leone A, and Goebel R. The dynamics of interhemispheric compensatory processes in mental imagery. *Science*, 308 (5722):702-704, 2005.

Schenkenberg T, Bradford DC, and Ajax ET. Line bisection and unilateral visual neglect in patients with neurologic impairment. *Neurology*, 30 (5):509-517, 1980.

Sheremata SL, Bettencourt KC, and Somers DC. Hemispheric asymmetry in visuotopic posterior parietal cortex emerges with visual short-term memory load. *Journal of Neuroscience*, 30 (38):12581-12588, 2010.

Smith A. *Symbol digit modalities test (sdmt). Manual (revised)*. Western Psychological Services: Los Angeles, 1982.

Smith EE, Jonides J, and Koeppel RA. Dissociating verbal and spatial working memory using pet. *Cerebral Cortex*, 6 (1):11-20, 1996.

Stroop J. Studies of interference in serial verbal reactions. *Journal of Experimental Psychology*, 18:643-662, 1935.

van Dijck J-P and Fias W. A working memory account for spatial numerical associations. *Cognition*, 119 (1):114-119, 2011.

van Dijck J-P, Gevers W, and Fias W. Numbers are associated with different types of spatial information depending on the task. *Cognition*, 113:248-253, 2009.

van Dijck J-P, Gevers W, Lafosse C, Doricchi F, and Fias W. Non-spatial neglect for the mental number line. *Neuropsychologia*, 49 (9):2570-2583, 2011.

Van Strien JW. Classification of left- and right-handed research participants. *Tijdschrift voor de Psychologie*, 47:88-92, 2002.

Vandierendonck A, Kemps E, Fastame MC, and Szmalec A. Working memory components of the corsi block task. *British Journal of Psychology*, 95:57-79, 2004.

Vos P. *Bourdon- vos test: The manual*, 2nd ed. Swets & Zeitlinger: Lisse, 1992.

Warrington EK and James M. *The visual object and space perception battery*. Thames Valley Test: Bury St. Edmunds, Suffolk, 1991.

Wilson BA, Alderman N, Burgess PW, Emslie H, and Evans J. *Behavioral assessment of dysexecutive syndrome*. Thames Valley Test Company, 1996.

Wilson BA, Cockburn JM, and Halligan PW. Development of a behavioral-test of visuospatial neglect. *Archives of Physical Medicine and Rehabilitation*, 68 (2):98-102, 1987.

Wojciulik E, Husain M, Clarke K, and Driver J. Spatial working memory deficit in unilateral neglect. *Neuropsychologia*, 39 (4):390-396, 2001.

Zimmer HD. Visual and spatial working memory: From boxes to networks. *Neuroscience and Biobehavioral Reviews*, 32 (8):1373-1395, 2008.

Table 1. Overview of the general neuropsychological assessment

| | Administered tasks | Raw score | Interpretation | |
|----------------------------|--|---|--|--------|
| Perception | Auditory perception | | | |
| | <i>Seashore Rhythm test</i> ¹ | 12/12 | Normal | |
| | Visual object recognition | | | |
| | <i>Effron-figures for visual form perception</i> <i>Visual Object and Space Perception Battery (VOSP)</i> ² <i>Birmingham Object Recognition Battery (BORB)</i> ³ | No inaccurate responses No inaccurate responses No inaccurate responses | Normal Normal Normal | |
| Visuospatial perception | <i>Dot Counting (VOSP)</i> | No inaccurate responses | Normal | |
| | | | | |
| Memory | Verbal | | | |
| | <i>Letter span (forward)</i> ²⁰ <i>Letter span (backward)</i> <i>Buschke Selective Reminding test</i> ⁴ | Sequence length= 3 Sequence length= 3 Total recall= 89; z=-3.4 | Impaired Impaired Impaired | |
| | Visual/ spatial | | | |
| | <i>Visual Patterns Test</i> ⁵ <i>Corsi</i> ²⁰ | Score=2; <pc.05 Sequence length= 5 | Impaired Normal | |
| Attention | Focused attention | | | |
| | <i>Bourdon-Vos Cancellation</i> ⁶ <i>Symbol Digit Modalities test (SDMT)</i> ⁷ <i>Computerised Visual Search Task (FEPSY)</i> ⁸ | 4 omissions; z=-1 n=40; z=-1.2 Mean time= 3.86; <dc.1 | Borderline Borderline Impaired | |
| | Sustained attention | <i>Continuous Performance task (FEPSY)</i> | Hit rate= 0.87; pc.50 | Normal |
| | Spatial attention | | | |
| | <i>Schenkenberg Line Bisection</i> ⁹ <i>Albert Line Cancellation</i> ¹⁰ <i>Star Cancellation</i> ¹¹ <i>Bell Cancellation</i> ^{12*} <i>Benton Line Orientation test</i> ¹³ | Left= 2%dev; Centre= -4%dev; Right=-7%dev Omissions left=0; right=3 Omissions left=0; right=4 Omissions Left=1; Right= 5 Nr. correct=13 | Impaired Borderline Borderline Impaired Borderline | |
| | <i>Aachen Aphasia Test</i> ¹⁴ <i>Boston Naming task</i> ¹⁵ | Normal score on all subtests No inaccurate responses | Normal Normal | |
| Executive functions | | | | |
| | <i>Behavioural assessment of Dysexecutive syndrome (BADS)</i> ¹⁶ <i>Stroop Color-Word Test</i> ¹⁷ <i>Wisconsin Card Sorting test</i> ¹⁸ <i>Tower of London</i> ¹⁹ | Total profile score=15; z=-1 Interference score=66; pc. 1 Number of perseverations :6 Total scaled score=15 | Borderline Impaired Borderline Normal | |

¹(Reitan and Wolfson, 1993), ²(Warrington and James, 1991), ³(Riddoch and Humphreys, 1993), ⁴(Buschke and Fuld, 1974), ⁵(Della Sala et al., 1999), ⁶(Vos, 1992), ⁷(Smith, 1982), ⁸(FEPSY, 1995), ⁹(Schenkenberg et al., 1980), ¹⁰(Albert 1973), ¹¹(Wilson et al., 1987), ¹²(Gauthier et al., 1989)* this task was administered at the end of the experimental investigations, ¹³(Benton et al., 1978), ¹⁴(Graetz et al., 1992), ¹⁵(Kaplan et al., 1983), ¹⁶(Wilson et al., 1996), ¹⁷(Stroop, 1935), ¹⁸(Heaton et al., 1993), ¹⁹(Lezak, 1995 p. 657), ²⁰ The method and procedure of both the letter and the Corsiblock span are described in van Dijck, Gevers and Fias (2009). For the purpose of this study, data from a age and sex matched HCs (age range: 52-58 years; mean=53 years) were collected. A comparison of GG's performance with the performance of the HCs (verbal span= 5.36 ST:p=.05), SD=1.03; spatial span=4.55, SD=0.69;ST:p=0.54). Reprinted from Neuropsychologia, Vol. 49, van Dijck, Gevers, Lafosse, Doricchi &

Fias, Non-spatial neglect for the mental number line, Pages 2570-2583., Copyright (2011), with permission from Elsevier.

ACCEPTED MANUSCRIPT

Figure 1: CT scans

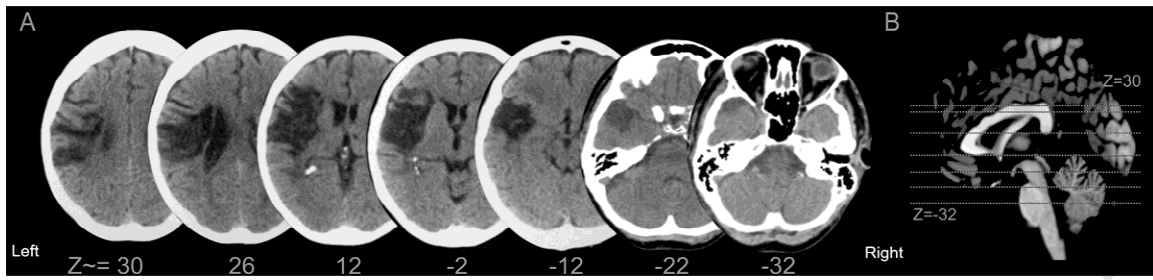
A: GG's CT scans, acquired two months after the onset of the stroke, revealed a massive ischemic left hemisphere lesion due to an obstruction of the left middle cerebral artery. These scans show that besides a clear prefrontal involvement, the lesion extends to the very ending part of the descending sector of the intra-parietal sulcus at its junction with the post-central sulcus. This cortical-subcortical area is typically damaged in neglect (e.g. Doricchi and Tomaiuolo, 2003). Figure 1B: The anatomical references are given for the different depicted slices to have a better view on the extension of the lesion. Reprinted from *Neuropsychologia*, Vol. 49, van Dijck, Gevers, Lafosse, Doricchi & Fias, Non-spatial neglect for the mental number line, Pages 2570-2583, Copyright (2011), with permission from Elsevier.

Figure 2. Results of the map of Flanders task

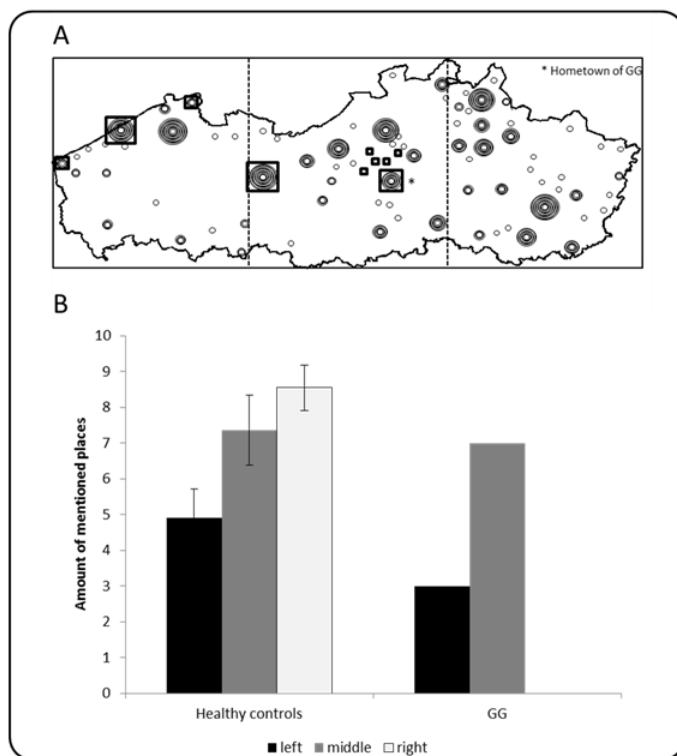
(A) The reconstruction of the map of Flanders described from mental imagery by GG and the healthy controls (HCs). Each circle on the figure indicates a named town/ village plotted on an outline of Flanders. The magnitude of each dot reflects the amount of times this place is mentioned by the HCs. GG's responses are indicated by black squares. (B) Distribution of the named places in relation to their location on the map for GG and the HCs. The error bars reflect the standard error of mean across the HCs.

Figure 3. Results of the spatial probe recognition task

The bars on the left represent the percentage of correctly recognized left and right-presented spatial locations. The bars on the right reflect the amount of correctly rejected left and right-presented no-match trials. Errors bars give the standard error of the mean across subjects for the HCs.



ACCEPTED MANUSCRIPT



ACCEPTED

