

Semen collection, assessment and artificial insemination in the cat

T. Rijsselaere, A. Van Soom

Department of Reproduction, Obstetrics and Herd Health,
Faculty of Veterinary Medicine, Ghent University,
Salisburylaan 133, B-9820 Merelbeke, Belgium

tom.rijsselaere@ugent.be

ABSTRACT

The first successful artificial insemination in cats was described 40 years ago. However, the insemination in cats is at present not as commonly performed in daily veterinary practice as the insemination in dogs due to the practical difficulties in collecting a sperm sample from the tomcat, the small volume of the sperm obtained, the few possibilities to determine the optimal timing of insemination and the need for ovulation induction and sedation of the queen. Recently, a new and practical method has been described for sperm collection, using urethral catheterization after sedation of the tomcat with medetomidine. Sperm can subsequently be inseminated in the vagina or directly into the uterus by laparotomy or transcervical catheterization.

INTRODUCTION

Up till recently, the reproduction in cats has hardly been studied, despite the fact that the reproductive cycle of the cat is unique in a number of aspects, such as the induced ovulation and the sequence of events in the course of natural mating. In recent decades however, a considerable amount of new information has been published, mainly due to the increased interest in cat reproduction in daily practice and due to the use of the cat as a research model for endangered wild felids and for several human pathologies (Axner and Lindforsberg, 2002). The first successful artificial insemination (AI) in cats was described 40 years ago by Sojka *et al.* (1970). Subsequently, several research groups worldwide published new information although AI in cats is at present not as commonly performed as AI in dogs in daily veterinary practice. The main reasons to perform an insemination in the cat are (1) if natural mating is impossible due to anatomical, physiological or behavioral problems, (2) the preservation (chilled or frozen) and subsequent transport of genetic material of valuable breeding animals and (3) the research and use of information obtained in the domestic cat for the conservation of endangered wild felids.

SPERM COLLECTION

Various techniques have been described for sperm collection in cats: artificial vagina, electroejaculation, urethral catheterization after sedation with medetomidine and retrieval of epididymal sperm.

Artificial vagina

A trained tomcat mounts a queen in heat and grasps her in the neck to fix her (Figure 1). Subsequently,

sperm is collected by using a small artificial vagina consisting of a 2 ml rubber bulb-pipette and a small test tube which is placed in a water bottle at 37°C (Sojka *et al.*, 1970). However, not all tomcats allow this procedure and if they allow it, they have mostly been trained for this procedure since puberty. Consequently, this method is largely restricted to universities or research facilities with large breeding colonies of queens and trained tomcats but it is difficult to apply with tomcats that are presented only occasionally in daily practice.

Electroejaculation

The tomcat is anesthetized by using medetomidine (80-100 µg/kg IM) and ketamine (5 mg/kg IM) (Platz and Seager, 1978). After the removal of feces a probe with 3 electrodes is inserted 6 to 8 cm into the rectum

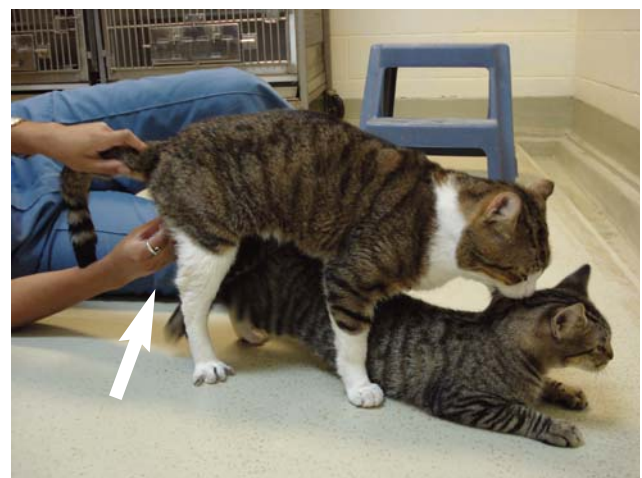

Figure 1. Sperm collection in a tomcat using an artificial vagina. The trained male mounts the queen in heat, fixing her in the neck while an artificial vagina is inserted over the penis to collect the sperm (see arrow).




Figure 2. A. Electroejaculator with a rectal probe containing 3 electrodes; B: Technique of electroejaculation in the cat (the probe is inserted in the rectum while an Eppendorf tube is placed over the top of the penis to collect the semen).

(Figure 2A and B). Subsequently, a series of electrical stimuli is applied (e.g. 80 stimuli of 2, 3 and 4V in 3 successive series) which makes the tomcat to ejaculate. By using this method sperm can be collected without any previous training or the presence of a queen in heat. Moreover, this procedure can be applied in every male which can be safely anesthetized but is ethically questionable and is therefore prohibited in several countries. Moreover, the required equipment is expensive and many cat owners and breeders are reluctant to apply this method.

Urethral catheterization

This recently developed technique requires the sedation of the tomcat using medetomidine (100-150 µg/kg; Zambelli *et al.*, 2007, 2008; Filliers *et al.*, 2010), which stimulates the α_2 -adrenergic receptors and allows the release of a small volume of highly concentrated sperm from the cauda epididymis in the urethra. Subsequently, the sperm is collected by using a urinary catheter (Buster® Cat Catheter, 1.0 mm x 13.0 cm), with its tip cut to get a shorter, open-ended catheter which is inserted approximately 9 cm into the urethra, taking care not to reach the bladder. Subsequently, the catheter is removed from the urethra and the semen sample is collected. Immediately after collection, the sperm sample is placed in a pre-warmed Eppendorf tube with a diluent. Currently, this method is probably the most practical and the least invasive procedure for sperm collection in tomcats in daily practice.

Epididymal sperm

After castration the testicles and epididymi are collected and placed in a petridish. The epididymi are separated from the testicles, incised repeatedly using a scalpel after which the spermatozoa are allowed to disperse during 10 minutes in the surrounding medium (Hepes TALP or physiological saline solution; Filliers *et al.*, 2008). Finally, the medium with the spermatozoa is collected and purified by density gradient centrifugation (such as Percoll® or Isolate®).

Table 1. Sperm quality parameters in the tomcat (Axner and Linde-Forsberg, 2002).

Parameter	Value
Volume	0.03-0.3 ml
Concentration	100-5000 x 10 ⁶ /ml
Sperm/ejaculate	3-160 x 10 ⁶
Motility	56-85%
Normal morphology	38-95%

This procedure is rather easy to perform and is routinely performed in laboratories for *in vitro* fertilization experiments (Filliers *et al.*, 2008). Additionally, it can be used for genetically valuable tomcats that unexpectedly died.

SPERM EVALUATION

After the collection, the quality of the semen sample is evaluated by assessing the main sperm parameters, i.e. the concentration, motility, morphology and the membrane integrity. The concentration can be measured by means of a counting chamber (Bürker or Thoma), the motility by using subjective assessment of the percentage motile and progressively motile spermatozoa on a pre-warmed glass slide and the morphology and membrane integrity on e.g. eosin/nigrosin or diff-quick stained slides. Recently, several new techniques for sperm assessment have been described in cats, such as computer assisted sperm analysis and fluorescent stainings, which allow a more detailed sperm assessment (Filliers *et al.*, 2008, 2010). One of the most important disadvantages for the sperm evaluation in the tomcat however is the very low volume of the ejaculate, which limits the number of sperm evaluations dramatically. Moreover, up till now, the 'cut-off values' for sperm quality in cats have hardly been studied and defined, and the relation between sperm quality and *in vivo* fertility is not completely clear (Table 1). Finally, the sperm quality is influenced by the season (Axner and Linde-Forsberg, 2002).

Table 2. Pregnancy results obtained after AI in the cat with fresh and frozen-thawed semen.

Type of Sperm	Deposition Site	Number of cats	Sperm dose	Pregnancy rate	References
Fresh	Vaginal	26	5-50x10 ⁶	40-67%	Sojka <i>et al.</i> , 1970
Fresh	Vaginal (2x)	8	5x10 ⁶	77%	Sojka <i>et al.</i> , 1970
Fresh	Vaginal	9	80x10 ⁶	77.8%	Tanaka <i>et al.</i> , 2000
Fresh	Intra-uterine	10	8x10 ⁶	80%	Tsutsui <i>et al.</i> , 2000
Frozen	Vaginal	56	50-100x10 ⁶	10.6%	Platz and Seager, 1978
Frozen	Intra-uterine	14	50x10 ⁶	57%	Tsutsui <i>et al.</i> , 2000
Frozen	Intra-uterine	12	20x10 ⁶	41.7%	Chatdarong <i>et al.</i> , 2007

TIMING OF AI AND INDUCTION OF OESTRUS

The insemination in queens can be performed during natural or induced heat with a subsequent induction of the ovulation by using e.g. hCG (100-250 IU) on the second or third day of the estrus. AI during natural heat is preferable because the gonadotropins used for the induction of heat may cause an inappropriate maternal response. The ovulation in cats generally occurs 24-48 hours after coitus (Shille *et al.*, 1983). After the determination of the optimal moment by means of

behavioral changes and/or vaginal cytology, AI can be performed on the second day of the estrus with a second AI 2 days later (Chatdarong *et al.*, 2002).

ARTIFICIAL INSEMINATION

After the collection and evaluation, mostly fresh spermatozoa are inseminated. However, cat semen can be conserved either chilled at 4-5°C for several days or cryopreserved at -196°C for a long period, which makes (inter)national transport and the use of the genetic material of valuable breeding animals possible (Zambelli *et al.*, 2008).

To perform AI successfully in cats, the basic knowledge of the female genital tract is required. During the estrus, the vestibulum, vagina and cervix measure 20.2 ± 3.3, 26.8 ± 3.9 and 1.2 ± 0.1 mm, respectively (Zambelli and Cunto, 2005). The insemination can be performed in the vagina or directly into the uterus. General anesthesia or sedation is required in both cases. Intravaginal AI is performed by inserting a needle (9 cm long - 20 G) with a bulb on the tip (Sojka *et al.*, 1970) or by a nylon probe (9 cm long - 1.5 mm diameter) and a stainless probe (9 cm long - 2 mm diameter) into the anterior part of the narrow and non-distensible vagina (Tanaka *et al.*, 2000). The animals are in dorsal recumbency (up to 20 minutes after AI) with the hind quarters elevated to improve the transport of the spermatozoa into the uterus.

Intrauterine AI can be obtained by performing a laparotomy and direct injection of the spermatozoa into the uterus of an anesthetized queen by means of a syringe and a small needle (25G) (Tsutsui *et al.*, 2000). Although this procedure is easy to perform, it is considered invasive and unethical and is therefore prohibited in several countries. Alternatively, several techniques have been described using specific types of transcervical catheters and a speculum (Figure 3), which requires practice to master. Zambelli and Cunto (2005) successfully applied a transcervical intra-uterine technique with the aid of transrectal digital manipulation (Figure 3D). The latter technique takes only several minutes to perform but requires an extensive training period.

PREGANCY RESULTS

The results that can be obtained by AI in the cat are variable and depend on many factors, such as the type

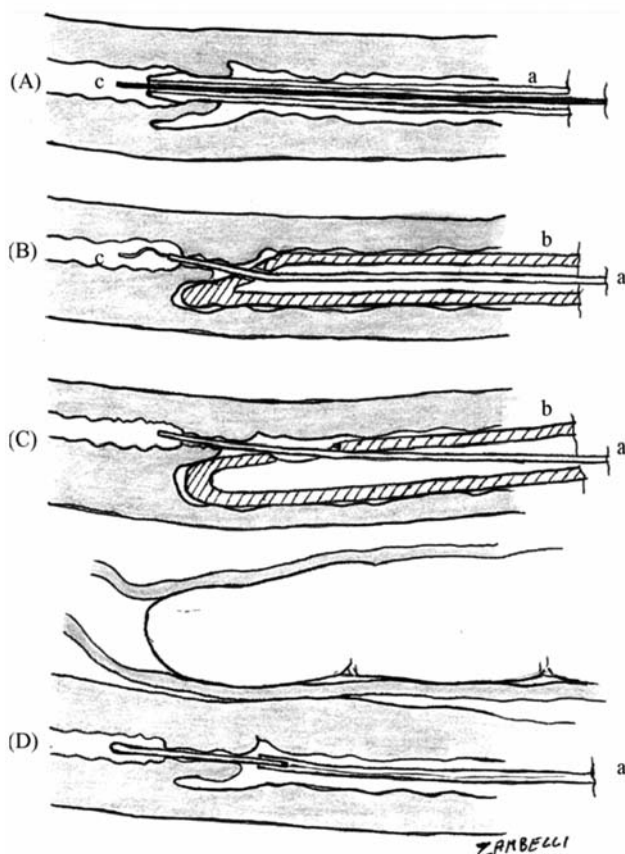


Figure 3. Several methods for intra-uterine AI in cats using a transcervical catheter of 1 to 2.7 mm (a) and a speculum (b) described by (A) Hurlbut *et al.* 1988, (B) Swanson *et al.*, 1994, (C) Chatdarong *et al.*, 2001, (D) Zambelli *et al.*, 2005.

(Picture Reprinted from Transcervical artificial insemination in the cat. Zambelli D., Cunto M. (2005). *Theriogenology* 64, 698-705. Copyright (2005), with permission from Elsevier).

of semen used (fresh, chilled or frozen), the site of insemination (intravaginal or intrauterine), the number of inseminated spermatozoa, the quality of the spermatozoa. Moreover, studies published on the results obtained after AI in the cat are scarce and frequently include only a small number of animals. In Table 2, the results that can be obtained by AI in cats are summarized. In general, the results obtained after AI with fresh semen are acceptable, whereas the results after AI with frozen semen are at present poor. The number of spermatozoa necessary to obtain acceptable pregnancy rates (75-80%) is lower when the sperm is inseminated directly into the uterus than in the case of intravaginal insemination. Intrauterine AI is therefore recommended for cryopreserved and poor quality semen.

REFERENCES

- Axnér E., Forsberg L. (2002). Semen collection and assessment, and artificial insemination in the cat. In: Concannon *et al.* (Editors). *Recent Advances in Small Animal Reproduction*. International Veterinary Information Service (www.ivis.org), Ithaca, New York, p.1-9.
- Chatdarong K., Lohachit C., Ponglowhapan S., Linde-Forsberg C. (2001). Transcervical catheterization and cervical patency during the estrus cycle in domestic cat. *Journal of Reproduction and Fertility Supplements* 57, 353-356.
- Chatdarong K., Kampa N., Axner E., Linde-Forsberg C. (2002). Investigation of cervical patency and uterine appearance in domestic cats by fluoroscopy and scintigraphy. *Reproduction in Domestic Animals* 37, 275-281.
- Chatdarong K., Axnér E., Manee-In S., Thuwanut P., Linde-Forsberg C. (2007). Pregnancy in the domestic cat after vaginal or transcervical insemination with fresh and frozen semen. *Theriogenology* 68, 1326-1333.
- Filliers M., Rijsselaere T., De Causmaecker V., Bossaert P., Dewulf J., Pope C.E., Van Soom A. (2008). Computer-assisted semen analysis of fresh epididymal cat spermatozoa and the impact of cooled storage (4°C) on sperm quality. *Theriogenology* 70, 1550-1559.
- Filliers M., Rijsselaere T., Bossaert P., Zambelli D., Anastasi P., Hoogewijs M., Van Soom A. (2010). In vitro evaluation of fresh sperm quality in tomcats: a comparison of two collection techniques. *Theriogenology* 74, 31-39.
- Hurlbut S.L., Bowen M.J., Kraemer D.C. (1988). The feasibility of transcervical catheterization and nonsurgical embryo collection in the domestic cat. *Theriogenology* 29, 264.
- Platz C.C., Seager S.W. (1978). Semen collection by electroejaculation in the domestic cat. *Journal of American Veterinary Medicine Association* 173, 1353-1355.
- Shille V.M., Munro C., Farmer S.W., Papkoff H., Stabenfeldt G.H. (1983). Ovarian and endocrine responses in the cat after coitus. *Journal of Reproduction and Fertility* 69, 29-39.
- Sojka N.J., Jemings L.L., Hamner C.E. (1970). Artificial insemination in the cat (*Felis catus*). *Laboratory Animal Care* 20, 198-204.
- Swanson W.F., Godke R. (1994). Transcervical embryo transfer in the domestic cat. *Laboratory Animal Science* 44, 288-291.
- Tanaka A., Takagi Y., Nakagawa K., Fujimoto Y., Hori T., Tsutsui T. (2000). Artificial intravaginal insemination using fresh semen in cats. *The Journal of Veterinary Medical Science* 62, 1163-1167.
- Tsutsui T., Tanaka A., Takagi Y., Nakagawa K., Fujimoto Y., Murai M., Anzai M., Hori T. (2000). Unilateral intrauterine horn insemination of fresh semen in cats. *The Journal of Veterinary Medical Science* 62, 1241-1245.
- Zambelli D., Cunto M. (2005). Transcervical artificial insemination in the cat. *Theriogenology* 64, 698-705.
- Zambelli D., Cunto M., Prati F., Merlo B. (2007). Effects of ketamine or medetomidine administration on quality of electro-ejaculated sperm and on sperm flow in the domestic cat. *Theriogenology* 68, 796-803.
- Zambelli D., Prati F., Cunto M., Iacono E., Merlo B. (2008). Quality and in vitro fertilizing ability of cryopreserved cat spermatozoa obtained by urethral catheterization after medetomidine administration. *Theriogenology* 69, 485-490.