

Electrocardiography in horses – part 2: how to read the equine ECG

Elektrocardiografie bij paarden – deel 2: interpretatie van het EKG

T. Verheyen, A. Decloedt, D. De Clercq, P. Deprez, S. U. Sys, G. van Loon

Department of Large Animal Internal Medicine
Faculty of Veterinary Medicine, Ghent University
Salisburylaan 133, 9820 Merelbeke, Belgium

Tinne.Verheyen@UGent.be

ABSTRACT

The equine practitioner is faced with a wide variety of dysrhythmias, of which some are physiological. The recording of an exercise electrocardiogram (ECG) can help distinguish between physiological and pathological dysrhythmias, underlining the importance of exercise recordings.

The evaluation of an ECG recording should be performed in a highly methodical manner in order to avoid errors. Each P wave should be followed by a QRS complex, and each QRS complex should be preceded by a P wave.

The classification of dysrhythmias according to their origin helps to understand the associated changes on the ECG. In this respect, sinoatrial nodal (SA nodal), atrial myocardial, atrioventricular nodal (AV nodal) and ventricular myocardial dysrhythmias can be distinguished.

Artefacts on the ECG can lead to misinterpretations. Recording an ECG of good quality is a prerequisite to prevent misinterpretations, but artefacts are almost impossible to avoid when recording during exercise. Changes in P or T waves during exercise also often lead to misinterpretations, however they have no clinical significance.

SAMENVATTING

De paardendierenarts wordt geconfronteerd met een waaier van dysritmieën, waarvan sommige fysiologisch zijn. Een elektrocardiogram (EKG) tijdens inspanning kan helpen om een onderscheid te maken tussen fysiologische en pathologische dysritmieën, wat het belang van opnamen tijdens inspanning onderstreept.

De evaluatie van een EKG moet volgens een strikte werkwijze verlopen om fouten te vermijden. Een vuistregel is dat elke P-golf moet worden gevolgd door een QRS-complex, en elk QRS-complex moet voorafgegaan worden door een P-golf.

De classificatie van dysritmieën volgens hun oorsprong helpt de veranderingen die deze veroorzaken op het EKG te verklaren. Op deze manier kunnen dysritmieën met een oorsprong in de sinusknoop, het atriale myocard, de atrioventriculaire knoop of het ventriculaire myocard worden onderscheiden.

Artefacten kunnen leiden tot misinterpretaties. Aan de basis van het vermijden van misinterpretaties ligt een EKG-opname van goede kwaliteit, maar tijdens inspanning kunnen artefacten bijna niet vermeden worden. Veranderingen in P- en T-golven die optreden tijdens inspanning, leiden vaak ook tot verkeerde interpretaties maar hebben geen enkele klinische betekenis.

INTRODUCTION

Due to their high vagal tone, horses have a higher incidence of cardiac dysrhythmias at rest than any other domestic species (Hamlin, 1972; Young, 2004). These physiological dysrhythmias are usually abolished when the vagal tone decreases and the sympathetic tone increases, such as during exercise or excitement (Senta *et al.*, 1970). On the other hand, exercise may exacerbate certain dysrhythmias making the recording of an exercise ECG an indispensable part of a cardiac diagnostic work-up.

In this paper a schematic approach for ECG interpretation is presented and the typical characteristics of common dysrhythmias are described. Finally, common pitfalls are discussed.

Standard approach to ECG interpretation

Before all, one should assess the quality of the recording and the sufficiency for accurate diagnosis. Overinterpretation of artefacts from a poor quality recording is a commonly made mistake.

In order to avoid errors, the evaluation of the ECG recording should be performed in a methodical manner (Patteson, 1996). The heart rate, heart rhythm, the correlation between P waves and QRS complexes, the morphology of P waves and QRS complexes and the duration of the different complexes and intervals should be evaluated.

At rest, the horse's heart rate ranges between 24 to 50 beats per minute (bpm) (Reef, 1985; Fregin, 1992), increasing to a maximum of 220–240 bpm during exer-

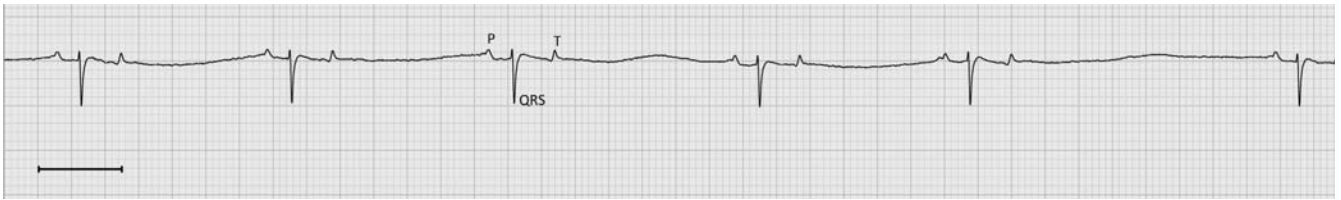

Figure 1. Sinus bradycardia. Heart rate is below 24 bpm but every P wave is followed by a QRS complex and every QRS complex is preceded by a P wave. The line bar indicates 1 second.

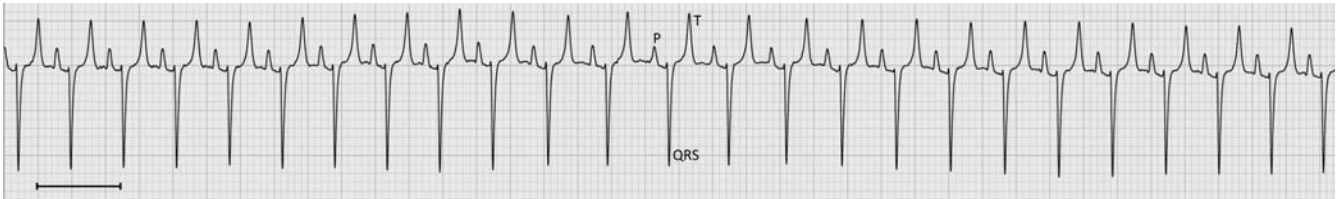


Figure 2. Sinus tachycardia. Heart rate is above 50 bpm but every P wave is followed by a QRS complex and every QRS complex is preceded by a P wave. The line bar indicates 1 second.

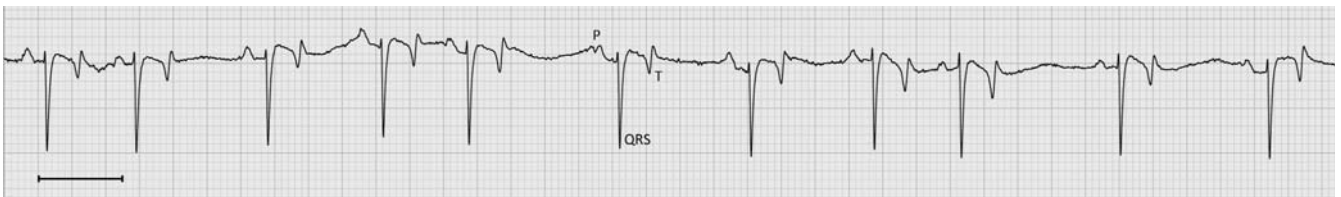

Figure 3. Sinus arrhythmia. RR intervals are irregular but every P wave is followed by a QRS complex and every QRS complex is preceded by a P wave. The line bar indicates 1 second.

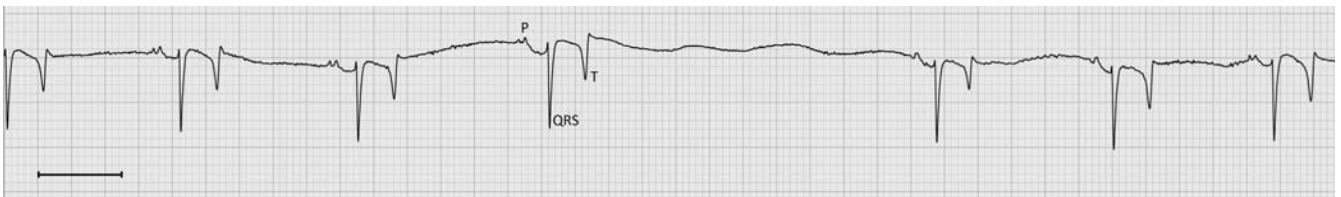


Figure 4. Sinus block. RR interval is equal to 2 normal RR intervals. The line bar indicates 1 second.

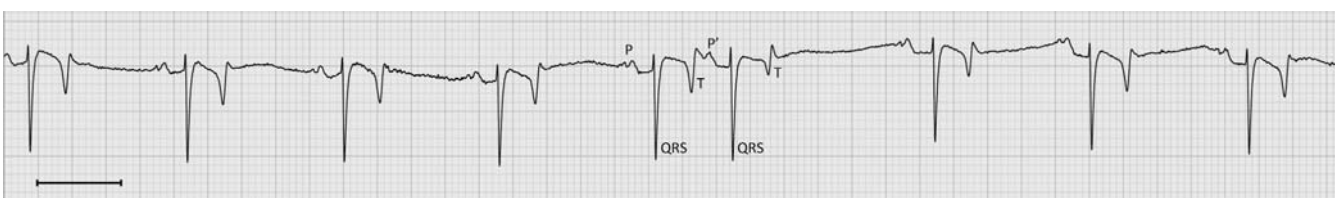

Figure 5. Atrial premature contraction. The P' wave occurs prematurely and is followed by a normal QRS-T complex. There is a non compensatory pause which indicates that the SA node is reset. The line bar indicates 1 second.

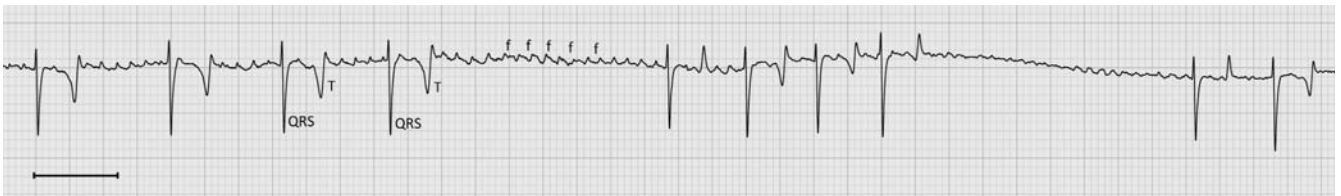

Figure 6. Atrial fibrillation. P waves are absent, f waves with a variable morphology are present, the QRS morphology and duration are normal but RR intervals are irregular. The line bar indicates 1 second.

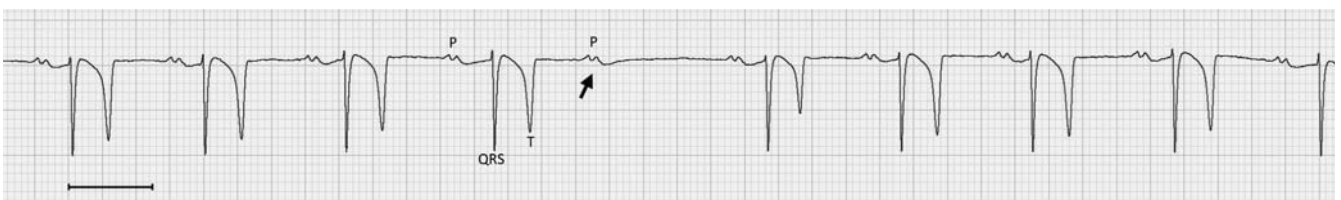


Figure 7. Second degree AV block, Mobitz type I. PQ interval lengthens until one P wave is not followed by a QRS complex (arrow). PP interval is regular. The line bar indicates 1 second.

cise. Heart rates below 24 bpm are called bradycardia, those above 50 bpm tachycardia (Fregin, 1992). Computer software facilitates the calculation of beat-to-beat intervals. However, depending on heart rate and electrode position, the tall T wave of the equine ECG is commonly mistaken for a QRS complex by the commercial software. For this reason, manual inspection of the analysis remains compulsory.

Heart rhythm is assessed to determine whether it is regular or irregular although small deviations in the RR interval are physiological. It has been suggested that RR variations of more than 8-20% should be considered as abnormal (Nørgaard, 2008). This threshold for dysrhythmia detection can be preset in computer software. When the threshold is set low, the sensitivity for true irregularities is high, but many physiological RR variations will also be indicated. If irregularities are present, their nature should be investigated: are they intermittent or persistent, do they occur at random or do they follow a possibly predictable pattern, are they induced or terminated by any form of excitement (Patteson, 1996)?

The final step is to assess the morphology and duration of the different waves, and the relation between waves. Each complex should have the same morphology. Each P wave should be followed by a QRS complex and each QRS complex should be preceded by a P wave. On the ECG, premature waves are usually indicated by an apostrophe ('), e.g. P' for indicating the P wave of an atrial premature complex, and QRS' for indicating a ventricular premature complex.

Classification of dysrhythmias

Dysrhythmias can be classified according to their origin in sinoatrial nodal (SA nodal), atrial myocardial, atrioventricular nodal (AV nodal) or ventricular myocardial dysrhythmias.

SA nodal dysrhythmias

The SA node, as the natural pacemaker of the heart, can fire too slow, too fast or at irregular intervals, leading to SA nodal dysrhythmias.

Sinus bradycardia

Sinus bradycardia is a rare condition that is usually associated with a physiological high vagal tone, although it can also be pathologic in nature. In those cases sinus bradycardia may lead to poor performance. The distinction between physiological or pathological sinus bradycardia is made by recording an exercise ECG. When caused by a high vagal tone, it is abolished by exercise, whereas in pathological bradycardia the chronotropic response is attenuated (Young, 2004).

Sinus bradycardia is diagnosed when the RR intervals are regular but the heart rate is below 24 bpm. All waves and complexes have a normal appearance and the relation between P waves and QRS complexes is normal (Figure 1). However, other vagal-induced

dysrhythmias, such as sinus arrhythmia and 2nd degree AV block, may be present concurrently.

Sinus tachycardia

Sinus tachycardia is caused by an increase in sympathetic tone or a decrease in parasympathetic tone and can be a physiological response in order to increase cardiac output. When it is seen at rest, the animal might have an increased sympathetic tone, caused by e.g. fever, hemorrhage, anemia, shock or heart failure (Fregin, 1992).

Sinus tachycardia is characterized by a resting heart rate above 50 bpm, with regular RR intervals. The morphology, duration and relation of P waves and QRS complexes are normal (Figure 2). At higher rates, P waves may be masked by the preceding T wave.

Sinus arrhythmia

Sinus arrhythmia is a periodic waxing and waning of the heart rate, caused by alterations in vagal tone (Hilwig, 1977; Fregin, 1992). It can occur in resting horses but appears much more frequently during the recovery period following exercise. Usually, the rhythm becomes regular again when the heart rate slows down to resting level. The condition is considered physiological but should disappear with a decreasing parasympathetic or increasing sympathetic tone, e.g. during exercise (Patteson, 1996).

On an ECG, sinus arrhythmia is characterized by varying PP and RR intervals. P-QRS relations are normal (McGuirk and Muir, 1985) and QRS complexes always have a normal morphology, but the shape of the P wave can be variable (Hilwig, 1977) (Figure 3). The heart rate can be normal, but is usually between 50 and 110 bpm. Sometimes sinus arrhythmia can have a more or less cyclic pattern, starting with a long RR interval, followed by a number of shortening RR intervals, until a long RR appears again.

Sinus (exit) block and sinus arrest

Sinus block and sinus arrest are characterized by long pauses during which there are no P-QRS-T complexes. A high vagal tone is considered to be the underlying cause of these dysrhythmias, preventing the depolarization to exit the sinus node (sinus block) or interrupting the firing rate of the SA node (sinus arrest) (Buchanan, 1965). They are infrequent and rarely pathological. Similar to sinus arrhythmia, these dysrhythmias are usually vagal induced and should disappear during exercise. In rare cases, cardiac output can drop to such a low level that syncope can develop.

Horses with sinus block and sinus arrest have a slow to normal heart rate. Characteristic on the ECG is that the PP and RR intervals are equal to (sinus block) or greater than (sinus arrest) 2 normal PP or RR intervals (McGuirk and Muir, 1985; Fregin, 1992). All other aspects of the ECG are normal: the morphology of P waves and QRS complexes is normal, every P

wave is followed by a QRS complex and every QRS complex is preceded by a P wave (Figure 4). During a long pause however, a junctional or ventricular escape beat may occur on the ECG (McGuirk and Muir, 1985), appearing as QRS complexes with an abnormal morphology and duration, and no relation with a P wave (see below).

Atrial myocardial dysrhythmias

Atrial myocardial dysrhythmias are caused by an abnormal impulse formation from the atrial myocardium outside the SA node.

Atrial premature contraction

Atrial premature contractions (APCs) or atrial premature beats occur earlier than expected in the normal basic rhythm (Hilwig, 1977). In athletic horses, APCs occur occasionally, but the performance is affected only when they cause an excessive heart rate during exercise or predispose to paroxysmal atrial fibrillation (Young and van Loon, 2008). When, in the absence of systemic disease, APCs occur frequently, e.g. 1 to 5 per minute, it is more likely that underlying atrial disease is present (Patteson, 1996).

On the ECG, a premature P' wave is present; its morphology can be normal or abnormal. Whether or not the P' wave conducts to the ventricles depends on the timing within the cardiac cycle (Mitten, 1996). If conduction occurs, the QRS morphology and duration are normal (Figure 5). The impulse of the APC usually enters the SA node and resets the 'timer' of the node. This resetting interrupts the basic rhythm of the node, causing it to resume its normal pacemaker activity at an earlier time than would have been expected from the normal RR interval. The interval from the premature complex to the next normal QRS complex is called a 'non compensatory pause', because it is less than a compensatory pause (Tilley, 1992). In some occasions, the SA node is not reset by the APC and continues to fire at the expected point in time, but fails to produce a P wave. In this case the length of 2 RR intervals preceding the APC is equal to the length of the RR intervals between the sinus beat preceding the APC, the APC and the sinus beat following the APC. In rare cases, an interlaced APC appears between 2 normal sinus beats, without interrupting the basic rhythm of the SA node. No P wave is dropped and an extra P' wave appears between the 2 normal P waves.

Atrial tachycardia

When 4 or more APCs occur successively, atrial tachycardia is present (Patteson, 1996; Mitten, 1996). It can be caused by underlying atrial myocardial disease, but other possible causes include electrolyte disturbances or systemic disease (Mitten, 1996). Atrial tachycardia should be distinguished from sinus tachycardia, which is a normal physiological response. In atrial tachycardia the atrial rate is high, without an ap-

parent reason for a high heart rate such as excitement or pain.

On the ECG, P' waves occur at an increased rate, they may show a regular or irregular rhythm and have a normal or abnormal morphology. At higher rates, P' waves are buried in the preceding T wave and become invisible. P' waves that conduct to the ventricles result in a QRS complex with normal morphology.

Atrial fibrillation

Atrial fibrillation (AF) is a condition whereby the atria no longer contract in a coordinated manner, instead, they quiver (Holmes, 1980). It is particularly common in horses because of their large atria and high vagal tone (Patteson, 1996). AF can be paroxysmal, e.g. in thoroughbreds during racing, and then spontaneously revert to sinus rhythm within 72 hours. However, most frequently AF is permanent once it has started, and it does not convert spontaneously. At rest, it will usually not result in clinical symptoms, because of the relatively small contribution of the atrial contraction to ventricular filling and cardiac output. During exercise, however, the heart rate may become excessively high, whereby the decreased ventricular filling time results in a decreased stroke volume. The absence of atrial contraction exacerbates this decrease, potentially resulting in poor performance, especially in high demanding sport disciplines such as racing, eventing or endurance (van Loon, 2008).

Atrial fibrillation (AF) is characterized by the absence of P waves, the presence of fibrillation waves or f waves and irregularly irregular RR intervals with a normal QRS morphology (Young and van Loon, 2008) (Figure 6). In case of very short RR intervals, the T wave will be opposite to the QRS complex, which might differ from the other T waves. Such a complex should not be mistaken for a ventricular premature beat. The morphology of the f waves varies from coarse to fine, often alternating within recordings. The frequency of the f waves can be as high as 500 per minute, but only a limited number of impulses is conducted through the AV node. In the absence of underlying cardiac disease, the ventricular rate at rest is normal. During excitement or exercise, the heart rate easily surpasses the maximal heart rate of 240 bpm, often resulting in short lasting episodes of high ventricular rates up to 250 to 450 bpm.

AV nodal dysrhythmias

The normal AV node 'passes' the atrial impulse to the ventricles. In AV block, this conduction towards the ventricles is delayed (1st degree), intermittently blocked (2nd degree) or completely absent (3rd degree).

First degree AV block

In 1st degree AV block, the conduction of the atrial impulse through the AV node is delayed. In horses, this is usually due to the vagal tone (Hilwig, 1977), but it

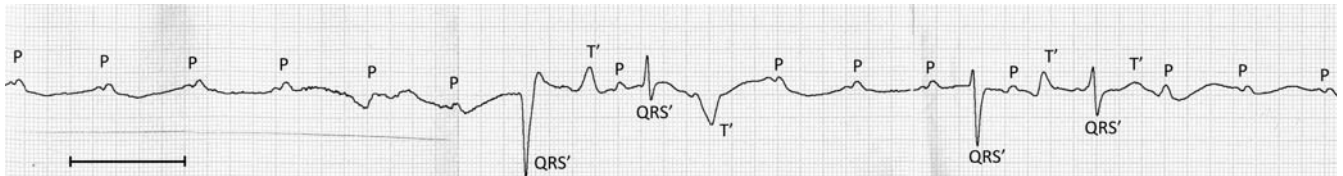


Figure 8. Third degree AV block. PP intervals are regular but P waves have no relationship to QRS complexes. QRS complexes have bizarre shapes. First QRS complex is an example of an escape beat. The line bar indicates 1 second.

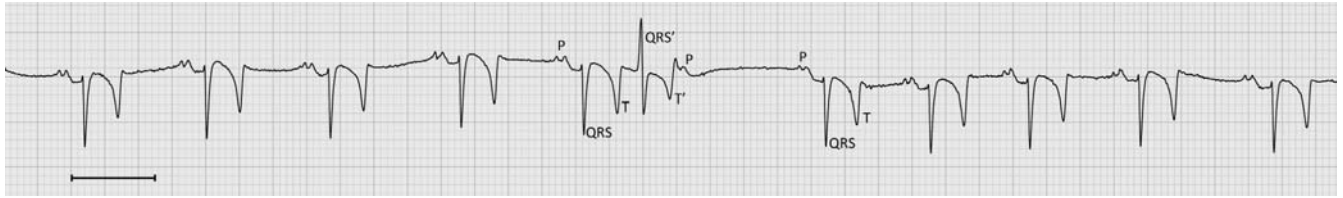


Figure 9. Ventricular premature beat. QRS' complex has a bizarre morphology and is not preceded by a P wave. RR' interval is too short. VPC is followed by a compensatory pause. The line bar indicates 1 second.

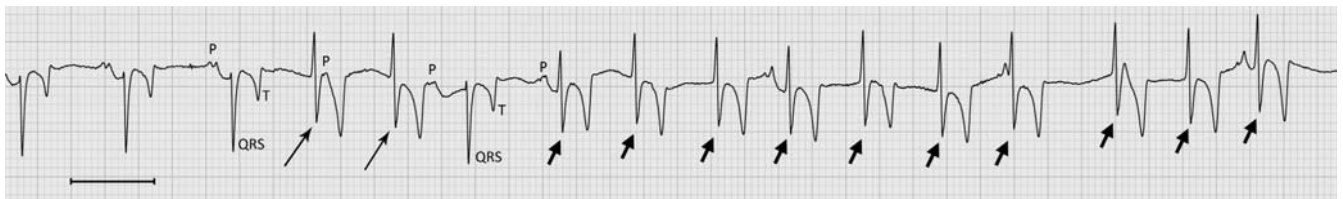

Figure 10. Ventricular tachycardia. Two VPCs (long arrows) are followed by one normal P-QRS-T complex and a train of VPCs: VT (short arrows). The line bar indicates 1 second.

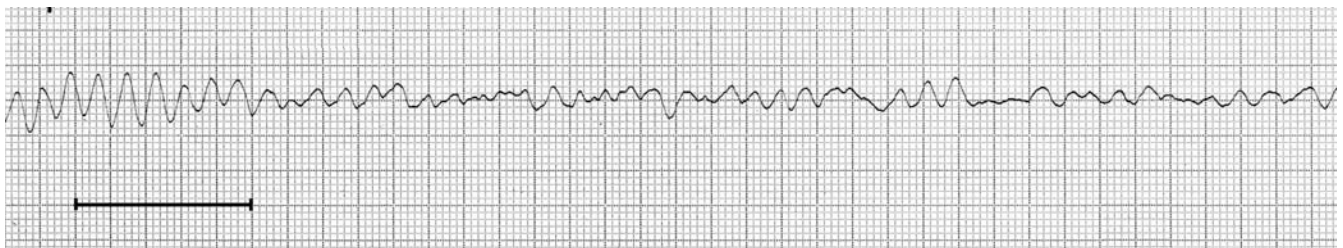

Figure 11. Ventricular fibrillation. Undulating baseline with no identifiable QRS complexes or T waves. The line bar indicates 1 second.

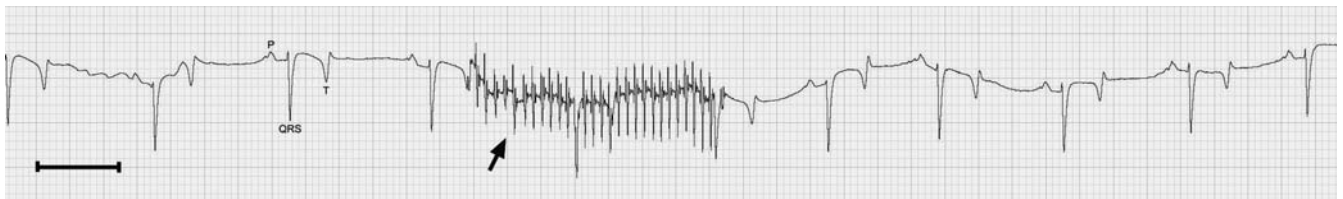

Figure 12. Muscle tremor causing sharp narrow deflections (arrow) of the baseline in the ECG trace. The line bar indicates 1 second.

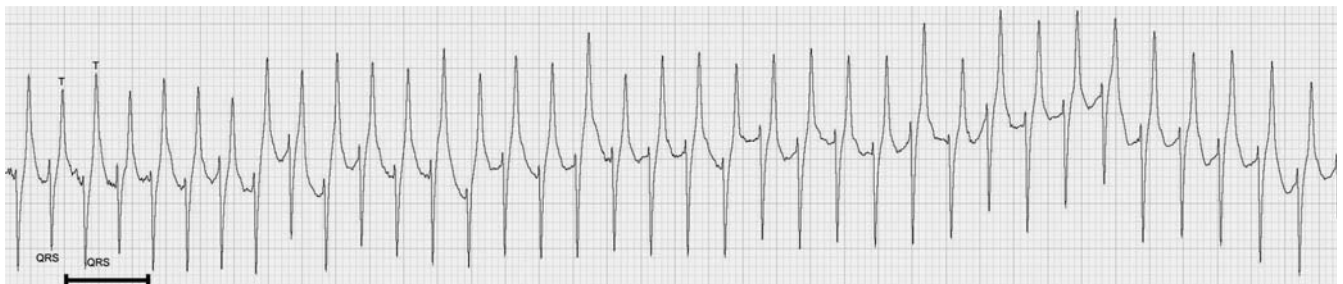

Figure 13. ECG during exercise. T waves are large and opposite in polarity to QRS complexes. P waves are no longer visible as they are incorporated in the preceding T waves. The line bar indicates 1 second.

can also be caused by drugs, such as α_2 agonists or digoxin (Patteson, 1996). The dysrhythmia is generally physiological and of little clinical significance. AV nodal disease is present only on rare occasions.

During 1st degree AV block, each P wave is followed by a QRS complex and every QRS complex is preceded by a P wave but the PR interval is prolonged (> 0.44 sec). The morphology of P waves and QRS complexes is normal.

Second degree AV block

Intermittent failure of the atrial impulse to conduct toward the ventricles is called 2nd degree AV block. This is the commonest physiological dysrhythmia found in horses (Buchanan, 1965) and is usually caused by a high vagal tone (Senta *et al.*, 1970). It is considered to be physiological and could be a normal mechanism in regulating blood pressure (Patteson, 1996). During exercise or excitement, this type of dysrhythmia should disappear with the abolishment of the high vagal tone.

Two types of 2nd degree AV block can be distinguished: Mobitz type I (or Wenckebach periodicity) and Mobitz type II. In type I blocks, there is a lengthening of the PR interval on the ECG, until a P wave is not followed by a QRS complex. However, the PR interval immediately preceding the dropped beat is not necessarily the longest one in the sequence. Mobitz type II blocks are characterized by P waves that are periodically not followed by a QRS complex, without preceding sign of the block (Hilwig, 1977). In both cases, the morphology of P waves and QRS complexes is normal. Every QRS complex is preceded by a P wave, but not every P wave is followed by a QRS complex (Figure 7). Of the 2 types of blocks, this type is the most frequently observed (Buchanan, 1965).

Sometimes 2nd degree AV block can be so profound that it is considered a pathological dysrhythmia, i.e. advanced 2nd degree AV block. In those cases, several successive P waves are blocked before a normal conduction takes place. Long pauses may lead to a drop in blood pressure and even syncope. Long term ECG recording may be required in order to diagnose this condition. The ECG shows normal PP intervals but multiple, successive P waves are not followed by a QRS complex. QRS complexes following a P wave have a normal morphology and duration. During long pauses, escape beats may appear.

Third degree AV block

In 3rd degree AV block or complete heart block, none of the atrial impulses conducts through the AV node. The ventricles are left to contract according to their own intrinsic escape rhythm, which is usually slower than the normal sinus rhythm. This condition is invariably pathological and can be caused by degenerative or inflammatory AV nodal disease (Mitten, 1996). It can be associated with syncope or weakness and is only rarely reversible.

The ECG shows P waves with a normal morpho-

logy and a regular PP interval. P waves have no relationship with the QRS complexes. The rate of the P waves is usually high as a reflex to hypotension (McGuirk and Muir, 1985). QRS complexes can be bizarrely shaped although a ventricular escape rhythm originating close to the AV node is usually regular and results in a close to normal QRS complex (Figure 8).

Ventricular dysrhythmias

Ventricular dysrhythmias are the consequence of abnormal impulses that arise somewhere in the ventricular myocardium.

Ventricular premature contraction

Ventricular premature contractions (VPCs) occur earlier than expected during normal sinus rhythm. They occur less frequently in horses than in other species (Patteson, 1996), and their significance and underlying etiology are not well understood (Young, 2004). However, they can be caused by myocardial or systemic disease and potentially lead to ventricular tachydysrhythmias (Buchanan, 1965; Young, 2004). This is why horses with VPCs at rest should be retired from ridden work and should be thoroughly examined (Young, 2004).

Because the VPC conducts in a different direction and from cell to cell, not over specialized conduction tissue, the resultant QRS' complex is longer in duration and has a different morphology (Hilwig, 1977). Depending on the site of origin, the QRS' complex may have a bizarre or close to normal appearance. Multiple lead recordings are therefore helpful to detect certain VPCs. The VPC is not associated with a preceding P wave (Figure 9) (Young, 2004). Naturally, a normal P wave with variable PR interval may, by coincidence, precede the VPC, but it is not associated with the VPC. The abnormal QRS complex is usually followed by a compensatory pause, since the first sinus beat after the VPC occurs while the ventricles are still refractory. However, VPCs may occasionally present without disturbing the underlying rhythm, i.e. 'interlaced' beats. On rare occasions, by coincidence, the ventricle may be depolarized by a normally conducted beat and a VPC that occur at the same time. The resultant QRS' is called a 'fusion beat' and has a morphology which is a mixture between the normal QRS and VPC morphology (cf. part 1: how to make a good recording, Figure 3).

Ventricular escape beat

When for some reason the ventricles are not depolarized by an impulse and the heart rate becomes too low, a ventricular escape beat arises from the ventricular myocardium. Escape beats occur later than expected in the normal sinus rhythm and can be said to "rescue" the ventricles from asystole. They are a sign of underlying atrial or junctional disease (Patteson, 1996) that results in bradycardia.

The ECG shows a longer than normal RR' interval and the QRS' complex has an abnormal morphology and duration (McGuirk and Muir, 1985) (cf. 1st QRS complex on Figure 8). A P wave can be absent, or is non-conducted with no correlation to the QRS' complex. When escape beats arise in close proximity to the AV node, they may have a fairly normal appearance. For this reason, multiple lead recordings may be helpful for diagnosis.

Ventricular tachycardia

When 4 or more VPCs occur in a row, this is termed ventricular tachycardia (VT) (Patteson, 1996; Young, 2004). VT may be paroxysmal or sustained if it persists for many minutes or hours (Hilwig, 1977). It nearly always indicates underlying cardiac or systemic disease (Patteson, 1996). VT is a potentially life-threatening dysrhythmia since it can lead to ventricular fibrillation and death (Young, 2004).

Ventricular tachycardia is characterized by abnormal QRS' complexes which are not related to P waves (Figure 10). When the QRS' complexes all have the same morphology, monomorphic VT is present. When the ventricular impulses arise from more than one location, the QRS' complexes have different morphologies, which results in polymorphic VT. Sometimes no P waves can be identified because they get hidden in the QRS' complexes. The heart rate is higher than normal but may range from around 50 to more than 200 bpm. The rhythm can be regular, usually when monomorphic VT is present, or irregular. When a premature ventricular complex follows very closely after the T wave of the preceding complex, the 'R-on-T' phenomenon is present. This phenomenon is a potential initiator of a fatal dysrhythmia (Mitten, 1996).

Ventricular fibrillation

During ventricular fibrillation there are no longer coordinated contractions of the ventricles. It is almost invariably a terminal event despite treatment.

The ECG shows undulations of the baseline with no identifiable QRS complexes or T waves (Figure 11). P waves can still be present but are no longer followed by QRS complexes.

Common pitfalls

Sometimes artefacts arise on an ECG recording, which can be mistaken for P waves or QRS complexes and thus lead to misinterpretations. Artefacts are deflections on an ECG recording that are not caused by electrical activity of the heart.

The commonest cause of artefacts is movement, either of the horse or of the lead wires or electrodes. It is helpful to use self-adhesive electrodes and to prevent the wires from swinging, but when recording an ECG of an exercising animal, artefacts are almost impossible to avoid. These artefacts are seen as sharp deflections which occur at random but can sometimes resemble a

QRS complex. Muscle tremor causes very sharp and narrow multiple deflections of the baseline (Figure 12). Large undulations in the baseline are usually due to exaggerated respiratory motion (Patteson, 1996).

Another source of artefacts is the interference from electrical mains, especially when using recorders that are mains-powered. These artefacts are characterized by sharp, narrow and regular deflections of the entire ECG recording with a frequency of 50 Hz. They should not be mistaken for atrial fibrillation since P waves are still present and the undulations are regular. By using the filter on the ECG recorder, those artefacts can be largely avoided. A simple rule that can help to distinguish true dysrhythmias from artefacts is that artefacts do not have T waves.

Changes occurring on the ECG during exercise can also lead to misinterpretations. P waves can change in amplitude and shape (Hilwig, 1977), and often, a gradual 'displacement' of the P wave in the direction of the preceding T wave can be seen with an increasing heart rate. Eventually, the P wave can disappear entirely in the preceding T wave.

At rest, the T wave can present as a positive, negative or biphasic wave, but during exercise or stress, its polarity becomes opposite to the QRS complex (Figure 13). The ST segment often elevates, forming an upward slope which becomes progressively steeper as it merges with the T waves (Senta *et al.*, 1970). All these changes are normal and have no clinical significance whatsoever (Evans, 1991).

CONCLUSION

Dysrhythmias can be divided according to their origin into 4 groups: SA nodal, atrial myocardial, AV nodal and ventricular myocardial dysrhythmias. This classification helps to understand the changes these dysrhythmias cause on the ECG. The equine clinician is faced with a wide variety of dysrhythmias, of which a number are normal and caused by a high parasympathetic tone at rest in horses (Young, 2004). Exercise ECG recordings can help to make the distinction between physiological and pathological dysrhythmias. On these recordings, caution should be made for misinterpreting movement artefacts. Exercise or stress cause changes in the P and T waves on the recording but these changes have no clinical significance. With a systematic approach to evaluate an ECG recording, mistakes can be largely avoided.

REFERENCES

- Buchanan J.W. (1965). Spontaneous arrhythmias and conduction disturbances in domestic animals. *Annals of the New York Academy of Sciences* 127. Issue Comparative Cardiology, 224-238.
- Evans D.L. (1991). T-waves in the equine electrocardiogram: effects of training and implications for race performance. *Equine Exercise Physiology* 3, 475-481.
- Fregin G.F. (1992). Medical evaluation of the cardiovascular system. *Veterinary Clinics of North America: Equine Practice* 8, 329-346.

- Hamlin R.L., Klepinger W.L., Gilpin K.W., Smith C.R. (1972). Autonomic control of heart rate in the horse. *American Journal of Physiology* 222, 976-978.
- Hilwig R.W. (1977). Cardiac arrhythmias in the horse. *Journal of the American Veterinary Medical Association* 170, 153-163.
- Holmes J.R. (1980). Cardiac rhythm irregularities in the horse. *In Practice* 2, 15-25.
- McGuirk S.M., Muir W.W. (1985). Diagnosis and treatment of cardiac arrhythmias. *Veterinary Clinics of North America: Equine Practice* 1, 353-370.
- Mitten L. (1996). Cardiovascular causes of exercise intolerance. *Veterinary Clinics of North America: Equine Practice* 12, 3473-494.
- Nørgaard L.M., Johnsen E.B., Restrepo J., Buhl R. (2008). Evaluation of RR-intervals from equine ECG recordings during submaximal and maximal exercise intensity: Is there a standard criterion for arrhythmia assessment? *BEVA Congress 2008 Handbook of Presentations*, 138-139.
- Patteson M. (1996). *Equine Cardiology*. Blackwell Science Ltd, Oxford, p. 1-254.
- Reef V.B. (1985). Evaluation of the equine cardiovascular system. *Veterinary Clinics of North America: Equine Practice* 1, 275-288.
- Senta T., Smetzer D.L. (1970). Effects of exercise on certain electrocardiographic parameters and cardiac arrhythmias in the horse. A radiotelemetric study. *The Cornell Veterinarian* 60, 552-569.
- Tilley L.P. (1992). *Essentials of Canine and Feline Electrocardiography. Interpretation and Treatment*. 3e Ed., Lea & Febiger, Philadelphia, London, p. 290-291.
- van Loon G. (2008). Atrial fibrillation: Ordered chaos? In: *Proceedings of the 47th BEVA Congress*. April 10-13th, 2008, Liverpool, UK, p 294-296.
- Young L. (2004). Diseases of the heart and vessels. In: Hinchcliff K.W., Kaneps A.J., Geor R.J. (editors). *Equine Sports Medicine and Surgery - Basic and Clinical Sciences of the Equine Athlete*. Elsevier Limited, Edinburgh, p. 728-767.
- Young L., van Loon G. (2008). Sudden poor performance in the equine athlete: could it be the heart? In: Lindner A. (editor). *The Acutely Poor Performing Sport Horse. Conference on Equine Sports Medicine and Science*, p. 69-80.





KLAAR DE KLUS MET DUNLOP PUROFORT+

Voor de professionele veearts brengt onze Purofort+ range comfort en duurzame kwaliteit. Purofort+ is ideaal voor intensief gebruik, is lichtgewicht, houdt voeten warm tot -20 °C en is resistent tegen velerlei agri chemicaliën en reinigingsmiddelen.*

Dunlop: Engineered for professionals, used in leisure, designed for comfort.

* Zie onze individuele laarzen eigenschappenlijst voor meer informatie voor optimale resistentie.

COMFORT
DROOG • WARM • BETROUWBAAR

VOOR MEER
INFORMATIE KIJK OP
DUNLOPBOOTS.COM



THE ULTIMATE PROTECTION FOR YOUR FEET