

Electrocardiography in horses – part 1: how to make a good recording

Elektrocardiografie bij paarden – deel 1: een goede opname maken

T. Verheyen, A. Decloedt, D. De Clercq, P. Deprez, S. U. Sys, G. van Loon

Department of Large Animal Internal Medicine
Faculty of Veterinary Medicine, Ghent University
Salisburylaan 133, 9820 Merelbeke, Belgium

Tinne.Verheyen@UGent.be

ABSTRACT

Upon auscultation, cardiac dysrhythmias can be suspected, but electrocardiography is the ultimate diagnostic tool. Electrocardiogram (ECG) recording used to be reserved to specialized centers, but nowadays relatively cheap and small recorders are available to the practitioner in the field. ECGs can therefore be recorded ambulatory and during prolonged periods at rest or even during exercise. The know-how of a good quality recording is mandatory for a correct diagnosis. The basic equipment consists of electrodes, a recorder and a way to display the trace. Self-adhesive electrodes should be used, and positioned along the mean electrical axis of the heart. Small recording devices offer the advantage of allowing recordings during exercise.

As the electrical impulse spreads through the heart, the ECG trace shows successively a P wave, a QRS complex and a T wave. T_a waves are not always clearly visible in horses.

The positioning of the electrodes may differ for ambulatory, exercise or long-term resting recordings. However, as long as the electrodes are positioned along the mean electrical axis, their exact position is not of crucial importance.

SAMENVATTING

Bij auscultatie kunnen bepaalde dysritmieën vermoed worden, maar enkel een elektrocardiogram (EKG) laat een exacte diagnose toe. Vroeger kon elektrocardiografie enkel door gespecialiseerde centra uitgevoerd worden, maar sinds kort zijn betaalbare en compacte EKG-systemen beschikbaar voor de praktijkdierenarts. Om het stellen van een correcte diagnose mogelijk te maken, is kennis van het maken van een kwalitatief goede EKG-opname onontbeerlijk. EKG's kunnen ambulante en gedurende langere perioden tijdens rust of tijdens inspanning opgenomen worden. De basisuitrusting bestaat uit elektroden, een opnametoestel en een manier om het opgenomen tracé te tonen. Zelfklevende elektroden hebben de voorkeur en worden parallel met de gemiddelde elektrische as van het hart geplaatst. Compacte opnametoestellen hebben als voordeel dat ze opnamen tijdens inspanning toelaten.

De verspreiding van de elektrische impuls doorheen het hart resulteert bij EKG achtereenvolgens in een P-golf, een QRS-complex en een T-golf. T_a-golven kunnen niet altijd duidelijk waargenomen worden bij het paard.

De positie van de elektroden kan verschillen voor ambulante opnamen, opnamen tijdens rust of tijdens inspanning. Zolang de richting van de gemiddelde elektrische as echter gerespecteerd wordt bij het plaatsen van de elektroden, is de exacte positie van deze laatste niet van cruciaal belang.

INTRODUCTION

A cardiac exam always starts with a detailed history and a thorough clinical exam. An imperative aspect of the clinical examination is a skillfully performed auscultation which allows the gathering of important information about the cardiac cycle and blood flow (Patteson, 1996). Further diagnostic tests, such as biochemistry, echocardiography and electrocardiography, can be carried out to obtain additional information about the exact cause and importance of cardiac disease.

Echocardiography allows the imaging of cardiac structures, the determination of chamber size and provides information about the cardiac function (Patteson, 1996).

Electrocardiography is the ultimate tool for the

diagnosis and classification of dysrhythmias. An electrocardiogram (ECG) can be recorded for brief (ambulatory) or prolonged (e.g. 24-hour or "Holter" recording) periods, at rest and during exercise. ECG recording during exercise used to be reserved to specialized centers because of the expensive equipment. Over the last years, relatively cheap, battery-powered recorders have become available to the equine practitioner for ECG recording under field conditions. In order to correctly diagnose a dysrhythmia, a good quality recording and a thorough knowledge of ECG interpretation are mandatory.

This paper consists of two parts. The first part explains how to make a good quality ECG recording in resting and exercising horses. The second part describes how to interpret the ECG and reach a final diagnosis.

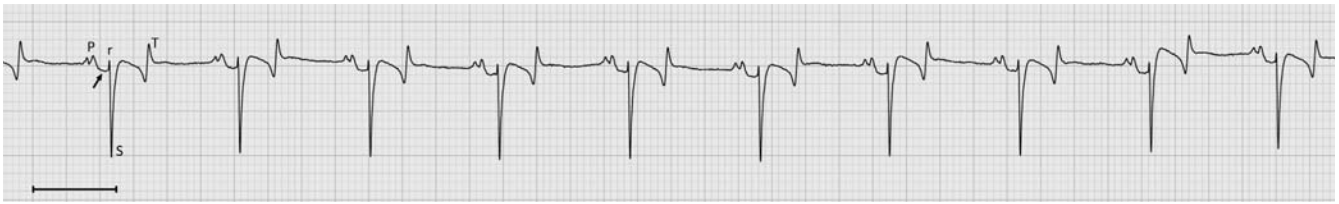

Figure 1. Normal sinus rhythm with P wave, QRS complex and T wave. The arrow indicates T_a wave, the line bar indicates 1 second.

Principles of electrophysiology

When a cardiac cell depolarizes or repolarizes, different currents flow across the cell membrane at various time points resulting in a potential difference and an external electrical field. When enough cells de- or repolarize at the same time, the electrical field will be strong enough to be recorded from the body surface. The ECG register changes in the electrical field around the heart via electrodes, usually placed on the skin. The sum of potential differences of all individual cells can be represented by a mean electrical axis (MEA), which indicates the average direction of electrical activity in the heart. The recorded potential difference is largest when the electrodes are placed parallel to the MEA.

The combination of two electrodes, one negative and one positive, between which a potential difference is measured, is called a “lead”. If the direction of the overall depolarizing electrical activity is headed towards the positive electrode, the deflection on the ECG will be upward (positive). If the electrical activity points away from the positive electrode, the deflection will be downward (negative) (Patteson, 1996).

Normal equine ECG

The normal conduction process follows a rather fixed pathway through the heart: from the sinus node through the atrial myocardium, the AV node, the Hiss and Purkinje system to the ventricles. As the rhythm originates from the sinus node, it is called ‘sinus rhythm’.

Deflections on the ECG originate from the depolarization or repolarization of a relatively large muscle mass, such as the atrial and ventricular myocardium. The depolarization of a small group of cells, such as sinus node and atrioventricular (AV) node, fail to produce sufficient changes in the electrical field. For this reason, the impulse generation in the sinus node is not visible on the ECG (Patteson, 1996).

When the impulse spreads through the atria, the ECG shows a P wave (Figure 1). The morphology of P waves is variable: it can be bifid, simple positive or biphasic. When the heart rate changes, the P wave morphology often changes as well, and even successive P waves are not always identical in the normal horse. At a slow heart rate, the P wave is often bifid. The first peak represents the depolarization of the right atrium and the second one that of the left atrium. In its biphasic morphology, the P wave is usually of the negative/positive type. A normal P wave should take less

than 0.16 seconds (Bonagura and Reef, 2004) (Table 1). The T_a wave, which is the atrial repolarization, is not always clearly identifiable (Figure 1).

Atria and ventricles are isolated from each other by fibrous tissue, except at the level of the AV node. The conduction of the impulse through the AV node is very slow, and profoundly affected by a vagal tone (Patteson, 1996). As the conduction itself does not result in a deflection on the ECG, it presents as the flat PR segment. In horses, the normal PR interval may last up to 0.5 seconds, because of their high vagal tone (Bonagura and Reef, 2004) (Table 1).

Once through the AV node, the impulse spreads very rapidly through the Hiss bundle and Purkinje system to depolarize the ventricular myocardium. The latter produces a large deflection on the ECG, the QRS complex (Figure 1). The QRS complex is composed of various components, defined according to international agreements. By convention, the first positive (upward) deflection is an R wave. The first negative (downward) deflection that precedes an R wave is called a Q wave. The first negative deflection that follows an R wave is the S wave. Subsequent positive deflections are R' waves and subsequent negative deflections S' waves (Tilley, 1992). This means that although the complex is named ‘QRS’, it has not always – and usually not – a ‘QRS’ morphology in horses. The rS or rSr' morphology is most common in horses. The duration of the QRS complex should not exceed 0.14 seconds (Bonagura and Reef, 2004) (Table 1).

Each depolarization is followed by a repolarization, represented by the T wave (Figure 1). In horses, the T wave is very variable in size and orientation and particularly dependent on the heart rate. Even beat-to-beat changes in the RR interval often affect the morphology of the T wave. T waves are not helpful in the

Table 1. Duration of different waves and complexes on a normal ECG (Rossdale, 1967; Lombard *et al.*, 1984; Fregin, 1992; Vaala, 1993; Patteson, 1996; Bonagura and Reef, 2004).

Wave or complex	Duration (seconds)
P wave	≤ 0.16
PR interval	≤ 0.5 (pony: ≤ 0.24) (foal: 0.11 – 0.18)
QRS complex	≤ 0.14 (foal: 0.05 – 0.08)
QT interval	≤ 0.58 (foal: 0.19 – 0.36)

diagnosis of cardiac disease (Patteson, 1996) but may be helpful to differentiate between a normal and abnormal ventricular beat, and between artefacts (which do not have T waves). The QT interval in normal horses takes no longer than 0.58 seconds (Bonagura and Reef, 2004) (Table 1).

It is essential to realize that the Purkinje fibre system is much more extended in horses than in humans and small animals. Therefore, the equine QRS complex provides little or no information about the heart size or the exact origin of an ectopic beat. Basically, it only provides information regarding the heart rate and rhythm.

Equipment

The basic equipment consists of electrodes, a recording device and a way to display the trace.

In the past, crocodile clamps were pinched to the horse's skin after the application of contact gel (Fregin, 1985). Drawbacks of using those electrodes were the fact that they could be painful or result in skin reaction, and that they easily produce artefacts. Self-adhesive electrodes are better tolerated and significantly improve recording quality. Specific equine self-adhesive electrodes should be used as they contain more gel to improve skin contact and stronger glue to remain in place, even during exercise. Clipping of the hair coat is generally not necessary and even undesirable since it causes the electrodes to fall off more easily, especially during sweating. Extra gel can be used when the hair coat is very long, e.g. during winter, or extra glue in case of excessive sweating.

Any ECG device can be used for ambulatory recording. However, a small, battery-powered device, fixed to the horse's back, allows to make recordings during exercise. The signal can then be digitally stored or wireless transmitted (telemetry) through radio-frequency or Bluetooth. Telemetry allows for beat-to-beat real-time monitoring and thus represents an advantage above other systems (Magdesian, 2004). When a device has sufficient storage capacity, e.g. on a digital card, also long-term (e.g. 24-hour) monitoring becomes possible.

Nowadays, the recorded signals can be imported into computer software for the automatic analysis of normal and abnormal rhythms. The software detects R waves and screens for sudden irregularities in the RR interval. Complex algorithms for the analysis of the QRS morphology exist in more advanced software packages designed for human or small animal cardiology. However, these algorithms usually fail to interpret the horse's ECG correctly, partly because of the large T wave on the equine ECG. Therefore, the visual screening of the horse's ECG usually remains necessary.

Recording of an ECG

An ambulatory ECG has high diagnostic value for dysrhythmias that are continuously present. For occa-

sionally occurring dysrhythmias, 24-hour monitoring is necessary (Magdesian, 2004). This type of monitoring allows the frequency of dysrhythmias to be catalogued. Also when a horse is examined for seizures or collapse, continuous ECG monitoring may be necessary to confirm or rule out a cardiac cause. Many dysrhythmias only occur during exercise while others, although present at rest, may disappear during exercise. Therefore, exercise ECGs are a mainstay in the diagnosis of dysrhythmias and the work-up of a poor performing horse (Morris and Seeherman, 1991; Scheffer and Sloet van Oldruitenborgh-Oosterbaan, 1996).

To start recording an ECG, electrodes need to be attached to the horse's body and connected to the recording device. Different devices may have 3, 4, or up to 10 electrodes (Figure 2).

There is no universally accepted lead system for the use in large animals (Reef and McGuirk, 2002). Usually, a single-lead recording is sufficient (Holmes, 1984). However, the advantage of a multiple lead system is that each lead detects the potential difference between its 2 electrodes from a unique angle, which might help to differentiate between a normal or abnormal complex (Figure 3) (Reimer *et al.*, 1992). In addition, when one electrode falls off in a multiple-lead system, the recording can still continue from the remaining electrodes. Whichever method is used, the procedure should be standardized so that ECGs can be compared (Holmes, 1984).

Systems with 4 electrodes are most commonly used. In such a system, the black electrode serves as a reference electrode for the electrocardiograph and can be positioned anywhere on the body surface of the horse. The remaining 3 electrodes are used to construct 3 leads: lead I between the red (right arm, -) and the yellow (left arm, +) electrode, lead II between the red (-) and the green (left foot, +) electrode, and lead III between the yellow (-) and the green (+) electrode (Fregin, 1985). Modern devices will automatically record from all 3 leads at the same time, offering the advantages of a multiple-lead recording. Older devices might require a manual switch between each lead.

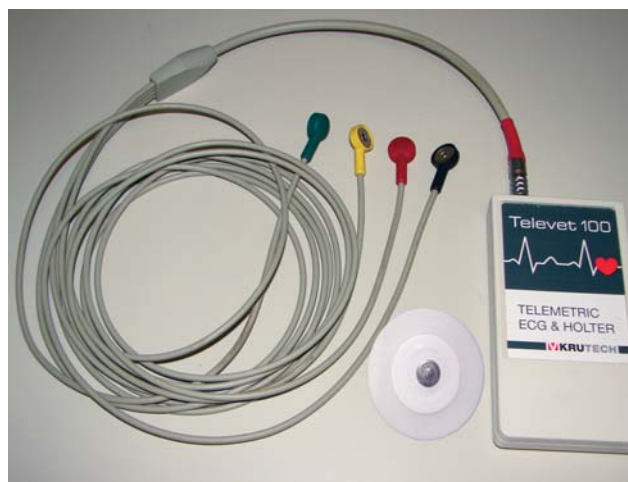

Figure 2. Recording device (Televet 100[®]) with 4 electrode cables (green, yellow, red and black) and a self-adhesive electrode.

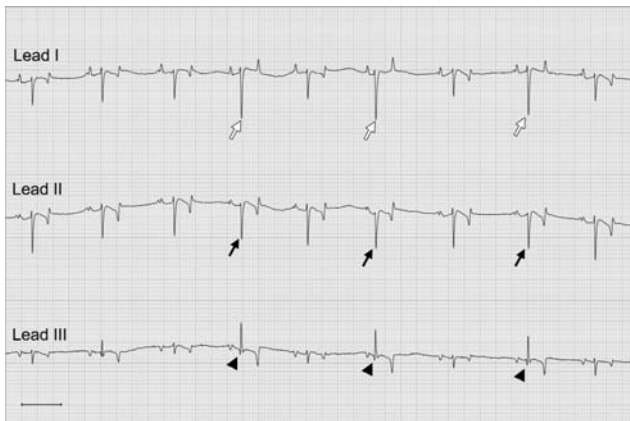


Figure 3. Multiple lead recording from a horse with abnormal QRS complexes (due to fusion beats) clearly visible in lead III (arrowheads), but easily overlooked in lead II (black arrows). Lead I shows QRS complexes with a larger amplitude (open arrows). The line bar indicates 1 second.

The positioning of the electrodes is not strictly defined in horses and can be adapted according to the circumstances. As a general rule of thumb, electrodes need to be positioned along the MEA, which is directed from the apex of the heart towards the base and slightly to cranial and to the right. This means that one electrode should be on the lower thorax near the cardiac apex: between the elbow and xiphoid area. The second electrode should be positioned towards the cardiac base which is more dorsal, in the region between the lower neck and the withers.

Below, some examples for electrode placement are given.

Ambulatory ECG recording

For ambulatory recordings at rest, the base-apex lead system gives the best results. It corresponds best to the MEA direction and hence results in the largest deflections for both atrial and ventricular waveforms (Young, 2004). The negative (red) electrode is positioned in the lower third of the right jugular groove or on the scapula, corresponding to the base area of the heart. The positive (green) electrode is positioned over the apex beat area of the heart, on the thorax, caudal to the left elbow. The yellow electrode can be positioned on the middle of the left scapula. The remaining black electrode can be positioned anywhere on the body surface of the horse. Lead II is recorded.

Exercise ECG recording

The base-apex system is unsuited for recordings during exercise (Young, 2004), since electrodes are then more prone to creating movement artefacts and falling off, and can interfere with the freedom of movement of horse and rider. For ridden exercise recordings, an adaptation of the base-apex system should be used.

The negative (red) electrode is placed on the left shoulder blade, near the withers. When saddled, this position is just in front of the left saddle flap. The po-

sitive (green) electrode is placed just behind the saddle girth on the left, on a position where the leg of the rider doesn't interfere with it. The remaining yellow electrode can be placed just above or underneath the green one, creating an extra lead. A good position for the reference electrode is just underneath the red one. In this construction, the rider can easily reattach any electrode, and the electrodes are unlikely to be affected by the saddle or girth slipping backwards during fast exercise (Young, 2004). The left-to-right component of the MEA is missing here, but the deflections on the ECG are still clearly visible, although the atrial deflection (P wave) will be slightly lower in amplitude (Young, 2004). The negative (red) and reference (black) electrodes can also be placed underneath the left saddle flap, which offers extra protection against dislodging.

To prevent electrodes from dislodging, e.g. during intensive exercise or during lunging exercise, one can use an elastic girth around the horse's thorax and place the electrodes underneath the girth. In this vertical modification of the base-apex system, the cranio-caudal orientation of the MEA is lost. Therefore, the P wave will be lower in amplitude than that of a true base-apex configuration but large QRS deflections will still be present. The negative (red) electrode is positioned on the right side of the withers, and the positive (green) electrode behind the left elbow joint, on the apex beat area. The remaining (yellow) electrode is placed about 10 cm above the green one. The reference electrode can be positioned anywhere under the girth (Figure 4). The girth can be used during lunging exercise but also during ridden exercise or in trotters, where it is placed just cranial and partially underneath the saddle or harness.

Long-term ECG recording

For long-term recordings, e.g. 24 hours or more, the recording device, electrodes and wires need to be protected. The girth, with the electrode configuration mentioned above, is suited as it covers all electrodes and wires so that the horse can not damage them. The recorder itself is placed in a protective box so that it does not get damaged during rolling.

As stated before, no universally accepted lead system exists for recordings in large animals. Adaptations to the systems described above can be made according to personal experience and preferences.

CONCLUSION

Electrocardiography is the ultimate diagnostic tool when cardiac dysrhythmias are suspected. Nowadays, relatively cheap equipment (€ 1000-3000) has become available to the equine practitioner. An ECG can be recorded ambulatory, for a brief period, or for a longer period when monitoring for less frequent dysrhythmias. An exercise ECG is mandatory to assess the importance of certain dysrhythmias found at rest and especially in horses with poor performance.




Figure 4. The positioning of electrodes for 24-hour ECG monitoring or lunging exercise, using a custom designed girth (Orthohorse® Mainat Vet). ‘Right arm’ corresponds to the red electrode, ‘left arm’ to the yellow electrode and ‘left foot’ to the green electrode.

For the recording of an ECG, self-adhesive electrodes are most appropriate. Modern recording devices offer the possibility of a wireless transmission and the storing of the recorded signal, allowing online monitoring during exercise and making 24-hour recordings. When the signal can be displayed on a computer, software may aid to analyze the recorded trace. However, visual inspection of the equine ECG usually remains necessary because the large equine T wave may interfere with the automatic analysis.

The exact position of the electrodes is not that important, as long as the leads are constructed along the MEA. Multiple lead systems have the advantage of being more sensitive and always have one or more “backup” leads in case of electrode dislodgement.

The interpretation of the recorded ECG can be challenging and requires experience. A guideline to the interpretation of an ECG and identification of the different kind of dysrhythmias are discussed in part 2.

REFERENCES

Bonagura J.D., Reef V.B. (2004). Disorders of the cardiovascular system. In: Reed S.M., Bayly W.M., Sellon D.C. (editors). *Equine Internal Medicine*. 2de Ed., Saunders, Missouri, p. 355-459.

Fregin G.F. (1985). Electrocardiography. *Veterinary Clinics of North America: Equine Practice* 1 (2), 419-432.

Fregin G.F. (1996). Medical evaluation of the cardiovascular system. *Veterinary Clinics of North America: Equine Practice* 8 (2), 329-346.

Holmes J.R. (1984). Equine electrocardiography: some practical hints on technique. *Equine Veterinary Journal* 16 (5), 477-479.

Lombard C.W., Evans M., Martin L., Tehrani J. (1984). Blood pressure, electrocardiogram and echocardiogram measurements in the growing pony foal. *Equine Veterinary Journal* 16 (4), 342-347.

Magdesian K.G. (2004). Monitoring the critically ill equine patient. *Veterinary Clinics of North America: Equine Practice* 20 (1), 11-39.

Morris E.A. and Seeherman H.J. (1991). Clinical evaluation of poor performance in the racehorse: the results of 275 evaluations. *Equine Veterinary Journal* 23 (3), 169-174.

Patterson M. (1996). *Equine Cardiology*. Blackwell Science Ltd, Oxford, p. 1-254.

Reef V.B. and McGuirk S.M. (2002). Diseases of the cardiovascular system. In: Smith B.P. (editor). *Large Animal Internal Medicine*. 3e Ed., Mosby, Missouri, p. 443-478.

Reimer J.M., Reef V.B., Sweeney R.W. (1992). Ventricular arrhythmias in horses: 21 cases (1984-1989). *Journal of the American Veterinary Medical Association* 201 (8), 1237-1243.

Rossdale P.D. (1967). Clinical studies on the newborn thoroughbred foal. II. Heart rate, auscultation and electro-

cardiogram. *The British Veterinary Journal* 123 (12), 521-532.

Scheffer C.J.W., Sloet van Oldruitenborgh-Oosterbaan M.M. (1996). Computerized ECG recording in horses during a standardized exercise test. *Veterinary Quarterly* 18 (1), 2-7.

Tilley L.P. (1992). *Essentials of Canine and Feline Electrocardiography. Interpretation and Treatment*. 3e Ed., Lea & Febiger, Philadelphia, London, p. 40-55.

Vaala W.E. (1993). Diseases of foals during the neonatal period: The cardiac and respiratory systems. In: McKinnon A.O. and Voss J.L. (editors). *Equine Reproduction*. 1st Ed., Wiley-Blackwell, Oxford, p. 1041-1060.

Young L. (2004). Diseases of the heart and vessels. In: Hinchliff K.W., Kaneps A.J., Geor R.J. (editors). *Equine Sports Medicine and Surgery – Basic and Clinical Sciences of the Equine Athlete*. Elsevier Limited, Edinburgh, p. 728-767.

Uit het verleden

464

PROVINCIE OOST-VLAANDEREN.

BELASTING OP DE HONDEN.

Jaar 1934.

Kantoor

Ontvangen van Mr. *Peplandt - Edouard*

de som van *48* frank (.. *30* fr. taks + 60 opc.).

a) als provinciale belasting op

b) als hondenverkooper.

den *30 - 3* 1934.

..... werkhond

..... gewone hond

..... hond dienende tot de jacht.

— De Ontvanger der rechtstreeksche belastingen.

EXTRAKT DER VERORDENING VAN 18^e MAART 1931.

Art. 4. — Iedere bezitter of houder van een hond is verplicht er de aangifte van te doen bij den Ontvanger der belastingen van het gebied, in zijn kantoor of ter gelegenheid eener ontvangtzitting in de gemeente, vóór 1^e April van ieder jaar of binnen de 15 dagen van het in bezit komen of binnen de 15 dagen na het ophouden der oorzaak die den hond van de belasting vrijstelde. Hij is gehouden de belasting te betalen op het oogenblik der aangifte, tegen kwijtschrift van den Ontvanger.

Art. 7. — De ouders, voogden en meesters zijn burgerlijk verantwoordelijk voor de overtredingen aan huidige verordening begaan door hunne minderjarige kinderen, pupillen of dienstboden bij hen inwonende.

Art. 9. — Alwie een hond bezit of houdt zonder er de door artikel 4 voorgeschrevene aangifte en taksbetaling van gedaan te hebben, zal, overeenkomstig art. 3. der wet van 12^e Juli 1922, voor het gansche jaar, dus zonder inachtneming der dagteekening van in bezittreding der belastbare dieren, van ambtswege, voor het dubbel bedrag der ontdoken rechten aangeslagen worden.

In geval van niet betaling van den ambtelijken dubbelen aanslag binnen den vastgestelden termijn, zal deze aanslag vervangen worden door een proces-verbaal en zullen de overtreders gestraft worden met eene boete gelijk aan vijf maal het beloop der geslokene belasting.