

Neonatal foal death due to infection with equine arteritis virus in Belgium

Neonatale veulensterfte ten gevolge van een infectie met het equine arteritis virus in België

¹A. Gryspeerdt, ²K. Chiers, ³J. Govaere, ²G. Vercauteren, ²R. Ducatelle, ¹G.R. Van de Walle, ¹H.J. Nauwynck

¹Laboratory of Virology, Parasitology and Immunology
²Department of Pathology, Bacteriology and Poultry Diseases
³Department of Reproduction, Obstetrics and Herd Health
Faculty of Veterinary Medicine, Ghent University,
Salisburylaan 133, B-9820, Merelbeke, Belgium

Annick.gryspeerdt@ugent.be

ABSTRACT

This case report describes a small outbreak of neonatal foal death in Belgium due to infection with equine arteritis virus (EAV). The outbreak started with one foal suffering from acute dyspnea four days after birth. Despite intensive treatment, this foal died within a few hours. Three weeks later, another foal was born on the same farm in a healthy condition, although placental edema was found. At the age of 10 days, the foal showed acute respiratory distress and severe dyspnea and died shortly after. Post-mortem examination of both foals revealed consolidated diaphragmatic lung lobes with compensatory emphysema. Histologic lesions consisted of a mild acute interstitial pneumonia. Microscopic examination of the allantochorion from the second foal showed a focal necrotizing vasculitis, and immunolabeling demonstrated the presence of EAV antigens in chorionic vascular endothelial cells and macrophages. Upon inoculation of rabbit kidney (RK13) cell culture with a suspension of lung tissue, a cytopathic effect was observed. The agent was identified as equine arteritis virus by means of immunostainings.

SAMENVATTING

In deze casuïstiek wordt een beperkte uitbraak beschreven van neonatale sterfte in België, veroorzaakt door een infectie met het equine arteritis virus (EAV) bij twee veulens. De uitbraak begon met een veulen dat acute dyspneu vertoonde 4 dagen na de geboorte. Ondanks een intensieve behandeling stierf het veulen enkele uren later. Drie weken later werd op hetzelfde bedrijf een tweede veulen geboren dat gezond leek. Tijdens het onderzoek van de vruchtvlieszen werd een verdikt oedemateus allantochorion vastgesteld. Op de leeftijd van 10 dagen werden acute ademhalings-symptomen en ernstige dyspneu waargenomen. Het veulen stierf voordat een behandeling kon worden ingesteld. Bij de autopsie werden bij beide veulens vast aanvoelende diafragmatische longkwabben en compensatoir emfyseem waargenomen. De histologische letsels waren indicatief voor een acute interstitiële pneumonie. Bij het microscopisch onderzoek van het allantochorion van het tweede veulen werd een focale necrotiserende vasculitis vastgesteld. EAV-antigenen werden met behulp van immunohistochemie aangetoond in endotheelcellen en macrofagen. Na de inoculatie van konijnniercellen (RK13) met longsuspensie van beide veulens werd een cytopathisch effect waargenomen. Het agens werd met behulp van immunologische kleuringen geïdentificeerd als equine arteritis virus.

INTRODUCTION

Equine viral arteritis (EVA) is an infectious disease in horses caused by the equine arteritis virus (EAV), which is an RNA virus classified in the family of *Arteriviridae* (genus *Arterivirus*, order *Nidovirales*) (Cavanagh, 1997). Serological surveys have shown that EVA infections occur among horses in North and South America, Europe, Australia, Africa and Asia, with considerable variation in seroprevalence among

countries and within equine populations (Timoney and McCollum, 1993).

The two most important modes of transmission are aerogenic and venereal. *In utero* transmission, transmission via secretions and transmission via indirect contamination have also been reported (Bryans *et al.*, 1975; Timoney and McCollum, 1993; Holyoak *et al.*, 2008). Within 2 days after infection, the virus spreads rapidly within the lungs and bronchial lymph nodes, followed by dissemination throughout the body via the

blood circulation (McCullum *et al.*, 1971; Henson and Crawford, 1974). A second cycle of infection and replication occurs in endothelial cells of internal organs, causing extensive endothelial damage (Bryans *et al.*, 1957).

Most infections are subclinical. Clinical signs during an outbreak vary widely between individual horses and between outbreaks (de Vries *et al.*, 1996). In adult horses, EVA infections frequently resemble other infectious respiratory diseases, especially those caused by equine herpes viruses 1 and 4 and equine influenza virus (Timoney and McCullum, 1993). Fever and leukopenia are the most consistently observed features, but others like abortion, systemic illness and persistent infection in accessory glands of the reproductive tract of stallions have also been reported (Bryans *et al.*, 1957; Holyoak *et al.*, 1993; Holyoak *et al.*, 2008). In neonates, sudden death, fever, depression, edema, hemorrhagic enteritis and/or severe respiratory distress have been described (Del Piero *et al.*, 1997; Del Piero, 2000).

In Belgium, a severe outbreak of equine viral arteritis abortion in an Arabian stud farm occurred in 2000 (van der Meulen *et al.*, 2001). Cases of neonatal foal death have not been reported in Belgium until now.

CASE HISTORY

The first foal was born after a normal gestation period. Complete placenta expulsion occurred after 3 hours. The foal received anti-tetanus serum (Intervet, Belgium) and prophylactic antibiotics (Cobactan[®] 4,5%, Intervet, Belgium). The immunoglobulin concentration in the serum of this foal was > 8g/l 16 hours after birth. Two days later, the mare showed an elevated temperature (39.8°C) and therefore the uterus was flushed with saline. The next day, the foal showed severe dyspnea, without fever. A treatment with ipratropiumbromide (Atrovent[®], Boehringer Ingelheim NV, Belgium), ceftiofur (Excenel[®], Pfizer, Belgium), oxygen and furosemide (Dimazon[®], Intervet, Belgium) was started. No clinical improvement was seen and the foal died a few hours later.

At the same farm, a second healthy foal was born from an 8-year-old Belgian Warmblood mare after 346 days of pregnancy. Placenta expulsion occurred within 20 minutes. The placental weight was increased (8,950 kg) and edema was seen on the pregnant horn. No other placental abnormalities were noticed upon macroscopic examination. Samples from the pregnant horn, corpus and placenta at the level of the cervix were fixed in 10% formalin for histological examination. The foal received anti-tetanus serum (Intervet, Belgium) and prophylactic antibiotics (Cobactan[®] 4.5%, Intervet, Belgium) were given for 5 days. The concentration of immunoglobulins, which was checked 18 hours after birth, was higher than 8 g/l. Ten days later, the foal was found suffering from tachypnea and tachycardia and died before further clinical examination and veterinary treatment were initiated.

LABORATORY EXAMINATIONS

Gross examination

Post-mortem examination of both foals revealed enlarged, non-collapsed, congested and consolidated lungs with superficial rib imprints. Alveolar, interstitial and focal bullous emphysema was present in the craniodorsal lobes of the second foal. Samples from the lungs were fixed in 10% formalin for histology and immunohistochemistry. In addition, samples from the lungs and spleen were collected for bacteriological examination and samples from the lungs, spleen and liver were collected for virological examination.

Histological examination and immunohistochemistry

Fixed samples were embedded in paraffin, sectioned at 4 µm and stained with hematoxylin and eosin (HE) according to standard techniques.

Histologically, a focal moderately necrotizing vasculitis was found in allantochorionic villi (Figure 1a). Adjacent to this lesion, a moderate infiltrate of neutrophils and lymphocytes was present. Multifocal co-

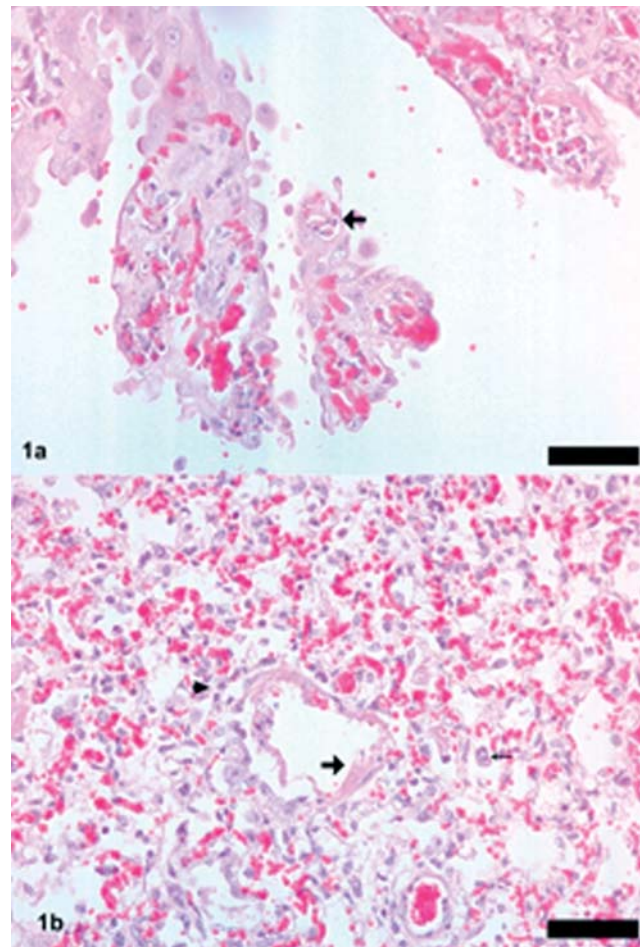


Figure 1. a: Necrotizing vasculitis of arteriole (arrow) in the chorion of the placenta. HE, bar 50 µm. **b:** Acute alveolar damage in lungs: hyaline membranes (large arrow) in bronchioli, hyperplastic type 2 pneumocytes (arrowhead) and activated pulmonary alveolar macrophages (small arrow). Bar 250 µm.

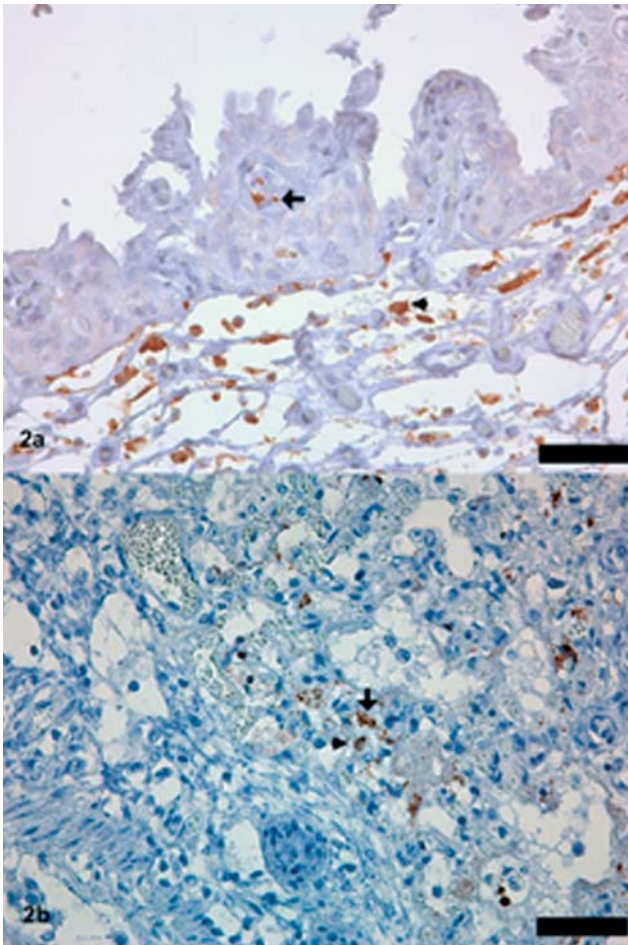


Figure 2. a: Positive immunolabeling for EVA in endothelial cells (arrow) and macrophages (arrowhead) in chorion of the placenta. Bar 50 μm . **b:** Positive immunolabeling for EVA in endothelial cells of alveolar capillaries (arrow) and pulmonary alveolar macrophages (arrowhead) in lungs. Bar 50 μm .

agulation necrosis of placental trophoblasts was observed upon microscopic examination. In the lungs of both foals, multifocal necrosis of alveolar and bronchiolar epithelial cells was present. Alveoles were often lined by hyaline membranes (Figure 1b). Overall, the number of alveolar macrophages was increased. Type II pneumocytes were hypertrophied and hyperplastic (Figure 1b). Occasionally, necrosis of the tunica media of medium-sized arteries was observed.

Paraffin sections from lungs and placenta were stained by immunohistochemistry using a mixture of three mouse monoclonal antibodies (mAbs): two mAbs were directed against the G1 protein and one mAb was directed against the M protein of EAV (van der Meulen *et al.*, 2001). Staining was performed using Envision-mouse (Dako, Denmark). In addition, samples of liver and lungs were immunostained with biotinylated anti-EHV1 polyclonal antibodies (van der Meulen *et al.*, 2003), followed by Envision+system-HRP (DAB) (Dako, Denmark) for exclusion of equine herpesvirus type 1 (EHV1) infection. Immunolabelling for EAV antigens was positive in the lungs of both foals and the placenta of the second

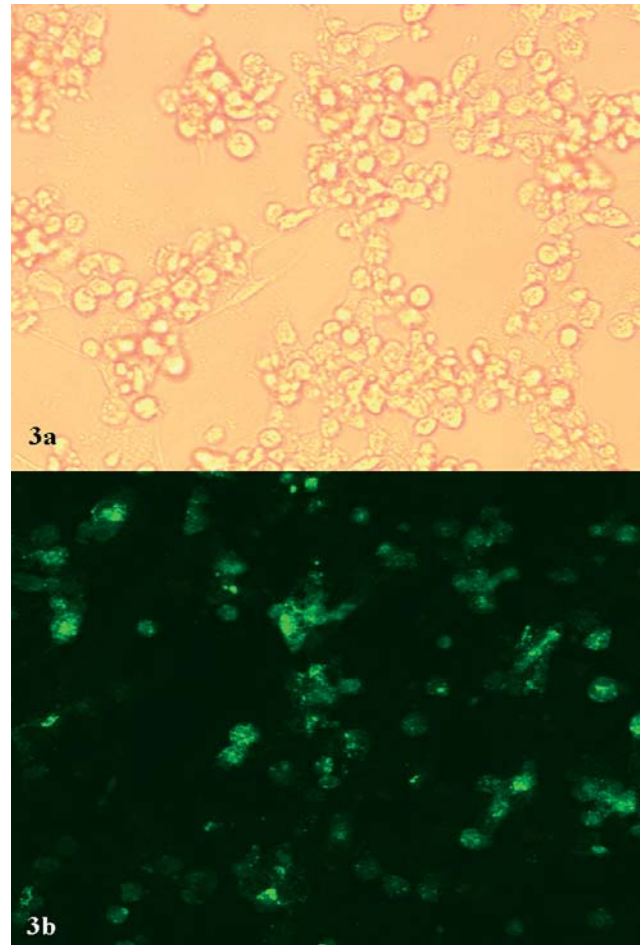


Figure 3. a: Cytopathic effect of EVA in RK13 cells at 7 days post inoculation. Rounding and vacuolization of the cells were observed. **b:** EVA-positive RK13 cells as revealed by immunofluorescence.

foal. Positive staining in allantochorion was restricted to patchy areas of vascular endothelium and macrophages in the lamina propria (Figure 2a). In the lungs, multifocal, ad random distributed areas of EAV positive cells were mainly localized in the endothelium of alveolar capillaries and occasionally in moderately-sized arteries, as well as in the alveolar macrophages (Figure 2b). EHV1 antigens were not demonstrated.

Bacteriological examination

Standard bacteriological and mycological examinations were performed on the lungs and spleen of both foals. Pathogenic bacteria were not isolated from any of the samples.

Virological examination

Suspensions (20%) of the lungs, spleen and liver were incubated for 1 hour with monolayers of RK 13 cells at 37°C in an atmosphere containing 5% CO₂. Afterwards, the inoculum was replaced by medium and

the cells were further incubated. Rounding and vacuolization of the RK13 cells were observed after 4 days of incubation, and after 7 days most of the cells were detached from their support (Figure 3a). No such changes were observed in the negative control cells.

An indirect immunofluorescence staining was performed on virus-infected RK13 cells and lung tissue using the three anti-EAV mouse mAbs, as described above. In a second step, tissues and cells were incubated with a goat anti-mouse antibody labeled with FITC (Molecular Probes, Eugene, OR, USA). EAV-positive antigens were found in the cytoplasm of virus-infected RK13 cells (Figure 3b) and in the cytoplasm of lung cells.

DISCUSSION

Although equine viral arteritis (EVA) has a worldwide distribution, few clinical cases have been reported in Belgium. In 2000, a severe outbreak of abortion occurred in a Belgian stud (van der Meulen *et al.*, 2001). The present study describes the first neonatal foal death caused by EVA in Belgium.

How the outbreak started remains elusive, as both foals appeared normal at birth. In the first case, the mare showed fever two days post-partum. The most common cause for fever after partus is an endometritis. However, in this case the placenta was completely expelled and no macroscopic remains could be found during uterine lavage with saline, although the reliability of macroscopic evaluation can be questioned. No further examination of the placenta was performed. In the second case, the placenta was edematous and closer examination revealed a focal moderately necrotizing vasculitis in the allantochorionic villi. Such lesions suggest an infectious cause, and an *in utero* infection of the foal (Del Piero *et al.*, 1997). The hypothesis of an infectious etiology was confirmed by immunohistochemical staining, where EAV-positive macrophages and endothelial cells were demonstrated in the allantochorion. Transplacental infections with EVA during late gestation have been reported, but are not very common (Vaala *et al.*, 1992; Timoney and McCollum, 1993). Neonatal deaths associated with naturally acquired EVA have also been reported (Doll *et al.*, 1957; Golnick *et al.*, 1981), along with a sporadic, isolated case in a foal (Vaala *et al.*, 1992). Hence, to date, only a few reports of EVA outbreaks are available, primarily affecting neonates (Del Piero *et al.*, 1997; Del Piero, 2000). The histological findings in the lungs and allantochorion are in agreement with those reports.

Looking in retrospect, the outbreak described in this study probably started with an EVA infection in the first mare, which was introduced without quarantine to the farm to foal. The virus was most likely then transmitted by the respiratory route to the foal. The second mare probably got infected around the same period, either via the respiratory route or via indirect contamination, and it then passed the virus on, *in utero*, to its unborn foal. There were no records of other

horses showing fever or other symptoms in the same stable at that time. Since the infections were mostly subclinical, other adult horses on the same farm might have got an EVA infection without being noticed. More than 40 foals were born healthy on the farm in the months following this outbreak.

The outbreak of EVA in neonates described in the present report serves as a warning about the necessity to include EVA in the differential diagnosis when foals are presented with fever, depression, edema, respiratory distress and/or sudden death. Since the prevalence of EVA in Belgium seems to be rising, more clinical outbreaks can be expected in the future. Although vaccines are available abroad, they are not yet registered for use in Belgium. The most important measures in the event of an outbreak in Belgium are management strategies such as quarantining new animals and eliminating EVA-positive breeding stallions from breeding populations (Holyoak *et al.*, 2008).

ACKNOWLEDGEMENTS

The authors wish to thank Chris Bracke, Sarah Loomans, Delphine Ameye and Christian Puttevils for their excellent technical assistance, as well as Professor Dr. P. Rottier of the University of Utrecht for providing the three mouse monoclonal antibodies.

REFERENCES

- Bryans J.T., Crowe M.E., Doll E.R., McCollum W.H. (1957). Isolation of a filterable agent causing arteritis of horses and abortion by mares; its differentiation from the equine abortion (influenza) virus. *The Cornell Veterinarian* 47, 3-41.
- Cavanagh D. (1997). Nidovirales: a new order comprising Coronaviridae and Arteriviridae. *Archives of Virology* 142, 629-633.
- Del Piero F., Pamela A., Wilkins, Lopez J.W., Glaser A.L., Dubovi E.J., Schlafer D.H., Lein D.H. (1997). Equine viral arteritis in newborn foals: clinical, pathological, serological, microbiological and immunohistochemical observations. *Equine Veterinary Journal* 29 (3), 178-185.
- Del Piero F. (2000). Equine Viral arteritis. *Veterinary Pathology* 37, 287-296.
- Doll E.R., Knappenberger R.E., Bryans J.T. (1957). An outbreak of abortion caused by the equine arteritis virus. *The Cornell Veterinarian* 47, 69-75.
- de Vries A.A.F., Rottier P.J.M., Glaser A.L., Horzinek M.C. (1996). Equine viral arteritis. In: Studdert M.J. (editor). *Virus Infections of Vertebrates, Volume 6: Virus infections of Equines*. Elsevier Science B.V., Amsterdam, p. 171-200.
- Golnick W., Michalska Z., Michalak T. (1981). Natural equine viral arteritis in foals. *Schweizer Archiv für Tierheilkunde* 123, 523-533.
- Henson J.B., Crawford T.B. (1974). The pathogenesis of virus-induced arterial disease-Aleutian disease and equine viral arteritis. *Advances in Cardiology* 13, 183-191.
- Holyoak G.R., Little T.V., McCollum W.H. and Timoney P.J. (1993). Relationship between onset of puberty and establishment of persistent infection with equine arteritis virus in the experimentally infected colt. *Journal of Comparative Pathology* 109, 29-46.

Holyoak G.R., Balasuriya U.B.R., Broaddus C.C., Timoney P.J. (2008). Equine viral arteritis: Current status and prevention. *Theriogenology* 70, 403-414.

McCullum W.H., Prickett M.E., Bryans J.T. (1971). Temporal distribution of equine arteritis virus in respiratory mucosa, tissues and body fluids of horses infected by inhalation. *Research in Veterinary Science* 12, 459-464.

Timoney P.J., McCullum W.H. (1993). Equine viral arteritis. *Veterinary Clinics of North America – Equine Practice* 9, 295-309.

Vaala W.E., Hamir A.N., Dubovi E.J., Timoney P.J., Ruiz B. (1992). Fatal, congenitally acquired infection with equine arteritis virus in a neonatal Thoroughbred. *Equine*

Veterinary Journal 24, 155-158.

van der Meulen K., Caij A., Nauwynck H., Pensaert M. (2001). An outbreak of equine viral arteritis abortion in Belgium. *Vlaams Diergeneeskundig Tijdschrift* 70, 221-222.

van der Meulen K.M., Nauwynck H.J., Pensaert M.B. (2003). Absence of viral antigens on the surface of equine herpesvirus 1-infected blood mononuclear cells: strategy to avoid complement-mediated lysis. *Journal of General Virology* 84, 93-99.

HET GRIEPPVIRUS MUTEERT



ProteqFlu™ verandert mee



ProteqFlu is het enig goedgekeurde vaccin in Europa* dat de nieuwe stam A/eq/Ohio/2003 bevat. A/eq/Ohio/2003 wordt aanbevolen door de deskundigen van het OIE en WHO Expert Surveillance Panel on Equine Influenza Vaccines.

* Marketing autorisatie voor ProteqFlu met de Ohio/2003 stam (ter vervanging van de Kentucky/94 stam) was toegekend voor alle EU-landen en Zwitserland in april 2008.

ProteqFlu Samenstelling per dosis: Influenza A/equi-2/Ohio/03 [H3N8] recombinant kanariepokkenvirus (vCP2242) en Influenza A/equi-2/Newmarket/2/93 [H3N8] recombinant kanariepokkenvirus (vCP1533), beide $\geq 5.2 \log_{10}$ FAID50. **ProteqFlu™-Te** - Suspensie - EU/2/03/038/005 (Reg. NL 10104): **Samenstelling** per dosis: Influenza A/equi-2/Ohio/03 [H3N8] recombinant kanariepokkenvirus (vCP2242) en Influenza A/equi-2/Newmarket/2/93 [H3N8] recombinant kanariepokkenvirus (vCP1533), beide $\geq 5.2 \log_{10}$ FAID50; Clostridium tetani toxoid ≥ 30 IU. **Doel diersoort:** Paarden. **Indicaties:** Actieve immunisatie tegen paardeninfluenza ter vermindering van klinische symptomen en van virussecretie na infectie en (ProteqFlu™-Te) tegen tetanus ter preventie van sterfte bij paarden van 4 maanden of ouder. **Dosering en toedieningsweg:** Eén dosis (1 ml) door middel van een intramusculaire injectie, bij voorkeur ter hoogte van de nek, volgens het volgende schema: Basisvaccinatie: de 1e injectie vanaf een leeftijd van 5-6 maanden, de 2de injectie 4-6 weken later. Herhalingsvaccinaties: 5 maanden na de basisvaccinatie en daarna jaarlijkse boosterinjecties. Bij verhoogd risico op infectie of onvoldoende opname van colostrum een extra eerste injectie op de leeftijd van 4 maanden, gevolgd door het volledige vaccinatieprogramma. **Contra-indicaties:** Geen. **Bijwerkingen:** voorbijgaande zwelling, in uitzonderlijke gevallen pijn, lokale hyperthermie, apathie, verminderde eetlust en overgevoeligheidsreactie. Een lichte stijging van de temperatuur (max. 1,5 °C) kan voorkomen. **Wachtijd:** Nul dagen. Op recept verkrijgbaar **diergeneesmiddel** (LDD); voor België MERIAL BELGIUM NV/SA, Bld Sylvain Dupuislaan 243, B-1070 Brussel, Tel: + 32-(0) 2 529 49 00; voor Nederland MERIAL B.V., Kleermakerstraat 10, 1991 JL Velsersbroek, Tel: + 31-235.20.10.80. hr230608.™ handelsmerk van Merial. © 2009. Alle rechten voorbehouden. Matt Art 14350/02/09.

