

## INHALATION ANESTHESIA WITH ISOFLURANE IN A BLACK JAGUAR (*PANTHERA ONCA*) FOR SURGICAL REPAIR OF A FRACTURED MANDIBLE

*Inhalatieanesthesie met isofluraan bij een zwarte jaguar (Panthera onca) voor de chirurgische correctie van een mandibulafractuur*

T. Waelbers<sup>1</sup>, T. Bosmans<sup>1</sup>, M. Risselada<sup>2</sup>, P. Verleyen<sup>2</sup>, I. Polis<sup>1</sup>

<sup>1</sup>Department of Small Animal Medicine and Clinical Biology

<sup>2</sup>Department of Medical Imaging of Domestic Animals, Faculty of Veterinary Medicine  
Ghent University, Salisburylaan 133, B-9820 Merelbeke

timwaelbers@hotmail.com

### ABSTRACT

A black jaguar (*Panthera onca*) was anesthetized with a combination of medetomidine, ketamine and isoflurane in oxygen for radiological examination and surgical repair of a fractured mandible. Since a non-domesticated cat is potentially dangerous, induction of anesthesia was performed by intramuscular injection using a mechanical squeeze cage. The cardiopulmonary parameters during anesthesia remained within normal ranges; only a small increase in the respiration rate was recorded 75 minutes after intubation. This hyperventilation was treated with buprenorphine (for additional analgesia) and an increased inspiratory fraction of isoflurane. Recovery was rather slow after 165 minutes of general anesthesia, so atipamezole was administered. Ten minutes after the intramuscular injection of atipamezole, the animal started to recover. Meloxicam and buprenorphine were used for post-operative analgesia.

### SAMENVATTING

Een zwarte jaguar (*Panthera onca*) werd onder algemene anesthesie gebracht met een combinatie van medetomidine, ketamine en isofluraan met zuurstof voor de radiografische diagnose en chirurgische correctie van een mandibulafractuur. Aangezien zo'n niet-gedomesticeerd dier gevaarlijk kan zijn, werd het dier in een dwangkooi geïnduceerd door middel van een intramusculaire injectie. Tijdens de anesthesie bleven de cardiopulmonaire parameters binnen de normale grenzen; er werd enkel een lichte stijging van de ademhalingsfrequentie geregistreerd 75 minuten na de intubatie. Deze lichte hyperventilatie werd behandeld door de inspiratoire fractie van isofluraan te verhogen alsook door buprenorphine als supplementair analgeticum toe te dienen. De recovery, na 165 minuten algemene verdoving, verliep eerder traag, totdat atipamezole werd toegediend. Tien minuten na de intramusculaire toediening van atipamezole, begon het dier te ontwaken. Meloxicam en buprenorphine werden gebruikt voor de behandeling van de postoperatieve analgesie.

### INTRODUCTION

Jaguars (*Panthera onca*) are the largest felid species in the New World and the only member of the genus '*Panthera*' that occurs in the Americas (Deem, 2004). They are exclusive forest dwellers and they use their anterior limbs to make primary contact with their prey, which can even exceed their own body weight (Gonyea, 1976).

Most of the veterinary procedures on these species involve chemical restraint. Because of the effects that restraint stress may have on the physiological parameters,

potentially compromising the animal once anesthetized, it is important to minimize the effects of such restraint (Nogueira and Silva, 1997; Deem, 2004). The application of mechanical restraint, such as a mechanical squeeze cage used for administering an injection to the animal, should be kept as short as possible.

Many species of non-domesticated cats are potentially dangerous, even when sedated, and for this reason, high doses of drugs are often given to ensure safety for those handling the animals (Forsyth *et al.*, 1999). However, it appears that big cats require less anesthetic per kilogram

to produce surgical anesthesia compared to smaller domestic cats (Thurmon *et al.*, 1996). The importance of appropriate dosing in combination with a correct estimation of the body weight should be emphasized.

Many species of non-domesticated cats have been immobilized with high doses of ketamine alone, but salivation, muscle rigidity and convulsions often occur (Hime, 1974). Since  $\alpha_2$ -agonists are potent central nervous system depressants with sedative, muscle relaxant and some analgesic properties, the combination of an  $\alpha_2$ -agonist with ketamine is preferred to negate the side effects of the latter (Nielsen, 1996). Combinations of xylazine and ketamine; medetomidine and ketamine; xylazine-midazolam-ketamine or medetomidine-midazolam-ketamine and even propofol and ketamine have been successfully used to anesthetize different species of wild felids (Jalanka and Koeken, 1990; Epstein *et al.*, 2002; Curro *et al.*, 2004).

Tiletamine, another dissociative anesthetic, has also been used for immobilizing wild felids, though with conflicting results. Grassman *et al.* (2004) used a combination of tiletamine and zolazepam to immobilize wild felids in Thailand and they preferred this combination over the combination of xylazine and ketamine because of the smaller volume that had to be injected, the faster induction time and the absence of prolonged muscle rigidity. Fahlman *et al.* (2005) even used the combination of medetomidine, zolazepam and tiletamine for anesthesia of free-ranging lions.

In lions and tigers, however, a certain percentage are at risk for a potentially life-threatening reaction to the tiletamine, which can present one or two days after an apparently full recovery. Some tigers have even died, apparently from continuous seizure activity and hyperthermia (L. Klein, personal communication, 2000). According to Wack (2003), tiletamine and zolazepam can be used safely in many species of Felidae, in which it produces smooth and rapid induction, with good muscle relaxation. It should, however, not be given to tigers, especially not to the white variant.

In the case of tigers, the combination of medetomidine and ketamine IM was chosen, because of the previously mentioned advantages, in addition to the rather small volume, the route of administration, our experience with this combination and the possibility of antagonizing medetomidine in the event of prolonged recovery. As the procedure was supposed to take a long time and because of the fact that oral surgery enhances the risk for aspiration of blood, it was opted to intubate the animal and maintain anesthesia using isoflurane in oxygen. After the IV catheter was placed, propofol, a fast acting intravenous anesthetic

agent, was used – as a safety measure – to provide supplemental anesthesia if it should be needed.

## CASE DESCRIPTION

### History

A 15-year-old female black jaguar (*Panthera onca*) with an estimated body weight of 40 kg was presented with a fractured mandible. The animal had been raised by its owner, lived in captivity, and was used to being handled, since she participated in commercials and movies. After she got stuck in her cage with her collar, she tried to free herself by biting the bars of the cage. This action resulted in a fracture of the mandible.

The animal had already been successfully anesthetized for clinical examination the previous day by the referring veterinarian, who used medetomidine 60  $\mu\text{g}/\text{kg}$  (Domitor®, Pfizer Animal Health, Louvain-la-Neuve, Belgium) and ketamine 2.5 mg/kg (Anesketin®, Eurovet, Heusden-Zolder, Belgium) intramuscularly. At that time she was also treated with antibiotics (amoxicillin and clavulanic acid) (Synulox® 8.75 mg/kg SQ, Pfizer Animal Health, Louvain-la-Neuve, Belgium) and the non-steroidal anti-inflammatory drug (NSAID), meloxicam (Metacam® 5 mg/ml, Boehringer Ingelheim Vetmedica GmbH, Germany), both intramuscularly.

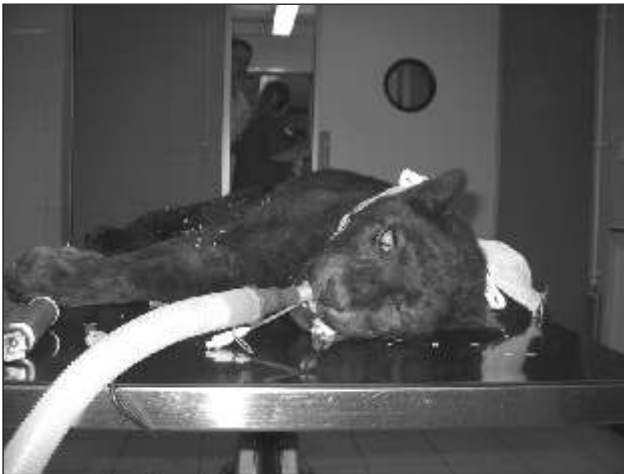She needed to be anesthetized for radiological confirmation of the diagnosis and surgery of the fractured mandible.

### Pre-anesthetic examination

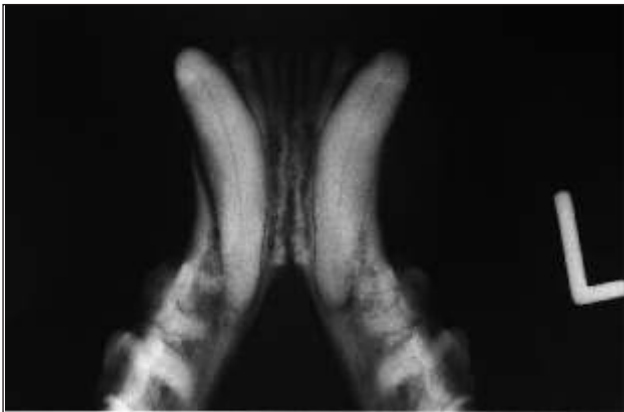
The animal was presented in the clinic in a small transportation cage (1x1x0,6m). Since it is a wild animal, the pre-anesthetic examination was restricted to the visual observation of the patient. Except for some excessive salivation due to the fractured mandible, the animal seemed to be in good physical condition. Although the animal had suffered an open fracture, bleeding out of the mouth was not observed. She was relatively calm and her respiration was costo-abdominal at a normal rate. According to the owner, food and water had been withheld for at least 12 hours.

### Anesthetic technique

The owner had trained the animal to enter a cage for transport without sedation. With a supplemental steel squeeze wall, the animal was pushed firmly against the bars of the cage, which made intramuscular injection for induction of anesthesia possible.



**Figure 1.** Jaguar in left lateral recumbency after endotracheal intubation in the preparation room.

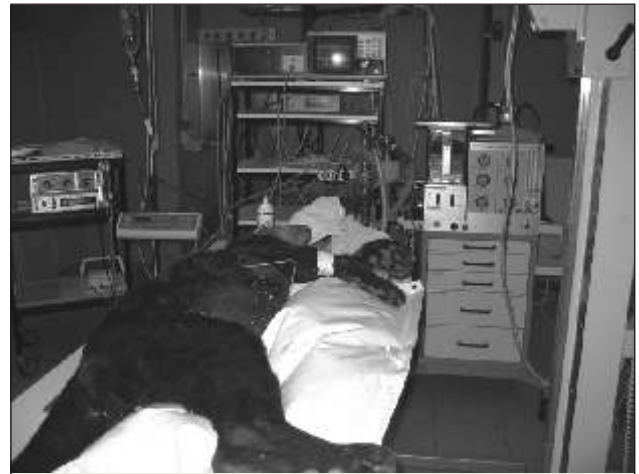

**Figure 3.** Preoperative radiography. An oblique fracture in the right mandibular body.

Anesthesia was induced with a combination of medetomidine 60 µg/kg (Domitor®, Pfizer Animal Health, Louvain-la-Neuve, Belgium) and ketamine 2.5 mg/kg (Anesketin®, Eurovet, Heusden-Zolder, Belgium) intramuscularly in the hind limb.

After 15 minutes the animal was taken out of the cage. After the larynx was visualized with a laryngoscope (Miller no. 3 blade) and sprayed with lidocaine (Xylocaine® 2%, Astra Zeneca, Brussels, Belgium), the animal was intubated using an 11 mm internal diameter silicone endotracheal tube (Cook Veterinary Products, Queensland, Australia). Intubation went very smoothly and the size of the endotracheal tube seemed to be right. The cuff was left deflated, since squeezing the reservoir bag did not reveal any leakage around it.

General anesthesia was maintained with isoflurane (Isoflo®, Abbott Laboratories Ltd., Queensborough, Kent, United Kingdom) in 1.4 L/min of oxygen using a circle anesthetic system (Spiromat 656, Dräger, Lübeck, Germany) and a precision out-of-circuit vaporizer (Vapor 19,3®, Dräger, Lübeck, Germany) (Figure 1). A 20 gauge



**Figure 2.** Jaguar in the surgical suite, with the anesthetic monitoring equipment attached; in the middle of the image at the top from left to right: the ECG recorder (Hewlett Packard) and the multi-anesthetic gas analyzer (Capnomac Ultima®, Datex Engstrom Instrumentation Corp.), beneath those the pulse oximeter (Nellcor Puritan Bennett Inc.) and at the right hand side the circle anesthetic machine (Spiromat 656, Dräger, Lübeck, Germany).

over-the-needle IV catheter (Optiva®2, Medex Medical Ltd. Haslingden, Rossendale, Great Britain) was placed in the cephalic vein and lactated Ringer's solution (Hartmann, Baxter, Lessen, Belgium) was infused at a rate of 10 ml/kg/h during anesthesia. A blood sample was taken out of the jugular vein for routine analysis (values summarized in Table 1).

The radiological examination, which was performed in the surgical theatre, took 45 minutes and revealed an open, oblique fracture in the right mandibular body, running along the caudal border of the canine tooth (Figure 3). Surgical repair was required and antibiotics were administered at induction: amoxicillin 10 mg/kg IV (Clamoxyl®, Glaxo-SmithKlein, Genval, Belgium) perioperatively and amoxicillin and clavulanic acid 8.75 mg/kg subcutaneously (Synulox®, Pfizer Animal Health, Louvain-la-Neuve, Belgium). After a standard aseptic preparation and with the jaguar in dorsal recumbency (Figure 2), surgery included an open ventral approach to appose the bone ends. Three encircling cerclage wires and a dorsal interfragmentary wire in a figure-of-eight configuration were used to maintain apposition of the fracture.

Seventy-five minutes after intubation, when the respiration rate was increasing, buprenorphine 0.3 mg (Temgesic® 0.3 mg/ml, Schering-Plough, Brussels, Belgium) was given intravenously. Just prior to recovery, meloxicam 7 mg (Metacam® 5 mg/ml, Boehringer Ingelheim Vetmedica GmbH, Germany) was administered intravenously to provide post-operative analgesia. The animal was covered with a heating pad during surgery.

**Table 1. Haematology and biochemistry of the panthera onca. Sample obtained just after the induction of anesthesia.**

Haematology (units)		Mean	Standard deviation
WBC (/μl)	20690	12010	4099
Segmented Neutrophils (/μl)	18766	8560	3920
Lymphocytes (/μl)	1262	2150	2090
Monocytes (/μl)	559	350	390
Basophils (/μl)	0	51	100
Eosinophils (/μl)	62	297	307
RBC (10 <sup>6</sup> /μl)	8.26	7.26	1.36
Hemoglobine (g/dl)	11.4	11.8	2.3
Hematocrit (%)	35.8	34.8	5.7
Platelet Count (10 <sup>3</sup> /μl)	0.371	273	107
<b>Biochemistry (units)</b>			
BUN (mg/dl)	54	24	9
Creatinine (mg/dl)	2.28	2	0.7
Total protein (g/dl)	7.3	7.3	0.6
Albumin (g/dl)	3.39	3.4	0.4
Total Bilirubin (mg/dl)	0.19	0.2	0.1
AST (IU/l)	148	35	16
ALT (IU/l)	55		
GGT (IU/l)	< 3	3	3
Glucose (mg/dl)	132	137	55

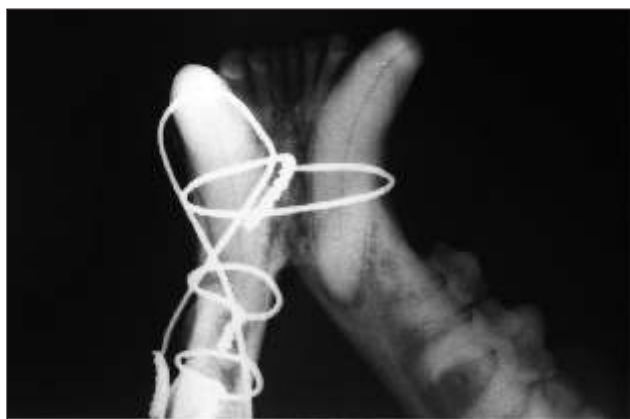Mean values and standard deviation (Deem, 2004).

Anesthetic monitoring included multi-gas analysis (Capnomac Ultima®, Datex, Helsinki, Finland), which determines inspiratory and end tidal anesthetic agent concentration (FiAA % and ETAA %), inspiratory oxygen fraction (FiO<sub>2</sub>), end tidal CO<sub>2</sub> concentration (ET CO<sub>2</sub> %) and respiratory rate (RR). Gas samples were taken at the Y-part with a rate of 200 ml/min and were returned to the anesthetic circuit. Tidal volume (TV) was measured using a respirometer (Volumeter®, Dräger, Lübeck, Germany), and heart rate (HR) and peripheral hemoglobin saturation (SpO<sub>2</sub> %) were monitored with a pulse oximeter (N-20PA Portable Pulse Oximeter®, Nellcor Puritan Bennett Inc.,

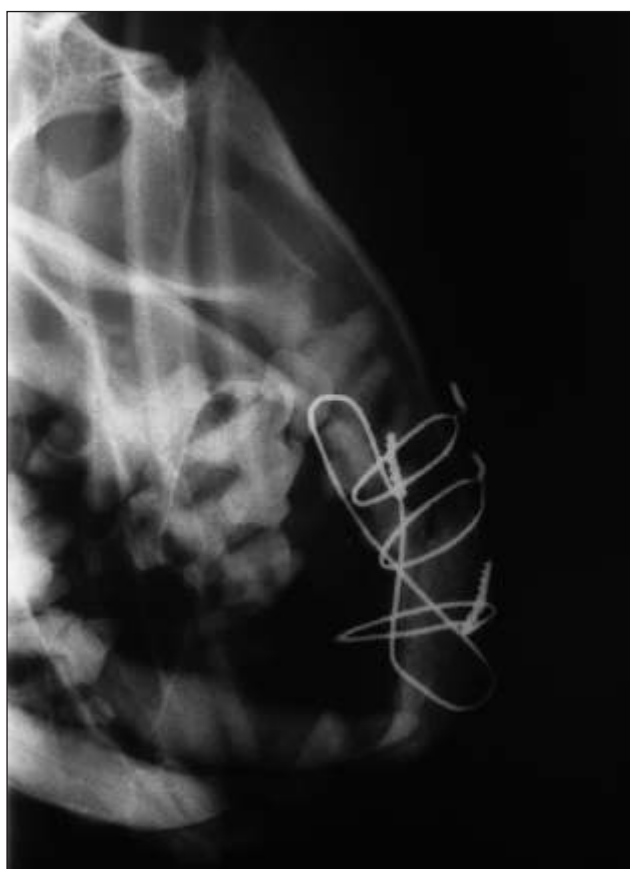Pleasanton, CA, U.S.A.) with the probe placed on the tongue. The electrocardiogram (ECG) (78352A, Hewlett Packard, Brussels, Belgium) was also continuously recorded. Evaluation of the eyelid reflex was difficult because of the draping of the surgical area and the position of the animal.

The patient breathed spontaneously throughout 165 minutes of general anesthesia. The first 60 minutes after intubation the respiration was rather irregular. At seventy-five minutes after intubation, the respiratory rate suddenly increased from 16 breaths per minute to 26 breaths per minute at which time buprenorphine 0.3 mg (Temge-





**Figure 4.** Postoperative radiography (ventrodorsal projection). A good apposition and alignment of the fracture caused by the encircling cerclage wires.



**Figure 5.** Postoperative radiography (lateral projection).

sic® 0.3 mg/ml, Schering-Plough, Brussels, Belgium) was administered intravenously and the inspiratory fraction of isoflurane was augmented from 0.8 to 1.2 (FiAA %), which resulted in a return to 18 breaths per minute at 100 minutes after intubation. The difference between the FiAA% (0.7-0.8%) and the ETAA% (0.6-0.7%) was stable until the vaporizer was turned higher; 15 minutes later the difference stabilized again at a higher level (1.3-1.4% and 0.9-1.1%, respectively), and remained at this level until the vaporizer was switched off. The tidal volume

was rather small but stable between 140 ml and a maximum of 200 ml. The end tidal CO<sub>2</sub> (ET CO<sub>2</sub> %) varied during the whole anesthesia period between 3% and 4.6% (23.4 and 35.9 mmHg, respectively). The heart rate increased from 48 beats per minute (bpm) in the beginning, to 85 bpm at the end of anesthesia. Cardiac arrhythmias were not observed. SpO<sub>2</sub>% remained between 97 and 100%.

After completion of surgery and postoperative radiographs, the venous catheter and all monitoring devices were removed in case the recovery should be unexpectedly rapid. The radiographs showed good apposition and alignment (Figures 4 and 5). Isoflurane was discontinued, and the animal was extubated and placed in its cage. The rectal temperature at this time was 35.3 °C, despite the use of a heating pad during surgery.

Since the animal was still not responsive 45 minutes after cessation of isoflurane administration, atipamezole 5 mg (Antisedan®, Pfizer Animal Health, Louvain-la-Neuve, Belgium) was given intramuscularly. Ten minutes later the animal started to respond to noise, so was moved into the truck and returned home. The day after surgery the animal was bright and responsive and was already able to eat small pieces of meat, as advised. She received antibiotics mixed in her food during the following five days (Synulox® 12.5 mg/kg PO b.i.d., Pfizer Animal Health, Louvain-la-Neuve, Belgium). According to the veterinarian, the animal was in good condition two months after surgery. Normally speaking, the three encircling cerclage wires and the dorsal interfragmentary wire still need to be removed.

## DISCUSSION

Persons undertaking to immobilize a wild animal take on responsibility for the health and safety of the animal and of all the persons working with it. Since these animals are more susceptible to stress than domesticated animals, it is important to induce anesthesia as quickly as possible. This is why, in our case, the animal was placed in quiet surroundings and anesthesia was rapidly induced using a combination of medetomidine and ketamine. Another difference compared to domesticated animals is the necessity to use intramuscular anesthetics in the wild species before placing an intravenous catheter. In general, anesthetic agents are administered by remote drug delivery systems (Deem, 2004), or exceptionally, as in this case, by an intramuscular injection through the bars of a squeeze cage, since this animal was used to human handling. As in domestic animals, adult felids should be fasted for at least 24 hours, and water should be withheld

for 12 hours before immobilization, to decrease the incidence of emesis and aspiration during induction and recovery from anesthesia (Lewis, 1994; Wack, 2003).

The blood results revealed that the thrombocyte count was clearly below the normal range. Possible explanations include clotting of the sample or the differing size of the platelets, which renders them undetectable for the blood count apparatus. According to Harvey (2001), platelet aggregates may occur even in properly collected EDTA-anticoagulated blood samples, and even small clots render a sample unuseable, as the platelet counts are markedly reduced. The increase of white blood cells caused by the elevation of segmented neutrophils, together with the decrease of lymphocytes and eosinophils, can be caused by stress. The high value of BUN is probably due to slight dehydration of the animal.

The choice of the anesthetic agents used depends on the type of intervention and surgery, and the presence or absence of pain. Acute pain is the result of a traumatic, surgical, or infectious event that is abrupt in onset and relatively short in duration. In general, it is alleviated by analgesic drugs. Drugs that can be used to reduce acute pain include the opioids, local anesthetics,  $\alpha_2$ -agonists and non-steroidal anti-inflammatory drugs (Dobromylskyi *et al.*, 2000). Balanced analgesia results from the administration of analgesic drugs, in combination and at multiple sites, to induce analgesia by altering more than one portion of the nociceptive process (Thurmon *et al.*, 1996). For all these reasons, a combined analgesic protocol including medetomidine, buprenorphine, ketamine and meloxicam was used.

In addition to their strong sedative effects,  $\alpha_2$ -adrenoceptor agonists have potent antinociceptive action, as described in both human and veterinary experimental and clinical studies (Maze and Tranquilli, 1991; Pertovaara, 1993). Although mostly used for pre-anesthetic medication, the antinociceptive action contributes to the intraoperative analgesia (Ossipov *et al.*, 1990). Additional advantages of incorporating an  $\alpha_2$ -agonist into the anesthetic protocol include both its reversibility and the resulting reduction of the amount of other anesthetics required for surgery. (Murrell and Hellebrekers, 2005). Medetomidine is a very selective and potent  $\alpha_2$ -agonist with a profound sedative and analgesic activity (Thurmon *et al.*, 1996). Following subcutaneous or intramuscular administration of medetomidine, bradycardia, peripheral vasoconstriction, vomiting and production of large volumes of dilute urine may be observed (Thurmon *et al.*, 1996). In our case however, vomiting did not occur, the production of urine was not monitored and the vasoconstriction was insufficient to cause difficulties in placing

an IV catheter. The bradycardic effects of medetomidine were probably offset by the sympathomimetic properties of ketamine. The antinociceptive synergism between  $\alpha_2$ -agonists and opioids is recognized (Ossipov *et al.*, 1990). Therefore, buprenorphine, a partial  $\mu$ -opioid agonist-antagonist, was added to the analgesic protocol. Its onset of action is relatively slow, requiring 20 to 30 minutes to reach full effect, but the analgesic action may last as long as 8 to 12 hours (Thurmon *et al.*, 1996). In the present case, buprenorphine was administered intravenously 75 minutes after intubation and when the respiration rate was increasing, probably as a reaction to a painful stimulus during surgery.

Non-steroidal anti-inflammatory drugs (NSAIDs) inhibit the formation of prostaglandins, which have a primary role in inflammation but are also critical to many physiological responses (Carroll and Simonson, 2005). NSAIDs generally are not sufficient by themselves to relieve severe postoperative pain, but they can be used in combination with opioids postoperatively to good effect because the two different drug groups have different sites and mechanisms of action (Thurmon *et al.*, 1996). Meloxicam is a NSAID with potent anti-inflammatory and analgesic properties and low gastrointestinal and renal toxicity (Carroll and Simonson, 2005). Because of the risk of transient hypotension or hemorrhage occurring during general anesthesia, meloxicam was administered just prior to recovery. If given preoperatively, fluids should be administered to support circulating volume (Carroll and Simonson, 2005). The administration of fluids to maintain normal blood pressure during anesthesia also decreases recovery time (Wack, 2003). In our case, lactated Ringer's solution (Hartmann, Baxter, Lessen, Belgium) was infused at a rate of 10 ml/kg/h during anesthesia.

Ketamine, on the other hand, which was used for induction of anesthesia, is a non-competitive antagonist to the phencyclidine site of the N-methyl-D-aspartate (NMDA) receptor for glutamate. The effects, however, are mediated by interactions with many other receptors (Annetta *et al.*, 2005). Ketamine produces dose-related unconsciousness and analgesia (Lin, 1996). It has been used successfully in many species, and doses vary widely from one species to another (Nielsen, 1996). The side effects of ketamine immobilization may include convulsions, catatonia, apnea, excessive salivation and hyperthermia as a consequence of catatonia (Nielsen, 1996). The use of ketamine is also known to cause an apneustic, shallow and irregular breathing pattern (Lin, 1996). Many of these side effects can be counteracted by adding a benzodiazepine or an  $\alpha_2$ -agonist, as was done in our case (Thurmon *et al.*, 1996).

When a procedure is expected to be of considerable duration, inhalation anesthesia and endotracheal intubation is preferred. Before endotracheal intubation, which can be achieved blindly or with a laryngoscope, the larynx should be sprayed with a local anesthetic to decrease the likelihood of laryngeal spasms (Thurmon *et al.*, 1996). Tubes of internal diameters between 12 and 18 mm are generally suitable for adult medium-sized cats (Lewis, 1994). In our case, the animal was intubated using an 11 mm id silicone endotracheal tube. The cuff was left deflated, since squeezing the reservoir bag did not reveal any leakage. Isoflurane, sevoflurane or halothane can be used safely as inhalation anesthetics in wild felids using precision vaporizers. According to Lewis (1994), isoflurane is the inhalant anesthetic agent of choice in non-domestic cats. In spite of the fact that recovery time might have been a little shorter using sevoflurane, isoflurane was used, mainly because of the experience of the authors using this inhalant.

A ventilator can be helpful for maintaining respiration because subclinical hypoxia is a common finding (Wack, 2003). In our case, despite the fairly small tidal volume, SpO<sub>2</sub>% remained above 97% and ET CO<sub>2</sub>% did not exceed 35.9 mmHg, so the patient was not ventilated.

Recovery is another critical point in the management of anesthesia in large exotic feline species. Due to safety considerations, intervention is usually impossible during this time. Therefore, the patient and the recovery area must be carefully prepared and recovery should be as fast as possible (Epstein *et al.*, 2002).

Since the recovery of the animal was relatively slow, atipamezole was administered intramuscularly, 45 minutes after cessation of isoflurane administration. Atipamezole is an  $\alpha_2$ -adrenoceptor antagonist with a high affinity for  $\alpha_2$ -adrenoceptors (high  $\alpha_2/\alpha_1$  selectivity ratio). It rapidly reverses sedation and anesthesia induced by  $\alpha_2$ -adrenoceptor agonists like medetomidine (Pertovaara, 2005). In a study involving 5 lions, atipamezole was able to reverse medetomidine-ketamine induced anesthesia smoothly and rapidly (Tomizawa *et al.*, 1997). In another study involving 6 adult lions anaesthetized with xylazine-ketamine, seizures occurred in 2 lions after xylazine was antagonized at the end of the procedure (Epstein, 2002). The time between induction of anesthesia and injection of atipamezole was much longer in the first study ( $\pm$  60 minutes) than in the second ( $\pm$  15 minutes), which might explain the seizures.

As atipamezole also reverses the analgesic effect of  $\alpha_2$ -adrenoceptor agonists, the need for additional analgesic medication must be evaluated, especially when painful procedures have been performed (Granhölm *et al.*, 2006). In our case analgesia was provided by buprenor-

phine and meloxicam as described previously. Ten minutes after the administration of the atipamezole, the animal started to react to noise, so it was then moved into the truck and returned home. Complete recovery was reached at home.

## CONCLUSION

Inhalation anesthesia with isoflurane in oxygen after induction of anesthesia using medetomidine and ketamine IM in a jaguar resulted in stable cardiopulmonary values throughout anesthesia. Adequate postoperative analgesia was provided using buprenorphine and meloxicam. Recovery was smooth and uneventful after atipamezole was used to antagonize the medetomidine. This combination of complementary drugs resulted in a safe and effective method for the immobilization of a black jaguar.

## REFERENCES

- Annetta MG, Iemma D., Garisto C., Tafani C., Proietti R. (2005). Ketamine: new indications for an old drug. *Current Drug Targets* 6, 789-794.
- Carroll GL., Simonson SM. (2005). Recent developments in nonsteroidal antiinflammatory drugs in cats. *Journal of the American Hospital Association* 41, 347-354.
- Curro TG., Okeson D., Zimmerman D., Armstrong DL., Simmons LG. (2004). Xylazine-midazolam-ketamine versus medetomidine-midazolam-ketamine anesthesia in captive Siberian tigers (*Panthera tigris altaica*). *Journal of Zoo and Wildlife Medicine* 35, 320-327.
- Deem S.L. (2004). Capture and immobilization of free-living jaguars (*Panthera onca*). In: Heard D. (editor). *Zoological Restraint and Anesthesia*. International Veterinary Information Service ([www.ivis.org](http://www.ivis.org)), Ithaca, New York, USA. Internetreferentie: [www.ivis.org](http://www.ivis.org). Document No. B0183.1204.
- Dobromylskiy P., Flecknell PA., Lascelles BD., Pascoe PJ., Taylor P., Waterman-Pearson A. (2000). Management of postoperative and other acute pain. In: Flecknell P., Waterman-Pearson A. (eds.). *Pain Management in Animals*. W.B. Saunders, London, p. 81-145.
- Epstein A., White R., Horowitz IH., Kass PH., Ofri R. (2002). Effects of propofol as an anesthetic agent in adult lions (*Panthera leo*): a comparison with two established protocols. *Research in Veterinary Science* 72, 137-140.
- Fahlman A., Loveridge A., Wenham C., Foggin C., Arnemo JM., Nyman G. (2005). Reversible anesthesia of free-ranging lions (*Panthera leo*) in Zimbabwe. *Journal of the South African Veterinary Association* 76, 187-192.
- Forsyth SF., Machon RG., Walsh VP. (1999). Anaesthesia of a Sumatran tiger on eight occasions with ketamine, medetomidine and isoflurane. *New Zealand Veterinary Journal* 47, 105-108.
- Gonyea WJ. (1976). Adaptive differences in the body proportions of large felids. *Acta Anatomica* (Basel) 96, 81-96.



- Granhölm M., McKusick BC., Westerholm FC., Aspegren JC. (2006). Evaluation of the clinical efficacy and safety of dexmedetomidine or medetomidine in cats and their reversal with atipamezole. *Veterinary Anaesthesia and Analgesia* 33, 214-223.
- Grassman LI Jr., Austin SC., Tewes ME., Silvy NJ. (2004). Comparative Immobilization of Wild Felids in Thailand. *Journal of Wildlife Diseases* 40, 575-578.
- Harvey John W. (2001). *Atlas of Veterinary Hematology*. W.B. Saunders Company, Philadelphia, p.3-20.
- Hikasa Y., Takase K., Ogasawara S. (1989). Evidence for the involvement of alpha2-adrenoceptors in the emetic action of xylazine in cats. *American Journal of Veterinary Research* 50, 1348-1351.
- Hime JM. (1974). Use of Ketamine Hydrochloride in Non-Domesticated Cats. *The Veterinary Record* 95, 193.
- Jalanka HJ., Koeken BO. (1990). The use of Medetomidine, Medetomidine-Ketamine combinations and atipamezole in Nondomesticated Mammals: A Review. *Journal of Zoo Wildlife Medicine* 21, 259-282.
- Lewis JCM. (1994). Anaesthesia of Non-domestic cats. In: Hall LW and Taylor PM (editors). *Anaesthesia of the Cat*. Baillière Tindall, London, 310-345.
- Lin HC (1996). Dissociative anesthetics. In: Thurmon JC., Tranquilli WJ., Benson GJ. (editors). *Lumb & Jones' Veterinary Anesthesia*. 3th Edition, Williams & Wilkins, Baltimore, 241-296.
- Maze M., Tranquilli W. (1991). Alpha-2 adrenoceptor agonists: defining the role in clinical anesthesia. *Anesthesiology* 74, 581-605.
- Murrell JC., Hellebrekers LJ. (2005). Medetomidine and dexmedetomidine: a review of cardiovascular effects and antinociceptive properties in the dog. *Veterinary Anaesthesia and Analgesia* 32, 117-127.
- Nielsen L. (1996). Chemical immobilization of free-ranging terrestrial mammals. In: Thurmon JC., Tranquilli WJ., Benson GJ. (editors). *Lumb & Jones' Veterinary anesthesia*. 3th Edition, Williams & Wilkins, Baltimore, 736-764.
- Nogueira GP., Silva JC. (1997). Plasma cortisol levels in captive wild felines after chemical restraint. *Brazilian Journal of Medical and Biological Research* 30, 1359-1361.
- Ossipov M., Harris S., Lloyd P., Messineo E., Lin BS., Bagley J. (1990). Antinociceptive interaction between opioids and medetomidine: systemic additivity and spinal synergy. *Anesthesiology* 73, 1227-1235.
- Pertovaara A. (1993). Antinociception induced by alpha-2-adrenoceptor agonists, with special emphasis on medetomidine studies. *Progress in Neurobiology* 40, 691-709.
- Pertovaara A., Haapalinna A., Sirvio J., Virtanen R. (2005). Pharmacological properties, central nervous system effects, and potential therapeutic applications of atipamezole, a selective alpha2-adrenoceptor antagonist. *CNS Drug Reviews* 11, 273-288.
- Thurmon JC., Tranquilli WJ., Benson GJ. (1996). *Lumb & Jones' Veterinary anesthesia*. 3th Edition, Williams & Wilkins, Baltimore, p. 40-60; p. 183-209; p. 686-735.
- Tomizawa N., Tsujimoto T., Itoh K., Ogino T., Nakamura K., Hara S. (1997). Chemical restraint of African Lions (*Panthera leo*) with medetomidine-ketamine. *The Journal of Veterinary Medical Science* 59 307-310.
- Wack Ray F. (2003) Felidae. In: Fowler ME, Miller RE (2003) *Zoo and Wild animal Medicine*. Fifth Edition, Saunders, Missouri, 491-501.