

Magnetic resonance (MRI) features of flexor enthesopathy (FE) in canine elbow.

I. Gielen, B. Van Ryssen, E. De Bakker, H. van Bree.

Department of Medical Imaging & Small Animal Orthopaedics, Veterinary Faculty, UGhent

Although the most important cause of elbow lameness in dogs is medial coronoid disease (MCD), recently flexor enthesopathy (FE) has been recognized as an elbow disorder in medium and large breed dogs and is characterized by lesions of the medial epicondyle and the attaching flexor muscles. The differential diagnosis between both elbow disorders is not obvious and a combination of these two elbow diseases is possible. The challenge in these cases is to define the cause of the elbow pain in order to make the correct treatment decision. In both, MCD and FE, the radiographic features may be minimal and indistinct. The aim of this study is to describe the imaging features in dogs suffering FE.

In literature **radiographic signs** of flexor pathology have mainly been described as a calcified body and less frequently as spur formation. Radiographically, an irregular outline of the medial humeral epicondyle, a calcified body and a spur are regarded as radiographic signs of flexor enthesopathy. These radiographic changes found in primary flexor enthesopathy are not significantly different from those found in concomitant flexor enthesopathy and can be incidental findings. However, radiography is unable to detect soft tissue pathology of the flexor muscles.

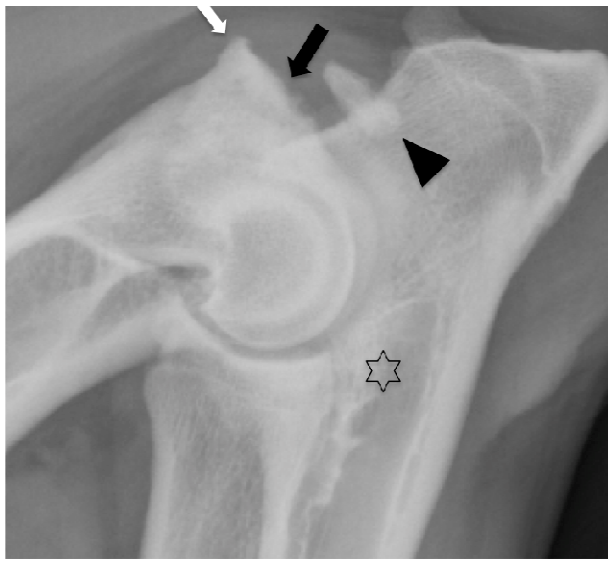
The main **ultrasonographic findings** of flexor enthesopathy are pre-insertional hypoechoic swelling, outward bowing and thickening of the common tendon of the flexor muscles. The tendon appears to be heterogenous with decreased echogenicity and focal or diffuse areas of irregular fibrillar appearance and ill-defined margins with partial or complete tears. Additionally cortical irregularities at the medial epicondyle (spur formation) and intra-tendinous calcifications can be detected.

HiSPECT, a refined scintigraphy technique, which enables more detailed anatomical localization of pathology within the elbow joint reveals focal increased bone tracer uptake in the region of the medial humeral epicondyle.

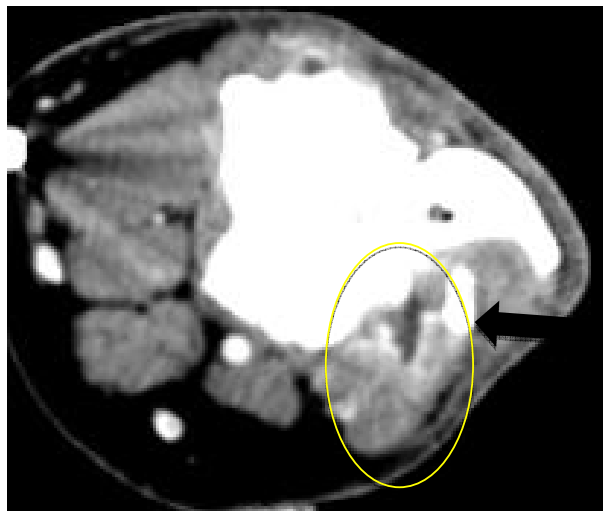Computerised tomography (CT) reveals new bone formation in all effected joints. The medial epicondyle appears sclerotic and shows a clear periosteal reaction in all cases. Mineralized opacity can be present within the flexor tendons. CT also shows concomitant lesions like coronoid disease whenever present. The soft tissue studies presents a thickening of the involved tendons in and IV administration of contrast shows enhancement in the affected tendons.

On **Magnetic Resonance Imaging (MRI)**, the sagittal T2-weighted sequence reveals a hyperintense signal around the proximal aspect of the flexor muscles extending in the muscle bellies. This signal can be confirmed as being a fluid signal on the fat suppressed STIR sequence. The T1 and T2 studies showed a thickening and irregular delineation of the involved tendons. There is obvious enhancement on T1 contrast studies.

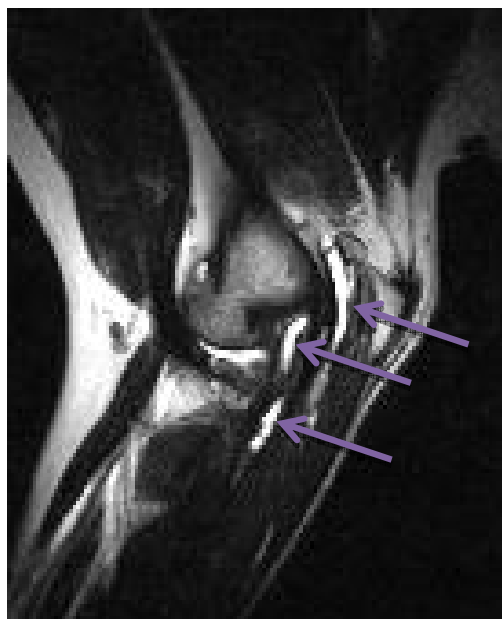
Arthroscopy shows the presence of loose fibres, degenerated tendinous tissue, cartilage loss and/or local synovitis at the attachment of the flexor muscles to the medial humeral epicondyle.



Lateral radiographic view of an elbow affected by primary flexor enthesopathy. An irregular outline of the medial humeral epicondyle (black arrow), a small spur (white arrow) and a large, elongated calcified body (black arrowhead) are visible. A moderate degree of subtrochlear sclerosis is visible (black star).



After intravenous injection of contrast medium clear enhancement on the soft tissue CT image is seen within the flexor muscles (yellow circle). The calcification within the flexor muscles can be noticed (black arrow).



T2 weighted sagittal MRI image showing fluid between the flexor muscles (purple arrows).