



Faculty of Medicine and Health Sciences

Long-term Outcome of Meniscus  
and  
Cruciate Ligament Stabilization  
in  
the Injured Knee

Franky Steenbrugge MD FRCS Ed

Thesis submitted as partial fulfilment of the requirements  
for the degree of PhD in Medical Sciences 2008

Promotor: Prof. Dr. R. Verdonk  
Co-promotor: Prof. Dr. K. Verstraete

ISBN : 9789081287913

EAN : 9789081287913

©Copyright 2008 F. Steenbrugge

No parts of this work may be reproduced in any form, by print, microfilm, or any other means, without written permission of the author.

Franky STEENBRUGGE

Department of Orthopaedic Surgery and Traumatology

ASZ Campus Aalst

Merestraat 80

B9300 Aalst

BELGIUM

franky.steenbrugge@telenet.be

'When faced without a challenge, make one'

Aan mijn ouders  
Voor Sophie, Charlotte, Amélie en Cédric

<b>Chapter I: General introduction and outline of the thesis</b>	7
1.1 Introduction	8
1.2 Meniscal tears	8
1.3 Anterior cruciate ligament tears	8
1.4 Why save the meniscus ?	9
1.5 Why reconstruct the ACL ?	10
<b>Chapter II: Description of the normal anatomy of the knee joint</b>	13
2.1 Anterior cruciate ligament	14
2.2 Posterior cruciate ligament	16
2.3 Blood supply to the cruciate ligaments	16
2.4 Neurosensory function of the cruciate ligaments	18
2.5 Menisci	18
2.6 Blood supply to the menisci	20
<b>Chapter III: Radiological imaging of the knee</b>	21
3.1 Introduction	22
3.2 Plain radiographs	22
3.3 Arthrography	22
3.4 Computed axial tomography	22
3.5 Magnetic resonance imaging	23
<b>Chapter IV Meniscal injury and repair</b>	27
4.1 Introduction	28
4.2 Meniscal healing and repair	30
4.3 Meniscal remodelling	31
4.4 Meniscal repair using a fibrin clot	32
4.5 Meniscal regeneration	32
4.6 Arthroscopic meniscal repair	33
4.6.1 Medial meniscus repair	33
4.6.2 Lateral Meniscus repair	36
4.6.3 All-inside technique using the Biofix resorbable arrows	36
4.7 Rehabilitation	38
<b>Chapter V: Anterior cruciate ligament injury and repair</b>	41
5.1 Who should have surgery?	42
5.2 When should surgery be done?	42
5.3 What should be operated on?	43
5.4 How should the operation be done?	43
5.4.1 Operative technique	44
5.4.2 Preparation of the intercondylar notch	44
5.4.3 Selection and preparation of osseous tunnels	44
5.4.4 Femoral tunnel location	45
5.4.5 Tibial tunnel location	46
5.4.6 Passing the graft	47

5.4.7 Fixation	48
5.5 Phases of ligament healing	49
5.6 Principles of rehabilitation	49
<b>Chapter VI: Clinical applications</b>	<b>55</b>
6.1 Long-term assessment of arthroscopic meniscus repair: a 13-year follow-up study	58
6.2 Arthroscopic meniscus repair: inside-out versus biofix meniscus arrow	70
6.3 Arthroscopic meniscus repair in the ACL-deficient knee	82
6.4 Magnetic resonance imaging of the surgically repaired meniscus: a 13-year follow-up study	89
6.5 Repair of chronic ruptures of the ACL using allograft reconstruction and a ligament augmentation device	96
6.6 Allograft reconstructions for chronic ruptures of the anterior cruciate ligament: augmentation versus non-augmentation	106
<b>Chapter VII: Discussion</b>	<b>117</b>
<b>Chapter VIII: Summary</b>	<b>125</b>
<b>Chapter IX: Samenvatting</b>	<b>129</b>
<b>Appendix</b>	<b>133</b>
<b>Acknowledgements</b>	<b>159</b>
<b>Curriculum Vitae</b>	<b>163</b>



CHAPTER I  
GENERAL INTRODUCTION AND  
OUTLINE OF THE THESIS

# CHAPTER I: GENERAL INTRODUCTION AND OUTLINE OF THE THESIS

## 1.1 Introduction

The knee is designed for rapid and complex movements; at the same time, it is usually encumbered with the weight of the body.

These two requirements, speed and strength, place stresses upon the joint which may in turn produce symptoms. Another characteristic is the exposed position of the knee which makes it vulnerable in many occupations and sports. The combination of this vulnerability to injury and its underlying sophistication must be kept in mind when identifying the mechanism of injuries to the knee but also when planning a return to normal activities, let alone to strenuous forms of work or to athletics.

## 1.2 Meniscal tears

Meniscal tears are the most common intraarticular knee injuries, comprising 75% or more of all internal derangements of the knee (35). Historically, operative treatment for symptomatic meniscal tears involved total meniscectomy by arthrotomy regardless of tear type, size or location. This procedure, which was felt to be benign (36), was subsequently shown to produce major long-term sequelae. Fairbank (15) was the first to demonstrate clinically the deleterious long-term effects of total meniscectomy. His classic description of radiographic joint space narrowing, flattening of the femoral condyle, and marginal osteophyte formation after meniscectomy with subsequent progressive hyaline cartilage failure remains a landmark in the treatment of meniscal tears. The histologic and biochemical structure of the meniscus as well as its biological function have been well defined (2,6,23,37). The meniscal-ligamentous complex, which works in concert with joint congruity, provides functional stability through a wide range of stresses and demands. The menisci contribute to load transmission (17,26,37,42), shock absorption (25), joint stability (14,22,27,29) and lubrication of articular cartilage (10,31). The pivotal role of the meniscus in joint function as evidenced by the increased incidence of degenerative changes after meniscectomy has been underscored (9,10,15,21,22,25,28,31,41).

During the last decade increasing understanding of the histologic, biologic and functional significance of the menisci has led to a more conservative therapeutic approach to lesions of the meniscus. Today's selective approach includes nonoperative treatment of meniscal tears, partial meniscectomy, and meniscal repair as alternatives to routine meniscectomy.

Since Annandale (1) reported the first meniscal repair in the late 1800s, studies of the vascular anatomy of the meniscus have documented its healing potential (3,4,22).

Clinical reports of successful open and arthroscopic repairs have engendered enthusiasm for these procedures. Long-term follow-up of meniscal repair procedures is important to ascertain that repaired menisci will survive, function effectively, and prevent the late degenerative changes seen after meniscectomy (5,11,12,16,38).

## 1.3 Anterior Cruciate Ligament tears

Acute ACL rupture is most commonly associated with injury to other ligaments of the knee, the menisci, or both. In combination with collateral ligament ruptures it has been found to further com-



promise stability (17,37).

Consequently, a direct correlation has been suggested between the complexity of the injuries associated with ACL rupture and the need for surgical repair or replacement.

Likewise, patients without associated ligamentous or meniscal injuries (those having isolated ACL ruptures) are assumed to have a better prognosis. Autogenous and allogeneic grafts that have been used to reconstruct ACL-deficient knees undergo a precipitous drop in strength in the early postoperative period due to tissue necrosis, revascularization, and remodelling (4,12,28,37,40).

#### **1.4 Why save the meniscus ?**

Thomas Annandale was the first to perform a medial meniscal suture. A 10-month old torn anterior horn of the medial meniscus was sutured to its peripheral attachment. The patient was discharged after 10 weeks with an almost normal functioning knee. Since that time, arthrotomy and meniscectomy have become common orthopaedic procedures.

Indeed, in the 1950's and 1960's total meniscectomy was performed for almost any meniscal tear that was positive on clinical examination. In the last two decades, however, arthroscopy of the knee joint has provided us with a means of performing adequate meniscectomy following the technical rules laid down by several authors (7,8,18,20,21).

The period between 1970 and 1980 showed that with a carefully executed arthroscopic meniscectomy for a torn meniscus, functional restoration was achieved in more than 90% of cases.

The short-term results of these resections are comparable to those of open meniscectomy as far as the medial compartment of the knee is concerned.

In the longer term and in the event of medial meniscectomy, factors such as varus malalignment and mechanical overload increase the risk of degeneration of the loadbearing cartilage in the medial compartment. Not only will the buffer function of the semilunar cartilage be absent between the femoral condyle and medial tibial plateau, but the stabilizing factor, i.e. the meniscal wall, will also be lacking.

As a result, there will be an increased anteroposterior shift of the femoral condyle in relation to the medial plateau.

Any ligamentous laxity produced by the initial trauma, will increase the degenerative changes in the load bearing area.

Of even more importance but medically uncontrollable, is the magnitude of the mechanical load. This load is a separate element dependent on the weight of the patient and on work- and sports-related activity.

The same principle applies to the older age groups. The short-term results of accurate arthroscopic meniscectomy are superior to those of open total meniscectomy (8,40).

This can be accounted for by the preservation of the meniscal wall. Again, the quality of the loadbearing cartilage will determine the functional outcome in this age group.

In the long run, only 50% of the patients will benefit from arthroscopic medial meniscectomy. These poor to fair results, in the older age groups have cautioned against the negative consequences of meniscectomy, so that a meniscal suture is performed whenever this is feasible.

Whithin a short time, meniscal suture will lead to meniscal healing, and one can expect a functionally competent knee and an anatomical restoration in 90% of the cases (12).

If one accepts that chondral congruity is improved by the presence of the medial meniscus under loading conditions, then this certainly applies to the lateral compartment. Indeed, the convex lateral femoral condyle articulates with an almost convex lateral plateau.

The contact area between both cartilaginous elements is flattened and widened only because of the presence of the O-shaped lateral meniscus. One should even be more cautious in the treatment of a lateral meniscal lesion than when confronted with a torn medial meniscus (19,32,34).

### **1.5 Why reconstruct the ACL ?**

When we ask whether it is appropriate to operate on the ACL, we must ask two additional questions: How does the knee joint function shortly after rupture of the ACL ? What are the long-term sequelae of an untreated rupture?

Both questions touch on the problems of the natural history of an untreated ACL rupture.

To answer them, we must look at previously published data and reports that let us compare the results of non operative treatment (functional therapy or immobilization and splintage) or lack of treatment in undiagnosed cases with surgical intervention (though there may be substantial differences in terms of economic implications such as vocational and athletic disability and the costs of physical therapy and splints).

To answer the above questions, let us recall the typical course of an untreated ACL rupture: untreated instability of the ACL can cause a subjective feeling of instability that is manifested by episodes of giving-way, i.e. a sudden buckling of the knee due to pathologic translation and a momentary loss of proprioceptive coordination at the joint.

This causes very large peak loads and shear stresses to act upon the cartilage, menisci, and the peripheral capsule and ligaments (13).

One result of this may be the "ACL syndrome" with cartilage erosion, meniscal lesions, and peripheral laxity. Late sequelae include postmeniscectomy and instability-related osteoarthritis. It has also been observed that the absence of the ACL is well tolerated by some patients, who can continue to perform their normal activities and even engage in sports without external support for 20-30 years (13).

Other patients can remain asymptomatic by modifying their activities, such as changing to a less strenuous form of recreation. Finally there are patients who do very well with a knee brace and experience no instability problems. It remains unclear whether this asymptomatic or minimally symptomatic "conservative" group will remain free of longterm degenerative disease and retain full, permanent functional competence of the knee, or whether subthreshold, subclinical pathologic translations and rotations will lead to accelerated degenerative articular changes. Classic studies, of which there are still far too few, provide some insight into this question (13,22,24,30).

The goal of this thesis is to enhance the knowledge of the long-term results of meniscus repair and anterior cruciate reconstruction with respect to the development of osteoarthritis.

### **References**

1. Annandale T. An operation for displaced semilunar cartilage. *Br Med J* 1885; 1: 799.
2. Arnoczky S, Adams M, DeHaven KE. Meniscus. In Woo SY, Buckwalter JA, eds. *Injury and Repair of the Musculoskeletal Soft Tissues*. Chicago, American Academy of Orthopedic Surgeons, 1987: 487.
3. Arnoczky SP, Warren RF. The microvasculature of the meniscus and its response to injury : An experimental study in the dog. *Am J Sports Med* 1983; 11: 131-141.

4. Arnoczky SP, Warren RF. The microvasculature of the human meniscus. *Am J Sports Med* 1982; 10: 90-95.
5. Bronstein R, Kirk P, Hurley J. The usefulness of MRI in evaluating menisci after repair. *Orthopedics* 1992; 15: 149-152.
6. Bullough PG, Munuera L, Murphy J. The strength of the menisci of the knee as it relates to their fine structure. *J Bone Joint Surg (Br)* 1970; 52B: 564-570.
7. Cannon WD. Arthroscopic meniscal repair. In McGinty JB, ed. *Operative Arthroscopy*, New York, Raven Press, 1991; 237-251.
8. Cannon WD, Morgan CD. Meniscal repair. *J Bone Joint Surg (Am)* 1994; 76A: 294-311.
9. Dandy DJ, Jackson RW. The diagnosis of problems after meniscectomy. *J Bone Joint Surg (Br)* 1975; 57B: 349-352.
10. Dandy DJ, Jackson RW. Meniscectomy and chondromalacia of the femoral condyle. *J Bone Joint Surg (Am)* 1975; 57A: 1116-1119.
11. DeHaven KE. Meniscus repair : current concepts. *Am J Sports Med* 1999; 27: 242-250.
12. DeHaven KE, Lohrer WA, Lovelock JE. Long-term results of open meniscus repair. *Am J Sports Med* 1995; 23: 524-530.
13. Dejour H, Walch G, Deschamps G, Chambat P. Arthrose du genou sur laxité chronique antérieure. *Rev Cir Orthop* 1987 ; 73: 157-170.
14. Egli S, Wegmüller H, Kosina J. Long-term results of arthroscopic meniscal repair : an analysis of isolated tears. *Am J Sports Med* 1995; 23: 715-720.
15. Fairbank TJ. Knee joint changes after meniscectomy. *J Bone Joint Surg (Br)* 1949; 30: 664-670.
16. Fukubayashi T, Kurosawa H. The contact area and pressure distribution pattern of the knee. *Acta Orthop Scand* 1980; 51: 871-879.
17. Hanks GA, Gause TM, Sebastianelli WJ. Repair of peripheral meniscal tears : Open versus arthroscopic technique. *Arthroscopy* 1991; 7: 72-77.
18. Hanks GA, Trenton MG, Handal JA. Meniscus repair in the anterior cruciate deficient knee. *Am J Sports Med* 1990; 18: 606-613.
19. Henning CE. Arthroscopic repair of meniscus tears. *Orthopedics* 1983; 6: 1130-1132.
20. Jackson JP. Degenerative changes in the knee after meniscectomy. *Br Med J* 1968; 72: 525-527.
21. Johnson RJ, Kettlekamp DB, Clark W. Factors affecting late results after meniscectomy. *J Bone Joint Surg (Am)* 1974; 56: 719-729.
22. King D. The healing of the semilunar cartilages. *J Bone Joint Surg* 1936; 18: 333-342.
23. Kostogiannis I, Ageberg E, Neuman P, Dahlberg L, Friden T, Roos H (2007) Activity level and subjective knee function 15 years after anterior cruciate ligament injury: a prospective, longitudinal study of nonreconstructed patients. *Am J Sports Med* 2007; Jul(35): 1135-1143.
24. Krause WR, Pope MH, Johnson RJ. Mechanical changes in the knee after meniscectomy. *J Bone Joint Surg (Am)* 1976; 58A: 599-604.
25. Kurosawa H, Fukubayashi T, Nakajima H. Load-bearing mode of the knee joint: Physical behavior of the knee joint with or without menisci. *Clin Orthop* 1980; 149: 283-290.
26. Levy IM, Torzilli PA, Warren RF. The effect of medial meniscectomy on anterior-posterior motion of the knee. *J Bone Joint Surg (Am)* 1982; 64A: 883-888.
27. Macnicol MF, Thomas NP. The knee after meniscectomy. *J Bone Joint Surg (Br)* 2000; 82B: 157-159.
28. Markolf KL, Bargar WL, Shoemaker SC. The role of joint load in knee stability. *J Bone Joint Surg (Am)* 1981; 63A: 570-585.

30. McDaniel WJ, Dameron TB. The untreated anterior cruciate ligament rupture. *Clin Orthop* 1983; 172: 158-163.
31. Radin EL, Delamotte F, Maquet P. Role of the menisci in the distribution of stress in the knee. *Clin Orthop* 1984; 185: 290-294.
32. Recht MP, Kramer J, Marcelis S. Abnormalities of articular cartilage in the knee: analysis of available MR techniques. *Radiology* 1993; 187: 473-478.
33. Renström P, Johnson RJ. Anatomy and biomechanics in the knee. *Clin Sports Med* 1990; 9: 523-538.
34. Rubman MR, Noyes FR, Barber-Westin SD. Arthroscopic repair of meniscal tears that extend into the avascular zone : a review of 198 single and complex tears. *Am J Sports Med* 1998; 26: 87-95.
35. Shands AR, Hutchinson JL, Ziv L. Derangements of the semilunar cartilages of the knee: A clinical and experimental study. *South Med J* 1936;29:1045-10502.
36. Smillie JS. *Injuries to the knee joint*. Baltimore, Williams and Wilkins, 1961.
37. Stone RG, Frewin PR, Gonzales S. Long-term assessment of arthroscopic meniscus repair : a two- to six-year follow-up study. *Arthroscopy* 1990; 6: 73-78.
38. Tenuta JJ, Arciero RA. Arthroscopic evaluation of meniscal repairs. Factors that effect healing. *Am J Sports Med* 1994; 22: 797-802.
39. Van Trommel MF, Potter HG, Ernberg LA. The use of noncontrast Magnetic Resonance Imaging in evaluating meniscal repair. *Arthroscopy* 1998; 14:2-8.
40. Verdonk R, Meire D, Van De Velde C, Van Eetvelde G, Claessens H. CT scan of the knee: correlation with clinical and arthroscopic findings. *Acta Orthop Belg* 1991; 57: 49-55.
41. Veth RPH. Clinical significance of knee joint changes after meniscectomy. *Clin Orthop* 1985; 198: 56-60.
42. Walker PS, Erkman MJ. The role of the menisci in force transmission across the knee. *Clin Orthop* 1975; 109: 184-192.

CHAPTER II  
DESCRIPTION OF THE NORMAL ANATOMY  
OF THE KNEE

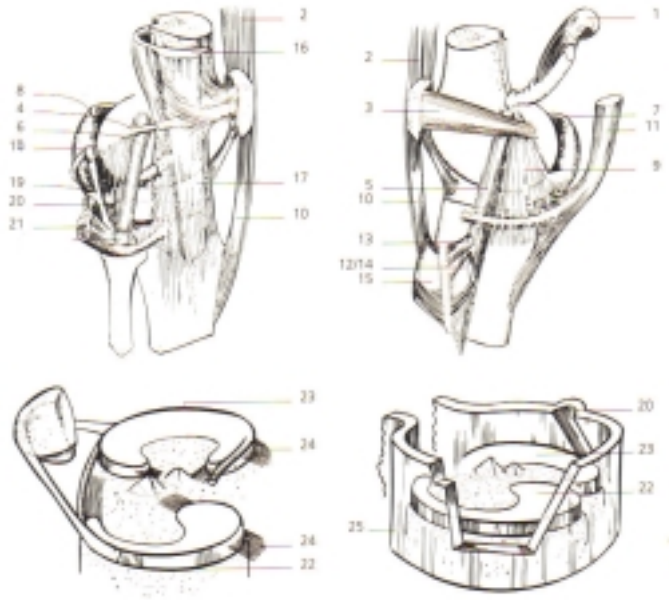
# CHAPTER II: DESCRIPTION OF THE NORMAL ANATOMY OF THE KNEE JOINT

## Basic science of the knee - Anatomy

### 2.1 Anterior cruciate ligament

The anterior cruciate ligament (ACL) is attached to a fossa on the posterior aspect of the medial surface of the lateral femoral condyle. The femoral attachment is in the form of a segment of a circle, with its anterior border straight and its posterior border convex. Its long axis is tilted slightly forward from the vertical, and the posterior convexity is parallel to the posterior articular margin of the lateral femoral condyle (2,5,6)(Fig.1).

The tibial attachment of the ACL is in a fossa in front of and lateral to the anterior tibial spine. At this attachment, the ACL passes beneath the transverse meniscal ligament, and a few fascicles of the ACL may blend with the anterior attachment of the lateral meniscus. In some instances, fascicles from the posterior aspect of the tibial attachment of the ACL may extend to and blend with the posterior attachment of the lateral meniscus. The tibial attachment of the ACL is somewhat wider and stronger than the femoral attachment. The ACL courses anteriorly, medially and distally across the joint as it passes from the femur to the tibia. As it does, it twists on itself in a slight outward (lateral) spiral. This occurs because of the orientation of its bony attachments. The orientation of the femoral attachments of the ACL, with regard to joint position (flexion-extension), is also responsible for the relative tension of the ligament throughout the range of motion. The ACL is attached to the femur and tibia not as a single cord but rather as a collection of individual fascicles that fan out over a broad, flattened area. These fascicles have been summarily divided into two groups: the anteromedial band (AMB), those fascicles originating at the proximal aspect of the femoral attachment and inserting at the anteromedial aspect of the tibial attachment, and the posterolateral bulk (PLB), the remaining bulk of fascicles, which are inserted at the posterolateral aspect of the tibial attachment. When the knee is extended, the PLB is taut, and the AMB is moderately lax. However, as the knee is flexed, the femoral attachment of the ACL assumes a more horizontal orientation, causing the AMB to tighten and the PLB to loosen (2,5,6). Although this designation provides a general idea as to the dynamics of the ACL through the range of motion, it is an oversimplification. Whereas a functional anteromedial band is defined in flexion and a posterolateral band is present in extension, the ACL is actually a continuum of fascicles, a different portion of which is taut throughout the range of motion. This is of great clinical importance because in any position of the knee, a portion of the ACL remains under tension and functional.



**FS**

Fig. 1 : Anatomy of the knee

- |                                    |                                     |
|------------------------------------|-------------------------------------|
| 1. M. Gastrocnemius caput medialis | 15. M. Sartorius                    |
| 2. M. Quadriceps tendon            | 16. Fascia lata                     |
| 3. Medial retinaculum patellae     | 17. Iliotibial band                 |
| 4. Lateral retinaculum patellae    | 18. Fabellum                        |
| 5. Medial collateral ligament      | 19. Ligamentum popliteum arcuatum   |
| 6. Lateral collateral ligament     | 20. M. Popliteus and tendon         |
| 7. Posteromedial capsule           | 21. M. Biceps and tendon            |
| 8. Posterolateral capsule          | 22. Medial meniscus                 |
| 9. Medial collateral ligament      | 23. Lateral meniscus                |
| 10. Patellar tendon                | 27. Fibrous attachments of meniscus |
| 11. M. Semimembranosus             | 28. Capsule                         |
| 12. Pes anserinus                  |                                     |
| 13. M. Gracilis                    |                                     |
| 14. M. Semitendinosus              |                                     |

## 2.2 Posterior cruciate ligament

The posterior cruciate ligament (PCL) is attached to the posterior aspect of the lateral surface of the medial femoral condyle (Fig.1). Like the ACL, the femoral attachment of the PCL is in the form of a segment of a circle. The general orientation of the attachment is in the horizontal plane, with the lower boundary convex and parallel to the lower articular margin of the condyle (2,5,6).

The tibial attachment of the PCL is a slight depression located behind the intraarticular proximal surface of the tibia. The attachment extends for a few millimetres onto the posterior surface of the tibia. Shortly above its tibial attachment, the PCL sends a few fascicles to blend with the posterior horn of the lateral meniscus.

As with the ACL, the shape of the femoral and tibial attachments of the PCL and their orientation in flexion and extension determine the relative tension and laxity of the ligament components. In extension, the anterior bulk of the ligament is lax, whereas a small posterior band of fascicles is taut. When the knee is flexed, this posterior band becomes lax, and the anterior bulk of the ligaments tightens. This again is an oversimplification but serves to exemplify the multifascicular arrangement of the ligament and the fact that these fascicles tighten and loosen throughout the range of motion. Cadaver studies have shown the anterior band to be significantly larger and stronger than the posterior band (2,3,5,6).

## 2.3 Blood supply to the cruciate ligaments

The blood supply to the cruciate ligaments arises from the ligamentous branches of the middle genicular artery, as well as some terminal branches of the inferior genicular arteries. The cruciate ligaments are covered by a synovial fold that originates at the posterior inlet of the intercondylar notch and extends to the anterior tibial insertion of the ligament, where it joins the synovial tissue of the joint capsule distal to the infrapatellar fat pad (1,2,3,5,6)(Fig.2,3).

This synovial membrane, which forms an envelope about the ligaments, is richly endowed with vessels that originate predominantly from the ligamentous branches of the middle genicular artery. A few smaller terminal branches of the lateral and medial inferior genicular arteries also contribute some vessels to this synovial plexus through its connection with the infrapatellar fat pad. The synovial vessels arborize to form a weblike network of periligamentous vessels, which ensheath the entire ligament. These periligamentous vessels then give rise to smaller connecting branches, which penetrate the endoligamentous vessels.

These vessels, along with their supporting connective tissues, are oriented in a longitudinal direction and lie parallel to the collagen bundles within the ligament (1,2,3,5,6).

The blood supply to the cruciate ligaments is predominantly of soft-tissue origin. Although the middle genicular artery gives off additional branches to the distal femoral epiphysis and proximal tibial epiphysis, the ligamentous-osseous junction of the cruciate ligaments does not contribute significantly to the vascular scheme of the ligaments themselves (1,2,5,6).

Although the PCL is in intimate contact with the ligamentous branches of the middle genicular artery and the vascular synovial tissue of the posterior joint capsule, there is no evidence to suggest that the PCL has a better vascular supply than the ACL (1,3).



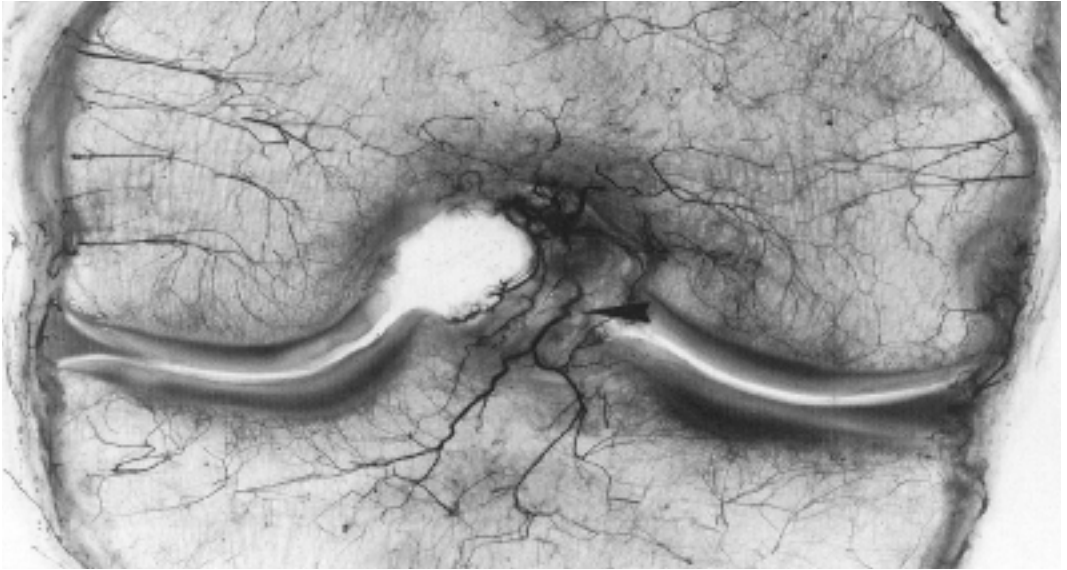


Fig. 2 : The blood supply to the cruciate ligaments arises from ligamentous branches of the middle genicular artery as well as some terminal branches of the inferior genicular arteries

From *Knee Anatomy for Orthopaedic Surgeons ESSKA 2000*

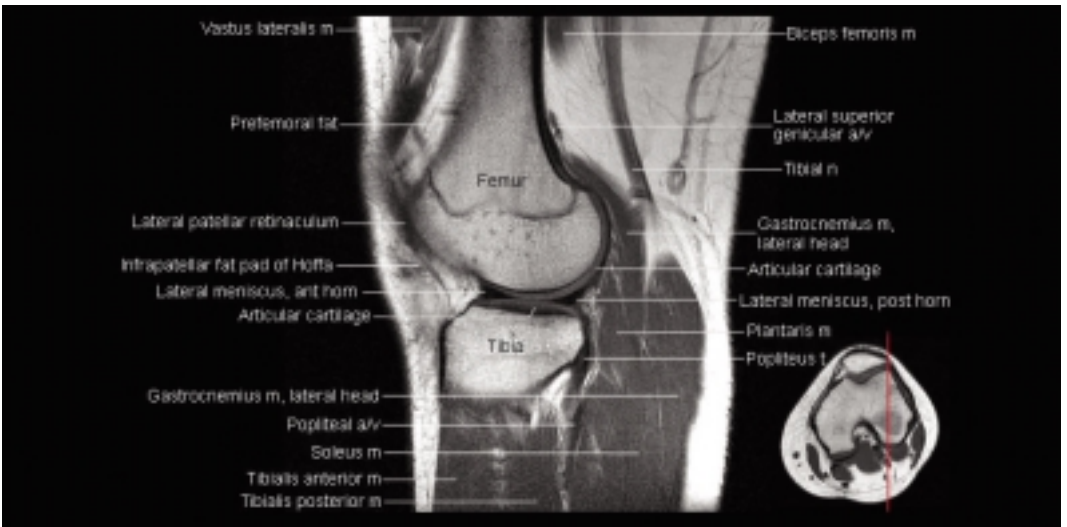


Fig. 3 : Sagittal MRI image of the knee showing the musculature, blood supply and innervation of the knee

From *Knee Anatomy for Orthopaedic Surgeons ESSKA 2000*

## 2.4 Neurosensory function of the cruciate ligaments

Nerve fibers and sensory receptors have been described throughout the ACL, either accompanying vessels in the form of neurovascular bundles or located separately within the ligament. It has been estimated that 1% of the volume of the ACL is occupied by free nerve endings and specialized nerve receptors, including Ruffini end-organs and pacinian corpuscles. Although the ACL does appear to have some sensory input in joint position and movement, its role is not well understood (3).

## 2.5 Menisci

The menisci are C-shaped discs of fibrocartilage interposed between the condyles of the femur and the tibia (1,2,5,6,7)(Fig.1,4). Properly regarded as functional extensions of the tibia, the menisci serve to deepen the surfaces of the articular fossa of the head of the tibia for the reception of the condyles of the femur (1). The peripheral border of each meniscus is thick, convex and attached to the inside capsule of the joint. The opposite border tapers to a thin, free edge. The proximal surfaces of the menisci are concave and in contact with the condyles of the femur. Their distal surfaces are flat and rest on the articular surface of the proximal tibia. The medial meniscus is somewhat semicircular in form. It is approximately 3.5 cm in length and considerable wider posteriorly than it is anteriorly. The anterior horn of the medial meniscus is attached to the tibial plateau in the area of the anterior intercondylar fossa in front of the ACL (1,2,5,6,7)(Fig. 1,4).

The posterior fibers of the anterior horn attachment merge with the transverse intermeniscal ligament, which connects the anterior horns of the medial and lateral menisci. The posterior horn of the medial meniscus is firmly attached to the posterior intercondylar fossa of the tibia between the attachments of the lateral meniscus and the PCL. The periphery of the medial meniscus is attached to the joint capsule throughout its length. The tibia portion of this capsular attachment is often referred to as the coronary or meniscotibial ligament. At its midpoint, the medial meniscus is more firmly attached to the femur and tibia through a condensation in the joint capsule known as the deep medial ligament (1,6).

The lateral meniscus is almost circular and covers a larger portion of the tibial articular surface than the medial meniscus. The anterior and posterior horns are approximately the same width (1,2,5,6,7)(Fig.1,4).

The anterior horn of the lateral meniscus is attached to the tibia in front of the intercondylar eminence and behind the attachment of the ACL, with which it partially blends. The posterior horn of the lateral meniscus is attached behind the intercondylar eminence of the tibia but anterior to the posterior root of the medial meniscus. Although there is no attachment of the lateral meniscus to the lateral collateral ligament, there is a loose peripheral attachment to the joint capsule. This peripheral attachment is interrupted at the posterolateral aspect of the knee to accommodate the passage of the popliteal tendon (popliteal hiatus). At this location, the inferior portion of the lateral meniscus is tethered to the joint capsule by an extension of capsular tissue (1,2,5,6,7).

In spite of these capsular attachments, the menisci are actually quite mobile. Using cine-MRI, a study has demonstrated 11.2 mm of translation of the lateral meniscus and 5.1 mm of the medial meniscus with flexion of the knee (7).

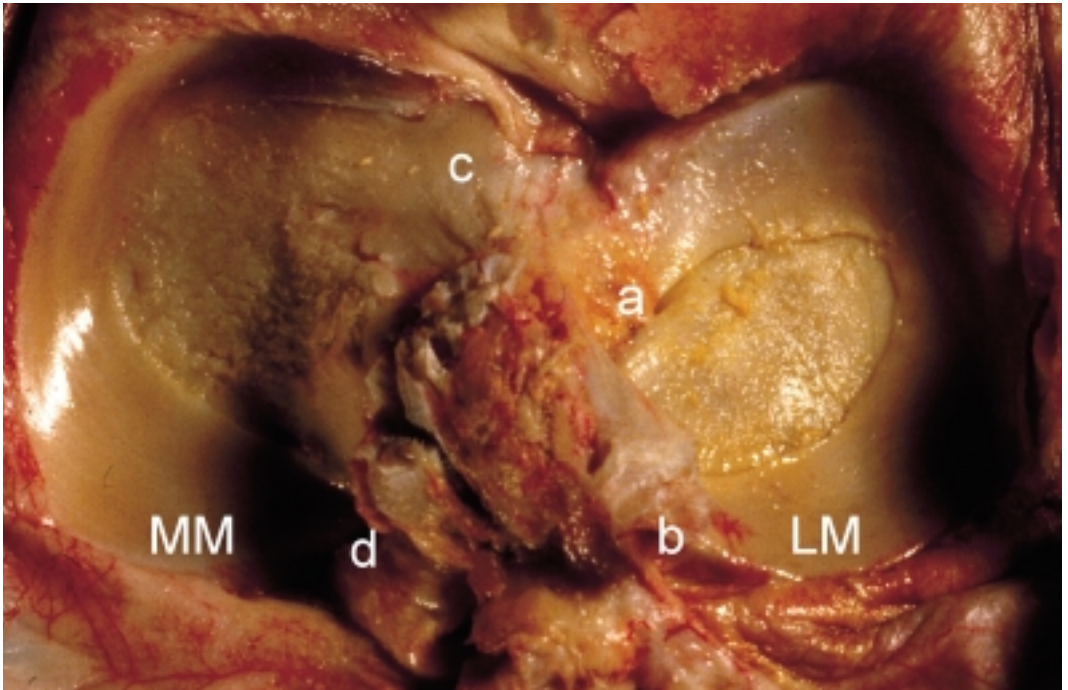


Fig. 4 : Medial and Lateral meniscus

Lateral Meniscus (LM) : covers about 80% of the lateral tibial plateau

(a) anterior horn inserts to the eminentia intercondylaris and posterior the ACL insertion

(b) posterior horn inserts to the eminentia intercondylaris and to the insertion of the medial meniscus

Medial Meniscus (MM) : covers about 60% of the medial tibial plateau

(c) anterior horn inserts anterior the ACL insertion

(d) posterior horn inserts between the posterior horn of the lateral meniscus and the PCL

From *Knee Anatomy for Orthopaedic Surgeons ESSKA 2000*

## 2.6 Blood supply to the menisci

The vascular supply to the medial and lateral menisci of the knee originates predominantly from the lateral and medial geniculate arteries (both inferior and superior) (1)(Fig.2,3).

Branches from these vessels give rise to a premeniscal capillary plexus within the synovial and capsular tissues of the knee joint. This plexus is an arborizing network of vessels that supplies the peripheral border of the meniscus throughout its attachment to the joint capsule.

These perimeniscal vessels are oriented in a predominantly circumferential pattern, with radial branches directed toward the center of the joint. Anatomic studies have shown that the degree of vascular penetration is 10% to 30% of the width of the medial meniscus and 10% to 25% of the width of the lateral meniscus (1,6). The middle genicular artery, along with a few terminal branches of the medial and lateral geniculate arteries, also supplies vessels to the meniscus through the vascular synovial covering of the anterior and posterior horn attachments. These synovial vessels penetrate the horn attachments and give rise to endoligamentous vessels that enter the meniscal horns for a short distance and end in terminal capillary loops. A small reflection of vascular synovial tissue is also present throughout the peripheral attachments of the medial and lateral menisci on both the femoral and tibial articular surfaces. (An exception is the posterolateral portion of the lateral meniscus adjacent to the area of the popliteal tendon). This synovial fringe extends for a short distance (1 to 3 mm) over the articular surface of the menisci and contains small, terminally looped vessels.

Although this vascular synovial tissue adheres intimately to the articular surface of the menisci, it does not contribute vessels into the meniscal tissue (1,6).

## References

1. Arnockzy SP, Warren RF. Microvasculature of the human meniscus. *Am J Sports Med* 1982 ; 10:90.
2. Gray H. *Gray's Anatomy*, 20th edition, 2000 New-York, Bartleby ed.
3. Harner CD, Xerogeanes JW, Carlin GL, Kusayama T. et al. The human posterior cruciate ligament complex : an interdisciplinary study. *Proceeding of the 20th annual American Orthopaedic Society for Sports Medicine Meeting*. 1994: 39-40.
4. Heller L, Langman J. The menisiofemoral ligaments of the human knee. *J Bone Joint Surg* 1964; 46B: 307.
5. McGinty JB. *Operative arthroscopy*. Lipincot –Raven 1996.
6. Neyret Ph, Verdonk R. *Knee anatomy for orthopaedic surgeons - ESSKA 2000*; CD presented at the ESSKA Conference 2004 Athens, Greece.
7. Thompson WO, Thaete L, Fu F, Dye SF. Tibial meniscal dynamics using three-dimensional reconstruction of magnetic resonance images. *Am J Sports Med* 1991; 19: 210-216.

CHAPTER III  
RADIOLOGICAL IMAGING OF THE KNEE

# CHAPTER III: RADIOLOGICAL IMAGING OF THE KNEE

## 3.1 Introduction

Today it's becoming more and more difficult to decide when it is necessary to rely on advanced imaging techniques. With such accurate non-invasive means of imaging available, it is only too easy to become overreliant on these techniques. The clinician must always remember that the clinical evaluation of the patients remains the cornerstone of diagnosis and treatment. An accurate, detailed history and physical examination are necessary not only in the primary evaluation of the patient, but also in the determination of appropriate imaging studies. The failure to perform an adequate clinical evaluation renders the orthopaedic physician an unimportant obstacle to the technological evaluation of the patient. Furthermore, with increasing pressure on physicians to efficiently use the resources available to them, unnecessary use of expensive adjunctive studies must be discouraged.

## 3.2 Plain radiographs

Plain radiographs are an essential part of the routine evaluation of the knee, and should be obtained as a screening tool regardless of clinical presentation.

The basic radiographic evaluation of the knee usually includes a standard anteroposterior (AP) view of the knee taken with the patient standing. It is important to include both knees in the exam so that subtle differences from the normal side can be noted. A lateral view is also obtained. In 45° of flexion, this allows for the most accurate evaluation of patellar height.

The Merchant view allows for patellar view (8). A standing flexion view or schuss view offers a good tool for early detection of joint narrowing (18).

Evaluation of bony abnormality remains the primary purpose of plain radiographs. General femorotibial alignment can be estimated, as can patellar alignment and tilt. Bone density is also assessed, and generalized or localized changes are noted.

A Segond fracture, or lateral capsular sign, has been shown to have a high correlation to ACL disruption. Calcification near the medial femora epicondyle, or Pellegrini-Stieda lesion, suggests injury to the medial collateral ligament (MCL)(9,19).

## 3.3 Arthrography

Arthrography of the knee has been nearly replaced by MRI as the imaging study of choice for intraarticular pathology of the knee (14,22). It can still, however, provide a fairly accurate radiographic assessment of the internal structures of the knee at institutions where MRI is not readily available, or in particular situations, such as following meniscal repair (7,12).

## 3.4 Computed axial tomography

With the rapid advances made in MRI, CT has taken on less importance in the evaluation of emergent and elective knee problems (14,20,22). Although its visualization of ligamentous and meniscal structures about the knee remains less accurate than MRI, it can still give valuable information about bony detail. Its standard axial images and reconstructions can give valuable insight into the configuration of complex fractures, especially those involving the tibial plateau. CT also remains an extremely valuable tool in the evaluation of bone and soft tissue tumors about the knee, where it can provide information as to the extent of a tumor as well as to its composition (22).

CT is less valuable in the evaluation of the menisci and ligaments of the knee. It has an accuracy of 89% for tears of the medial meniscus and 96% for the lateral meniscus (14,22).

Because of its inability to visualize the ligaments well, however, it remains inferior to MRI in this regard (14). Arthro CT allows to overcome some of these shortcomings. It's a valuable alternative in cases where MRI is not available (22).

### **3.5 Magnetic resonance imaging**

Magnetic resonance imaging is a rapidly evolving imaging modality that offers unsurpassed soft tissue imaging quality (5,10,13,15).

It has been used to evaluate meniscal, ligament, hyaline, synovial and tendon pathology (11,16,20,23).

Some shortcomings in the use of MRI exist, however. Some of these are technical limitations of the modality itself, including its occasional oversensitivity or findings for which the clinical significance has yet to be determined (3, 12,20). The best example of this is the identification of meniscal degeneration in asymptomatic knees (1,13,23).

MRI can accurately assess the condition of menisci, and this is one of its most common uses (4,19). The accuracy of MRI in identifying medial meniscus tears has been reported to range from 72% to 98%, with a sensitivity of 77-97.56% and a specificity of 37-100%. The positive predictive values and negative predictive values range from 68% to 89% and 79% to 98% respectively (3,6,16).

The ability to identify lateral meniscus tears is only slightly lower than for medial meniscus tears in most studies (3,16,20).

MRI is very accurate in the identification of ACL tears, ranging from 93% to 97% (4,6). The sensitivity and specificity have been shown to range between 61% and 100%, and 82% and 97% respectively (4,6). The Positive Predictive Value and Negative Predictive Value range from 70% to 76% and 70% to 100%, respectively (3,4,6).

The use of MRI to identify PCL tears has proven to be extremely accurate (3,4,6).

The collateral ligaments are also well visualized on MRI, although clinical examination alone is often adequate to assess the collateral ligaments.

MRI is valuable in the evaluation of hyaline cartilage lesions (17,23). It has been shown to identify lesions as shallow as 1 mm in depth and 100% of lesions greater than 3 mm in width and depth in cadavers. It has also been able to demonstrate up to 80% of partial thickness lesions in patients (17, 23).

Of growing importance is the evaluation of the postoperative knee (7,11,12,13,20,21).

MRI remains inconsistent in this regard. It has not proven very accurate in the evaluation of retears following surgery (12,20). Although MRI has been shown to be able to identify postoperative meniscal tears following partial meniscectomy with an accuracy of 89% if less than 25% of the meniscus has been previously resected, this drops to an accuracy of only 65% if 25-75% of the meniscus has been previously resected (1,6,7,11,12,13,21,23).

The accuracy has been increased to 87% with the use of contrast MRI (7,20).

The status of the menisci following repair has been especially difficult to evaluate (7,12,20).

Several studies have shown that repaired menisci may exhibit areas of increased signal intensity simulating changes consistent with a re-tear for over a year following repair in up to 90% of cases (2,7,12,20).

Because of this, an arthrogram should be considered (7,20,23).

The evaluation of ACL reconstructed knees has been more encouraging (6,11,20).

Despite its high level of accuracy, MRI must not be used as a substitute for sound clinical judgment, and it should not be used as a routine screening study in all cases where management is not likely to be affected, it need not be used (20).

However, there are limitations in the ability of the clinician to always make a definitive diagnosis and treatment recommendation, and it is here that MRI can be invaluable (20).

## References

1. Applegate GR, Flannigan BD, Tolin BS, Fox JM, Del Pizzo W. MR diagnosis of recurrent tears in the knee: value of intrarticular contrast material. *Am J Roentgenol* 1993; 161: 821-825.
2. Craig JG, Go L, Blechinger J, Hearshen D, Bouffard JA, Diamond M, van Holsbeeck MT. Three tesla imaging of the knee: initial experience. *Skeletal Radiol* 2005 Aug; 34(8): 453-461.
3. Fischer SP, Fox JM, Del Pizzo W, Friedman MJ, Snyder SJ, Ferkel RD. Accuracy of diagnosis from magnetic resonance imaging of the knee. *J Bone Joint Surg (Am)*1991;73A: 2-7.
4. Glashow JL, Katz R, Schneider M, Scott WN. Double-blind assessment of the value of magnetic resonance imaging in the diagnosis of anterior cruciate and meniscal lesions. *J Bone Joint Surg (Am)* 1989; 71A: 113-119.
5. Jackson DW, Jennings LD, Maywood RM, Berger PE. Magnetic resonance imaging of the knee. *Am J Sports Med* 1988; 16: 29-38.
6. Lee JK, Yao L, Phelps CT, Wirth CR, Czajka J, Lozman J. Anterior cruciate ligament tears: MR imaging compared with arthroscopy and clinical tests. *Radiology* 1988;166: 861-864.
7. Magee T, Shapiro M, Rodriguez J, Williams D. MR arthrography of postoperative knee: for which patients is it useful ? *Radiology* 2003; 229:159-163.
8. Merchant AC, Mercer RL, Jacobsen RH, Cool RC. Roetgenographic analysis of patellofemoral congruence. *J Bone Joint Surg (Am)* 1974; 56A: 1391-1396.
9. Milch H. Cortical avulsion fracture of the lateral tibial condyle. *J Bone Joint Surg (Am)* 1936; 18A: 159-164.
10. Mink JH, Levy T, Crues JV. Tears of the anterior cruciate ligament and menisci of the knee: MR imaging evaluation. *Radiology* 1988; 167: 769-774.
11. Moeser P, Bechtold RE, Clark T, Rovere G, Karstaedt N, Wolfman N. MR imaging of anterior cruciate ligament autografts during the first year of implantation. *Am J Sports Med* 1991; 19: 42-47.
12. Mustonen AO, Tielinen L, Lindahl J, Hirvensalo E, Kiuru M, Koskinen SK. MRI of menisci repaired with bioabsorbable arrows. *Skeletal Radiol* 2006 Jul; 35(7): 515-521.
13. Negendank WG, Fernandez-Madrid FR, Heilbrun LK, Teitge RA. Magnetic resonance imaging of meniscal degeneration in asymptomatic knees. *J Orthop Res* 1990; 8: 311-320.
14. Passariello R, Trecco F, Paulis F, Masciocchi C, Bonanini G, Zobel BB. Meniscal lesion of the knee joint: CT diagnosis. *Radiology* 1985; 157: 29-34.
15. Polly DW, Callaghan JJ, Sikes RA, McCabe JM, McMahan K, Savory CG. The accuracy of selective magnetic resonance imaging compared with the findings of arthroscopy. *J Bone Joint Surg (Am)* 1988; 70A: 192-198.
16. Raunest J, Oberle K, Loehnert J, Hoetzing H. The clinical value of of magnetic resonance imaging in the evaluation of meniscal disorders. *J Bone Joint Surg (Am)* 1991; 73A: 11-16.
17. Recht MP, Kramer J, Marcelis S. Abnormalities of articular cartilage in the knee: analysis of available MR techniques. *Radiology* 1993;187:473-478.



18. Ritchie J, Al-Sarawan M, Worth R. A parallel approach : the impact of schuss radiography of the degenerate knee on clinical management. *Knee* 2004; 11(4): 283-287.
19. Segond P. Recherches cliniques et expérimentales sur les épanchements sanguins du genou par entorse. *Progres Med* 7 : 1879 ; 7 : 279.
20. Thomas S, Pullagura M, Robinson E, Cohen A, Banaskiewicz P. The value of magnetic resonance imaging in our current management of ACL and meniscal injuries. *Knee Surg Sports Traumatol Arthrosc* 2007 May; 15(5): 533-536.
21. Van Trommel MF, Potter HG, Ernberg LA. The use of noncontrast Magnetic Resonance Imaging in evaluating meniscal repair. *Arthroscopy* 1998;14:2-8.
22. Verdonk R, Meire D, Van De Velde C, Van Eetvelde G, Claessens H. CT scan of the knee: correlation with clinical and arthroscopic findings. *Acta Orthop Belg* 1991; 57: 49-55.
23. Wojtys E, Wilson M, Buckwalter K, Braunstein E, Martel W. Magnetic resonance imaging of knee hyaline cartilage and intraarticular pathology. *Am J Sports Med* 1987; 15: 45-463.



CHAPTER IV  
MENISCAL INJURY AND REPAIR

# CHAPTER IV: MENISCAL INJURY AND REPAIR

## 4.1 Introduction

The menisci of the knee are formed of fibrocartilage, with some proteoglycan present. The collagen fibers are arranged in a predominantly circumferential orientation, which reflects the circumferential tension that develops in the meniscus during normal loading (1,2, 22,29,31).

The extracellular matrix of the fibrocartilagenous menisci is composed of collagen and proteoglycan. Biochemical analysis has shown that collagen comprises over 75% of the dry weight of meniscal fibrocartilage, whereas proteoglycan comprises only 2,5% (6,29,31).

Thus, fibrocartilage has a composition more like that of tendon than that of cartilaginous tissue (6,29,31).

Although the collagen in the meniscus is type I, similar to that found in bone and skin, the proteoglycans are in many ways similar to those found in hyaline cartilage (5,6,29,31). The most obvious differences between the proteoglycan of meniscal fibrocartilage and hyaline cartilage are in their composition and concentration. Meniscal fibrocartilage contains only about one-eighth the proteoglycan concentration of hyaline cartilage. Also, GAG composition differs, with dermatan sulphate making up 20% of the GAG content of the meniscus. Keratin sulphate accounts for approximately one third of the GAG pool, with the rest being made up of chondroitin sulphate. In spite of these differences, the proteoglycan molecules of the menisci convey functional properties similar to those of articular cartilage proteoglycan (5,6,31)(Fig 1,2,3).

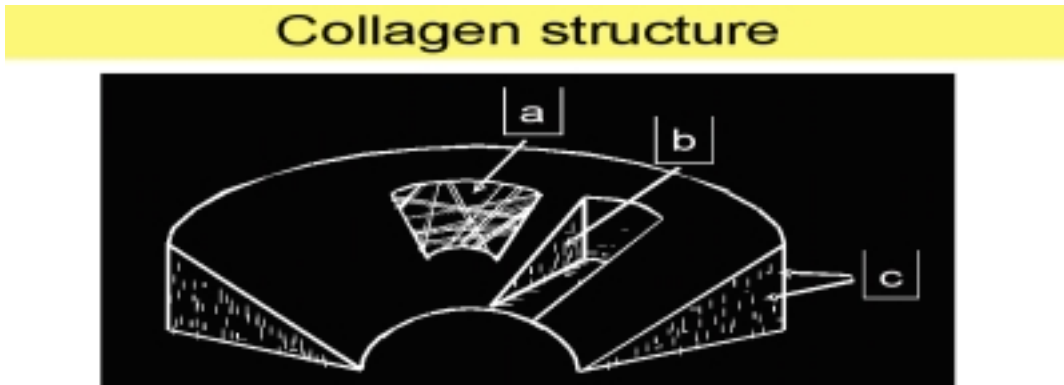


Fig. 1: Structure of the meniscus

- a. fine fibrils, random mesh-like woven matrix
- b. rope-like collagen fibre bundles principally arranged circumferentially
- c. smaller radial fibres – reinforcement

Meniscus tissue composition:

75% water

20% collagen (type I – 90%, II, III, V, VI)

3% proteoglycans, non collagenous proteins, lipids

2% cells (fibrochondrocytes, fibroblasts, mast cells, myofibroblasts)

From *Knee Anatomy for Orthopaedic Surgeons ESSKA 2000*

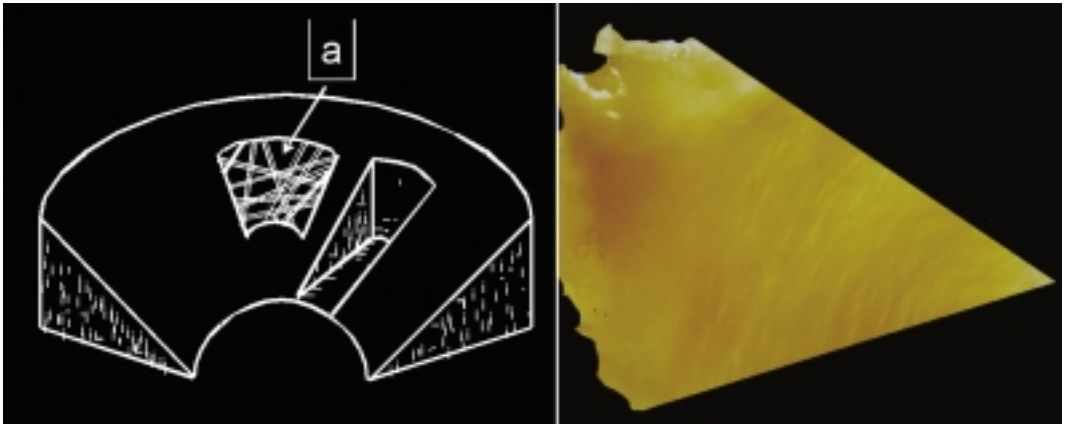


Fig. 2: Cross-section of the meniscus  
 a. fine fibrils, random mesh-like woven matrix

From *Knee Anatomy for Orthopaedic Surgeons ESSKA 2000*




Fig. 3: Cross-section of the meniscus  
 b. rope-like collagen fibre bundles principally arranged circumferentially  
 c. smaller radial fibres – reinforce

From *Knee Anatomy for Orthopaedic Surgeons ESSKA 2000*

## 4.2 Meniscal healing and repair

Thomas Annandale (4) was credited with the first surgical repair of a torn meniscus in 1883, but it was not until 1936, when King (20) published his classic experiment on meniscal healing in dogs, that the actual biologic limitations of meniscal healing were set forth. King demonstrated that for meniscal lesions to heal, they must communicate with the peripheral blood supply (20).

Although this vascular supply appears to be an essential element in determining the potential for meniscal repair, of equal importance is the ability of this blood supply to support the inflammatory response characteristic of wound repair (5,6). Clinical and experimental observations have demonstrated that the peripheral meniscal blood supply is capable of producing a reparative response similar to that observed in other connective tissues (5,6,29,31).

Following injury within the peripheral vascular zone, a fibrin clot forms that is rich in inflammatory cells. Vessels from the perimeniscal capillary plexus proliferate through this fibrin scaffold, accompanied by the proliferation of undifferentiated mesenchymal cells.

Eventually the lesion is filled with a cellular fibrovascular scar tissue that glues the wound edges together and appears continuous with the adjacent normal meniscus fibrocartilage.

Vessels from the perimeniscal capillary plexus, as well as a proliferative vascular pannus from the synovial fringe, penetrate the fibrous scar to provide a marked inflammatory (healing) response (5,6,9,29,31).

Experimental studies have shown that radial lesions of the meniscus extending to the synovium are completely healed, with fibrovascular scar tissue, by 10 weeks (5,6,24,30).

Modulation of this scar tissue into normal-appearing fibrocartilage, however, requires several months (5,6,8,29,31). It should be stressed that the initial strength of this repair tissue, compared with normal meniscus, is minimal. Further study is required to delineate the biomechanical properties of this repair tissue. The ability of meniscal lesions to heal has provided the rationale for the repair of certain meniscal injuries, and several reports have demonstrated excellent results following primary repair of peripheral meniscal lesions (12,13,14,16,17,24,26,27).

Postoperative examination of these peripheral lesions revealed a repair process similar to that noted in the animal models (31).

When damaged menisci are examined for potential repair, lesions are often classified by the location of the tear relative to the blood supply of the meniscus and the vascular appearance of the peripheral and central surfaces of the tear (5,6,26). The red-red tear (peripheral capsular detachment) has a functional blood supply on the capsular and meniscal side of the lesion and, thus, has the best potential for healing. The red-white tear (meniscal rim tear through the peripheral vascular zone) has an active peripheral blood supply, whereas the central (inner) surface of the lesion is devoid of functioning (perfused) vessels (5,26,28,29). Theoretically, these lesions should have sufficient vascularity to heal by the aforementioned fibrovascular proliferation.

White-white tears (meniscal lesion completely in the avascular zone) are without blood supply on either side of the lesion and theoretically cannot heal (1,2,5,31)(Fig.4).

Although meniscal repair has been limited to the peripheral vascular area of the meniscus (red-red and red-white tears), a significant number of meniscal lesions occur in the avascular portion of the meniscus (white-white tears). Experimental and clinical observations have shown that these lesions are incapable of healing and have thereby provided the rationale for partial meniscectomy. Experimental evidence has demonstrated, however, that if lesions in the avascular portion of the meniscus are connected to the peripheral vasculature by vascular access channels or scarification of the synovial fringe, these lesions are capable of healing through a process of fibrovascular scar proliferation similar to that described previously (5,6,26).

Although the vascular anatomy of the meniscus does not appear to change appreciably with age, the ability of peripheral meniscus lesions to heal in individuals over 40 years old is debatable (12,13,14,21,24,25).

This may suggest that although a blood supply is present, the character of the meniscal tissue in these individuals may not be optimal for repair. Indeed, investigations have shown the presence of degenerative changes in a high percentage of grossly normal medial menisci from individuals less than 55 years of age (18,25). Additional clinical evaluations are necessary before the limitation of age on meniscus repair can be determined (18,25,27).

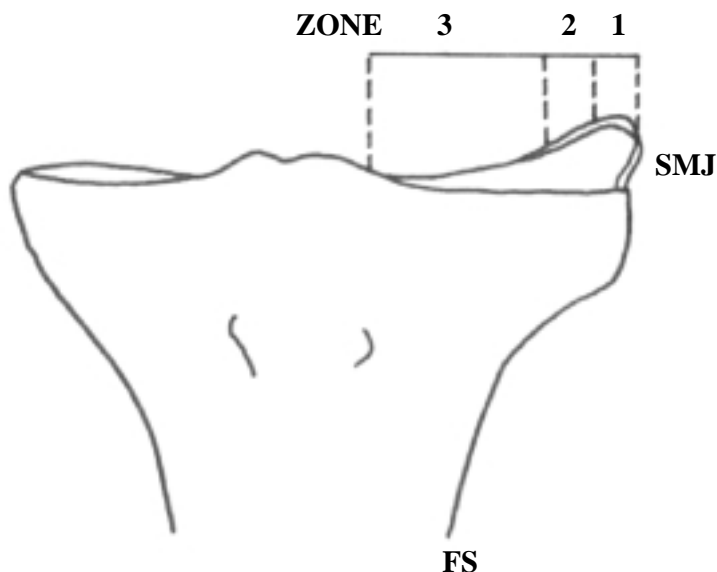


Fig. 4 Description of different zones in the meniscus

Zone 1 : red-red zone

Zone 2 : red-white zone

Zone 3 : white-white zone

SMJ : Synoviomeniscal junction

### 4.3 Meniscal remodelling

Research has shown that the meniscus is capable of repair within the scope of its vascularity, but little is known about the response of the meniscus to partial meniscectomy (within the avascular zone)(5,6,18,23,25,26,31). Although previous clinical and experimental impressions suggest that the meniscus is incapable of any reparative response within the avascular zone, arthroscopic observations of menisci following partial meniscectomy have revealed remodelling of some of the meniscectomy surfaces (10,25,26). Whether this remodelling process occurs in all cases and represents an intrinsic response of the meniscus, some type of extrameniscal accretion, or merely an attritional wearing away of the meniscus was unclear (10,26). However, an experimental study has shown that following partial meniscectomy (limited to the avascular zone), the meniscus may remodel through the

organization and maturation of a fibrin clot that adheres to the cut edge of the meniscus (6,13,29,31). This clot presumably arises from postoperative hemarthrosis, is populated with cells from the synovium and adjacent meniscus and eventually differentiates into a fibrocartilage-like tissue.

Thus, this remodelling represents an accretion of new tissue rather than an intrinsic regeneration. However, the mechanical (functional) character of this new tissue has not been determined (13,25,29,31).

If hemarthrosis is not present or insufficient to form a fibrin clot, the edge of the meniscus remains essentially unchanged. It is important to note that partial meniscectomy does not appear to predispose the remaining meniscus to further degeneration, although its effect on articular cartilage is variable (31).

#### **4.4 Meniscal repair using a fibrin clot**

Based on these observations of the ability of a fibrin clot to act as a scaffold and stimulus for fibrocartilaginous tissue formation in the avascular portion of the meniscus, the use of a fibrin clot in the repair of avascular meniscal lesions has been proposed. In an experimental study, stable meniscal lesions in the avascular portion of canine medial menisci filled with a fibrin clot healed with the formation of dense connective tissue that modulated into fibrocartilaginous connective tissue by 6 months (6). Although this avascular repair tissue was morphologically different from normal meniscal tissue at 6 months, it was similar to the meniscal repair tissue seen following injury in the vascular portion of the meniscus.

Defects not filled with a fibrin clot showed no evidence of repair.

In addition to providing a scaffold for the repair process, the clot contains chemotactic and mitogenic factors that stimulate the migration and proliferation of reparative cells. Although the exact origin of these cells is unclear, they are thought to be from the adjacent meniscal tissue and synovium. Tissue culture studies have shown that meniscal cells are capable of proliferation and matrix synthesis when exposed to factors normally present in a fibrin clot.

Long-term biochemical and biomechanical evaluation of this reparative tissue is needed before its true implication in the avascular repair of meniscal tissue can be realized, and the results of the experimental studies to date may warrant a rethinking of our traditional concepts of meniscal repair (6,29).

#### **4.5 Meniscal regeneration**

Controversy exists within the orthopaedic literature regarding the ability of a meniscus or meniscuslike tissue to regenerate following meniscectomy. This dichotomy may have resulted from confusion as to the extent of meniscectomy, partial versus total, or the fact that much of the data regarding meniscal regeneration have been limited to investigations in animals.

Experiments in rabbits and dogs have demonstrated that following total meniscectomy there is regrowth of a structure similar in shape and texture to the removed meniscus. It is thought that following removal of the meniscus, fibrocytes from the synovium and joint capsule migrate into the joint and are transformed into undifferentiated fibroblasts, which, in turn, form a loose, fibrous connective tissue (1,2,6). In time, joint motion and the resultant hydrostatic pressure provide the proper environment for the transformation of these fibroblasts into fibrocartilage.

Studies have shown that by 7 months, this tissue has the histologic appearance of fibrocartilage and grossly must be resected to expose the vascular synovial tissue, or, in the case of subtotal menis-



ectomy, the excision must extend into the peripheral vasculature of the meniscus (1,2,6). The importance of the peripheral synovial tissues in meniscal regeneration has been shown in experimental studies in rabbits. In animals in which total meniscectomy was accompanied by synovectomy, there was no evidence of tissue regrowth at 12 weeks. However, total meniscectomy alone was followed by regrowth of a meniscuslike structure in 83% of the animals. Evidence that the fibrous joint capsule may also be instrumental in the regeneration of fibrocartilaginous tissue within the joint space has been demonstrated by the presence of regenerated fibrocartilaginous rims in patients following total knee arthroplasty. Although these regenerated tissues did not grossly resemble normal menisci, histologic examination revealed a fibrocartilaginous tissue consisting of chondrocytes in a dense connective tissue matrix (6,29).

## **4.6 Arthroscopic meniscal repair**

The three basic types of repair are inside-out, outside-in and all-inside (13). The inside-out technique can be further subdivided into double-barrel cannula and single-needle passage techniques (12,13). Since collagen bundles are oriented predominantly circumferentially on the periphery of the meniscus, there is an advantage in being able to direct the individual throws of the mattress suture in superior and inferior directions so that the suture is oriented vertically on the periphery, thus securing more meniscal tissue for better fixation (3,7,13). A double barrel system may be more prone to suture pull-out, or it may not provide adequate meniscal coaptation unless it is used like a single-barrel system by rotating it between needle throws to create vertically oriented sutures (13). Common to all meniscal repair techniques should be adequate preparation of the tear site and perimeniscal synovium. Such preparation is best carried out using 2- and 3-mm rasps. A small, powered shaver may also be used (13).

### **4.6.1 Medial meniscal repair**

A tourniquet is placed around the proximal thigh. A well-padded leg holder is placed distal to the tourniquet, and if meniscal repair is planned, the thigh should be elevated approximately 45° in the leg holder to provide access to the posteromedial corner of the knee. It is important to pad the leg holder well and place it on the thigh distal to the tourniquet to prevent any pressure posteriorly on the sciatic nerve. Elevation of the thigh may not be necessary if the surgeon prefers to sit and flex the end of the table, but the thigh must extend far enough beyond the edge of the table break for access to the posterior corners of the knee. The leg may be kept in this position without redraping it if ACL reconstruction is to be carried out after meniscal repair (12,13,28).

After diagnostic arthroscopy has established the need to repair the medial meniscus, a 6-cm longitudinal incision is made just posterior to the posterior border of the medial collateral ligament. The incision should be done with the knee flexed so that the pes anserinus and the sartorial branch of the saphenous nerve will lie posterior to the joint line, but care must be taken throughout the procedure to avoid excessive retraction or entrapping the nerve with sutures (12,13,22).

Dissection is carried down to the posterior capsule, deep to the semimembranosus, and half-way across the medial head of the gastrocnemius. If the direct head of the semimembranosus is too tight, it may be necessary to release several millimetres of its attachment. If suturing of the midcentral portion of the meniscus is contemplated, subcutaneous tissue should be dissected off the medial collateral ligament anterior to the posteromedial incision. A popliteal retractor is then inserted behind the posterior capsule. From the anterolateral portal, the arthroscope is run medial to the posterior cruciate ligament to inspect the posteromedial compartment of the joint (12,13,22).

Both sides of the tear should be freshened, especially if the tear is older than 8 weeks.

The inferior surface of a posterior horn tear and the superior and inferior surfaces of a midcentral tear are best rasped with a burr-type rasp or edge-cutting rasp introduced anteromedially. It is important to devote time to adequate abrasion of the synovium under the inferior portion of the meniscus (12,13,18,22).

Suturing is carried out using 2-0 nonabsorbable Ethibond suture with double-armed tapered needles (22). A 10° to 15° bend is made every 4 mm from the needle tip, and a second 10° to 15° bend is made approximately 10 mm from the first bend in the same direction. The needle is then press fit loaded into the needle holder. Suture placement for the posterior horn of the medial meniscus is carried out from the anteromedial portal. A short cannula is placed through the anteromedial portal close to the medial edge of the patellar tendon. Suturing is begun close to the posterior horn origin of the tear, and the first suture preferably should be placed on the inferior surface of the meniscus. Once the needle has been inserted approximately 3 to 4 mm from the tear site and up to the second bend in the needle, a third bend should be created in the needle by pushing the cannula and needleholder into the intercondylar notch. The extra bend in the needle will allow easier needle retrieval from the posteromedial incision. The first suture throw should be directed from the inferior surface upward through the meniscus so as to include as much meniscal tissue in a vertical orientation as possible. The surgeon may then carefully palpate the posterior capsule to determine whether the exit site of the needle will allow it to be contained by the popliteal retractor.

Once this determination has been made, the needle may be advanced and grasped posteriorly with the needle holder. The needle should never be advanced while palpating posteriorly.

After release of the needle anteriorly, it is pulled out through the posteromedial incision. The second throw of the first suture penetrates beyond the tear site near the meniscosynovial junction, thus creating a vertically oriented suture. In an alternate suturing technique, the second throw of the suture is made approximately 3 to 4 mm from the first throw, thus creating a horizontal mattress suture (Fig 5,6).

The needles should be passed in divergent directions so as to include as much meniscal tissue in a vertical orientation as possible.

Starting at the posterior horn origin, suture placement is alternated between the superior and inferior surfaces of the meniscus, spaced approximately 3 mm apart.

If the tear extends into the middle third of the medial meniscus, the arthroscope should be switched to the anteromedial portal, and suturing should be carried out through the anterolateral portal. Sutures placed on the superior surface of the meniscus should have less the suture loop exposed compared with those on the inferior surface. An attempt should be made to direct these sutures to the posteromedial incision site. The most anterior sutures may be directed out through a 1-cm incision placed between the posteromedial and the anteromedial incisions.

Sutures placed in this fashion will avoid shear forces that may result from sutures directed obliquely out through the posteromedial incision (3,8,15). If difficulty is encountered in adequately visualizing or directing sutures through the posterior horn fragment, a probe inserted through an accessory anteromedial portal may be used to bring the meniscal fragment anterior, or to tilt it so that the suture placement can be optimized. Displaced bucket-handle tears also can be successfully repaired. If ACL reconstruction is to be performed, the sutures are not tied until the end of the reconstruction (13,23). The sutures can be kept tight in the meantime by threading them through 7-cm pieces of intravenous extension tubing and crossclamping the tubing. All isolated meniscal repairs should have fibrin clot introduced into the tear site before tying the sutures.

Approximately 50 to 75 ml of venous blood is placed in a plastic container on the operative field, and the blood is stirred with one or two 10- or 20-mm glass syringe barrels for approximately 5 to

10 minutes until the clot adheres to the glass barrels. The clot is then removed and blotted with moistened gauze. A suture (2-0 Ethibond) is placed and secured at each end of the tabulated clot. After introduction of a 6- to 7-mm cannula, the two free needles are bent in the same manner as for meniscal repair and loaded into the Henning needle holders. They are passed through the cannula and under the inferior surface of the meniscus through the meniscosynovial junction at the most posterior and anterior poles of the tear. They are retrieved posteriorly. After the clot has been tucked into the tear site, all sutures are tied. The single strands of the clot sutures are tied to adjacent meniscal repair sutures. Alternative methods of clot introduction include the use of a commercially available clot introducer, or the clot can be introduced through a 6-mm cannula with a blunt obturator or a glass syringe with a blunt 13-gauge curved needle. The tear site is then pulled open with a probe, and with the joint evacuated of fluid so that the clot does not float away, the clot is placed under the inferior surface of the meniscus throughout the length of the tear. The sutures are pulled tight, trapping the fibrin clot, and tied.

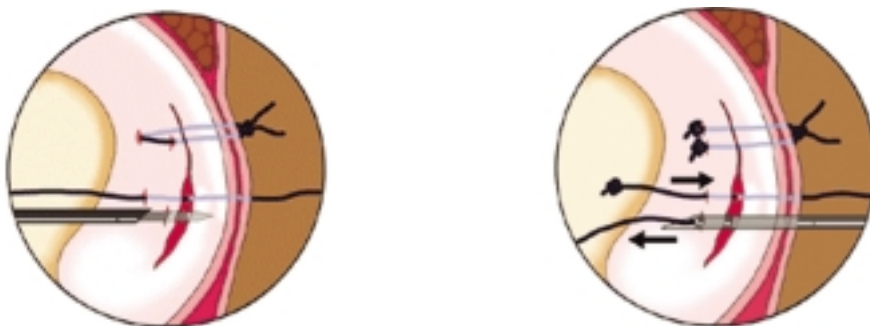


Fig. 5: Technique of inside-out & outside-in suture: the first suture throw should be directed from the inferior surface upward through the meniscus as to include as much meniscal tissue in a vertical orientation as possible

From *Knee Anatomy for Orthopaedic Surgeons ESSKA 2000*

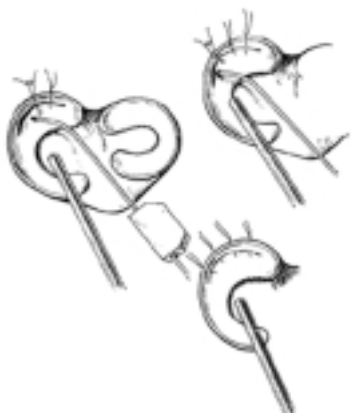

Fig. 6: Technique of inside-out suture : starting at the posterior horn origin, suture placement is alternated between the superior and inferior surfaces of the meniscus, spaced approximately 3 mm apart

From *Knee Anatomy for Orthopaedic Surgeons ESSKA 2000*

#### **4.6.2 Lateral meniscus repair**

The technique of lateral meniscal repair is similar to that of the medial meniscus. A 6-cm vertical incision is made at the posterolateral corner of the knee. A longitudinal incision is made in the deep fascia along the posterior margin of the iliotibial band, and the biceps is retracted posteriorly with the knee flexed 90°. The lateral head of the gastrocnemius is dissected off the posterior capsule to a point where a nerve hook passed from the anteromedial portal over the top of the posterior horn origin of the lateral meniscus can be palpated through the posterolateral incision.

With the knee flexed 90°, the peroneal nerve will lie posterior to the biceps except in the proximal portion of the incision, where it crosses over behind the biceps to lie closer to the posterior surface of the lateral head of the gastrocnemius. The peroneal nerve does not have to be dissected out and identified. Abrasion of both tear surfaces is carried out as described for the medial side. Suture placement is done exclusively from the anteromedial portal. There should not be too much concern if a suture passes through the popliteus tendon, although, preferably, this should be avoided. Radial split tears of the posterior horn can be approximated by passing one suture through the posterior leaf close to the inner margin of the meniscus and the second suture through the anterior leaf of this tear. Since adequate healing has been difficult to radial split tears in the middle third of the lateral meniscus, they are probably best left alone (13).

#### **4.6.3 All-inside technique using the Biofix resorbable arrows**

The Biofix implant provides a horizontal fixation and has been designed to create optimal fixation of the meniscus (1,2,3,15,19). A specially designed instrument set allows repair through standard arthroscopy portals, and consists of six cannulas with various curves, an obturator, a needle, perforator, pusher, and hammer. After the rupture has been freshened and reduced, the chosen cannula with the blunt obturator inside is inserted through the portals. After withdrawal of the obturator the cannula is fixed at 3-4 mm from the lesion, and the meniscus is kept reduced. With a special perforator, a hole for the arrow is made through the meniscus into the joint capsule (Fig 7,8,9).

The irrigation is turned off, and the perforator is retracted. A tack is pushed into the cannula with the pusher and hammered into the meniscus. A special reciprocating instrument can be used for this procedure. Every 5-10 mm a new tack is inserted until the rupture is stable. The implants have a diameter of 1.1 mm and are available in three lengths (10, 13 and 16 mm) for different localizations of the meniscal lesion (1,2,3,15,19).

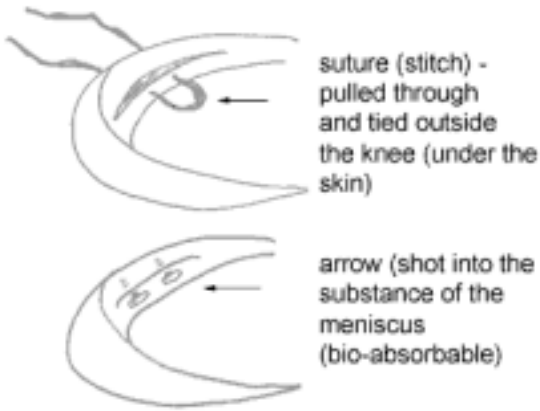


Fig. 7 : Inside-out versus all-inside suture technique

From *Knee Anatomy for Orthopaedic Surgeons ESSKA 2000*

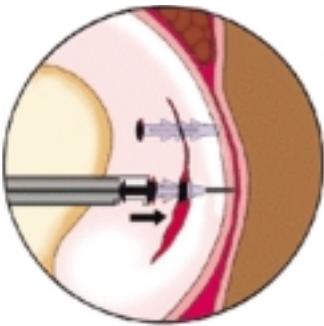


Fig. 8 : Pushing through of the arrows: a tack is pushed into the cannula with the pusher and hammered into the meniscus

From *Knee Anatomy for Orthopaedic Surgeons ESSKA 2000*

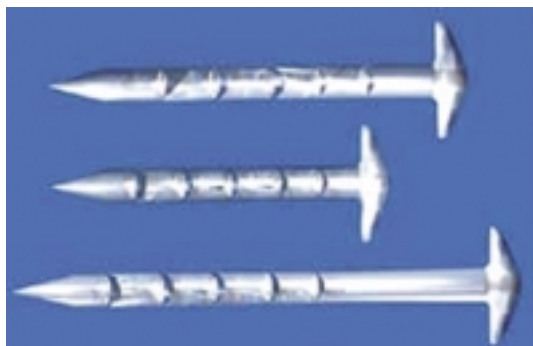


Fig. 9 : Bioresorbable meniscus arrows

From *Knee Anatomy for Orthopaedic Surgeons ESSKA 2000*

#### 4.7 Rehabilitation

If ACL reconstruction has been done along with meniscal repair, early motion is emphasized to prevent an unacceptable incidence of stiffness and flexion contractures (1,2,3,12,13,19,28).

In the case of isolated meniscal repairs, partial weight bearing is initiated after 3 weeks. Full-weight bearing is begun from 3 to 6 weeks. Stationary bicycle riding is begun. Straight ahead running can be started at 5 months and light sports at 6 months. Contact sports, such as football and basketball, are discouraged before 9 months after treatment (13).

#### References

1. Albrecht-Olsen P, Kristensen G, Burgaard P, Joergensen U, Toerholm C. The arrow versus horizontal suture in arthroscopic meniscus repair. A prospective randomized study with arthroscopic evaluation. *Knee Surg Sports Traumatol Arthrosc* 1999; 7 : 268-273.
2. Albrecht-Olsen P, Kristensen G, Törmälä P. Meniscus bucket-handle fixation with an absorbable Biofix tack: development of a new technique. *Knee Surg Sports Traumatol Arthrosc* 1993; 1: 104-106.
3. Albrecht-Olsen P, Lind T, Kristensen G, Falkenberg B. Failure strength of a new meniscus arrow repair technique: biomechanical comparison with horizontal suture. *Arthroscopy* 1997; 2: 183-187.
4. Annandale T. An operation for displaced semilunar cartilage. *Br Med J* 1885; 1:799
5. Arnoczky SP, Warren RF. The microvasculature of the human meniscus. *Am J Sports Med* 1982;10:90-95.
6. Arnoczky SP, Warren RF. The microvasculature of the meniscus and its response to injury: An experimental study in the dog. *Am J Sports Med* 1983;11:131-141.
7. Asik M, Sener N. Failure strength of repair devices versus meniscus suturing techniques. *Knee Surg Sports Traumatol Arthrosc* 2002; 10: 25-29.
8. Borden P, Nyland J, Caborn DN, Pienkowski D. Biomechanical comparison of the FasT-Fix Meniscal repair suture system with vertical mattress sutures and meniscus arrows *Am J Sports Med* 2003; 31: 374-378.

9. Bos RRM, Boering G, Rozema FR, Leenslag JW. Resorbable poly (L-lactide) plates and screws for the fixation of zygomatic fractures. *J Oral Maxillofac Surg* 1987; 45: 751-753.
10. Bronstein R, Kirk P, Hurley J. The usefulness of MRI in evaluating menisci after repair. *Orthopedics* 1992; 15:149-152.
12. Cannon WD, Morgan CD. Meniscal repair. *J Bone Joint Surg Am* 1994; 76: 294-311.
13. DeHaven KE. Meniscus repair: current concepts. *Am J Sports Med* 1999; 27: 242-250
14. DeHaven KE, Lohrer WA, Lovelock JE. Long-term results of open meniscus repair. *Am J Sports Med* 1995; 23 : 524-530.
15. Dervin GF, Downing BE, Kenée CR, McBride DG. Failure strengths of suture versus biodegradable arrow for meniscus repair: an in vitro study. *Arthroscopy* 1997;13: 296-300.
16. Egli S, Wegmüller H, Kosina J. Long-term results of arthroscopic meniscal repair: an analysis of isolated tears. *Am J Sports Med* 1995; 23 : 715-720.
17. Hantes M, Zachos VC, Vartimidis SE. Arthroscopic meniscal repair : a comparative study between three different surgical techniques. *Knee Surg Sports Traumatol Arthrosc* 2006; 14:1232-137.
18. Jäger A, Starker M, Herresthal J. Can meniscus refixation prevent early development of arthrosis in the knee joint? Long-term results. *Zentralbl Chir* 2000; 125(6): 532-535.
19. Hürel C, Mertens F, Verdonk R. Biofix resorbable meniscus arrow for meniscal ruptures; results of a 1-year follow-up. *Knee Surg Sports Traumatol Arthrosc* 2000; 8 : 46-52.
20. King D. The healing of the semilunar cartilages. *J Bone Joint Surg* 1936;18:333-342.
21. Majewski M, Stoll R, Widmer H, Müller W, Friedrich NF. Midterm and long-term results after arthroscopic suture repair of isolated, longitudinal, vertical meniscal tears in stable knees. *Am J Sports Med* 2006 Jul; 34(7): 1072-1076.
22. McGinty JB, Cannon WD. Arthroscopic meniscal repair . In McGinty JB, Caspari RB, Jackson RW eds. *Operative arthroscopy*. New-York, Lipincot –Raven 1996; 299-316.
23. Meunier A, Odensten M, Good L. Long-term results after primary repair or non-surgical treatment of anterior cruciate ligament rupture: a randomized study with a 15-year follow-up. *Scand J Med Sci Sports* 2007 Jun; 17(3): 320-327.
24. Noyes FR, Barber-Westin SD. Arthroscopic repair of meniscal tears extending into the avascular zone in patients younger than twenty years of age. *Am J Sports Med* 2002; 30: 589-600.
25. Roos H, Adalbrecht T, Dahlberg L, Lohmander LS. Osteoarthritis of the knee after injury to the anterior cruciate ligament or meniscus: the influence of time and age. *Osteoarthritis Cartilage* 1995; 3:261-267.
26. Rubman MR, Noyes FR, Barber-Westin SD. Arthroscopic repair of meniscal tearsthat extend into the avascular zone : a review of 198 single and complex tears. *Am J Sports Med* 1998; 26 : 87-95.
27. Siebold R, Dehler C, Boes L, Ellermann A. Arthroscopic all-inside repair using the Meniscus Arrow: long-term clinical follow-up of 113 patients. *Arthroscopy* 2007 Apr;23(4): 394-399.
28. Stone RG, Frewin PR, Gonzales S. Long-term assessment of arthroscopic meniscus repair: a two- to six-year follow-up study. *Arthroscopy* 1990; 6: 73-78.
29. Verdonk P. The human meniscus: transplatation, characterisation and tissue engineering. Doctoral thesis 2006.
30. Verdonk R, Meire D, Van De Velde C, Van Eetvelde G, Claessens H. CT scan of the knee : correlation with clinical and arthroscopic findings. *Acta Orthop Belg* 1991; 57 : 49-55.
31. Yasunaga T, Kimura M, Kikuchi S. Histologic change of the meniscus and cartilage tissue after meniscal suture. *Clin Orthop* 2001; 387 : 232-240.





CHAPTER V

ANTERIOR CRUCIATE LIGAMENT INJURY  
AND RECONSTRUCTION

# CHAPTER V: ANTERIOR CRUCIATE LIGAMENT INJURY AND RECONSTRUCTION

## 5.1 Who should have surgery?

In theory, our discussion on patient selection would be most meaningful if it were possible to select as surgical candidates the "at risk" group that will suffer objectively and subjectively from cruciate ligament insufficiency, and thus withhold surgery and its potential complications from individuals that will have normal knee function even without an ACL (3,11,12,16,24,29,35,38,43,45,46).

In this more philosophical than scientific debate (apparently there are no strictly scientific criteria to be applied), we must base our judgment on signs suggesting that one type of progression is more likely to occur than another in a given case (24,35,46).

Arguments that favour surgery are: youthful age of the patient, heavy manual labour or strenuous sports activity, high demands in terms of joint performance, inability or refusal to modify activities, preexisting meniscal and cartilage lesions, frequent instability with activities of normal living, recurrent swelling, feeling of instability 6 months after intensive rehabilitation, and previous identical lesion in the opposite knee with the same outcome (2,24,34,35,39,40,48). Conservative treatment is favoured in patients over 45 years of age and in less active patients with a sedentary job (24). If both patient and physician are reluctant to proceed with surgery, little will be lost by watching and waiting for a possible intercurrent meniscal tear and the need for a meniscal repair and joint stabilization (1,3,16,24,37,38,41,42,46).

## 5.2 When should surgery be done?

Timing is a more important concern for meniscal repair, which we believe is more rewarding when done acutely than in the chronic stage (3,5,8,37,38,42). Thus, in cases where a non-operative approach is agreed upon in the initial consultation, early arthroscopy should be performed to exclude a meniscal detachment (1,16,41). Positive cases are an indication for a meniscal repair, which in turn would necessitate a cruciate ligament repair since residual instability would reduce the prospect for successful healing and salvage of the meniscus (1,7,16,41,48).

In the acute stage when the articular cartilage is still intact, the result of the ACL and meniscal repairs in term of joint function and stability is better than in the chronic stage, although acute cases more often require manipulation under anesthesia and more arthroscopies to separate adhesions than chronic cases (1,6,9,10,11,29,39,40,43).

This has fostered a trend to postpone surgery for an acute cruciate tear combined with a medial collateral ligament rupture by 4-6 weeks to give the patient a chance to recover articular motion (15,46,47).

This is believed to lower the incidence of adhesions and reduce the need for manipulation (9).

The patient who still feels unstable after a conservative trial and is unhappy with restrictions on his athletic activities will generally request surgery (24). The instability is most likely to be manifested during sports activities that involve deceleration, acceleration, and cutting. The decision belongs to the patient, who, in the face of chronic symptoms, is asked to rate subjectively the quality of the non-surgical result. He must decide for himself whether he can accept activity restriction that avoid pivot-shift episodes or whether he would like to engage more actively in sports or the general activities of daily living. If the patient complains that his functional disability is interfering with his desired life style and he remains symptomatic after an individualized rehabilitation program, we recommend surgical treatment. An overly rigorous muscular strengthening program can create an

unchecked potentially harmful quadriceps muscle action that increases the risk of meniscal and cartilage damage (14,34,46,47,48). In this sense a rupture of the ACL is an indication for operative treatment in the short or long term. In the sceptical patient, it can be helpful to postpone surgery for 2-3 years until the patient himself becomes convinced of its necessity (24).

### **5.3 What should be operated on?**

In addressing this question, we must take into account all the structures that contribute to the essential stability of the joint: the ACL itself, the menisci, and the peripheral restraints (14,22,23,30,46,47,48,51,52).

There is no question about the need to preserve the meniscal tissue, which forms a stabilizing wedge interposed between the femoral condyle and tibial plateau (1,3,5,16,17,25,26,41).

The preservation of this fibrous ring system also maintains a critical link with the peripheral restraints. A concomitant rupture of the collateral ligament and capsule is less important in the acute stage if the ACL is stabilized to a degree that permits postoperative functional therapy of the joint (15,46,47,48). Several studies have proven the superiority of postoperative exercises over cast immobilization for tears of the medial collateral ligament (15,34,48,49).

If there is a coexisting meniscal tear ("unhappy triad" pattern), the tear is repaired but the torn collateral ligament is left alone (3,5,15,37,38,39,40,41).

With a lateral-posterolateral lesion, the meticulous repair of all structures is advocated. In the advanced stage of chronic global anterior instability with pronounced anteromedial and anterolateral displacement of the tibial plateau, it must be asked whether surgery should be limited to the central pivot (i.e. the cruciate ligaments) or whether the periphery should also be repaired (3,5,15,22,23).

It is unlikely, of course, that reconstruction of the central pivot alone, an extra-articular repair, or their combination offers the most appropriate or technical optimum solution.

Basic scientific principles and rational criteria still need to be worked out, and greater attention must be given to these aspects in future studies (3,5,14,18,46,47,48,50,51).

### **5.4 How should the operation be done?**

Probably the key issue here is what provides for adequate stabilization in a structural sense following an ACL reconstruction: is it the graft, is it the augmentation, or is it the overall mass of scar fibers that occupy the intercondylar notch (1,2,3,5,21,30,44,46,47,48)?

It is common during follow-up arthroscopy at about 1 year to find a scar that starts far anterosuperiorly, where the synovial plica normally attaches (not the expected gleaming cruciate ligament with its constituent bundles)(1,2,3,5,9). At a deeper level the graft itself may indeed be attached at the anatomically correct "isometric" site corresponding to the surgeon's intention, but the functionally important scar fibers add new meaning to the traditional concept of isometry (9,30,46,47,48,50).

Despite this sobering insight, it is reasonable to assume that a strong, accurately placed graft offers the best prospect for the development of a sound substitute ligament (3,5,14,30,44,46,47,48).

Bathed by synovial fluid, the graft becomes revascularized at a variable rate. A graft attached by bone blocks inserted into osseous tunnels revascularizes in 6-10 months, which apparently is more rapid than the synovialization and revascularization of a graft that has been sutured directly to the bone (46,47,48).

### **5.4.1 Operative technique (current technique – bone-patellar-bone graft)**

Systematic arthroscopic examination of the knee allows careful inspection and documentation of the status of all intrarticular structures. A high-flow superomedial inflow cannula is established, followed by placement of the arthroscope through a standard inferolateral portal.

Both inferomedial and inferolateral portals may be placed within the margins of the existing skin incision (13,28). The articular surfaces, patellar tracking, and both menisci should be visualized, probed when necessary, and documented in the knee record. The ACL and PCL are inspected and probed both at resting length and under tension. Associated injuries amenable to arthroscopic treatment are treated before addressing the ligamentous reconstruction (1,28). Repairs of amenable meniscal tears are undertaken. Visualization of the tear and intrarticular suture placement are easier while the knee is unstable and before notchplasty and osseous tunnel drilling cause significant intraarticular bleeding. Likewise, damage to the articular cartilage is documented and treated as deemed most appropriate (3,13,28,30,44).

### **5.4.2 Preparation of the intercondylar notch**

The stump of the ACL is debrided with a full-radius shaver. The ligamentum mucosum is also debrided for enhanced visualization. The fat pad and synovium overlying the PCL are protected. The notchplasty begins with debridement of the soft tissue and periosteum from the lateral wall of the notch. The entire surface of the lateral wall is uniformly debrided. Some bleeding may be encountered at this point and may be controlled with electrocautery, or inflation of the tourniquet, or both. Sufficient hydrostatic pressure via gravity inflow irrigation or infusion pump seems to minimize undesired intraarticular bleeding. Once the notch is visualized, the surgeon can identify the extent of bony notchplasty that might be thought necessary. There is no consensus as to what constitutes an indication for notchplasty (9,28,30,51,52).

A notchplasty is indicated where there is difficulty visualizing the femoral attachment and when graft impingement will occur against either the lateral femoral condyle or the roof of the notch. A bony notchplasty is more frequently needed in the chronic ACL-deficient knee (8,9,11,27,28,31,33). This is secondary to osteophyte formation and notch encroachment and most evident at the articular margin of the anterior notch. If the notch requires significant widening, a curved osteotome may be introduced through the medial portal to remove the anterior-inferior bone. The large bone fragments should be removed with a grasper. Minimal articular cartilage removal is desirable. Additional bony resection can often be carried out with the full-radius shaver or burr. Regardless of the technique used, one must not be fooled into misinterpreting the so-called resident's ridge for the posterior margins of the notch. This slightly more stenotic region of the intercondylar notch often deceives the less experienced surgeon into believing the over-the-top position has been reached. This error in landmark selection may cause the femoral tunnel to be placed more anterior than desired (4,13,30,32).

### **5.4.3 Selection and preparation of osseous tunnels**

The selection of ideal osseous tunnels

The relationship of the intercondylar notch to the ACL graft is critical (4,9,30,32,46,47,48,50,51,52).

Proper graft positioning will allow full extension and allow for impingement of the graft to be avoided (4,9,30,32). The selection of ideal osseous tunnel sites is a crucial step in ACL reconstruction. The normal ACL is composed of a large number of fibers. Each fiber has a different length, has a different origin and insertion, and is under different tension during the range of motion of the knee (46,47,48). The graft replacing the ACL will have parallel fibers.

Even with optimal selection of the placement of the osseous tunnels, the fibers of the graft will undergo length and tension changes with range of motion (14,30,46,47,48,50,51,52).

Therefore, the ACL replacement will not duplicate the original ligament (46,47,48,50).

However, placing the center of the osseous tunnels at the most isometric points will maximize the stability obtained (4,30,46,47,48,50,51,52).

#### 5.4.4 Femoral tunnel location

The selection point for the center of the osseous tunnel requires visualization of the over-the-top position and superolateral aspect of the intercondylar notch (3,5,28). Flexing the knee to 70° or more enhances visualization of both these landmarks and aids in preparation of the femoral osseous tunnel. If femoral interference screw fixation is desired, the selection of the femoral tunnel site should be reproducibly result in an osseous tunnel with a 1- to 2-mm thick posterior cortical wall (3,4,5,19,28,30,31). This provides a posterior buttress for interference screw fixation and protects the posterior vessels and nerves (13,19,31). A placement guide keys off the over-the-top position. The surgeon must still choose the rotation of the guide to place the drill guide in the axilla of the notch. The center of the selected femoral tunnel site is then marked with a guidewire. This point is verified visually and with a nerve hook to confirm the correct distance from the over-the-top position (4,28)(Fig. 1).

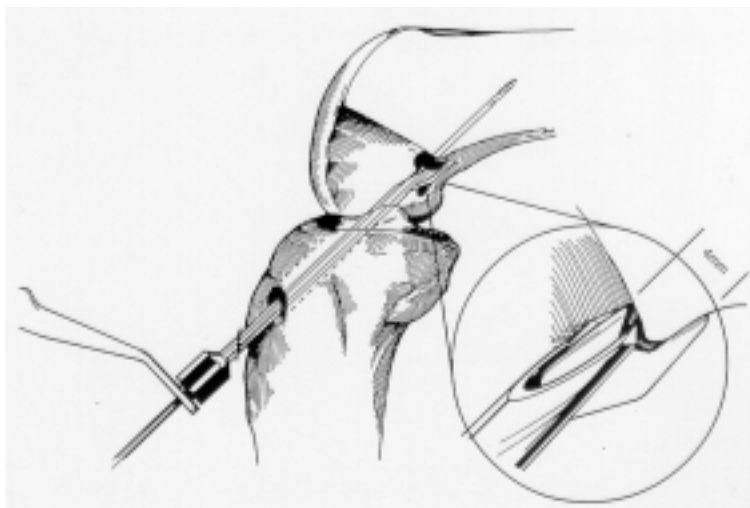


Fig. 1: Placement of femoral aiming guide

From *Knee Anatomy for Orthopaedic Surgeons ESSKA 2000*

### 5.4.5 Tibial tunnel location

Selecting the proper tibial tunnel site is important in obtaining appropriate tunnel length and angulation, which in turn, affects graft fixation and potential impingement and abrasion (4,13,28,32,51,52). The recommended position for graft placement has moved posteriorly as ACL reconstructive surgery has evolved (4,13,30,32,46,47,48). The current recommendation is to locate the center of the tibial tunnel just posterior to the anatomic center of the ACL tibial footprint (4,9,13).

Four consistent anatomic landmarks are used to locate the tibial tunnel center: (a) the anterior horn of the lateral meniscus, (b) the medial tibial spine, (c) the PCL, (d) the ACL stump (4,13,51,52). The anterior-posterior center of the tibial tunnel is closely approximated by extending a line in continuation with the inner edge of the anterior horn of the lateral meniscus. This point is consistently located 6 to 7 mm anterior to the anterior border of the PCL (3,4,5,28,31,52).

The medial-lateral placement of the tunnel center should correspond to the depression medial to the medial tibial spine in the medial-lateral center of the ACL stump. This tunnel placement should allow the ACL graft, once in place, to touch the lateral aspect of the PCL but not be significantly deflected by it (4,13,31,46,47,48,51,52). Similarly, it should neither abrade nor impinge against the medial aspect of the lateral femoral condyle or the roof of the intercondylar notch in extension.

With the tunnel center chosen, the knee is flexed 90°, and the tip of the tibial drill guide is placed into position through the medial infrapatellar portal. The skin incision is retracted medially and distally while the drill sleeve is placed against the tibial cortex, medial to the tubercle. The drill guide length is set to the calculated length, and a guidewire is drilled into place. Visualization of the tip of the guidewire as it enters the joint allows any adjustments in pin location to be made at this time. It is important to realize that the residual ACL stump may deceive the surgeon into believing the guidewire is more posterior than it actually is. Because of the 50° to 60° angle with which the wire penetrates the plateau, the entry point is actually 2 to 3 mm anterior to where the tip is first visualized (4,13,28,31,52). Careful confirmation as the pin enters the joint or removal of an adequate amount of the ACL remnant helps minimize this source of error.

As the drill is advanced, a curette or curved snap may be used to prevent proximal migration of the guidewire, as well as accidental plunging of the drill into the joint. The tibial tunnel is then plugged to preserve joint distention while a shaver is used to remove any debris in the joint and chamfer the tunnel edges. Residual tissue anterior to the graft exit site or roof impingement is believed to contribute to formation of a postoperative Cyclops lesion (9).

Thus, it is important to remove debris from the tunnel edges anteriorly as well as posteriorly.

If the tibial tunnel ends up too anterior, a femoral drill bit or a burr placed through the tibial tunnel can be used to move the entrance posteriorly (4,13,30,31).

With the tibial tunnel drilled and posterior edge chamfered, the femoral tunnel can be prepared. With the knee flexed 70°, the guidewire is placed in the premarked position through the tibial tunnel and advanced only 10 to 15 mm (3,4,5,28). A calibrated cannulated drill is advanced over the wire by hand until it engages the lateral wall of the intercondylar notch. Care should be taken to prevent damage to the PCL while the drill is being advanced.

The power reamer is attached, and the tunnel is reamed to the desired depth.

Next, a pin is advanced through both tunnels with the knee flexed between 90° and 110°.

The pin contains an eyelet that will be threaded with the graft's sutures for passage. It is drilled out the anterolateral thigh under power. To assist the drill's emergence through the skin, the flat edge of a metallic instrument may be placed just proximal to the exit point as the drill tents the skin. A drill puller may then be placed over the tip to stabilize the drill, cover the sharp tip, and pass the sutures

across the joint. Care must be taken to ensure the knee remains flexed to the same degree to prevent bending or breaking the pin (3,4,5,9,28)(Fig. 2).

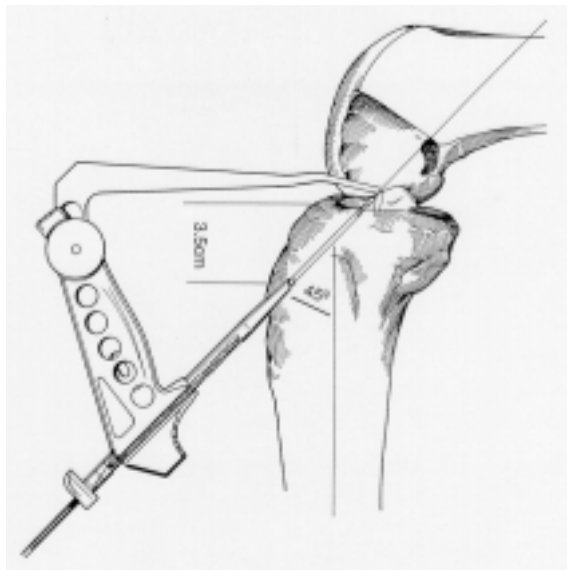


Fig. 2 : Placement of aiming device

From *Knee Anatomy for Orthopaedic Surgeons ESSKA 2000*

#### 5.4.6 Passing the graft

The surgeon threads the patellar bone plug suture through the eyelet of the pin. One assistant must hold the graft and the remaining tibial plug sutures while also preventing the nylon suture from being pulled out of the patellar plug (19,20,21,27,31,36). This is easily done by pinching together both sides of the nylon suture as it emerges from the drill hole in the patellar plug.

The drill puller is pulled proximally until the nylon suture exits the skin over the anterolateral thigh. A haemostat is attached to both free ends of the suture to pull the graft into the tibial tunnel. Under arthroscopic visualization, the graft is passed into the femoral tunnel with cephalad traction on the proximal suture. The cancellous surface is placed anterolaterally so that the collagen fibers of the new ligament are posterior in the femoral tunnel. A haemostat may be placed through the inferomedial portal to help the proximal plug past the PCL and properly orient the graft in the femoral tunnel. The graft is fully seated when the junction of the bone plug and ligament, marked earlier with a pen, is visualized at the tunnel mouth (3,4,5,19,31,33).

The distal plug is rotated 90° externally so that the cancellous bone surface is posterior in the tibial tunnel. However, if the graft should impinge, the tibial bone plug may be rotated, a larger notch-plasty performed, or the tibial tunnel shifted posteriorly (3,4,5,9,31)(Fig. 3).

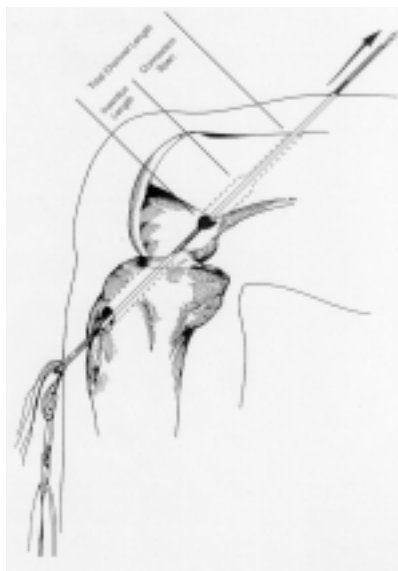

Fig. 3: Pulling through of the tendon

From *Knee Anatomy for Orthopaedic Surgeons ESSKA 2000*

#### 5.4.7 Fixation

Cannulated interference screws have the advantages of providing among the highest initial fixation strength attainable, not requiring additional drilling, not depending on potentially weak sutures or knots, and being able to be placed completely within bone (19,31,33). This reduces the incidence of local irritation due to prominent hardware (19,31,33,39,40) (Fig. 4).

The femoral interference screw is placed first. The guidewire is inserted into the anterolateral notch created earlier in the femoral tunnel. This will position the screw against the cancellous side of the plug, away from the collagen. The guidewire is placed during graft passage and advanced as the femoral plug is seated.

Once the screwdriver and wire have been removed, distal traction of approximately 40 pounds is placed on the three sutures in the tibial bone plug to test the femoral fixation under arthroscopic visualization (19,31,33,46,47,48). Should fixation prove inadequate, another attempt at screw placement may be attempted. If stable fixation cannot be obtained or if the posterior cortex has been violated, proximal fixation may be obtained with additional sutures placed in the bone plug and tied to the lateral femoral screw. This requires a lateral femoral incision and femoral tunnel drilling using a rear entry drill guide. An alternative is to use an endoscopic button, which may be placed arthroscopically over the lateral femoral cortex through a small diameter drill hole (31). This is similar to endoscopic fixation used for hamstring tendon ACL reconstructions (31,33).

The knee is then cycled 5 to 10 times through a full range of motion with the graft under tension (46,47,48). This will confirm the femoral fixation and allows an estimation of the excursion of the tibial bone plug within the tibial tunnel. Although true isometry is not possible with a linear, cylindrical graft, we expect less than 2 mm excursion of the tibial plug (14,46,47,48,50).



More than 2 mm excursion suggests inadequate proximal fixation, injury to the graft, or poor selection of femoral tunnel site (46,47,48,50).

As the length of the graft is greatest during extension, the tibial interference screw is placed with the knee between near extension and 20° of flexion (14,46,47,48,50).

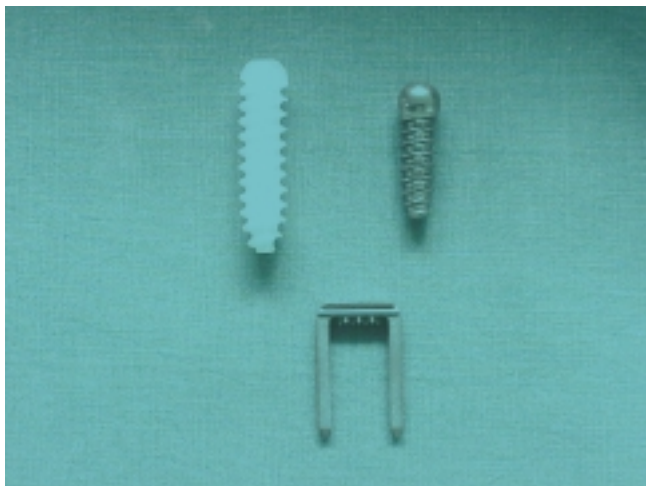

Fig. 4: Tendon fixation devices

From *Knee Anatomy for Orthopaedic Surgeons ESSKA 2000*

### 5.5 Phases of ligament healing

Both autografts and allografts go through a predictable sequence of stages after implantation (20,21,27,33,36,44,46,47,48). After graft placement, a fairly rapid loss of cellularity occurs, which is largely due to unknown factors but may be related to loss of vascularity or innervation or both (20,21,27,33,36,44,46,47,48).

Allograft acellularity, in addition, may be due to an immunologic reaction (20,21,27,44,46,47,48). After a period of cellular necrosis, a repopulation of the graft with cells that are extrinsic, intrinsic, or both occurs. This process is referred to as "ligamentization" (46,47,48). However, such grafts are not normal mechanically and, hence, are not ligamentized in a functional sense (27,46,47,48).

### 5.6 Principles of rehabilitation

Immobilization induces deleterious morphologic and biomechanical changes in intact ligaments (9,24,34,46,47,48,49). Following prolonged immobilization, there is a loss of the parallel organization of the collagen fibers and a decrease in the number and size of the collagen bundles (34,46,47,48). These morphologic changes are manifested by a decrease in the ultimate load, linear stiffness, and energy absorbing capacity of the ligament. The effects can be prolonged, as remobilization seems to only partially restore the material properties of the ligament (34,46,47,48).

Graft tissue has been noted to be mechanically weaker than the native ACL for long periods of time after reconstruction, even with ideal graft placement (9,46,47,48,49). This may be due to inappropriate levels of tension as a result of imprecise surgical technique, surrounding milieu, failure to achieve cellular differentiation, or degeneration of the fibril structures (46,47,48).

Thus, despite current technical advances, surgery cannot fully restore the structural, biochemical, and mechanical properties of the normal ACL. Further research should be conducted to determine the influence of these factors on patient outcome (14,27,33,46,47,48,49).

Progression of the rehabilitation should be based on careful monitoring of the patient's functional status. Early emphasis is placed on achieving full hyperextension equal to the opposite side. Passive and active range of motion is carried out as tolerated (24,34). Full weight bearing is done as soon as tolerated with no limp (unless otherwise indicated). Controlled exercises can be performed without the use of the brace (50). The patient should be well aware that healing and tissue maturation continue to take place for 1 year after surgery (46,47,48).

## References

1. Ahn JH, Wang JH, Yoo JC. Arthroscopic all-inside repair of medial meniscus lesion in anterior cruciate ligament-deficient knees: results of second-look arthroscopies in 39 cases. *Arthroscopy* 2004; Nov (20)9: 936-945.
2. Ait Si Selmi T, Fithian S, Neyret P. The evolution of osteoarthritis in 103 patients with ACL reconstruction at 17 years follow-up. *Knee* 2006; Oct;13(5): 353-358.
3. Arnoczky S, Adams M, DeHaven KE. Meniscus. In Woo SY, Buckwalter JA, eds. *Injury and Repair of the Musculoskeletal Soft Tissues*. Chicago, American Academy of Orthopedic Surgeons, 1987:487.
4. Behrend H, Stutz G, Kessler MA. Tunnel placement in anterior cruciate ligament (ACL) reconstruction: quality control in a teaching hospital. *Knee Surg Sports Traumatol Arthrosc* 2006; Nov 14(11); 1159-1165.
5. Cannon WD, Morgan CD. Meniscal repair. *J Bone Joint Surg (Am)* 1994; 76: 294-311.
6. Cohen M, Amaro JT, Ejnisman B. Anterior cruciate ligament reconstruction after 10 to 15 years: association between meniscectomy and osteoarthritis. *Arthroscopy* 2007; Jun; 23(6): 629-634.
7. Davis KW, Tuite MJ. MR imaging of the postoperative meniscus of the knee. *Semin Musculoskelet Radiol* 2002; 6: 5-45
8. DeHaven KE. Meniscus repair : current concepts. *Am J Sports Med* 1999; 27:242-250.
9. DeHaven KE, Cosgarea AJ, Sebastianelli WJ. Arthrofibrosis of the knee following ligament surgery. *Instr Course Lect* 2003; 52: 369-381.
10. Dejour H, Walch G, Neyret P, Adeleine P. Résultats des laxités chroniques antérieures opérées. A propos de 251 cas revus avec un recul minimum de 3 ans. *Rev Chir Orthop* 1988; 74: 622-636.
11. Drogset JO, Grondtvedt T, Robak OR. A sixteen-year follow-up of three operative techniques for the treatment of acute ruptures of the anterior cruciate ligament. *J Bone Joint Surg Am* 2006; May 88(5): 944-952.
12. Gacon G, Barba L, Lalain JJ, Laurençon M, Ray A. Résultats à plus de dix ans de 54 plasties intra-articulaires du ligament croisé antérieur du genou. *Rev Chir Orthop* 1992; 78:130-131.

13. Garofalo R, Moretti B, Kombot C, Moretti L. Femoral tunnel placement in anterior cruciate ligament reconstruction: rationale of the two incision technique. *J Orthop Surg* 2007; May 21: 2-10.
14. Grover D, Thompson D, Hull ML, Howell SM. Empirical relationship between lengthening an anterior cruciate ligament graft and increase in knee anterior laxity: a human cadaveric study. *J Biomech Eng* 2006; Dec 128(6): 969-972.
15. Halinen J, Lindahl J, Hirvensalo E, Santavirta S. Operative and nonoperative treatments of medial collateral ligament rupture with early anterior cruciate ligament reconstruction: a prospective randomized study. *Am J Sports Med* 2006; Jul 34(7): 1134-1140.
16. Hanks GA, Trenton MG, Handal JA. Meniscus repair in the anterior cruciate deficient knee. *Am J Sports Med* 1990; 18:606-613.
17. Hart AJ, Buscombe J, Malone A, Dowd GS. Assessment of osteoarthritis after reconstruction of the anterior cruciate ligament: a study using single-photon emission computed tomography at ten years. *J Bone Surg Br* 2005; Nov;87(11): 1483-1487.
18. Johnston DR, Baker A, Rose C, Scotland TR, Maffulli N. Long-term outcome of MacIntosh reconstruction of chronic anterior cruciate ligament insufficiency using fasci lata. *J Orthop Sci* 2003; 8(6): 789-795.
19. Kaeding C, Farr J, Kavanaugh T, Pedroza A. A prospective randomized comparison of bioabsorbable and titanium anterior cruciate ligament interference screws. *Arthroscopy* 2005; Feb 21(2): 147-151.
20. Kuhn MA, Ross G. Allografts in the treatment on anterior cruciate ligament injuries. *Sports Med Arthrosc* 2007; Sep 15(3): 133-138.
21. Kumar K, Maffulli N. The ligament augmentation device: an historical perspective. *Arthroscopy* 1999; May 15(4): 422-432.
22. LaPrade RF, Johansen S, Wentorf FA, Engebretsen L. An analysis of an anatomical posterolateral knee reconstruction: an in vitro biomechanical study and development of a surgical technique. *Am J Sports Med* 2004; Sep 32(6): 1405-1414.
23. LaPrade RF, Morgan PM, Wentorf FA, Johansen S, Engebretsen L. The anatomy of the posterior aspect of the knee. An anatomic study. *J Bone Joint Surg (Am)* 2007; Apr 89(4): 758-764.
24. Li RC, Maffulli N, Hsu YC, Chan KM. Isokinetic strength of the quadriceps and hamstrings and functional ability of the anterior cruciate deficient knees in recreational athletes. *Br J Sports Med* 1996; Jun 30(2): 161-164.
25. Link TM, Steinbach LS, Ghosh S, Ries M, Lu Y, Lane N, Majumbar S. Osteoarthritis: MR Imaging findings in different stages of disease and correlation with clinical findings. *Radiology* 2003; 226:373-381.
26. Magee T, Shapiro M, Rodriguez J, Williams D. MR arthrography of postoperative knee: for which patients is it useful ? *Radiology* 2003; 229:159-163.
27. Marrale J, Morrissey MC, Haddad FS. A literature review of autograft and allograft anterior cruciate ligament reconstruction. *Knee Surg Sports Traumatol Arthrosc* 2007; Jun 15(6): 690-704.
28. McGinty JB, Jackson JW, Shrock KB. Arthroscopic management of the anterior cruciate ligament deficient knee. In McGinty JB, Caspari RB, Jackson RW eds. *Operative arthroscopy*. New-York, Lipincot -Raven 1996; 511-530.
29. Meunier A, Odensten M, Good L. Long-term results after primary repair or non-surgical treatment of anterior cruciate ligament rupture: a randomized study with a 15-year follow-up. *Scand J Med Sci Sports* 2007; Jun 17(3): 320-327.

30. Musahl V, Plakseychuk A, VanSyoc A, Fu FH. Varying femoral tunnels between the anatomical footprint and isometric positions: effect on kinematics of the anterior cruciate ligament-reconstructed knee. *Am J Sports Med* 2005; May 33(5): 712-718.
31. Oh YH, Namkoong S, Strauss EJ, Ishak C, Rosen J. Hybrid femoral fixation of soft-tissue grafts in anterior cruciate ligament reconstruction using the EndoButtol CL and bioabsorbable interference screws: a biomechanical study. *Arthroscopy* 2006; Nov 22(11): 1218-1224.
32. Pässler HH, Höher J. Intraoperative quality control of the placement of bone tunnels for the anterior cruciate ligament. *Unfallchirurg* 2004; Apr 107(4): 263-272.
33. Poolman RW, Farrokhyar F, Bhandari M. Hamstring tendon autograft better than bonepatellar-tendon bone autograft in ACL reconstruction. A cumulative meta-analysis and clinically relevant sensitivity analysis applied to a previously published analysis. *Acta Orthop* 2007; Jun 78(3): 350-354.
34. Risberg MA, Holm I, Myklebust G, Engebretsen L. Neuromuscular training versus strength training during the first 6 months after anterior cruciate ligament reconstruction: a randomized clinical trial. *Phys Ther* 2007; Jun 87(6): 737-750.
35. Roos H, Adalbrecht T, Dahlberg L, Lohmander LS. Osteoarthritis of the knee after injury to the anterior cruciate ligament or meniscus: the influence of time and age. *Osteoarthritis Cartilage* 1995; 3:261-267.
36. Sgaglione NA, Douglas JS. Allograft bone augmentation in anterior cruciate ligament reconstruction. *Arthroscopy* 2004; Jul 20 suppl 2: 171-177.
37. Steenbrugge F, Verdonk R, Hürel C, Verstraete K. Arthroscopic meniscus repair: inside-out vs. Biofix meniscus arrow. *Knee Surg Sports Traumatol Arthrosc* 2004; 12: 43-49.
38. Steenbrugge F, Verdonk R, Verstraete K. Magnetic resonance imaging of the surgically repaired meniscus: a 13-year follow-up study. *Acta Orthop Scand* 2004; 75:323-327.
39. Steenbrugge F, Verdonk R, Vorlat P, Mortier F, Verstraete K. Repair of chronic ruptures of the anterior cruciate ligament using allograft reconstruction and a ligament augmentation device. *Acta Orthop Belg* 2001; 67(3): 252-258.
40. Steenbrugge F, Verdonk R, Verstraete K. Allograft reconstructions for chronic ruptures of the anterior cruciate ligament: augmentation versus non-augmentation. *Eur J Orthop Surg Traumatol* 2002; 12: 8-13.
41. Steenbrugge F, Van Nieuwenhuysse W, Verdonk R, Verstraete K. Arthroscopic meniscus repair in the ACL-deficient knee. *Int Orthop* 2005; 29: 109-112.
42. Stone RG, Frewin PR, Gonzales S. Long-term assessment of arthroscopic meniscus repair: a two- to six-year follow-up study. *Arthroscopy* 1990; 6:73-78.
43. Strand T, Molster A, Hordvik M, Krukhaug Y. Long-term follow-up after primary repair of the anterior cruciate ligament: clinical and radiological evaluation 15-23 years postoperatively. *Arch Orthop Trauma Surg* 2005; May 125(4): 217-221.
44. West RV, Harner CD. Graft selection in anterior cruciate ligament reconstruction. *J Am Acad Orthop Surg* 2005; May-Jun 13(3): 197-207.
45. Witvoet J, Kerboul L, Christel P. Résultats à long terme (4-10 ans) de 88 ligamentoplasties intra-articulaires dans le traitement des instabilités antérieures chroniques du genou. *Rev Chir Orthop* 1991; 77: 56-157.
46. Woo SL, Abramowitch SD, Kilger R, Liang R. Biomechanics of knee ligaments: injury, healing and repair. *J Biomech* 2006; 39(1): 1-20.
47. Woo SL, Thomas M, Chan Saw SS. Contribution of biomechanics, orthopaedics and rehabilitation: the past present and future. *Surgeon* 2004; Jun 2(3): 125-136.

48. Woo SL, Wu C, Dede O, Vercillo F, Noorani S. Biomechanics and anterior cruciate ligament reconstruction. *J Orthop Surg* 2006; Sep 25: 1-2.
49. Wright RW, Fretzer GB. Bracing after ACL reconstruction: a systematic review. *Clin Orthop Relat Res* 2007; Feb 455: 162-168.
50. Yonetani Y, Toritsuka Y, Yamada Y, Shino K. Graft length changes in the bi-socket anterior cruciate ligament reconstruction : comparison between isometric and anatomic femoral tunnel placement. *Arthroscopy* 2005; Nov 21(11): 1317-1322.
51. Zantop T, Herbort M, Raschike MJ, Fu FH, Petersen W. The role of the anteromedial and posterolateral bundles of the anterior cruciate ligament in anterior tibial translation and internal rotation. *Am J Sports Med* 2007; Feb 35(2): 223-227.
52. Zantop T, Petersen W, Sekiya JK, Musahl V, Fu FH. Anterior ligament anatomy and function relating to anatomical reconstruction. *Knee Surg Sports Traumatol Arthrosc* 2006; Oct 14(10): 982-992.



CHAPTER VI  
CLINICAL APPLICATIONS

## CHAPTER VI: CLINICAL APPLICATIONS

Prospective studies have confirmed knee trauma to be a significant risk factor for development of knee osteoarthritis (3,11).

Injury to the anterior cruciate ligament, isolated or with associated injuries to the menisci or collateral ligaments leads to a high frequency of radiographic knee osteoarthritis (5,8).

Among subjects who have undergone total meniscectomy, with no other associated injuries, approximately 50% have radiographic knee osteoarthritis about 20 years after the surgery (9).

Accordingly, one of the areas of attention in osteoarthritis research is to detect early alterations in joint metabolism by molecular markers (4). In addition, various modern imaging techniques, such as magnetic resonance imaging have the potential to detect very early structural change (6).

Today, techniques of meniscal repair are widely used when the lesion is located within or adjacent to the vascularised zone of the meniscus.

However, rehabilitation after repair is more extensive than after meniscal resection, and the long-term outcome of meniscal repair compared with meniscectomy related to osteoarthritis is still unknown (1,2,5, 7,10).

The aim of this thesis is to enhance the knowledge of the long-term results of meniscus repair and anterior cruciate reconstruction with respect to the development of osteoarthritis.

The **first study** was set up to investigate the long-term outcome of meniscal sutures.

Magnetic resonance imaging was used to evaluate the repairs and the development of degenerative changes in knees with an intact or reconstructed ACL or a ruptured ACL.

The **second study** looked into the long-term outcome results of two different suture techniques.

The **third study** was initiated to look at the long-term outcome of meniscal repair in ACL deficient knees compared to repairs in ACL intact knees.

The **fourth study** looked at the radiographic changes on MRI of repaired menisci at long-term follow-up. The development of osteoarthritis was evaluated in ACL intact knees and knees with a ruptured ACL.

The **fifth study** was set up to investigate the long-term outcome of ACL repair using allografts and a ligament augmentation device. Clinical outcome as well as radiographic changes were noted in patients with intact or repaired menisci or patients that had undergone partial meniscectomy. X-rays were used to evaluate the development of osteoarthritis.

The **sixth study** showed the long-term outcome differences between allograft reconstructions of ACL-injured knees with or without a ligament augmentation device. Clinical outcome as well as radiographic changes were noted in patients with intact or repaired menisci or patients that had undergone partial meniscectomy. X-rays were used to evaluate the development of osteoarthritis.

### References

1. Almqvist KF, Jan H, Vercruyse C, Verbeeck R, Verdonk R. The tibialis tendon as a valuable anterior cruciate ligament allograft substitute: biomechanical properties. *Knee Surg Sports Traumatol Arthrosc* 2007; Aug: epub ahead of print.
2. DeHaven KE, Lohrer WA, Lovelock JE. Long-term results of open meniscus repair. *Am J Sports Med* 1995; 23(5):524-530.
3. Gelber AC, Hochberg MC, Mead LA. Joint injury in young adults and risk for subsequent knee and hip osteoarthritis. *Ann Intern Med* 2000; 133(5):321-328.



4. Lohmander LS, Poole AR. Defining and validating the clinical role of molecular markers in osteoarthritis. In: Osteoarthritis (Eds. Brandt KD, Doherty M and LohmanderLS) Oxford University Press, Oxford 2003; 468-474.
5. Neyret P, Donell ST, Dejour H. Results of partial meniscectomy related to the state of the anterior cruciate ligament. Review at 20 to 35 years. *J Bone Joint Surg (Br)* 1993; 75(1): 36-40.
6. Peterfly CG. Magnetic resonance imaging. In: Osteoarthritis (Eds. Brandt KD, Doherty M and LohmanderLS) Oxford University Press, Oxford 2003; 431-451.
7. Rockborn P, Messner K. Long-term results of meniscus repair and meniscectomy: a 13-year functional and radiographic follow-up study. *Knee Sports Traumatol Arthrosc* 2000; 8(1): 2-10.
8. Roos H, Adalberth T, Dahlberg L, Lohmander LS. Osteoarthritis of the knee after injury to the anterior cruciate ligament or meniscus: the influence of time and age. *Osteoarthritis Cartilage* 1995; 3(4): 261-267.
9. Roos EM, Roos HP, Lohmander LS, Ekdahl C, Beynnon BD. Knee Injury and Osteoarthritis Outcome Score (KOOS)-development of a self-administered outcome measure. *J Orthop Sports Phys Ther* 1998; 28 (2): 88-96.
10. Stone RG, Frewin PR, Gonzales S. Long-term assessment of arthroscopic meniscus repair: a two-to-six year follow-up study. *Arthroscopy* 1990; 6(2):73-78.
11. Wilder FV, Hall BL, Barret Jr JP, Lemrow NB. History of acute knee injury and osteoarthritis of the knee: a prospective epidemiological assessment. The Clearwater Osteoarthritis Study. *Osteoarthritis Cartilage* 2002; 10(8): 611-616.

**Long-term assessment of arthroscopic meniscus repair: a 13-year follow-up study** Franky Steenbrugge <sup>a\*</sup>,  
Rene Verdonk <sup>a</sup>, Koen Verstraete <sup>b</sup>

<sup>a</sup>Department of Orthopaedic Surgery and Traumatology, UZ-Gent,  
De Pintelaan 185, B-9000 Gent, Belgium

<sup>b</sup>Department of Radiology, Ghent University Hospital, B-9000 Gent, Belgium

Received 15 June 2001; received in revised form 30 November 2001;

accepted 2 January 2002

## Abstract

A prospective study was set up to evaluate meniscal suturing using an inside-out technique. Of an initial group of 20 patients who underwent closed meniscus repair between 1985 and 1988 using an inside-out technique, 13 were studied. All patients were subjected to a clinical examination and a magnetic resonance imaging (MRI) investigation. The findings were compared with those of their previous follow-up examination (1994). The Hospital for Special Surgery (HSS) knee rating system (R.G. Stone et al. *Arthroscopy* 1990; 73–78) was used. The study included seven men and six women, ranging in age from 29 years to 50 years (mean age: 35 years months). The mean follow-up was 13 years 2 months (11 years 11 months – 15 years 4 months). Six left and seven right knees were involved. Seven patients also had an anterior cruciate ligament (ACL) injury of which one was repaired years after meniscal repair. All patients obtained an HSS score of more than 75%. In all patients, the site of the previous suture was still visible on MRI mainly by small metal artefacts in the meniscus. Patients with an unrepaired ACL lesion had an early onset of arthrosis and cartilage degeneration. Meniscal suturing gives good clinical long-term results. Magnetic resonance imaging, however, showed signs of mucoid degeneration or scar tissue in 46% of the patients. © 2002 Elsevier Science B.V. All rights reserved.

**Keywords:** Meniscal suture; Inside-out technique; Arthroscopy; MRI

## 1. Introduction

Meniscal tears are the most common intra-articular knee injuries, comprising 75% or more of all internal derangements of the knee [1]. Historically, operative treatment for symptomatic meniscal tears involved total meniscectomy by arthrotomy, regardless of tear type, size or location. This procedure, which was felt to be benign [2], was subsequently shown to produce major long-term sequelae. Fairbank [3] was the first to demonstrate clinically, the deleterious long-term effects of total

meniscectomy. His classic description of radiographic joint space narrowing, flattening of the femoral condyle and marginal osteophyte formation after meniscectomy, with subsequent progressive hyaline cartilage failure, remains a landmark in the treatment of meniscal tears. The histologic and biochemical structure of the meniscus, as well as its biological function, have been well defined [4–7]. The meniscal–ligamentous complex, which works in concert with joint congruity, provides functional stability through a wide range of stresses and demands. The menisci contribute to load transmission [7–10], shock absorption [11], joint stability [12–15] and lubrication of articular cartilage [16,17]. The pivotal role of the meniscus in joint function as evidenced by the increased incidence of degenerative changes after meniscectomy, has been underscored [3,11,13,16–21].

During the last decade, increasing understanding of the histologic, biologic and functional significance of the menisci has led to a more conservative therapeutic approach to lesions of the meniscus. Today's selective approach includes non-operative treatment of meniscal tears, partial meniscectomy and meniscal repair as alternatives to routine meniscectomy. Since Annandale [22] reported the first meniscal repair in the late 1800s, studies of the vascular anatomy of the meniscus have documented its healing potential [13,23,24]. Clinical reports of successful open and arthroscopic repairs have engendered enthusiasm for these procedures. Long-term follow-up of meniscal repair procedures is important to ascertain that repaired menisci will survive, function effectively and prevent the late degenerative changes seen after meniscectomy [25,26].

\*Corresponding author. Tel.: +32-9-240-2264; fax: +32-9-240-49-75.

E-mail address: franky.steenbrugge@rug.ac.be (F. Steenbrugge).

0968-0160/02/\$ - see front matter © 2002 Elsevier Science B.V. All rights reserved.

PII: S0968-0160(02)00017-0

Table 1  
Patient distribution

Patient	Age	Sex	Side	ACL	Extente of tear	Socore	Acute-chronic
1	44 y 6 m	M	L		Zone 2	R-W	Acute
2	50 y 2 m	M	L	Rupt	Zone 3	W-W	Chronic
3	48 y 1 m	M	R	Rupt	Zone 1	R-W	Acute
4	31 y 10 m	M	L	Rupt	Zone 2	R-W	Chronic
5	35 y 1 m	M	R	Rupt	Zone 1	R-W	Acute
6	38 y	M	R		Zone 2	R-W	Chronic
7	37 y 10 m	M	L	Rupt (repaired)	Zone 1	R-R	Acute
8	31 y 1 m	F	R		Zone 1	R-W	Chronic
9	29 y 6 m	F	L		Zone 3	R-W	Chronic
10	32 y 9 m	F	R		Zone 2	R-W	Acute
11	34 y 6 m	F	L		Zone 2	R-W	Chronic
12	31 y 10 m	F	R		Zone 3	R-R	Acute
13	44 y 10 m	F	R		Zone 2	R-W	Chronic

Mean follow-up:13 years 2 months;mean age at follow-up:35 years months;patient number,7:ACL rupture repaired after years;extent of tear: Zone 1,0 –3 mm; Zone 2,4 –mm; Zone 3, >6mm; location of tear: Red –Red, Red –White, White–White; acute:injury-to-repair interval <2 weeks; chronic: injury-to-repair interval >2 weeks.

## 2. Materials

Between June 1985 and June 1988, 20 consecutive arthroscopic meniscal repairs using an inside-out technique were performed on 20 knees of 20 patients.

Thirteen patients returned for a clinical examination and MRI-evaluation at a 13-year follow-up. The remaining 7 patients were interviewed by telephone. This review includes only those 13 patients who returned for a complete examination,including MRI evaluation. All patients sought medical advice for acute or chronic knee symptoms.

## 3. Methods

History, physical examination and preoperative CT-scan were always used to identify ligamentous or meniscal injury in all patients [27]. The presence of a meniscal lesion was confirmed in all patients at the time of intervention.

Each patient was questioned regarding pain,swelling, symptoms of giving-way and,in an attempt to establish the functional level,his or her ability to return to sports or work.The knee was examined for an effusion,soft tissue swelling,joint line tenderness,intra-articular crepitus and ability to squat. McMurray 's test [28] was also performed.Muscle power,thigh circumference and range of knee motion were measured,and compared to those of the contralateral extremity.

A modification of the Hospital for Special Surgery (HSS )knee rating system [28] was used for evaluation.

Patients were assigned to either excellent, good, fair or poor groups, based on their HSS score. This

study population consisted of otherwise healthy, athletic persons (7 men and 6 women) whose mean age was 35 years 6 months at the time of follow-up (29 years-50 years 2 months). The follow-up averaged 13 years 2 months, with an 11 years months - 15 years 4 months range. Six left and seven right knees were involved.

The location and the extent of the tear were described by zones (1,2 and 3 )based on the distance from the synovial meniscal junction (SMJ )and the length of the tear: zone 1, 0 –3 mm long;zone 2,4 – 6 mm; and zone 3, >6 mm. Four patients had a tear between 0 and 3 mm length, patients between 3 and mm and 3 patients had a tear of more than mm.Two tears were located in the red–red zone,10 were in the red–white zone and one was in the white–white zone (Table 1).

We used the hooked palpator with markings to make the measurements.

#### **4. Techniques**

Twenty patients underwent an arthroscopic meniscal repair,using an inside-out technique as described by Henning and Cannon [29]. We used absorbable sutures with double-barreled tapered Keith needles that were custom-bent at surgery and inserted through a long, straight or curved canula,using a needle holder. Posteromedial and posterolateral cutaneous incisions and a popliteal retractor were routinely used to protect and retract neurovascular structures,where the needles penetrated the posterior capsule as the sutures were tied over the capsule. During the procedure,the body of the meniscus and the peripheral rim were meticulously prepared. This included excision of any loose or unstable meniscal fragments or tags and rasping of both sides of the tear site.A thorough rasping of the parameniscal synovium in both the meniscofemoral and meniscotibial regions was performed for the red–red tears. The sutures were placed at 3–4 mm intervals. The aftercare included a 3-week period of maximum protection to provide the best opportunity for healing to occur.

The patients were allowed to mobilize immediately.

During these 3 weeks only touch weight bearing was permitted.This was followed by a period of continuing protection from heavy stresses,during maturation of the repair tissue,until 3 months after surgery. During this time,efforts were focused on regaining a full range of motion,excellent muscle strength, flexibility and endurance. The patients were cautioned not to squat down on the operated knee and they were advised not to undertake any running (not even in a straight line) or agilityactivities. After 3 months, a gradual return to full-speed running,agility,and unrestricted activities was encouraged as desired and tolerated.

Table 1  
Patient distribution

Patient	Age	Sex	Side	ACL	Extent of tear	Location of tear	Acute –chronic	Socore
1		M			Zone 2	R-W	Acute	Excellent
2		M		Rupt	Zone 3	W-W	Chronic	Good
3		M		Rupt	Zone 1	R-W	Acute	Good
4		M		Rupt	Zone 2	R-W	Chronic	Good
5		M		Rupt	Zone 1	R-W	Acute	Good
6		M			Zone 3	R-W	Chronic	Fair
7		M		Repaired	Zone 1	R-R	Acute	Good
8		F			Zone 1	R-W	Chronic	Excellent
9		F		Rupt	Zone 3	R-W	Chronic	Fair
10		F			Zone 2	R-W	Acute	Good
11		F			Zone 2	R-W	Chronic	Good
12		F		Rupt	Zone 2	R-R	Acute	Good
13		F			Zone 2	R-W	Chronic	Good

## 5. Results

Based on a modification of the HSS knee evaluation form, two patients had an excellent result and nine patients a good result, making a total of 11 with a 'satisfactory' outcome. Two patients of the study population had a fair result. There were no poor results. The results were compiled and classified in reference to many factors, which facilitates comparisons among the four different groups (excellent, good, fair, poor). The average follow-up of 13 years was similar for the four groups. The age range matched closely. Age did not change the outcome, probably because the selection criteria for meniscus repair were stricter in the older age group. The sex of the patient had no effect on the outcome, with 85% of all male and female patients having good-to-excellent results. All acute tears (injury-to-repair interval <2 weeks and 80% of all chronic tears (injury-to-repair interval > 2 weeks) had good-to-excellent results. The two patients in the fair group had a chronic tear. Approximately 15% of tears fell within 0–3 mm of SMJ (zone 1). All zone 1-tear repairs and 80% of all zone 2-tear repairs had good-to-excellent results. Only one zone 3-tear (>6mm from the SMJ) was repaired. This patient scored a good result. Patients with a tear between 0–3 mm had a good-to-excellent result. Two patients with a tear between 3–mm had a fair result. All other patients had good-to-excellent results. Of the 13 patients at follow-up, seven demonstrated an associated ACL injury. Only one was reconstructed, years after meniscal repair. One of these six patients had a fair result. The five other patients had good-to-excellent results (Tables 2 and 3).

Complications included one superficial infection, managed with antibiotics and one saphenous neura-praxia. No patient had permanent functional impairment.

As mentioned earlier, seven patients of the initial group of 20 patients were interviewed by telephone.

Table 3

Compilation and classification of the number of patients with Excellent, Good, Fair or Poor results in reference to different factors

Factors	Excellent	Good	Fair	Poor
Males	1	5	1	0
Females	1	4	1	0
Zone 1 tear	1	3	0	0
Zone 2 tear	1	5	0	0
Zone 3 tear	0	1	2	0
R –R tear	0	2	0	0
R –W tear	2	2	0	0
W –W tear	0	1	0	0
Acute	1	5	0	0
Chronic	1	4	2	0
ACL	0	5	1	0

One patient had an ACL tear repaired at the 6-year follow-up: he scored a Good result; Extent of tear: Zone 1, 0–3 mm; Zone 2, 4–6 mm; Zone 3, >6 mm; location of tear: Red–Red; Red–White; White–White.

Table 4

Results of the seven patients interviewed by telephone

Patient	Age	Sex	Side	ACL	Extent of tear	Location of tear	Acute-chronic	Score
1	42 y 5 m	M	R		Zone 2	R-R	Acute	Excellent
2	37 y 2 m	M	L		Zone 3	R-W	Acute	Good
3	34 y 1 m	M	R	Rupt	Zone 1	R-W	Chronic	Fair
4	41 y 9 m	M	L		Zone 2	R-R	Chronic	Good
5	33 y	F	R		Zone 1	R-R	Acute	Good
6	36 y 4 m	F	L		Zone 3	R-W	Chronic	Good
7	37 y 10 m	F	L		Zone 1	R-R	Acute	Excellent

Score based on Modification of Hospital for Special Surgery Knee Rating Scale: Excellent, Good, Fair, Poor; Clinical assessment scores were not available; mean follow-up: 13 years 5 months; mean age at follow-up: 36 years 9 months.

This group had similar results compared to the group of 13 patients (Table 4 ).

## 6. MRI evaluation

Unfortunately, follow-up arthroscopic evaluation is an invasive procedure that exposes the patient to an additional period of recuperation and risk, even though limited. These issues, plus cost-containment concerns prevalent in health care today, have made follow-up arthroscopic evaluation unsuitable for clinical research purposes alone.

MRI is at least as accurate as arthrography in assessing meniscal repair, with statistical significance [30]. In all patients a MR examination was performed at review. Sagittal proton-density and T2-weighted images followed by 2-mm coronal three-dimensional-gradient-echo images were acquired. Four-millimeter axial T1 weight-ed images and 3-mm sagittal T2-weighted images were also obtained. In all patients ( $n = 13$ ), the site of the previous suture could still be detected, mainly by the small micrometal artefacts in the meniscus, evident on the gradient echo images (Fig. 1). In one patient, a new tear was found. In five patients, hyperintense areas were discovered in the meniscus, in the area of the previous intervention. We presume this corresponds to mucoid degeneration or scar tissue (Fig. 2). Seven patients had an ACL rupture, of which one was repaired years post-meniscal repair. Four patients clearly showed an early onset of arthritis and cartilage degeneration (grade 3) (Fig. 3) and two showed minor signs of cartilage degeneration (grade 1) [31]. The patients with grade 3 lesions had good-to-excellent functional results (Table 5).

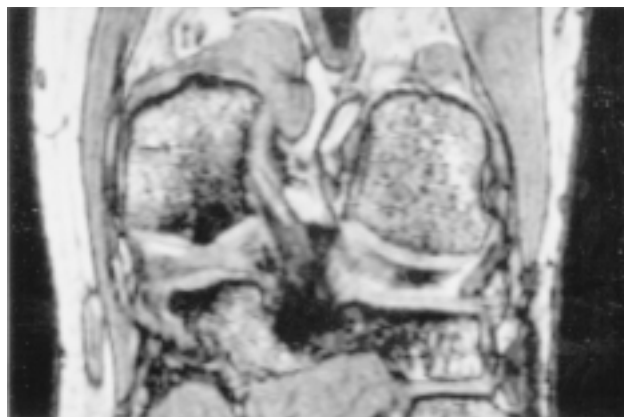


Fig. 1. Gradient echo MRI image. Small micrometal artefacts in the meniscus, showing the previous site of suture.



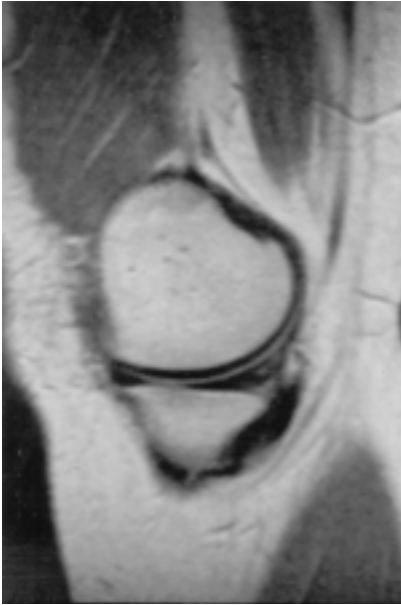

Fig. 2. Hyperintense area in the meniscus due to mucoid degeneration.

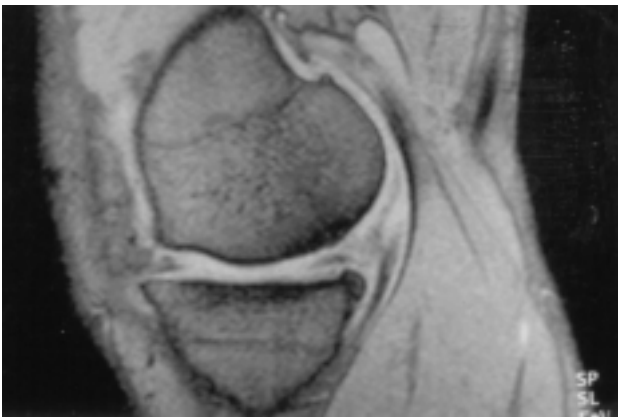


Fig. 3. Early onset of arthritis and cartilage degeneration (grade 3).

In 1994, the site of the previous suture was also visible in all patients (n s 13). A new tear was found in one patient. This tear was not repaired. In 1999, there were no signs of this tear. Only two patients showed signs of mucoid degeneration in the area of the previous intervention. There were seven patients with an ACL rupture. Two patients showed signs of grade 3 cartilage degeneration and two patients had minor signs (grade 1).

## 7. Discussion

Meniscus tears suitable for repair with a great chance of success are traumatic ruptures within the vascular zone, in which the peripheral circumferential fibers remain intact and damage to the meniscus body is minimal. The most common tear types that fit these criteria are peripheral, or near peripheral, vertical, longitudinal tears. Patients with other types of tears, which are clearly in the avascular zone or where the vascularity is doubtful, must be considered questionable candidates for repair. Many factors influence the results of meniscus repair. They include the age and sex of the patient, the Seven patients sustained an ACL injury, of which only one was reconstructed, years after meniscal repair.

They all had good-to-excellent results. Stability of the knee did not seem to affect the result of meniscal repair.

Hanks et al. [33] reported on meniscus repair in the ACL-deficient knee. They had a 13% failure rate.

They chronicity of the tear from the time of injury, and the location of the tear.

The results of medial or lateral meniscus repair depend on the location of the tear, as related to the distance from the SMJ, the length of the tear, the stability of the ACL, the vascularity and the cooperation of the patient. In our study, chronicity of the tear was found to affect the percentage of satisfactory results. All the menisci repaired within 2 weeks of injury had a good-to-excellent result. Only one zone 3-tear was repaired and this patient scored a good result. Rubman and Noyes [32] recommend arthroscopic repair for meniscal tears extending into the avascular zone, in select cases. The 20% reoperation rate in their study should not be interpreted as the rate of meniscal healing, but as the incidence of tibiofemoral joint symptoms.

Seven patients sustained an ACL injury, of which only one was reconstructed, years after meniscal repair.

They all had good-to-excellent results. Stability of the knee did not seem to affect the result of meniscal repair.

Hanks et al. [33] reported on meniscus repair in the ACL-deficient knee. They had a 13% failure rate. They concluded that even though the failure rate may be higher in an unstable knee, meniscus repair was not contraindicated in an ACL-deficient knee.

Neither the age of the patient nor the length or extent of the tear seemed to affect the result of meniscal repair.

We believe that in clinically asymptomatic patients, the meniscus is either histologically healed or acts as an autograft and fulfills the biomechanical tasks of an injured meniscus. Long-term studies evaluating the development of arthrosis in patients with clinically healed meniscal tears after arthroscopic repair may provide more evidence to support this hypothesis.

Hanks et al. [34], Henning [35] and Cannon [36] suggested that MRI may prove to be an ideal diagnostic tool in evaluating meniscal healing. The first studies using MRI after meniscal repair were performed by Farley et al. [37] and Bronstein et al. [38]; these authors reported a persistent pathologic signal after suture of the meniscus. The remaining question in these short-term studies was whether these mainly grade 3 signals represented persisting tears or the increased water content of

fresh scar tissue, which may disappear eventually.

We found the presence of mucoid degeneration or scar tissue in six of 13 patients after an average follow-up of more than 13 years. Therefore, we believe that asymptomatic menisci produce abnormal MRI signals, even though they have stable unions and that MRI signals at the site of repair represent edematous scar tissue, not true non-unions. Egli et al. found similar findings in their study [12].

## **8. Conclusion**

Our current protocol for the repair of meniscal tears relies on several technical details that the authors consider to be essential for the successful repair of simple and complex meniscal tears. A careful examination is required to determine the integrity of the meniscal tissue and assess chronic changes, such as deformation or degeneration. The meniscus must contain a reducible tear with good tissue integrity that will maintain its position in the joint once repaired.

Degenerative, poor quality meniscal tissue is not strong enough to hold the sutures and should not be considered for repair. Stable fixation of the meniscal tear decreases the possibility of motion between the meniscal fragments, and allows a postoperative rehabilitation program that emphasizes early motion and weight bearing.

Multiple, non-absorbable sutures, in both the superior and inferior surfaces of the meniscus, are placed every 3–4 mm to ensure the repair will be held in position to allow healing to occur. A recent report of the results of repair of longitudinal meniscal tears evaluated arthroscopically found that no tear with a rim width of greater than 4 mm healed [39]. The sutures in that study were placed at least 4 mm apart. It is the senior author's opinion that complex tear patterns and meniscal tears in the central region are subjected to higher stresses than those incurred in single longitudinal tears located in the periphery, and therefore require sutures to be placed at closer intervals. Because the location of the tear within the meniscus is not a primary consideration for which tears are amenable to repair, we no longer measure the rim width at the time of repair. All tears that undergo repair, regardless of pattern or location, are held in place with multiple sutures placed at 3–4 mm intervals.

Partial meniscectomy for complex tear patterns or tears that extend into the avascular zone require removal of a large portion of the meniscus and they may render it non-functional. If meniscus repair is performed, the long-term data in our study show that at 13 years after surgery, a majority of the patients will be asymptomatic.

Table 5

Correlation between scores and MRI evaluation at 13-year follow-up

Patient	ACL	Score	MRI evaluation
1		Excellent	Suture site visible, hyperintense area
2	Rupt	Good	Suture site visible, hyperintense area,new tear
3	Rupt	Good	Suture site visible, cartilage degeneration (grade 3)
4	Rupt	Good	Suture site visible, cartilage degeneration (grade 3)
5	Rupt	Good	Suture site visible, cartilage degeneration (grade 3)
6		Fair	Suture site visible
7	Repaired	Good	Suture site visible, hyperintense area, cartilage degeneration (grade 1)
8		Excellent	Suture site visible
9	Rupt	Fair	Suture site visible, cartilage degeneration (grade 1)
10		Good	Suture site visible, hyperintense area
11		Good	Suture site visible
12	Rupt	Good	Suture site visible, cartilage degeneration (grade 3)
13		Good	Suture site visible, hyperintense area

**References**

[1] Shands AR,Hutchinson JL,Ziv L.Derangements of the semilunar cartilages of the knee:a clinical and experimental study.South Med J 1936; 29: 1045 –1050.

[2] Smillie JS. Injuries to the knee joint. Baltimore: Williams and Wilkins, 1961.

[3] Fairbank TJ. Knee joint changes after meniscectomy. J Bone Jt Surg (Br) 1948; 30B: 664 –670.

[4] Arnoczky S, Adams M, DeHaven KE. Meniscus. In: Woo SY, Buckwalter JA, editors.Injury and Repair of the Musculoskeletal Soft Tissues. Chicago: American Academy of Orthopedic Surgeons; 1987 .p. 487

[5] King D. The healing of the semilunar cartilages. J Bone Jt Surg 1936; 18:333 –342.

[6] Bullough PG, Munuera L, Murphy J. The strength of the menisci of the knee as it relates to their fine structure.J Bone Jt Surg (Br )1970;52B:564–570.

[7] Renstrom P,Johnson RJ.Anatomy and biomechanics in the knee. Clin Sports Med 1990; 9:523–538.

[8] Fukubayashi T, Kurosawa H. The contact area and pressure distribution pattern of the knee. Acta Orthop Scand 1980; 51:871–879.

[9] Kurosawa H, Fukubayashi T, Nakajima H. Load-bearing mode of the knee joint: physical behavior of the knee joint with or without menisci. Clin Orthop 1980; 149: 283 –290.

[10] Walker PS,Erkman MJ.The role of the menisci in force transmission across the knee. Clin Orthop 1975; 109: 184–192.

[11] Krause WR, Pope MH, Johnson RJ. Mechanical changes in the knee after meniscectomy. J Bone Jt Surg (Am) 1976; 58A-: 599–604.

[12] Eggli S, Wegmuller H, Kosina J. Long-term results of arthro-scopic meniscal repair: an analysis of isolated tears. Am J Sports Med 1995; 23: 715–720.

[13] Johnson RJ, Kettelkamp DB, Clark W. Factors affecting late results aftermeniscectomy. J Bone Jt Surg (Am )1974; 56A-: 719–729.

[14] Levy IM, Torzilli PA, Warren RF. The effect of medial meniscectomy on anterior-posterior motion of the knee. J Bone Jt Surg (Am) 1982; 64A: 883–888.

- [15] Markolf KL, Bargar WL, Shoemaker SC. The role of joint load in knee stability. *J Bone Jt Surg (Am)* 1981; 63A :570–585.
- [16] Dandy DJ, Jackson RW. Meniscectomy and chondromalacia of the femoral condyle. *J Bone Jt Surg (Am)* 1975; 57A: 1116–1119.
- [17] Radin EL, Delamotte F, Maquet P. Role of the menisci in the distribution of stress in the knee. *Clin Orthop* 1984; 185: 290–294.
- [18] Dandy DJ, Jackson RW. The diagnosis of problems after meniscectomy. *J Bone Jt Surg (Br)* 1975; 57B: 349–352.
- [19] Jackson JP. Degenerative changes in the knee after meniscectomy. *Br Med J* 1968;72:525–527.
- [20] Veth RPH. Clinical significance of knee joint changes after meniscectomy. *Clin Orthop* 1985; 198: 56–60.
- [21] Macnicol MF, Thomas NP. The knee after meniscectomy. *J Bone Jt Surg (Br)* 2000; 82B: 157–159.
- [22] Annandale T. An operation for displaced semilunar cartilage. *Br Med J* 1885; 1: 799.
- [23] Arnoczky SP, Warren RF. The microvasculature of the human meniscus. *Am J Sports Med* 1982; 10:90–95.
- [24] Arnoczky SP, Warren RF. The microvasculature of the meniscus and its response to injury: an experimental study in the dog. *Am J Sports Med* 1983; 11: 131–141.
- [25] De Haven KE, Lohrer WA, Lovelock JE. Long-term results of open meniscus repair. *Am J Sports Med* 1995; 23: 524–530.
- [26] De Haven KE. Meniscus repair: current concepts. *Am J Sports Med* 1999; 27: 242–250.
- [27] Verdonk R, Meire D, Van De Velde C, Van Eetvelde G, Claessens H. CT scan of the knee: correlation with clinical and arthroscopic findings. *Acta Orthop Belg* 1991; 57: 49–55.
- [28] Stone RG, Frewin PR, Gonzales S. Long-term assessment of arthroscopic meniscus repair: a two-to six-year follow-up study. *Arthroscopy* 1990; 6: 73–78.
- [29] Cannon WD, Morgan CD. Meniscal repair. *J Bone Jt Surg (Am)* 1994; 76A: 294–311.
- [30] Van Trommel MF, Potter HG, Ernberg LA. The use of non-contrast Magnetic Resonance Imaging in evaluating meniscal repair. *Arthroscopy* 1998; 14: 2–8.
- [31] Recht MP, Kramer J, Marcelis S. Abnormalities of articular cartilage in the knee: analysis of available MR techniques. *Radiology* 1993; 187: 473–478.
- [32] Rubman MR, Noyes FR, Barber-Westin SD. Arthroscopic repair of meniscal tears that extend into the avascular zone: a review of 198 single and complex tears. *Am J Sports Med* 1998; 26: 87–95.
- [33] Hanks GA, Trenton MG, Handal JA. Meniscus repair in the anterior cruciate deficient knee. *Am J Sports Med* 1990; 18: 606–613.
- [34] Hanks GA, Gause TM, Sebastianelli WJ. Repair of peripheral meniscal tears: open versus arthroscopic technique. *Arthroscopy* 1991; 7: 72–77.
- [35] Henning CE. Arthroscopic repair of meniscus tears. *Orthopedics* 1983; 6: 1130–1132.
- [36] Cannon WD. Arthroscopic meniscal repair. In: McGinty JB, editor. *Operative Arthroscopy*. New York: Raven Press; 1991. p. 237–251.
- [37] Farley TE, Howell SM, Love KF. Meniscal tears: MR and arthrographic findings after arthroscopic repair. *Radiology* 1991; 180: 517–522.
- [38] Bronstein R, Kirk P, Hurley J. The usefulness of MRI in evaluating menisci after repair. *Orthopedics* 1992; 15: 149–152.
- [39] Tenuta JJ, Arciero RA. Arthroscopic evaluation of meniscal repairs. Factors that effect healing. *Am J Sports Med* 1994; 22: 797–802.

# Arthroscopic meniscus repair: inside-out technique vs. Biofix meniscus arrow

Franky Steenbrugge • René Verdonk • Chan Hürel • Koen Verstraete

Received: 26 March 2002 Accepted: 27 July 2003 Published online: 26 September 2003 ©Springer-Verlag 2003

F. Steenbrugge (•) Department of Orthopaedic Surgery, ASZ, 9300 Aalst, Belgium  
Tel.: +32-53-764914 Fax: +32-53-764918 e-mail: Fsteenbr@belgacom.net

R. Verdonk • C. Hürel Department of Orthopaedic Surgery, Ghent University Hospital, 9000 Ghent, Belgium  
K. Verstraete Department of Radiology, Ghent University Hospital, 9000 Ghent, Belgium

**Abstract** A retrospective study evaluated meniscal suturing using an inside-out technique vs. an all-inside technique (Biofix meniscus Arrow).

Fifty-five knees in 55 patients who underwent closed meniscus repair between 1985 and 1995 were divided in two groups: 20 managed by an inside-out technique; and 35 managed by an all-inside technique. All patients underwent the same postoperative program of partial weight bearing, immediate motion, and rehabilitation of the knee. They were subjected to a clinical examination using Hospital for Special Surgery knee rating system. The mean follow-up was 13 years, 2 months (11 years, 11 months – 15 years, 4 months) in the inside-out group and 6 years, 5 months (6 years – 6 years 10 months) in the Biofix Arrow group. Sixteen patients also had an anterior cruciate ligament injury, of which six were repaired at the time of meniscus repair and one 6 years after meniscal repair. Thirty-nine patients had an excellent or good result (87% satisfactory outcome), three had a fair result, and three had a poor result. Meniscal suturing thus provides good clinical long-term results. The advantages of an all-inside technique include short operating time, superfluous capsular exposure, easier technique, and potentially lower risk of neurovascular lesions, especially when posterior horns are involved.

**Keywords** Meniscal suture • Inside-out technique • Arthroscopy • Meniscus Arrow • Anterior cruciate ligament

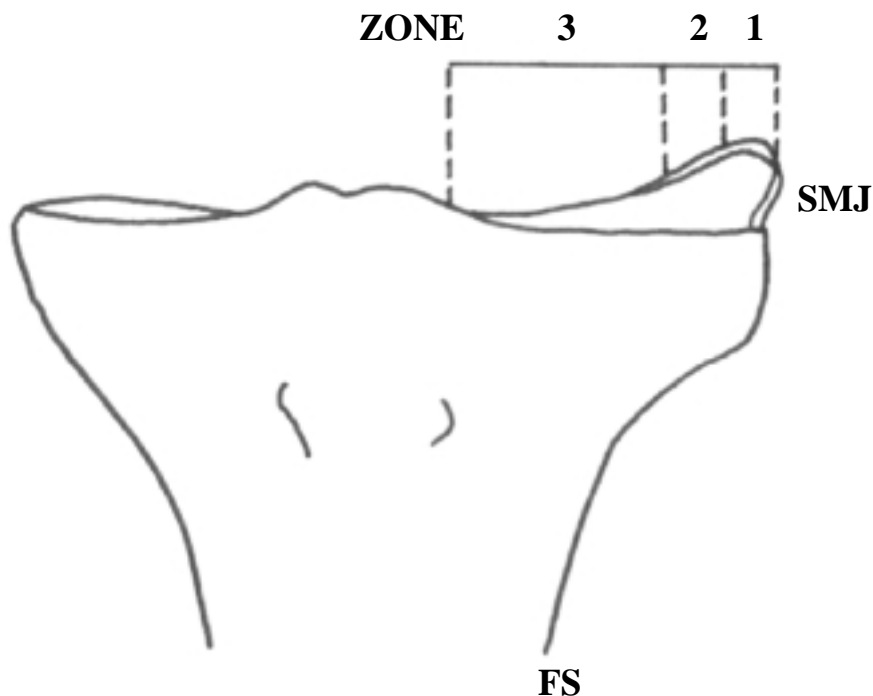
## Introduction

Meniscal tears are the most common intra-articular knee injuries, comprising 75% or more of all internal derangements of the knee [18]. Although initially reported by Annandale in 1885 [4], meniscus repair did not receive wide-spread attention and acceptance until the past two decades. This attention has been the result of increasing awareness of the functional significance of normal menisci, documentation of the consequences of meniscus loss, increasing awareness of the healing potential of certain meniscus tears, and the development of reliable open and arthroscopic repair techniques. During the past decade increasing understanding of the histological, biological, and functional significance of the menisci has led to a more conservative therapeutic approach to lesions of the meniscus [22]. Today's selective approach includes nonoperative treatment of meniscal tears, partial meniscectomy, and meniscal repair as alternatives to routine meniscectomy. Long-term follow-up of meniscal repair procedures is important to ascertain that repaired menisci survive, function effectively, and prevent the late degenerative changes seen after meniscectomy

[10,11]. Various arthroscopic techniques for meniscus repair, such as the inside-out or outside-in techniques, can be used. However, several complications including saphenous and common peroneal nerve injuries have been reported [10].

Initial fixation strength of the various repair techniques is also an important consideration. Experimental studies have demonstrated that vertical suture techniques are superior to horizontally oriented sutures, regardless of the type of suture material being used. Vertical sutures have been shown to be at least twice as strong as horizontal sutures [5,6]. In 1993 in an attempt to avoid neurovascular injuries and to shorten operating time, Albrecht-Olsen and Kristensen developed a new all-inside meniscal repair technique using absorbable tacks [1,2,3]. It consists of a T-shaped tack with barbs on the stem, resembling a fishing hook, and is made of totally absorbable self-reinforced polyactic acid (Biofix; Bioscience, Tampere, Finland), which is a highly biocompatible and totally biodegradable substance in the human body. Experimental studies have shown that implant degradation time is up to 4 years in the body [7].

In this study we reviewed a consecutive series of arthroscopic meniscal repairs using an inside-out technique or an all-inside technique, comparing surgical technique, clinical outcomes, and complications in the two groups.



**Fig.1** Schematic drawing indicating the various zones of the meniscus. Zone 1 Tear within 3 mm of the synovial meniscal junction (*SMJ*), vascular area; zone 2 tear within 3–5 mm from the *SMJ*, variable vascularity; zone 3 tear 5 mm or more from the *SMJ*,

## Materials and methods

### Materials

Fifty-five consecutive operations for the treatment of meniscal rupture were performed by the senior author (R.V.) between 1985 and 1995. Between June 1985 and June 1990 such repairs were carried out with an inside-out technique; between October 1994 and August 1995 an all-inside technique was used. Forty-five patients were left in the study – otherwise healthy, athletic persons (27 men, 18 women). All of the patients returned for the evaluation, at a mean of 84 months (66–102 months). The patients were divided into two groups according to the technique that had been used.

### Methods

History, physical examination, and preoperative computed tomography were used to identify ligamentous or meniscal injury in all patients [8,15,21]. The presence of a meniscal lesion was confirmed in all patients at the time of intervention. Each patient was questioned regarding pain, swelling, symptoms of giving-way, and in an attempt to establish the functional level his or her ability to return to sports or work. The knee was examined for an effusion, soft tissue swelling, joint line tenderness, intra-articular crepitus, and ability to squat. McMurray's test [19] was also performed. Muscle power, thigh circumference and range of knee motion were measured and compared to those of the contralateral extremity. A modification of the Hospital for Special Surgery (HSS) knee rating system [19] was used for evaluation. Patients were assigned to either excellent, good, fair, or poor groups based on their HSS score.

Patients in group were managed by an inside-out technique (11 men, 9 women; mean age at the time of follow-up 33 years, 6 months, range 15–57 years, 2 months). There 17 medial meniscus and 3 lateral meniscus repairs. The mean follow-up period was 13 years, 2 months (range 11 years 11 months–15 years 4 months).

Ten left and ten right knees were involved. Seven patients sustained an anterior cruciate ligament (ACL) injury, of which only one was reconstructed 6 years after meniscal repair.

Group 2 originally was composed of 35 consecutive patients in whom the all-inside Biofix arrow fixation technique had been used [15]; ten patients were lost to follow-up, and thus the group included 25 patients (16 men, 9 women; mean age at the time of follow-up 37 years, 6 months, range 19–63 years). There were 23 medial meniscus and 2 lateral meniscus repairs. They were evaluated at an average of 6 years, 5 months after their operation (range 6 years–6 years, 10 months). The group included 14 right and 11 left knees.

Nine patients had an ACL injury, of which four were reconstructed at the time of meniscus repair and 2 after 5 months.

The location and the extent of the tear were described by zones (1, 2, and 3) based on the distance from the synovial meniscal junction (SMJ) and the length of the tear; length 1, 0–3 mm long; length 2, 4–6 mm; and length 3, more than 6 mm (Fig. 1). In group 1 there were 7 patients with a tear 0–3 mm long, 8 between 3 and 6 mm, and 5 longer than 6 mm. There were 5 tears located in the red-red zone, 14 in the red-white, and 1 in the white-white (Table 1).

Group 2 included 6 patients with a tear 0–3 mm long, 11 between 3 and 6 mm, and 8 longer than 6 mm. Ten tears were located in the red-red zone, 14 in the red-white zone, and 1 was in the white-white zone (Table 2). In both groups all tears were symptomatic.

We used the hooked palpator with markings to make the measurements. The association between



the grouping and explanatory variables was analyzed using the  $\chi^2$  test (or Fisher's exact test in 2x2 tables) for numerical data. The level of statistical significance was set at  $\alpha=0.05$ .

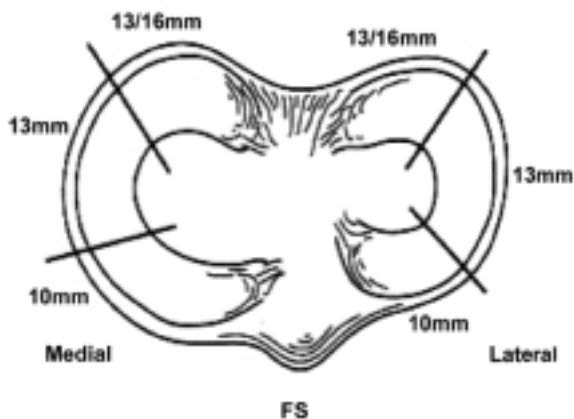
## Techniques

Twenty patients (group 1) underwent an arthroscopic meniscal repair using an inside-out technique as described by Cannon and Morgan [9]. We used absorbable sutures with double-barreled tapered Keith needles that were custom-bent at surgery and inserted through a long, straight or curved cannula using a needle holder.

Posteromedial and posterolateral cutaneous incisions and a popliteal retractor were routinely used to protect and retract neurovascular structures where the needles penetrated the posterior capsule as the sutures were tied over the capsule. During the procedure the body of the meniscus and the peripheral rim were meticulously prepared.

This included excision of any loose or unstable meniscal fragments or tags and rasping of both sides of the tear site. A thorough rasping of the parameniscal synovium in both the meniscofemoral and meniscotibial regions was performed for the red-red tears. The sutures were placed at intervals of 3–4 mm.

The Biofix implant (group 2) provides a horizontal fixation and has been designed to create optimal fixation of the meniscus. A specially designed instrument set allows repair through standard arthroscopy portals and consists of six cannulas with various curves, an obturator, a needle, perforator, pusher, and hammer. After the rupture had been freshened and reduced, the chosen cannula with the blunt obturator inside was inserted through the portals. After withdrawal of the obturator the cannula was fixed 3–4 mm from the lesion, and the meniscus was kept reduced. With a special perforator, a hole for the arrow was made through the meniscus into the joint capsule. The irrigation was turned off, and the perforator was retracted. A tack was pushed into the cannula with the pusher and hammered into the meniscus. A special reciprocating instrument can be used for this procedure. Every 5–10 mm a new tack was inserted until the rupture was stable. The implants used had a diameter of 1.1 mm and were available in three lengths (10, 13, and 16 mm) for different localizations of the meniscal lesions (Fig. 2).



**Fig. 2** Choice of appropriate arrow length for specific zones

The aftercare in both groups included a 3-week period of maximum protection to provide the best opportunity for healing to occur. The patients were allowed to mobilize immediately. During these 3 weeks only touch weight bearing was permitted. This was followed by a period of continuing protection from heavy stresses during maturation of the repair tissue until 3 months after surgery. During this time efforts were focused on regaining a full range of motion, excellent muscle strength, flexibility, and endurance. The patients were cautioned not to squat down on the operated knee, and they were advised not to undertake any running (not even in a straight line) or agility activities. After 3 months a gradual return to full-speed running, agility, and unrestricted activities was encouraged as desired and tolerated.

**Table 1** Patient distribution in group 1 (R-R red-red, R-W red-white, W-W white-white, acute injury to repair period shorter than 2 weeks, chronic injury to repair period longer than 2 weeks)

Patient no.	Age (years, months)	Sex	Side	ACL	Extent of tear (mm)	Location of tear	Acute-chronic
1	42,5	M	R	–	4–6	R-R	Acute
2	37,2	M	L	–	>6	R-W	Acute
3	34,1	M	R	Rupt	0–3	R-W	Chronic
4	41,9	M	L	–	4–6	R-W	Chronic
5	44,6	M	L	–	4–6	R-W	Acute
6	50,2	M	L	–	>6	W-W	Chronic
7	48,1	M	R	Rupt <sup>a</sup>	0–3	R-W	Acute
8	31,10	M	L	Rupt	4–6	R-W	Chronic
9	35,1	M	R	Rupt	0–3	R-W	Acute
10	38,0	M	R	–	4–6	R-W	Chronic
11	37,10	M	L	Rupt(repaired)	0–3	R-R	Acute
12	31,1	F	R	–	0–3	R-W	Chronic
13	29,6	F	L	Rupt	>6	R-W	Chronic
14	32,9	F	R	–	4–6	R-W	Acute
15	34,6	F	L	–	4–6	R-W	Chronic
16	31,10	F	R	Rupt	>6	R-R	Acute
17	44,10	F	R	–	4–6	R-W	Chronic
18	33,0	F	R	–	0–3	R-R	Acute
19	36,4	F	L	–	>6	R-W	Chronic
20	37,10	F	L	–	0–3	R-R	Acute

<sup>a</sup>ACL rupture repaired after 6 years

**Table 2** Patient distribution in group 2 (*R-R* red-red, *R-W* red-white, *W-W* white-white, acute injury to repair period shorter than 2 weeks, chronic injury to repair period longer than 2 weeks)

Pat,ient no.	Age (years, months)	Sex	Side	ACL	Extent of tear (mm)	Location of tear	Acute-chronic
1	45,5	M	R	–	4–6	R-R	Chronic
2	27,4	M	L	Rupt	0–3	R-W	Acute
3	34,1	M	R	–	>6	R-W	Chronic
4	40,9	M	L	–	4–6	R-R	Chronic
5	44,6	M	L	–	>6	R-R	Chronic
6	50,2	M	L	Repaired	0–3	R-W	Chronic
7	63,0	M	R	–	4–6	R-W	Chronic
8	31,10	M	L	–	>6	R-R	Acute
9	35,1	M	R	Rupt	0–3	R-W	Chronic
10	38,0	M	R	Repaired	4–6	R-R	Chronic
11	37,10	M	L	–	4–6	R-W	Chronic
12	41,6	M	R	–	4–6	W-W	Chronic
13	19,0	M	L	–	4–6	R-W	Acute
14	32,9	M	R	Repaired	>6	R-W	Chronic
15	34,6	M	L	Rupt	0–3	R-R	Acute
16	31,10	M	R	–	4–6	R-W	Chronic
17	44,10	F	R	–	0–3	R-R	Chronic
18	33,0	F	R	–	>6	R-W	Chronic
19	46,4	F	L	Repaired	0–3	R-R	Acute
20	37,10	F	L	–	0–3	R-W	Chronic
21	25,8	F	R	Repaired	>6	R-W	Chronic
22	37,10	F	L	–	4–6	R-R	Chronic
23	33,6	F	R	–	4–6	R-W	Chronic
24	31,1	F	R	Repaired	>6	R-R	Acute
25	22,10	F	R	–	4–6	R-W	Chronic

**Table 3** Results at 13 years' follow--up. Score based on modified Hospital for Special Surgery Knee Rating Scale (R-R red-red, R-W red-white, W-W white-white, acute injury to repair period shorter than 2 weeks, chronic injury to repair period longer than 2 weeks)

Patient no.	Sex	ACL	Extent of tear	Location of tear	Acute-chronic	Score
1	M	–	4–6	R-R	Acute	Excellent
2	M	–	>6	R-W	Acute	Good
3	M	Rupt	0–3	R-W	Chronic	Fair
4	M	–	4–6	R-W	Chronic	Good
5	M	–	4–6	R-W	Acute	Excellent
6	M	–	>6	W-W	Chronic	Good
7	M	Rupt	0–3	R-W	Acute	Good
8	M	Rupt	4–6	R-W	Chronic	Good
9	M	Rupt	0–3	R-W	Acute	Good
10	M	–	4–6	R-W	Chronic	Fair
11	M	Rupt	0–3	R-R	Acute	Good
12	F	–	0–3	R-W	Chronic	Excellent
13	F	Rupt	>6	R-W	Chronic	Fair
14	F	–	4–6	R-W	Acute	Good
15	F	–	4–6	R-W	Chronic	Good
16	F	Rupt	>6	R-R	Acute	Good
17	F	–	4–6	R-W	Chronic	Good
18	F	–	0–3	R-R	Acute	Good
19	F	–	>6	R-W	Chronic	Good
20	F	–	0–3	R-R	Acute	Excellent

**Table 4** Patient distribution in group 1 (R-R red-red, R-W red-white, W-W white-white, acute injury to repair period shorter than 2 weeks, chronic injury to repair period longer than 2 weeks)

Patient no.	Sex	ACL	Extent of tear	Location of tear	Acute-chronic	Score
1	M	–	4–6	R-R	Chronic	Excellent
2	M	Rupt	0–3	R-W	Acute	Poor
3	M	→	6	R-W	Chronic	Excellent
4	M	–	4–6	R-R	Chronic	Good
5	M	–	>6	R-R	Chronic	Excellent
6	M	Repaired	0–3	R-W	Chronic	Excellent
7	M	–	4–6	R-W	Chronic	Good
8	M	–	>6	R-R	Acute	Excellent
9	M	Rupt	0–3	R-W	Chronic	Excellent
10	M	Repaired	4–6	R-R	Chronic	Good
11	M	–	4–6	R-W	Chronic	Poor
12	M	–	4–6	W-W	Chronic	Good
13	M	–	4–6	R-W	Acute	Excellent
14	M	Repaired	>6	R-W	Chronic	Good
15	M	Rupt	0–3	R-R	Acute	Excellent
16	M	–	4–6	R-W	Chronic	Excellent
17	F	–	0–3	R-R	Chronic	Good
18	F	–	>6	R-W	Chronic	Poor
19	F	Repaired	0–3	R-R	Acute	Excellent
20	F	–	0–3	R-W	Chronic	Excellent
21	F	Repaired	>6	R-W	Chronic	Good
22	F	–	4–6	R-R	Chronic	Good
23	F	–	4–6	R-W	Chronic	Excellent
24	F	Repaired	>6	R-R	Acute	Good
25	F	–	4–6	R-W	Chronic	Excellent

All acute tears (injury to repair <2 weeks) and 80% of chronic tears (injury to repair >2 weeks) had good to excellent results. The three patients in the fair group had a chronic tear. Approximately 25% of tears fell within 0–3 mm of SMJ (zone 1) in both groups. All zone 1 tear repairs and 80% of zone 2 tear repairs had good to excellent results. Only 1 zone 3 tear (>6 mm from the SMJ) was repaired in group 1. This patient scored a good result. In group 2 the patient with the zone 3 tear kept on complaining of pain and joint effusion. He underwent a repeat arthroscopy at 1-year follow-up, and nonunion was found.

A partial meniscectomy was then performed. All patients in both groups with a tear between 0–3 mm in length had a good to excellent result. In group 2 two patients with tears of 3–6 mm had poor results. Two patients with a tear longer than 6 mm had a fair result (group 1). All other patients had good to excellent results. Of the 45 patients at follow-up 16 demonstrated an associated ACL injury initially. Four were reconstructed at the time of meniscus repair (group 2) and two after 5 months (group 2). One was reconstructed 6 years after the initial operation (group 1). Three patients in group 2 and 6 patients in group 1 were left with an unreconstructed ACL. Two of these six patients in group 1 had a fair result. The other four had good to excellent results. In group 2 all patients with repaired ACL had good to excellent results. One patient with an unreconstructed ACL had a poor result (Tables 3,4). As noted above, the results were compiled and classified in reference to many factors, which facilitates comparisons between the groups.

No statistical significant differences were found between the groups on any variables (Table 5).

**Table 5** Compilation and classification of the number of patients in reference to various factors

	Group 1	Group 2	<i>P</i> <sup>a</sup>
Sex: M/F	11/9	15/10	0.54
Length of tear			0.88
0–3 mm	7	7	
4–6 mm	8	11	
>6 mm	5	7	
Location of tear			0.56
Red-red	5	9	
Red-white	13	14	
White-white	1	1	
Acute-chronic			0.07
Acute	10	6	
Chronic	10	19	
ACL			0.036
Ruptured	6	3	
Repaired	1	9	
Score			0.01
Excellent	4	13	
Good <sup>b</sup>	13	9	
Fair	3	0	
Poor	0	3	

<sup>a</sup> $\alpha = 0.05$ ,  $\chi^2$  or Fisher's exact test (in 2x2 tables)

<sup>b</sup>One patient had an ACL tear repaired at 6 years' follow-up and was scored as a good result

## Discussion

Meniscus tears suitable for repair with a great chance of success are traumatic ruptures within the vascular zone in which the peripheral circumferential fibers remain intact and damage to the meniscus body is minimal. The most common tear types that fit these criteria are peripheral, or nearly peripheral, vertical, longitudinal tears. Patients with other types of tears which are clearly in the avascular zone or where the vascularity is doubtful must be considered questionable candidates for repair. Many factors influence the results of meniscus repair. These include the age and sex of the patient, the chronicity of the tear from the time of injury, and the location of the tear. The results of medial or lateral meniscus repair depend on the location of the tear as related to the distance from the SMJ, length of the tear, stability of the ACL, vascularity, and cooperation of the patient. In our study chronicity of the tear seemed to affect the percentage of satisfactory results. All the menisci repaired within 2 weeks of injury had a good to excellent result. This difference, however, was not statistically significant. Two zone 3 tears were repaired, and one of these scored a good result. Rubman et al. [17] and Noyes and Barber-Westin [16] recommend arthroscopic repair for meniscal tears extending into the avascular zone in select cases. The 20% reoperation rate in their study should not be interpreted as the rate of meniscal healing but as the incidence of tibiofemoral joint symptoms. Sixteen patients sustained an ACL injury, seven of which were reconstructed. Nine were left untreated. Five had good to excellent results, and two fair results. Hanks et al. [14] reported meniscus repair in the ACL-deficient knee. They had a 13% failure rate. They concluded that even though the failure rate may be higher in an unstable knee, meniscus repair was not contraindicated in an ACL-deficient knee.

Inside-out and outside-in techniques are encumbered with several complications, including popliteal artery injuries and saphenous and common peroneal nerve damage.

To reduce the risk of neurovascular complications and simplify meniscal repair an all-inside technique using resorbable implants has been proposed by Albrecht-Olsen et al. [1,2,3]. They reported that the operating time is half as long as with other techniques, and that the healing rate is significantly higher in the Biofix arrow group. However, they also reported soft tissue and nerve irritation problems [1,2,3]. It might be possible to reduce such complications by choosing the zone specific arrow length. The current arrows are made in three lengths: 10, 13, and 16 mm.

The 13- and 16-mm arrows are used in the most posterior parts of the meniscus. For the anterior one-third 10-mm arrows are recommended, and for the middle one-third 13-mm arrows. Albrecht-Olsen et al. [1] reported that repair with Biofix arrows has approximately the same failure strength as a horizontal suture loop. Pull-out strengths of vertical loop suture techniques and the Biofix arrow method have also been compared by Dervin et al. [12].

They found that the main failure load of the vertical loop is superior to the meniscus arrow, and they suggest modifications to the implant design to achieve better fixation.

There were no significant differences between the groups concerning complications or repeat arthroscopies or secondary meniscectomies. Neither the age of the patient nor the length or extent of the tear seemed to affect the result of meniscal repair.

We believe that in clinically asymptomatic patients the meniscus is either histologically healed or acts as an auto-graft and fulfills the biomechanical tasks of an injured meniscus. Long-term studies evaluating the development of arthrosis in patients with clinically healed meniscal tears after arthroscopic repair may provide more evidence to support this hypothesis [13]. This was a retrospective study, and both series were continuous and not simultaneous.

Our follow-up protocol did not include radiography. Degenerative changes could therefore not be detected.

## Conclusion

Our current protocol for the repair of meniscal tears relies on several technical details that the authors consider to be essential for the successful repair of simple and complex meniscal tears. A careful examination is required to determine the integrity of the meniscal tissue and assess chronic changes, such as deformation and degeneration. The meniscus must contain a reducible tear with good tissue integrity that maintains its position in the joint once repaired. Degenerative, poor-quality meniscal tissue is not strong enough to hold the sutures and should not be considered for repair. Stable fixation of the meniscal tear decreases the possibility of motion between the meniscal fragments and allows a postoperative rehabilitation program that emphasizes early motion and weight bearing. Multiple, nonabsorbable sutures in both the superior and inferior surfaces of the meniscus are placed every 3–4 mm to ensure the repair is held in position to allow healing to occur. A recent report of the results of repair of longitudinal meniscal tears evaluated arthroscopically found that no tear with a rim width of greater than 4 mm healed [20]. The sutures in that study were placed at least 4 mm apart. It is the senior author's opinion that complex tear patterns and meniscal tears in the central region are subjected to higher stresses than those incurred in single longitudinal tears located in the periphery and therefore require sutures to be placed at closer intervals. Because the location of the tear within the meniscus is not a primary consideration for which tears are amenable to repair, we no longer measure the rim width at the time of repair. All tears that undergo repair, regardless of pattern or location, are held in place with multiple sutures placed at intervals of 3–4 mm. Partial meniscectomy for complex tear patterns or tears that extend into the avascular zone requires removal of a large portion of the meniscus, and they may render it nonfunctional.

We detected no major differences in the clinical out-come between our two study groups. The advantages of the all-inside technique include short operating time, superfluous capsular exposure, easier technique, and potentially lower risk of neurovascular lesions, especially when posterior horns are involved. However, the cost of the implant is much higher than that of previous methods.

**Acknowledgements** The statistical analysis was carried out by Prof. Dr. G. Van Maele, Department of Medical Statistics, University Hospital Ghent, Belgium. All experiments complied with current laws in Belgium.

## References

1. Albrecht-Olsen P, Kristensen G, Törmälä P (1993) Meniscus bucket-handle fixation with an absorbable Biofix tack: development of a new technique. *Knee Surg Sports Traumatol Arthrosc* 1: 104–106
2. Albrecht-Olsen P, Lind T, Kristensen G, Falkenberg B (1997) Failure strength of a new meniscus arrow repair technique: biomechanical comparison with horizontal suture. *Arthroscopy* 2: 183–187
3. Albrecht-Olsen P, Kristensen G, Burgaard P, Joergensen U, Toerholm C (1999) The arrow versus horizontal suture in arthroscopic meniscus repair. A prospective randomized study with arthroscopic evaluation. *Knee Surg Sports Traumatol Arthrosc* 7: 268–273
4. Annandale T (1885) An operation for displaced semilunar cartilage. *BMJ* 1: 799



5. Asik M, Sener N (2002) Failure strength of repair devices versus meniscus suturing techniques. *Knee Surg Sports Traumatol Arthroscop* 10: 25–29
6. Borden P, Nyland J, Caborn DN, Pienkowski D (2003) Biomechanical comparison of the Fas T-Fix meniscal repair suture system with vertical mattress sutures and meniscus arrows *Am J Sports Med* 31: 374–378
7. Bos RRM, Boering G, Rozema FR, Leenslag JW (1987) Resorbable poly (L-lactide) plates and screws for the fixation of zygomatic fractures. *J Oral Maxillofac Surg* 45: 751–753
8. Bronstein R, Kirk P, Hurley J (1992) The usefulness of MRI in evaluating menisci after repair. *Orthopedics* 15: 149–152
9. Cannon WD, Morgan CD (1994) Meniscal repair. *J Bone Joint Surg Am* 76: 294–311
10. De Haven KE (1999) Meniscus repair: current concepts. *Am J Sports Med* 27: 242–250
11. De Haven KE, Lohrer WA, Lovelock JE (1995) Long-term results of open meniscus repair. *Am J Sports Med* 23: 524–530
12. Dervin GF, Downing BE, Kenée CR, McBride DG (1997) Failure strengths of suture versus biodegradable arrow for meniscus repair: an in vitro study. *Arthroscopy* 13: 296–300
13. Egli S, Wegmüller H, Kosina J (1995) Long-term results of arthroscopic meniscal repair: an analysis of isolated tears. *Am J Sports Med* 23: 715–720
14. Hanks GA, Trenton MG, Handal JA (1990) Meniscus repair in the anterior cruciate deficient knee. *Am J Sports Med* 18: 606–613
15. Hürel C, Mertens F, Verdonk R (2000) Biofix resorbable meniscus arrow for meniscal ruptures: results of a 1-year follow-up. *Knee Surg Sports Traumatol Arthrosc* 8: 46–52
16. Noyes FR, Barber-Westin SD (2002) Arthroscopic repair of meniscal tears extending into the avascular zone in patients younger than twenty years of age. *Am J Sports Med* 30: 589–600
17. Rubman MR, Noyes FR, Barber-Westin SD (1998) Arthroscopic repair of meniscal tears that extend into the avascular zone: a review of 198 single and complex tears. *Am J Sports Med* 26: 87–95
18. Shands AR, Hutchinson JL, Ziv L (1936) Derangements of the semilunar cartilages of the knee: a clinical and experimental study. *South Med J* 29: 1045–1050
19. Stone RG, Frewin PR, Gonzales S (1990) Long-term assessment of arthroscopic meniscus repair: a two-to six-year follow-up study. *Arthroscopy* 6: 73–78
20. Tenuta JJ, Arciero RA (1994) Arthroscopic evaluation of meniscal repairs. Factors that effect healing. *Am J Sports Med* 22: 797–802
21. Verdonk R, Meire D, Van De Velde C, Van Eetvelde G, Claessens H (1991) CT scan of the knee: correlation with clinical and arthroscopic findings. *Acta Orthop Belg* 57: 49–55
22. Yasunaga T, Kimura M, Kikuchi S (2001) Histologic change of the meniscus and cartilage tissue after meniscal suture. *Clin Orthop* 387: 232–240

# Arthroscopic meniscus repair in the ACL-deficient knee

F. Steenbrugge • W. Van Nieuwenhuyse • R. Verdonk • K. Verstraete

Received: 17 October 2004 / Accepted: 26 October 2004 / Published online: 5 February 2005

© Springer-Verlag 2005

**Abstract** Between 1985 and 1995, 45 patients underwent closed meniscus repair. There were 30 men and 15 women with a mean age of 32.5 years. In 23 patients, the anterior cruciate ligament was intact (group 1) whereas it was deficient in 22 patients (group 2). All patients were managed with the same postoperative program of partial weight bearing, immediate motion and rehabilitation of the knee.

Five patients had a failed meniscal repair and underwent a repeat arthroscopy and a partial meniscectomy. These patients were considered as failures and excluded from the final scoring. After a mean follow-up of more than 9 years, all patients were subjected to a clinical examination using the Hospital for Special Surgery (HSS) knee rating system.

Seven patients in group 2 had episodes of frequent giving way and had their anterior cruciate ligament (ACL) reconstructed 6 and 7 years after the initial meniscus repair.

None of the other patients had any clinical symptoms or signs of a meniscal tear. In group 1, 20 patients and in group 2, 14 patients, all had a satisfactory knee score. Even though the failure rate of meniscus repair may be greater in an unstable knee, it is concluded that meniscal repair is not contraindicated in a knee with a deficient ACL.

**Résumé** Entre 1985 et 1995 45 malades ont eu une réparation méniscale à foyer fermé. Il y avait 30 hommes et 15 femmes à l'âge moyen de 32,5 ans. Chez 23 malades le ligament croisé antérieur (LCA) était intact (Groupe 1), alors qu'il était défectueux chez 22 malades (Groupe 2).

Tous les malades ont eu le même programme postopératoire avec appui partiel, mobilisation immédiate et rééducation du genou. Cinq malades ont présentés un échec et ont subi une arthroscopie secondaire avec méniscectomie partielle.

Ces malades ont été considérés comme échecs et ont exclu du dernier marquage de points. Après une moyenne de suivi de plus de neuf ans tous les malades ont été soumis à un examen clinique qui utilise le score HSS pour l'estimation du genou. Sept malades du groupe 2 ont eu de fréquent épisodes de déroboement et ont eu leur LCA reconstruit 6 et 7 ans après la réparation du ménisque. Aucun des autres malades n'avait de symptôme clinique ou de signe d'une déchirure méniscale. Vingt malades du groupe 1 et 14 malades du groupe 2 avaient tous un score du genou satisfaisant. Bien que le taux d'échec de réparation du ménisque puisse être plus grand dans un genou instable, notre conclusion est que la réparation du ménisque n'est pas contre-indiquée sur un genou avec un LCA défectueux.

F. Steenbrugge (✉) • W. Van Nieuwenhuyse Department of Orthopaedic Surgery and Traumatology,  
ASZ Campus Aalst, Merestraat 80, 9300 Aalst, Belgium  
e-mail: Fsteenbr@belgacom.net Tel.: +32-5-3764914 Fax: +32-5-3764918

R. Verdonk Department of Orthopaedic Surgery and Traumatology, University Hospital, Ghent, Belgium

K. Verstraete Department of Radiology, University Hospital, Gent, Belgium

## Introduction

Meniscal tears are the most common knee injuries, comprising 75% or more of all internal derangements of the knee [2, 15]. Meniscus repair, however, did not receive widespread attention and acceptance until the last two decades [6, 14]. During the last decade, better understanding of the histological, biological and functional significance of the meniscus has led to a more conservative therapeutic approach to lesions of the meniscus [3]. Long-term follow-up of meniscal repair procedures is important to ascertain that repaired menisci will survive, function effectively and prevent late degenerative changes seen after meniscectomy [6, 16].

When meniscal tears occur in conjunction with anterior cruciate ligament (ACL) injuries, most authors, including us, advocate concurrent meniscal repair and repair or reconstruction of the torn ACL. However, some patients elect to have a meniscal repair without ACL reconstruction.

This study was undertaken to evaluate the results of meniscal repair in knees lacking a functional ACL and compare these results with those of meniscal repair in ACL-intact knees.

## Materials and methods

Between 1985 and 1995, 45 patients (45 knees) underwent meniscal repair by a closed arthroscopic technique. There were 30 men and 15 women with a mean age of 32.5 (17–55) years. In 23 patients (group 1), the knee had an intact ACL and in 22 patients (group 2), the knee was ACL-deficient.

At 5-years' follow-up, 20 patients also underwent an MRI investigation. In all patients, history, physical examination and preoperative CT scan were always used to identify ligamentous or meniscal injury [19]. A modification of the Hospital for Special Surgery (HSS) knee rating system [17] was used for evaluation. Based on their score, patients were assigned to excellent, good, fair, or poor results. The mean follow-up was 9 years 2 months (7 years 11 months to 13 years 4 months) for group 1 and 9 years 5 months (8 years to 13 years 10 months) for group 2. The location and the extent of the tear were described by zones based on the distance from the synovial meniscal junction (SMJ) and whether the tear length was smaller than 3 mm; from 4 to 6 mm or longer than 6 mm (more details see Tables 1 and 2). Approximately 45% of tears fell within 0–3 mm of the SMJ in both groups.

Ten patients in each group underwent an arthroscopic meniscal repair using an inside-out technique as described by Cannon [1] whereas in the remaining, an all-inside technique was used. For the red-red (R-R) tear, a rasping of the parameniscal synovium in both meniscofemoral and meniscotibial regions was performed and sutures placed at 3- to 4-mm intervals. The Biofix suture device was used in 13 patients in group 1 and in 12 patients in group 2.

After the rupture had been freshened and reduced, the chosen cannula with the blunt obturator inside was inserted through the portals. Every 5–10 mm, a new tack was inserted until the rupture was stable.

In both groups, aftercare included a 3-week period of maximum protection where only touch weight bearing was permitted. This was followed by a period of continuing protection from heavy stresses until 3 months after surgery.

Hereafter, a gradual return to full-speed running, agility and unrestricted activities was encouraged as desired and tolerated.

**Table 1** Patient characteristics and results in group 1 with intact anterior cruciate ligament (ACL). *R-R* red-red zone, *R-W* red-white zone, *W-W* white-white zone, Acute injury-to-repair interval <2 weeks, chronic injury-to-repair interval >2 weeks, *I-O* inside-out, *A-I* all-inside

Patient	Age (yaers/ months)	Gender	Side	Extent of tear	Zone of Location	Acute/ chronic	Suture	Score <sup>a</sup>
1	44y 6m	M	L	>6 mm	R-W	Acute	I-O	Excellent
2	45y 5m	M	L	0-3 mm	R-R	Chronic	A-I	Good
3	34y 1m	M	R	>6 mm	R-W	Chronic	A-I	Excellent
4	40y 9m	M	L	4-6 mm	R-R	Chronic	A-I	Good
5	44y 6m	M	L	0-3 mm	R-R	Acute	A-I	Good
6	38y	M	R	4-6 mm	R-W	Chronic	I-O	Good
7	63y	M	R	4-6 mm	R-W	Chronic	A-I	Fair
8	31y 10m	M	L	>6 mm	R-R	Acute	A-I	Excellent
9	37y 10m	M	L	4-6 mm	R-W	Chronic	A-I	Good
10	41y 6m	M	R	4-6 mm	W-W	Acute	I-O	Failure
11	19y	M	L	4-6 mm	R-R	Acute	A-I	Good
12	31y 10m	M	R	4-6 mm	R-W	Chronic	I-O	Good
13	44y 10m	M	R	0-3 mm	R-R	Acute	A-I	Good
14	33y	M	R	>6 mm	R-W	Chronic	A-I	Excellent
15	37y 10m	M	L	0-3 mm	R-R	Acute	I-O	Good
16	37y 10m	M	L	>6 mm	R-W	Chronic	A-I	Fair
17	33y 6m	M	R	>6 mm	R-W	Chronic	A-I	Excellent
18	22y 10m	F	R	4-6 mm	R-W	Chronic	A-I	Good
19	35y 6m	F	L	>6 mm	R-R	Acute	I-O	Excellent
20	31y 1m	F	R	0-3 mm	R-W	Chronic	I-O	Good
21	32y 9m	F	R	4-6 mm	R-R	Acute	I-O	Good
22	34y 6m	F	L	>6 mm	R-R	Chronic	I-O	Good
23	44y 10m	F	R	0-3 mm	R-W	Acute	I-O	Good

<sup>a</sup>Score based on Modification of Hospital for Special Surgery (HSS) knee rating scale

**Table 2** Patient characteristics and results in group 2 with deficient anterior cruciate ligament (ACL). R-R red-red zone, R-W red-white zone, W-W white-white zone, Acute injury-to-repair interval <2 weeks, chronic injury-to-repair interval >2 weeks, I-O inside-out, A-I all-inside

Patient	Age	Gender	Side	Extent	Zone of location	Acute/ chronic	Suture	Score <sup>a</sup>	ACL
1	27y 4m	M	L	4-6 mm	R-R	Acute	I-O	Excellent	Reconstructed
2	50y 2m	M	L	>6 mm	W-W	Chronic	I-O	Failure	
3	48y 1m	M	R	0-3 mm	R-W	Acute	A-I	Excellent	
4	31y 10m	M	L	4-6 mm	R-W	Chronic	A-I	Good	
5	35y 1m	M	R	0-3 mm	R-W	Acute	A-I	Good	Reconstructed
6	29y 6m	M	L	0-3 mm	R-R	Acute	I-O	Excellent	
7	37y 10m	M	L	4-6 mm	R-W	Chronic	I-O	Poor	
8	31y 4m	M	R	>6 mm	R-W	Chronic	I-O	Good	
9	29y 6m	M	L	>6 mm	R-W	Chronic	A-I	Fair	
10	69y 5m	M	R	4-6 mm	R-R	Acute	I-O	Failure	Reconstructed
11	34y 6m	M	L	4-6 mm	R-R	Acute	A-I	Good	Reconstructed
12	31y 10m	M	R	>6 mm	R-W	Chronic	I-O	Fair	
13	27y 6m	M	L	4-6 mm	R-W	Chronic	A-I	Good	Reconstructed
14	50y 2m	F	L	>6 mm	R-W	Chronic	A-I	Fair	
15	35y 1m	F	L	0-3 mm	R-R	Acute	A-I	Excellent	
16	38y	F	R	4-6 mm	R-R	Acute	I-O	Good	Reconstructed
17	32y 9m	F	R	>6 mm	R-W	Chronic	A-I	Good	
18	34y 6m	F	L	>6 mm	R-R	Acute	A-I	Failure	Reconstructed
19	46y 4m	F	L	0-3 mm	R-R	Chronic	I-O	Good	
20	25y 8m	F	R	>6 mm	R-W	Acute	A-I	Excellent	
21	31y 1m	F	L	4-6 mm	R-R	Chronic	I-O	Failure	Reconstructed
22	22y 10m	F	R	>6 mm	R-R	Acute	A-I	Good	

<sup>a</sup>Score based on Modification of Hospital for Special Surgery (HSS) knee rating scale

## Results

In each group, there was one superficial infection and in group 1 a patient with neurapraxia of the saphenous nerve.

In group 2, one patient showed persistent hemarthrosis during the first postoperative month, which regressed spontaneously.

Irritation from the Biofix implant was observed in two cases of which one (group 1) had a repeat arthroscopy. Five patients had a secondary meniscectomy, one in group 1 and four in group 2, and were excluded from the rating of the final result. Seven patients in group 2 had episodes of frequent giving way and had their ACL reconstructed 6 and 7 years after the initial meniscal repair. In group 1, six patients were rated as excellent, 14 as good and two as fair. There were no poor results. In group 2, six patients had an excellent result, eight a good result, two a fair result and two patients were rated as poor. If ratings of excellent and good were considered as satisfactory, there were 20 satisfactory in group 1 and 14 satisfactory in group 2. Age did not affect the outcome, nor did gender. All acute tears (interval from injury to repair less than 2 weeks) had good-to-excellent results. All repairs of tears in the R-R zone and 80% of all in the red-white (R-W) zone had good-to-excellent results. Only one white-white (W-W) zone tear (>6 mm from the SMJ) was repaired in group 1. This patient underwent a secondary meniscectomy and was excluded from the final evaluation. In group 2, the patient with the W-W zone tear also had a repeat arthroscopy at 1 year follow-up, and a partial meniscectomy was performed due to non-union. In both groups patients with a tear between 0 and 3 mm in length had good-to-excellent results.

Ten patients in each group had an MR examination at 5 years' follow-up. Sagittal proton-density and T2-weighted images followed by 2-mm coronal 3D gradient echo images and 4-mm axial T1-weighted images and 3-mm sagittal T2-weighted images were obtained. In all patients, the site of the previous suture could still be detected, mainly by the small micrometal artefacts in the meniscus evident on the gradient echo images. In one patient, a new tear was found. In five patients (three in group 1, two in group 2), hyperintense areas were found in the meniscus.

Four patients (group 2) clearly showed an early onset of arthritis and cartilage degeneration (grade 3), and two (group 1) showed minor signs of cartilage degeneration (grade 1) [9, 11]. The patients with grade 3 lesions had good-to-excellent functional results.

## Discussion

Ideally, in a knee in which there is both an ACL tear and a repairable meniscal tear, the former should be reconstructed and the latter repaired [4, 7, 8]. However, for various reasons, some patients elect not to undergo a ligament reconstruction. In our study, chronicity of the tear was found to affect the percentage of satisfactory results. All menisci repaired within two weeks of injury had a good-to-excellent result.

Rubman and Noyes [13] recommend arthroscopic repair for meniscal tears extending into the avascular zone in select cases. The 20% reoperation rate in their study should not be interpreted as the rate of meniscal healing but as the incidence of tibiofemoral joint symptoms. In our study, both cases of meniscal tears in the W-W zone were due to suture failure.

Knee stability seems to affect the result of meniscal repair. In the current study there was a failure rate of 18% (4/22) in group 2 versus 5% (1/23) in group 1. Hanks et al. [8] reported a 13% failure rate of meniscal repair in the ACL-deficient knee. They concluded that even though the failure rate may be higher in an unstable knee, meniscal repair was not contraindicated in an ACL-deficient

knee. Roos et al. [12] concluded that osteoarthritis (OA) of the knee after injury to the ACL or meniscus became increasingly severe with an increase in time between joint injury and examination. The OA changes appeared sooner in older patients than in the younger. Also, in our study, the youngest patient showed only minor cartilage degeneration. Neither the age of the patient nor the length or extent of the tear seemed to affect the result of meniscal repair. We believe that in clinically asymptomatic patients, the meniscus is either healed or acts as an autograft and fulfills the biomechanical tasks of an uninjured meniscus.

Link et al. [9] concluded that cartilage lesions, bone marrow oedema pattern and meniscal and ligamentous lesions were frequently demonstrated on MRI in patients with advanced osteoarthritis. Clinical findings, however, showed no significant correlations with the Kellgren-Lawrence scale score and the extent of findings at MR imaging. Hanks et al. [8], Magee [10] and Totty [18] suggested that MRI may prove an ideal diagnostic tool in evaluating meniscal healing. The first studies using MRI after meniscal repair reported a persistent pathological signal after meniscal suture. The remaining question in these short-term studies was whether these mainly, grade 3 signals, represented persisting tears or increased water content of fresh scar tissue, which may eventually disappear. We found presence of mucoid degeneration or scar tissue in six of 20 patients after an average follow-up of more than nine years. Therefore, we believe that asymptomatic menisci produce abnormal MRI signals even though they have stable unions and that MRI signals at the site of repair represent oedematous scar tissue, not true nonunions. Eggli et al. found similar findings in their study [5].

Our current protocol for the repair of meniscal tears relies on several technical details that the authors consider to be essential for the successful repair of simple and complex meniscal tears. Degenerative, poor quality meniscal tissue is not strong enough to hold sutures and should not be considered for repair. Stable fixation of the meniscal tear decreases the possibility of motion between meniscal fragments and allows a postoperative rehabilitation program that emphasizes early motion and weight bearing. Because the location of the tear within the meniscus is not a primary consideration for which tears are amenable to repair, we no longer measure the rim width at the time of repair. All tears that undergo repair, regardless of pattern or location, are held in place with multiple, nonabsorbable sutures placed at 3- to 4-mm intervals. If meniscal repair is performed, the long-term data in our study show that at nine years after surgery, a majority of the patients will be asymptomatic.

## References

1. Cannon WD, Morgan CD (1994) Meniscal repair. *J Bone Joint Surg Am* 76:294–311
2. Dandy DJ, Jackson RW (1975) The diagnosis of problems after meniscectomy. *J Bone Joint Surg Br* 57:49–352
3. DeHaven KE (1999) Meniscus repair: current concepts. *Am J Sports Med* 27: 242–250
4. Dejour H, Walch G, Neyret P, Adeleine P (1988) Résultats des laxités chroniques antérieures opérées. A propos de 251 cas revus avec un recul minimum de 3 ans. *Rev Chir Orthop* 74: 622–636
5. Eggli S, Wegmüller H, Kosina J (1995) Long-term results of arthroscopic meniscal repair: an analysis of isolated tears. *Am J Sports Med* 23: 715–720

6. Englund M, Roos EM, Roos HP, Lohmander LS (2001) Patient-relevant outcomes fourteen years after meniscectomy: influence of type of meniscal tear and size of resection. *Rheumatology* 40: 631–639
7. Gacon G, Barba L, Lalain JJ, Laurençon M, Ray A (1992) Résultats à plus de dix ans de 54 plasties intra-articulaires du ligament croisé antérieur du genou. *Rev Chir Orthop* 78:130–131
8. Hanks GA, Trenton MG, Handal JA (1990) Meniscus repair in the anterior cruciate deficient knee. *Am J Sports Med* 18:606–613
9. Link TM, Steinbach LS, Ghosh S, Ries M, Lu Y, Lane N, Majumbar S (2003) Osteoarthritis: MR Imaging findings in different stages of disease and correlation with clinical findings. *Radiology* 226: 373–381
10. Magee T, Shapiro M, Rodriguez J, Williams D (2003) MR arthrography of postoperative knee: for which patients is it useful? *Radiology* 229: 159–163
11. Recht MP, Kramer J, Marcelis S (1993) Abnormalities of articular cartilage in the knee: analysis of available MR techniques. *Radiology* 187: 473–478
12. Roos H, Adalbrecht T, Dahlberg L, Lohmander LS (1995) Osteoarthritis of the knee after injury to the anterior cruciate ligament or meniscus: the influence of time and age. *Osteo-arthritis Cartilage* 3: 261–267
13. Rubman MR, Noyes FR, Barber-Westin SD (1998) Arthroscopic repair of meniscal tears that extend into the avascular zone: a review of 198 single and complex tears. *Am J Sports Med* 26:87–95
14. Saragaglia D, Rose-Pittet L, Lebas JF, Coulomb M, Butel J (1989) L'imagerie par résonance magnétique nucléaire dans l'exploration des lésions ménisco-ligamentaires du genou: 85 examens contrôlés par arthroscopie. *Rev Chir Orthop* 75:52–458
15. Shands AR, Hutchinson JL, Ziv L (1936) Derangements of the semilunar cartilages of the knee: A clinical and experimental study. *South Med J* 29:1045–1050
16. Steenbrugge F, Verdonk R, Verstraete K (2004) Magnetic resonance imaging of the surgically repaired meniscus: a 13-year follow-up study. *Acta Orthop Scand* 75:323–327
17. Stone RG, Frewin PR, Gonzales S (1990) Long-term assessment of arthroscopic meniscus repair: a two- to six-year follow-up study. *Arthroscopy* 6:73–78
18. Totty WG, Matava MJ (2000) Imaging the postoperative meniscus. *Magn Reson Imaging Clin N Am* 8:271–283
19. Verdonk R, Meire D, Van De Velde C, Van Eetvelde G, Claessens H (1991) CT scan of the knee: correlation with clinical and arthroscopic findings. *Acta Orthop Belg* 57:49–55



# Magnetic resonance imaging of the surgically repaired meniscus A 13-year follow-up study of 13 knees

Franky Steenbrugge<sup>1</sup>, Koenraad Verstraete<sup>2</sup> and René Verdonk<sup>3</sup>

Departments of 1 Orthopaedic Surgery, Algemeen Stedelijk Ziekenhuis, Campus Aalst, BE-9300 Aalst, Belgium,  
2 Radiology, 3 Orthopaedic  
Surgery, Ghent University Hospital, BE-9000 Ghent, Belgium  
Correspondence FS: fsteenbr@belgacom.net  
Submitted 03-01-24. Accepted 03-10-14

**Background** This study was initiated to evaluate the long-term outcome of meniscal sutures and to correlate clinical findings with MRI findings. We were interested to see if a clinically healed meniscus also showed as such on MRI and if degenerative changes were present. **Patients and methods** We studied prospectively 13 patients (7 men) aged between 29 and 50 years, who had undergone closed meniscus repair between 1985 and 1988 using an inside-out technique, clinically and with MRI, with a mean follow-up time of 13 years.

**Results** Meniscal suture gave good clinical long-term results: all patients got a Hospital for Special Surgery score of more than 75%. In all patients the site of the previous suture was still visible on MRI, mainly from small metal artefacts in the meniscus. 4 of 7 patients with an un-repaired ACL lesion had signs of arthrosis and cartilage degeneration. MRI showed signs of mucoid degeneration or scar tissue in 6/13 of the patients.

**Interpretation** We believe that asymptomatic meniscal tears produce abnormal MR signals even though they have stable unions, and that MR signals at the site of repair represent edematous scar tissue, not true nonunions.

Meniscal tears comprise 75% or more of all internal derangements of the knee (Shands et al. 1936). Although initially reported by Annandale in 1885, meniscus repair has not received widespread attention and acceptance until the last 2 decades, because of an awareness of the functional significance of normal menisci, documentation of the consequences of meniscus loss, increasing awareness of the healing potential of certain meniscus tears, and the development of reliable open and arthroscopic repair techniques (De Haven 1999).

Today's approach includes nonoperative treatment, partial meniscectomy, and meniscal repair as alternatives to routine meniscectomy. Long-term follow-up of meniscal repair procedures is important in order to ascertain that repaired menisci will survive, function effectively, and prevent the late degenerative changes seen after meniscectomy (Dandy and Jackson 1975, De Haven 1999). This is a long-term follow-up.

## *Patients*

Between 1985 and 1988, 20 consecutive arthroscopic meniscal repairs using an inside-out technique were performed on 20 knees of 20 patients.

13 patients returned for a clinical examination and MRI evaluation after 13 years of follow-up. The remaining 7 patients were interviewed by telephone. This study includes only those 13 patients who returned for a complete examination, including MRI evaluation.

### ***MRI technique***

All patients were examined with a sagittal fast spin-echo proton density and T2-weighted sequence (3 mm thickness), followed by a coronal mixed T1 and T2 weighted gradient-echo imaging technique (2 mm). For evaluation of cartilage, a sagittal T2\*-gradient-echo technique was performed (3 mm).

### ***Methods***

History, physical examination, and preoperative CT-scan were always used to identify ligamentous or meniscal injury in all patients (Verdonk et al. 1991). The presence of a meniscal lesion was confirmed in all patients at the time of intervention.

Each patient was questioned regarding pain, swelling, symptoms of giving-way and, in an attempt to establish the functional level, his or her ability to return to sports or work. The knee was examined for an effusion, soft tissue swelling, joint line tenderness, intraarticular crepitus, and ability to squat. McMurray's test (Stone et al. 1990) was also performed. Muscle power, thigh circumference and range of knee motion were measured and compared to those of the contralateral extremity.

A modification of the Hospital for Special Surgery (HSS) knee rating system (Stone et al. 1990) was used for evaluation. Patients were assigned to either excellent, good, fair, or poor groups based on their HSS score. The study population consisted of 13 otherwise healthy, athletic persons (7 men, 7 right knees) whose mean age was 35 (29–50) years at the time of follow-up. The follow-up averaged 13 (12–15) years. The location and the extent of the tear were described by zones (R-R (red), R-W (white) and W-W) based on the distance from the Synovial Meniscal Junction (SMJ) and the length of the tear: length 1, 0–3 mm long; length 2, 4–6 mm; and length 3, >6 mm. 4 patients had a tear between 0–3 mm in length, 6 patients between 3–6 mm and 3 patients had a tear of more than 6 mm. 2 tears were located in the red-red zone, 10 were in the red-white zone and 1 was in the white-white zone (Table). We used the hooked palpator with markings to make the measurements.

### ***Techniques***

20 patients underwent an arthroscopic meniscal repair using an inside-out technique as described by Henning (1983) and Cannon and Morgan (1994).

We used absorbable sutures with double-barrelled tapered Keith needles that were custom-bent at surgery. Posteromedial and posterolateral cutaneous incisions and a popliteal retractor were routinely used to protect and retract neurovascular structures where the needles penetrated the posterior capsule as the sutures were tied over the capsule. During the procedure, the body of the meniscus and the peripheral rim were meticulously prepared. The sutures were placed at 3–4 mm intervals. The aftercare included a 3-week period of maximum protection to provide the best opportunity for healing to occur. This was followed by a period of continued protection from heavy stresses during maturation of the repair tissue, until 3 months after surgery. After 3 months, a gradual return to full-speed running, agility, and unrestricted activities was encouraged as desired and tolerated.

## Results

Based on a modification of the HSS knee evaluation form, 2 patients had an excellent result, 9 patients a good result, and 2 patients had a fair result. There were no poor results. Age did not change the outcome, probably because the selection criteria for meniscus repair were stricter in the older age group.

The sex of the patient had no effect on the outcome. All acute tears (injury-to-repair interval <2 weeks) and 8/10 of all chronic tears (injury-to-repair interval >2 weeks) had good-to-excellent results. The 2 patients in the fair group had a chronic tear. 2 of all tears were R-R tears. All R-R tear repairs and 8/10 of all R-W tear repairs showed good-to-excellent results. Only 1 W-W tear was repaired. This patient scored as having a good result. Patients with a tear-length between 0–3 mm had a good-to-excellent result. 2 patients with a tear-length between 3–6 mm had a fair result. All other patients had good-to-excellent results. Of the 13 patients at follow-up, 7 showed an associated ACL injury. 1 was reconstructed, 6 years after meniscal repair. Of these 6 patients, only 1 had a fair result and the other 5 patients had good-to-excellent results (Table). Complications included 1 superficial infection managed with antibiotics and 1 saphenous neurapraxia. No patient had permanent functional impairment. 7 patients of the initial group of 20 patients were interviewed by telephone. This group had similar results to the group of 13 patients who were examined (Table).

Patient distribution and results at 13 years of follow-up. MRI evaluation and results of patients interviewed by telephone

Patient	Age	Sex	Side	ACL	Zone	Location	A/C	Score	MRI evaluation
1	44	M	L		2	R-W	Acute	Excellent	Hyperintense area
2	50	M	L	Rupture	3	W-W	Chronic	Good	Hyperintense area, new tear
3	48	M	R	Rupture	1	R-W	Acute	Good	Cartilage degeneration (grade 3)
4	31	M	L	Rupture	2	R-W	Chronic	Good	Cartilage degeneration (grade 3)
5	35	M	R	Rupture	1	R-W	Acute	Good	Cartilage degeneration (grade 3)
6	38	M	R		2	R-W	Chronic	Fair	
7	37	M	L	Repaired	1	R-R	Acute	Good	Hyperintense area, cartilage
8	31	F	R		1	R-W	Chronic	Excellent	
9	29	F	L	Rupture	3	R-W	Chronic	Fair	Cartilage degeneration (grade 1)
10	32	F	R		2	R-W	Acute	Good	Hyperintense area
11	34	F	L		2	R-W	Chronic	Good	
12	31	F	R	Rupture	3	R-R	Acute	Good	Cartilage degeneration (grade 3)
13	44	F	R		2	R-W	Chronic	Good	Hyperintense area
1	42	M	R		2	R-R	Acute	Excellent	
2	37	M	L		3	R-W	Acute	Good	
3	34	M	R	Rupture	1	R-W	Chronic	Fair	
4	41	M	L		2	R-W	Chronic	Good	
5	33	F	R		1	R-R	Acute	Good	
6	36	F	L		3	R-W	Chronic	Good	
7	37	F	L		1	R-R	Acute	Excellent	

### **MRI evaluation**

We used MRI, which is at least as accurate as arthrography in assessing meniscal repair (Van Trommel et al. 1998). In all patients (n = 13) the site of the previous suture could still be detected, mainly by the small micrometal artefacts in the meniscus, evident on the gradient echo images (Figure 1). In 1 patient, a new tear was found. This tear was not repaired. There were no signs of this tear in 1999. In 5 patients hyperintense areas were discovered in the meniscus, in the area of the previous intervention. We presume that this corresponds to mucoid degeneration or scar tissue (Figure 2). 7 patients had an ACL rupture, of which 1 was repaired 6 years after meniscal repair: 4 patients clearly showed an early onset of arthrosis and cartilage degeneration (grade 3) (Figure 3) and 2 showed minor signs of cartilage degeneration (grade 1) (Recht et al. 1993). The patients with grade 3 lesions had good-to-excellent functional results (Table). 1 patient showed a localized area of avascular necrosis on the posterior part of the femoral condyle at 7 years of follow-up. In 1999, these signs had clearly diminished. The knot of the meniscal suture had been at this level and had presumably caused this lesion through direct pressure. As the knot gradually resorbed, the condyle recovered (Figures 3 and 4). In 1994, the site of the previous suture was also visible in all patients.

### **Discussion**

In our study, chronicity of the tear was found to affect the percentage of satisfactory results. All the menisci repaired within 2 weeks of injury had a good-to-excellent result. 7 patients sustained an ACL injury (1 reconstructed). All patients had good-to-excellent results. Stability of the knee did not seem to affect the result of meniscal repair. A study by Hanks et al. (1990) described meniscus repair in ACL-deficient knees, with a 13% failure rate. These authors concluded that even though the failure rate may be higher in an unstable knee, meniscus repair was not contraindicated in an ACL-deficient knee. Roos et al. (1995) concluded that OA of the knee after injury to the ACL or meniscus became increasingly severe with increased time between joint injury and examination. The OA changes appeared sooner in the older patients than in the young. In our study also, the youngest patient showed only minor cartilage degeneration.

Neither the age of the patient, nor the length or extent of the tear seemed to affect the result of meniscal repair. We believe that in symptom-free patients, the meniscus is either histologically healed or acts as an autograft and fulfills the mechanical tasks of an injured meniscus. Only one W-W tear was repaired and this patient scored a good result. Rubman et al. (1998) recommended arthroscopic repair for meniscal tears extending into the avascular zone in select cases. The 20% reoperation rate in their study should not be interpreted as the rate of meniscal healing, but as the incidence of tibiofemoral joint symptoms.

Link et al. (2003) concluded in their study that cartilage lesions, bone marrow edema pattern, and meniscal and ligamentous lesions were frequently seen on MR images in patients with advanced osteoarthritis. Clinical findings, however, showed no significant correlations with Kellgren-Lawrence scale score and extent of findings at MR imaging.

Long-term studies evaluating the development of arthrosis in patients with clinically healed meniscal tears after arthroscopic repair may provide more evidence to support this hypothesis. We found the presence of mucoid degeneration or scar tissue in 5/13 patients after an average follow-up of more than 13 years. Thus, we believe that asymptomatic menisci produce abnormal MRI signals even though they have stable unions, and that MRI signals at the site of repair represent edematous scar tissue, not true nonunions. Eggli et al. (1995) found similar findings in their study. Englund et al. (2001) reported in their study that the long-term outcome of meniscal injury and surgery appears to be determined largely by the type of meniscal tear. Furthermore, their findings supported the use of minimal meniscal resection in the treatment of degenerative tears. They suggested that the disease processes associated with the development of OA of the joint cartilage may also be active in the meniscus, and that a tear in a meniscus with degenerative changes might be regarded as the first sign of OA of the joint.

Our current protocol for the repair of meniscal tears relies on several technical details that we think are essential for the successful repair of meniscal tears. A careful examination is required to determine the integrity of the tissue and assess chronic changes, such as deformation or degeneration. The meniscus must contain a reducible tear with good tissue integrity that will maintain its position in the joint once repaired. Degenerative, poor-quality meniscal tissue is not strong enough to hold the sutures and should not be considered for repair. Stable fixation of the meniscal tear decreases the possibility of motion between the meniscal fragments and allows a postoperative rehabilitation program that emphasizes early motion and weight bearing.

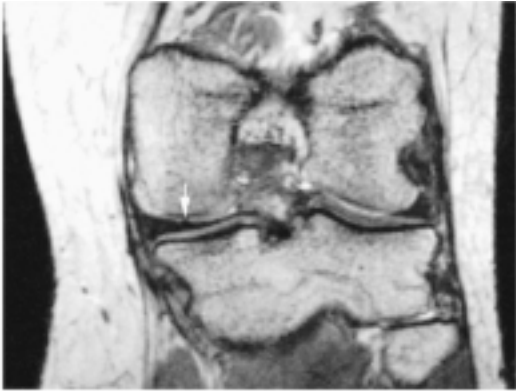


Figure 1. Coronal gradient-echo MRI image. Small micro-metal artefacts in the meniscus or cartilage, showing the previous site of suture (arrow).

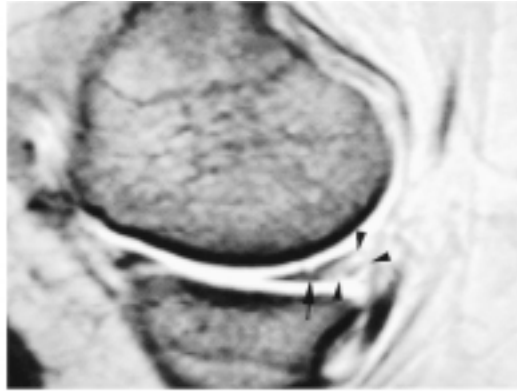


Figure 2. Sagittal T2\*-weighted gradient-echo image showing a hyperintense area in the meniscus due to mucoid degeneration (arrowheads). is also visible (arrow).

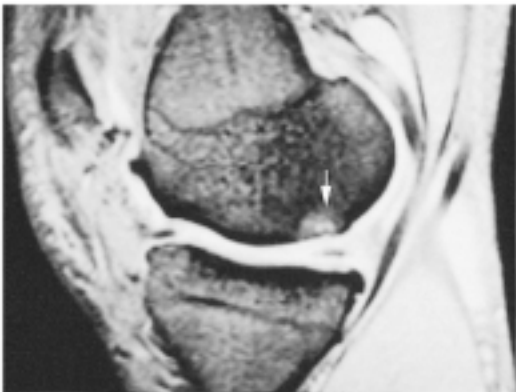

Figure 3. Sagittal T2\*-weighted MR image showing arthritis and cartilage degeneration (grade 3), most evident opposite the posterior horn of the sutured medial meniscus (arrow). This is a localized area of avascular necrosis in the subchondral bone with trabecular bone resorption (arrow).

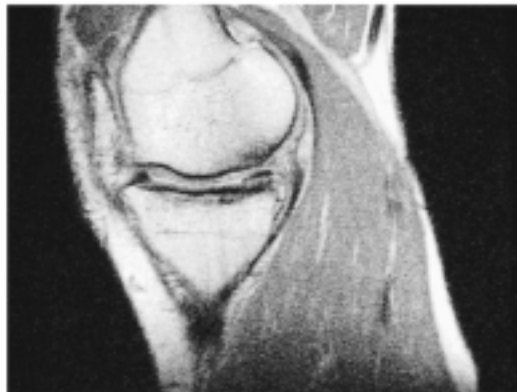

Figure 4. The same patient as in Figure 3 at final follow-up. 5 years later, there are no longer signs of localized necrosis but only subchondral sclerosis. There is a localized area of cartilage thinning opposite the posterior horn of the sutured meniscus.

Multiple, nonabsorbable sutures, in both the superior and inferior surfaces of the meniscus, should be placed every 3–4 mm to ensure that the repair will be held in position to allow healing to occur. A recent report of the results of repair of longitudinal meniscal tears evaluated arthroscopically found that no tear with a rim width of greater than 4 mm healed (Van Trommel et al. 1998). The sutures in that study were placed at least 4 mm apart. We believe that complex tear patterns and meniscal tears in the central region are subjected to higher stresses than those incurred in single longitudinal tears located at the periphery, and therefore require sutures to be placed at closer intervals. Because the location of the tear within the meniscus is not a primary consideration for which tears are amenable to repair, we no longer measure the rim width at the time of repair.

Partial meniscectomy for complex tear patterns or tears that extend into the avascular zone require removal of a large portion of the meniscus and they may render it nonfunctional. If meniscus repair is performed, the long-term data in our study show that at 13 years after surgery, most patients will be symptom-free.

### **No competing interests declared.**

Annandale T. An operation for displaced semilunar cartilage. *Br Med J* 1885; 1: 779-81.

Cannon W D, Morgan C D. Meniscal repair. *J Bone Joint Surg (Am)* 1994; 76: 294-311.

Dandy D J, Jackson R W. The diagnosis of problems after meniscectomy. *J Bone Joint Surg (Br)* 1975; 57: 349-52.

De Haven K E. Meniscus repair: current concepts. *Am J Sports Med* 1999; 27: 242-50.

Eggl S, Wegmüller H, Kosina J. Long-term results of arthroscopic meniscal repair: an analysis of isolated tears. *Am J Sports Med* 1995; 23: 715-20.

Englund M, Roos E M, Roos H P, Lohmander L S. Patient-relevant outcomes fourteen years after meniscectomy: influence of type of meniscal tear and size of resection.

*Rheumatology* 2001;40:631-9.

Hanks G A, Trenton M G, Handal J A. Meniscus repair in the anterior cruciate deficient knee. *Am J Sports Med* 1990; 18: 606-13.

Henning C E. Arthroscopic repair of meniscus tears. *Orthopedics* 1983; 6: 1130-2.

Link T M, Steinbach L S, Ghosh S, Ries M, Lu Y, Lane N, Majumbar S. Osteoarthritis: MR Imaging findings in different stages of disease and correlation with clinical findings. *Radiology* 2003; 226: 373-81.

Recht M P, Kramer J, Marcelis S. Abnormalities of articular cartilage in the knee: analysis of available MR techniques. *Radiology* 1993; 187: 473-8. Roos H, Adalbrecht T, Dahlberg L, Lohmander L S.

Osteoarthritis of the knee after injury to the anterior cruciate ligament or meniscus: the influence of time and age.

*Osteoarthritis Cartilage* 1995;3:261-7.

Rubman M R, Noyes F R, Barber-Westin S D. Arthroscopic repair of meniscal tears that extend into the avascular zone: a review of 198 single and complex tears. *Am J Sports Med* 1998; 26: 87-95.

Shands A R, Hutchinson J L, Ziv L. Derangements of the semilunar cartilages of the knee: A clinical and experimental study. *South Med J* 1936; 29: 1045-50.

Stone R G, Frewin P R, Gonzales S. Long-term assessment of arthroscopic meniscus repair: a two- to six-year follow-up study. *Arthroscopy* 1990; 6: 73-8.

Van Trommel M F, Potter H G, Ernborg L A. The use of noncontrast Magnetic Resonance Imaging in evaluating meniscal repair. *Arthroscopy* 1998; 14: 2-8.

Verdonk R, Meire D, Van De Velde C, Van Eetvelde G, Claessens H. CT scan of the knee: correlation with clinical and arthroscopic findings. *Acta Orthop Belg* 1991;

57: 49-55.

# **REPAIR OF CHRONIC RUPTURES OF THE ANTERIOR CRUCIATE LIGAMENT USING ALLOGRAFT RECONSTRUCTION AND A LIGAMENT AUGMENTATION DEVICE**

**F. STEENBRUGGE, R. VERDONK , P. VORLAT , F. MORTIER , K. VERSTRAETE\***

Department of Orthopedic Surgery and \*Department of Radiology, Ghent University Hospital, B-9000 Gent, Belgium.

Correspondence and reprints: F. Steenbrugge, Department of Orthopedic Surgery and Trauma, UZ-Gent, De Pintelaan 185, B-9000 Gent, Belgium.

**A prospective study was performed to determine the effect of a ligament augmentation device (LAD) on the replacement of the anterior cruciate ligament (ACL) using tendon allografts. Twenty-five patients were followed for 66 to 98 months after tendon allo-graft replacement with LAD reinforcement for ACL**

**rupture. The evaluation was done using the form of the International Knee Documentation Committee (IKDC), the Lysholm score and the Tegner scale. Two patients sustained a rerupture after major injury.**

**Three other multiply-injured patients scored poorly because of associated injuries and fractures (IKDC grade D). Four patients scored normal (grade A), 12 patients nearly normal (grade B), and 5 patients abnormal (grade C). The Lysholm score showed 14 excellent (average 96), 5 good (average 86) and 4 fair results (average 76). Three patients with excellent results were IKDC grade C, solely because the xrays showed slight narrowing of the medial joint line, which might indeed indicate future problems. On the Tegner scale, the sports level decreased by an average of 1.4 points (from 7.25 to 5.83). Only five patients showed an anteroposterior displacement of more than 3 mm, of which only one was in the grade C group.**

**Keywords:** anterior cruciate ligament ; ligament aug-mentation device; joint instability; tendon allograft; knee injury; chronic instability.

**Mots-clés:** ligament croisé antérieur; renforcement ligamentaire; instabilité articulaire; allogreffe tendi-neuse; laxité chronique.



## INTRODUCTION

Acute ACL rupture is most commonly associated with injury to other ligaments of the knee, the menisci, or both. When combined with collateral ligament ruptures it has been found to further compromise stability (7, 13, 28, 32).

Consequently, a direct correlation has been suggested between the complexity of the injuries associated with ACL rupture and the need for surgical repair or replacement. Likewise, patients without associated ligamentous or meniscal injuries (those having isolated ACL ruptures) are assumed to have a better prognosis. Autogenous and allogeneic grafts that have been used to reconstruct ACL-deficient knees undergo a precipitous drop in strength in the early postoperative period due to tissue necrosis, revascularization, and remodeling (1, 3, 4, 5, 8, 14, 16, 24, 26). In an effort to protect a healing autogenous patellarligament reconstruction in the early postoperative period, Kennedy et al. proposed the use of a ligament augmentation device made of polypropylene braid (3 M, St. Paul, Minn. USA) in 1980. They hypothesized that load-shearing between the ligament augmentation device and the biological graft would protect the graft during the period of degeneration and weakening, after which so-called collagenization would eventually occur. Van Kampen et al. (30) later supported this hypothesis by postulating that the load would be gradually transferred from the synthetic device to the autogenous graft, over time, as the biological graft remodeled and became inherently stronger.

These authors suggested that the outcome of a reconstruction with an augmented graft would depend on the amount of load that was carried by the biological tissue; they believed that the tissue must carry a sufficient amount of load to allow the graft to mature. Kennedy et al. stated (15, 16) that the polypropylene braided device for ligament augmentation had adequate tensile strength, fatigue, and creep properties for it to be used as an adjunct to reconstructions with autogenous patellar ligaments.

Sheep, dog and goat models demonstrated that the augmentation of biological grafts with the device resulted in less anteroposterior displacement than when the graft was used alone (8) and that the device did not affect the remodeling process of the biological graft. Encouraged by early reports of success in animal models (8) and in an effort to increase the success rate of the allograft reconstructions in our patients, we initiated a small prospective study of the combined use of the ligament augmentation device and the allograft in knees with a torn ACL. In our department we have been using fresh-frozen tendon allografts since November 1988 (2, 31).

## MATERIALS

Between July 1990 and August 1994, 25 consecutive operations for chronic ACL rupture were performed by the senior author (RV), using a tendon allograft with an augmentation device. Twenty male and five female patients were evaluated at an average of 74 months after their operation (66 to 98 months). The mean age at the time of follow-up was 37 years (range: 23 to 55 years). All cases were traumatic in origin. Twenty (80%) had injured the knee during sports activities (table I). Prior to the ACL reconstruction, 10 patients had already undergone one or more surgical interventions, mainly meniscal procedures but no ligament reconstructions (table II).

Table I. — Traumatic etiology

Sports	20	Work	5
soccer	15		
ski	1		
handball	1		
basketball	2		
athletics	1		

Table II. — Previous surgery

lateral and medial meniscectomy	9
medial meniscal suture	1
ligamentous reconstructions	0

Table III. — Associated procedures

Partial medial meniscectomy	1
Medial meniscal suture	1
MCL suture-reefing-stapling	1

The indications were as follows: In young patients, anterolateral rotatory instability (ALRI) (pivot+) was an indication for a combined intra-articular and extra-articular reconstruction, if they complained of instability during activities of daily living or expressed a strong wish to continue contact or pivot sports. Combined ALRI and anteromedial rotatory instability (AMRI) was treated with an intra-articular and a lateral extra-articular procedure, augmented with suture of the MCL or reefing of the posterior oblique ligament (POL). This is a protocol designed for treatment of ligamentous lesions in our department. Only one patient required medial col-lateral ligament reefing, one patient had a partial medial meniscectomy and another patient had a suture of the medial meniscus. None of the other patients had any associated ligamentous injuries (table III). All patients were operated on for chronic ligamentous instability, at least 8 weeks after injury.

## METHODS

Under sterile conditions, the allografts are harvested in the operating room within 12 hours of death from general organ donors, screened for transmittable diseases.

After microbial culture, the tendon is stored at minus 80°C for a minimum of 14 days and a maximum of 6 months. We use only tibialis anterior and posterior tendons. We normally use an LAD of 8-mm width and 15 cm in length. This is placed inside the transplant, which is closed in a cylinder along its entire length by a seam of resorbable sutures. The LAD is then fixed to the transplant by 3 or 4 resorbable sutures. The graft is implanted through a limited arthrotomy (double-incision technique). The LAD enters the joint from the medial side through a predrilled tibial bone hole just over the pes anserinus attachment, to a point slightly anterior and medial to the center of the ACL

anatomic attachment. A heavy suture is threaded through the eye of a curved passer, which is driven into the joint cavity via the medial entry portal. The passer is brought through the intercondylar notch over-the-top of the lateral condyle. After opening the iliotibial band and elevating the vastus lat-eralis, the heavy leading suture is pulled through a 3- to 4-cm skin incision on the distal third of the thigh. The opposite end is passed from the joint cavity to the medial side of the tibia via the osseous tunnel, with the help of a hook. The graft is secured proximally with a staple. The distal end of the synthetic band is also fixed with a staple after preloading with the knee joint in 30° flexion. As shown in table III, a number of patients were also treated for associated meniscal damage. Because the load in full extension is supported by the LAD during the early postoperative period, the LAD in double-end fixation is supposed to permit early postoperative functional treatment. Stress shield prevents the allograft structure of the ACL reconstruction from being overloaded. Full weightbearing of the operated knee joint was permitted immediately after the operation, if there were no additional intra-articular lesions. Every patient had a custom-made brace with an extension lag of 30° for a period of six weeks. Because the ligament is taut and fixed at 30° of flexion, there is a postoperative limitation of extension. Rehabilitation aimed at correcting this flexion will lead to stretching and possible rupture of the transplant. The use of the brace was initiated because we believed that elongation of the graft should occur within limits for optimal healing and “ligamentization”. In case of a combined intra-articular and extra-articular ligamentoplasty, immediate mobilization was initiated using continuous passive motion between 20° and 90° of flexion. Progressive dynamic rehabilitation and proprioceptive training were prescribed for 6 months. Return to sports was discouraged within the first 6 months. Pivot and contact sports were not allowed within the first year.

## **RESULTS**

### **Short-term**

Two complications were noted in the early postoperative course. For a persistent flexion lag, one patient required manipulation under anesthesia 6 months after the operation. In one patient the tibial staples had to be removed after 6 months because of irritation. There was no clinical evidence of allograft rejection, deep infection, thrombosis or per-sistent effusion. The average flexion was 128°. One patient had an extension lag of 20°.

### **Medium-term**

If an intra-articular lesion was suspected, a repeat arthroscopy was performed (4 patients). Two ruptures of the reconstructed ligament were noted. They all occurred after a major injury (1 sports, 1 traffic) between 2 and 6 years postoperatively. The other 2 patients showed an intact reconstructed ACL, and in both cases a partial medial meniscectomy was performed.

## **EVALUATION**

Knee performance was evaluated using the form of the International Knee Documentation Committee (IKDC), the Lysholm score and the Tegner scale. The reruptures were excluded.

### **Lysholm score**

Fourteen patients had an excellent result (average 96). Five patients scored good (average 86) and four patients poor (average 76).

**Tegner scale**

The mean level for sporting activities was 7.25 preoperatively and 5.83 at evaluation. The Tegner scale should be used with caution in the interpretation of medium-term results. Most of the patients, being more than 40 years of age at evaluation, did not wish to return to their preinjury sports level. The mean decrease of professional activities was 0.5.

**Range of motion and laxity testing**

Laxity testing was performed using the KT-1000 arthrometer, using a force of 90 Newton (N) (34). The average range of flexion was 131°. There were no patients with an extension lag. Satisfactory results were obtained on clinical mediolateral laxity evaluation. The results are shown in table IV.

Table IV. — Laxity testing with the KT-1000 arthrometer using a force of 90 N

< 3 mm	> 3 mm	< 5 mm
AP neutral	5	2
Lachmann	6	3
Pivot	0	0
med laxity	0	0
lat laxity	0	0

**IKDC form**

Four patients scored normal (grade A), twelve patients nearly normal (grade B), five patients abnormal (grade C) and two severely abnormal (grade D).

**DISCUSSION**

Allografts can be used for revisions and multiple reconstructions if insufficient or no autografts can be harvested. This results in a shorter operating time, a smaller incision with arthroscopic techniques, and reduced postoperative donor site morbidity (14, 19, 21).

Synovitis is a serious problem associated with artificial ligaments (9, 27). Tolerance of the Kennedy LAD was satisfactory, since there were no cases of acute or chronic synovitis and no clinical or radiological signs of iatrogenic disease associated with the synthetic reinforcement. It is possible that some had a mild synovitis that was not diagnosed because they did not pay attention to it.

Reports have been made of increasing effusion rates over time using artificial ligaments (23).

The comparison of our results with those of studies in which no reinforcements were used (6, 11, 18, 29, 33) is difficult because of differences in the study groups, the condition of the menisci, and the time elapsed between accident and intervention. Noyes and Barber (22) studied the effect of the ligament augmentation device on reconstructions using bone-patellar ligament-bone allografts. The patients were followed for a mean of 34 months, and the failure rate was found to be 29% in knees that were not augmented and 27% in the augmented group. They concluded that the addition of the ligament augmentation device did not improve the results of allograft reconstruction. Our results show a failure rate of 12%. An anteroposterior displacement on laxity testing of more than 3 mm was considered a failure. We had two complications. The ruptures occurred after major trauma and

are therefore not regarded as complications. Our rehabilitation program was designed to maximize the possible protective effect of the augmentation device. Fixation of the device at both ends should reduce the load on the graft by approximately one third (12).

We used the IKDC scoring system because it is widely employed to report data in the current orthopedic literature. The IKDC scoring system was designed in 1991 and modified 2 years later by 11 members of the AOSSM and 10 members of the European Society for Knee Surgery and Arthroscopy (ESKA). There are eight categories of assessment, each of which has four grades: normal, nearly normal, abnormal and severely abnormal. The worst grade determines the final evaluation.

Only the first four categories' grades for subjective assessment count toward the final evaluation in patients with chronic ACL rupture. However, the lowest score in any of the groups will determine the final score and may not reflect knee function accurately. Therefore we believed that the Lysholm score, despite its subjective and optimistic nature, added crucial information to the final evaluation. The patients in this series had good results on the Lysholm score. Four scored poorly, most probably because of their associated injuries. The results on the Tegner scale were good, when corrected for age by asking the patients for the sports level they actually desired to achieve.

The results of laxity testing are acceptable. The reruptures were caused by new severe trauma in patients with a good score at evaluation before the ACL rupture. The scorings on the IKDC form are debatable. The patients scoring severely abnormal (grade D) also had poor Lysholm scores. One was a multiply-injured patient with several associated lesions. Another one showed marked degenerative changes on xrays. Three patients scored abnormal (grade C), because of a slight (1-mm) narrowing of the medial compartment on xrays. Nevertheless, they had an excellent Lysholm score. This narrowing was probably caused by a medial meniscectomy in two of these patients (10, 20, 24).

Since the device is fixed at both ends and may thus function as a prosthesis, stress protection may have occurred. This could lead to increased laxity when the ligament augmentation device eventually breaks. If it is taking most of the load during our rehabilitation program, we feel that breakage would probably have occurred before the two-year review.

## CONCLUSION

Previous and current studies place us in a dilemma with regard to the use of allografts in knees with a chronic ACL rupture. All studies show a highly significant improvement in the subjective ratings of symptoms, function, and activity levels, but the arthrometric data are not satisfactory either for the knees that have been treated with an allograft alone or for those that have been treated with the allograft and the augmentation device.

Our results are in the same range as those of the longest follow-up studies of allografts with an augmentation device (17, 22, 25). Augmentation did not give better results than when no augmentation was performed (2, 17, 31). Although the strict IKDC scoring suggests average results of the allograft reconstruction technique, satisfactory results are achieved on the Lysholm and Tegner scale, and on clinical examination after 6 years. Although the LAD has been shown to be effective in augmenting hamstring or the medial quadricepsperiosteum autografts or allografts, which are inherently weaker than the bone-tendon-bone autograft, there is no evidence to prove the usefulness of the LAD with better techniques of graft selection and isometric graft positioning (17).

Nevertheless, we found it to be a valuable alternative to reconstruction with autografts, especially for knees with multiple ligament lesions and for revision cases (31).

We currently no longer perform this operation through an arthrotomy, but instead we perform it arthroscopically. We have abandoned the over-the-top technique because it fails to provide adequate isometry for graft placement (25).

Implantation of allograft ligament material with an augmentation device as a substitute for the ACL has not induced clinically detectable rejection in this medium-term evaluation or, at the time of writing, transmission of disease.

## REFERENCES

1. Aglietti P, Buzzi R., D'Andria S., Zaccherotti G. Long-term study of anterior cruciate ligament reconstruction for chronic instability using the central one-third patellar tendon and a lateral extra-articular tenodesis. *Am. J. Sports Med.*, 1992, 20, 38-45.
2. Arnauw G., Verdonk R., Harth A., Moerman J., Vorlat P., Bataillie F., Claessens H. Prosthetic versus tendon allo-graft replacement of ACL-deficient knees. *Acta Orthop. Belg.*, 1991, 57 (suppl II), 67-74.
3. Butler D. L., Grood E. S., Noyes F. R., Olmstead M. L., Hohn R.B., Arnoczky S. P., Siegel M.G. Mechanical properties of primate vascularized versus nonvascularized patellar tendon grafts ; changes over time. *J. Orthop. Res.*, 1989, 7, 68-79.
4. Cabaud H. E., Feagin J. A., Rodkey W. G. Acute anterior cruciate ligament injury and augmented repair. Experimental studies. *Am. J. Sports Med.*, 1980, 8, 395-401.
5. Curtis R. J., Delee J. C., Drez D. J. Reconstruction of the anterior cruciate ligament with freeze dried fascia lata allo-grafts in dogs. A preliminary report. *Am. J. Sports Med.*, 1985, 13, 408-414.
6. Dejour H., Walch G., Neyret P., Adeleine P. Résultats des laxités chroniques antérieures opérées. A propos de 251 cas revus avec un recul minimum de 3 ans. *Rev. Chir. Orthop.*, 1988, 74, 622-636.
7. Fetto J. F., Marshall J. L. Medial collateral injuries of the knee: A rationale for treatment. *Clin. Orthop.*, 1978, 132, 206-218.
8. Fowler P., Amendola A. Allograft ACL reconstruction in a sheep model - The effect of synthetic augmentation. *Trans. Orthop. Res. Soc.*, 1990, 15, 80.
9. Fox J., Karzel R., Diefendorf D., Four year experience with the Gore-Tex prosthetic ligament in anterior cruciate deficient knees. In : *Proceedings of the 57<sup>th</sup> annual meeting of the American Academy of Orthopaedic Surgeons, New Orleans, 1990, paper 413.*
10. Friedrich N. F., O'Brien W. R. Gonarthrose nach Verletzung des vorderen Kreuzbandes: Eine Multizenter-Langezeitstudie. *Z. Unfallchir. Versicherungsmed.*, 1993, 86, 81-89.
11. Gacon G., Barba L., Lalain J.J., Laurençon M., Ray A. Résultats à plus de dix ans de 54 plasties intra-articulaires du ligament croisé antérieur du genou. *Rev. Chir. Orthop.*, 1992, 78 (suppl I), 130-131.
12. Hanley P., Lew W.D., Lewis J.L., Hunter R.E., Kirstukas S., Kowalszyk C. Load sharing and graft forces in anterior cruciate ligament reconstructions with the ligament augmentation device. *Am. J. Sports Med.*, 1989, 17, 414-422.

13. Hughston J.C., Barrett G.R. Acute anteromedial rotatory instability. *J. Bone Joint Surg.*, 1973, 65-A, 145-152.
14. Kartus J., Stener S., Lindahl S., Engstrom B., Eriks-son B. L., Karlsson J. Factors affecting donor-site morbidity after anterior cruciate ligament reconstruction using bone-patellar tendon-bone autografts. *Knee Surg. Sports Traumatol. Arthrosc.*, 1997, 5, 222-228.
15. Kennedy J. C. Application of prosthetics to anterior cruciate ligament and repair. *Clin. Orthop.*, 1983, 172, 125-128.
16. Kennedy J. C., Roth J. H., Mendenhall H. V., Sanford J. B. Presidential address. Intraarticular replacement in the anterior cruciate ligament-deficient knee. *Am. J. Sports Med.*, 1980, 8, 1-8.
17. Kumar K., Maffuli N. The ligament augmentation device: An historical perspective. *Arthroscopy*, 1999, 15, 422-432.
18. Lerat J.L., Dupré Latour L., Herzberg G., Moyon B. Revue de 100 patients opérés pour laxité chronique antérieure du genou par un procédé dérivé des méthodes de Kenneth Jones et de D. MacIntosh. Intérêt de la radiographie dynamique pour l'analyse objective des résultats. *Rev. Chir. Orthop.*, 1987, 73 (suppl II), 201-204.
19. Marks P.H., Cameron M., Fu F.H. Die Rekonstruktion der Kreuzbänder mit allogenen Transplantaten. Techniken, Ergebnisse und Perspektiven. *Orthopade*, 1993, 22, 386-391.
20. McDaniel W.J., Dameron T.B. The untreated anterior cruciate ligament rupture. *Clin. Orthop.*, 1983, 172, 158-163.
21. Nikolaou P.K., Seaber A.V., Glisson R.R., Ribbeck B.M., Bassett F.H. Anterior cruciate ligament allograft transplantation. Long term function, histology, revascularization, and operative technique. *Am. J. Sports Med.*, 1986, 14, 348-360.
22. Noyes F.R., Barber S.D. The effect of a ligament - augmentation device on allograft reconstructions for chronic ruptures of the anterior cruciate ligament. *J. Bone Joint Surg.*, 1992, 74-A, 7, 960-973.
23. Paulos L, Rosenberg J., Grewe S., The Gore-Tex anterior cruciate ligament reconstruction : Five-year follow-up. In: Proceedings of the 57<sup>th</sup> annual meeting of the American Academy of Orthopaedic Surgeons, New Orleans, 1990, paper 412.
24. Sabiston P, Frank C., Lam T., Shrive N. Allograft ligament transplantation. A morphological and biomechanical evaluation of medial collateral ligament complex in a rabbit model. *Am. J. Sports Med.*, 1990, 18, 160-168.
25. Saragaglia D., Leroy J.M., De Sousa B., Tourne Y., Abu Al Zahab M. Medium-term results of 173 ligamentoplasties of the anterior cruciate ligament using the MacIntosh technique reinforced by the Kennedy ligament augmentation device (LAD). *Knee Surg. Sports Traumatol. Arthrosc.*, 1995, 3, 68-74.
26. Shino K., Kawasaki T., Hirose H., Gotoh I., Inoue M., Ono K. Replacement of the anterior cruciate ligament by an allogeneic tendon allograft. An experimental study in the dog. *J. Bone Joint Surg.*, 1984, 66-B, 672-681.
27. Sledge S., Steadman J., Silliman J., Five-year results with the Gore-Tex anterior cruciate ligament prosthesis. *Am. J. Sports Med.*, 1992, 5, 65-70.
28. Sullivan D., Levy I. M., Sheskie S. Medial restraints to anterior-posterior motion of the knee. *J. Bone Joint Surg.*, 1984, 66-A, 930-936.
29. Thuresson P., Sandberg R., Johansson O., Balkfors B., Westlin N. Anterior cruciate ligament reconstruction with the patellar tendon - Augmentation or not? A 2-year follow-up of 82 patients. *Scand. J. Med. Sci. Sports*, 1996, 6, 247-254.

30. Van Kampen C. L., Mendenhall H. V., McPherson G. K. Synthetic augmentation of biological anterior cruciate ligament substitutions, In: *The Anterior Cruciate Deficient Knee. New Concepts in Ligament Repair*, pp 236-238. Eds. D.W. Jackson, D. Drez, St. Louis, CV Mosby, 1987, 74-A, pp. 960-997.
31. Vorlat P., Verdonk R., Arnauw G. Long-term results of ten-don allografts for anterior cruciate ligament replacement in revision surgery and in cases of combined complex injuries. *Knee Surg. Sports Traumatol. Arthrosc.*, 1999, 7, 318-322.
32. Warren R., Marshall J. L. Injuries of the anterior cruciate and medial collateral ligaments of the knee. A long-term follow-up of 86 cases. *Clin. Orthop.*, 1978, 136, 198-211.
33. Witvoet J., Kerboul L., Christel P. Résultats à long terme (4-10 ans) de 88 ligamentoplasties intra-articulaires dans le traitement des instabilités antérieures chroniques du genou. *Rev. Chir. Orthop.*, 1991, 77 (suppl II), 156-157.
34. Wroble R. R., Van Ginkel L. A., Grood E. S., Noyes F. R., Shaffer B.L. Repeatability of the KT-1000 arthrometer in a normal population. *Am. J. Sports Med.*, 1990, 18, 396-399.

## SAMENVATTING

*F. STEENBRUGGE, R. VERDONK, P. VORLAT,  
F. MORTIER, K. VERSTRAETE. Plastie van chronische  
scheuren van de voorste kruisband met behulp van pees-allogreffes  
en een peesverstevigingsapparaat.*

We hebben een prospectieve studie gedaan om het effect te beoordelen van een peesverstevigingsapparaat (ligament augmentation device – LAD) op de plastie van chronische voorste kruisband (VKB) scheuren met peesallogreffes. Vijf en twintig patiënten werden gevolgd gedurende 6 jaar (gemiddeld 74 maanden) na plastie van de VKB met een peesallogrefte en LAD. De evaluatie gebeurde aan de hand van het document van de International Knee Documentation Committee (IKDC), de Lysholm score en de Tegner score. Twee patiënten hadden een herruptuur van hun hersteld ligament na een nieuw ernstig trauma. Drie andere patiënten die multiple letsels hadden, scoorden slecht omwille van hun geassocieerde letsels (IKDC graad D). Vier patiënten scoorden normaal (graad A), twaalf patiënten bijna normaal (graad B), en vijf patiënten abnormaal (graad C). De Lysholm score toonde 14 (gemiddeld 96) uitstekende resultaten, 5 goede (gemiddeld 86) en 4 behoorlijke resultaten (gemiddeld 76). Drie van de uitstekende resultaten waren IKDC-graad C, enkel omdat de radiografische opnames een kleine vernauwing toonden van het mediale kraakbeen wat op toekomstige problemen kan wijzen. Op de Tegnerschalen was het sportniveau gedaald met een gemiddelde van 1.4 punten (van 7.25 tot 5.83).

Slechts 5 patiënten toonden een voorachterwaartse verplaatsing van meer dan 3 mm, waarvan er enkel een in groep C was.



## RÉSUMÉ

*F. STEENBRUGGE, R. VERDONK, P. VORLAT,  
F. MORTIER, K. VERSTRAETE. Ligamentoplastie pour  
rupture chronique du ligament croisé antérieur par allogreffe  
et renfort synthétique.*

Nous avons conduit une étude sur l'effet d'un renforcement ligamentaire synthétique (ligament augmentation device – LAD) sur le résultat des plasties du ligament croisé antérieur (LCA) par allogreffe. Vingt-cinq patients ont été suivis pendant 66 à 98 mois (moyenne: 74 mois) après plastie du LCA par allogreffe et LAD.

L'évaluation a été faite avec le formulaire de l'International Knee Documentation Committee (IKDC), le score de Lysholm, et le score de Tegner. Deux patients ont eu une rerupture de leur ligamentoplastie après un nouveau traumatisme important. Trois patients qui présentaient des lésions multiples, avaient un mauvais score en raison des lésions et fractures associées (IKDC grade D).

Quatre patients avaient un score normal (grade A), douze patients un score presque normal (grade B), et cinq patients un score anormal (grade C). Le score de Lysholm montrait 14 résultats excellents (score moyen: 96), 5 résultats bons (score moyen: 86) et 4 résultats passables (score moyen: 76). Trois des résultats excellents étaient IKDC-grade C, uniquement parce que les radiographies montraient un petit pincement de l'interligne médial, ce qui peut faire présager de problèmes dans l'avenir. Le score de Tegner montrait que le niveau sportif était diminué en moyenne de 1.4 points (de 7.25 à 5.83). Cinq patients seulement avaient un déplacement antéropostérieur de plus de 3 mm, dont seulement un était dans le groupe C.

# Allograft reconstructions for chronic ruptures of the anterior cruciate ligament: augmentation versus non-augmentation

F. Steenbrugge • R. Verdonk • K. Verstraete

Received: 9 July 2001 / Accepted: 3 December 2001 / Published online: 20 April 2002 © Springer-Verlag 2002

F. Steenbrugge (✉) • R. Verdonk • Department of Orthopaedic Surgery and Trauma,  
UZ Gent, De Pintelaan 185, 9000 Gent, Belgium  
E-mail: Franky.Steenbrugge@rug.ac.be • Tel.: +0032-9-2402264 • Fax: +0032-9-2404975  
K. Verstraete • Department of Radiology, Ghent University, Hospital, 9000 Gent, Belgium

**Abstract** A retrospective study was performed to determine the effect of a ligament augmentation device (LAD) combined with a tendon allograft for the treatment of chronic rupture of the anterior cruciate ligament (ACL). Fifty-four knees in 54 patients were divided into two groups. Group 1 consisted of 29 knees that were managed with a tibialis anterior allograft alone, and group 2 consisted of 25 knees that were managed with both the allograft and a Kennedy LAD. All patients were managed with the same post-operative programme of immediate motion and rehabilitation of the knee. Forty patients returned for evaluation at a mean of 84 months post-operatively. Results were evaluated with the International Knee Documentation Committee (IKDC) grades, the Lysholm score, and the Tegner scale. Use of the LAD did not improve reconstruction with regard to any of the individual variables of the overall score. Although the LAD reduced anterior-posterior displacement effectively for the first 20 weeks post-operatively, there was no difference between the groups in terms of the percentage of knees that had abnormal displacement at the latest follow-up. The overall rate of failure was 20% (8) of the 40 knees.

**Keywords** Anterior cruciate ligament • Ligament augmentation device • Joint instability • Tendon allograft • Chronic instability

**Ligamentoplastie pour rupture chronique du ligament croisé antérieur par allogreffe: renfort synthétique ou non**

**Résumé** Nous avons effectué une étude rétrospective sur l'effet d'un renforcement ligamentaire synthétique (ligament augmentation device –LAD) sur le résultat des plasties du ligament croisé antérieur (LCA) par allo-greffe. Cinquante-quatre patients ont été divisés en deux groupes. Le groupe 1 consistait de 29 genoux réparés par allo-greffe et le groupe 2 consistait en 25 genoux réparés par allo-greffe et LAD. Tous les patients ont reçus le même programme postopératoire de mobilisation immédiate. Quarante patients ont été revus avec un recul moyen de 84 mois. L'évaluation a été faite avec le document de l'International Knee Documentation Committee (IKDC), le score de Lysholm, et le score de Tegner. Les résultats des reconstructions par allo-greffe et LAD n'étaient pas supérieurs par rapport aux reconstructions par allo-greffe seule. Le déplacement antéro-postérieur diminuait effectivement pour les premières 20 semaines post-opératoires. Néanmoins, il n'y avait plus de différence entre le pourcentage de genoux des deux groupes ayant un déplacement anormal au dernier rappel. L'échec général était de 20% (8) sur 40 genoux.

**Mots clés** Ligament croisé antérieur • Renforcement ligamentaire • Instabilité articulaire •

## Introduction

Acute anterior cruciate ligament (ACL) ruptures are often associated with injury to other ligaments of the knee, the menisci, or both. In combination with collateral ligament ruptures it has been found to further compromise stability [7,13,30,34]. Consequently, a direct correlation has been suggested between the complexity of the injuries associated with ACL rupture and the need for surgical repair or replacement.

It has been well documented that autogenous and allogenic grafts undergo a major decrease in strength during the early post-operative period due to necrosis of the tissue, softening from revascularisation, and remodelling [1,3,4,5,8,14,16,25,27]. Kennedy (1980) proposed the use of a ligament augmentation device (LAD) made of polypropylene braid (3 M, St Paul, MN, USA) in an effort to protect a healing autogenous patellar ligament reconstruction in the early post-operative period [15]. He hypothesised that load between the LAD and the biological graft would protect the graft during the period of degeneration and weakening, after which so-called collagenisation would eventually occur. The load would be transferred from the synthetic device to the autogenous graft gradually as the biological graft remodelled and became inherently stronger. The authors believed that the graft must carry a sufficient load to promote maturation. Kennedy, in two separate reports [15,16], stated that the polypropylene braid device for ligament augmentation had adequate tensile strength, fatigue, and creep properties for it to be used as an adjunct to reconstructions with autogenous patellar ligament grafts. Sheep, dog, and goat models have demonstrated that the augmentation of biological grafts with the device resulted in less anterior-posterior displacement than when the biological graft was used alone [8,32] and that the device did not affect the remodelling process of the biological graft.

We began to use allografts to treat chronic ACL ruptures in 1981, as has been reported previously [2,33].

Encouraged by early reports of success in animal models, and in an effort to increase the rate of success of allograft reconstruction in our patients, we initiated a prospective study of the use of a composite of the LAD and the allograft in knees that had a torn ACL [29]. The purpose of this retrospective study is to compare the results when allografts have been used in conjunction with an LAD.

## Patients and methods

### Patient selection

Fifty-four consecutive operations for the treatment of chronic rupture of the ACL were performed by the senior author (RV) between 1981 and 1990. Between November 1981 and December 1990 such reconstructions were done with an allograft alone; between July 1990 and August 1994 an LAD was used in conjunction with the allograft. Forty patients were left in the study. All of the patients returned for the evaluation at a mean of 84 (66–102) months.

Patients were divided into two groups according to the procedure that had been done. Group 1 consisted of the 29 patients described in an earlier report [33] in whom only an intra-articular replacement with an allograft had been done. Ten patients were lost to follow-up. Ten men and seven women were evaluated at an average of 94 (85–102) months after operation. The mean age at the time of follow-up was 39 (range 25–63) years. All cases were traumatic in origin: Four occurred in traffic accidents, one in a private setting, and the remaining 14 were sports-related (Table 1).

Prior to ACL reconstruction seven patients had undergone a partial lateral meniscectomy and one a partial medial meniscectomy (Table 2). No patient had undergone a previous ligamentous repair or reconstruction. Group 2 was composed of 25 consecutively managed patients in whom the intra-articular allograft replacement had been augmented with an LAD [29]. Twenty men and five women were evaluated at an average of 74 (66–98) months after operation. The mean age at the time of follow-up was 37 (range 23–55) years. All cases were traumatic in origin. Twenty (80%) had injured the knee during sports activities (Table 1). Prior to ACL reconstruction ten patients had already undergone one or more surgical interventions, mainly meniscal procedures, but no ligamentous reconstructions (Table 2).

**Table 1.** Traumatic aetiology

	Group 1	Group 2
Sports	15	20
Soccer	5	15
Ski	3	1
Handball	3	1
Basketball	3	2
Athletics	1	1
Work	0	5

**Table 2.** Previous surgery

	Group 1	Group 2
Lateral and medial meniscectomy	7	9
Medial meniscal suture	1	1
Ligamentous reconstructions	0	0

A patient was included in the study only if he or she had a complete rupture of the ACL, had not had an operative procedure for restoration of the lateral extra-articular iliotibial band restraints, and had been followed for at least 2 years after the index operation. All of the patients had positive Lachmann and pivot-shift tests, and all were found to have a complete rupture of the ACL at the operation. In young patients antero-lateral rotatory instability (ALRI) was an indication for a combined intra-articular and extra-articular reconstruction if they complained of instability during activities of daily living or expressed a strong wish to continue contact or pivot sports. Combined ALRI and antero-medial rotatory instability (AMRI) was treated with an intra-articular and a lateral extra-articular procedure augmented with suture of the medial collateral ligament (MCL) or reefing of the posterior oblique ligament (POL). This is a protocol designed for treatment in our department of ligamentous lesions. All patients were operated on for chronic ligamentous instability at least 8 weeks after injury (Table 3).

There were no differences between the two groups in terms of 15 variables, including age, time from injury to the index operation, results of pivot-shift and arthrometric testing, levels of sports activity, functional limitations, symptoms of pain and partial givingway, radiographic changes, or overall knee rating score before the index operation.

## Methods

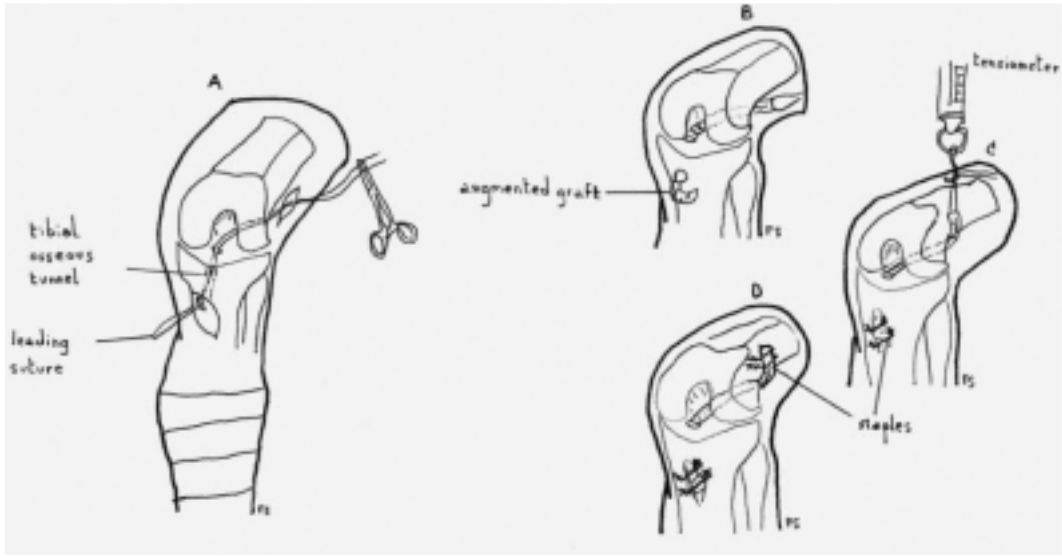
Under sterile conditions the allografts were harvested in the operating room within 12 h of death from general organ donors and screened for transmittable diseases. After bacteriological culture the tendon was stored at minus 80 C for a minimum of 14 days and a maximum of 6 months. We used only the tibialis anterior and posterior tendons with an LAD of 8 mm in width and 15 in in length. This was placed inside the transplant, which was closed in a cylinder along its entire length by a continuous resorbable suture.

The LAD was then fixed to the transplant by three or four resorbable sutures. The graft was implanted through a limited arthrotomy (double-incision technique). The LAD was tunneled into the joint from the medial side through a predrilled tibial bone hole just proximal to the pes anserinus attachment, to a point slightly anterior and medial to the centre of the ACL anatomic attachment.

**Table 3.** Associated procedures

	Group 1	Group 2
Partial medial meniscectomy	3	1
Medial meniscal	4	1
MCL suture-reefing-stapling	0	1

A heavy suture was threaded through the eye of a curved passer, which was driven into the joint cavity through the medial entry portal. The passer was brought through the intercondylar notch over the top of the lateral condyle. After opening the iliotibial band, and by elevating the vastus lateralis, the heavy leading suture was pulled through a 3–4 cm skin incision in the distal third of the thigh. The opposite end was passed from the joint cavity to the medial side of the tibia via the osseous tunnel, with the help of a hook. The graft was secured proximally with a staple. The distal end of the synthetic band was also fixed with a staple after preloading with the knee joint in 30 flexion (Fig. 1).



**Fig. 1.** Kennedy LAD anterior cruciate reconstruction. **a**, **b**, **c**, and **d** are different surgical steps of the technique. For more details see text

A number of patients in both groups were also treated for as-associated meniscal damage. Because the load in full extension was supported by the LAD during the early post-operative period, the LAD in double-end fixation was supposed to permit early post-operative functional treatment. Stress shielding prevents the allo-graft structure of the ACL reconstruction from being overloaded.

Full weightbearing of the operated knee joint was permitted immediately after the operation if there were no additional intra-articular lesions. Every patient had a custom-made brace with an extension block of 30 for a period of 6 weeks. Because the ligament is taut and fixed at 30 of flexion there is a post-operative limitation of extension. Rehabilitation aimed at correcting this flexion leads to stretching and possible rupture of the transplant.

The use of the brace was initiated because we believed that elongation of the graft should occur within limits for optimal healing and "ligamentisation".

In case of a combined intra-articular and extra-articular ligamentoplasty immediate mobilisation was initiated using continuous passive motion between 20 and 90 of flexion. Progressive dynamic rehabilitation and proprioceptive training were prescribed for 6 months. Return to sports was discouraged within the first 6 months; pivot and contact sports were not allowed within the first year. Surgical technique and post-operative rehabilitation programmes were identical in the non-augmented allograft group.

## Results

### Short-term results

For both groups five complications were noted in the early post-operative period. Two patients in group 1 and one in group 2 required a manipulation under anaes-thesia 6 months after the operation for a persistent flexion deformity. Tibial staples had to be removed after 6 months from one patient in each group because of irritation. There were no cases of deep infection, thrombosis, or persistent effusion.

### Medium-term results

If an intra-articular lesion was suspected, a repeat arthroscopy was performed (6 patients). Four ruptures of the reconstructed ligament were noted –two in both groups. They all occurred after a major injury (two sports, one traffic, and one work) between 2 and 6 years post-operatively. The other two patients (group 2) showed an intact reconstructed ACL, and in both cases a partial meniscectomy was performed.

### Evaluation

Knee performance was evaluated using the form of the International Knee Documentation Committee (IKDC), the Lysholm score, and the Tegner scale. The re-ruptures were excluded.

### Lysholm score

In group 1, nine patients had an excellent result (average 98), five good (average 84), one fair (70), and two poor (average 64). In group 2, 14 patients had an excellent result (average 96), five good (average 86), and four poor (average 76).

### *Tegner scale*

The mean level for sporting activities was 6.9 pre-operatively and 4.7 at evaluation in group 1, and 7.25 pre-operatively and 5.83 at evaluation in group 2. Most patients, being more than 40 years of age at evaluation, did not wish to return to their pre-injury sports level. The mean decrease of professional activities was 0.6 in group 1 and 0.5 in group 2.

### *Range of motion and laxity testing*

Laxity testing was performed using the KT-1000 arthrometer, using an antero-posterior force of 90 N pre-operatively and post-operatively [34]. Arthrometric data were assessed first by calculation of the percentage of knees that had a difference of less than 3 mm of displacement compared with the contralateral knee, those that had a difference of 3–5.5 mm, and those that had a difference of 6 mm or more. A second classification system was used to determine if the knees in which the displacement was 3–5.5 mm more than in the contralateral knee had a partially functioning reconstruction or a complete failure.

Partial function was defined as a correction of 50% or more and improvement of 3 mm or more compared with the pre-operative difference between displacement of the involved and uninvolved knees. Complete failure was defined as correction of less than 50% or improvement of less than 3 mm compared with the pre-operative value. A value of more than 5.5 mm was defined as a complete failure regardless of the improvement compared with the pre-operative value. Average range of flexion was 128 in group 1 and 131 in group 2. There were no patients with an extension lag. Satisfactory results were obtained on clinical medio-lateral laxity evaluation. Results are shown in Table 4.

**Table 4.** Laxity testing with the KT-1000 arthrometer using a force of 90 N

	<3 mm		>3 mm Group 1	<5 mm Group 2
	Group 1	Group 2		
AP neutral	14	18	3	5
Lachmann	4	8	2	3
Pivot	0	0	0	0
Medial laxity	0	0	0	0
Lateral laxity	0	0	0	0

### *IKDC form*

Four patients scored normal (grade A) in group 2. Nine patients scored nearly normal (grade B) in group 1 and 12 in group 2. Six patients scored abnormal (grade C) in group 1 and five in group 2. Two patients scored severely abnormal (grade D) in group 1 and group 2.

## **Discussion**

Allografts can be used for revisions and multiple reconstructions if autografts cannot be harvested. This procedure results in a shorter operating time, a smaller incision with arthroscopic techniques, and reduced post-operative donor site morbidity [14, 20, 22]. Synovitis is a serious problem associated with artificial ligaments [9, 28]. Tolerance of the Kennedy LAD was satisfactory since there were no cases of acute or chronic synovitis and no clinical or radiological signs. It is possible that some patients had a mild synovitis, and increasing effusion rates have been described over time using artificial ligaments [19, 24].

We used the IKDC scoring system because it is widely employed to report data in the current orthopaedic literature. The IKDC scoring system was designed in 1991 and modified 2 years later by 11 members of the American Orthopaedic Society for Sports Medicine (AOSSM) and ten members of the European Society for Knee Surgery and Arthroscopy (ESKA). There are eight categories of assessment, each of which has four grades: normal, nearly normal, abnormal, and severely abnormal. The worst grade determines the final evaluation. Grades for subjective assessment in the first four categories only count toward the final evaluation in patients with chronic ACL rupture. However, the lowest score in any of the categories will determine the final score and may not reflect knee function accurately. Therefore, we believe that the Lysholm score, although it is subjective and



optimistic in nature, added crucial information to the final evaluation.

Patients in both groups had good results on the Lysholm score: Six scored poorly (groups 1 and 2), probably because of their associated injuries. Results on the Tegner scale were good when corrected for age by asking patients for the sports level they actually desired to perform. Results of laxity testing were acceptable.

The re-ruptures in both groups were caused by a new severe trauma in patients with a good score at evaluation before the ACL rupture. Scorings on the IKDC form were debatable. Patients in both groups scoring severely abnormal (grade D) also had poor Lysholm scores: One was a multiple-injury patient with several associated lesions and another one showed markedly degenerative changes on X-rays. Three patients scored abnormal (grade C) because of a slight (1 mm) narrowing of the medial compartment on X-rays. Nevertheless, they had an excellent Lysholm score. This narrowing was probably caused by a medial meniscectomy in two of these patients [10,21,25].

Since the device is fixed at both ends and may thus function as a prosthesis, stress protection may have occurred, which could lead to increased laxity when the LAD eventually breaks. If the device was taking most of the load during our rehabilitation programme we feel that breakage would probably have occurred before the 2-year review. Comparison of our results with those of studies in which no reinforcements were used [6, 11, 18, 31, 35] is difficult because of differences in the study groups, the condition of the menisci, and the time elapsed between accident and intervention.

Noyes and Barber [23] studied the effect of the LAD on reconstructions using bone-patellar ligament-bone allografts. Patients were followed for a mean of 34 months and the failure rate was found to be 29% in non-augmented knees and 27% in the augmented group. They concluded that the addition of the LAD did not improve the results of allograft reconstruction. Our results show an overall failure rate of 20%. An antero-posterior displacement on laxity testing of more than 3 mm was considered a failure. We had two complications. The re-ruptures occurred after a major trauma and were therefore not regarded as complications. Our rehabilitation programme was similar in both groups and was designed to maximise the possible protective effect of the LAD. Fixation of the device at both ends should reduce the load on the graft by approximately one third [12].

In conclusion, previous and current studies place us in a dilemma with regard to the use of allografts in knees with a chronic ACL rupture. All studies show a highly significant improvement in the subjective ratings of symptoms, function, and activity levels, but the arthrometric data are neither satisfactory for the knees that have been treated with an allograft alone nor for those that have been treated with the allograft and the augmentation device.

Our results are in the same range as those of the longest follow-up studies of allografts with or without an augmentation device [17,23,26], although augmentation did give better early results than when no augmentation was performed [2, 17, 33]. Although strict IKDC scoring suggests average results of the allograft reconstruction technique, satisfactory results were achieved on the Lysholm and Tegner scale and on clinical examination after 6 years. Although the LAD has been shown to be effective in augmenting hamstring or medial quadriceps-periosteum autografts or allografts, which are inherently weaker than the bone-tendon-bone autografts, there is no evidence to support the value of the LAD with better techniques of graft selection and isometric graft positioning [17].

Nevertheless, we found it a valuable alternative to reconstruction with autografts, especially for knees with multiple ligament lesions and revision cases [33]. We no longer perform this operation through an arthrotomy but instead undertake it arthroscopically. The "over-the-top" technique has been abandoned because of its lack of isometry [26]. Implantation of allograft ligament material with or without an augmentation device as a substitute for the ACL has not induced clinically detectable rejection in this medium-term evaluation, nor at the time of writing—transmission of disease.

## References

1. Aglietti P, Buzzi R, D'Andria S, Zaccherotti G (1992) Long-term study of anterior cruciate ligament reconstruction for chronic instability using the central one-third patellar tendon and a lateral extra-articular tenodesis. *Am J Sports Med* 20: 38–45
2. Arnauw G, Verdonk R, Harth A, Moerman J, Vorlat P, Bataillie F, Claessens H (1991) Prosthetic versus tendon allo-graft replacement of ACL-deficient knees. *Acta Orthop Belg* 57: 67–74
3. Butler DL, Grood ES, Noyes FR, Olmstead ML, Hohn RB, Arnoczky SP, Siegel MG (1989) Mechanical properties of primate vascularized vs. nonvascularized patellar tendon grafts; changes overtime. *J Orthop Res* 7: 68–79
4. Cabaud HE, Feagin JA, Rodkey WG (1980) Acute anterior cruciate ligament injury and augmented repair. Experimental studies. *Am J Sports Med* 8: 395–401
5. Curtis RJ, Delee JC, Drez DJ (1985) Reconstruction of the anterior cruciate ligament with freeze-dried fascia lata allografts in dogs. A preliminary report. *Am J Sports Med* 13: 408–414
6. Dejour H, Walch G, Neyret P, Adeleine P (1988) Résultats des laxités chroniques antérieures opérées. A propos de 251 cas revus avec un recul minimum de 3 ans. *Rev Chir Orthop* 74: 622–636
7. Fetto JF, Marshall JL (1978) Medial collateral injuries of the knee: A rationale for treatment. *Clin Orthop* 132: 206–218
8. Fowler P, Amendola A (1990) Allograft ACL reconstruction in a sheep model—the effect of synthetic augmentation. *Trans Orthop Res Soc* 15:80
9. Fox J, Karzel R, Diefendorf D (1990) Four-year experience with the Gore-Tex prosthetic ligament in anterior cruciate deficient knees. In: Proceedings of the 57th annual meeting of the American Academy of Orthopaedic Surgeons, New Orleans
10. Friedrich NF, O'Brien WR (1993) Gonarthrose nach Verletzung des vorderen Kreuzbandes: Eine Multizenter-, Langezeitstudie. *Z Unfallchir Versicherungsmed* 86:81–89
11. Gacon G, Barba L, Lalain JJ, Laurenc, on M, Ray A (1992) Résultats à plus de dix ans de 54 plasties intra-articulaires du ligament croisé antérieur du genou. *Rev Chir Orthop* 78: 130–131
12. Hanley P, Lew WD, Lewis JL, Hunter RE, Kirstukas S, Kowalszyk C (1989) Load sharing and graft forces in anterior cruciate ligament reconstructions with the ligament augmentation device. *Am J Sports Med* 17: 414–422
13. Hughston JC, Barrett GR (1973) Acute anteromedial rotatory instability. *J Bone Joint Surg* 65-A: 145–152
14. Kartus J, Stener S, Lindahl S, Engstrom B, Eriksson BL, Karlsson J (1997) Factors affecting donor-site morbidity after anterior cruciate ligament reconstruction using bone-patellar tendon-bone autografts. *Knee Surg Sports Traumatol Arthrosc* 5: 222–228
15. Kennedy JC (1983) Application of prosthetics to anterior cruciate ligament and repair. *Clin Orthop* 172: 125–128
16. Kennedy JC, Roth JH, Mendenhall HV, Sanford JB (1980) Intraarticular replacement in the anterior cruciate ligament-deficient knee. *Am J Sports Med* 8: 1–8
17. Kumar K, Maffulli N (1999) The ligament augmentation device: a historical perspective. *Arthroscopy* 15: 422–432
18. Lerat JL, Dupré Latour L, Herzberg G, Moyen B (1987) Revue de 100 patients opérés pour laxité chronique antérieure du genou par un procédé dérivé des méthodes de Kenneth Jones et de MacIntosh. Intérêt de la radiographie dynamique pour l'analyse objective des résultats. *Rev Chir Orthop* 73: 201–204
19. Macnicol MF, Penny ID, Sheppard L (1991) Early results of the Leeds-Keio anterior cruciate

- ligament replacement. *J Bone Joint Surg* 73-B: 377–380
20. Marks PH, Cameron M, Fu FH (1993) Die Rekonstruktion der Kreuzbänder mit allogenen Transplantaten. *Techniken, Ergebnisse und Perspektiven Orthopäde* 22: 386–391
  21. McDaniel WJ, Dameron TB (1983) The untreated anterior cruciate ligament rupture. *Clin Orthop* 172: 158–163
  22. Nikolaou PK, Seaber AV, Glisson RR, Ribbeck BM, Bassett FH (1986) Anterior cruciate ligament allograft transplantation. Long-term function, histology, revascularization, and operative technique. *Am J Sports Med* 14: 348–360
  23. Noyes FR, Barber SD (1992) The effect of a ligament-augmentation device on allograft reconstructions for chronic ruptures of the anterior cruciate ligament. *J Bone Joint Surg* 74-A: 960–973
  24. Paulos L, Rosenberg J, Grewe S (1990) The Gore-Tex anterior cruciate ligament reconstruction: five-year follow-up. In: *Proceedings of the 57th annual meeting of the American Academy of Orthopaedic Surgeons, New Orleans*
  25. Sabiston P, Frank C, Lam T, Shrive N (1990) Allograft ligament transplantation. A morphological and biomechanical evaluation of medial collateral ligament complex in a rabbit model. *Am J Sports Med* 18: 160–168
  26. Saragaglia D, Leroy JM, De Sousa B, Tourne Y, Abu Al Zahab M (1995) Medium-term results of 173 ligamentoplasties of the anterior cruciate ligament using the MacIntosh technique reinforced by the Kennedy ligament augmentation device (LAD). *Knee Surg Sports Traumatol Arthrosc* 3: 68–74
  27. Shino K, Kawasaki T, Hirose H, Gotoh I, Inoue M, Ono K (1984) Replacement of the anterior cruciate ligament by an allogeneic tendon allograft. An experimental study in the dog. *J Bone Joint Surg* 66-B: 672–681
  28. Sledge S, Steadman J, Silliman J (1992) Five-year results with the Gore-Tex anterior cruciate ligament prosthesis. *Am J Sports Med* 5: 65–70
  29. Steenbrugge F, Verdonk R, Vorlat P, Mortier F, Verstraete K (2001) Repair of chronic ruptures of the anterior cruciate ligament using allograft reconstructions and a ligament augmentation device. *Acta Orthop Belg* 67: 252–258
  30. Sullivan D, Levy IM, Sheskier S (1984) Medial restraints to anterior-posterior motion of the knee. *J Bone Joint Surg* 66-A: 930–936
  31. Thuresson P, Sandberg R, Johansson O, Balkfors B, Westlin N (1996) Anterior cruciate ligament reconstruction with the patellartendon-augmentation ornot? A 2-year follow-up of 82 patients. *Scand J Med Sci. Sports* 6: 247–254
  32. Van Kampen CL, Mendenhall HV, McPherson GK (1987) Synthetic augmentation of biological anterior cruciate ligament substitutions. In: Jackson DW, Drez D (eds) *The anterior cruciate deficient knee. New concepts in ligament repair*. Mosby, St. Louis, pp 236–238
  33. Vorlat P, Verdonk R, Arnauw G (1999) Long-term results of tendon allografts for anterior cruciate ligament replacement in revision surgery and in cases of combined complex injuries. *Knee Surg Sports Traumatol Arthrosc* 7: 318–322
  34. Warren R, Marshall JL (1978) Injuries of the anterior cruciate and medial collateral ligaments of the knee. A long-term follow-up of 86 cases. *Clin Orthop* 136: 198–211
  35. Witvoet J, Kerboul L, Christel P (1991) Résultats à long terme (4–10 ans) de 88 ligamentoplasties intra-articulaires dans le traitement des instabilités antérieures chroniques du genou. *Rev Chir Orthop* 77: 156–157
  36. Wroble RR, Van Ginkel LA, Grood ES, Noyes FR, Shaffer BL (1990) Repeatability of the KT-1000 arthrometer in a normal population. *Am J Sports Med* 18: 396–399



CHAPTER VII  
DISCUSSION

## CHAPTER VII: DISCUSSION

A lot of water has been flowing under the bridges of Edinburgh since Thomas Annandale proposed meniscus suture 123 years ago. During the last 25 years the interest in meniscus suture has increased dramatically. This change has occurred partially because we know how essential the meniscus is for protecting the joint line against wear and partly we have learnt to use easier techniques.

Arguments that favour surgery are: youthful age of the patient, heavy manual labour or strenuous sports activity, high demands in terms of joint performance, inability or refusal to modify activities, preexisting meniscal and cartilage lesions, frequent instability with activities of normal living, recurrent swelling, feeling of instability 6 months after intensive rehabilitation, and previous identical lesion in the opposite knee with the same outcome (1,2,36,9,16,20). Conservative treatment is favoured in patients over 45 years of age and in less active patients with a sedentary job (25).

Long-term results of partial medial meniscectomy show good-to-excellent results in 60% of patients in stable knees, but only 48% of patients in partial lateral meniscectomy (4,13,14,15,22,23,24).

Radiological detectable degenerative changes can be seen in 24% of patients on long-term follow-up in case of a partial medial meniscectomy versus 40% of patients in case of a lateral partial meniscectomy (4,13,14,15,22,23,24).

Our studies have proven that in patients who underwent meniscal repair, the meniscus is either healed or acts as an autograft and fulfills the functional tasks of an uninjured meniscus, even after 13 years (27,28,29,30,31).

Recent reports support this finding (1,16,20).

Majewski et al.(2006) reported on the mid- and long-term results after arthroscopic suture repair of isolated, longitudinal, vertical tears in stable knees (20). This retrospective study included 88 patients with a follow-up of 5 to 17 years (mean 10 years). Scoring systems (Tegner, Lysholm) were comparable to our investigation. The success rate clinically was 72%. No MRI evaluation was done, but weightbearing X-rays showed signs of osteoarthritis in 71% of the patients.

However 65% of the patients showed no difference in the grade of osteoarthritis between the injured knee and the uninjured knee.

Jäger et al.(2000) investigated whether meniscal suture can prevent early development of arthrosis (6). Mean follow-up was 6.4 years. In only 21% of patients with an isolated tear and in 13% of those with a stable knee after a combined injury beginning of osteoarthritic changes were noted more than 5 years postoperatively. Early radiographic changes were present within 5 years postoperatively in unstable knees. Clinical scores however showed good results.

Ahn et al. (2004) looked into the results of arthroscopic meniscus repair in unstable knees.

They reviewed 39 patients of an original group of 78, operated between 1997 and 2001, using a second-look arthroscopy (1).

The success rate was 82% on complete healing and 15% on incomplete healing but without any positive findings of the clinical symptoms.

Our studies also showed that patients with meniscus repair in a stable knee can have good-to-excellent results in 85% of cases at long-term follow-up (27,28,29,30,31,32,33).

In case of meniscus repair in a knee with a reconstructed ACL, good-to-excellent results are seen in 73% of cases at long-term follow-up (27,28,29,30,31,32,33).

Meniscus repair in an unstable knee shows good-to-excellent results in 60% of cases at long-term follow-up (27,28,29,30,31,32,33).

In case of meniscus repair in a stable knee, 7% of patients will show radiological detectable degenerative changes at long-term follow-up (27,28,29,30,31,32,33).

Meniscus repair in ACL reconstructed knees shows radiological detectable degenerative changes in 15% of cases at long-term follow-up (27,28,29,30,31,32,33).

Meniscus repair in unstable knees results in radiological detectable changes in 31% of cases at long-term follow-up (27,28,29,30,31,32,33).

The failure rate of suturing is higher in the unreconstructed ACL patients. On clinical scoring, both groups in all studies do well to very good (1,16,20).

Therefore, meniscal suturing is not contraindicated in the ACL deficient knee (6,12,16,25,27,28,29,30,31). Concomittant repair of the ACL is recommended depending on patient activities and requirements.

Anterior cruciate ligament reconstruction can reduce the risk of secondary meniscus tears (7,17,28,29,30,31,32,33). Conservative treatment of ruptured ACL knees will lead to more meniscal lesions or reruptures of sutured menisci compared to reconstructed ACL knees (31) if the activity level includes sports, not in normal activities of daily living.

Therefore, meniscal suturing, if possible, is preferred over partial meniscectomy when performing reconstructive surgery for the ACL (7,17,29,31).

Although radiological examination shows clear signs of osteoarthritis on mid- and long-term follow-up in ACL reconstructed or non-ACL reconstructed knees, these patients have good clinical results (28,29,30,31,32,33).

Recent studies support our findings (2,6,7,8,9,12,17,21,34).

Meunier et al. (2007) reported on the long-term results after primary repair or non-surgical treatment of anterior cruciate ligament rupture in a randomized study with a 15-year follow-up (21). The study involved 100 patients randomly allocated to primary repair (augmented or non-augmented) or non-surgical treatment of the ruptured ACL. They found that ACL repair itself could not reduce the risk of osteoarthritis nor increase the subjective outcome scores.

If a meniscectomy was performed, two-thirds of the patients showed osteoarthritic changes regardless of the initial treatment of the ACL.

Cohen et al. (2007) reviewed 62 patients 10 to 15 years after ACL reconstruction. A significant association was found between arthrosis and meniscal injury (6). No difference was found between acute and chronic reconstructions.

Drogset et al. (2006) compared three surgical techniques for the treatment of acute ruptures of the anterior cruciate ligament at 16-year follow-up (8).

Osteoarthritis was found in 11% of patients at 16-years follow-up. Lysholm scoring showed good-to-excellent results.

Ait Si Selmi et al. (2006) looked at the evolution of osteoarthritis in 103 patients with ACL reconstruction at 17 years follow-up (2). Onset of osteoarthritis showed an association with the status of the meniscus. Knees with a preserved meniscus (healthy or sutured) had a significantly better radiological outcome. Again, nevertheless 88% of the patients had a good-to-excellent result on subjective scoring.

Hart et al. (2005) used single-photon emission computed tomography (SPECT) to determine the long-term risk of degenerative change after reconstruction of the anterior cruciate ligament at ten years (12). All patients of the group of 31 had good-to-excellent subjective results. Half of the patients had undergone a partial meniscectomy. The risk of developing osteoarthrosis was low in this series but a significant increase in degenerative change was seen in patients who had a reconstruction of their ACL and a partial meniscectomy compared to those who had a reconstruction and a meniscal suture or reconstruction alone.

Strand et al. (2005) evaluated 81 patients clinically and radiologically 15-23 years after primary repair of the ACL (25). Meniscal suturing was performed in 28 patients. Grade B osteoarthritic changes were seen in 42% of the patients, grade C changes in 9% of the patients and 1% had grade D changes. Of this group of patients with osteoarthritic changes, 40% had good-to-excellent function according to Lysholm scoring.

The development of osteoarthrosis was higher in older patients.

Dejour (1999) reviewed 148 patients after reconstructive surgery of the ACL with a 10 year follow-up (7). In case of a combined partial meniscectomy, 42% of patients developed early degenerative changes at follow-up. In case of a combined meniscal suture this was only 11%.

On IKDC scoring however, 89% of patients had good-to-excellent results.

Lerat (1995) evaluated 42 patients after medial meniscal suture associated with reconstruction of the ACL with a mean follow-up of 5 years (17). In 30 cases, arthrography was used at follow-up. Early degenerative signs on radiological examination were seen in 7.2% of patients. The overall success rate of the suturing was 73%. On IKDC scoring, 75% had good-to-excellent results.

To evaluate repaired menisci, MRI is the ideal diagnostic tool (12,30,35) although arthro-CT and arthro-MRI have proven their value too (18,35).

Today, there are three arthroscopic techniques for meniscal repair: the inside-out and outside-in suturing techniques and the all-inside technique, which uses biodegradable products and was developed originally by Albrecht-Olsen et al. (3) in 1993. Since then, a plethora of absorbable devices such as arrows, screws and anchors have been developed that allow for all-inside meniscal repair. Our studies showed no major differences in the clinical outcome between inside-out and all-inside using a bioabsorbable arrow (27,28,29,30,31).

The inside-out technique remains the gold standard (31).

Recent studies support our findings (11).

Hantes et al. (2006) conducted a comparative study between three different surgical techniques. They concluded that the inside-out technique is the technique to which all other techniques must be compared. Cost and device specific complications mainly make the difference (11).

Very few studies are available today on meniscal suturing or reconstructive surgery of the anterior cruciate ligament looking into the development of osteoarthritis at long-term follow-up. It remains difficult to compare the present studies, especially on reconstructive surgery of the ACL due to the different operative techniques used at the time of operation and the way the studies were conducted. Newer techniques and equipment have been developed so future studies have to show whether these reports stay consistent.

In conclusion, at long-term follow-up in clinically asymptomatic patients, the sutured meniscus is either histologically healed or acts as an autograft and fulfills the functional tasks of an uninjured meniscus.

Meniscus repair in a stable knee shows better clinical results at long-term follow-up compared to meniscus repair combined with reconstructive surgery of the ACL or meniscus repair in an unstable knee. Meniscal repair in unstable knees is not contra-indicated but concomitant ACL reconstruction is highly recommended.

Radiological imaging at long-term follow-up shows early degenerative changes in about 30% of patients in case of meniscus repair in an unstable knee.

Meniscus repair in ACL stable knees shows early degenerative changes to a lesser degree compared to ACL reconstructed knees.



Anterior cruciate ligament reconstruction combined with meniscus repair does not seem to prevent the development of osteoarthritis at long-term follow-up. It will prevent secondary meniscal tears or reruptures.

In terms of success rate of meniscus repair, the status of the ACL is the main prognostic factor (27,28,29,30,31,32,33) .

In terms of success rate of reconstructive surgery of the ACL towards prevention of early degenerative changes of the knee, the status of the meniscus is the main prognostic factor (27,28,29,30,31,32,33) .

Therefore, meniscal suturing is recommended when possible over partial meniscectomy.

## References

1. Ahn JH, Wang JH, Yoo JC. Arthroscopic all-inside repair of medial meniscus lesion in anterior cruciate ligament-deficient knees: results of second-look arthroscopies in 39 cases. *Arthroscopy* 2004; Nov (20)9: 936-945.
2. Ait Si Selmi T, Fithian S, Neyret P. The evolution of osteoarthritis in 103 patients with ACL reconstruction at 17 years follow-up. *Knee* 2006; Oct;13(5): 353-358.
3. Albrecht-Olsen P, Kristensen G, Törmälä P. Meniscus bucket-handle fixation with an absorbable Biofix tack: development of a new technique. *Knee Sports Traumatol Arthrosc*, 1993; 1: 104-106.
4. Andersson-Molina H, Karlsson H, Rockborn P. Arthroscopic partial and total meniscectomy: a long-term follow-up study with matched controls. *Arthroscopy* 2002; Feb 18(2): 183-189.
5. Chatain F, Adeleine P, Chambat P, Neyret P. A comparative study of medial versus lateral arthroscopic partial meniscectomy on stable knees: 10 years minimum follow-up. *Arthroscopy* 2003; Oct 19(8): 842-849.
6. Cohen M, Amaro JT, Ejnisman B. Anterior cruciate ligament reconstruction after 10 to 15 years: association between meniscectomy and osteoarthritis. *Arthroscopy* 2007; Jun 23(6): 629-634.
7. Dejour H, Dejour D, Ait Si Selmi T. Chronic anterior laxity of the knee treated with free patellar graft and extra-articular lateral plasty: 10-year follow-up of 148 cases. *Rev Chir Orthop Reparatrice Appar Mot* 1999 Dec; 85(8): 777-789.
8. Drogset JO, Grondtvedt T, Robak OR. A sixteen-year follow-up of three operative techniques for the treatment of acute ruptures of the anterior cruciate ligament. *J Bone Joint Surg Am* 2006 May; 88(5): 944-952.
9. Englund M, Roos EM, Lohmander LS. Impact of type of meniscal tear on radiographic and symptomatic knee osteoarthritis: a sixteen-year follow-up of meniscectomy with matched controls. *Arthritis Reum* 2003; 48: 2178-2187.
10. Fairbank TJ. Knee joint changes after meniscectomy. *J Bone Joint Surg (Br)* 1948; 30: 664-670.
11. Hantes M, Zachos VC, Vartimidis SE. Arthroscopic meniscal repair : a comparative study between three different surgical techniques. *Knee Surg Sports Traumatol Arthrosc* 2006; 14:1232-137.
12. Hart AJ, Buscombe J, Malone A, Dowd GS. Assessment of osteoarthritis after reconstruction of the anterior cruciate ligament: a study using single-photon emission computed tomography at ten years. *J Bone Joint Surg (Br)* 2005; Nov; 87(11): 1483-1487.
13. Hede A, Larsen E, Sandberg H. Partial versus Total meniscectomy. A prospective randomized study. *Ugeskr Laeger* 1994; Jan 3;156 (1): 48-52.

14. Hede A, Larsen E, Sandberg H. The long term outcome of open and partial meniscectomy related to the quantity and site of the meniscus removed. *Int Orthop* 1992; 16(2): 122-5.
15. Hulet C, Locker BG et al. Arthroscopic medial meniscectomy on stable knees. *J Bone Joint Surg Br* 2001; Jan 83(1): 29-32.
16. Jäger A, Starker M, Herresthal J. Can meniscus refixation prevent early development of arthrosis in the knee joint? Long-term results. *Zentralbl Chir* 2000; 125(6): 532-535.
17. Lerat JL, Imbert P, Moyon B, Besse JL, Brunet-Guedj E, Bochu M. Results of sutures of the internal meniscus associated with reconstruction of the anterior cruciate ligament in chronic knee joint instability. A propos of 42 cases, 30 of them controlled by arthrography. *Rev Chir Orthop Reparatrice Appar Mot* 1995; 81(6): 514-526.
18. Link TM, Steinbach LS, Ghosh S, Ries M, Lu Y, Lane N, Majumbar S (2003) Osteoarthritis: MR Imaging findings in different stages of disease and correlation with clinical findings. *Radiology* 2003; 226:373-381
19. Magee T, Shapiro M, Rodriguez J, Williams D. MR arthrography of postoperative knee: for which patients is it useful ? *Radiology* 2003 229:159-163.
20. Majewski M, Stoll R, Widmer H, Müller W, Friedrich NF. Midterm and long-term results after arthroscopic suture repair of isolated, longitudinal, vertical meniscal tears in stable knees. *Am J Sports Med* 2006; Jul 34(7): 1072-1076.
21. Meunier A, Odensten M, Good L. Long-term results after primary repair or non-surgical treatment of anterior cruciate ligament rupture: a randomized study with a 15-year follow-up. *Scand J Med Sci Sports* 2007; Jun 17(3): 320-327.
22. Pierre A, Hulet C et al. Outcome of 95 stable meniscal tears left in place after reconstruction of the anterior cruciate ligament. *Rev Chir Orthop Repar Appar Mot* 2001; Nov 87(7): 661-668.
23. Rockborn P, Gillquist J. Results of open meniscus repair. Long-term follow-up with a matched uninjured control group. *J Bone Joint Surg Br.* 2000; May 82 (4): 494-498.
24. Rockborn P, Messner K. Long- term results of meniscus repair and meniscectomy: a 13-year functional and radiographic follow-up study. *Knee Surg Sports Traumatol Arthrosc* 2000; 8(1): 2-10.
25. Roos H, Adalbrecht T, Dahlberg L, Lohmander LS. Osteoarthritis of the knee after injury to the anterior cruciate ligament or meniscus: the influence of time and age. *Osteoarthritis Cartilage* 1995; 3:261-267.
26. Siebold R, Dehler C, Boes L, Ellermann A. Arthroscopic all-inside repair using the Meniscus Arrow: long-term clinical follow-up of 113 patients. *Arthroscopy* 2007; Apr;23(4): 394-399.
27. Steenbrugge F, Corteel J, Verdonk R, Verstraete K. Evaluation à long-term de la réparation arthroscopique du ménisque. *Rev Chir Orthop* 2003; 89: 699-706.
28. Steenbrugge F, Van Nieuwenhuysse W, Verdonk R, Verstraete K. Arthroscopic meniscus repair in the ACL-deficient knee. *Int Orthop* 2005; 29: 109-112.
29. Steenbrugge F, Verdonk R, Verstraete K. Long-term assessment of arthroscopic meniscus repair: a 13-year follow-up study. *Knee* 2002; 9: 181-187.
30. Steenbrugge F, Verstraete K, Verdonk R. Magnetic resonance imaging of the surgically repaired meniscus. A 13-year follow-up study of 13 knees. *Acta Orthop Scand* 2004; 75(3): 323-327.
31. Steenbrugge F, Verdonk R, Hürel C, Verstraete K. Arthroscopic meniscus repair: inside-out technique vs. Biofix meniscus arrow. *Knee Surg Sports Traumatol Arthrosc* 2004; 12: 43-49.
32. Steenbrugge F, Verdonk R, Vorlat P, Mortier F, Verstraete K. Repair of chronic ruptures of the anterior cruciate ligament using allograft reconstruction and a ligament augmentation device. *Acta Orthop Belg* 2001; 67(3): 252-258.

33. Steenbrugge F, Verdonk R, Vertstraete K. Allograft reconstructions for chronic ruptures of the anterior cruciate ligament: augmentation versus non-augmentation. *Eur J Orthop Surg Traumatol* 2002; 12: 8-13.
34. Strand T, Molster A, Hordvik M, Krukhaug Y. Long-term follow-up after primary repair of the anterior cruciate ligament: clinical and radiological evaluation 15-23 years postoperatively. *Arch Orthop Trauma Surg* 2005; May 125(4): 217-221.
35. Totty WG, Matava MJ. Imaging the postoperative meniscus. *Magn Reson Imaging Clin N Am* 2000; 8:271-283.



## CHAPTER VIII

### SUMMARY

## CHAPTER VIII: SUMMARY

**The first paper** reports on the long-term follow-up of meniscus repair.

This encompasses an arthroscopic procedure. In this study an inside-out technique is used.

The indications, operative technique, complications and results are clearly presented.

In **the second paper**, the clinical results of two different suture techniques are presented and compared. The study shows that there is no significant difference in clinical results between the two techniques. The overall outcome at 6 years follow-up shows that 87% of patients had good-to-excellent results. Poor results or reruptures are seen in patients who had an unstable knee (anterior cruciate ligament rupture).

**The third paper** presents the results of arthroscopic meniscus repair in the anterior cruciate ligament deficient knee.

Two different groups are compared. In the first group meniscal repair is performed in an ACL intact knee, in the second group surgery is done in an ACL deficient knee. The mean follow-up is 9 years. Failures are more present in the ACL deficient group.

About ten patients in the first group have an MRI investigation at follow-up. The images show clear signs of degenerative changes, even a rerupture. Clinical results however, show in these cases good-to-excellent results.

It is concluded that although failure rate is higher in ACL deficient knees, meniscal repair is not contraindicated.

In **the fourth paper**, clinical as well as radiographic results of meniscal suturing are presented.

The radiographic evaluation is done by magnetic resonance imaging. Overall results show good clinical long-term results at 13 years follow-up in more than 75% of patients. The site of the previous suture is still visible. Signs of arthritis and cartilage degeneration are seen in 4 of 7 patients with an unrepaired ACL. Their clinical results however are good.

Asymptomatic meniscal tears produce abnormal MR signals even though they have stable unions, and that MR signals at the site of repair represent edematous scar tissue, not true nonunions.

Taken together, the clinical results of meniscal suturing are encouraging on long-term follow-up. Meniscal sutures in anterior cruciate deficient knees show more failures.

In clinically asymptomatic patients, the meniscus is either histologically healed or acts as an autograft and fulfills the biomechanical tasks of an injured meniscus.

Meniscus repair is not contraindicated in the ACL deficient knee but concomitant repair of the ACL is highly recommended.

**The fifth paper** reports on the reconstruction of chronic ruptures of the anterior cruciate ligament using allografts and a ligament augmentation device. The indications, operative technique and complications are clearly described. The augmentation device does not offer an additional advantage. Patients with partial meniscectomies and ACL repair show more degenerative changes on X-ray at 6 years follow-up compared to patients who had undergone meniscal suture or who had intact menisci. In this study, ACL reconstruction does not prevent the onset of osteoarthritis. The status of the meniscus at the time of surgery is a predictor for future development of osteoarthritis.

**The sixth paper** presents the results of allograft reconstructions for chronic ruptures of the anterior cruciate ligament and the use of a ligament augmentation device or not. The first group consists of 29 patients and the second group of 25 patients. Both groups include patients with previous meniscal injuries and partial meniscectomies. The study shows that the use of a ligament augmentation device does not offer an additional advantage. Reruptures in both groups occurred after a serious trauma.

X-rays at 7 years follow-up show clear degenerative changes in both groups. These changes are more intense in the patients with the partial meniscectomies. IKDC scoring shows poor results for those patients, but on more subjective scoring, they do good.

Taken together, injury to the anterior cruciate ligament, isolated or with associated injuries to the menisci or collateral ligaments leads to a high frequency of radiographic knee osteoarthritis.

Patients who had undergone ACL reconstruction, even with intact or repaired menisci show degenerative changes on X-ray or MRI at long-term follow-up.

Patients with pre-existing injuries or partial meniscectomies before or at the time of surgery, show clear signs of degenerative changes or osteoarthritis on X-ray or MRI at long-term follow-up. The changes are more outspoken compared to patients who had intact or repaired menisci at the time of surgery. When reconstructive surgery of the ACL is performed, meniscal suturing is preferred over partial meniscectomy when possible.

Despite poor radiographic scoring, these patients have good clinical results.

Most of the techniques described in these papers for reconstruction of the ACL have been modified since better equipment or fixation techniques have become available. Furthermore, it is difficult to compare results with other published data since there is a great discrepancy in the study designs. Few long-term follow-up studies on meniscus repair and cruciate ligament reconstruction and the relationship on developing osteoarthritis exist today. Future work should be focused to define whether the present techniques and equipment will offer better results at long-term follow-up.





CHAPTER IX  
SAMENVATTING

## CHAPTER IX: SAMENVATTING

**Het eerste artikel** geeft de resultaten van meniscus herstel op lange termijn weer.

De ingreep gebeurt via arthroscopische toegangsweg. De gebruikte techniek was een inside-out techniek. De indicaties, operatie techniek, complicaties en resultaten worden opgesomd.

**In het tweede artikel** worden de klinische resultaten van twee verschillende hechtingstechnieken met elkaar vergeleken. De studie toont aan dat er geen significant verschil is tussen de twee methodes. Na 6 jaar hebben 87% van de patiënten nog steeds goed tot uitstekende resultaten. Minder goede resultaten of herscheuren worden aangetroffen bij patiënten die een onstabiele knie hebben (voorste kruisband scheur).

**Het derde artikel** vermeldt de resultaten van arthroscopisch meniscusherstel bij patiënten met een gescheurde voorste kruisband (VKB). Twee groepen worden vergeleken. De eerste groep bestaat uit patiënten met meniscusherstel met een intacte VKB, de tweede groep bestaat uit patiënten met meniscusherstel met een gescheurde VKB. De patiënten werden gevolgd gedurende ongeveer 9 jaar. Er waren meer slechte resultaten in de groep met de gescheurde VKB. Ongeveer 10 patiënten werden ook onderzocht met een MRI scan. De beelden op MRI scan toonden duidelijke tekens van degeneratief lijden, zelfs een nieuwe scheur. De klinische resultaten waren bij deze patiënten nochtans goed tot uitstekend. De conclusie is dat alhoewel patiënten met een gescheurde VKB minder kans hebben op een goed resultaat, dit geen contra-indicatie hoeft te zijn voor herstel van de meniscus.

**Het vierde artikel** beschrijft de klinische en radiografische resultaten op MRI van meniscus herstel. De globale resultaten tonen goede klinische resultaten na 13 jaar in meer dan 75% van de patiënten. De plaats van de sutuur is nog steeds zichtbaar. Er zijn 7 patiënten met een gescheurde VKB en 4 ervan hebben duidelijke tekens van arthrose en kraakbeendegeneratie.

Hun klinisch resultaat is echter goed.

We zijn ervan overtuigd dat asymptomatische meniscusscheuren abnormale MR signalen geven ook al zijn ze eigenlijk stabiel. MR signalen thv. de sutuurplaats wijzen op oedemateus littekenweefsel maar niet op een echte non-union.

De klinische resultaten van meniscusherstel op lange termijn zijn bemoedigend. Er zijn meer nieuwe scheuren in kniën met een gescheurde VKB.

We zijn ervan overtuigd dat in klinisch asymptomatische patiënten de meniscus ofwel histologisch geheeld is ofwel functioneert als een autogreffe en de functionele taken vervult van een intacte meniscus. Meniscus herstel kan in een knie met een gescheurde VKB doch herstel van beide lijkt de beste behandeling.

**Het vijfde artikel** toont de resultaten van het gebruik van allogreffe en een versterkingsapparaat om een chronische ruptuur van de voorste kruisband te reconstrueren.

Indicaties, operatie techniek en complicaties worden duidelijk vermeld. Het versterkingsapparaat biedt geen duidelijke voordelen. Patiënten die een partiële meniscectomie hadden ondergaan alsook een reconstructie van de voorste kruisband toonden meer degeneratieve veranderingen op radiografische opnames. Uit deze studie blijkt dat reconstructie van de voorste kruisband de evolutie naar osteoarthrose niet tegenhoudt. De toestand van de meniscus op het ogenblik van de ingreep is een belangrijke predictor met het oog op verdere ontwikkeling van osteoarthrose.

**Het zesde artikel** geeft de resultaten weer van de reconstructie van chronische VKB letsels met een allogreffe, al of niet met een versterkingsapparaat. De ene groep omvat 29 patienten, de andere 25. In beide groepen zijn er patiënten met voorafbestaande meniscale letsels en partiële meniscectomiën. Ook hier blijkt dat het gebruik van een versterkingsapparaat geen voordelen biedt. Een nieuwe scheur van de VKB gebeurde telkens na een nieuw ernstig trauma. De radiografische opnames, 7 jaar na de ingreep, tonen duidelijke degeneratieve veranderingen in beide groepen. De veranderingen zijn meer uitgesproken bij de patiënten met een partiële meniscectomie. De IKDC score toont een matige score, maar een meer subjectieve score toont een goed resultaat.

VKB letsels, alleenstaand of samen met meniscusletsels of letsels van de collaterale ligamenten tonen een hoge frequentie van degeneratieve veranderingen op radiografische opnames. De patienten die een reconstructie van de VKB hadden ondergaan, zelfs met intacte of herstelde menisci, vertoonden ook tekens van osteoarthrose op RX of MRI bij controle op lange termijn. De patienten met voorafbestaande meniscale letsels of partiële meniscectomiën op het ogenblik van de ingreep vertonen duidelijke tekens van degeneratief lijden of osteoarthrose op RX of MRI beelden, duidelijk meer uitgesproken in vergelijking met patienten die intacte of gesutureerde menisci hadden.

Wanneer reconstructieve heelkunde van de VKB wordt verricht, dient meniscale sutuur boven partiële meniscectomie te worden verkozen. Deze patiënten hadden goede klinische resultaten in tegenstelling tot hun radiografische scores.

De meeste technieken beschreven in de artikels mbt. reconstructie van de voorste kruisband zijn ondertussen gemodificeerd aangezien er beter fixatie technieken en materieel beschikbaar zijn geworden. Bovendien is en blijft het moeilijk resultaten met andere gepubliceerde data te vergelijken vermits er een grote discrepantie bestaat in studie opzet tussen de verschillende studies. Heden ten dage bestaan er weinig studies omtrent reconstructieve chirurgie van de voorste kruisband en sutuur van de meniscus die de lange-termijn resultaten en de ontwikkeling van osteoarthrose beschrijven.

Toekomstige studies zullen moeten aantonen dat de huidige technieken betere resultaten kunnen bieden.



## APPENDIX

## **APPENDIX**

### **CLINICAL SCORING SYSTEMS**

Lysholm score

Tegner Activity Level Scale

Modified H.S.S

IKDC Scoring System

KOOS

## LYSHOLM SCORE

Naam:

Geb. dat:

### INSTABILITEIT

	Datum	
- nooit	25	_____
- soms bij sport	20	
- vaak bij sport	15	
- soms bij ADL	10	
- vaak bij ADL	5	
- elke stap	0	

### ZWELLING

- nooit	10	_____
- na zware belasting	6	
- in ADL	2	
- altijd	0	

### MANK LOPEN

- nooit	5	_____
- soms	3	
- altijd	0	

### SLOTVERSCHIJNSELEN

- nooit	15	_____
- klikken	10	
- soms	6	
- vaak	2	
- blokkade tijdens onderzoek	0	

### PIJN

- nooit	25	_____
- soms bij zware belasting	20	
- vaak bij zware belasting	15	
- bij een wandeling <2 km	5	
- altijd	0	

### TRAPLOPEN

- geen probleem	10	_____
- licht beperkt	6	
- tree voor tree	2	
- moeizaam	0	

### STEUN

- geen stok of kruk	5	_____
- soms	3	
- altijd	0	

### HURKEN

- geen probleem	5	_____
- licht beperkt	4	
- <90°	2	
- onmogelijk	0	

### TOTAALSCORE

\_\_\_\_\_

## TEGNER ACTIVITY LEVEL SCALE

Please indicate in the spaces below the **HIGHEST** level of activity that you participated in **BEFORE YOUR INJURY** and the highest level you are able to participate in **CURRENTLY**.

BEFORE INJURY: Level \_\_\_\_\_ CURRENT: Level \_\_\_\_\_

Level 10	Competitive sports- soccer, football, rugby (national elite)
Level 9	Competitive sports- soccer, football, rugby (lower divisions), ice hockey, wrestling, gymnastics, basketball
Level 8	Competitive sports- racquetball or bandy, squash or badminton, track and field athletics (jumping, etc.), down-hill skiing
Level 7	Competitive sports- tennis, running, motorcars speedway, handball  Recreational sports- soccer, football, rugby, bandy, ice hockey, basketball, squash, racquetball, running
Level 6	Recreational sports- tennis and badminton, handball, racquetball, down-hill skiing, jogging at least 5 times per week
Level 5	Work- heavy labor (construction, etc.)  Competitive sports- cycling, cross-country skiing,  Recreational sports- jogging on uneven ground at least twice weekly
Level 4	Work- moderately heavy labor (e.g. truck driving, etc.)
Level 3	Work- light labor (nursing, etc.)
Level 2	Work- light labor  Walking on uneven ground possible, but impossible to back pack or hike
Level 1	Work- sedentary (secretarial, etc.)
Level 0	Sick leave or disability pension because of knee problems

Y Tegner and J Lysolm. *Rating Systems in the Evaluation of Knee Ligament Injuries. Clinical Orthopedics and Related Research.* Vol. 198: 43-49, 1985.

### SURGICAL HISTORY

Have you had any additional surgeries to your knee other than those performed by Dr. Stone?

Yes / No

If Yes:

What procedure(s) were performed? \_\_\_\_\_

When was the surgery performed? \_\_\_\_\_

Who performed the surgery? \_\_\_\_\_



Modified HSS scoring system. The system is subdivided into a knee score that rates only the knee joint itself (max. 100 points). Flexion contracture, extension deficit and malalignment are dealt with as deductions. Additionally, a daily functional score (max 100 points) rates the patient's ability to walk (max. 50 points) and to climb stairs (max 50 points), with deductions for walking aids.

: the pains score and functional score of the modified HSS system were used for the survival analysis.

<b>KNEE SCORE</b>		<b>FUNCTION SCORE</b>	
<b>PAIN</b>	<b>POINTS</b>	<b>WALKING</b>	<b>POINTS</b>
None	50	unlimited	50
Mild or occasional	45	> 10 blocks	40
Stairs only	40	5-10 blocks	30
Walking & stairs	30	< 5 blocks	20
Moderate		housebound	10
Occasional	20	unable	0
Continual	10		
Severe	0		
<b>RANGE OF MOTION</b> (5°=1 point)	25	<b>STAIRS</b>	
		normal up & down	50
		normal up, down with rail	40
		up & down with rail	30
		up with rail, unable down	15
		unable	0
<b>STABILITY</b>		<b>SUBTOTAL</b>	
Anteroposterior	10	<b>DEDUCTIONS</b>	
<5mm	10	cane	5
5-10mm	5	two canes	10
10mm	0	crutche or walker	20
Mediolateral		<b>TOTAL DEDUCTIONS</b>	
<5°	15		
6°-9°	10		
10°-14°	5		
15°	0		
<b>SUBTOTAL</b>			
<b>DEDUCTIONS</b>			
Flexion contracture			
5°-10°	2		
10°-15°	5		
16°-20°	10		
>20°	15		
Extension lag			
<10°	5		
10°-20°	10		
>20°	15		
Alignment			
5-10°	0		
0-4°	3 points each degree		
11-15°	3 points each degree		
other	20		
<b>TOTAL DEDUCTIONS</b>			
<b>KNEE SCORE</b>	<b>/100</b>	<b>FUNCTION SCORE</b>	<b>/100</b>

**2000**

**IKDC**

**KNEE FORMS**

## INTRODUCTION

The entire IKDC form, which includes a MODEMS™ compatible demographic form, current health assessment form, subjective knee evaluation form, knee history form, surgical documentation form, and knee examination form, may be used as separate forms. Researchers who want to remain MODEMS™ compatible and use benchmarking data are required to complete the demographic form and current health assessment form. The knee history form and surgical documentation form are provided for convenience. All researchers are required to complete the subjective knee evaluation and knee examination form. Instructions for scoring the subjective knee evaluation form and the knee examination form are provided on the back of the forms.



## TABLE OF CONTENTS

- 1. Demographic Form**
- 2. Current Health Assessment Form**
- 3. Subjective Knee Evaluation Form**
- 4. Knee History Form**
- 5. Surgical Documentation Form**
- 6. Knee Examination Form**

## IKDC DEMOGRAPHIC FORM

**Your Full Name** \_\_\_\_\_

**Your Date of Birth** \_\_\_\_\_ / \_\_\_\_\_ / \_\_\_\_\_  
Day Month Year

**Your Social Security Number** \_\_\_\_ - \_\_\_\_ - \_\_\_\_ **Your Gender:**  Male  Female

**Occupation** \_\_\_\_\_

**Today's Date** \_\_\_\_\_ / \_\_\_\_\_ / \_\_\_\_\_  
Day Month Year

The following is a list of common health problems. Please indicate "Yes" or "No" in the first column, and then skip to the next item. If you do have the problem, please indicate in the second column if you receive medications or some other type of treatment for the problem. In the last column, indicate if the problem limits any of your activities.

	Do you have the problem?		Do you receive treatment for it?		Does it limit your activities?	
	Yes	No	Yes	No	Yes	No
Heart disease	<input type="checkbox"/>	<input type="checkbox"/>	<input type="checkbox"/>	<input type="checkbox"/>	<input type="checkbox"/>	<input type="checkbox"/>
High blood pressure	<input type="checkbox"/>	<input type="checkbox"/>	<input type="checkbox"/>	<input type="checkbox"/>	<input type="checkbox"/>	<input type="checkbox"/>
Asthma or pulmonary disease	<input type="checkbox"/>	<input type="checkbox"/>	<input type="checkbox"/>	<input type="checkbox"/>	<input type="checkbox"/>	<input type="checkbox"/>
Diabetes	<input type="checkbox"/>	<input type="checkbox"/>	<input type="checkbox"/>	<input type="checkbox"/>	<input type="checkbox"/>	<input type="checkbox"/>
Ulcer or stomach disease	<input type="checkbox"/>	<input type="checkbox"/>	<input type="checkbox"/>	<input type="checkbox"/>	<input type="checkbox"/>	<input type="checkbox"/>
Bowel disease	<input type="checkbox"/>	<input type="checkbox"/>	<input type="checkbox"/>	<input type="checkbox"/>	<input type="checkbox"/>	<input type="checkbox"/>
Kidney disease	<input type="checkbox"/>	<input type="checkbox"/>	<input type="checkbox"/>	<input type="checkbox"/>	<input type="checkbox"/>	<input type="checkbox"/>
Liver disease	<input type="checkbox"/>	<input type="checkbox"/>	<input type="checkbox"/>	<input type="checkbox"/>	<input type="checkbox"/>	<input type="checkbox"/>
Anemia or other blood disease	<input type="checkbox"/>	<input type="checkbox"/>	<input type="checkbox"/>	<input type="checkbox"/>	<input type="checkbox"/>	<input type="checkbox"/>
Overweight	<input type="checkbox"/>	<input type="checkbox"/>	<input type="checkbox"/>	<input type="checkbox"/>	<input type="checkbox"/>	<input type="checkbox"/>
Cancer	<input type="checkbox"/>	<input type="checkbox"/>	<input type="checkbox"/>	<input type="checkbox"/>	<input type="checkbox"/>	<input type="checkbox"/>
Depression	<input type="checkbox"/>	<input type="checkbox"/>	<input type="checkbox"/>	<input type="checkbox"/>	<input type="checkbox"/>	<input type="checkbox"/>
Osteoarthritis, degenerative arthritis	<input type="checkbox"/>	<input type="checkbox"/>	<input type="checkbox"/>	<input type="checkbox"/>	<input type="checkbox"/>	<input type="checkbox"/>
Rheumatoid arthritis	<input type="checkbox"/>	<input type="checkbox"/>	<input type="checkbox"/>	<input type="checkbox"/>	<input type="checkbox"/>	<input type="checkbox"/>
Back pain	<input type="checkbox"/>	<input type="checkbox"/>	<input type="checkbox"/>	<input type="checkbox"/>	<input type="checkbox"/>	<input type="checkbox"/>
Lyme disease	<input type="checkbox"/>	<input type="checkbox"/>	<input type="checkbox"/>	<input type="checkbox"/>	<input type="checkbox"/>	<input type="checkbox"/>
Other medical problem	<input type="checkbox"/>	<input type="checkbox"/>	<input type="checkbox"/>	<input type="checkbox"/>	<input type="checkbox"/>	<input type="checkbox"/>
Alcoholism	<input type="checkbox"/>	<input type="checkbox"/>	<input type="checkbox"/>	<input type="checkbox"/>	<input type="checkbox"/>	<input type="checkbox"/>

1. Do you smoke cigarettes?

- Yes
- No, I quit in the last six months.
- No, I quit more than six months ago.
- No, I have never smoked.

2. Your height \_\_\_\_\_  centimeters  inches

3. Your weight \_\_\_\_\_  kilograms  pounds

4. Your race (indicate all that apply)

- White  Black or African-American  Hispanic
- Asian or Pacific Islander  Native American Indian  Other

5. How much school have you completed?

- Less than high school  Graduated from high school  Some college
- Graduated from college  Postgraduate school or degree

6. Activity level

- Are you a high competitive sports person?
- Are you well-trained and frequently sporting?
- Sporting sometimes
- Non-sporting

## IKDC CURRENT HEALTH ASSESSMENT FORM \*

Your Full Name \_\_\_\_\_

Your Date of Birth \_\_\_\_\_/\_\_\_\_\_/\_\_\_\_\_  
Day      Month      Year

Today's Date \_\_\_\_\_/\_\_\_\_\_/\_\_\_\_\_  
Day      Month      Year

1. In general, would you say your health is: Excellent    Very Good    Good    Fair    Poor
2. Compared to one year ago, how would you rate your health in general now?
- Much better now than 1 year ago    Somewhat better now than 1 year ago    About the same as 1 year ago
- Somewhat worse now than 1 year ago    Much worse now than 1 year ago

3. The following items are about activities you might do during a typical day. Does your health now limit you in these activities? If so, how much?

	Yes, Limited A Lot	Yes, Limited A Little	No, Not Limited At All
a. Vigorous activities, such as running, lifting heavy objects, participating in strenuous sports	<input type="checkbox"/>	<input type="checkbox"/>	<input type="checkbox"/>
b. Moderate activities, such as moving a table, pushing a vacuum cleaner, bowling, or playing golf	<input type="checkbox"/>	<input type="checkbox"/>	<input type="checkbox"/>
c. Lifting or carrying groceries	<input type="checkbox"/>	<input type="checkbox"/>	<input type="checkbox"/>
d. Climbing several flights of stairs	<input type="checkbox"/>	<input type="checkbox"/>	<input type="checkbox"/>
e. Climbing one flight of stairs	<input type="checkbox"/>	<input type="checkbox"/>	<input type="checkbox"/>
f. Bending, kneeling or stooping	<input type="checkbox"/>	<input type="checkbox"/>	<input type="checkbox"/>
g. Walking more than a mile	<input type="checkbox"/>	<input type="checkbox"/>	<input type="checkbox"/>
h. Walking several blocks	<input type="checkbox"/>	<input type="checkbox"/>	<input type="checkbox"/>
i. Walking one block	<input type="checkbox"/>	<input type="checkbox"/>	<input type="checkbox"/>
j. Bathing or dressing yourself	<input type="checkbox"/>	<input type="checkbox"/>	<input type="checkbox"/>

4. During the past 4 weeks, have you had any of the following problems with your work or other regular daily activities as a result of your physical health?

	YES	NO
a. Cut down on the amount of time you spent on work or other activities	<input type="checkbox"/>	<input type="checkbox"/>
b. Accomplished less than you would like	<input type="checkbox"/>	<input type="checkbox"/>
c. Were limited in the kind of work or other activities	<input type="checkbox"/>	<input type="checkbox"/>
d. Had difficulty performing the work or other activities (for example, it took extra effort)	<input type="checkbox"/>	<input type="checkbox"/>

5. During the past 4 weeks, have you had any of the following problems with your work or other regular daily activities as a result of any emotional problems (such as feeling depressed or anxious)?

	YES	NO
a. Cut down on the amount of time you spent on work or other activities	<input type="checkbox"/>	<input type="checkbox"/>
b. Accomplished less than you would like	<input type="checkbox"/>	<input type="checkbox"/>
c. Didn't do work or other activities as carefully as usual	<input type="checkbox"/>	<input type="checkbox"/>

**Page 2 – IKDC CURRENT HEALTH ASSESSMENT FORM \***

6. During the past 4 weeks, to what extent has your physical health or emotional problems interfered with your normal social activities with family, friends, neighbors, or groups?

Not At All       Slightly       Moderately       Quite a Bit       Extremely

7. How much bodily pain have you had during the past 4 weeks?

None       Very Mild       Mid       Moderate       Severe       Very Severe

8. During the past 4 weeks, how much did pain interfere with your normal work (including both work outside the home and housework)?

Not at All       A Little Bit       Moderately       Quite a Bit       Extremely

9. These questions are about how you feel and how things have been with you during the past 4 weeks. For each question, please give the one answer that comes closest to the way you have been feeling. How much of the time during the past 4 weeks...

	All of the time	Most of the time	A good bit of the time	Some of the time	A little of the time	None of the time
a. Did you feel full of pep?	<input type="checkbox"/>	<input type="checkbox"/>	<input type="checkbox"/>	<input type="checkbox"/>	<input type="checkbox"/>	<input type="checkbox"/>
b. Have you been very nervous?	<input type="checkbox"/>	<input type="checkbox"/>	<input type="checkbox"/>	<input type="checkbox"/>	<input type="checkbox"/>	<input type="checkbox"/>
c. Have you felt calm and peaceful?	<input type="checkbox"/>	<input type="checkbox"/>	<input type="checkbox"/>	<input type="checkbox"/>	<input type="checkbox"/>	<input type="checkbox"/>
d. Did you have a lot of energy?	<input type="checkbox"/>	<input type="checkbox"/>	<input type="checkbox"/>	<input type="checkbox"/>	<input type="checkbox"/>	<input type="checkbox"/>
e. Have you felt down-hearted and blue?	<input type="checkbox"/>	<input type="checkbox"/>	<input type="checkbox"/>	<input type="checkbox"/>	<input type="checkbox"/>	<input type="checkbox"/>
f. Did you feel worn out?	<input type="checkbox"/>	<input type="checkbox"/>	<input type="checkbox"/>	<input type="checkbox"/>	<input type="checkbox"/>	<input type="checkbox"/>
g. Have you been a happy person	<input type="checkbox"/>	<input type="checkbox"/>	<input type="checkbox"/>	<input type="checkbox"/>	<input type="checkbox"/>	<input type="checkbox"/>
h. Did you feel tired?	<input type="checkbox"/>	<input type="checkbox"/>	<input type="checkbox"/>	<input type="checkbox"/>	<input type="checkbox"/>	<input type="checkbox"/>

10. During the past 4 weeks, how much of the time has your physical health or emotional problems interfered with your social activities (like visiting with friends, relatives, etc.)?

All of the time       Most of the time       Some of the time       A little of the time       None of the time

11. How TRUE or FALSE is each of the following statements for you?

	Definitely True	Mostly True	Don't Know	Mostly False	Definitely False
a. I seem to get sick a little easier than other people	<input type="checkbox"/>	<input type="checkbox"/>	<input type="checkbox"/>	<input type="checkbox"/>	<input type="checkbox"/>
b. I am as healthy as anybody I know	<input type="checkbox"/>	<input type="checkbox"/>	<input type="checkbox"/>	<input type="checkbox"/>	<input type="checkbox"/>
c. I expect my health to get worse	<input type="checkbox"/>	<input type="checkbox"/>	<input type="checkbox"/>	<input type="checkbox"/>	<input type="checkbox"/>
d. My health is excellent	<input type="checkbox"/>	<input type="checkbox"/>	<input type="checkbox"/>	<input type="checkbox"/>	<input type="checkbox"/>

\*This form includes questions from the SF-36™ Health Survey. Reproduced with the permission of the Medical Outcomes Trust. Copyright © 1992.

## 2000 IKDC SUBJECTIVE KNEE EVALUATION FORM

Your Full Name \_\_\_\_\_

Today's Date: \_\_\_\_/\_\_\_\_/\_\_\_\_  
Day Month Year

Date of Injury: \_\_\_\_/\_\_\_\_/\_\_\_\_  
Day Month Year

### **SYMPTOMS\*:**

\*Grade symptoms at the highest activity level at which you think you could function without significant symptoms, even if you are not actually performing activities at this level.

1. What is the highest level of activity that you can perform without significant knee pain?

- Very strenuous activities like jumping or pivoting as in basketball or soccer
- Strenuous activities like heavy physical work, skiing or tennis
- Moderate activities like moderate physical work, running or jogging
- Light activities like walking, housework or yard work
- Unable to perform any of the above activities due to knee pain

2. During the past 4 weeks, or since your injury, how often have you had pain?

Never    0    1    2    3    4    5    6    7    8    9    10    Constant  
                                           

3. If you have pain, how severe is it?

No pain    0    1    2    3    4    5    6    7    8    9    10    Worst pain  
                                                imaginable

4. During the past 4 weeks, or since your injury, how stiff or swollen was your knee?

- Not at all
- Mildly
- Moderately
- Very
- Extremely

5. What is the highest level of activity you can perform without significant swelling in your knee?

- Very strenuous activities like jumping or pivoting as in basketball or soccer
- Strenuous activities like heavy physical work, skiing or tennis
- Moderate activities like moderate physical work, running or jogging
- Light activities like walking, housework, or yard work
- Unable to perform any of the above activities due to knee swelling

6. During the past 4 weeks, or since your injury, did your knee lock or catch?

- Yes     No

7. What is the highest level of activity you can perform without significant giving way in your knee?

- Very strenuous activities like jumping or pivoting as in basketball or soccer
- Strenuous activities like heavy physical work, skiing or tennis
- Moderate activities like moderate physical work, running or jogging
- Light activities like walking, housework or yard work
- Unable to perform any of the above activities due to giving way of the knee



**SPORTS ACTIVITIES:**

8. What is the highest level of activity you can participate in on a regular basis?

- Very strenuous activities like jumping or pivoting as in basketball or soccer  
 Strenuous activities like heavy physical work, skiing or tennis  
 Moderate activities like moderate physical work, running or jogging  
 Light activities like walking, housework or yard work  
 Unable to perform any of the above activities due to knee

9. How does your knee affect your ability to:

		Not difficult at all	Minimally difficult	Moderately Difficult	Extremely difficult	Unable to do
a.	Go up stairs	<input type="checkbox"/>	<input type="checkbox"/>	<input type="checkbox"/>	<input type="checkbox"/>	<input type="checkbox"/>
b.	Go down stairs	<input type="checkbox"/>	<input type="checkbox"/>	<input type="checkbox"/>	<input type="checkbox"/>	<input type="checkbox"/>
c.	Kneel on the front of your knee	<input type="checkbox"/>	<input type="checkbox"/>	<input type="checkbox"/>	<input type="checkbox"/>	<input type="checkbox"/>
d.	Squat	<input type="checkbox"/>	<input type="checkbox"/>	<input type="checkbox"/>	<input type="checkbox"/>	<input type="checkbox"/>
e.	Sit with your knee bent	<input type="checkbox"/>	<input type="checkbox"/>	<input type="checkbox"/>	<input type="checkbox"/>	<input type="checkbox"/>
f.	Rise from a chair	<input type="checkbox"/>	<input type="checkbox"/>	<input type="checkbox"/>	<input type="checkbox"/>	<input type="checkbox"/>
g.	Run straight ahead	<input type="checkbox"/>	<input type="checkbox"/>	<input type="checkbox"/>	<input type="checkbox"/>	<input type="checkbox"/>
h.	Jump and land on your involved leg	<input type="checkbox"/>	<input type="checkbox"/>	<input type="checkbox"/>	<input type="checkbox"/>	<input type="checkbox"/>
i.	Stop and start quickly	<input type="checkbox"/>	<input type="checkbox"/>	<input type="checkbox"/>	<input type="checkbox"/>	<input type="checkbox"/>

**FUNCTION:**

10. How would you rate the function of your knee on a scale of 0 to 10 with 10 being normal, excellent function and 0 being the inability to perform any of your usual daily activities which may include sports?

FUNCTION PRIOR TO YOUR KNEE INJURY:

Cannot perform daily activities    0   1   2   3   4   5   6   7   8   9   10    No limitation in daily activities

CURRENT FUNCTION OF YOUR KNEE:

Cannot perform daily activities    0   1   2   3   4   5   6   7   8   9   10    No limitation in daily activities

## Scoring Instructions for the 2000 IKDC Subjective Knee Evaluation Form

Several methods of scoring the IKDC Subjective Knee Evaluation Form were investigated. The results indicated that summing the scores for each item performed as well as more sophisticated scoring methods.

The responses to each item are scored using an ordinal method such that a score of 1 is given to responses that represent the lowest level of function or highest level of symptoms. For example, item 1, which is related to the highest level of activity without significant pain is scored by assigning a score of 1 to the response "Unable to Perform Any of the Above Activities Due to Knee" and a score of 5 to the response "Very strenuous activities like jumping or pivoting as in basketball or soccer". For item 2, which is related to the frequency of pain over the past 4 weeks, the response "Constant" is assigned a score of 1 and "Never" is assigned a score of 11.

The IKDC Subjective Knee Evaluation Form is scored by summing the scores for the individual items and then transforming the score to a scale that ranges from 0 to 100. **Note:** The response to item 10 "Function Prior to Knee Injury" is not included in the overall score. The steps to score the IKDC Subjective Knee Evaluation Form are as follows:

1. Assign a score to the individual's response for each item, such that lowest score represents the lowest level of function or highest level of symptoms.
2. Calculate the raw score by summing the responses to all items with the exception of the response to item 10 "Function Prior to Your Knee Injury"
3. Transform the raw score to a 0 to 100 scale as follows:

$$\text{IKDC Score} = \left[ \frac{\text{Raw Score} - \text{Lowest Possible Score}}{\text{Range of Scores}} \right] \times 100$$

Where the lowest possible score is 18 and the range of possible scores is 87. Thus, if the sum of scores for the 18 items is 60, the IKDC Score would be calculated as follows:

$$\text{IKDC Score} = \left[ \frac{60 - 18}{87} \right] \times 100$$

$$\text{IKDC Score} = 48.3$$

The transformed score is interpreted as a measure of function such that higher scores represent higher levels of function and lower levels of symptoms. A score of 100 is interpreted to mean no limitation with activities of daily living or sports activities and the absence of symptoms.

The IKDC Subjective Knee Score can still be calculated if there are missing data, as long as there are responses to at least 90% of the items (i.e. responses have been provided for at least 16 items). To calculate the raw IKDC score when there are missing data, substitute the average score of the items that have been answered for the missing item score(s). Once the raw IKDC score has been calculated, it is transformed to the IKDC Subjective Knee Score as described above.

## 2000 IKDC KNEE HISTORY FORM

Patient Name \_\_\_\_\_ Birthdate \_\_\_\_\_ / \_\_\_\_\_ / \_\_\_\_\_  
Day Month Year

Date of Injury \_\_\_\_\_ / \_\_\_\_\_ / \_\_\_\_\_ Date of Initial Exam \_\_\_\_\_ / \_\_\_\_\_ / \_\_\_\_\_ Today's Date \_\_\_\_\_ / \_\_\_\_\_ / \_\_\_\_\_  
Day Month Year Day Month Year Day Month Year

Involved Knee:  Right  Left

Contralateral:  Normal  Nearly Normal  Abnormal  Severely abnormal

Onset of Symptoms: (date) \_\_\_\_\_ / \_\_\_\_\_ / \_\_\_\_\_  
Day Month Year

Chief Complaint: \_\_\_\_\_

Activity at Injury:  ADL  Sports  Traffic  Work

Mechanism of Injury:

- Non-traumatic gradual onset  Traumatic non-contact onset  
 Non-traumatic sudden onset  Traumatic contact onset

### Previous Surgery:

Type of Surgery: (check all that apply)

Meniscal Surgery

- Medial meniscectomy  Lateral meniscectomy  
 Medial meniscal repair  Lateral meniscal repair  
 Medial meniscal transplant  Lateral meniscal transplant

Ligament Surgery

- ACL Repair  Intraarticular ACL reconstruction  Extraarticular ACL reconstruction  
 PCL Repair  Intraarticular PCL reconstruction  Posterolateral corner reconstruction  
 Medial collateral ligament repair/reconstruction  
 Lateral collateral ligament repair/reconstruction

Type of Graft

- Patella tendon graft  Ipsilateral  Contralateral  
 Single hamstring graft  
 2 Bundle hamstring graft  
 4 Bundle hamstring graft  
 Quadriceps tendon graft  
 Allograft  
 Other

Extensor Mechanism Surgery

- Patella tendon repair       Quadriceps tendon repair

Patellofemoral Surgery

- Extensor Mechanism Realignment

Soft Tissue Realignment

- Medial imbrication       Lateral release

Bone Realignment

Movement of the tibial tubercle

- Proximal       Distal       Medial       Lateral       Anterior

- Trochleoplasty

- Patellectomy

Osteoarthritis Surgery

- Osteotomy

- Articular Surface Surgery       Shaving       Abrasion       Drilling       Microfracture  
 Cell therapy       Osteochondral autograft transfer/mosaic-plasty       Other

Total number of previous surgeries \_\_\_\_\_

**Imaging Studies:**

- Structural       MRI       CT       Arthrogram

- Metabolic (Bone Scan)

Findings:

Ligament \_\_\_\_\_

Meniscus \_\_\_\_\_

Articular Cartilage \_\_\_\_\_

Bone \_\_\_\_\_

## 2000 IKDC SURGICAL DOCUMENTATION FORM

Patient's Name: \_\_\_\_\_ Date of Index Procedure: \_\_\_\_/\_\_\_\_/\_\_\_\_  
Day    Month    Year

Postoperative Diagnosis:

1. \_\_\_\_\_

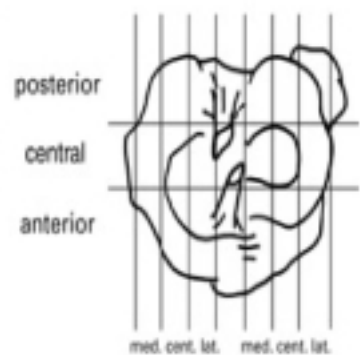
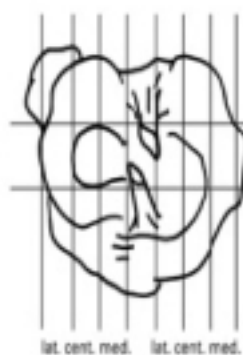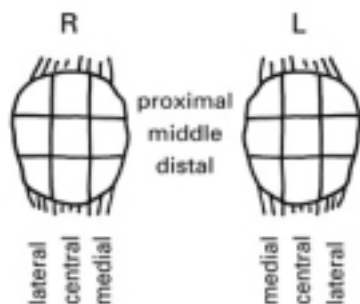
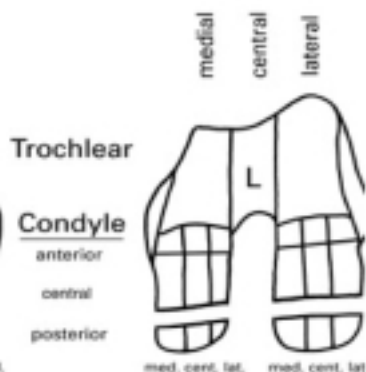
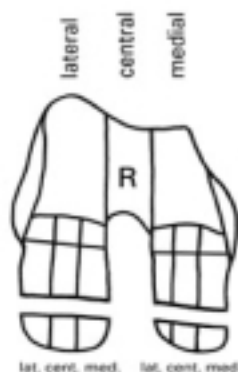
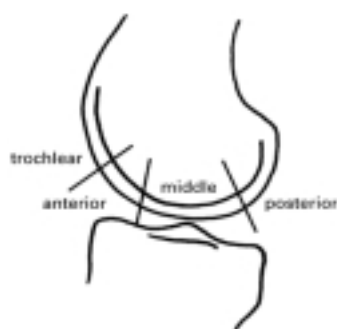2. \_\_\_\_\_

3. \_\_\_\_\_

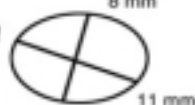Status After Procedure:

### ARTICULAR CARTILAGE STATUS:

Document the size and location of articular cartilage defects on these figures according to the ICRS mapping system<sup>6</sup>.



Measurement of the defect size



**Record size, location and grade of articular cartilage lesions.****Femur**

Side	Right	Left		
Condyle	Medial	Lateral		
Sagittal plane	Trochlear	Anterior	Middle	Posterior
Frontal plane	Lateral	Central	Medial	

Cartilage lesion (Grade) (\*)  
 Defect size pre-debridement  
 Defect size post-debridement


 mm  
 mm


 First Lesion


 Second Lesion

Normal



ICRS Grade 1 –

**Nearly Normal**

Superficial lesions. Soft indentation (A) and/or superficial fissures and cracks (B).



A B

ICRS Grade 2 –

**Abnormal**

Lesions extending down to <50% of cartilage depth.

**Tibia**

Side	Right	Left		
Plateau	Medial	Lateral		
Sagittal Plane	Anterior	Middle	Posterior	
Frontal Plane	Lateral	Central	Medial	

Cartilage lesion (Grade) (\*)  
 Defect size pre-debridement  
 Defect size post-debridement


 mm  
 mm



**Patella**

Side	Right	Left		
Sagittal plane	Distal	Middle	Proximal	
Frontal plane	Lateral	Central	Medial	

Cartilage lesion (Grade) (\*)  
 Defect size pre-debridement  
 Defect size post-debridement


 mm  
 mm



ICRS Grade 3 –

**Severely Abnormal**

Cartilage defects extending down >50% of cartilage depth (A) as well as down to calcified layer (B) and down to blisters are included in this Grade (C).



A B



C D

ICRS Grade 4 –

**Severely Abnormal**

Osteochondral injuries, lesions extending just through the subchondral boneplate (A) or deeper defects down into trabecular bone (B). Defects that have been drilled are regarded as osteochondral defects and classified as ICRS-C.



A B

**Diagnosis:**  Traumatic cartilage lesion  OOD  OA  AVN  Others

**Biopsy/Osteochondral Plugs:**

Location: \_\_\_\_\_ Number of Plugs: \_\_\_\_\_

Diameter of Plugs: \_\_\_\_\_ mm

**Treatment:**  Shaving  Abrasion  
 Drilling  Microfracture  
 Osteochondral autograft transfer/mosaic-plasty  
 Cell therapy  Other

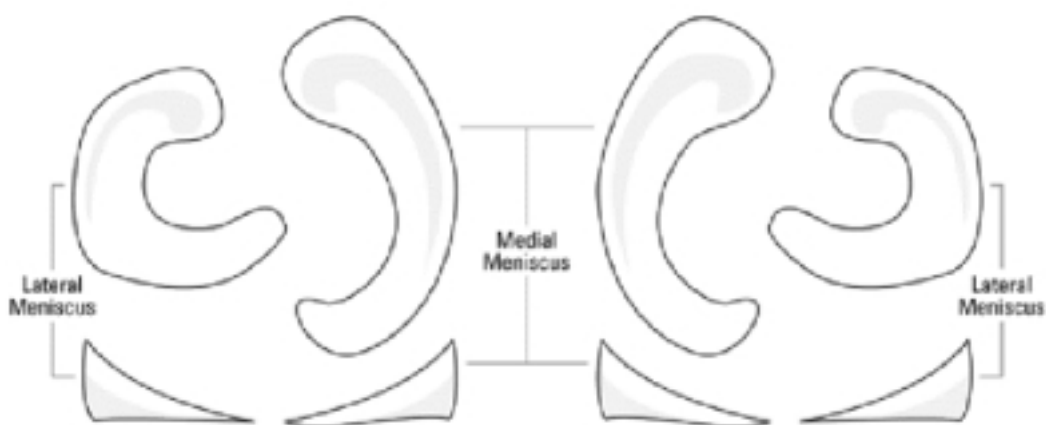
**Notes:**

**MENISCUS STATUS:**

- Procedure:  medial meniscectomy       lateral meniscectomy  
 medial meniscal repair       lateral meniscus repair  
 medial meniscal transplant       lateral meniscal transplant  
 medial abrade & trephine       lateral abrade & trephine

**Right Knee****Left Knee**

Document tears of the menisci or meniscectomy on these figures

**Medial:**

- Normal       1/3 Removed       2/3 Removed       3/3 Removed
- Circumferential Hoop Fibers:  Intact       Disrupted
- Remaining Meniscal Tissue:  Normal       Degenerative changes  
 Stable tear       Unstable tear  
 Tear left in situ

**Lateral:**

- Normal       1/3 Removed       2/3 Removed       3/3 Removed
- Circumferential Hoop Fibers:  Intact       Disrupted
- Remaining Meniscal Tissue:  Normal       Degenerative changes  
 Stable tear       Unstable tear  
 Tear left in situ

**LIGAMENT STATUS:**

Procedure:

- |  |  |  |
|--|--|--|
| <input type="checkbox"/> ACL repair  | <input type="checkbox"/> Intraarticular ACL reconstruction | <input type="checkbox"/> Extraarticular ACL reconstruction           |
| <input type="checkbox"/> PCL repair  | <input type="checkbox"/> Intraarticular PCL reconstruction | <input type="checkbox"/> Posterolateral corner repair/reconstruction |
| <input type="checkbox"/> Medial collateral ligament repair/reconstruction  |  |  |
| <input type="checkbox"/> Lateral collateral ligament repair/reconstruction |  |  |

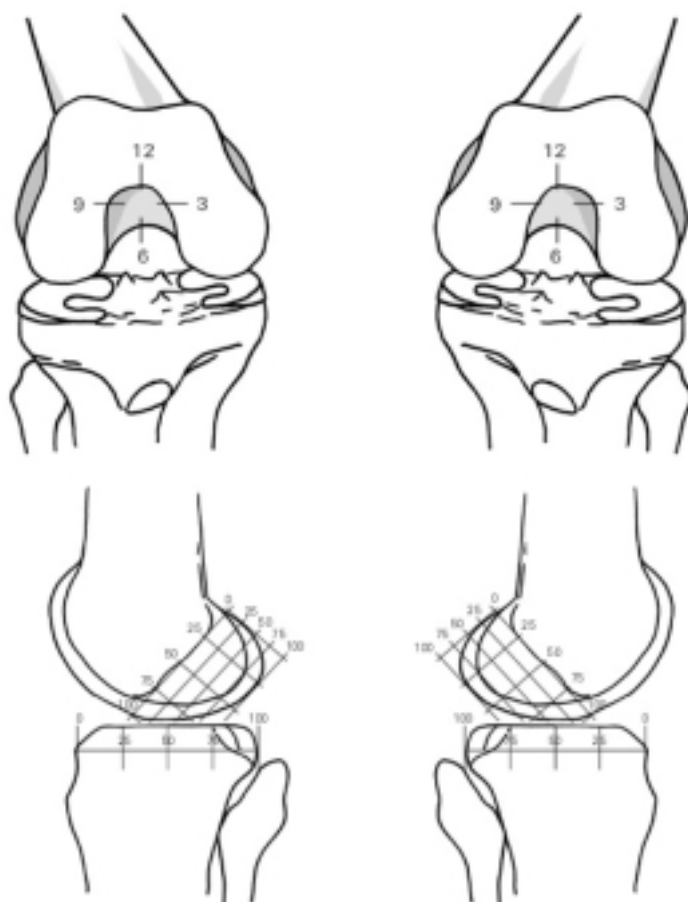
Graft:

- |  |  |  |
|--|--|--|
| <input type="checkbox"/> Autologous patella tendon | <input type="checkbox"/> Hamstring tendons | <input type="checkbox"/> Quadriceps tendon |
| <input type="checkbox"/> Other _____               |  |  |

Previous Graft Harvest:

- |  |  |  |
|--|--|--|
| <input type="checkbox"/> Autologous patella tendon | <input type="checkbox"/> Hamstring tendons | <input type="checkbox"/> Quadriceps tendon |
|--|--|--|

**Document drill hole placement for ligament reconstruction on these figures.**





**2000  
IKDC KNEE EXAMINATION FORM**

Patient Name: \_\_\_\_\_ Date of Birth: \_\_\_\_/\_\_\_\_/\_\_\_\_  
Day Month Year

Gender: ? F ? M Age: \_\_\_\_\_ Date of Examination: \_\_\_\_/\_\_\_\_/\_\_\_\_  
Day Month Year

Generalized Laxity: ? tight ? normal ? lax

Alignment: ? obvious varus ? normal ? obvious valgus

Patella Position: ? obvious baja ? normal ? obvious alta

Patella Subluxation/Dislocation: ? centered ? subleable ? subluxed ? dislocated

Range of Motion (Ext/Flex):  
 Index Side: passive \_\_\_\_/\_\_\_\_/\_\_\_\_ active \_\_\_\_/\_\_\_\_/\_\_\_\_  
 Opposite Side: passive \_\_\_\_/\_\_\_\_/\_\_\_\_ active \_\_\_\_/\_\_\_\_/\_\_\_\_

	SEVEN GROUPS				FOUR GRADES				*Group Grade			
	A	B	C	D	A	B	C	D	A	B	C	D
	Normal	Nearly Normal	Abnormal	Severely Abnormal								
<b>1. Effusion</b>	? None	? Mild	? Moderate	? Severe	? ? ? ?							
<b>2. Passive Motion Deficit</b>												
ΔLack of extension	? <3°	? 3 to 5°	? 6 to 10°	? >10°								
ΔLack of flexion	? 0 to 5°	? 6 to 15°	? 16 to 25°	? >25°	? ? ? ?							
<b>3. Ligament Examination</b> (manual, instrumented, x-ray)												
ΔLachman (25° flex) (134N)	? -1 to 2mm	? 3 to 5mm(1°)	? 6 to 10mm(2°)	? >10mm(3°)								
		? <-1 to -3	? <-3 stiff									
ΔLachman (25° flex) manual max Anterior endpoint:	? -1 to 2mm	? 3 to 5mm	? 6 to 10mm	? >10mm								
	? firm		? soft									
ΔTotal AP Translation (25° flex)	? 0 to 2mm	? 3 to 5mm	? 6 to 10mm	? >10mm								
ΔTotal AP Translation (70° flex)	? 0 to 2mm	? 3 to 5mm	? 6 to 10mm	? >10mm								
ΔPosterior Drawer Test (70° flex)	? 0 to 2mm	? 3 to 5mm	? 6 to 10mm	? >10mm								
ΔMed. Joint Opening (20° flex/valgus rot)	? 0 to 2mm	? 3 to 5mm	? 6 to 10mm	? >10mm								
ΔLat. Joint Opening (20° flex/varus rot)	? 0 to 2mm	? 3 to 5mm	? 6 to 10mm	? >10mm								
ΔExternal Rotation Test (30° flex prone)	? <5°	? 6 to 10°	? 11 to 19°	? >20°								
ΔExternal Rotation Test (90° flex prone)	? <5°	? 6 to 10°	? 11 to 19°	? >20°								
ΔPivot Shift	? equal	? +glide	? ++(clunk)	? +++(gross)								
ΔReverse Pivot Shift	? equal	? glide	? gross	? marked								
					? ? ? ?							
<b>4. Compartment Findings</b>												
ΔCrepitus Ant. Compartment	? none	? moderate	? mild pain	? >mild pain								
ΔCrepitus Med. Compartment	? none	? moderate	? mild pain	? >mild pain								
ΔCrepitus Lat. Compartment	? none	? moderate	? mild pain	? >mild pain								
<b>5. Harvest Site Pathology</b>	? none	? mild	? moderate	? severe								
<b>6. X-ray Findings</b>												
Med. Joint Space	? none	? mild	? moderate	? severe								
Lat. Joint Space	? none	? mild	? moderate	? severe								
Patellofemoral	? none	? mild	? moderate	? severe								
Ant. Joint Space (sagittal)	? none	? mild	? moderate	? severe								
Post. Joint Space (sagittal)	? none	? mild	? moderate	? severe								
<b>7. Functional Test</b>												
One Leg Hop (% of opposite side)	? ≥90%	? 89 to 76%	? 75 to 50%	? <50%								
<b>**Final Evaluation</b>					? ? ? ?							

\* Group grade: The lowest grade within a group determines the group grade.

\*\* Final evaluation: the worst group grade determines the final evaluation for acute and subsacute patients. For chronic patients compare preoperative and postoperative evaluations. In a final evaluation only the first 3 groups are evaluated but all groups must be documented. Δ Difference in involved knee compared to normal or what is assumed to be normal.

## INSTRUCTIONS FOR THE 2000 IKDC KNEE EXAMINATION FORM

The Knee Examination Form contains items that fall into one of seven measurement domains. However, only the first three of these domains are graded. The seven domains assessed by the Knee Examination Form are:

### 1. Effusion

An effusion is assessed by ballotting the knee. A fluid wave (less than 25 cc) is graded mild, easily ballotteable fluid – moderate (25-60 cc), and a tense knee secondary to effusion (greater than 60 cc) is rated severe.

### 2. Passive Motion Deficit

Passive range of motion is measured with a goniometer and recorded on the form for the index side and opposite or normal side. Record values for zero point/hyperextension/flexion (e.g. 10 degrees of hyperextension, 150 degrees of flexion = 10/0/150; 10 degrees of flexion to 60 degrees of flexion = 0/10/150). Extension is compared to that of the normal knee.

### 3. Ligament Examination

The Lachman test, total AP translation at 70 degrees, and medial and lateral joint opening may be assessed with manual, instrumented or stress x-ray examination. Only one should be graded, preferably a "measured displacement". A force of 134 N (30 lbs) and the maximum manual are recorded in instrumented examination of both knees. Only the measured displacement at the standard force of 134 N is used for grading. The numerical values for the side to side difference are rounded off, and the appropriate box is marked.

The end point is assessed in the Lachman test. The end point affects the grading when the index knee has 3-5 mm more anterior laxity than the normal knee. In this case, a soft end point results in an abnormal grade rather than a nearly normal grade.

The 70-degree posterior sag is estimated by comparing the profile of the injured knee to the normal knee and palpating the medial femoral tibial stepoff. It may be confirmed by noting that contraction of the quadriceps pulls the tibia anteriorly.

The external rotation tests are performed with the patient prone and the knee flexed 30° and 70°. Equal external rotational torque is applied to both feet and the degree of external rotation is recorded.

The pivot shift and reverse pivot shift are performed with the patient supine, with the hip in 10-20 degrees of abduction and the tibia in neutral rotation using either the Losee, Noyes, or Jakob techniques. The greatest subluxation, compared to the normal knee, should be recorded.

### 4. Compartment Findings

Patellofemoral crepitation is elicited by extension against slight resistance. Medial and lateral compartment crepitation is elicited by extending the knee from a flexed position with a varus stress and then a valgus stress (i.e., McMurray test). Grading is based on intensity and pain.

### 5. Harvest Site Pathology

Note tenderness, irritation or numbness at the autograft harvest site.

### 6. X-ray Findings

A bilateral, double leg PA weightbearing roentgenogram at 35-45 degrees of flexion (tunnel view) is used to evaluate narrowing of the medial and lateral joint spaces. The Merchant view at 45 degrees is used to document patellofemoral narrowing. A mild grade indicates minimal changes (i.e., small osteophytes, slight sclerosis or flattening of the femoral condyle) and narrowing of the joint space which is just detectable. A moderate grade may have those changes and joint space narrowing (e.g., a joint space of 2-4 mm side or up to 50% joint space narrowing). Severe changes include a joint space of less than 2 mm or greater than 50% joint space narrowing.

### 7. Functional Test

The patient is asked to perform a one leg hop for distance on the index and normal side. Three trials for each leg are recorded and averaged. A ratio of the index to normal knee is calculated.

## KOOS KNEE SURVEY

Today's date: \_\_\_\_/\_\_\_\_/\_\_\_\_ Date of birth: \_\_\_\_/\_\_\_\_/\_\_\_\_

Name: \_\_\_\_\_

**INSTRUCTIONS:** This survey asks for your view about your knee. This information will help us keep track of how you feel about your knee and how well you are able to do your usual activities.

Answer every question by ticking the appropriate box, only one box for each question. If you are unsure about how to answer a question, please give the best answer you can.

### Symptoms

These questions should be answered thinking of your knee symptoms during the **last week**.

S1. Do you have swelling in your knee?

Never  Rarely  Sometimes  Often  Always

S2. Do you feel grinding, hear clicking or any other type of noise when your knee moves?

Never  Rarely  Sometimes  Often  Always

S3. Does your knee catch or hang up when moving?

Never  Rarely  Sometimes  Often  Always

S4. Can you straighten your knee fully?

Always  Often  Sometimes  Rarely  Never

S5. Can you bend your knee fully?

Always  Often  Sometimes  Rarely  Never

### Stiffness

The following questions concern the amount of joint stiffness you have experienced during the **last week** in your knee. Stiffness is a sensation of restriction or slowness in the ease with which you move your knee joint.

S6. How severe is your knee joint stiffness after first wakening in the morning?

None  Mild  Moderate  Severe  Extreme

S7. How severe is your knee stiffness after sitting, lying or resting **later in the day**?

None  Mild  Moderate  Severe  Extreme

## Pain

P1. How often do you experience knee pain?

Never  Monthly  Weekly  Daily  Always

What amount of knee pain have you experienced the **last week** during the following activities?

P2. Twisting/pivoting on your knee

None  Mild  Moderate  Severe  Extreme

P3. Straightening knee fully

None  Mild  Moderate  Severe  Extreme

P4. Bending knee fully

None  Mild  Moderate  Severe  Extreme

P5. Walking on flat surface

None  Mild  Moderate  Severe  Extreme

P6. Going up or down stairs

None  Mild  Moderate  Severe  Extreme

P7. At night while in bed

None  Mild  Moderate  Severe  Extreme

P8. Sitting or lying

None  Mild  Moderate  Severe  Extreme

P9. Standing upright

None  Mild  Moderate  Severe  Extreme

## Function, daily living

The following questions concern your physical function. By this we mean your ability to move around and to look after yourself. For each of the following activities please indicate the degree of difficulty you have experienced in the **last week** due to your knee.

A1. Descending stairs

None  Mild  Moderate  Severe  Extreme

A2. Ascending stairs

None  Mild  Moderate  Severe  Extreme

For each of the following activities please indicate the degree of difficulty you have experienced in the **last week** due to your knee.

A16. Heavy domestic duties (moving heavy boxes, scrubbing floors, etc)

None                      Mild                      Moderate                      Severe                      Extreme  
                                                                                       

A17. Light domestic duties (cooking, dusting, etc)

None                      Mild                      Moderate                      Severe                      Extreme  
                                                                                       

### Function, sports and recreational activities

The following questions concern your physical function when being active on a higher level. The questions should be answered thinking of what degree of difficulty you have experienced during the **last week** due to your knee.

SP1. Squatting

None                      Mild                      Moderate                      Severe                      Extreme  
                                                                                       

SP2. Running

None                      Mild                      Moderate                      Severe                      Extreme  
                                                                                       

SP3. Jumping

None                      Mild                      Moderate                      Severe                      Extreme  
                                                                                       

SP4. Twisting/pivoting on your injured knee

None                      Mild                      Moderate                      Severe                      Extreme  
                                                                                       

SP5. Kneeling

None                      Mild                      Moderate                      Severe                      Extreme  
                                                                                       

### Quality of Life

Q1. How often are you aware of your knee problem?

Never                      Monthly                      Weekly                      Daily                      Constantly  
                                                                                       

Q2. Have you modified your life style to avoid potentially damaging activities to your knee?

Not at all                      Mildly                      Moderately                      Severely                      Totally  
                                                                                       

Q3. How much are you troubled with lack of confidence in your knee?

Not at all                      Mildly                      Moderately                      Severely                      Extremely  
                                                                                       

Q4. In general, how much difficulty do you have with your knee?

None                      Mild                      Moderate                      Severe                      Extreme  
                                                                                       

Thank you very much for completing all the questions in this questionnaire.



## ACKNOWLEDGEMENTS

Professor Verdonk, Beste René, ik wil u eerst en vooral bedanken voor alle kansen die u mij gegeven hebt. Een kans tot specialisatie in de orthopedische chirurgie, een kans tot het schrijven van deze thesis. Bedankt ook voor alle advies en steun tijdens het tot stand komen van dit avontuur dat eigenlijk bijna 19 jaar geleden begon. Ik hoop dat ik u met dit resultaat niet ontgoocheld heb!

Professor Verstraete, Beste Koenraad, ik heb bewondering voor uw eindeloos geduld waarmee u steeds weer de MRI beeldjes bekeek, op zoek naar gegevens en details die de vorige keer misschien net niet waren opgemerkt. Dank ook aan u omwille de kennis en kunde die u ter beschikking stelde tijdens het tot stand komen van deze thesis!

Lieve ouders, als ik naar het leeftijdsverschil met mijn broer en zus kijk, denk ik dat ik waarschijnlijk niet echt gepland was, maar daar was ik dan. Ik herinner me nog vaag de allereerste schooldag, 33 jaar geleden, en nu staan we hier. Dank u voor al de liefde, geduld, kansen en steun die ik van jullie gekregen heb en nog steeds krijg!

Dr. Verhelst, Dr. Van Nuffel, Dr. Raes , Beste Michiel, Jan en Rik, stagemeesters en vrienden van het eerste uur. Mijn verblijf in Tielt heeft een onuitwisbare impressie achtergelaten. Ik kan mij geen betere plaats bedenken om een opleiding te beginnen!

Dr. Van Overschelde, Dr. De Witte, Dr. Van Damme, Dr. Van Nieuwenhuysse, Dr. Claus, Beste Jacques, Eric, Raf, Wim en Bart, dank voor de opleiding die ik van jullie mocht genieten in Aalst en dank u voor de mogelijkheid die jullie mij gegeven hebben om deze prachtige dienst samen met jullie verder uit te bouwen!

Mr. Macnicol, Mr. Robb, Mr. Annan, Miss McBirnie and Mr. Hooper, Dear Malcolm, James, Ian, Julie and Geoffrey. I'm very much impressed and thankful for the expertise and knowledge you offered me. The Royal Hospital for Sick Children is a world renown center for state of the art medical care and surgery as well as for medical education and teaching. I was probably infected with the virus to write this thesis in Edinburgh. Beside all the surgery and science, you also let me discover your beautiful country Scotland!

Beste kennissen, vrienden, collega's en familie. Dank aan jullie om in de voorbije jaren een luisterend oor te hebben, begrip te tonen , tips te geven. Er waren momenten dat de inspiratie ver weg was en dat er enkel een zwart gat blaakte. Kleine woorden en gebaren helpen je dan weer op weg. Mijn bijzondere dank gaat uit naar Mevrouw Iris Wojtowicz van de dienst Orthopedie UZ Gent en Mevrouw Joke Rutsaert van de dienst Orthopedie ASZ Campus Aalst voor hun logistieke en morele ondersteuning. Deze thesis schrijven gaf me een Flandrien gevoel: plezierig als het vooruit gaat, vloeken als de fut er uit is, jezelf tegenkomen,vechten, doorgaan en een ongelooflijk gevoel als je de finish bereikt!



Last but not least, mijn echtgenote Sophie. We waren pas getrouwd of ik vertrok reeds naar Schotland voor een jaar. Toen ik de kriebel kreeg om aan deze thesis te beginnen waren we nog met ons tweetjes, toen met ons drietjes, vieren en nu zijn we vijf man sterk. Ik begrijp dat het niet altijd eenvoudig is geweest voor jou om dit alles te combineren maar ik ben blij dat ik je aan mijn zijde heb. Charlotte, Amélie en Cédric, jullie zijn mijn oogappels en de beste en mooiste inspiratiebron die ik mij kan wensen!



# CURRICULUM VITAE

## **PERSONALIA**

Name : Dr. Franky Steenbrugge MD FRCS Ed

Date of birth and place : Gent, 18/03/1969

Address : Landlede 24A

B-9451 Kerksken

Belgium

Married to: Roegies Sophie °08/01/1975

Children: Charlotte, Amélie, Cédric

Tel. : 0032-53-624294

Mobile: 0032495426007

Email : [franky.steenbrugge@telenet.be](mailto:franky.steenbrugge@telenet.be)

Belgian Medical Council Registration Number : 1-35133-85-480

## **EDUCATION**

Sint-Lievenscollege, Gent

### ***Medical Training at the State University of Ghent :***

Kandidaturen in de Geneeskundige Wetenschappen : 1987-1990

Doctoraten in Genees-, Heel-, en Verloskunde : 1990-1994

### ***Postacademic education :***

#### ***Ghent University***

Radiation protection for medical diagnostic purposes (1998)

#### ***The Royal College of Surgeons of Edinburgh***

Fellow of the Royal College of Surgeons of Edinburgh (2002)

#### ***The Royal College of Surgeons of Edinburgh & The American College of Surgeons***

Master's Degree in Orthopaedic Surgery (Master's Course in Orthopaedic Surgery organized by the Royal College of Surgeons of Edinburgh and the American College of Surgeons during the Quincentenary Congress of the Royal College of Surgeons of Edinburgh July 2005)

### ***Specialist Training in Orthopaedic Surgery and Traumatology :***

Head of Department: Prof. Dr. R. Verdonk, MD, PhD, UZ-Gent

### ***Training :***

1994-1996

Sint-Andriesziekenhuis, Krommewalstraat 9-11, B-8700 Tielt, West-Vlaanderen

Dr. R. Maurau, Dr. Vandesande ( Consultants General Surgery-Thoracic-Vascular Surgery)

Dr. M. Verhelst, Dr. J. Vannuffel, Dr. R. Raes (Consultants Orthopaedic Surgery and

Traumatology)

1996-1998

Aalsters Stedelijk Ziekenhuis, Merestraat 80, B-9300 Aalst, Oost-Vlaanderen  
Dr. J. Van Overschelde, Dr. E. De Witte, Dr. R. Van Damme, Dr. W. Van Nieuwenhuyse, Dr. B. Claus (Consultants Orthopaedic Surgery and Traumatology)  
1998-2000

University Hospital Ghent, De Pintelaan 185, B-9000 Gent, Oost-Vlaanderen  
Prof. Dr. R. Verdonk, Prof. Dr. D. Uyttendaele, Dr. P. Burssens, Dr. B. Poffyn, Dr. L. De Wilde, Dr. K. De Smet, Dr. W. Vanhove, Dr. N. Hollevoet (Consultants Orthopaedic Surgery and Traumatology)

***Princess Margaret Rose Orthopaedic Hospital, Edinburgh, Scotland:***

01/09/2000-06/02/2001

Hand Surgery and Traumatology : St.-John's Hospital at Howden, Department of Plastic Surgery, Howden Road West, Livingston, EH54 6PP  
Mr. G. Hooper, Consultant Orthopaedic and Hand Surgeon.

07/02/2001-07/08/2001

Paediatric Orthopaedics and Traumatology  
Royal Hospital for Sick Children, Sciennes Road, Edinburgh EH9 1LF  
Mr. M.F. Macnicol, Mr. J.E. Robb, Mr. I.H. Annan, Miss J. Mcbirnie, Consultant Orthopaedic Surgeons

**MEMBERSHIPS**

Belgische Vereniging voor Orthopedie en Traumatologie-Belgian Association of Orthopaedic Surgery and Traumatology (BVOT-BOTA)

Member Belgian Hand Group (BHG)

Member of the Belgian Knee Society (BKS)

Member of the British Society of Surgery of the Hand

Fellow of the Royal College of Surgeons of Edinburgh – FRCS Ed

Languages :

Dutch, English, French, German

**AWARDS**

1) Winner of the American Orthopaedic Association - Orthopaedica Belgica Travelling Fellowship Zimmer Award 2002 (15 May – 16 June)

Departments Visited :

Hamot Medical Center – Prof. Dr. John D. Lubahn – Erie, Pennsylvania  
University of Pittsburgh Medical Center - Prof. Dr. Freddie H. Fu – Pittsburgh, Pennsylvania  
Virginia Commonwealth University – Prof. Dr. Wilhelm A. Zuelzer – Richmond, Virginia  
University of Maryland – Prof. Dr. Vincent D. Pellegrini – Baltimore, Maryland John Hopkins  
Institute – Prof. Dr. Frank J. Frassica – Baltimore, Maryland Alfred I. duPont Institute – Prof. Dr.  
R. Bowen – Wilmington, Delaware University of Pennsylvania – Prof. Dr. John P. Dormans –  
Philadelphia, Pennsylvania Mount Sinai Medical Center – Prof. Dr. Dempsey S. Springfield –  
New York, New York Columbia University – Prof. Dr. Louis U. Bigliani – New York, New York

2) Winner of the Award of Best Paper for the 21st Congress of Sports Medicine of the AZ Sint-  
Jan Brugge 2002 (18 – 19 October) : "Arthroscopic meniscus repair: inside-out technique versus  
biofix meniscus arrow";

## **CURRENT POSITION**

Consultant Orthopaedic and Trauma Surgeon  
Department of Orthopaedics and Traumatology  
ASZ Aalst  
Merestraat 80  
B-9300 Aalst  
Belgium

## **PUBLICATIONS IN NATIONAL AND INTERNATIONAL JOURNALS**

### 1) *Meniscle letsels: resectie, sutuur of transplant ? (Dutch)*

Tijdschrift voor Geneeskunde 1994, 50(3): 205-208.

R. Verdonk, C. De Meulemeester, F. Steenbrugge, H. Claessens

### 2) *Tendon allograft replacement of ACL deficiënt knees (A five year follow-up)*

Acta Orthop Traumatol Turc 1994, 28(5): 328-329.

W. Degraeve, F. Steenbrugge, K. Pierets, N. Hollevoet, R. Verdonk

### 3) *Viable meniscal allografts: 25 cases with a 1 to 5-year follow-up*

Journal of Bone and Joint Surgery 1995, 77-B: 186 (Orthopaedic Proceedings, Supplement II).

R. Verdonk, F. Steenbrugge, G. Verbruggen

### 4) *Meniscal Suturing: a 7-year follow-up study. MR-imaging correlated with clinical findings in 20 patients*

Journal of Bone and Joint Surgery 1995, 77-B: 186 (Orthopaedic Proceedings, Supplement II).

R. Verdonk, F. Steenbrugge, D. Meire

### 5) *Seidel Nailing*

Acta Orthopaedica Belgica 1995, 61: 207.

Y. Claessens, J. Van Overschelde, W. De Groote, C. De Meulemeester, F. Steenbrugge

- 6) Displaced femoral neck fractures in adult and elderly patients, pitfalls in treatment options: Internal fixation or replacement ?  
Folia Traumatologica Belgica 2000, 1: 6-9.  
F. Steenbrugge, K. Govaers, W. Van Nieuwenhuijse, J. Van Overschelde
- 7) Displaced femoral neck fractures in adult and elderly patients, pitfalls in treatment options: Internal fixation or replacement ? (Turkish)  
Acta Orthopaedica et Traumatologica Turcica 2000, 34: 430-433.  
F. Steenbrugge, K. Govaers, W. Van Nieuwenhuijse, J. Van Overschelde
- 8) Recurrent massive subperiosteal hematoma in a patient with neurofibromatosis  
European Radiology 2001, 11: 480-483.  
F. Steenbrugge, K. Verstraete, B. Poffyn, D. Uyttendaele, R. Verdonk
- 9) Neurofibromatosis, gigantism, recurrent subperiosteal hematoma in patient: a new case report and review of the literature  
Acta Orthopaedica Belgica 2001, 67(2): 168-172.  
F. Steenbrugge, B. Poffyn, D. Uyttendaele, R. Verdonk, K. Verstraete
- 10) Repair of chronic injuries of the anterior cruciate ligament using an allograft and a ligament augmentation device  
Acta Orthopaedica Belgica 2001, 67(3): 252-258.  
F. Steenbrugge, R. Verdonk, P. Vorlat, F. Mortier, K. Verstraete
- 11) Parosteal osteosarcoma of the humerus: a case report  
Acta Orthopaedica Belgica 2001, 67(4): 387-394.  
F. Steenbrugge, B. Poffyn, D. Uyttendaele, R. Verdonk, K. Verstraete
- 12) Pitfalls and guidelines in the treatment of supracondylar fractures of the elbow in children  
Current Orthopaedics 2001, 15: 214-219.  
F. Steenbrugge, M.F. Macnicol
- 13) Low contact stress knee prosthesis system: 6 to 8 years of experience  
Journal of Bone and Joint Surgery 2001, 83-B: 217 (Orthopaedic Proceedings, Supplement II).  
E. Jansseghers, F. Steenbrugge, F. Almqvist, P. Byn, K. Verheye, R. Verdonk
- 14) Long-term assessment of arthroscopic meniscus repair; A 13-year follow-up study  
Journal of Bone and Joint Surgery 2001, 83-B: 218 (Orthopaedic Proceedings, Supplement II).  
F. Steenbrugge, R. Verdonk, K. Verstraete
- 15) La suture méniscale  
Journal de la Traumatologie du Sport 2001, 18: 198-200.  
R. Verdonk, F. Steenbrugge
- 16) Arthroscopic meniscus repair: inside-out technique versus Biofix meniscus repair  
Congressbook Brusport 2002: 141-150.  
F. Steenbrugge, R. Verdonk

17) Osteochondritis dissecans following Perthes' disease: a cause of concern?

Acta Orthopaedica Belgica 2002, 68(5): 485-489.

F. Steenbrugge, M.F. Macnicol

18) Long -term assessment of arthroscopic meniscus repair: a 13-year follow-up study

The Knee 2002, Sep 9(3): 181-187.

F. Steenbrugge, R. Verdonk, K. Verstraete

19) Allograft reconstructions for chronic ruptures of the anterior cruciate ligament: augmentation versus non-augmentation

European Journal of Orthopaedics and Traumatology 2002, 12: 8-13.

F. Steenbrugge, R. Verdonk, K. Verstraete

20) Avascular necrosis of the head of the first metatarsal and atherosclerosis. A case report.

Foot and Ankle Surgery 2003, 9(1): 41-43.

F. Steenbrugge, E. Van Ovost, P. Burssens, K. Verstraete

21) Repair of complete acromioclavicular separations : hook- plate versus K-wiring

Folia Traumatologica Lovaniensa 2003: 14-17 (ISBN 90-803 659-9-8)

A. Monsaert, F. Steenbrugge et al.

22) Evaluation a long terme de la réparation arthroscopique du ménisque

Revue de Chirurgie Orthopédique et réparatrice de l'appareil moteur 2003 Dec 89(8): 699-706.

F. Steenbrugge, J. Corteel, R. Verdonk, K. Verstraete

23) Bassini's hernial repair and adductor longus tenotomy in the treatment of chronic groin pain in athletes

Acta Orthopaedica Belgica 2003, 69(1): 35-41.

K. Van der Donckt, F. Steenbrugge, R. Verdonk, M. Verhelst

24) Arthroscopic meniscus repair: inside-out technique versus Biofix meniscus repair

Knee Surgery Sports Traumatology Arthroscopy 2004, 12: 43-49.

F. Steenbrugge, R. Verdonk, K. Verstraete

25) Magnetic resonance imaging in surgically repaired menisci

Acta Orthopaedica Scandinavica 2004, 75(3): 323-327.

F. Steenbrugge, R. Verdonk, K. Verstraete

26) Arthroscopic meniscus repair in the ACL deficient knee

International Orthopaedics 2005, Apr 29(2): 109-112.

F. Steenbrugge, W. Van Nieuwenhuysse, R. Verdonk, K. Verstraete

27) Ochronosis of the knee. A case report and review of the literature

Knee Surg Sports Traumatol Arthrosc 2008, Feb 16(2): 182-184.

M. Raaijmakers, F. Steenbrugge, C. Dierickx



## BOOK CHAPTER

### The use of allografts in ACL reconstructions in the knee

R. Verdonk, F. Steenbrugge, P. Vorlat, E. Witvrouw, p 295-305

In "Pathologie Ligamentaire du Genou" by Landreau Ph, Christel P, Dijan P  
Springer Verlag France, Paris 2004 (ISBN 2-287-59733-6)

## POSTER PRESENTATIONS

### 1) MR imaging of meniscal sutures correlated with clinical findings in 20 patients

7th Congress of ESSKA, May 10-15, 1996, Budapest, Hungary

F. Steenbrugge, D. Meire, R. Verdonk

### 2) Magnetic resonance imaging of the surgically repaired meniscus: a 13-year follow-up study

9th Congress of ESSKA, 16-20 September 2000, London, UK

F. Steenbrugge, E. Van Oost, R. Verdonk

### 3) Long-term results of a ligament augmentation device in allograft reconstructions for chronic ruptures of the anterior cruciate ligament

9th Congress of ESSKA, 16-20 September 2000, London, UK

F. Steenbrugge, E. Van Oost, R. Verdonk

### 4) Magnetic resonance imaging of the surgically repaired meniscus: a 13-year follow-up study

ISAKOS Congress, 14-18 May 2001, Montreux, Switzerland

F. Steenbrugge, E. Van Oost, R. Verdonk

### 5) Long-term results of a ligament augmentation device in allograft reconstructions for chronic ruptures of the anterior cruciate ligament

ISAKOS Congress, 14-18 May 2001, Montreux, Switzerland

F. Steenbrugge, E. Van Oost, R. Verdonk

### 6) Long-term results of tendon allograft replacement with LAD in ACL-deficient knees

ISAKOS Congress, 14-18 May 2001, Montreux, Switzerland

P. Vorlat, R. Verdonk, F. Steenbrugge

### 7) Long-term results of tendon allograft replacement with LAD in ACL-deficient knees

Isakos Congress, 3-7 April 2005, Hollywood, Florida

R. Verdonk, F. Steenbrugge, P. Vorlat, K. Verstraete

## NATIONAL AND INTERNATIONAL PRESENTATIONS

### 1) Postgraduate Conferences, UZ-Gent

Classification of Spinal Fractures

26 October 1993

F. Steenbrugge, W. Degraeve

Meniscal Sutures: A 7-years follow-up study  
28 February 1995  
F. Steenbrugge

2) 2nd EFORT Congress, Munich, 4-7 July 1995

Viable meniscal allografts: 25 cases with a 1 to 5-year follow-up  
K. Van den Abeele, R. Verdonk, F. Steenbrugge, G. Verbruggen

Meniscal Suturing: a 7 - year follow-up study. MR imaging correlated with clinical findings  
in 20 patients  
F. Steenbrugge, R. Verdonk, D. Meire

3) Instructional Course: Meniscal Rupture: Leave it or fix it ?

Aula University of Ghent, 8 November 1996

Meniscal Sutures: a 7-year follow-up study. Correlation between MRI and arthroscopic findings  
F. Steenbrugge, R. Verdonk

4) BOTA, 7th Symposium of the Belgian Orthopaedic Trauma Association  
Brussels, 12 September 1998

Displaced femoral neck fractures in adults and the elderly, pitfalls in treatment options,  
fixation or replacement ?  
F. Steenbrugge, K. Govaers, W. Van Nieuwenhuyse, J. Van Overschelde.

5) Course Orthopaedica Belgica, Medical Imaging, 28 November 1998, Antwerp

Parosteal osteosarcoma of the humerus: a case report  
F. Steenbrugge, B. Poffyn, D. Uyttendaele, R. Verdonk

6) Callus-Belgian Association of Plaster Technicians, 1 April 2000, UZ-Gent

Foot and Ankle: an update. Fasciitis plantaris  
F. Steenbrugge

7) ABA Ostend 6 May 2000

Magnetic resonance imaging of the surgically repaired meniscus: a 13-year follow-up study  
F. Steenbrugge, R. Verdonk, W. Huysse, K. Verstaete

8) Clinical Conference 8th May 2001, Princess Margaret Rose Orthopaedic Hospital, Edinburgh,  
Scotland

Osteochondritis dissecans following Perthes' disease: a cause of concern ?  
F. Steenbrugge, M.F. Macnicol

9) 5th EFORT Congress, Rhodes, Greece, 3-7 June 2001

Long-term assessment of arthroscopic meniscus repair: a 13-year follow-up study  
F. Steenbrugge, R. Verdonk, K. Verstraete

Long-term results of a ligament augmentation device on allograft reconstructions for chronic rup-  
tures of the anterior cruciate ligament  
F. Steenbrugge, R. Verdonk, K. Verstraete

10) Annual Conference Aalst for physicians – September 2001

Rhizarthosis and its treatment

F. Steenbrugge

11) Brusport: the 21st Congress of Sports Medicine of the AZ Sint-Jan AV, 18-19 October 2002

Arthroscopic meniscus repair: inside-out technique versus Biofix meniscus repair

F. Steenbrugge, R. Verdonk

12) 3<sup>rd</sup> Combined meeting NVA-ABA Amsterdam Arena 28 May 2003

Arthroscopic meniscus repair: inside-out technique versus Biofix meniscus repair

F. Steenbrugge, R. Verdonk

13) Callus-Belgian Association of Plaster Technicians, 17 May 2003, ASZ Aalst

Foot deformities in children

F. Steenbrugge

14) Annual Conference Aalst for physicians – September 2003

Amputations of digits at the hand: treatment options

F. Steenbrugge

15) ESSKA, 11th Congress, 5-8 May 2004, Athens, Greece

Faculty Member: Use of allografts in ACL Reconstructions of the Knee

Invited Speaker

16) BVOT, 10-12 June 2004, Alden-Biezen, Belgium

Faculty Member-Belgian Knee Society

17) Annual Conference Aalst for physicians – September 2005

Südeck's atrophy at the hand

F. Steenbrugge

18) Annual Conference Aalst for physicians – September 2006

Minor hand trauma

F. Steenbrugge

19) Annual Conference Aalst for physicians – September 2007

Sportstrauma in children

F. Steenbrugge

## **COURSES**

1) AO - International

AO Basic Course, 1-6 December 1996, Davos - Switzerland

2) AO - International

AO Advanced Course, 7-12 December 1997, Davos - Switzerland

3) AO International

AO Hand Surgery Course, 27-29 October 1999, Tihange, Belgium

4) Northwick Park Institute For Medical Research

Microsurgery Workshop: 15-19 March 1999, London, UK

5) Edinburgh Trauma Course

Trauma Course, August 1999, Edinburgh, Scotland

6) Continental Surgeon's Course

11-18 June 2000, Nottingham, UK

7) Lister Postgraduate Institute

Hand Surgery Course, 12-14 March 2001, Edinburgh, Scotland

8) International Spring Trauma Course

Phlimzen, Switzerland, March 2002

9) Shoulder Surgery for Sports Injuries – Instructional Course and Cadaver Workshops

Department of Anatomy, Royal College of Surgeons, 4-5 September 2002, Dublin, Ireland

10) International Hip Meeting

Tenerife, Spain, May 2003

11) ICRAD Strassbourg – Advanced Course on meniscus and cruciate ligament repair

IRCAD Strassbourg France, September 2003

12) AO International

Rationale of Pelvic and Acetabular Fracture Care, 18-20 March 2004, Leuven, Belgium

13) ICRS Hands on course of cartilage repair

ICRS Congress, May 2004, Ghent, Belgium

14) Edinburgh Trauma Course

Trauma Course, August 2004, Edinburgh, Scotland

15) Rationale for Hip Resurfacement

Hip Resurfacement Course, October 2004, Ghent, Belgium

16) Hip Resurfacement Course

Hip Course, October 2004, London-Ontario, Canada

17) International Hip Meeting

Berlin, Germany, May 2005

18) Quincentenary Congress of the Royal College of Surgeons of Edinburgh  
Master's Course in Orthopaedic Surgery, Edinburgh, Scotland, July 2005

19) International Fall Trauma Conference  
Athens, Greece, October 2005

20) International Trauma Meeting  
Berlin, Germany, February 2006

21) UMC Advanced Course on cruciate ligament repair  
UMC Utrecht, Netherlands, June 2006

22) ISAKOS International Meeting  
Florence, Italy, May 2007

23) Cadaver Workshop MIS Hip Surgery  
Vienna, Austria, June 2007

24) FESSH Meeting  
Athens, Greece, June 2007

## **OTHER PRESENTATIONS**

1) BOTA, Brussels 30 April 1994.

Fractures of the pelvic ring

B. Van Innis, J. Vanhaecken, M. Vanderplaetsen, F. Steenbrugge, R. Verdonk

2) ESSKA, April 18 - 22, 1994 Berlin

Tendon allograft replacement of ACL - deficient knees. A four-year follow-up.

W. Degraeve, F. Steenbrugge, K. Pierets, R. Verdonk

3) Orthopedic Forum: October, November, December 1994 (Pfizer)

Meniscal Sutures: indications and results

R. Verdonk, F. Steenbrugge

4) Gerhard Kuntscher-Kreis, Osteosynthese International

Leuven, 15 - 17 September 1994

Intramedullary supracondylar nailing of distal femoral fractures

L. Cuyper, M. Vanderplaetsen, F. Steenbrugge, R. Verdonk

Intramedullary fixation of proximal third humeral fractures

R. Verdonk, C. De Meulemeester, F. Steenbrugge, H. Claessens

5) BOTA Spring Symposium, Leuven, 18 March 1995

Percutaneous reduction and fixation of calcaneal fractures

W. Van den Broucke, C. Sommeling, F. Steenbrugge, L. Haeck

6) European Congress of Radiology, Vienna, Austria, 1995

MRI of meniscal sutures in correlation with clinical findings seven years after repair  
D.Meire, K. Verstaete, F. Steenbrugge, W. Degraeve, R. Verdonk, M. Kunnen

7) ABA Tenth Anniversary Congress: Past, Present & Future in Arthroscopy  
Brughes, March 15-16, 1996

Meniscal Suturing: a 7-year follow-up study. MR imaging correlated with clinical  
findings in 20 patients  
F. Steenbrugge, W. Degraeve, R. Verdonk

8) Knee Conference Namur, Belgium 1999

The LCS Total Knee Prosthesis: the UZ-Gent experience  
E. Janseghers, F. Steenbrugge, F. Almqvist, P. Byn, K. Verheye, R. Verdonk

9) AO/ASIF Comprehensive Spine Course, 3-6 May 1999 Antwerp

Indications and techniques for anterior stabilization  
B. Poffyn, F. Steenbrugge, D. Uyttendaele

Anterior Cages-ALIF

B. Poffyn, F. Steenbrugge, D. Uyttendaele

10) 5th EFORT Congress, Rhodes, Greece, 3-7 June 2001

Low contact stress knee prosthesis system: 6 to 8 years of experience  
Janseghers, F. Steenbrugge, F. Almqvist, P. Byn, K. Verheye, R. Verdonk

**CONSULTANT REVIEWER OF INTERNATIONAL JOURNALS WITH  
PEER REVIEW**

- 1) Acta Orthopaedica Scandinavica
- 2) American Journal of Rheumatology
- 3) Medical Science Monitor
- 4) BioMed Central – Open Access Journals



