



Ghent University

Department of Rehabilitation Sciences and Physiotherapy

**ANATOMICAL AND FUNCTIONAL APPROACH OF THE
VERTEBRAL ARTERY IN THE OCCURRENCE OF SIDE AND
ADVERSE EFFECTS AFTER SPINAL MANIPULATION**

Barbara Cagnie

Thesis submitted in fulfilment of the requirements for the degree
of Doctor in Motor Rehabilitation and Physiotherapy

Ghent 2005

About the cover:

The giraffe (scientific name: *Giraffa camelopardalis*) is a striking animal with a huge neck, which is found most commonly in the semi-arid areas of dry savannahs and open woodlands of Africa, south of the Sahara. Besides the fact that this animal is my favourite, the giraffe was chosen on the cover because there are some similarities between this thesis and this beautiful animal.

This thesis focuses on the cervical region, which is also the reason why giraffes are so famous. The characteristic long neck consists of exactly the same number of vertebrae as all other mammals – seven – but each vertebra is extremely lengthened. You can imagine the size of the vertebral arteries, as they have to pump blood about 2.5 meters up to the brain, in order to prevent fainting.

Giraffe also makes sense of the expression, “to stick one's neck out”. Research in the field of complications after spinal manipulation is a risky business as this is a highly emotive subject.

Promotor:

Prof. dr. D. Cambier

Examination Board:

Dr. E. Barbaix

Prof. dr. D. Cambier

Prof. dr. L. Danneels

Prof. dr. K. D'Herde

Prof. dr. R. Dierckx

Prof. dr. E. Ernst (University of Exeter, UK)

Dr. F. Jacobs

Prof. dr. G. Vanderstraeten

Prof. dr. P. Van Roy (Vrije Universiteit Brussel)

Supervisory Committee:

Dr. E. Barbaix

Prof. dr. D. Cambier

Prof. dr. K. D'Herde

Prof. dr. R. Dierckx

Dr. F. Jacobs

TABLE OF CONTENTS

Introduction and outline of the thesis	1
Introduction	3
Outline	16
Part I: Occurrence of side and adverse effects after spinal manipulation	23
Chapter 1 Side and adverse effects of spinal manipulation	25
Chapter 2 How common are side effects of spinal manipulation and can these side effects be predicted?	37
Part II: Anatomical approach of the vertebral artery	53
Chapter 3 Extrinsic risk factors for compromised blood flow in the vertebral artery: anatomical observations of the transverse foramina from C3 to C7	55
Chapter 4 Atherosclerosis in the vertebral artery: an intrinsic risk factor in the use of spinal manipulation?	67
Chapter 5 Abnormalities in the course of the vertebral artery associated with an ossified hyoid chain. A contra-indication for manipulations of the cervical spine?	79
Chapter 6 A vertebral artery without atlantic and intradural sections. A case report and a review of the literature	93
Part III: Functional approach of the vertebral artery	103
Chapter 7 Changes in cerebellar blood flow after manipulation of the cervical spine using Technetium 99m-Ethyl Cysteinate Dimer	105
General discussion	117
Summary and clinical implications	119
Future directions	131
Final conclusions	132
Nederlandstalige samenvatting	137

ACKNOWLEDGEMENTS

The “making of” a thesis is not a ‘one-woman work’, but relies on the contribution of many persons.

First of all, I would like to thank my promotor, Prof. dr. Dirk Cambier who has supported the work all the way long. He was always there to listen to my rants and raves. His ability to transform himself into an expert, whatever the subject may be, never ceases to amaze me.

I gratefully acknowledge the members of the supervisory committee, Prof. dr. Katharina D’Herde, dr. Erik Barbaix, Prof. dr. Rudy Dierckx and dr. Filip Jacobs, for their constructive advice and valuable feedback. I especially would like to thank dr. Barbaix, for the huge amount of help he gave me on this project and for being a good devil’s advocate.

I wish to acknowledge the external members of the examination board, prof. dr. L. Danneels, prof. dr. E. Ernst, prof. dr. G. Vanderstraeten, and prof. dr. P. Van Roy, for their suggestions for improvement and critical remarks on my dissertation.

I’m grateful to all REVAKI and postgraduate Manual Therapy students for their assistance in collecting the data. I also would like to thank Aron, for his care in the “dissection room”. I’m grateful to Anna, Geert and Moris, for their linguistic revisions.

I warmly thank all my colleagues of the department of Rehabilitation Sciences and Physiotherapy. The good team atmosphere and interesting conversations, not only concerning science, make me love going to work every day. A special thank you to my ‘soul mate’ Elke, to Lieven for being a sincere friend, to Kim and Tine for the enjoyable gwenola-talks, to Els as my closest colleague, and to Axel for his continuous enthusiasm and support.

My family, friends and in particular Dries, Diede and the little baby in my belly, thank you for making me realize that there is much more in life than reading and writing. You make me happy!!

Barbara Cagnie
Ghent, april 2005

INTRODUCTION AND OUTLINE OF THE THESIS

*The vertebral artery lies buried in a sea of
generalities, prejudices, fear and ignorance
(Carney A, 1981)*

INTRODUCTION

Over many years, spinal manipulation has evolved to a popular form of treatment for a variety of conditions, notwithstanding the debate about its clinical efficacy. Numerous randomised, controlled trials have evaluated spinal manipulation over the last thirty years, resulting in reviews and meta-analyses of these trials in the past decade.^{5,13,17,22,27,30,33,44,77,86} The poor quality, inconsistent conclusions, and biases of many studies and reviews have led to confusion. Most of the results support, but do not prove, that spinal manipulation provides at least a short-term benefit to some patients. However, there is no evidence to support the idea that spinal manipulation achieves better clinical outcomes than mobilisation. The paucity of evidence from these studies on back and neck pain requires more research to allow systematic reviews to formulate stronger conclusions.

Besides the discordant results of studies on its effectiveness, the lack of scientific investigations regarding its safety sharply contrasts the popularity of manipulative techniques.^{8,20,22,28,29,31,43,73,76} Complications are mainly reported after cervical spine manipulation, but also after treatment to the thoracic and lumbar spine. The unwanted medical consequences vary from simple spells of nausea to the locked-in syndrome and even death.^{20,22,43,44,46,69,74,79} Damage to the vertebrobasilar system, and more specifically to the vertebral arteries is by far the most serious, well-known and feared complication after manipulation of the cervical spine.^{22,35,68} The unique anatomy of the vertebral artery and the biomechanics of the cervical spine as it relates to the vertebral arteries are thought to render these arteries particularly vulnerable to injury.^{8,43,80,82}

Some practitioners believe that complications following spinal manipulation are statistically insignificant events: 'a storm in a tea-cup'.⁸¹ On the contrary, several manipulative therapists are fully aware of the potential dangers to nerves and vessels in the neck. The result of this divergent opinion is a disparity of factual knowledge of complications following spinal manipulation. This ascertainment necessitates thorough literature reviews and fundamental research to gather new facts and evidence to bring about a better understanding of the issues surrounding this highly emotive subject.

To facilitate a better perception of the content and aims of this thesis, some underlying fundamental concepts will first be explained. A short historical section will outline the genesis of spinal manipulation and the consequences associated with this kind of technique, followed by the current definition of spinal manipulation. Subsequently, attention will be given to the anatomy and blood supply of the vertebral artery, as well as to the clinical biomechanics of the upper cervical spine in relation to this artery. Finally, the relationship between spinal manipulation and damage to the vertebral artery will be explained.

Spinal manipulation through the ages

Joint manipulation is an ancient art that has been practiced for thousands of years. However, its origin is hard to be traced.^{31,70} Probably it was merely an intuitive attempt to relieve suffering. The first reliable documentation of manual manipulative treatments dates back to the 5th century BC, within the writings of Hippocrates, the Father of Medicine (460-370 BC). In one of his manuscripts he described a method of spinal manipulation, with regard to spinal deformities:

"The physician or anyone else who is strong and not uninstructed should place the thenar of the one hand upon the hump and the thenar of the other hand upon the former, he should make pressure, attending whether this force should be applied directly downward, or toward the head, or toward the hips. This method of applying force is particularly safe; and it is also safe for a person to sit upon the hump while extension is made, and raising himself up, to let himself fall again upon the patient. And there is nothing to prevent a person from placing a foot on the hump, and supporting his weight on it, and making little pressure..."²

Associated with this technique, the first warning was recorded:

"...for extension along the spine downward has no proper hold at the bone called the os sacrum; and extension upward, along the neck and head, has indeed a hold; but extension thus made is unseemly to behold, and, besides, if increased, may occasion **much mischief** otherwise."²

In the following centuries, a handful of physicians practiced Hippocrates' methods of spinal manipulation. For the most part, manipulative therapy survived by being handed

down informally from one generation to another.⁷⁰ During this time, manipulative therapy was often described as "bonesetting".

By the time spinal manipulation reached its zenith of popularity in the mid-19th century, a certain polemic was developing between practitioners who used manipulation and those who warned against its potential complications.⁷⁰ In 1867, Sir James Paget described in his lecture entitled, 'cases that bone setters cure' a case of violent adjustment:⁷⁰

“Chaos of this kind are of frequent occurrence. To the bone-setters every injured point is ‘put out’, and the one method of cure is the wrench and the rough movements by which it is said that the joint is ‘put in’ again ... Now it would be of little use to us to estimate, even if it were possible, the quantity of mischief done by treatment such as this. It is more important to know that it sometimes does good. Learn then to imitate what is good and avoid what is bad in the practice of the bone-setters; and if you would still further observe the rule; Fas est ab hoste doceri ... (it is right to be taught by the enemy)”

In 1874, Andrew Taylor Still established the concept of osteopathy and in 1895, Daniel Palmer, a student of dr. Still, developed another approach to manipulation, which he termed “chiropractic”.³⁴ Manual therapy originated in the early 20th century in England by James Cyriax and John Mennell who instructed spinal and peripheral joint manipulation to physical therapists.³⁴

While reports of benefits remained anecdotal, the first vascular accident associated with cervical manipulation was described in 1927.²¹ However, only within the past three decades attempts have been made to analyse the risks and complications of spinal manipulation in a standardized manner.

Definition of spinal manipulation

The word manipulation takes on different meanings among health practitioners and lay people. This ambiguity and the lack of a clear definition of manipulation result in communication problems ultimately leading to misconceptions.

A consensus definition of manipulation is “the use of the hands applied to the patient incorporating the use of instructions and maneuvers to achieve maximal painless movement and posture of the musculoskeletal system”.²⁴ In the English literature, the word ‘manipulation’ often implies the entire spectrum of manual skills, although generally this term is reserved for thrust techniques or ‘low-amplitude, high-velocity techniques’.⁵⁴

Thrust manipulation is the use of a high-velocity, low amplitude motion delivered at the limit of a restricted range of motion. This manipulation may create a distraction (gapping) or a translation (gliding) of joint surfaces, which may help to restore full, painless motion activity to a joint in dysfunction.¹⁰ The manipulation can disrupt joint adhesions, alter vertebral position, normalize joint motion by stretching periarticular tissue (ligament, capsule and deep, short musculature) and reduce pain by normalizing mechanoreceptor activity.^{10,32}

This type of manipulation is usually associated with an audible ‘crack’. This is not an absolute requirement for the mechanical effects to occur, but may be a reliable indicator for successful joint gapping.³²

High-velocity techniques can be general or specific.¹⁰ General thrust manipulation involves a high-velocity, low amplitude stretch to more than one joint and possibly one segment. With the notable exception of Cyriax, most manipulative therapists and physicians advise against general manipulation in the cervical and lumbar areas because of the possibility of an existing joint hypermobility.

Specific thrust manipulation involves 1) the use of spinal locking procedures designed to minimize force on uninvolved spinal segments and maximize force on the involved segment. When precise localization of force is achieved by spinal locking, manipulative force is minimized. In fact, in some situations a joint release is obtained at the level of dysfunction during the locking procedure; 2) the use of a high-velocity movement; and 3) the application of a low amplitude.

All thrust techniques require overpressure at the end of the restricted joint range. Therefore, motion slack must be removed at all uninvolved spinal levels and within the segment to be manipulated before the thrust.¹⁰

The vertebral artery

Embryology

The development of vertebral arteries takes place between day 33 and 55 of intra-uterine life. ⁴⁷ The vertebral artery is formed by the development of longitudinal anastomoses that link the cervical intersegmental arteries, which initially originate from each of the paired dorsal aortae. The intersegmental arteries eventually regress except for the seventh, which becomes the primal subclavian artery and which includes the point of origin of the vertebral artery. (Figure 1)

Anatomy ^{6,15,48,52,53,81,82,85}

The vertebral artery is unique among the cervico-cephalic vessels by virtue of its position and relationship to the adjacent structures. Four segments are usually described: the prevertebral (V1), the vertebral (V2), the atlanto-axial (V3), and the intracranial segment (V4). (Figure 2)

The prevertebral segment (V1)

From its usual origin from the subclavian artery, the vertebral artery traverses the subclavian triangle, lateral to the longus colli muscle and medial to the scalenus anterior muscle to penetrate the transverse foramen of C6. The prevertebral segment of the artery is surrounded by the cervical sympathetic plexus and by two vertebral veins.

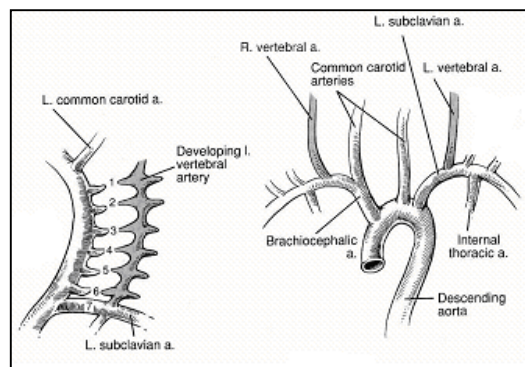


Figure 1: Embryologic development of the vertebral artery. ⁴⁷

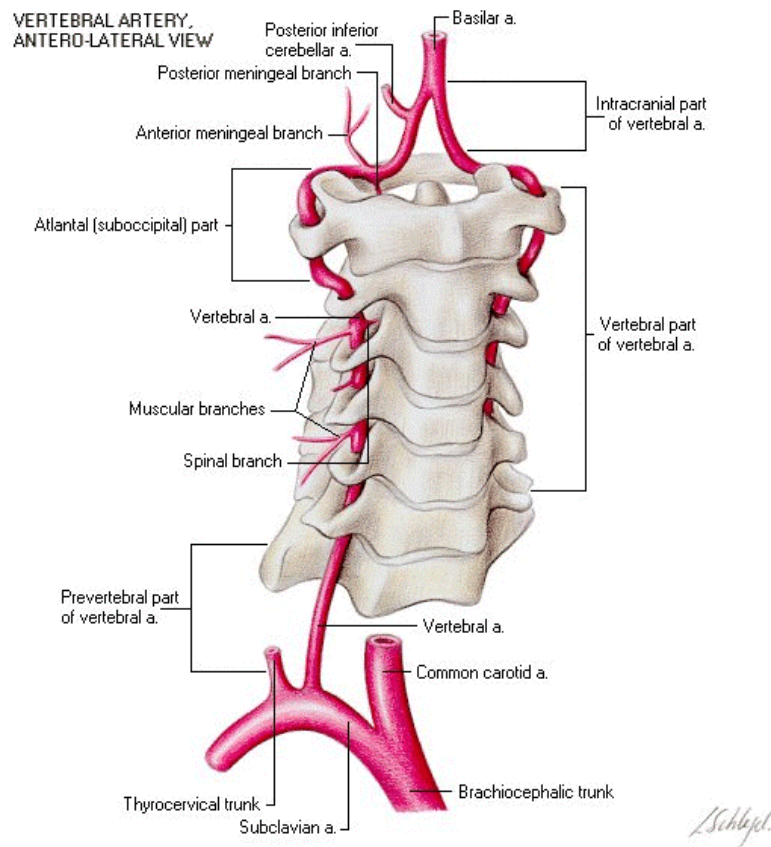


Figure 2: The course of the vertebral artery ⁹²

Variations in vertebral artery origin and course are relatively common and may have some haemodynamic consequences. In 3.5% to 6% of cases, the vertebral artery originates from another artery. ^{1,57,78,85,87} For the left vertebral artery the aortic origin is the most common variant. ^{1,57,85} The artery may also have duplicate origins, generally from the aortic arch and subclavian artery. ^{3,57,78}

Most vertebral artery origin variants are based on failures of involution in one of the first six cervical intersegmental arteries in the aforementioned embryologic mechanism. ¹⁶ If the persistence in one of the cervical intersegmental artery occurs in the upper (first or second) intersegmental arteries, the result is an abnormal origin of the vertebral artery from the internal or external carotid artery; if, however, the involitional failure occurs in the lower (third through sixth) cervical intersegmental arteries, the result is an abnormal origin of the vertebral artery from the aortic arch on the left side or the common carotid artery on both sides. ¹⁶ A double vertebral artery origin may occur if two intersegmental arteries persist.

In 88% to 90% of cases, the artery reaches its intraforaminal course at the level of C6. In the other instances, the artery enters at C5 or to a lesser extent at C7 and seldom at C3 or C4.^{1,78,85} This variation of foraminal entrance is usually associated with variations in origin and is more common on the left side.^{1,82}

Anomalies of fusion may also result in some tortuosities of the vessel.⁵⁷ A high percentage of vertebral arteries demonstrate some form of tortuosity in the V1-segment on both the left and right side of which the plane of tortuosities can be horizontal, sagittal and frontal.⁵⁷

The vertebral segment (V2)

In the V2 segment, the artery fits tightly into the consecutive transverse foramina of the sixth to the third cervical vertebrae as it follows a relatively linear course. Throughout its ascent it is surrounded by the vertebral venous plexus and accompanied by a plexus of sympathetic nerve fibers originating from the cervical ganglia.^{82,89} The artery is in close relationship medially with the uncinat processes of each vertebral body, and posteriorly with the ventral rami of the cervical nerves.^{25,26}

The atlanto-axial segment (V3)

The V3 segment extends from the C3-C2 intertransverse space to the foramen magnum where it penetrates the dura mater. In this segment the vessel has four contours. From the third cervical vertebra onward the artery undergoes a more lateral course to reach the transverse foramen of the axis. As it leaves this foramen the artery inclines further laterally and then bends upward to reach the transverse foramen of the atlas. After emerging from the transverse foramen of the atlas, the vertebral artery turns posteriorly and runs medially along the lateral aspect of the superior articular process of the atlas for a distance of approximately 1 cm. Deep to the obliquus capitis inferior muscle it comes to reach a groove on the upper surface of the posterior arch of the atlas. This groove can range in size and depth from a shallow indentation (vertebral artery sulcus) to a bony ring (retroarticular foramen). In case of a retroarticular foramen, three types can be distinguished: a tiny lateral or posterior ponticulus and a posterolateral tunnel.^{37,85} On the arch the vertebral artery lies superior to the dorsal ramus of the first cervical nerve, in the depth of the suboccipital triangle. Where the artery crosses the sulcus it is loosely connected to the capsule of the atlanto-occipital joint and leaves the triangle by passing medially in front of the posterior atlanto-occipital membrane.

The intracranial segment (V4)

At the atlanto-occipital level, the intracranial segment (V4) traverses the dura mater and enters the cranial cavity through the foramen magnum. It then runs in a medial, anterior and cranial direction to unite with the heterolateral vertebral artery to form the basilar artery on the ventral side of the medulla oblongata between the rootlets of the first cervical nerve and the twelfth cranial nerve.

Blood supply ^{48,53,67,82}

The brain receives its blood supply from two major arterial systems – the anteriorly placed internal carotid arteries and the posteriorly placed vertebrobasilar system. The vertebrobasilar system supplies the spinal cord, brain stem, cerebellum, and the inferior and posterior parts of the cerebrum (occipital and temporal lobes).

In its intracranial part, just before joining the basilar artery, each vertebral artery gives rise to three branches, the posterior spinal artery, anterior spinal artery, and posterior inferior cerebellar artery. The two *posterior spinal arteries* run caudally along the dorsolateral aspect of the spinal cord and supply the posterior third of the spinal cord. The *anterior spinal artery* joins its counterpart from the opposite side, forming a single anterior spinal artery that runs

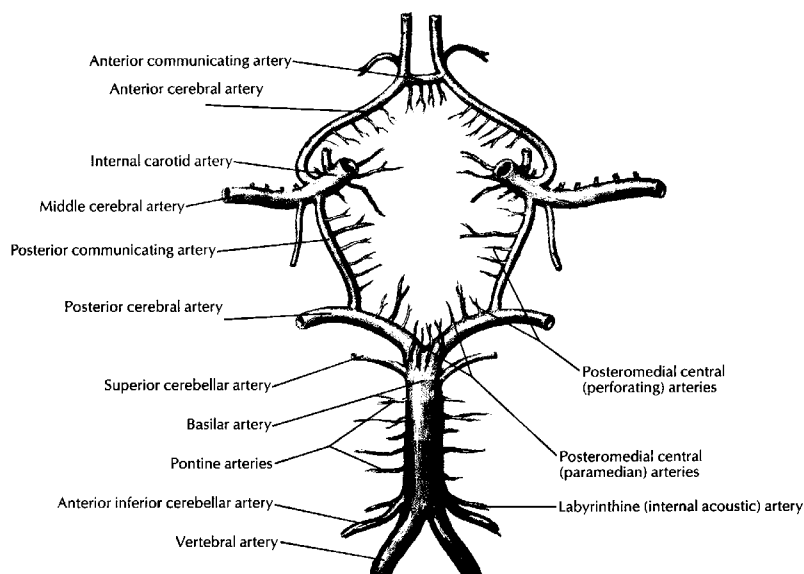


Figure 3: Vertebrobasilar distribution of blood supply ⁶⁶

caudally along the ventral midline of the spinal cord, supplying the anterior two thirds of the spinal cord. The *posterior inferior cerebellar artery* (PICA) supplies much of the inferior surface of the cerebellar hemisphere. However it sends also branches to other structures on its way to the cerebellum. As it curves around the brainstem, the artery supplies the choroid plexus of the fourth ventricle and much of the lateral medulla oblongata. If occlusion of one of the vertebral arteries occurs, the PICA has to be filled by retrograde flow from the origin of the basilar artery. In 15% of the cases, however, one or both PICA's originate from the basilar artery.¹ In some rare cases, the PICA may be absent unilaterally, double or hypoplastic.⁵³

The basilar artery proceeds rostrally and, at the level of the midbrain, bifurcates into the two posterior cerebral arteries. (Figure 3) Before this bifurcation, it gives rise to numerous tiny branches, the labyrinthine and pontine arteries and two larger cerebellar arteries: the *anterior inferior cerebellar artery* (AICA) arises just rostral to the formation point of the basilar artery and supplies the more anterior portion of the inferior surface of the cerebellum, as well as parts of the caudal pons. The *superior cerebellar artery* (SCA) arises just caudal to the bifurcation of the basilar artery and supplies the superior surface of the cerebellum and much of the caudal midbrain and rostral pons. Between the SCA, PICA and AICA, anastomoses exist.⁴⁸

The clinical syndrome 'vertebrobasilar insufficiency (VBI)' is a direct result of decreased blood flow in one or more of the vessels of the vertebrobasilar circulation to the hindbrain.⁵⁶ Reduced blood flow in these vessels will give rise to a variety of signs and symptoms according to the site of ischemia, of which the most important symptoms are dizziness/vertigo, diplopia, dysarthria, dysphagia, drop attacks and/or nausea.⁵⁴

Clinical biomechanics

Although the vertebral artery may be damaged with almost any motion of the head and neck, most literature suggests that end-range rotation and extension are the most stressful.^{7,38-42,49,51,62,64,72} This belief is supported anecdotally with a plethora of case histories in which symptoms occurred after archery, star gazing, extension of the neck during a bleeding nose,

drinking in a bar (also known as the bottoms-up syndrome), visits to a hairdresser (beauty parlor syndrome), yoga, ...

The close association of the vertebral artery to its surrounding structures have directed a great deal of attention on the effects of head movements on the vertebral artery. In order to achieve a better understanding of the biomechanical aspects of damage to the vertebral artery, it is necessary to reconsider roughly the rather complicated biomechanics of the upper cervical spine in relation to this artery. The atlas vertebra serves to cradle the occiput. Into its superior articular sockets it receives the condyles of the occiput. The union between the head and atlas, through the atlanto-occipital joints, is strong, and allows only for nodding movements between the two structures.¹² The existence of axial rotation at this level depends on anatomical variations of the joint.⁸⁵ Because the vertebral artery is relatively fixed at the point of dural penetration, significant tensile strain is placed on the upper portion of the vertebral artery during extension as the inferior aspect of the occipital condyle glides forward in the atlantal socket.⁵⁹

Carrying the head the atlas sits on the axis, with the weight being borne through the lateral atlanto-axial joints.¹² After weight bearing, the cardinal function of the atlanto-axial junction is to permit a large range of axial rotation. Nearly one half of the axial rotation capability of the cervical spine is provided by the C1-C2 junction. During rotation, the ipsilateral lateral mass of the atlas must slide backwards and medially while the contralateral lateral mass must slide forwards and medially. Because the vertebral artery is relatively fixed in the transverse foramina of C1 and C2, atlanto-axial rotation produces a hairpin deformation of the artery with a significant degree of tensile strain at the contralateral side and compressive strain at the ipsilateral side.⁵⁹

The mechanism and effect of cervical spine rotation and extension on reduction of vertebral artery blood flow has been studied by the following methods: cadaveric studies^{11,14,21,75,83,84,90}, angiography^{4,9,36,45,71,76}, Doppler sonography^{19,38-42,50,51,72,73,90} and Magnetic Resonance Angiography^{23,88}.

Cadaveric specimens have been examined in order to assess the effects of head rotation on the vertebral arteries.^{11,14,21,75,83,84,90} Vertebral artery patency was reduced or lost in some of

these experimental conditions. Although interesting, the extrapolation of this work to *in vivo* events is limited.

Several angiography studies in the early sixties and seventies demonstrated obstruction of vertebral artery blood flow by neck rotation.^{4,9,36,45,71,76}

Doppler sonography has gained acceptance as a valid and reliable procedure to evaluate the patency of extracranial vessels, and can therefore be used to assess physiological abnormalities in arterial flow. Studies using Doppler sonography have however produced conflicting evidence regarding the effect of neck position on vertebral artery blood flow, demonstrating no change, decreased flow, and even increased flow.^{19,38-42,50,51,72,73,90} However, it is difficult to reach a consensus from these studies, as there are considerable differences in methodological factors, such as the blood flow parameters, the level of measurement, the used neck movements and/or combination of movements, the patient's position – sitting or supine, the kind of subjects, the type of ultrasound equipment and the level of expertise of the ultrasonographer. It could be argued that measurements of extracranial vertebral artery blood flow proximal to the point of restriction may have limited clinical value as some part of the blood flow may escape via the many collaterals of the vertebral artery (i.e. the spinal and muscular branches). Moreover, according to Bernouilli's law, a reduction of blood flow proximal to a point of restriction of a vessel may be compensated for by an increased velocity distal to this point. However, if the restriction reaches a critical level, blood flow velocity is reduced distal to the point of restriction.⁶⁴ It is this part of the vertebral artery and its branches that supply the hindbrain and into which branches of the collateral circulation feed to ensure adequate perfusion of brain tissue. Therefore, the validity of the assessment of the effect of cervical spine rotation on the blood flow to the hindbrain may be much better if the measurements are made distal to the believed point of restriction at the level of the atlanto-axial joints. These data may favour the use of transcranial Doppler or studies investigating the blood flow in the cerebellum and pons, such as Single Photon Emission Computer Tomography (SPECT), as more appropriate methods.

In conclusion, it is difficult to categorically state that blood flow alterations with head movement do or do not occur in the general population. Vertebral artery blood flow may

change in a subset of individuals and this may also explain the diversity of results in the previous studies. Secondly, even if decreased vertebral artery flow does occur, it may not be symptomatic in all individuals. A lack of symptoms is probably due to collateral circulation that maintains an adequate blood flow to the posterior cranial circulation.⁵⁸ Symptoms commonly occur due to inadequate collateral circulation, i.e. when one vertebral artery is substantially smaller, is absent, ends blindly or terminates in the PICA. In these cases, occlusion of the larger dominant artery embarrasses blood supply to the brainstem and may result in VBI.^{4,46}

Relationship between spinal manipulation and vertebral artery damage

Using a monocausal approach, the injuries to the vertebral artery system may be explained in three ways: cervical manipulation is co-incident to the occurrence of VBI; cervical manipulation is iatrogenic in normal individuals; or cervical manipulation exacerbates a pre-existing and undiagnosed pathology.⁵⁸

Co-incident

While some injuries attributed to cervical manipulation may be coincidental, the close temporal relationship of manipulation to VBI is difficult to discount as being entirely coincidental.³⁵ Analysis of 255 cases by Terrett revealed that in 69% of the cases, symptoms began immediately or within minutes after spinal manipulation; 23% began within 24 hours after spinal manipulation and in only 8% of the cases there was a time delay of at least 24 hours.⁸¹

Iatrogenic

If cervical manipulation has an iatrogenic role in VBI, it must adversely affect normal tissue or tissue that is susceptible to injury. This has been described in two basic models of the injury mechanism to the vertebral artery following manipulation: trauma to the arterial wall producing vasospasm; and/or trauma to the arterial wall producing tissue damage which is followed by thrombosis and/or embolization.⁸¹

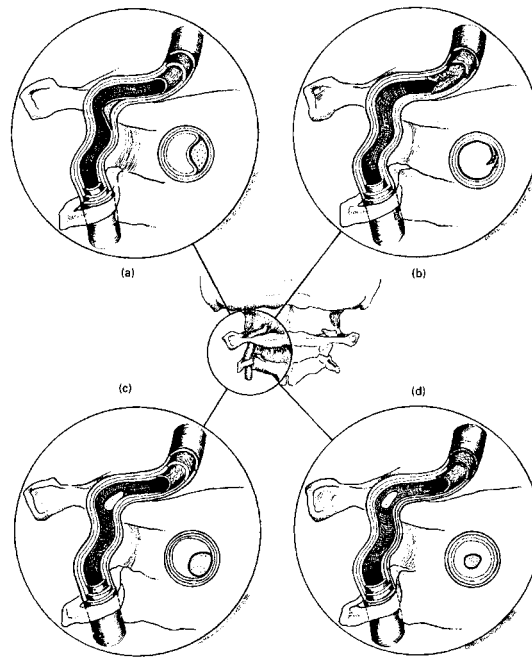


Figure 4: Vascular injury model ⁵⁸

Several authors have postulated that irritation of the vertebral nerve (branches of the sympathetic plexus which accompany the vertebral artery) may cause spasm of the vertebrobasilar arteries and their branches, which may produce VBI signs and symptoms. Fortunately, in most cases, this spasm is transient, and if not accompanied by severe arterial damage, or retraumatized, the patient soon recovers without any deficit. Spasm would be particularly deleterious in the presence of contralateral hypoplasia of the vertebral artery, or if the contralateral vertebral artery terminates in the PICA. ⁸¹ The role of vasospasm in the context of VBI is however poorly understood.

Intimal injury and subsequent subintimal haematoma, dissection and embolization are better understood and described. In most cases of VBI following spinal manipulation where angiography or autopsy findings are available, damage to the artery wall is a common finding. Initially, a subintimal haematoma occurs due to haemorrhage of the vasa vasorum in the tunica media (figure 4a). If the vertebral artery is sufficiently stressed, a tear may develop in the intima of the artery, thereby exposing the subsurface collagen to blood flow (figure 4b). The damaged artery may heal as platelets become adherent to the site of the tear, mix with fibrin, and form a 'white thrombus' that retracts into the vessel wall and may or may not produce narrowing of the lumen. However, if the damaged blood vessel is

again stressed or if the initial injury to the intima is significant enough, blood under systolic pressure may enter the arterial wall, thereby splitting its layers. If this split occurs between the tunica intima and media, the result is often a significant stenosis of the artery. Conversely, blood entering the wall through a split between the tunica media and adventitia will typically produce aneurysmal dilatation of the artery.⁵⁹ Vessel wall dissection exposes the subendothelial tissue resulting in thrombosis (figure 4c). Secondly, the blood flow may 'break off' the thrombus, which can then cause embolism, leading to brain stem, cerebellar or even cerebral infarction (figure 4d).

Pre-existing

Some patients may be vulnerable to arterial dissection because of a pre-existing pathology. In young to middle-aged patients in whom most cases of stroke after manipulation have been reported to occur, the most common cause of decreased blood flow through vertebral arteries would likely be hypoplasia (i.e. diameter less than 2 mm) or – more exceptionally - aplasia (absent vertebral artery). Atherosclerosis and osteophytic impingement are more common in older patients.⁴²

Neck pain and headache, both of which are often treated with manipulation, are common complaints of vertebral artery dissection. This may drive patients, with a pre-existing dissection, to seek manual treatment. These patients are likely to be misdiagnosed and subsequently manipulated, which in turn may precipitate a vascular occlusion.

OUTLINE

Due to the complexity of the topic, case reports make up the largest source of information on complications following cervical manipulation. The disparity of factual knowledge of complications following spinal manipulation and the lack of scientific investigations regarding its safety necessitate further research in order to contribute to a therapist's decision on whether to perform spinal manipulation. The overall objective of this thesis is to contribute to a better understanding of the anatomical and functional role of the vertebral artery in the occurrence of side and adverse effects after spinal manipulation and to advance the current knowledge on this topic. In the following section, the aims of the thesis will be formulated and the designs of the different studies will be outlined. The aims are threefold:

- Aim 1: to investigate the characteristics and risk factors of side and adverse effects/complications following spinal manipulation
- Aim 2: to gain a better insight into the anatomical factors affecting the course of the vertebral artery
- Aim 3: to determine whether manipulation of the cervical spine can influence the cerebral perfusion.

Part I investigates the characteristics and risk factors of side and adverse effects following spinal manipulation. *Chapter 1* intends to provide an overview of the transient side effects and the more serious adverse effects after spinal manipulation, based upon case reports, review articles and pro- and retrospective investigations. *Chapter 2* reports the results of a prospective observational survey regarding the side effects of spinal manipulation and its risk factors. Although minor reactions are very common in clinical practice, little scientific support is available concerning common and uncommon reactions after spinal manipulation. Though it is difficult to label side effects as a risk, it is important to inform those patients who are susceptible to side effects in order to prevent a potential feeling of concern.

The unique anatomy of the vertebral artery and the biomechanics of the cervical spine as it relates to the vertebral artery are thought to render them particularly vulnerable to injury.

There are several congenital and structural factors that may contribute to a reduction in blood flow in the vertebral artery, causing ischemia and consequent neurological symptoms. Exostoses of the vertebrae may compress the vessel from outside, whereas atherosclerotic plaques in the vessel wall can be considered as an internal cause of compromised blood flow in the artery. **Part II** is aimed to gain a better insight into these anatomical factors, which may influence the course of the vertebral artery. In pursuit of this aim, cadaveric studies and studies on dry vertebrae were performed. In order to identify extrinsic risk factors, the minimal and maximal diameter of 111 transverse foramina in dry cervical vertebrae were studied (*chapter 3*). The presence of osteophytes and their influence on the vertebral artery were evaluated at the vertebral body and at the superior and inferior articular facets of these dry specimens. *Chapter 4* reports on a study on 57 human cadavers which was performed to identify the sites and frequency of atherosclerotic plaques and to determine their relation to the tortuous course of the vertebral artery as an intrinsic risk factor.

Congenital anatomical variants of the vertebral arteries and their branches are not infrequent and may constitute a predisposing factor to side and adverse effects after neck manipulations. In *chapter 5* and *6*, two case studies are reported of anatomical variants, which are of clinical importance for the manipulative practitioner. *Chapter 5* describes a case of a simultaneous occurrence of an ossified stylohyoid ligament and anomalies of the vertebral artery. *Chapter 6* covers a case in which the right vertebral artery did not participate in the formation of the basilar artery.

Minor transient side effects following manipulation of the cervical spine, such as headache, dizziness and nausea are frequently reported. The fundamental mechanisms of these specific responses are questioned. One of the hypotheses is that they are caused by ischemia in the areas perfused by the vertebral arteries. **Part III** aims to determine whether manipulation of the cervical spine can influence the cerebral perfusion. *Chapter 7* presents the results of a SPECT activation study in which changes in regional cerebral blood flow (rCBF) caused by cervical spine manipulation in 15 volunteers were examined.

In the general discussion, the most important findings are summarized and discussed. On the basis of these findings, clinical implications are formulated and integrated in a clinical decision algorithm. Suggestions are made for further research.

References

1. Adachi B. *Das Arteriensystem der Japaner*. Bd I. Maruzen, Kyoto, 1928.
2. Adams F. *The genuine works of Hippocrates*. Huntington, NY, Robert E. Krieger Publishing Company, 1972.
3. Albayram S, Gailloud P, Wasserman B. Bilateral arch origin of the vertebral arteries. *Am J Neuroradiol* 2002; 23: 455-58.
4. Andersson R, Carleson R, Nylen O. Vertebral artery insufficiency and rotational obstruction. *Acta Med Scand* 1970; 188: 475-7.
5. Anderson R, Meeker W, Wirick B, Mootz R, Kirk D, Adams A. A meta-analysis of clinical trials of spinal manipulation. *J Manipulative Physiol Ther* 1992; 15: 181-94.
6. Argenson C, Francke J, Sylla S, Dintimille H, Papasian S, di Marino V. Les artères vertébrales. *Anatomica Clinica* 1979; 2(1): 29-41.
7. Arnold C, Bourassa R, Langer T, Stoneham G. Doppler studies evaluating the effect of a physical therapy screening protocol on vertebral artery blood flow. *Man Ther* 2004; 9: 13-21.
8. Assendelft W, Bouter L, Knipschild P. Complications of spinal manipulation: a comprehensive review of the literature. *J Fam Pract* 1996; 42(5): 475-80.
9. Barton J, Margolis M. Rotational obstruction of the vertebral artery at the atlantoaxial joint. *Neuroradiol* 1975; 9: 117-20.
10. Basmajian J, Nyberg R. *Rational Manual Therapies*. Baltimore: Williams & Wilkins, 1993.
11. Biemond A. Thrombosis of the basilar artery and vascularization of the brainstem. *Brain* 1951; 74: 300-17.
12. Bogduk N, Mercer S. Biomechanics of the cervical spine. I. Normal kinematics. *Clinical Biomechanics* 2000; 15: 633-48.
13. Bronfort G, Haas M, Evans R, Bouter L. Efficacy of spinal manipulation and mobilization for low back pain and neck pain: a systematic review and best evidence synthesis. *Spine J* 2004; 4(3): 335-56.
14. Brown B, Tissington-Tatlow W. Radiographic studies of the vertebral arteries in cadavers. *Radiology* 1963; 81: 80-8.
15. Carney A. Vertebral artery surgery: historical development, basic concepts of brain hemodynamics, and clinical experience of 102 cases. *Adv Neurol* 1981; 30: 249-82.
16. Chen C, Wang L, Wong Y. Abnormal origin of the vertebral artery from the common carotid artery. *Am J Neuroradiol* 1998; 19: 1414-6.
17. Cherkin D, Sherman K, Deyo R, Shekelle P. A review of the evidence for the effectiveness, safety, and cost of acupuncture, massage therapy, and spinal manipulation for back pain. *Ann Intern Med* 2003; 138(11): 898-906.
18. Cloud G, Markus H. Diagnosis and management of vertebral artery stenosis. *Q J Med* 2003; 96: 27-34.
19. Cote P, Kreitz B, Cassidy J, Thiel H. The validity of the extension-rotation test as a clinical screening procedure before neck manipulation: a secondary analysis. *J Manipulative Physiol Ther* 1996; 19(3): 159-64.
20. Coulter I. Efficacy and risks of chiropractic manipulation: what does the evidence suggest? *Integrative Medicine* 1998; 1(2): 61-66.
21. Dekleyn A, Nieuwenhuysse P. Schwindelanfelle und Nystagmus Die einter Bestimmten Stellung des Kopfes. *Acta Otolaryngol (Stockh)* 1927; 11: 155-57.
22. Di Fabio R. Manipulation of the cervical spine: risks and benefits. *Phys Ther* 1999; 79(1): 50-65.
23. Dumas J, Salama J, Dreyfus P, Thoreux P, Goldlust D, Chevrel J. Magnetic resonance angiographic analysis of atlanto-axial rotation: anatomic bases of compression of the vertebral arteries. *Surg Radiol Anat* 1996; 18: 303-13.
24. Dvorak J, Dvorak V, Schneider W. *Manual medicine*. Berlin: Springer-Verlag; 1984.

25. Ebraheim N, Lu J, Haman S. Anatomic basis of the anterior surgery on the cervical spine: relationships between uncus-artery-root complex and vertebral artery injury. *Surg Radiol Anat* 1998; 20: 389-92.
26. Ebraheim N, Xu R, Ahmad M, Heck B. The quantitative anatomy of the vertebral artery groove of the atlas and its relation to the posterior atlantoaxial approach. *Spine* 1998; 23(3): 320-3.
27. Ernst E, Harkness E. Spinal manipulation: a systematic review of sham-controlled, double-blind, randomized clinical trials. *J Pain Symptom Manage* 2001; 22(4): 879-89.
28. Ernst E. Commentaire: spinal manipulation: its safety is uncertain. *CMAJ* 2002; 166(1): 40-1.
29. Ernst E. Manipulation of the cervical spine: a systematic review of case reports of serious adverse events, 1995-2001. *Med J Aust* 2002; 176: 376-80.
30. Ernst E. Chiropractic spinal manipulation for neck pain: a systematic review. *J Pain* 2003; 4(8): 417-21.
31. Ernst E. Cerebrovascular complications associated with spinal manipulation. *Phys Ther Rev* 2004; 9: 5-15.
32. Evans D. Mechanisms and effects of spinal high-velocity, low amplitude thrust manipulation: previous theories. *J Manipulative Physiol Ther* 2002; 25: 251-62.
33. Gross A, Hoving J, Haines T, Goldsmith C, Kay T, Aker P, Bronfort G, Cervical Overview Group. A Cochrane review of manipulation and mobilization for mechanical neck disorders. *Spine* 2004; 29(14): 1541-8.
34. Greenman P. Principles of manual medicine. Second edition. Lippincott: Williams & Wilkins, 1996.
35. Haldeman S, Kohlbeck J, Mc Gregor M. Risk factors and precipitating neck movements causing vertebrobasilar artery dissection after cervical trauma and spinal manipulation. *Spine* 1999; 24(8): 785-94.
36. Hardin C, Poser G. Rotational obstruction of the vertebral artery due to redundancy and extraluminal fascial bands. *Ann Surg* 1963; 158: 133-7.
37. Hasan M, Shukla S, Shakil Siddiqui M, Singh D. Posterolateral tunnels and ponticuli in human atlas vertebrae. *J Anat* 2001; 199: 339-43.
38. Haynes M. Doppler studies comparing the effects of cervical rotation and lateral flexion on vertebral artery blood flow. *J Manipulative Physiol Ther* 1996; 19(6): 378-84.
39. Haynes M. Vertebral arteries and neck rotation: Doppler velocimeter and duplex results compared. *Ultrasound Med Biol* 2000; 26(1): 57-62.
40. Haynes M, Hart R, McGeachie J. Vertebral arteries and neck rotation: Doppler velocimeter interexaminer reliability. *Ultrasound Med Biol* 2000; 26(8): 1363-7.
41. Haynes M. Vertebral arteries and cervical movement: Doppler ultrasound velocimetry for screening before manipulation. *J Manipulative Physiol Ther* 2002; 25: 556-67.
42. Haynes M, Cala L, Melsom A, Mastaglia F, Milne N, McGeachie J. Vertebral arteries and cervical rotation: modeling and magnetic resonance angiography studies. *J Manipulative Physiol Ther* 2002; 25:370-83.
43. Hufnagel A, Hammers A, Schönle P, Böhm K, Leonhardt G. Stroke following chiropractic manipulation of the cervical spine. *J Neurology* 1999; 246 (8): 638-8.
44. Hurwitz E, Aker P, Adams A, Meeker W, Shekelle P. Manipulation and mobilization of the cervical spine. A systematic review of the literature. *Spine* 1996; 21: 1746-59.
45. Husni E, Bell H, Storer J. Mechanical occlusion of the vertebral artery: a new clinical concept. *J Am Med Assoc* 1966; 196: 101-4.
46. Klougart N, Leboeuf-Yde C, Rasmussen L. Safety in chiropractic practice, part I: The occurrence of cerebrovascular accidents after manipulation to the neck in Denmark from 1978-1988. *J Manipulative Physiol Ther* 1996; 19: 371-7.
47. Larsen W. Human Embryology, 2nd Ed., Churchill Livingstone, New York, 1997.
48. Lazorthes G, Gouazé A, Salomon G. Vascularisation et circulation de l'encéphale. Paris, France: Masson, 1976.

49. Li Y, Zhang Y, Lu C, Zhong S. Changes and implications of blood flow velocity of the vertebral artery during rotation and extension of the head. *J Manipulative Physiol Ther* 1999; 22(2): 91-5.
50. Licht P, Christensen H, Flemming P. Vertebral artery volume flow in human beings. *J Manipulative Physiol Ther* 1999; 22(6): 363-6.
51. Licht P, Christensen H, Hojgaard P, Hoilund-Carlsen P. Triplex ultrasound of vertebral artery flow during cervical rotation. *J Manipulative Physiol Ther* 1998; 1(1): 27-31.
52. Lu J, Ebraheim N. The vertebral artery: surgical anatomy. *Orthopedics* 1999; 22(11): 1081-5
53. Luzsa G. X-ray anatomy of the vascular system. Budapest. Butter Worths. 1974
54. Magarey M, Coughlan B, Rebbeck T. Australian Physiotherapy Association (APA). Clinical guidelines for pre-manipulative procedures for the cervical spine. Unpublished manuscript (available from the Australian Physiotherapy Association National Office, Melbourne)
55. Maigne R. Diagnosis and treatment of pain of vertebral origin: a manual medicine approach. Baltimore: Williams & Wilkins. 1996
56. Martin P. Vertebrobasilar ischaemia. *W J Med* 1996; 91: 799-811.
57. Matula, C, Tratting, S, Tschabitscher, M, Day J, Koos W. The course of the prevertebral segment of the vertebral artery: anatomy and clinical significance. *Surg Neurol* 1997; 48: 125-31.
58. McDermaid C. Vertebrobasilar incidents and spinal manipulative therapy of the cervical spine. In: Vernon H, The Craniocervical syndrome mechanisms, assessment and treatment. Butterworth – Heinemann, Oxford, 2001.
59. Michaud T. Uneventful upper cervical manipulation in the presence of a damaged vertebral artery. *J Manipulative Physiol Ther* 2002; 25:472-83.
60. Mitchell J, McKay A. Comparison of left and right vertebral artery intracranial diameters. *Anat Rec* 1995; 242: 350-4.
61. Mitchell J. Vertebral artery atherosclerosis: a risk factor in the use of manipulative therapy? *Physiother Res Int* 2002; 7(3): 122-35.
62. Mitchell J. Changes in vertebral artery blood flow following normal rotation of the cervical spine. *J Manipulative Physiol Ther* 2003; 26: 347-51.
63. Mitchell J. Differences between left and right suboccipital and intracranial vertebral artery dimensions: an influence on blood flow to the hindbrain? *Physiother Res Int* 2004; 9: 85-95.
64. Mitchell J, Keene D, Dyson C, Harvey L, Prueve C, Philips R. Is cervical spine rotation, as used in the standard vertebrobasilar insufficiency test, associated with a measurable change in intracranial vertebral artery blood flow? *Man Ther* 2004; 9: 220-7.
65. Morris L. Case reports. Non-union of the vertebral arteries. *Br J Radiol* 1962; 35: 496-8.
66. Netter F. Atlas of human anatomy. Third edition. Icon learning systems. Teterboro, New Jersey. 2003.
67. Nolte J. The human brain. An introduction to its functional anatomy. Mosby-year book, Inc. 1993.
68. Norris J, Beletsky V, Nadaresihvili Z. Sudden neck movement and cervical artery dissection. The Canadian Stroke Consortium. *CMAJ* 2000; 163: 38-40.
69. Povlsen U, Kjaer L, Arlien-Soborg P. Locked-in syndrome following cervical manipulation *Acta Neurol Scand* 1987; 76: 486-8.
70. Powell F, Hanigan W, Olivero W. A risk/benefit analysis of spinal manipulation therapy for relief of lumbar or cervical pain. *Neurosurgery* 1993; 33(1): 73-8.
71. Powers S, Drislane T, Nievins S. Intermittent vertebral artery compression: a new syndrome. *Surgery* 1961; 49: 257-64.
72. Refshauge K. Rotation: a valid premanipulative dizziness test? Does it predict safe manipulation? *J Manipulative Physiol Ther* 1994; 17(1): 15-9.
73. Rivett D. Neurovascular compromise complicating cervical spine manipulation: what is the risk. *J Manual and Manipulative Therapy* 1995; 3:144-51.
74. Rothwell D, Bondy S, Williams I. Chiropractic manipulation and stroke: a population based case-control study. *Stroke* 2001; 32: 1054-60.
75. Selecki B. The effects of rotation of the atlas on the axis: experimental work. *Med J Aust* 1969; 56(20): 1012-5.

76. Sheehan S, Bauer R, Meyer J. Vertebral artery compression in cervical spondylosis. Arteriographic demonstration during life of vertebral artery insufficiency due to rotation and extension of the neck. *Neurology* 1960; 10:968-86.
77. Shekelle P, Adams A, Chassin M, Hurwitz E, Brook R. Spinal manipulation for low back pain. *Ann Intern Med* 1992; 117(7): 590-8.
78. Skopakoff C. Ober die Variabilität der Abzweigung der A subclavia und ihrer Hauptäste. *Anat Anz* 1964; 115: 393-402.
79. Stevinson C, Honan W, Cooke B, Ernst E. Neurological complications of cervical spine manipulation. *J R Soc Med* 2001; 94: 107-110.
80. Stevinson C, Ernst E. Risks associated with spinal manipulation. *Am J Med* 2002; 112:566-70.
81. Terrett A. Current concepts in vertebrobasilar complications following spinal manipulation. West Des Moines, IA: NCMIC Group Inc, 2001.
82. Thiel H. Gross morphology and pathoanatomy of the vertebral arteries. *J Manipulative Physiol Ther* 1991; 14(2): 133-42.
83. Tissington Tatlow W, Bammer H. Syndrome of vertebral artery compression. *Neurology* 1957; 7: 331-40.
84. Toole J, Tucker S. Influence of head position upon cerebral circulation: studies on blood flow in cadavers. *Arch Neurol* 1960; 2: 616-23.
85. Van Roy P, Barbaix E, Clarys J. Functional anatomy of the cervical spine. In: Szpalski M & Gunzburg R, *The degenerative cervical spine*, Lippincott, Williams & Wilkins, Philadelphia, 2001.
86. Vernon H. The effectiveness of spinal manipulation for the treatment of headache disorders: a systematic review of randomized clinical trials. *Cephalalgia* 2003; 23(6): 479-80.
87. Waldron T, Antoine D. Tortuosity or aneurism? The palaeopathology of some abnormalities of the vertebral artery. *International Journal of Osteoarchaeology* 2002; 12(2): 79-88.
88. Weintraub M, Khoury A. Critical neck position as an independent risk factor for posterior circulation stroke. A magnetic resonance angiographic analysis. *J Neuroimaging* 1995; 5: 16-22.
89. Xiuqing C, Bo S, Shizhen Z. Nerves accompanying the vertebral artery and their clinical relevance. *Spine* 1988; 13: 1360-4.
90. Yi-Kai L, Yun-Kun Z, Cai-Mo L, Shi-Zhen Z. Changes and implications of blood flow velocity of the vertebral artery during rotation and extension of the head. *J Manipulative Physiol Ther* 1999; 22(2): 91-5.
91. Zaina C, Grant R, Johnson C, Cansie B, Taylor J, Spyropoulos P. The effect of cervical rotation on blood flow in the contralateral vertebral artery. *Man Ther* 2003; 8(2): 103-9.
92. <http://www.vesalius.com> consulted on march 26, 2001

**PART I: OCCURRENCE OF SIDE AND ADVERSE EFFECTS
AFTER SPINAL MANIPULATION**

CHAPTER 1

SIDE AND ADVERSE EFFECTS OF SPINAL MANIPULATION

(translated from the original dutch text: Manipulatie van de wervelkolom: bijwerkingen en verwickelingen)

Barbara Cagnie¹, Elke Vinck¹, Dirk Cambier¹

¹Department of Rehabilitation Sciences and Physiotherapy, Ghent University, Belgium

Tijdschrift voor Geneeskunde 2002; 58(20): 1317-1323.

Abstract

Based upon case reports, review articles and pro- and retrospective investigations, this article intends to provide an overview of the temporary side effects and the more serious adverse-effects after a spinal manipulation.

About half of all patients will experience transient side effects after a manipulation. These events can be divided into common reactions, such as local discomfort, headaches, tiredness and radiating discomfort and uncommon reactions, such as dizziness and nausea. However, literature data are scarce when it comes to describing type, frequency and duration of these temporary side effects.

The incidence of serious complications is generally considered to be low. Complications after cervical manipulations are apparently more frequent than after lumbar manipulation. Of all injuries after cervical manipulation, 82% can be classified as vertebrobasilar insufficiency.

The main emphasis should be placed upon assuring the safety of the patient during manipulation, in view of the seriousness of these complications and the risk of permanent neurological deficits. The elaboration of a thorough pre-manipulative testprotocol is mandatory.

Introduction

Spinal manipulation is a popular form of treatment for back- and neck pain. The first credible documentation of manipulative treatment dates back to the 5th century BC, when Hippocrates, the father of modern medicine, wrote the first guidelines for the application of manual manipulative treatments.

The remarkable popularity of spinal manipulation contrasts with a disappointing lack of scientific investigations regarding its safety. Severe injuries can occur, mainly after treatment to the neck, as well as in the mid-back and lumbar spine. Unfortunately, the incidence of complications associated with spinal manipulation is unknown. It is often suggested that the incidence is probably underestimated because many adverse events are not reported in the public domain. This might be because the majority of adverse events is transient and does not seem worth mentioning in the literature. Probably, only the 'tip of the iceberg' is published.

Spinal manipulation is practiced by chiropractors, osteopaths and manual therapists. In an attempt to distinguish between the three professions, the philosophy of chiropractors is mainly based on a mechanical approach of musculoskeletal dysfunctions. Osteopaths, in contrast, place greater emphasis on the relationship between the organs and the musculoskeletal system as well as on treating the whole individual rather than just the disease. The manipulative techniques used by manual therapists are based on both philosophies and focus mainly on the osteoarticular and neuromuscular system.

This article intends to provide an overview of the temporary side effects and the more serious adverse-effects after spinal manipulation.

Materials and methods

Computerised literature searches were carried out between 1966 and 2001 using Medline. The search terms used were manipulation, spinal, adverse effects, risks, side effects, complications. In addition, the bibliographies of all articles located were also studied. All articles were evaluated on a number of variables: author, publication year, age and gender of the patients, localisation of the manipulation, the kind of technique, type of side or adverse effect, kind of practitioner and outcome.

Results

In the first place, it is essential to distinguish side effects and adverse effects. Side effects can be described as ‘A consequence other than the one for which an agent, medium or therapy is used’, whereas adverse effects or complications can be defined as ‘A change in body function or the structures of cells due to an agent, medium or therapy that can lead to disease, health problems or even death’.

Side effects

Although side effects cannot be labelled as major risks, patients should be informed about possible minor reactions after spinal manipulation. Few studies have been published on these side effects regarding type, number and duration. Only three acceptable prospective investigations have been carried out and suggest that in general, approximately 50% of all patients will experience side effects after manipulation, of which women (65%) are more likely to report side effects than men (44%) (1-3).

Based on their frequency, side effects are divided into common and uncommon reactions (4). Common reactions include local discomfort, headaches, fatigue and radiating discomfort, while uncommon reactions encompass amongst others dizziness, nausea and hot skin.

These treatment reactions occur mainly after manipulation of the thoracic and cervical spine and are most commonly reported after the first visit, diminishing gradually after the following treatment sessions. In general, side effects are usually mild or moderate and only in 15% of the cases, may this lead to an unpleasant experience with possible functional impairment. The onset of symptoms is mostly on the day of the intervention (74%) or the day after (16%) and 75% of the complaints disappear within one hour. As these reactions occur mainly after the patient has left the practice room, it seems justifiable to inform patients about possible minor reactions in order to prevent a potential feeling of concern.

Complications

Although the transition from side effects to adverse effects is minimal, this cannot be said of the medical consequences. Cervical manipulation has a greater number of complications and of more serious nature, than lumbar or thoracic manipulation.

Lumbar spine

A number of acute and chronic pain syndromes are treated by lumbar manipulation. Absolute contra-indications for lumbar manipulative therapy include nuclear protrusion, radicular symptoms, cauda equina syndrome, spondylolisthesis and spondylolysis (5).

Eighty-eight reported complications after lumbar manipulation were traced (5-7). These complications can roughly be divided into four pathological entities: radiculopathy (n=16), bone fractures (n=7), paraplegia (n=3) and cauda equina syndrome (n=57). Cauda equina syndrome has been defined as low back pain associated with uni- or bilateral sciatica, saddle sensory disturbances, bladder and bowel dysfunction, and variable lower extremity motor and sensory loss. The cauda equina syndrome results from any lesion that compresses the cauda equina nerve roots in the spinal canal. The mean age of the affected patients with cauda equina is 41 years and men are twice as likely to be affected than women (2:1 male/female ratio). Two out of three complications led to surgical intervention, of which two fatal complications of surgery were reported. A residual handicap resulted in almost one in every two patients. Shekelle et al. estimated the rate of occurrence of the cauda equina syndrome as a complication of lumbar spinal manipulation to be on the order of less than one case per 100 million manipulations (5). Even if the number of cases of the cauda equina syndrome is underestimated by tenfold, the complication rate is still low. It does not appear that the rare occurrence of cauda equina syndrome would be reason to avoid such treatment (6). It is, however, essential that persons practicing or prescribing manipulation are aware of this complication. The increased caution inherent in such awareness may be sufficient to reduce further the incidence or at least insure that patients who develop cauda equina syndrome are recognized and treated as soon as possible.

Thoracic spine

Only seven cases with complications, resulting from thoracic manipulation are described in the literature (7). This low number of complications lead one to suspect that manipulations in this area are quiet safe. Rib fractures and dislocations seem to be relatively common, but due to their limited seriousness, they are often not reported. The more serious induced myelopathies arise commonly in primary and secondary malignancies. A correct interpretation of imaging before spinal manipulation is of great importance.

Cervical spine

The main indications of cervical spine manipulation are non-specific mechanical neck pain, cervicobrachial pain not due to nerve root compression, and cervicogenic headaches (8). Disk protrusion, radicular symptoms with nerve root injury and vascular disorders are absolute contra-indications for cervical manipulation.

Complications in the cervical region are mainly focused on manipulation of the upper cervical spine (7,9-14). Two hundred sixty-three cases were reported in the literature. Besides dislocation and fractures (5%), spinal cord injuries (1%) and 31 'other' complications, ranging from herniations and radiculopathies to uni- and bilateral diaphragm paralysis, 82% of the cases (n=216) can be classified as vertebrobasilar insufficiency.

The vertebrobasilar insufficiency cases can be divided into 1) arterial dissections (19%) enclosing pseudo-aneurysms, arterial spasm and ruptures; 2) cerebral, cerebellar and brain stem infarctions (44%); 3) Wallenberg syndrome (obstruction of the posterior inferior cerebellar artery) (11%); 4) Locked-in syndrome (occlusion of the basilar artery) (4%) and 5) 22% of 'other' complications including visual deficits, hearing loss and balance deficits.

The most frequent symptoms of vertebrobasilar insufficiency are neck pain, headaches, dizziness and nausea, vomiting, balance disturbances, visual disorders, unconsciousness, dysarthria, diplopia and dysphagia. Contralateral paralysis may seldom occur.

The mean age of the affected patients was 40 years and was slightly more reported for women (52%) than for men. The majority of injuries were attributed to manipulation by chiropractors (56%). Doctors, osteopaths and physical therapists were respectively involved in 9%, 6% and 5% of the cases. Three percent of the complications could be attributed to incompetent individuals (wife, a barber, a kung-fu practitioner). The specific type of manipulation was seldom described. When the type of manipulation was identified, manual procedures that involved rotational thrust had the largest representation (82%). The outcome in 9% of the cases was unknown, 32% recovered completely, almost one half suffered a residual handicap (i.e. paralysis, neurologic deficit or other permanent functional impairment), and one in seven patients died.

Discussion

The risk of injury due to spinal manipulation is not known. It is generally agreed that the complications associated with spinal manipulation are underreported, further limiting definite statistical analyses. In addition, one can assume that only the most serious cases are described in the literature. This has led to a wide variation of estimates (table 1) (7-11; 15-19). Based on the best available evidence, the rate of serious complications is estimated at 1 to 2 per 1 million manipulations.

The usefulness of spinal manipulation depends on an assessment of proven benefits and potential risks of spinal manipulation. Unfortunately, any risk-benefit analysis is hampered by the lack of reliable data regarding both efficacy and safety. A review suggests that spinal manipulation demonstrates consistent effectiveness as an alternative treatment for adults with acute low back pain. It has not been shown to be consistently superior to other conservative methods nor to offer a long-term benefit. The risk-benefit ratio is unacceptably high for patients with radicular symptoms and/or signs associated with prolapsed discs (20). In order to put the risk of manipulation in perspective, some authors have compared the estimated rate of occurrence of manipulation-induced injury to other therapeutic treatments. Hurwitz et al. reported that the incidence of a ‘serious gastrointestinal event’ associated with Non-Steroid Anti-Inflammatory Drugs (NSAID) use was 16 to 20 in 1.000.000 patients (10). Dabbs and Lauretti suggested that the risk of complications or death from the use of NSAID is 100 to 400 times greater than for the use of cervical manipulation (21) .

Author	Risk estimation
Hurwitz et al (9)	1 in 1.000.000 6 in 10.000.000 serious 3 in 10.000.000 fatal
Haynes (15)	< 5 in 100.000
Michaeli (16)	1 in 228.050
Gutman (17)	2-3 in 1.000.000
Dvorak et al. (18)	1 in 400.000 to 1.000.000
Klougart et al. (19)	1 in 1.300.000

Table 1: Risk estimations of complications after spinal manipulation.

Complications in the cervical region are focused mainly on manipulation of the upper cervical spine. This must be associated with the anatomical structures and their specific course. The unique anatomy of the vertebral artery and the biomechanics of the cervical spine as it relates to the vertebral artery are thought to render them particularly vulnerable to injury from mechanical trauma. The most common site of injury to the vertebral artery appears to be at the site of the atlanto-occipital joint, where the artery changes its vertical course to a horizontal one (7,11-13). Spinal manipulation may damage the intima or media, which results in interruption of blood flow and formation of a thrombosis. Secondly, the blood flow may 'break off' and form an embolus, which can then cause arterial occlusion distally, leading to brain stem, cerebellar or even cerebral infarction. However, manipulation may lead to subclinical damage to the tunica intima or media, resulting in transient symptoms. It is important to realize that this damage may result in a 'locus minoris resistentiae' during subsequent manipulation. Therefore, transient symptoms should be taken as absolute contra-indications to further cervical manipulation (12). It has been suggested that cervical manipulation in many cases may have been administered to patients who already had spontaneous dissection in progress (14,22,23). This suggestion arises from the observation that many patients with spontaneous dissection had initial symptoms of acute neck pain and headaches that progressed to infarction with passing time. The typical patient with vertebral artery dissection or a dissection in progress presents with pain in the back of the neck or head. It may be possible that these patients seek treatment with a manipulative therapist, because cervical manipulations are administered to treat neck pain and headaches. These patients are likely to be misdiagnosed and subsequently manipulated, which in turn could precipitate a vascular occlusion or dislodge an embolus.

The cervical arteries are most vulnerable during rotation of the head. This position places tension on the vertebral artery, thereby increasing the risk of vertebrobasilar events. The relatively high proportion of injuries linked to rotational manipulation has prompted some authors to recommend that upper cervical rotation procedures be abandoned in favour of thrust methods that do not require rotation (24).

The majority of injuries are attributed to manipulation by chiropractors. However, this deduction is based on the origin of the majority of articles. The articles are mostly from Canadian and American countries, where manipulation is mainly performed by chiropractors. This is not the case in European countries. Terrett disputes this stigma in a

literature review in which he demonstrates that chiropractors are frequently pointed wrongly as the culprit (25).

Prevention

Clinical screening examinations that might detect complications, and in particular vertebrobasilar insufficiency, have been advocated as a way of preventing injury from spinal manipulation. The question remains if the risk on vertebrobasilar insufficiency can be detected at all. The key features of the screening examinations involve patient history, provocation of symptoms by testing for signs of vertebral artery compression and medical imaging (12). Factors in the patient history can be used to identify 'warning' signs related to osseous, vascular, and neurological factors; i.e. osteophytes, previous neck trauma, hypertension, previous stroke, visual disorders. There is no wide agreement that these conditions are absolute contra-indications for spinal manipulation (12). Haldeman et al. reviewed the English literature and detected four important risk factors: migraine, hypertension, use of oral contraception and smoking (23).

Several tests have been used to assess the vulnerability of the vertebral artery in an extended position with rotation. These tests have to be maintained during 10 to 40 seconds and are based on the premise that these neck positions reduce the vertebral artery blood flow to the hindbrain, provoking symptoms or signs of vertebrobasilar insufficiency; i.e. vertigo, nystagmus, nausea and sensory disturbance.

The reliability and sensitivity of these tests are questioned by several authors (26-28). One of the problems is that placing the head in the sustained posture during the test exposes the patient to a greater risk than the brief thrust of a manipulation. In addition, the rapid thrust component of spinal manipulation is not simulated during vertebral artery testing (7,12). This contributes to false-negative results.

Perspectives

Besides the hope on quick recovery, a patient, seeking care with spinal manipulation has the right to know that the manipulation is not without a risk. Although side effects cannot be labelled as major risks, it seems justifiable to inform patients about possible minor reactions after spinal manipulation. Therefore, it is required to have clear data. To date, little scientific support is available concerning the type, number and duration of side effects

(9). Only three 'acceptable' prospective studies have been published on these side effects and focused mainly on just one group of therapists, namely chiropractors. Therefore, it is essential to conduct a prospective observational survey with a variety of manipulative therapists in order to investigate the necessary characteristics to inform the patient properly. In addition, it would be of interest to investigate the fundamental mechanisms of these specific responses.

Risk factors need to be identified. In the literature, there is little agreement or confirmation concerning the association of presumed 'risk factors' and vertebrobasilar vascular compromise. Prospective studies should be implemented to avoid speculation.

The validity and sensitivity of screening tests prior to manipulation are questioned. Future studies need to be designed to determine whether sensitive and specific pre-manipulative screening protocols can be developed.

Testing the vertebral artery blood flow is not enough. Variations in morphology and histology of the vertebral artery and atlas may also be responsible in the occurrence of vertebrobasilar insufficiency. Cadaveric studies and as well as medical imaging may clarify these variations.

As long there is no uniformity, manipulation should be performed with the consent of the patient, who will first have been given simple, honest and easily understandable information about the risk of manipulation. In this way, not only proper information is given, but also the consent can be used if complications occur.

Conclusion

Although the occurrence of serious complications is generally based on case studies, the incidence is basically considered to be low.

In view of the seriousness of these complications and the risk of permanent neurological deficits, manipulation should be prescribed and performed with prudence. The elaboration of a thorough pre-manipulative test protocol is mandatory, because at this moment the population at risk cannot be identified a priori. The main emphasis should be placed upon assuring the safety of the patient during manipulation.

References

1. Barrett A, Breen A. The adverse effects of spinal manipulation. *J R Soc Med* 2000; 93: 258-259.
2. Leboeuf-Yde C, Hennius B, Rudberg E, Leufvenmark P, Thunman M. Side effects of chiropractic treatment: a prospective study. *J Manipulative Physiol Ther* 1997; 20: 511-515.
3. Senstad O, Leboeuf-Yde C, Borchgrevink C. Frequency and characteristics of side effects of spinal manipulative therapy. *Spine* 1997; 22: 435-441.
4. Senstad O, Leboeuf-Yde C, Borchgrevink C. Predictors of side effects to spinal manipulative therapy. *J Manipulative Physiol Ther* 1996; 19: 441-445.
5. Shekelle PG, Adams AH, Chassin MR, Hurwitz EL, Brook RH. Spinal manipulation for low back pain. *Ann Intern Med* 1992; 117: 590-598.
6. Haldeman S, Rubinstein S. Cauda equina syndrome in patients undergoing manipulation of the lumbar spine. *Spine* 1992; 17: 1469-1473.
7. Assendelft WJ, Bouter LM, Knipschild PG. Complications of spinal manipulation: a comprehensive review of the literature. *J Fam Pract* 1996; 42: 475-480.
8. Vautravers P, Maigne JY. Cervical spine manipulation and the precautionary principle. *Joint Bone Spine* 2000; 67: 272-276.
9. Ernst E. Life-threatening complications of spinal manipulation. *Stroke* 2001; 32: 809-810.
10. Hurwitz EL, Aker PD, Adams AH, Meeker WC, Shekelle PG. Manipulation and mobilization of the cervical spine. A systematic review of the literature. *Spine* 1996; 21: 1746-1759.
11. Stevinson C, Honan W, Cooke B, Ernst E. Neurological complications of cervical spine manipulation. *J R Soc Med* 2001; 94: 107-110.
12. Di Fabio RP. Manipulation of the cervical spine: risks and benefits. *Phys Ther* 1999; 79: 50-65.
13. Hufnagel A, Hammers A, Schönle P, Bohm K, Leonhardt G. Stroke following chiropractic manipulation of the cervical spine. *J Neurol* 1999; 246: 683-688.
14. Rothwell D, Bondy S, Williams I. Chiropractic manipulation and stroke: a population based case-control study. *Stroke* 2001; 32: 1054-1060.
15. Haynes MJ. Stroke following cervical manipulation in Perth. *Chiropractic J Aust* 1994; 24: 42-46.
16. Michaeli A. Reported occurrence and nature of complications following manipulative therapy in South-Africa. *Aust Physiother* 1993; 39: 309-315.
17. Gutmann G. Verletzungen der Arteria Vertebralis durch Manuelle Therapie. *Manual Medizin* 1983; 21: 2-14.
18. Dvorak J, Baumgartner H, Brun L, et al. Consensus and recommendations as to the side-effects and complications of manual therapy of the cervical spine. *Manual Medizin* 1991; 6: 117-118.
19. Klougart N, Leboeuf-Yde C, Rasmussen LR. Safety in chiropractic practice, part I: The occurrence of cerebrovascular accidents after manipulation to the neck in Denmark from 1978-1988. *J Manipulative Physiol Ther* 1996; 19: 371-377.
20. Powell FC, Hanigan WC, Olivero WC. A risk/benefit analysis of spinal manipulation therapy for relief of lumbar or cervical pain. *Neurosurgery* 1993; 33: 73-78.
21. Dabbs V, Lauretti WJ. A risk assessment of spinal manipulation versus NSAIDs for the treatment of neck pain. *J Manipulative Physiol Ther* 1995; 18: 530-536.
22. Norris J, Beletsky V, Nadasivili Z. Sudden neck movement and cervical artery dissection. The Canadian Stroke Consortium. *CMAJ* 2000; 163: 38-40.
23. Haldeman S, Kohlbeck JF, McGregor M. Risk factors and precipitating neck movements causing vertebrobasilar artery dissection after cervical trauma and spinal manipulation. *Spine* 1999; 24: 785-794.
24. Coulter I. Efficacy and risks of chiropractic manipulation: what does the evidence suggest? *Integrative Medicine* 1998; 1: 61-66.
25. Terrett AG. Misuse of the literature by medical authors in discussing spinal manipulative therapy injury. *J Manipulative Physiol Ther* 1995; 18: 203-210.

26. Haynes M, Milne N. Color duplex sonographic findings in human vertebral arteries during cervical rotation. *J Clin Ultrasound* 2001; 23: 14-24.
27. Licht PB, Christensen HW, Hojgaard P, Marving J. Vertebral artery flow and spinal manipulation: a randomized, controlled and observer-blinded study. *J Manipulative Physiol Ther* 1998; 21: 141-144.
28. Refshauge KM. Rotation: A valid premanipulative dizziness test? Does it predict safe manipulation? *J Manipulative Physiol Ther* 1994; 17: 15-19.

CHAPTER 2

HOW COMMON ARE SIDE EFFECTS OF SPINAL MANIPULATION AND CAN THESE SIDE EFFECTS BE PREDICTED?

Barbara Cagnie¹, Elke Vinck¹, Axel Beernaert², Dirk Cambier¹

¹ Department of Rehabilitation Sciences and Physiotherapy, Ghent University, Belgium

² Postacademic Education in Manual Therapy, Ghent University, Belgium

Manual Therapy 2004; 9: 151-156

Abstract

Little scientific support is available concerning usual and unusual reactions after spinal manipulation although such reactions are very common in clinical practice. Fifty-nine manipulative therapists were requested to enroll 15 consecutive patients attending for their first visit to receive spinal manipulation. These patients were asked to complete a questionnaire after this first visit that asked for possible risk factors for spinal manipulation and asked about any side effects after the manipulation. The participating practitioners were asked to note medical diagnosis, manipulated spinal region, number of treated areas and type of additional treatment. Four hundred and sixty five valuable responses were analysed. Two hundred and eighty three patients (60.9%) reported at least one post-manipulative reaction. The most common were headache (19.8%), stiffness (19.5%), local discomfort (15.2%), radiating discomfort (12.1%) and fatigue (12.1%). Most of these reactions began within 4 h and generally disappeared within the next 24 h. Women were more likely to report adverse effects than men ($P<0.001$). Multivariate analysis showed that upper cervical manipulation (OR: 3.20; 95%CI: 1.89–7.77), use of medication (OR: 2.20; 95%CI: 1.31–3.69), gender (OR: 1.66; 95%CI: 1.01–2.75) and age (OR: 1.02; 95%CI: 1.00–1.05) were independent predictors of headache after spinal manipulation. The results of this study indicate that reactions to spinal manipulation may be relatively common but are benign in nature and of short duration. Although it is difficult to label side effects as a risk, it is important to differentiate those patients who are susceptible to side effects in order to inform them correctly.

Introduction

Spinal manipulation as a treatment for musculoskeletal complaints has been practiced for centuries. The remarkable popularity of spinal manipulation contrasts with a disappointing lack of scientific investigations regarding its safety.

Severe injuries may occur after spinal manipulation, mainly after treatment of the neck (cerebrovascular accidents), as well as in the mid-back (rib-fractures) and lumbar spine (cauda equina lesions) (Haldeman and Rubinstein, 1992; Powell et al., 1993; Assendelft et al., 1996; Di Fabio, 1999). Fortunately, the incidence of serious complications is generally considered to be low (Hurwitz et al., 1996; Klougart et al., 1996; Rivett and Milburn, 1996). However, relatively minor side effects of spinal manipulative therapy are common in clinical practice. Although therapists who regularly perform spinal manipulations probably know intuitively how to discern usual from unusual post-manipulative reactions in their patients, little scientific support is available that can confirm or refute such an experience. Therefore, no proper information can be given to the patient prior to a manipulative treatment. Although side effects cannot be labelled as major risks, it seems justifiable to inform patients about possible minor reactions after spinal manipulation. This is even more important as these reactions mainly occur after the patient has left the treatment room.

Few studies have been published on these side effects (Senstad et al. (1996a); Senstad et al. (1996b) and Senstad et al. (1997); Leboeuf-Yde et al., 1997; Barrett and Breen, 2000; Ernst, 2001). Nevertheless, some efforts have been made to classify them. According to Senstad et al. (1996a), side effects are divided into common and uncommon reactions, based on frequency of occurrence. Common reactions include local discomfort, headache, fatigue and radiating discomfort, while uncommon reactions include dizziness, nausea, hot skin and other reactions.

Attempts have been made to identify risk factors in order to predict adverse reactions to spinal manipulation. Risk factors that have been discussed in the literature include age, gender, migraine, hypertension, diabetes, smoking and oral contraceptives (Pattijn, 1991; Haldeman et al. (1999) and Haldeman et al. (2002)). Senstad et al. (1996a) have already investigated the influence of gender, age and treatment-related factors on the side effects of spinal manipulative therapy. To the best of our knowledge no other studies are available that include other possible predisposing factors that may increase the risk of side effects after spinal manipulation. Therefore, a prospective observational survey was designed and

conducted with a variety of manipulative therapists in order to investigate the necessary characteristics to inform the patient properly.

Subjects and methods

Subjects

A prospective survey was conducted among manual physiotherapists, chiropractors and osteopaths in Belgium. Fifty registered practitioners of each profession were randomly selected and invited by letter to take part in the study.

Twenty manual physiotherapists, 18 osteopaths and 21 chiropractors agreed to participate by sending back a reply card. Each of them received 15 questionnaires to hand to 15 new and consecutive patients at their first manipulative treatment session. To be included, patients had to be aged 18 or over, be new to the practice or consult for a new problem and should not have been manipulated for at least 12 months.

Study design

The patients were asked to complete a questionnaire regarding risk factors and side effects within 48 h post-manipulation. Afterwards they returned it anonymously to the study centre in a pre-stamped and addressed envelope.

The questionnaire consisted of two sections. The first 'general' section asked for personal data related to possible patient-related risk factors (see the appendix in the supplementary information). The second section asked if the patient had experienced any unpleasant reactions after the spinal manipulation and, if so, to report the type of this reaction, time of onset, duration and severity of symptoms. A list of possible reactions thought to occur after spinal manipulation was included in the survey. In addition, the questionnaire asked whether any reaction had caused difficulty in performing daily activities and how the patient felt 48 h after treatment.

The questionnaire was first tested in a pilot study aimed at designing a suitable questionnaire that would enable patients to answer it without having to ask their practitioner further questions. After this piloting, the survey was integrated in the protocol.

In a separate questionnaire, the practitioners were requested to note the medical diagnosis, the spinal region they treated, the number of spinal manipulations and the specific type of manipulation they performed. These questionnaires were also sent to the study centre.

The questionnaires from the patients and therapists could be linked together by codes, but the names of the participating therapists were completely blinded for data analysis.

Data collection started in December 2001 and continued for 4 months.

Statistical analysis

The data were analysed using the Statistical Package for the Social Sciences (SPSS) software (version 10.0). The results were analysed descriptively. When several types of reactions were recorded after one treatment, the most severe or the longest lasting of them was chosen if the analyses allowed only one symptom to be included.

Univariate and multivariate analyses were performed to identify risk factors. Differences between groups were calculated through cross-tabulations. Risk factors associated with side effects in univariate analysis were entered into logistic regression models. Different models were tested. Forward stepwise was used in the present study. Forward selection begins with no predictors in the regression equation. The predictor variable that has the highest correlation with the criterion variable is entered into the equation first. The remaining variables are entered into the equation depending on the contribution of each predictor.

Results

Description of the study sample

Fifty-one of 59 participating practitioners returned their questionnaires before the deadline (86.4%). An average of 12.5 questionnaires per therapist were distributed to patients, resulting in 639 questionnaires in total. This represents 83.5% of the optimal number of 765 questionnaires (51 multiplied by 15). The reasons for non-participating after having entered the study varied: two therapists handed in their data after the deadline, three said they did not have enough patients and three practitioners gave no reason.

Four hundred and sixty five patients returned their questionnaires of which 465 'linked' questionnaires (therapist and patient) were finally analysed. This represents 72.8% of the distributed questionnaires.

According to the therapist questionnaires, there was no significant difference in diagnosis and treatment of the patients who did respond and those who did not.

Two hundred and seventy one women (58.3%) and 194 men (41.7%) participated with an average age of 40.18 years (SD 12.88; range: 18–91). 47.1% were younger than 40, 45.8% were between 41 and 60 and 7.1% were older than 60 years of age.

The medical diagnosis for which the patients received treatment were cervical dysfunction (39.23%) [cervicalgia (21.77%), cervico-brachialgia (6.22%), cervicogenic headache/vertigo (11.24%)], thoracic dysfunction (8.13%), lumbar dysfunction (38.76%) [lumbalgia (25.60%), sciatica (13.16%)], sacroiliac dysfunction (4.55%) and others (9.33%). Most of these complaints had a spontaneous onset (69.9%), whereas 16.8% were caused by trauma, 1.9% resulted after surgery, 2.8% had a congenital onset and 8.6% were work-related.

23.8% of the patients were smokers, 25.8% had smoked in the past and 50.4% had never smoked, 2% had diabetes, 2.2% osteoporosis, 6.5% hypertension, 14.4% migraine and 75.5% reported none of these disorders.

32.6% of the patients reported that they took medication regularly, such as analgesics (26%), antihypertensive agents (17.12%), antimigraine drugs (4.11%), antidepressants (6.85%), cholesterol-lowering medication (6.16%) and other medication (43.84%). 32.3% of the female respondents used oral contraceptives.

The average number of manipulations per person during one session was two. In 28.5% of the cases three or more manipulations were performed during one session. Two manipulations were performed in 38.3% of the cases and only one spinal manipulation in 33.1% of the patients. Of a total of 930 recorded manipulations, 38.6% included the cervical spine, 25.7% the thoracic spine, 23.6% the lumbar spine and 12.1% the sacroiliac joint.

Side effects

Number and type of reactions

Of the 465 patients who submitted their questionnaire 283 patients (60.9%) reported at least one reaction. Of this number, 62.9% mentioned two or more side effects. The different types of reactions and their frequencies are shown in Fig. 1. The most commonly reported side effect was headache (19.84%), followed by stiffness (19.46%), aggravation of complaints (15.18%), radiating discomfort (12.06%) and fatigue (12.06%).

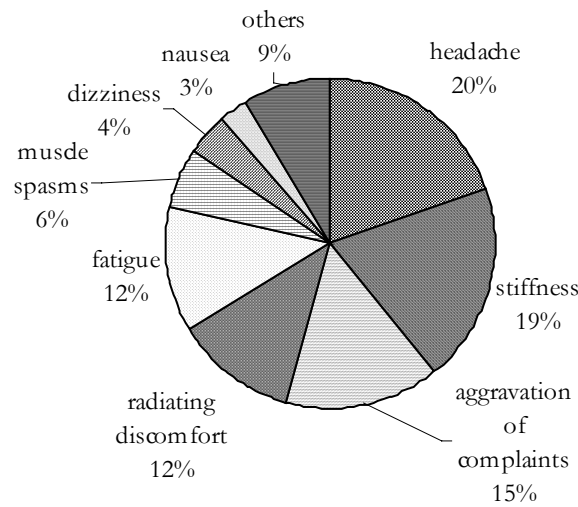


Figure 1: Types and frequency of reactions following spinal manipulative therapy

If several reactions were reported in the same questionnaire, the one that was experienced as the most severe or that lasted the longest was included in the analysis. Reports of muscle spasm (5.84%), dizziness (4.28%) and nausea (2.72%) were uncommon.

Onset, duration and severity of reactions

60.54% of the reactions started within 4 h after manipulation, and 63.96% had disappeared within the next 24 h. 19.37% of the reported reactions lasted more than 48 h after treatment. 14.29% of the side effects represented a slight discomfort, two out of three reactions were described as mild (26.47%) or moderate (38.66%) and 20.58% were defined severe.

Side effects resulted in 26.6% of the patients mentioning an impaired performance of their daily activities. These activities included: housekeeping (39.2%), sport (32.8%), sleeping (32.8%) and work (45.6%).

Despite the side effects, 66.9% of the patients reported that the complaints they were treated for improved within 48 h after the spinal manipulation.

Predictors of side effects

Univariate analysis revealed that women were more likely to report adverse effects than men ($P=0.001$). Women complained significantly more of stiffness ($P=0.038$), headache ($P=0.016$), fatigue ($P=0.036$) and local discomfort ($P=0.030$). Smokers registered

significantly more headache after spinal manipulation than people who had never smoked ($P=0.045$) and patients who used medication on a regular basis reported significantly more headache after treatment than people who did not ($P=0.011$). The use of oral contraceptives did not show any difference in type of symptoms. People with a medical history of migraine experienced significantly more headaches than people without this complaint ($P<0.001$).

In cases of only one area treated, manipulation of the cervical spine caused significantly more headache and fatigue than manipulations of the lumbar ($P=0.007$ and 0.037 , respectively) and thoracic spine ($P=0.037$ and 0.037 , respectively) only. The less common reactions such as dizziness ($P=0.022$) and nausea ($P=0.031$) were also significantly more present after cervical manipulation than lumbar and thoracic manipulation. In the cervical region, manipulation to the upper cervical spine caused significantly more headaches than lower cervical manipulation ($P=0.004$). The number of performed manipulations could not be associated with any of the outcome variables.

Analysis between the three professions revealed (1) a lower number of manipulations per treatment session performed by osteopaths in comparison with the two other professional groups ($P<0.001$) and (2) a lesser number of cervical manipulations performed by osteopaths ($P<0.001$) and sacroiliac manipulations performed by manual physiotherapists ($P=0.003$). According to the side effects, there was only a statistical significant difference between osteopaths and manual therapists with respect to fatigue ($P=0.010$).

Binary logistic regression analysis was performed to predict the probability of a patient experiencing side effects. The predictor variables were gender, age, smoking, medication and region of manipulation. Gender was the only statistically significant factor predicting the occurrence of all side effects after spinal manipulation (Table 1). Female patients were 1.84 times more likely to have side effects than male patients.

Predictor	<i>B</i>	Wald X ²	p-value	Odds ratio	95%CI
Gender	.609	9.597	0.002	1.840	1.251-2.705

Table 1: Logistic regression predicting side effects after spinal manipulation (n=465).

Definition of abbreviation: *B*: logistic regression coefficient

Predictor	B	Wald X ²	p-value	Odds ratio	95%CI
Type of manipulation					
LC versus UC	1.153	6.362	0.012	3.196	(1.293-7.766)
NC versus UC	0.786	7.216	0.007	2.194	(1.237-3.893)
Gender	0.510	3.983	0.046	1.664	(1.009-2.745)
Age	0.230	5.305	0.210	1.024	(1.003-1.044)
Medication	0.787	8.880	0.003	2.196	(1.309-3.685)

Table 3: Logistic regression predicting headache after spinal manipulation (n=465)

Definition of abbreviation: B: logistic regression coefficient; LC: lower cervical spine; UC: upper cervical spine; NC: non cervical spine

When applying the same logistic regression to the five most common side effects, only headache could be predicted. The probability of headache after spinal manipulation was best explained by the following model, summarized in Table 2. A test of the model with the predictors (1) type of manipulation, (2) gender, (3) age and (4) medication versus a model with intercept only was statistically significant, $X^2=29.250$, $P<0.001$. The model was able to classify 5.3% of those who would experience some side effects and 98.9% of those who would not, for an overall success rate of 79.2%.

The odds ratio for the type of manipulation indicates that when holding all other variables constant, manipulation of the upper cervical spine is 3.17 times more likely to cause headache than manipulation of the lower cervical spine. For every 1-year increase in age, there is a 2.4% decrease in risk of headache. Female patients have 1.66 times more the risk on having headache than males. Patients who use medication regularly are 2.20 times more likely to get headache than people who do not.

Discussion

Number and type of reactions

The number and type of side effects are in general comparable with previous studies. Senstad et al. (1996b) conducted a pilot study, which formed the basis for two, more extensive investigations (Leboeuf-Yde et al., 1997; Senstad et al., 1997). The percentage of

reactions observed in these trials, ranged from 34% to 55%. Local discomfort, headache, fatigue and discomfort outside the area of treatment were the most frequent complaints. In a study by Barrett and Breen (2000), 53% of the patients reported some sort of adverse reaction within 2 days of spinal manipulation that they attributed to the treatment.

The number of reactions reported in our own study was slightly higher than in previous studies (Senstad et al. (1996b) and Senstad et al. (1997); Leboeuf-Yde et al., 1997). This difference can probably be attributed to the fact that, in our study, patients were only asked about side effects after the first visit. Senstad et al. (1996a) found that treatment reactions were most commonly reported after the first visit, diminishing gradually after the following treatment sessions. One of their hypotheses is that many patients are fearful of spinal manipulation during the first visit. In addition, this study as well as the Barret and Breen (2000) study was carried out blind to the therapists. The higher incidences in both studies could be attributed to this blinding.

Onset, duration and severity of reactions

No serious adverse effects were noted. It is however possible that some side effects may have persisted given that 19.37% still had reactions after 48 h. Unfortunately, there are no data available about how much longer these side effects continued.

Predictors of side effects

Some patients are more likely to experience side effects than others and also the type of treatment determines whether side effects will occur.

Women are more likely to report unpleasant reactions from spinal manipulation than men. This is in accordance with the findings of Senstad et al. (1996a) and Senstad et al. (1996b). Whether these differences can be explained by some physiological phenomenon or whether women are more willing to report symptoms is not known.

Headache, dizziness and nausea are significantly more likely to present after cervical manipulation than lumbar and thoracic treatment. The patient should be asked about these reactions at the next visit. Vautravers and Maigne (2000) claim that cervical manipulations should be contra-indicated for patients who experience dizziness, nausea or acute headache persisting for more than 2 days. Ignoring these red flags increases the likelihood of harming the patient.

Limitations of the study

The present results must be viewed within the limitations of the study. The questionnaire asked only about side effects after the first visit. This may have resulted in over-reporting of reactions, because many patients may be fearful of spinal manipulation during their first treatment.

When interpreting the results of a postal survey, one has to bear in mind that non-response can create a bias. In this survey there are two kinds of non-responders: practitioners and patients. Whereas the non-response rate of the practitioners (13.6%) is mainly due to the limited period of duration of this survey (4 months), the higher rate in patients (27.2%) could be attributed to several factors (not interested, forgotten, lost, ...). In addition, it is possible that this group opted out because they did not experience any reactions and therefore disregarded the questionnaire. No demographic features of the patients could be obtained, as these questions were not asked in the practitioners' questionnaire. Since, according to the replies from the practitioners, there were no statistically significant differences in treatment-related variables between responders and non-responders, it can be considered that the non-response group had no or limited impact on the response bias.

The data collected in the clinics may be positively biased. For practical reasons, we used consecutive sampling. However, it was not possible to verify whether the practitioners selected their patients in some other way that may have introduced a bias.

Spinal manipulation was rarely the only treatment approach that was administered during the treatment session. It is therefore difficult for both the patient and the therapist to be certain whether side effects that arose were due to spinal manipulation. Side effects could have been due to other treatments during the session or to factors not covered in either questionnaire such as pre-existing problems, lifestyle or environmental impacts, or concurrent treatment by other health professionals.

The study model contained no control group. It is therefore not known whether some of the reported reactions are incidental or could have been a description of pre-existing symptoms.

Advantages of the study

Despite the limitations of this study there are some advantages in comparison to previous studies. The patient and the therapist filled in their questionnaire separately. This was in contrast with previous studies, all data of which were collected by the treating therapist

(Senstad et al. (1996a); Senstad et al. (1996b) and Senstad et al. (1997); Leboeuf-Yde et al. 1997). In these studies, patients may therefore have been reluctant to report negative reactions. The practitioner could misinterpret the information given or fail to record it correctly. In addition, the therapist could omit certain information on purpose.

Patients were asked to report side effects within 48 h after treatment. In previous studies side effects had to be reported at the next visit, so the time interval could be widely spaced, which may have affected the accuracy of reporting.

Previous studies made use of just one group of therapists (Senstad et al. (1996a); Senstad et al. (1996b) and Senstad et al. (1997); Leboeuf-Yde et al., 1997; Barrett and Breen, 2000), namely chiropractors, whereas this study used a heterogeneous group of therapists who perform spinal manipulation.

Conclusion

There is convincing evidence that spinal manipulation is associated with frequent minor adverse effects. The results of this study indicate that the common reactions can be predicted to some extent. Although it is difficult to label side effects as a risk, it is important to differentiate patients who are susceptible to side effects in order to inform them correctly. Theoretically, it would be possible to reduce the frequency of complications after manipulation if the patient at risk could be identified and excluded from receiving manipulation.

In clinical practice, it is important to differentiate between ‘normal’ and ‘abnormal’ side effects because the latter may indicate a need to reconsider diagnosis or therapy. Abnormal reactions, such as dizziness, nausea, etc. should alert the practitioner as precursors of more sinister treatment reactions.

Acknowledgements

The authors would like to thank Ms. Veerle De Loose, Ms. Sofie Demets, Mr. Diederik Fontaine and Mr. Robin Hellebuyck for their assistance in collecting the data.

References

- Assendelft W, Bouter L, Knipschild P 1996 Complications of spinal manipulation. *The Journal of Family Practice* 42(5): 475-480
- Barrett AJ, Breen AC 2000 The adverse effects of spinal manipulation. *Journal of Royal Society of Medicine* 93(5): 258-259
- Di Fabio RP 1999 Manipulation of the cervical spine: risks and benefits. *Physical Therapy* 79: 50-65.
- Ernst E 2001 Prospective investigations into the safety of spinal manipulation. *Journal of Pain Symptom Management* 21(3): 238-242
- Haldeman S, Rubinstein S 1992 Cauda equina syndrome in patients undergoing manipulation of the lumbar spine. *Spine* 17:1469-1473
- Haldeman S, Kohlbeck F, Mc Gregor M 1999 Risk factors and precipitating neck movements causing vertebral artery dissection after cervical trauma and spinal manipulation. *Spine* 24(8): 785-794
- Haldeman S, Kohlbeck F, Mc Gregor M 2002 Unpredictability of cerebrovascular ischemia associated with cervical spine manipulation therapy. A review of sixty-four cases after cervical spine manipulation. *Spine* 27(1): 49-55
- Hurwitz EL, Aker PD, Adams AH, Meeker WC, Shekelle PG 1996 Manipulation and mobilization of the cervical spine. A systematic review of the literature. *Spine* 21: 1746-1759
- Klougart N, Leboeuf-Yde C, Rasmussen LR 1996 Safety in chiropractic practice, part I: The occurrence of cerebrovascular accidents after manipulation to the neck in Denmark from 1978-1988. *Journal of Manipulative and Physiological Therapeutics* 19: 371-377
- Leboeuf-Yde C, Hennius B, Rudberg E, Leufvenmark P, Thunman M 1997 Side effects of chiropractic treatment: a prospective study. *Journal of Manipulative and Physiological Therapeutics* 20(8): 511-515
- Pattijn J 1991 Complications in manual medicine: A review of the literature. *Journal of Manual Medicine* 6: 89-92
- Powell FC, Hanigan WC, Olivero WC 1993 A risk/benefit analysis of spinal manipulation therapy for relief of lumbar or cervical pain. *Neurosurgery* 33: 73-78
- Rivett D, Milburn P 1996 A prospective study of complications of cervical spine manipulation. *Journal of manual and manipulative therapy* 4:166-170
- Senstad O, Leboeuf-Yde C, Borchgrevnkink C 1996 Predictors of side effects to spinal manipulative therapy. *Journal of Manipulative and Physiological Therapeutics* 19(7): 441-445
- Senstad O, Leboeuf-Yde C, Borchgrevnkink C 1996 Side effects of chiropractic spinal manipulation: types, frequency, discomfort and course. *Scandinavian Journal of Primary Health Care* 14: 50-53
- Senstad O, Leboeuf-Yde C, Borchgrevnkink C 1997 Frequency and characteristics of side effects of spinal manipulative therapy. *Spine* 22(4): 435-441
- Vautravers P, Maigne JY 2000 Cervical spine manipulation and the precautionary principle. *Joint Bone Spine* 67: 272-276

8. Do you take oral contraceptives? no yes For how many years?

9. For what symptoms are you currently being treated by your therapist?

B. Reactions after treatment

1. Did the complaints you reported, improved within 48 hours after the treatment?
 no
 yes which improvements? less pain
 more mobility
 less radiating discomfort
 other therapeutic effects Which?
2. How did you feel 48 hours (2 days) after the treatment?
 better
 same
 worse
3. Did you feel restricted in normal daily activities (home, work, hobby, sleeping) within the first 48 hours (2 days)?
 no
 yes Which daily activities?
4. Were you informed that you would be manipulated?
 no
 yes
5. Did you experience any discomfort during the first 48 hours (2 days) after treatment?
 no
 yes if yes, please continue with question 6
6. What type of discomfort did you experience during the first 48 hours?

Example: three hours after manipulation of the neck, I got moderate headache, which disappeared 24 hours later.

Discomfort	onset	duration	Severity
<input checked="" type="radio"/> aggravation of complaints	<input type="radio"/> after 10'	<input type="radio"/> 10'-1 h	<input type="radio"/> 1h – 12h
	<input checked="" type="radio"/> 1h – 4h	<input type="radio"/> 4h-24h	<input type="radio"/> 12 – 3 – 4
	<input type="radio"/> later: __ hours	<input checked="" type="radio"/> 12h-24h	<input type="radio"/> 24h-48h
		<input type="radio"/> > 2 days	

* Severity:
 1 = light
 2 = mild
 3 = moderate
 4 = severe

Discomfort	Onset		Duration		Severity
O aggravation of complaints	O after 10 ² O 1h – 4h O later: ___ hours	O 10 ² -1 h O 4h-24h	O 1 h O 12h-24h O > 2 days	O 1h – 12h O 24h-48h	1 – 2 – 3 – 4
O spasm: where?	O after 10 ² O 1h – 4h O later: ___ hours	O 10 ² -1 h O 4h-24h	O 1 h O 12h-24h O > 2 days	O 1h – 12h O 24h-48h	1 – 2 – 3 – 4
O stiffness where?	O after 10 ² O 1h – 4h O later: ___ hours	O 10 ² -1 h O 4h-24h	O 1 h O 12h-24h O > 2 days	O 1h – 12h O 24h-48h	1 – 2 – 3 – 4
O dizziness	O after 10 ² O 1h – 4h O later: ___ hours	O 10 ² -1 h O 4h-24h	O 1 h O 12h-24h O > 2 days	O 1h – 12h O 24h-48h	1 – 2 – 3 – 4
O headache	O after 10 ² O 1h – 4h O later: ___ hours	O 10 ² -1 h O 4h-24h	O 1 h O 12h-24h O > 2 days	O 1h – 12h O 24h-48h	1 – 2 – 3 – 4
O ringing in the ears	O after 10 ² O 1h – 4h O later: ___ hours	O 10 ² -1 h O 4h-24h	O 1 h O 12h-24h O > 2 days	O 1h – 12h O 24h-48h	1 – 2 – 3 – 4
O radiating discomfort where?	O after 10 ² O 1h – 4h O later: ___ hours	O 10 ² -1 h O 4h-24h	O 1 h O 12h-24h O > 2 days	O 1h – 12h O 24h-48h	1 – 2 – 3 – 4
O fatigue	O after 10 ² O 1h – 4h O later: ___ hours	O 10 ² -1 h O 4h-24h	O 1 h O 12h-24h O > 2 days	O 1h – 12h O 24h-48h	1 – 2 – 3 – 4
O nausea	O after 10 ² O 1h – 4h O later: ___ hours	O 10 ² -1 h O 4h-24h	O 1 h O 12h-24h O > 2 days	O 1h – 12h O 24h-48h	1 – 2 – 3 – 4
O vomiting	O after 10 ² O 1h – 4h O later: ___ hours	O 10 ² -1 h O 4h-24h	O 1 h O 12h-24h O > 2 days	O 1h – 12h O 24h-48h	1 – 2 – 3 – 4
O perspiration	O after 10 ² O 1h – 4h O later: ___ hours	O 10 ² -1 h O 4h-24h	O 1 h O 12h-24h O > 2 days	O 1h – 12h O 24h-48h	1 – 2 – 3 – 4
O shivering	O after 10 ² O 1h – 4h O later: ___ hours	O 10 ² -1 h O 4h-24h	O 1 h O 12h-24h O > 2 days	O 1h – 12h O 24h-48h	1 – 2 – 3 – 4
O hot skin	O after 10 ² O 1h – 4h O later: ___ hours	O 10 ² -1 h O 4h-24h	O 1 h O 12h-24h O > 2 days	O 1h – 12h O 24h-48h	1 – 2 – 3 – 4
O swallowing problems	O after 10 ² O 1h – 4h O later: ___ hours	O 10 ² -1 h O 4h-24h	O 1 h O 12h-24h O > 2 days	O 1h – 12h O 24h-48h	1 – 2 – 3 – 4
O visible changes which?	O after 10 ² O 1h – 4h O later: ___ hours	O 10 ² -1 h O 4h-24h	O 1 h O 12h-24h O > 2 days	O 1h – 12h O 24h-48h	1 – 2 – 3 – 4
O breathing changes which?	O after 10 ² O 1h – 4h O later: ___ hours	O 10 ² -1 h O 4h-24h	O 1 h O 12h-24h O > 2 days	O 1h – 12h O 24h-48h	1 – 2 – 3 – 4
O urinary problems which?	O after 10 ² O 1h – 4h O later: ___ hours	O 10 ² -1 h O 4h-24h	O 1 h O 12h-24h O > 2 days	O 1h – 12h O 24h-48h	1 – 2 – 3 – 4
O intestinal problems which?	O after 10 ² O 1h – 4h O later: ___ hours	O 10 ² -1 h O 4h-24h	O 1 h O 12h-24h O > 2 days	O 1h – 12h O 24h-48h	1 – 2 – 3 – 4
O tingling in the saddle region	O after 10 ² O 1h – 4h O later: ___ hours	O 10 ² -1 h O 4h-24h	O 1 h O 12h-24h O > 2 days	O 1h – 12h O 24h-48h	1 – 2 – 3 – 4
O others which?	O after 10 ² O 1h – 4h O later: ___ hours	O 10 ² -1 h O 4h-24h	O 1 h O 12h-24h O > 2 days	O 1h – 12h O 24h-48h	1 – 2 – 3 – 4

**PART II: ANATOMICAL APPROACH OF THE
VERTEBRAL ARTERY**

CHAPTER 3

EXTRINSIC RISK FACTORS FOR COMPROMISED BLOOD FLOW IN THE VERTEBRAL ARTERY: ANATOMICAL OBSERVATIONS OF THE TRANSVERSE FORAMINA FROM C3 TO C7

Barbara Cagnie¹, Erik Barbaix², Elke Vinck¹, Katharina D'Herde², Dirk Cambier¹

¹Department of Rehabilitation Sciences and Physiotherapy, Ghent University, Belgium

²Department of Human Anatomy, Embryology, Histology and Medical Physics, Ghent University, Belgium

Accepted in Surgical and Radiologic Anatomy

Abstract

Background: The vertebral artery (VA) is often involved in the occurrence of complications after spinal manipulative therapy. Due to osteophytes compressing the vertebral artery anteriorly from the uncinat process or posteriorly from the facet complex, the VAs are susceptible to trauma in the transverse foramina. Such altered anatomical configurations are of major clinical significance, as spinal manipulations may result in dissection of the VA with serious consequences for the blood supply to the vertebrobasilar region. The purpose of this study is to describe numerous structural features of the third to seventh cervical vertebrae in order to contribute to the understanding of pathological conditions related to the VA.

Methods: The minimal and maximal diameter of 111 transverse foramina in dry cervical vertebrae were studied. The presence of osteophytes and their influence on the VA were evaluated at the vertebral body and at the superior and inferior articular facets.

Results: The diameter of the transverse foramina increased from C3 to C6, while the transverse foramina of C7 had the smallest diameter. At all levels the mean dimensions of the left foramina were greater than those of the right side. Osteophytes from the uncinat process of C5 and C6 vertebrae were found in over 60% of dry vertebrae. Osteophytes from the zygapophyseal joints were more frequent at C3 and C4 vertebrae. About half of the osteophytes of the uncinat and of the superior articular process partially covered the transverse foramina. This was less common with those of the inferior articular facets.

Conclusions: Osteophytes covering the transverse foramen force the VAs to meander around these obstructions, causing narrowing through external compression and are potential sites of trauma to the VAs potentially even leading to dissection. We strongly advocate that screening protocols for vertebrobasilar insufficiency (VBI) be used prior to any manipulation of the cervical spine and should include not only extension and rotation but any starting position from which the planned manipulation will be performed.

Key words: transverse foramina; osteophytes, vertebral artery, spinal manipulation

Introduction

The vertebral artery (VA) is often involved in the occurrence of complications after spinal manipulative therapy [5]. An impaired blood flow through these arteries can result in vertebrobasilar insufficiency (VBI), which is by far the most frequent serious adverse reaction after manipulation of the cervical spine [5].

The atlanto-axial level is the most common site of injury [17]. However, several reports describe the involvement of the VA at its second cervical segment, where cervical osteophytes seem to be the major cause of mechanical occlusion [3,6,13,19,20]. In most cases, VA compression and insufficiency caused by cervical spondylosis is asymptomatic as long as adequate compensation is achieved by a competent contralateral VA [3]. A patient with haemodynamically critical narrowing of one VA on clinical testing, but with satisfactory collateral circulation, may not experience ischaemic damage.

Symptomatic VA stenosis may be caused by osteophytes compressing the VA anteriorly from the uncinat process or posteriorly from the facet complex [4,19]. Such configurations have quite some significance, as spinal manipulations may inflict a dissection of the VA with an endangered blood supply of the vertebrobasilar region.

Kawaguchi et al stated that no report has described the position and size of the outgrowth of osteophytes [9]. Therefore, the purpose of this study is to describe the structural features of the third to seventh cervical vertebrae to bring about a better understanding of pathological conditions related to the VA.

Materials and methods

For this study 111 dry vertebrae from C3 to C7 were obtained from the scientific collection of the anatomical laboratory of the Vrije Universiteit Brussels. The specimens came from people who died aged between 50 and 90 years and who, by testimony, dedicated their body for scientific purposes. For the purpose of confidentiality no personal history or medical antecedents were available.

Each vertebra was numbered for the analysis. Quantitative anatomic evaluation focused on the transverse foramina of C3 to C7. The minimal and maximal diameter of the transverse foramen was measured bilaterally on the inferior aspect using an electronic, digital, high precision calliper accurate to 0.01 mm. To evaluate the interobserver and intraobserver reliability of this method of measurement, two independent observers each made two separate sets of measurements for 20 vertebrae.

The presence of osteophytes at the uncinat process as well as at the superior articular facet was studied from superior. Osteophytes at the inferior articular facet were studied from inferior. To detect if the transverse foramen was covered by osteophytes, this foramen was observed from inferior using a diagram.

Statistical analysis

The data were analysed using the Statistical Package for the Social Sciences (SPSS) software (version 10.0). The mean, the standard deviation, and the range were calculated for all specimens.

Differences between sides were analysed using a paired t-test and differences between levels were examined by one-way Anova and LSD test with significance level of 0.05.

The intraclass correlation coefficient was calculated to determine the inter- and intrarater reliability of our methods of measurements.

Results

Reliability analysis

The intra- and interrater reliability of our methods of measurement were found to be excellent. Intraclass correlation coefficients were all greater than 0.98 for intrarater- and greater than 0.96 for interrater comparisons.

Diameter of transverse foramen

Table 1 presents the mean values for the maximal and minimal diameter on each side of the various vertebrae. It shows that the diameter increases from C3 to C6, while the transverse foramina of C7 have the smallest diameter. At all levels the mean dimensions of

		Right		Left		Right versus left	
		Maximal	Minimal	Maximal	Minimal	Maximal	Minimal
C3	22	6.32 (0.92)	5.21 (0.75)	6.47 (0.64)	5.39 (0.69)	0.328	0.275
C4	26	6.43 (0.77)	5.35 (0.70)	6.80 (0.69)	5.77 (0.55)	0.098	0.016*
C5	28	6.94 (1.13)	5.71 (0.98)	7.27 (0.97)	6.13 (0.86)	0.081	0.032*
C6	19	7.18 (1.42)	5.42 (1.16)	7.39 (1.35)	6.03 (1.05)	0.576	0.034*
C7	16	6.31 (1.35)	4.38 (1.13)	6.20 (1.14)	4.23 (1.13)	0.690	0.511
Total	111	6.65 (1.14)	5.29 (1.01)	6.86 (1.04)	5.61 (1.04)	0.039	<0.001*
Differences in levels		0.035*	0.001*	<0.001*	<0.001*		

Table 1: Mean values and standard deviation of maximum and minimum diameters (mm) of the left and right transverse foramina from C3 to C7. Last 2 columns give the probability of the paired t-test between left and right sides. The bottom row gives the p-value defining the differences between the respective levels.

the left foramina are greater than those of the right side. For single levels, the left/right differences are not significant, except for the small diameters of C4, C5 and C6.

Osteophytic encroachments

Globally, osteophytes of the uncinat process (48.13%) are more frequent than those of the superior (29.91%) and inferior (30.84%) articular facets. At the C3, C4 and C7 levels, osteophytes are equally frequent on all three locations, but at the C5 and C6 levels osteophytes of the uncinat process largely outnumber those of the zygapophyseal joints (Table 2). About half of the osteophytes of the uncinat and of the superior articular process partially cover the transverse foramina. This is less common with those of the inferior articular facets (Figure 1).

There are no significant differences between the left and right side.

	Uncinat process	Superior articular process	Inferior articular process
C3	45.2%	38.1%	35.7%
C4	32.0%	42.0%	42.0%
C5	61.1%	25.9%	24.1%
C6	63.2%	21.1%	23.7%
C7	36.7%	16.7%	26.7%
TOT	48.2%	29.9%	30.8%

Table 2: Frequency of osteophytes of uncinat process and zygapophyseal joints at different levels (% of vertebrae).

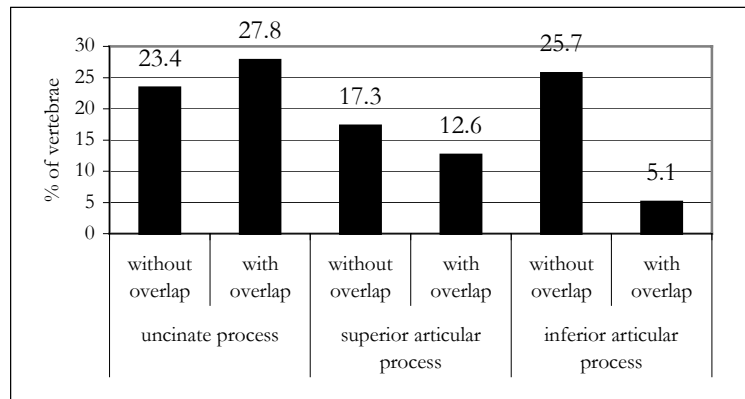


Figure 1: Osteophytes with and without partially covering the transverse foramina (% of vertebrae).

Discussion

The grossly oval transverse foramina of C3 to C6 transmit the vertebral artery, which is surrounded by a plexus of vertebral veins and sympathetic nerve fibers originating from the stellate, middle and inferior cervical ganglia. For these vertebrae the average minimal diameter of the transverse foramen diameter varies between 5.29 and 5.61 and the maximal diameter between 6.65 and 6.86 mm. According to the literature the average diameter of the vertebral artery varies between 3.0mm and 4.7 mm, so this artery covers about two thirds of the minimal and more than half of the maximal diameter of the transverse foramen [1,2,7,12,23].

In this study, as well as in several other investigations, a gradually enlarging diameter of the transverse foramen from C3 to C6 was found, whereas the transverse foramen of the seventh cervical vertebra showed the smallest diameter [8,21,24]. This may be explained by the fact that the transverse foramen of the seventh cervical vertebra usually does not contain the vertebral artery and serves as a passageway for the vertebral vein only. Our observation of a left transverse foramen being larger than the right one corresponds to the observations of Taitz et al. [21]. This could probably be related to the fact that the arteries of the left side are generally bigger than the right ones [1,2,7,12,23].

The most common site of osteophytosis is at the uncinat portion of the vertebrae, which is confirmed by other data [19]. 48.2% of the vertebrae show to have osteophytes at the uncinat process. Roughly half of these 48.2% (24.8%) partially cover the underlying transverse foramen from an anteromedial direction, forcing the VA to meander in a posterolateral direction (Figures 2 and 3). Covering of the foramen by osteophytes from the zygapophyseal joints is less frequent. At these joints, osteophytes from the caudal facet, i.e. the superior articular process of the inferior vertebra are more common at the ventral rim (figure 3). About 40% (12.6% of 29.9%) of them overlap the foramen. The cranial facet, on the inferior articular process of the superior vertebra more commonly protrudes from the posterior rim. Only about 15% (5.2% of 30.8%) of them overlap the foramina. Overlapping osteophytes from the zygapophyseal joints protrude from a dorsal direction, making the VA to run around them in a ventral direction.

It should be emphasized that the observation of overlap of the transverse foramina on dry vertebrae underrates the real overlap by the osteophytes and their surrounding soft tissues.

At the C3, C4 and C7 levels, osteophytes are equally frequent on all three locations, but at the C5 and C6 levels osteophytes of the uncinat process largely outnumber those of the zygapophyseal joints. Presher (1998) states that osteophytes of C5 and C6 vertebrae are more frequent than on higher levels and that this corresponds to the most mobile segments of the cervical spine [14]. Studies show that the uncinat processes are larger between C4 and C6, and may produce spurs in response to the greater shear forces acting at these levels




Figure 2: Sixth cervical vertebra. Discrete osteophytosis on the right side, pronounced osteophytosis of the uncinat process and superior articular facet, partially covering the transverse foramen on the left side.

a) cranial view; b) frontal view

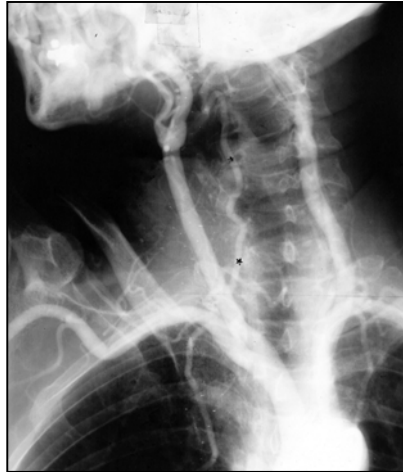

Figure 3: Angiography of the vertebral artery in which the direction of the vertebral artery is forced to meander due to osteophytes at the C5-C6 level.

[3,14,21]. However, compromise of the vertebral artery due to the degenerative cervical spondylotic process, has been shown to occur more commonly at the midcervical spine level, rather than at the lower cervical level [2]. This may be explained by the fact that the distance between the apex of the uncinat process and the medial border of the transverse foramen gradually decreases in a cephalad direction. At high levels, the distance may be less than 2 mm [25].

In most cases the compression is asymptomatic because of competency of the contralateral vertebral artery. Vertebral artery compression by spondylotic disease is only likely to become symptomatic when there is compromise of both vertebral arteries or if the contralateral vertebral artery is congenitally atretic or hypoplastic, ends as the posterior inferior cerebellar artery, or is occluded or stenosed by acquired processes.

An impaired blood flow through the VAs can result in VBI. It is defined as a group of disorders in which blood supply to the back of the brain via the two vertebral arteries and the basilar artery is disrupted [11]. According to the site of ischemia a variety of signs and symptoms will occur, of which the most important are dizziness/vertigo, diplopia, dysarthria, dysphagia, drop attacks and/or nausea.

Transient VBI is by far the most frequent serious adverse reaction after manipulation of the cervical spine and dissection of the VA is the most dramatic, often fatal complication

[3]. Before spinal manipulation takes place, it is mandatory to identify patients at risk in order to avoid damage of the VA. In an attempt to identify individuals at risk, screening tests are frequently performed immediately prior to manipulation of the upper cervical spine and atlanto-occipital junction even after the referring physician performed X-ray and possibly other medical imaging evaluations [16]. These safety tests always incorporate positioning tests combining cervical rotation and extension. This position has to be sustained for a minimum of 10 seconds, unless symptoms are provoked sooner. The therapist observes the patient's eyes for the appearance of nystagmus and simultaneously questions the patient about the reproduction of symptoms. Should these tests elicit symptoms or signs of VBI, no manipulation is done and the patient is referred back to the physician for further evaluation of vascular status. These protocols are based on the premise that these neck positions ascertain arterial compensation through the contralateral artery during temporary occlusion of the other VA.

Severe stenosis of the VA resulting from compression by osteophytes may be converted into complete obstruction of VA blood flow by neck rotation, resulting in symptoms of VBI, like dizziness and blurred vision. However, unilateral occlusion of VAs does not normally result in VBI, because of collateral blood flow from the contralateral VA and the anterior carotid circulation.

Several cases of VA compression by osteophytes are reported in the literature [6,10,13,15,18,19,20]. In many of these cases, the opposite VA was hypo- or aplastic, stenotic or atypically terminated into the posterior inferior cerebellar artery. Our observations offer a pathological explanation for these case reports and suggest that screening protocols should not be restricted to the upper cervical spine, but should be performed before any cervical manipulation.

In addition there is a risk of traumatizing the arterial wall by osteophytes during manipulation, resulting in dissection especially when arteriosclerotic plaques are situated at the same level. The lesion may remain subclinical or may precede objective neurological deficits if the dissection causes lumen obliteration, or thrombus formation and subsequent infarction [22].

It is rational that compression occurs at the ipsilateral side of rotation due to pressure against the osteophytes. The osteophyte causes an inflammatory reaction that produces a fibrous band around the VA; this restricts movement of the artery and increases the

likelihood of compression or kinking on head rotation [9,10]. However, in reports describing uncovertebral osteophytes as the cause of rotational occlusion at the second segment, the direction of rotation is not always ipsilateral to the site of VA occlusion. The question remains as to how the direction of the rotation, causing obstruction of the VA, can vary. Sheehan et al. (1960) proposed that rotational occlusion of the opposite VA occurs by stretching [19]. Again our observations suggest that not only rotational occlusion should be considered. Stretching over uncinat osteophytes could also occur during lateral flexion and stretching over zygapophyseal joints could occur during neck extension. Checking the permeability and compensatory ability of the VAs should be performed prior to any manipulation of the cervical spine, not only in extension-rotation positions, but also always including the specific position from which the manipulation will be performed.

Unless manipulation results in a significant clinical change in the patient's condition, it should be avoided, and never performed in the advanced degenerative disease or in the presence of pronounced neurological signs and symptoms.

Conclusions

Osteophytes from the uncinat process of C5 and C6 vertebrae were found in over 60% of dry vertebrae. About half of them partially covered the underlying transverse foramen from an anteromedial direction. Osteophytes from the zygapophyseal joints are more frequent at C3 and C4 vertebrae. They can also overlap the transverse foramina from a dorsal direction. These overlaps force the VAs to meander around these obstructions, causing narrowing through external compression and are potential sites of trauma to the VAs possibly even leading to dissection. We strongly advocate that screening protocols for VBI be used prior to any manipulation of the cervical spine and should include not only extension and rotation but any starting position from which the planned manipulation will be performed.

Literature

1. Abd-el Bary T, Dujnovny M, Ausman J (1995) Microsurgical anatomy of the atlantal part of the vertebral artery. *Surg Neurol* 44(4): 392-400
2. Argenson C, Francke JP, Sylla S, et al. (1980) The vertebral arteries (segments V1 and V2). *Anat Clin* 2:29-41
3. Citow J, Macdonald R (1999) Posterior decompression of the vertebral artery narrowed by cervical osteophyte: case report. *Surg Neurol* 51:495-499
4. Ebraheim N, Lu J, Biyani A, et al. (1997) Anatomic considerations for uncovertebral involvement in cervical spondylosis. *Clin Orthop* 334:200-206
5. Ernst E (2002) Manipulation of the cervical spine: a systematic review of case reports of serious adverse events, 1995-2001. *Med J Aust* 176: 376-380
6. Hardin C, Williamson W, Steegmann A (1960) Vertebral artery insufficiency produced by cervical osteoarthritic spurs. *Neurology* 10:855-858
7. Jeng J, Yip P (2004) Evaluation of vertebral artery hypoplasia and asymmetry by color-coded duplex ultrasonography. *Ultrasound in Med & Biol* 30 (5): 605-609
8. Jovanovic MS (1990) A comparative study of the transverse foramen of the sixth and seventh cervical vertebrae. *Surg Radiol Anat* 12:167-172
9. Kawaguchi T, Fujita S, Hosoda K, et al. (1997) Rotational occlusion of the vertebral artery caused by transverse process hyperrotation and unilateral apophyseal joint subluxation. *J Neurosurg* 86:1031-1035
10. Kuether T, Nesbit G, Clark W, et al. (1997) Rotational vertebral artery occlusion: a mechanism of vertebrobasilar insufficiency anatomical report. *Neurosurgery* 41(2): 427-433
11. Martin P (1998) Vertebrobasilar ischaemia. *Q J Med* 91: 799-811.
12. Mitchell J (2004) Differences between left and right suboccipital and intracranial vertebral artery dimensions: an influence on blood flow to the hindbrain. *Physiotherapy research international* 9(2): 85-95
13. Ogino M, Kawamoto T, Asakuno K, et al. (2001) Proper management of the rotational vertebral artery occlusion secondary to spondylosis. *Clin Neurol Neurosurg* 103:250-253
14. Prescher A (1998) Anatomy and pathology of the aging spine. *Eur J Radiol* 21:181-195
15. Puca A, Scogna A, Rollo M (2000) Craniovertebral junction malformation and rotational occlusion of the vertebral artery. *Br J Neurosurg* 14(4):361-364
16. Rivett D, Sharples K, Milburn P (1999) Effect of premanipulative tests on vertebral artery and internal carotid artery blood flow: A pilot study. *J Manipulative Physiol Ther*; 22: 368-379
17. Rosner A (2004) Spontaneous cervical artery dissections and implications for homocysteine. *J Manipulative Physiol Ther* 27(2): 124-132
18. Sakaguchi M, Kitagawa K, Hougaku H, et al. (2003) Mechanical compression of the extracranial vertebral artery during neck rotation. *Neurology* 61:845-847
19. Sheehan S, Bauer R, Meyer J (1960) Vertebral artery compression in cervical spondylosis. Arteriographic demonstration during life of vertebral artery insufficiency due to rotation and extension of the neck. *Neurology* 10:386-396
20. Streck P, Reron E, Maga P, et al. (1998) A possible correlation between vertebral artery insufficiency and degenerative changes in the cervical spine. *Eur Arch Otorhinolaryngol* 437-440
21. Taitz C, Nathan H, Arensburg B (1978) Anatomical observations of the foramina transversaria. *J Neurol Neurosurg Psychiatry* 41:170-176
22. Terrett A (2001) Current concepts in vertebrobasilar complications following spinal manipulation. West Des Moines, IA: NCMIC Group Inc., p.36.
23. Thiel H (1991) Gross morphology and pathoanatomy of the vertebral arteries. *Journal of Manipulative and Physiological Therapeutics* 14(2): 133-142
24. Vaccaro A, Ring D, Scuderi G, et al. (1994) Vertebral artery location in relation to the vertebral body as determined by two-dimensional computed tomography evaluation. *Spine* 23:2637-2641
25. Van Roy P, Barbaix E, Clarys J (2001) Functional anatomy of the cervical spine. In: Szpalski M & Gunzburg R *The degenerative cervical spine*. Lippincott, Williams & Wilkins, Philadelphia, pp 1-27.

CHAPTER 4

ATHEROSCLEROSIS IN THE VERTEBRAL ARTERY: AN INTRINSIC RISK FACTOR IN THE USE OF SPINAL MANIPULATION?

Barbara Cagnie¹, Erik Barbaix², Elke Vinck¹, Katharina D'Herde², Dirk Cambier¹

¹ Department of Rehabilitation Sciences and Physiotherapy, Ghent University, Belgium

² Department of Human Anatomy, Embryology, Histology and Medical Physics, Ghent University, Belgium

Submitted to Surgical and Radiologic Anatomy

Abstract

Background: The presence of atherosclerotic plaques and their influence on the vertebral artery is of clinical importance within the scope of spinal manipulation. Manipulation may stimulate the development of atherosclerotic plaques, could detach an embolus with ensuing infarction, injure the endothelium or may directly cause a dissection in the presence of atherosclerotic plaques. In order to identify the sites and frequency of atherosclerotic plaques and to determine its relation to the tortuous course of the vertebral artery, a cadaveric study was performed.

Methods: The vertebral arteries of 57 human cadavers were studied. Abnormalities in the origin and course of the vertebral artery were noted, along with any associated osseous, or cartilaginous anomalies in the neck. After dissection, the artery was opened and macroscopically screened for the presence of atherosclerotic plaques.

Results: In 22.8% of the cases, no atherosclerotic plaques were present. In 35.1%, the atherosclerotic plaques were unilateral, of which 60.0% on the left side and 40.0% on the right side, and in 42.1% of the cases the occurrence was bilateral. Atherosclerotic plaques were significantly more present in the V3 segment than in the V1 (0.007) and V2 segment (0.049). In the V1 ($p=0.008$) and V2 segment ($p=0.002$), there was a correlation between a tortuous course of the vessel and the occurrence of atherosclerotic plaques.

Conclusions: In individuals with marked atherosclerotic disease, stretching and compression effects of rotational manipulative techniques on atherosclerotic vessels impose a further risk factor for vertebrobasilar insufficiency. It is strongly recommended, that if any doubt exists about the nature of a clinical presentation, vigorous manual procedures should be avoided until either the diagnosis is definitive or gentle manual therapy has proven effective.

Key words: atherosclerosis, vertebral artery, manipulative therapy

Introduction

Manipulation is one of many interventions used by chiropractors, manual therapists and medical doctors and eventually other health practitioners to treat musculoskeletal disorders of the cervical spine. However, the benefits of these cervical spine manipulations are yet to be clearly established and the known risks are even potentially serious. Transient vertebrobasilar insufficiency is by far the most frequent serious adverse reaction after manipulation of the cervical spine while dissection of the vertebral artery is the most dramatic, often fatal complication [5].

Blood flow through the vertebral artery may be impaired by extrinsic lesions, such as osteophytes but is in most cases troubled by intrinsic lesions including atherosclerosis and dissection [3]. The presence of atherosclerotic plaques and their influence on the vertebral artery is therefore of major clinical importance within the scope of cervical spine manipulation.

In the first place, the development of atherosclerosis may be stimulated by stretching and/or compression of an artery, such as occurs in extreme rotation of the cervical spine. These applied forces decrease the luminal cross-sectional area and compromise the blood flow in the vessel. In extreme cases, injury to the tunica intima, and particularly the endothelium, may be inflicted. Such microtrauma may lead, ultimately, to the development of atherosclerosis in the artery [13].

Secondly, spinal manipulation could theoretically dislodge an embolus from an atherosclerotic plaque and subsequently cause an ischemic stroke [9]. This may especially occur in places where calcified plaques are bended or stretched over extrinsic compression points such as osteophytes.

Thirdly, atherosclerosis may also play a role in the pathogenesis of dissecting aneurysms, although its role is controversial [19]. The primary cause of fusiform aneurysms is thought to be atheromatous degeneration of the artery, including intimal thickening, disruption of internal elastic lamina, lipid deposition and loss of elasticity. Other investigators reported that the aneurysm is not necessarily associated with atherosclerosis, suggesting factors other

than atherosclerosis of which direct trauma to the wall, is the most common. The combination of atherosclerosis and direct trauma, such as manipulation of the neck, may therefore increase the risk of a dissection [19].

The complex anatomy and often well-hidden location of the vertebral artery has not made it an attractive or easy vessel to study [18]. Precise morphological examination of this vessel is desirable in patients presenting with a clinical diagnosis of vertebrobasilar insufficiency, although demonstration of atherosclerotic plaques can be difficult in this deep and tortuous vessel, surrounded by a bony canal.

Therefore, a cadaveric study was performed to identify the sites and frequency of atherosclerotic plaques and to determine their relation to the tortuous course of the vertebral artery.

Methods and materials

The vertebral arteries of 57 human cadavers (32 men and 25 women), who donated their body by testament to the Department of Anatomy of the Ghent University, were examined. The mean age was 81.3 years (SD: 10.4). 17% were younger than 70, 28.3% were between 70 and 79; 22.6% between 80 and 89 and 32.1% were older than 89 years of age. Each vertebral artery was dissected free of its loose connective tissue attachments from its origin up to the transverse foramen of the sixth cervical vertebra. The anterior bony boundary of the foramen of each of the sixth, fifth, fourth, and third cervical vertebrae was then removed and each artery was mobilised as far as the axis vertebra, using the scalpel handle.

After emerging from the transverse foramen of C3 the vertebral artery enters the ventral and somewhat anterior opening of the foramen of the axis. This foramen looks more like a short angulated canal, whose roof is formed by the processus articularis superior of C2. The exit opening is directed slightly posterior and cranial. The artery then continues in a cranial and slightly lateral direction to reach the foramen of the atlas. To mobilise the artery any further, it was necessary to sever the anterior and posterior bony boundary of the transverse foramen of the atlas vertebra, using the wire cutters. This gave sufficient

exposure to enable essential mobilisation of the artery as far as the posterior atlanto-occipital membrane.

The vertebral artery was virtually divided into four segments; the pre-vertebral (V1), the vertebral (V2), the atlanto-axial (V3), and the intracranial segment (V4). Abnormalities in the origin and course of the vertebral artery were noted, along with any associated osseous, or cartilaginous anomalies in the neck. After dissection, the artery was opened and macroscopically screened for the presence of atherosclerotic plaques.

The diameter of the vertebral arteries was determined by measuring the width of the artery after opening it longitudinally with a scissors and dividing the width by 3.14 (Π)

Statistical analysis

The data were analysed using the Statistical Package for the Social Sciences (SPSS) software (version 10.0). The results have been reported as descriptive statistics. Differences in the mean diameter of the vertebral artery between sides were analysed using a paired t-test. Differences in occurrence of atherosclerotic plaques between sides, segments and gender were calculated through cross-tabulations. Correlations between a tortuous course and the occurrence of atherosclerotic plaques were also determined by cross-tabulations.

Results

The mean diameter of the left vertebral artery [3.79mm (SD: 0.80)] was significantly greater than the mean right diameter [3.06mm (SD: 1.25)] ($p=0.005$). In 61.4% of the cases the left artery was dominant, whereas in 19.3% the right diameter was greater than the left. In 19.3% of the cases, both arteries had a similar diameter (difference ≤ 0.30 mm). The mean diameter of the dominant artery [4.00mm (SD: 1.05)] was significantly greater than the mean non-dominant diameter [2.85mm (SD: 0.82)] ($p<0.001$). Five vertebral arteries (4.4%) were atretic (<2 mm diameter), with the contralateral artery being of normal calibre.

Three left vertebral arteries originated from the arcus aortae and one right artery had a double origin from the subclavian artery. One right and two left arteries entered the transverse foramen of the fifth instead of the sixth cervical vertebra and one left artery penetrated the transverse foramen of the seventh cervical vertebra.

	Atherosclerotic plaque		
	Left	Right	Total
Origin	33.3%	23.6%	28.6%
V1 segment	10.5%	8.9%	9.7%
V2 segment	31.6%	10.7%	21.2%
V3 segment	29.8%	37.5%	33.6%
V4 segment	7.0%	7.1%	7.1%

Table 1: Frequency of occurrence of atherosclerotic plaques

In 22.8% of the cases, no atherosclerotic plaques were present. In 35.1%, the atherosclerotic plaques were unilateral, of which 60.0% on the left side and 40.0% on the right side, and in 42.1% of the cases the occurrence was bilateral. Atherosclerotic plaques were significantly more frequent in the V3 segment than in the V1 ($p=0.007$) and V2 segments ($p=0.049$). Although not significant, the frequency of atherosclerosis was obviously high at the origin and low in the V4 segment. (Table 1) There were no differences in occurrence of atherosclerotic plaques between left and right and between dominant and non-dominant side. In the V3-segment, the frequency of atherosclerotic plaques differed significantly between the age groups. (Table 2) During its course in the V2-segment, atherosclerotic plaques were equally divided at all levels (figure 1). In the V3-segment, the most frequently affected site was at the C1-C2 level. (Figure 2)

In the V1 ($p=0.008$) and V2 segment ($p=0.002$), there is a correlation between a tortuous course of the vessel and the occurrence of atherosclerotic plaques. In the V2 segment, a tortuous course of the vertebral artery was caused by osteophytes at the C5/6 level ($n=4$), C4/5 level ($n=6$) and C3/4 level ($n=4$). In the V3 segment, osteophytes were present at the C1/C2 level in 14% of the cases ($n=8$).

For all parameters, there were no significant differences between male and female.

	Percentage	Origin	V1	V2	V3	V4
<70	17%	27.8%	5.6%	38.9%	38.9%	0%
70-79	28.3%	26.7%	3.3%	16.7%	23.3%	6.7%
80-89	22.6%	33.3%	16.7%	12.5%	20.8%	0%
>89	32.1%	30.3%	14.7%	26.5%	55.9%	14.7%
		NS	NS	NS	0.015	NS

Table 2: Frequency of occurrence of atherosclerotic plaques according to age.

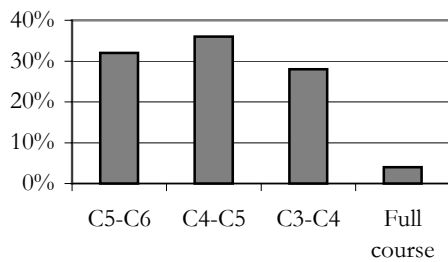


Figure 1: Distribution of atherosclerotic plaques in the V2 segment

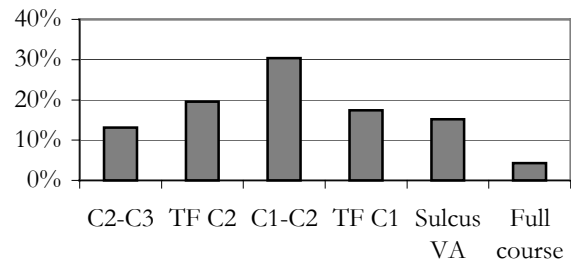


Figure 2: Distribution of atherosclerotic plaques in the V3 segment. TF = transverse foramen

Discussion

In most of the specimens, the left vertebral artery had a larger diameter than the right one. This is in accordance with previous reports [12,14,23]. On the other hand, in our study, dominance of the left vertebral artery was slightly more frequent (61.4%), than demonstrated in former published studies. According to this literature, the left vertebral artery is dominant in approximately 50% of the individuals, the right in 25% of the cases and in the remaining quarter both vertebral arteries have a similar calibre [1,2,4].

In 35.1%, the atherosclerotic plaques were unilateral, whereas in 42.1% of the cases the occurrence was bilateral. This may have some clinical consequences during manipulation of the cervical spine. Mechanical stretching of the artery, such as may occur during rotational manipulation, may cause a decrease in vertebral artery blood flow. Patients with a marked degree of atherosclerosis of the vertebral arteries should be handled with care because of the possibility of causing a significant decrease in vertebral artery blood flow that may already be reduced [14]. In an attempt to identify individuals at risk, screening tests are frequently performed prior to manipulation [16]. These protocols include provocation tests performed in different positions of neck extension combined with rotation and are based on the premise that these neck positions ascertain arterial compensation through the contralateral artery and anterior carotic circulation during temporary occlusion of the other vertebral artery [9]. A vertebral artery seriously narrowed by atherosclerosis, may not be capable to compensate for the positional occlusion of its normal counterpart. In this case, symptoms will occur during pre-manipulative testing and as a consequence manipulation is contra-indicated. A patient with critical narrowing of one vertebral artery due to

atherosclerosis, but with satisfactory collateral circulation, may not experience ischaemic damage during pre-manipulative testing. This situation may give the manipulative therapist a false sense of safety, because the manipulative procedure may still lead to vertebrobasilar injury due to extreme angulation and compression of the involved vertebral artery. In cases of bilateral involvement, manipulation is an absolute contra-indication.

Because of differences in blood flow dynamics, there are preferred sites of lesion formation within the arteries. Ravensbergen et al. suggested that atherosclerotic lesions tend to form just beyond the site where an artery changes directions or bifurcates [15]. Specific arterial sites, such as branches, bifurcations, and curvatures, cause characteristic alterations in the flow of blood, including decreased shear stress and increased turbulence. Thus, alterations in blood flow appear to be critical in determining which arterial sites are prone to lesions [17]. According to our results, atherosclerotic plaques are most frequently situated at the origin and in the V3 segment. Fisher et al. found the chief site of occlusion and stenosis at the origin of the vertebral artery from the subclavian [6]. Also in the series of Martin et al. and Stein et al. vertebral occlusion was always at its origin [10,22].

The third part of the vertebral artery is believed to be more vulnerable to stretching and/or compression distortions. The V3 segment extends from the C3-C2 intertransverse space to the point where it penetrates the dura mater [24]. This part of the vessel is relatively unprotected as it undergoes a series of bends to pass through the transverse foramen and lies on the posterior arch of the atlas vertebra, before passing through the dura mater to follow an intracranial path. Hence, distortion of the third part of the vertebral artery during movements of the cervical spine will result in a decrease in its luminal cross-sectional area, reducing the blood flow through the third, and subsequently, fourth parts of the vessel. Atherosclerosis of the artery would exacerbate this effect on vertebrobasilar blood flow.

In the V3-segment, the most frequently affected site is at the C1-C2 level. This is in accordance with the findings of Schievink, who found that both stenotic and aneurysmal lesions are most common in the distal segment of the artery at the level of the first and second cervical vertebrae [19].

The occurrence of atherosclerotic plaques in the fourth segment was less frequent. This is in accordance with the findings of Hutchinson and Yates, Solberg et al., Min et al. and Shin et al., who proposed that the fourth part of the vertebral artery is rarely and less affected by atherosclerosis than the second and third parts of the vessel [7,8,11,20,21]. Similarly, the

results of the present study are in agreement with those of the authors who reported a higher incidence of atherosclerosis in 'extracranial arteries'[13].

In the V1 and V2 segment, there is a correlation between a tortuous course of the vessel and the occurrence of atherosclerotic plaques. In the V2 segment, the artery fits tightly into the transverse foramen of the sixth to the second cervical vertebra as it follows a relatively linear course. The artery is in close relationship medially with the uncinat processes of each vertebral body, and posteriorly with the ventral rami of the cervical nerves. During its course through the transverse foramina, a segment of the vertebral artery may become looped or coiled and the abnormal or tortuous loop may cause pressure defects in the adjacent cervical vertebra. Similarly, anterior deflections of the vertebral artery may also be caused by osteophytes from the ventral rim of the zygapophyseal joints [24].

Limitations

The present results must be viewed within the limitations of the study. The mean age of the studied population was 81.2 years. This could explain the quite high frequency of atherosclerotic plaques and may overrate the problem. However, the lesions of atherosclerosis may be present throughout a person's lifetime.

Secondly, the atherosclerotic plaques were only studied in a macroscopic way. Although this could be seen as a limitation, it is assumed that only these plaques will have influence on the blood flow.

Conclusion

Stretching and compression effects of rotational manipulative techniques on atherosclerotic vessels impose a further risk factor not only for vertebrobasilar insufficiency but also for lesions of the endothelium and detaching existing thrombi in individuals with marked atherosclerotic diseases. The possibility of such underlying pathology should be considered in any treatment of patients involving the use of rotational cervical spine manipulations. Because atherosclerotic plaques may occur at all segments, pre-manipulative screening

protocols should not only be used before manipulation of the upper cervical spine, but before any cervical manipulation.

It is strongly recommended, that if any doubt exists about the nature of a clinical presentation, vigorous manual procedures should be avoided until either the diagnosis is definitive or gentle manual therapy has proven effective.

References

1. Abd-el Bary T, Dujnovny M, Ausman J (1995) Microsurgical anatomy of the atlantal part of the vertebral artery. *Surg Neurol* 44(4): 392-400
2. Adachi B (1928) *Das Arteriensystem der Japaner*. Bd I. Maruzen, Kyoto.
3. Citow J, Macdonald R (1999) Posterior decompression of the vertebral artery narrowed by cervical osteophyte: case report. *Surg Neurol* 51:495-499
4. Cloud G, Markus H (2003) Diagnosis and management of vertebral artery stenosis. *Q J Med* 96: 27-34.
5. Ernst E (2002) Manipulation of the cervical spine: a systematic review of case reports of serious adverse events, 1995-2001. *Med J Aust* 176: 376-380
6. Fisher C, Gore I, Okabe N, White P (1965) Atherosclerosis of the carotid and vertebral arteries - extracranial and intracranial. *J Neuropathol exp neurol* 24:455-476.
7. Hutchinson E, Yates P (1956) The cervical portion of the vertebral artery. A clinico-pathological study. *Brain* 79: 319-31.
8. Hutchinson E, Yates P (1957) Carotico-vertebral stenosis. *Lancet* 1: 2-8.
9. Licht PB, Christensen HW, Hojgaard P, Marving J (1998) Vertebral artery flow and spinal manipulation: a randomized, controlled and observer-blinded study. *J Manipulative Physiol Ther* 21: 141-144.
10. Martin M, Whisnant J, Sayre G (1960) Occlusive vascular disease in the extracranial cerebral circulation. *Arch Neurol* 3: 530-538.
11. Min W, Kim Y, Kim J, Park S, Suh C (1999) Atherothrombotic cerebellar infarction: vascular lesion-MRI correlation of 31 cases. *Stroke* 30: 2376-2381.
12. Mitchell J, McKay A (1995) Comparison of left and right vertebral artery intracranial diameters. *Anat Rec* 242: 350-354.
13. Mitchell J (2002) Vertebral artery atherosclerosis: a risk factor in the use of manipulative therapy? *Physiother Res Int* 7: 122-135
14. Mitchell J (2004) Differences between left and right suboccipital and intracranial vertebral artery dimensions: an influence on blood flow to the hindbrain? *Physiother Res Int* 9: 85-95.
15. Ravensbergen J, Ravensbergen JW, Krijger JKB, Hillen B, Hoogstraten HW (1998) Localizing role of hemodynamics in atherosclerosis in several human vertebrobasilar junction geometries. *Arterioscler Thromb Vasc Biol* 18: 706-716.
16. Rivett D, Sharples K, Milburn P (1999) Effect of premanipulative tests on vertebral artery and internal carotid artery blood flow: A pilot study. *J Manipulative Physiol Ther* 22: 368-379.
17. Ross R (1999) Atherosclerosis - an inflammatory disease. *N Engl J Med* 340: 115-126.
18. Sakata N, Takebayashi S, Kojima M, Masawa N, Suzuki K, Takatama M, Kusumi Y, Mitsumata M (2001) Different roles of arteriosclerosis in the rupture of intracranial dissecting aneurysms *Histopathology* 38: 325-337.
19. Schievink W (2001) Spontaneous dissection of the carotid and vertebral arteries. *N Engl J Med* 344: 898-906.
20. Shin H, Yoo K, Chang H, Caplan L (1999) Bilateral intracranial vertebral artery disease in the New England Medical Center, Posterior circulation Registry. *Arch Neurol* 56: 1353-58.
21. Solberg L, McGarry P, Moossy J, Strong J, Tejada C, Loken A (1968) Severity of atherosclerosis in cerebral arteries, coronary arteries and aortas. *Ann N Y Acad Sci* 149: 956-73.
22. Stein B, McCormick W, Rodriguez J, Taveras J (1961) Incidence and significance of occlusive vascular disease of the extracranial arteries as demonstrated by post-mortem angiography. *Tr Am Neurol Assoc* 86: 60-66.
23. Thiel H (1991) Gross morphology and pathoanatomy of the vertebral arteries. *J Manipulative Physiol. Ther* 14: 133-142.
24. Van Roy P, Barbaix E, Clarys JP (2001) Functional Anatomy of the cervical spine. In: Szpalski M. & Gunzburg R. *The degenerative cervical spine*, Lippincott, Williams & Wilkins, Philadelphia.

CHAPTER 5

ABNORMALITIES IN THE COURSE OF THE VERTEBRAL ARTERY ASSOCIATED WITH AN OSSIFIED HYOID CHAIN. A CONTRA-INDICATION FOR MANIPULATIONS OF THE CERVICAL SPINE?

Barbara Cagnie¹, Erik Barbaix², Elke Vinck¹, Katharina D'Herde², Dirk Cambier¹

¹ Department of Rehabilitation Sciences and Physiotherapy, Ghent University, Belgium

² Department of Human Anatomy, Embryology, Histology and Medical Physics, Ghent University, Belgium

Journal of Manipulative and Physiological Therapeutics, in press, April 2005

Abstract

Objective: To describe a case of a simultaneous occurrence of an ossified stylohyoid ligament and anomalies of the vertebral artery and to consider the clinical implications for manipulative therapists.

Clinical features: Developmental variants, post traumatic and degenerative changes of the hyoid apparatus may result in variable degrees of ossification or calcification. Pathology of this apparatus is seldom included in clinical evaluations by manipulative therapists, although ossification and calcification may be responsible, not only for pharyngeal pain but also for painful restrictions of head and neck movements and for syncope mimicking drop attacks.

Intervention and Outcome: Dissection showed a simultaneous occurrence of complete developmental ossification of the left hyoid apparatus, variants of the vertebral artery and a left superior vena cava in a 56-year-old male cadaver.

Conclusions: This unusual disorder should be considered in the differential diagnosis of facial and neck pain especially within the scope of manipulation of the upper cervical spine. Cervical spine manipulation can exacerbate existing pathological conditions of the stylohyoid apparatus, thereby irritating neurovascular structures, but can also induce a fracture. In addition, developmental ossification of this apparatus might be associated with anomalies in the atlantic section of the vertebral artery which make the patient more susceptible to vertebrobasilar insufficiency.

We hence conclude that extreme care should be taken in the presence of such an ossification, in order to avoid trauma to the stylohyoid apparatus and maybe even because of increased vertebrobasilar risk.

Key Indexing Terms: hyoid apparatus, stylohyoid ligament, vertebral artery, left superior vena cava, cervical spine manipulation.

Introduction

The styloid process is a site of muscle attachment and an important landmark on skull models.¹ The stylohyoid ligament connects the styloid process with the lesser horn of the hyoid bone. These elements are seldom included in clinical evaluation by therapists focussing on the musculoskeletal apparatus².

Developmental (congenital), post traumatic and degenerative changes frequently result in a variable degree of ossification and/or calcification of this ligament, ranging from discrete calcifications near the lesser horn to complete ossification.^{3,4} This clinical phenomenon is normally benign and asymptomatic, but a number of patients, generally over 40 years old, complain of vague symptoms such as irradiating pharyngeal pain, earache, headache, cervical pain and painful restrictions of the movements of head and neck.⁵⁻⁹ Especially the latter may be mistaken for symptoms of cervical spine pathologies and patients may therefore initially seek help from manipulative therapists. In addition, ossification of the stylohyoid ligament is often associated with malformations of the odontoid process of C2 and the atlanto-occipital joint, also resulting in neck complaints.¹⁰

Ossification of this apparatus may therefore have clinical implications for therapists who use manipulation and a correct diagnosis is of great importance within the scope of spinal manipulation of the upper cervical spine. Johnson et al hypothesize, on the basis of two cases, that congenital ossification of the stylohyoid apparatus might be associated with anomalies in the atlantic section of the vertebral artery.¹¹ If this is the case, an ossified stylohyoid ligament should be considered as an exclusion criterion for cervical spine manipulations.

We report a case of a simultaneous occurrence of an ossified stylohyoid ligament and anomalies of the vertebral artery and consider the clinical implications for manipulative therapists.

Case report

The present report deals with a male cadaver, dissected in the department of anatomy, Ghent University. The 56-year-old man had a completely ossified left stylohyoid ligament articulating with the styloid process through a synovial joint (Figure 1).

The vertebral artery originated from the aortic arch between the left carotic artery and the left subclavian artery (Figure 2) and entered the transverse foramen of the fifth instead of the sixth cervical vertebra. This artery had also a noticeably abnormal course at the atlanto-axial level, where the left vertebral loop was totally absent and thus was in close contact with the left lateral atlanto-axial joint. The diameter of the left vertebral artery was much smaller than the right vertebral artery (Figure 3).

There was also a left superior vena cava, which is in fact a persistent left precardinal vein, draining the left internal jugular and subclavian veins. This vein passed ventral to the hilus of the left lung, to reach the atrioventricular sulcus. It then ran to the right in this sulcus as a distended coronary sinus to empty in the right atrium. The right superior vena cava had a normal course. There was no anastomotic left brachiocephalic vein between the two venae cavae.

There was a scalenus minimus muscle inserting on the first rib, between the subclavian artery and the brachial plexus.

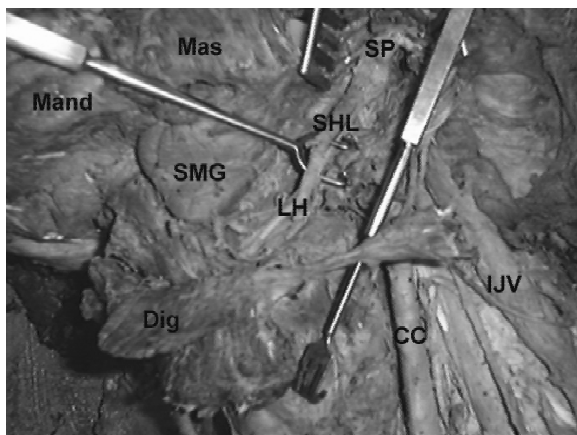


Figure 1: ossified stylohyoid ligament, lateral view
 Mas: masseter muscle; Mand: mandible; SMG: Submandibular gland; Dig: digastric muscle detached from mandible; CC: common carotid artery; IJV: internal jugular vein; SP: styloid process; SHL: stylohyoid ligament (ossified); LH: Lesser horn of the hyoid bone.

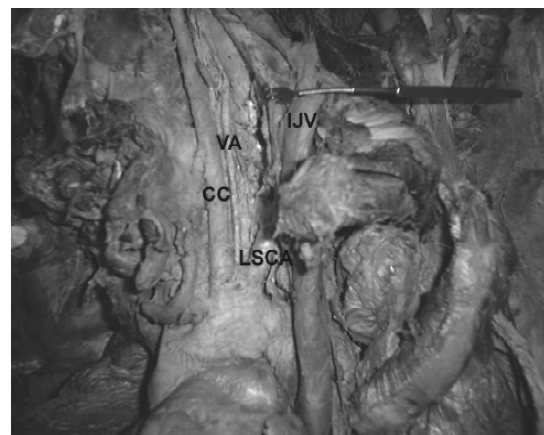


Figure 2: Origin of the vertebral artery from aorta.
 CC: common carotid artery; LSCA: left subclavian artery; VA: vertebral artery; IJV: internal jugular vein.

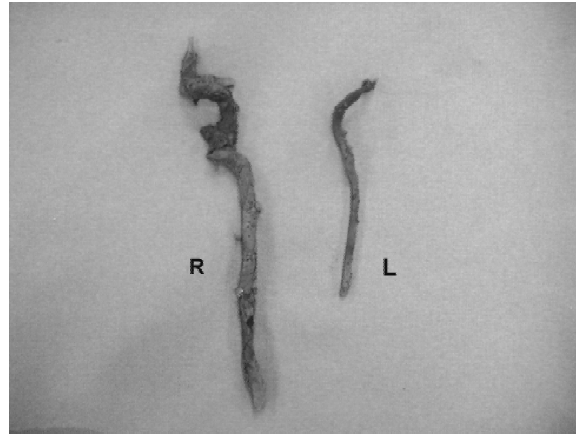


Figure 3: Right and left vertebral artery.

Embryology and clinical anatomy

The stylohyoid ligament

The styloid process and the stylohyoid ligament are derived from the second branchial arch.¹² These structures are first formed in cartilage from neural crest origin. The cartilage of the styloid process ossifies while the epihyal cartilage, which connects the styloid process and the hyoid bone, is usually reabsorbed.^{2,12} The stylohyoid ligament is formed from the remnants of the epihyal cartilage, also known as Reichert's cartilage. It develops between day 45 and 49 (Figure 4).¹⁰

The cause of an ossification of the stylohyoid ligament is unclear. Steinman has proposed three theories that could explain the ossification.⁹

Congenital ossification of the stylohyoid ligament may be attributed to the persistence of a cartilaginous element, the epihyal cartilage, which may grow abnormally and be converted to bone.^{12,13} As a result the stylohyoid ligament may become partially or even completely ossified resulting in one or two stylohyoid bones. Between the different ossified structures, synchondroses and true synovial joints may develop.⁷

Reactive changes could be due to stimulation of the still growing ossification centers of the styloid process, resulting in hyperplasia or excessive length of the process.³ Reactive metaplasia is another possibility. In this case osseous centers within the stylohyoid ligament are stimulated and start ossifying, thereby joining the stylohyoid apparatus into a stiff

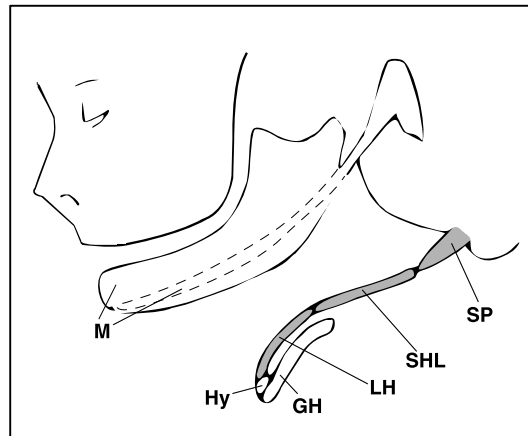


Figure 4: Schematic representation of the styloid apparatus with indication of embryologic derivation.

M: Meckel's cartilage; SP: styloid process; SHL: stylohyoid ligament; LH: lesser horn of the hyoid bone; Hy: body of the hyoid bone; GH: greater horn of the hyoid bone; grey zone corresponds with Reichert's cartilage.

inelastic cord to the styloid process.^{3,4} Tonsillectomy was initially recognized as a traumatic trigger of hyperplasia or metaplasia, but other traumata and recurrent or chronic inflammation could also induce these changes.^{3,4}

Changes are also seen in degenerative rheumatologic conditions like diffuse idiopathic skeletal hyperostosis (DISH) and in osteophytosis of the cervical spine.¹⁴ With the aging process, as soft tissues lose their elasticity, a localized inflammatory reaction causes a tendonitis at the junction of the ligament and the lesser horn. The ligament stiffens and the inflammatory response of associated tissues cause the symptoms.³

According to their etiology, Camarda classified cervicopharyngeal pain related to the stylohyoid apparatus into three distinct entities.³ A diagnosis of Eagle's syndrome is applied to symptomatic patients in whom elongated, ossified styloid processes develop within a period of time posttraumatically. Clinically, Eagle's syndrome is divided into two subtypes.^{15,16} The classical stylohyoid syndrome, almost always following tonsillectomy, is characterized by dull and persistent, pharyngeal pain, radiating to the mastoid region, accompanied occasionally by dysphagia and painful swallowing, foreign body sensation, as much as facial and/or cervical pain. The stylocarotid syndrome is characterized by cervical pain, provoked and aggravated by rotation and compression of the neck and the

occurrence of recurrent syncopes, exacerbated by certain movements, due to compression of the carotid artery and the glomus caroticum.

Second, a diagnosis of stylohyoid syndrome is applied to patients in whom elongated styloid processes and/or stylohyoid apparatus ossification develop early in life as an anatomic anomaly, and in whom symptoms later develop.³ Last, a diagnosis of pseudostylohyoid syndrome is applied to patients in whom, because of aging, a tendinosis at the junction of the stylohyoid ligament and the lesser horn of the hyoid bone develops.³ As the mandible is connected to the basis of the skull, not only by the sphenomandibular ligament but also by an expansion of the stylohyoid ligament for which the term mandibulo-stylohyoid ligament was proposed, movements of the mandible can also trigger symptoms.^{17,18}

The vertebral artery

The development of vertebral arteries takes place between day 33 and 55 of intra-uterine life.^{19,20} The vertebral artery is formed by the development of longitudinal anastomoses that link the seven cervical intersegmental arteries. The intersegmental arteries soon obliterate and disappear, except for the segment of the 7th intersegmental artery, which becomes the subclavian artery and which includes the point of origin of the vertebral artery in adults.²¹

In about 2,5% of the population, the anastomosis between the sixth and seventh intersegmental arteries does not develop on the left side and the sixth intersegmental artery persists. In this event the left vertebral artery originates from the aortic arch between the left common carotid and subclavian arteries (Figure 5).²⁰ When the vertebral artery originates from the aortic arch, it usually enters the transverse foramen of the fourth or fifth cervical vertebra rather than the sixth.²¹ Normally, from the third cervical vertebra onward, the artery undergoes a more lateral course to reach the transverse foramen of the axis.¹⁹ As it leaves the foramen the artery inclines further laterally and then bends upward to reach the transverse foramen of the atlas. After emerging from the transverse foramen of the atlas, the vertebral artery turns posteriorly and then medially around the lateral mass. After piercing the dural sac, it then runs anterosuperiorly to unite with its heterolateral counterpart to form the basilar artery.¹⁹ In the present case the transverse foramen of C2 was not angulated and only slightly oblique. The transverse process of C1 seemed shorter than we would normally expect, so the artery ran in close contact with the capsule of the lateral C1-C2 joint from which it was difficult to separate by dissection.

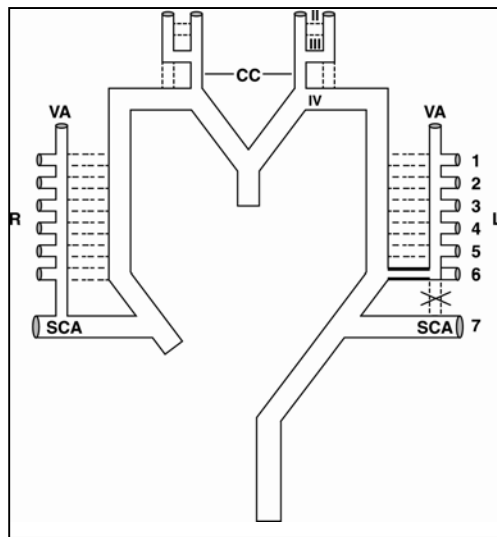


Figure 5: Schematic representation of the embryologic mechanisms underlying anatomic variants of the origin of the vertebral artery. Right: normal development; left: present variant development. CC: common carotid artery; SCA: subclavian artery; VA: vertebral artery; 1-7: intersegmental arteries; II-IV: branchial arteries.

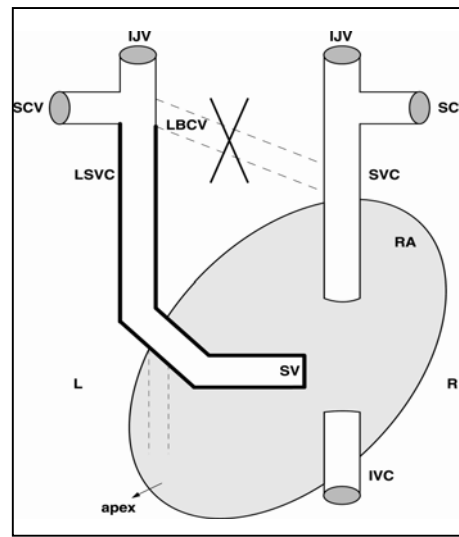


Figure 6: Schematic representation of the embryologic mechanism underlying anatomic variants of the vena cava superior (dorsal view). IJV: internal jugular vein; SVC: superior vena cava; LSVC: left superior vena cava; SCV: subclavian vein; LBCV: left brachiocephalic vein (not developed); SV: sinus venosus, becoming coronary sinus; IVC: inferior vena cava; RA: right atrium.

Superior vena cava

In the very early stages of the development of the venous system, the main veins are arranged in the shape of a letter H: a left and a right precardial and a left and a right postcardinal vein. On each side pre- and post cardinal veins join to form a short common cardinal vein which enters the horizontal sinus venosus at the dorsal side of the primitive heart.²² The precardial veins drain the head, neck and upper extremities and become the jugular and subclavian systems. An anastomosis between the left and right precardial veins develops around day 50 and becomes the left brachiocephalic vein. In about 0.4% of the population the anastomosis between left and right precardial veins does not develop or remains hypotrophic and the left precardial vein remains open, resulting in a normal right and a left superior vena cava (LSVC), draining into the coronary sinus (Figure 6).^{23,24}

Discussion

Damage to the vertebral artery is the most feared complication after manipulation of the cervical spine. Other complications are seldom considered in literature.²⁵

The present case as well as Johnson's case descriptions report on the simultaneous occurrence of an ossified stylohyoid ligament and anomalies of the vertebral artery.¹¹ The question arises as to whether this combination is a common phenomenon or a mere coincidence. If this link can be established, the discovery of an ossified stylohyoid ligament would be a warning for potential arterial abnormalities.

The stylohyoid ligament is formed from the remnants of the Reichert's cartilages. It develops between day 45 and 49.¹⁰ The earliest development of the vertebral arteries is apparent in the embryo at the 7 mm stage (day 33) and is usually completed by the 14 to 17 mm stage (day 54).¹⁹ The formation of the left brachiocephalic vein takes place around the 50th day, soon followed by the obliteration of the left precardinal vein.²² Given the embryological time table, it could be argued that some aberrant developments around the 50th day suggest a probable link between the observed anomalies.

The fact that in the present anatomical description as well as in Johnson's unilateral case, the vascular anomalies occurred on the same side as the ossification, adds to the hypothesis of a consistent link. However, given the embryological development, an aberrant development of the brachiocephalic vein with concomitant aberration of the right venous system is quite different and more exceptional.

This assumption may have clinical implications for therapists performing spinal manipulations in the cervical region. The normal loop at the atlanto-axial level, which is thought to protect the artery during rotational movements, is deficient in the described cases. Subjects with loop deficiencies may be more susceptible to disturbances in blood flow, resulting in vertebrobasilar insufficiency.

As a consequence, it seems worthwhile to increase the number of observations in order to confirm or deny the hypothetical link. If the link between deficient arterial loops and ossified stylohyoid ligaments is consistent, the ossified stylohyoid ligament, which is well visible on X—rays, should be considered as an exclusion criterion for cervical spine manipulations.

Other complications are attributable to the ossified stylohyoid ligament itself. Besides the relatively rare congenital complete ossification, posttraumatic changes are much more frequent. Potential problems can arise in the presence of trauma, such as whiplash. Since manual therapy is the treatment of choice for these types of cervical trauma, it is important that the therapist be knowledgeable about this syndrome.²⁶ S/He should be attentive in examining the routine lateral skull view and panoramic radiographs during diagnosis. The stylohyoid ligament can be injured and since these ligaments have high collagen content, they do not stretch, but rather permanently elongate. Cervical spine manipulation or end-range mobilisation can prolong irritation and inflammation in the compromised soft tissues surrounding the calcified stylohyoid structures.¹⁶ The therapist who initiates treatment blindly may unwittingly exacerbate the ossification of the stylohyoid ligament.

Once established, posttraumatic ossifications, especially those resulting in elongation of the styloid process, may induce a type II Eagle syndrome, through mechanical irritation of the neurovascular complex.³ The syncopes associated with this syndrome resemble drop attacks and hence should be considered as a contra-indication. The worst-case scenario for the uninformed or unsuspecting manipulator is the risk that this calcified pencil-shaped structure could damage the vital proximate vascular structures during the thrusts with devastating consequences.

Finally, ossified stylohyoid ligaments and elongated styloid processes may fracture with or without an obvious traumatic incident.^{12,27,28} With sudden jerking of the head, such as a thrust during a manipulation, a fracture of the ossified stylohyoid ligament can occur, and a non-union may develop because of continuous micro-movement of the hyoid bone. The proliferation of granulation tissue in the region of the non-union could then cause pressure on the surrounding structures, resulting in pain in that area.²⁹

As the stylohyoid ligament is also connected to the angle of the mandible through a mandibulo-stylohyoid ligament, regional rotational techniques grasping the mandible, can transmit traction onto the stylohyoid apparatus and fracture-ossified elements. Such a fracture causes heavy disabilities and pain and may require surgery.^{12,27,28}

Considering this, extreme caution should be exercised and forceful manipulations should be avoided in the case of an ossified stylohyoid ligament or elongated styloid process.

Conclusion

Developmental variants, post traumatic and degenerative changes can result in a variable degree of ossification or calcification of the stylohyoid apparatus. Pathology of this apparatus is seldom included in the clinical assessment by manipulative therapists, but it is of great importance to diagnose within the scope of manipulation of the upper cervical spine.

It is hypothesized that congenital ossification of the stylohyoid apparatus might be associated with anomalies in the atlantic section of the vertebral artery which make the patient more susceptible to vertebrobasilar insufficiency. More observations are required to confirm this link.

Cervical spine manipulation can exacerbate existing pathological conditions of the stylohyoid apparatus, thereby irritating neurovascular structures, but can also induce a fracture. Extreme care should be taken in the presence of such an ossification in order to avoid trauma to the apparatus.

The practitioner has to be attentive in examining the routine lateral X-rays of the cervical spine in order to substantiate the clinical diagnosis of an ossified stylohyoid apparatus.

References

1. Fini G, Gasparini G, Filippini F et al. The long styloid process syndrome or Eagle's syndrome. *J Craniomaxillofac Surg* 2000; 28:123-7.
2. Omnell K, Gandhi C, Omnell M. Ossification of the human stylohyoid ligament: a longitudinal study. *Med Oral Pathol Oral Radiol Endod* 1998; 85:226-32.
3. Camarda A, Deschamps C, Forest D. I. Styloid chain ossification: A discussion of etiology. *Oral Surg Oral Med Oral Pathol* 1989; 67:508-14.
4. Camarda A, Deschamps C, Forest D. II. Styloid chain ossification: A discussion of etiology. *Oral Surg Oral Med Oral Pathol* 1989; 67:515-20.
5. Eagle W. Elongated styloid process: report of two cases. *Arch Otolaryngol* 1937; 25:584-7.
6. Messer E, Abramson A. The styloid syndrome. *J Oral Surg* 1975; 33: 664-7.
7. Monsour P, Young W. Variability of the styloid process and stylohyoid ligament in panoramic radiographs. *Oral Surg Oral Med Oral Pathol* 1986; 61:522-6.
8. Smith R, Cherry J. Traumatic Eagle's syndrome: report of a case and review of the literature. *J Oral Maxillofac Surg* 1988; 46 :606-9.
9. Steinman I. Styloid syndrome in the absence of an elongated process. *Acta Otolaryngol* 1968; 66:347-56.
10. Arnould G, Tridon P, Laxenaire M et al. Appareil stylo-hyoidien et malformations de la charnière occipito-vertébrale. A propos de cinq observations. *Rev Otonéuroophthalmol* 1969;41(4):190-5.
11. Johnson C, Scraggs M, How T et al. A necropsy and histomorphometric study of abnormalities in the course of the vertebral artery associated with ossified stylohyoid ligaments. *J Clin Pathol* 1995; 48: 637-40.
12. McCorkell S. Fractures of the styloid process and stylohyoid ligament: an uncommon injury. *J Trauma* 1985; 25:1010-2.
13. Queresby F, Gold E, Arnold J. Eagle's syndrome in an 11-year old patient. *J Oral Maxillofac Surg* 2001; 59 :94-97.
14. Guo B, Jaovisidha S, Sartoris D et al. Correlation between ossification of the stylohyoid ligament and osteophytes of the cervical spine. *J Rheumatol* 1997; 24:1575-81.
15. Bafaqeeh S. Eagle syndrome: classic and carotid artery types. *J Otolaryngol* 2000; 29:88-94.
16. Miller DB. Eagle's syndrome and the trauma patient. Significance of an elongated styloid process and/or ossified stylohyoid ligament. *Funct Ortho* 1997; 14: 30-5.
17. Shimada K, Davis W, DiDio L. The mandibulo-stylohyoid ligament. *Surg Radiol Anat* 1986; 8: 67-70.
18. Shimada K, Gasser R. Morphology of the mandibulo-stylohyoid ligament in human adults. *Anat Rec* 1988; 222: 207-210.
19. Thiel H. Gross Morphology and pathoanatomy of the vertebral arteries. *J Manipulative Physiol Ther* 1991; 14:133-41.
20. Chen C, Wang L, Wong Y. Abnormal origin of the vertebral artery from the common carotid artery. *Am J Neuroradiol* 1998; 19:1414-6.
21. Larsen W. *Human Embryology*. Churchill Livingstone, 1997.
22. Barbaix E, Kerckaert I, D'Herde et al. Simultaneous occurrence of a thyromediastinal muscle, a truncus bicaroticobrachialis, and a left superior vena cava. *Clin Anat* 2003; 16: 176-81.
23. Roszel A. Über die anomalie der arteria subclavia dextra und über die persistenz der vena cava superior sinistra. *Anat Anz* 1966; 118:348-67.
24. Van Roy P, Barbaix E, Clarijs J. Functional anatomy of the cervical spine. In: *The degenerative cervical spine*. Lippincott Williams & Wilkins. Philadelphia; 2001:3-27.
25. Assendelft W, Bouter L, Knipschild P. Complications of spinal manipulation. A comprehensive review of the literature. *J Fam Pract* 1996; 42:475-80.
26. O'Shaughnessy T, Levenson R. Basic treatment precepts pursuant to a whiplash episode. *Funct Ortho* 1994; 11:16-20.

27. Blomgren K, Varnberg Y, Valtonen H. Spontaneous fracture of an ossified stylohyoid ligament. *J Laryng Otol* 1999; 113: 854-5.
28. Babad M. Eagle's syndrome caused by traumatic fracture of a mineralised stylohyoid ligament – literature review and a case report. *J Craniomandibular Prac* 1995; 13:188-92.
29. Balasubramanian S. The ossification of the stylohyoid ligament and its relation to facial pain. *Br Dent J* 1964; 4:108-11.

CHAPTER 6

A VERTEBRAL ARTERY WITHOUT ATLANTIC AND INTRADURAL SECTIONS.

A CASE REPORT AND A REVIEW OF THE LITERATURE

Barbara Cagnie¹, Erik Barbaix², Elke Vinck¹, Katharina D'Herde², Dirk Cambier¹

¹Department of Rehabilitation Sciences and Physiotherapy, Ghent University, Belgium

²Department of Human Anatomy, Embryology, Histology and Medical Physics, Ghent University, Belgium

Annals of Anatomy, in press, February 2005

Summary

This report covers a case in which the right vertebral artery (VA) did not participate in the formation of the basilar artery. The artery had an external diameter of about 1 mm. It ran through the transverse foramina of C6 through C2, then turned backward and entered the spinal canal and the dural envelope between the posterior arch of C1 and the lamina of C2 as a medullary artery to end in the spinal arteries. The basilar artery was a continuation of the left VA only. Only very few cases of non-union of the VA with the basilar artery have been previously described. Cases with extreme reduction of one of the VAs are not exceptional. This variant is clinically important. On arteriography, this extremely rare condition could easily be misdiagnosed as an obstruction. In view of manipulative therapy and in the detection of vertebrobasilar insufficiency, one has to bear in mind that cases of non-union may influence the interpretation of these tests.

Key words: vertebral artery, non-union, vertebrobasilar insufficiency, arteriography

Historical introduction

Bertha De Vriese was the first woman to graduate as a medical doctor from the Ghent University in 1900. In 1903, she was also the first woman to be appointed as assistant at the Ghent University. The *Anatomischer Anzeiger* (1904) announced her appointment in the Department of Anatomy under the direction of Professor H. Leboucq. A home for resident students has been named after her. Her graduation thesis for the "Scientific Diploma", the later PhD, concerned the arteries at the basis of the skull. She probably was the first anatomist to perform such a study on a large scale. Publications on that topic followed in 1904 and 1905 (De Vriese 1904; De Vriese 1905). For this study she made 150 casts of injected arteries, of which the majority are still conserved in the Department of Neurology of the Ghent University Hospital (Prof. Dr. De Reuck). One of the casts shows a very rare case of non-union of the VAs. One century later we also found a case of non-union.

Case report

Out of a series of 50 cervical spines dissected to study anomalies of the VAs, one specimen presented a well-developed left VA in combination with a very small right artery. The latter had an external diameter of 1 mm at its origin from the subclavian artery. Both arteries entered the transverse foramina of C6. At the foramen magnum only the left VA emerged from the spinal canal to form the basilar artery (Fig. 1). The right VA ran through the transverse foramina of the cervical vertebrae up to and including C2. Emerging from the C2 foramen it gave off a tiny branch ascending along the dens of the axis and subsequently did not enter the transverse foramen of the atlas but continued in a dorsal direction to join the exiting C2 nerves then entered the spinal canal at this point (Fig. 2). It joined the spinal arteries in the way normally seen in segmental medullary arteries.

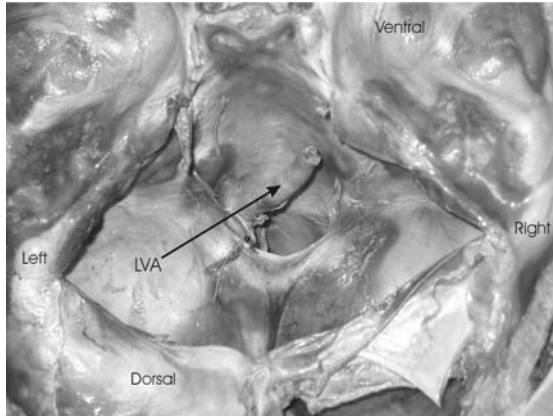


Figure 1: Intracranial view of foramen magnum without right vertebral artery.
LVA: left vertebral artery.

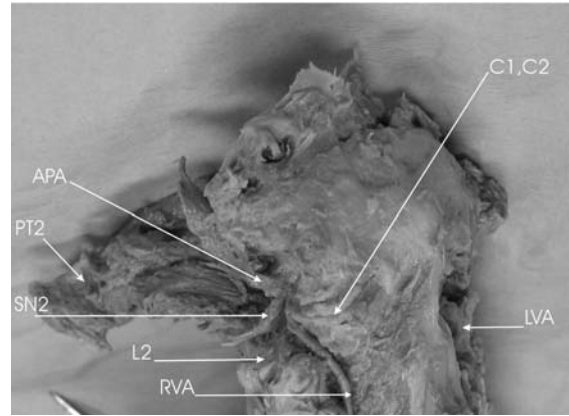


Figure 2: Atlanto-axial segment of anomalous small right vertebral artery
APA: arcus posterior of atlas; C1C2: lateral atlanto-axial joint; SN2: spinal nerve C2; L2: lamina of axis; LVA: left vertebral artery; RVA: right vertebral artery; PT2: reclined transverse process of axis

Review of the literature

Asymmetry of the VAs is common. The left VA is dominant in approximately 50%; the right in 25% and only in the remaining quarter of cases are the two VAs of similar calibre (Cloud et al. 2003). In up to 15% of the healthy population, one VA is atretic (<2 mm diameter) and makes little contribution to basilar artery flow (Cloud et al. 2003). The atretic artery can be extremely thin as was the case in 5 out of 83 specimens described by Adachi (1928) and in 5 out of 220 bodies studied by Blackburn (1907).

Cases of non-union of the VAs are very rare. In this event, the intracranial (V4) segment of one of the VAs is completely missing.

Batujeff (1889) reported a case of unilateral absence of the V4 segment of a very reduced left VA that ended at the level of the atlas. The right VA ended as the right posterior inferior cerebellar artery (PICA) but did not continue in the basilar artery. The basilar artery was formed by a branch of the left internal carotid artery penetrating the basis of the skull through the left condylar canal. According to De Vriese (1904), a similar case, but with the anomalous artery passing between the occipital bone and the atlas, was described by Duret in 1874.

De Vriese (1905) has studied the arteries of the basis of the skull in 50 adults and 100 newborns and fetuses. In one adult male the basilar artery was formed by the left VA only, the right one being absent (Fig. 3). In this case the posterior cerebral artery (PCA) on

the side of the missing VA originated from a large posterior communicating instead of the basilar artery.

Berry and Anderson (1909) reported a case of non-union of the VAs. The right VA continued intracranially as a PICA without participating in the formation of the basilar artery, which was formed by the left VA only.

In 6 out of 83 Japanese bodies examined by Adachi (1928) one of the VAs was so reduced that the basilar artery was practically formed by the larger artery only. Instead of giving off the PICA, the reduced VA ended in the PICA, which originated from the basilar artery. In one case there was no V4 segment on the left side, but the left VA ended in two terminal branches joining the spinal arteries (Fig. 4).

McMinn (1953) reported on a case of non-union in which the smaller (2.8mm) right VA did not unite with its larger (6mm) left counterpart but continued as the right PICA.

Despite the advent of vertebral arteriography as a routine procedure, only a few cases of non-union have been traced in the available literature. A persistent hypoglossal artery was found in 4 out of 1526 arteriographies reviewed by Lindgren in 1950. In all four these cases the corresponding VA was missing.

Between 1950 and 1970, 15 cases have been described in which one VA continued into the PICA, whereas the other supplied the remaining vertebrobasilar system (Radner 1951; Hauge 1954; Krayenbühl et al. 1957; Morris 1962).

Recently, 3 more cases, well documented with CT, MRI and ultrasound, were published by Strupp et al. (2000), Terenzi (2002) and Westaway et al. (2003), respectively.




Figure 3: Casting of a case of non-union by De Vriese with missing right vertebral artery and foetal origin of right posterior cerebral artery.




Figure 4: Non-union case of Adachi (1928) with foetal origin of both posterior cerebral arteries and right vertebral artery ending in the spinal arteries.

Embryology

A brief review of the embryogenesis of the cerebral circulation may be helpful to understand the anomalies generally associated with a non-union. In the early gestational period, the carotid system supplies the forebrain and contributes to the perfusion of the hindbrain via the trigeminal, hypoglossal and other primitive segmental arteries (Chaturvedi et al. 1999). At this early stage a posterior system develops from a pair of plexiform longitudinal arteries, the later VAs. The internal carotid artery forms an intracranial connection with the rostral end of the longitudinal neural arteries: the posterior communicating artery. The posterior cerebral artery (PCA) develops at the caudal end of the posterior communicating artery. At \pm 5 weeks gestation, the involution of the trigeminal, hypoglossal and other primitive arteries starts, and the longitudinal neural arteries fuse to form the basilar artery. If the fusion is incomplete, septation, reduplication, or fenestration of the basilar artery can occur. The developing posterior basilar system becomes the main supplier of blood to the developing PCA's, and as a consequence, the posterior communicating arteries become smaller. Occasionally they remain large, and a "foetal origin" of the PCA's persists. In exceptional instances the trigeminal or hypoglossal artery persists. In these events the VA often is hypoplastic or missing.

In the above-mentioned case descriptions, the missing V4 segment was always situated on the side of the smaller VA. A persistent hypoglossal artery was present in the cases described by Batujeff (1889) and Lindgren (1950). A foetal origin of the PCA on the side of the missing segment was obvious in the cases of De Vriese (1905b) and in the non-union as well as in 4 out of the 5 remaining cases of extreme reduction of the VA presented by Adachi (1928). An abnormal origin of the PICA was found in all the cases, with the PICA either as the terminal branch of the VA or originating from the basilar artery. Through its mode of ending in the spinal arteries, our case most closely resembles Adachi's case.

Clinical implications

Including the present case, we found only 29 cases of non-union in the literature. So it seems that the condition is exceptional. The higher incidence of non-unions in

arteriographies reviewed by Lindgren (1950) suggests that in a symptomatic population the condition might be more frequent, on the order of 0.25%.

A first important aspect of this condition is its recognition as a developmental anomaly. The absence of the V4 segment of one VA on arteriographies will probably lead to an initial interpretation as an occlusion. Based on the above-mentioned case descriptions, the observation of some other anomalies can help differentiate between a non-union and an occlusion. A missing V4 segment on the side of the smaller artery can be either a non-union or an occlusion. On the side of the larger artery it almost certainly is not a non-union but an occlusion. This point should be kept in mind with the following observations.

A **non-union** is highly probable in conjunction with the following findings: (1) a “foetal” origin of the PCA on the side of the missing segment; (2) the continuation of the smaller VA as a PICA, with a missing segment between PICA and basilar artery; (3) a PICA originating from the basilar artery on the side of the missing segment; (4) the complete absence of the segment between atlas and basilar artery, no blunt endings; (5) a very small VA (<1 mm) ending into the spinal arteries; (6) persistence of a trigeminal or hypoglossal artery.

An **occlusion** is the more probable hypothesis in conjunction with the following findings: (1) the missing segment is on the side of the larger VA; (2) the existence of blunt endings, especially a retrograde filling blunt ending from the “normal” confluence of the VAs at the beginning of the basilar artery; (3) only the segment between atlas and PICA is missing and the latter originates from a retrograde filling segment coming from the basilar.

A second aspect concerns the interpretation of testing of vertebrobasilar insufficiency (VBI). An impaired blood flow through the VAs can result in VBI, which is an absolute contra-indication to manipulation and by far the most frequent serious adverse reaction after manipulation of the cervical spine. (Ernst 2002)

In an attempt to identify individuals at risk, screening tests are frequently performed prior to manipulation (Rivett et al. 1999). These protocols include provocation tests performed in different positions of neck extension combined with rotation and are based on the premise that these neck positions ascertain arterial compensation through the contralateral artery during temporary occlusion of the other VA.

However, it is worth considering the predictive value of pre-manipulative testing in relation to various arterial pathologies (Magarey et al. 2004). VA compression and insufficiency is

usually asymptomatic as long as adequate compensation is achieved by a competent contralateral VA. When one VA is narrow, it may not be able to compensate for the positional occlusion of the larger one. On the other hand, positional occlusion of the small vessel may have so little influence on the blood supply to the brain stem and cerebellum that it is easily compensated by the larger one. In this case only the rotation towards the narrow side may induce symptoms like dizziness and nystagmus. Support for this is found in the literature. Husni and Storer (1967) studied 23 patients in whom symptoms of vertebrobasilar insufficiency were induced by rotational occlusion of one VA. In 22 of these patients, the opposite VA was hypoplastic and narrowed at its origin in one. Bladin and Merory (1975) also demonstrated occlusion of the only functional VA with contralateral head rotation in one subject, which resulted in vertigo and nystagmus. More recently, Strupp et al. (2000) described a patient with a left VA terminating in the PICA, resulting in vertebrobasilar insufficiency.

On the other hand, 2 patients tested negative on bilateral extension/rotation pre-manipulative screening positions despite an atretic and hypoplastic VA (Rivett et al. 1998; Terenzi 2002). This can be explained by the fact that in congenital hypoplasia or non-union, the ipsilateral PICA is often separately supplied by the smaller VA or by an aberrant hypoglossal artery, which is not affected by rotations of the head. In addition the posterior cerebral artery mostly has a foetal origin from the carotid system and the frequently enlarged posterior communicating arteries allow for more compensation between carotid and vertebral systems instead of the usual left-right compensation. As a result, positional testing may not provoke symptoms.

Conclusions

A case of non-union of the VAs is described. Only very few cases of non-union of the VA with the basilar artery have been previously published. The importance of this condition from clinical points of view is discussed. On arteriography, this extremely rare condition could easily be misdiagnosed as an occlusion. In pre-manipulative testing and in the detection of vertebrobasilar insufficiency, one has to bear in mind that cases of non-union may influence the interpretation of these tests.

References

- Adachi B (1928) Das Arteriensystem der Japaner. Bd I. Maruzen, Kyoto, pp. 119-137
- Anonymous (1904) Personalia, *Anat Anz*; 24(14): 384
- Batujeff N (1889) Eine seltene Arterienanomalie. *Anatomischer Anzeiger* 4: 282-285
- Berry R, Anderson J (1909) A case of non-union of the vertebrales with consequent abnormal origin of the basilaris. *Anatomischer Anzeiger* 35: 54-65
- Blackburn J (1907) Anomalies of the encephalic arteries among the Insane. *J Comp Neurol Psychol* 17: 493-517
- Bladin P, Merory J (1975) Mechanisms in cerebral lesions in trauma to high cervical portion of the vertebral artery-rotation injury. *Proc Aust Assoc Neurol* 12: 35-41
- Chaturvedi S, Lukovits T, Chen W, Gorelick P (1999) Ischemia in the territory of a hypoplastic vertebrobasilar system. *Neurology* 52: 980-983
- Cloud G, Markus H (2003) Diagnosis and management of vertebral artery stenosis. *Q J Med* 96: 27-34
- De Vriese B (1904) Sur les artères de la base du cerveau. *Verhandlungen der Anatomischen Gesellschaft. Jena*, p 88 - 99
- De Vriese B (1905) Sur la signification morphologique des artères cérébrales. *Archives de Biologie* 21: 357-458
- Ernst E (2002) Manipulation of the cervical spine: a systematic review of case reports of serious adverse events, 1995-2001. *Med J Aust* 176: 376-380
- Hauge T (1954) Catheter vertebral angiography. *Acta Radiol; suppl.* 109
- Husni E, Storer J (1967) The syndrome of mechanical occlusion of the vertebral artery: further observations. *Angiology* 18: 106-116
- Krayenbühl H, Yasargil M (1957) Die vaskulären Erkrankungen im Gebiet der Arteria vertebralis and Arteria basilaris. Thieme, Stuttgart
- Lindgren E (1950) Percutaneous angiography of the vertebral artery. *Acta Radiol*; 33: 389-404.
- Magarey M, Rebeck T, Coughlan B, Grimmer K, Rivett D, Refshauge K (2004) Pre-manipulative testing of the cervical spine review, revision and new clinical guidelines. *Manual Ther* 9:95-108
- McMin R (1953) A case of non-union of the vertebral arteries. *Anat Rec* 116: 283
- Morris L (1962) Case reports. Non-union of the vertebral arteries. *Br J Radiol*; 35: 496-498.
- Radner S (1951) Vertebral angiography by catheterisation. *Acta Radiol; suppl.* 87
- Rivett D., Milburn P, Chapple C (1998) Negative pre-manipulative vertebral artery testing despite complete occlusion: a case report of false negativity? *Manual Therapy* 3(2): 102-107
- Rivett D, Sharples K, Milburn P (1999) Effect of premanipulative tests on vertebral artery and internal carotid artery blood flow: A pilot study. *J Manipulative Physiol Ther*; 22: 368-375
- Strupp M, Planck J, Arbusow V, Steiger H, Bruckmann H, Brandt T (2000) Rotational vertebral artery occlusion syndrome with vertigo due to 'labyrinthine excitation'. *Neurology* 54:1376-1379
- Terenzi T (2002) Transcranial sonography and vertebrobasilar insufficiency. *J Manipulative Physiol Ther* 25:180-183
- Westaway M, Stratford P, Symons B (2003) False-negative extension/rotation pre-manipulative screening test on a patient with an atretic and hypoplastic vertebral artery. *Manual Therapy*; 8 (2):120-127

**PART III: FUNCTIONAL APPROACH OF THE
VERTEBRAL ARTERY**

CHAPTER 7

CHANGES IN CEREBELLAR BLOOD FLOW AFTER MANIPULATION OF THE CERVICAL SPINE USING TECHNETIUM 99m-ETHYL CYSTEINATE DIMER

Barbara Cagnie¹, Filip Jacobs², Erik Barbaix³, Elke Vinck¹, Rudi Dierckx², Dirk Cambier¹

¹ Department of Rehabilitation Sciences and Physiotherapy, Ghent University, Belgium

² Division of Nuclear Medicine, Ghent University Hospital, Belgium

³ Department of Human Anatomy, Embryology, Histology and Medical Physics, Ghent University, Belgium

Journal of Manipulative and Physiological Therapeutics 2005; 28: 103-107

Abstract

Background: Cervical spine manipulation is one of the many interventions practiced by health professionals to treat musculoskeletal disorders of the cervical spine. Although serious consequences of manipulation have been documented, the incidence is thought to be rare. More frequently, there may be minor transient side effects after manipulation of the cervical spine, such as headache, dizziness, and nausea. One of the hypothesis is that these side effects are caused by ischemia in the areas perfused by the vertebral arteries.

Objective: The purpose of this study was to investigate whether manipulation of the cervical spine can influence blood flow in the brain.

Methods: Single photon emission computed tomography was used to examine changes in regional cerebral blood flow caused by cervical spine manipulation (CSM) performed by a physiotherapist to 15 volunteers, using a 1-day split-dose Technetium 99m–ethyl cysteinate dimer single photon emission computed tomography activation paradigm.

Results: One brain region was identified showing a decreased regional cerebral blood flow after manipulation. This region was situated in the anterior lobe of the left cerebellum (−42, −48, −24).

Conclusions: These findings suggest that cerebellar hypoperfusion may occur after CSM. This could explain why certain people experience headache, dizziness, or nausea after CSM. Further investigation into patient symptoms in the presence of cerebellar hypoperfusion and the possible link of these findings with other adverse reactions are warranted.

Key Indexing Terms: Manipulation; Neck; Regional blood flow; Tomography; Emission-computed; Single-photon; Hypoperfusion

Introduction

Cervical spine manipulation (CSM) is an intervention commonly used by chiropractors, physiotherapists, and other health professionals to treat mechanical neck pain and cervicogenic headache. The acceptance of this kind of treatment has yielded a growing necessity to evaluate not only the effectiveness of the manipulation, but also its potential side effects and complications, the most serious of which is considered to be cerebrovascular accidents. Such serious consequences of CSM have been documented, but the incidence is thought to be rare.¹⁻⁶ The actual frequency remains unknown as reports in the literature vary between 1 in 5000 to 1 in 10 million manipulations.³⁻⁶ Notwithstanding small risk, the serious, irreversible, and possibly lethal nature of vascular accidents makes this a hazard, thus worth investigating.

Minor transient side effects after manipulation of the cervical spine are more frequent.⁷ Prospective investigations into the safety of spinal manipulation suggest that, in general, approximately 50% of all patients will experience side effects after manipulation, such as local discomfort, headache, tiredness, and radiating discomfort.⁸⁻¹¹ Dizziness (4.28%) and nausea (2.72%) are less common, but are significantly more present after cervical manipulation than after lumbar or thoracic treatment.¹⁰ Most of these reactions begin within 4 hours and generally disappear within the next 24 hours. The application of a mechanical force to a painful area of the spine in CSM easily explains subsequent local or radiating discomfort. However, it is more difficult to explain why people present symptoms such as headache and dizziness.

One of the hypotheses is that these consequences of CSM are caused by ischemia in the areas perfused by the vertebral arteries.⁷ In an attempt to identify individuals at risk, a protocol of physical screening tests is frequently performed before manipulation. These protocols include provocation tests performed in different positions of neck extension combined with rotation and are based on the premise that these neck positions reduce the vertebral artery blood flow to the hindbrain, provoking symptoms or signs of vertebrobasilar insufficiency.¹² The effect of cervical movement on vertebral artery blood flow has been investigated in vivo using Doppler ultrasound. However, the findings of

these studies are conflicting, leading to question the validity and positive predictive value of these screening tests.¹³

The aim of this study is to investigate cerebrovascular hemodynamic consequences of CSM to the upper cervical spine using a 1-day split-dose technetium Tc 99m–ethyl cysteinate dimer (99mTc-ECD) single photon emission computed tomography (SPECT) activation paradigm.^{14,15} The use of a 1-day split-dose paradigm enables us to acquire an image before and after CSM in 1 day. The applied tracer is captured by brain cells proportional to the regional cerebral blood flow (rCBF) within a 3-minute time frame. By injecting the tracer directly before CSM, one can assess local brain perfusion directly after CSM. Single photon emission computed tomography provides 3-dimensional images representing the spatial distribution of the injected tracer. The advantage of this paradigm is that it allows CSM to be performed on a regular examination table outside the nuclear medicine facility, which is not possible with positron emission tomography or functional magnetic resonance imaging (MRI) where the patient must stay positioned in the camera with the head fixed to allow simultaneous image acquisition.¹⁶

Materials and methods

Subjects

Fifteen volunteers participated in this study. The subjects' ages ranged from 21 to 48 years (mean, 26.5 years). None of the participants had a history of major medical or neuropsychiatric diseases and none of them took any medication with the exception of oral contraceptives. The study was approved by the local Ethics Committee of the Ghent University Hospital. Written informed consent was obtained from all the volunteers before the study after the nature of the procedures had been fully explained.

SPECT study

A peripheral infusion catheter was placed in the antecubital vein. Two SPECT studies were performed: a baseline and an activation study. For the baseline SPECT, each study participant first rested for 10 minutes in supine position in a quiet room with lights dimmed and eyes closed because rCBF is influenced by neuronal activity. After injecting 15

mCi ^{99m}Tc -ECD, the patient remained in the same position for another 10 minutes. The peak brain activity is reached within 2 to 3 minutes after injection and remains unchanged up to at least 2 hours, independent of rCBF variations occurring after the fixation time. This property of quick uptake and prolonged stability allows for so-called frozen images, reflecting the rCBF distribution at the time of injection, independent of the timing of SPECT acquisition. Data acquisition was started 30 minutes after injection. This time frame was chosen because the tracer consists of different isomers, of which only one is fixed by the brain. If there is a time delay of 30 minutes between injection and scanning, there will be less background activation and clearer images.

Data were acquired for 20 minutes with a Toshiba triple-head GCA9300A/hg gamma camera equipped with ultrahigh-resolution fan-beam collimators. To avoid movement artifacts, the head was fixed using Velcro straps.

Approximately 1 hour after the first injection, the activation SPECT was performed. The subject was asked to rest for another 10 minutes in the same quiet room with lights dimmed and eyes closed. Subsequently, cervical manipulation at the level of the C1 through C2 vertebrae was performed by a manual therapist with 25 years of experience. The patient was in a supine position. The manipulation was a high-velocity, low-amplitude thrust technique. The therapist used a chin hold grip with one hand and the other hand made contact with the C1 vertebra. The head was slightly rotated to the right and laterally flexed to the opposite side, combined with an upper cervical dorsal flexion and a slight compression force. The impulse was directed toward the right shoulder. When the manual therapist had positioned the patient to perform the manipulation, he signed the nurse to inject a second bolus of 15 mCi ^{99m}Tc -ECD. Immediately after the injection the manipulation was completed and the patient remained for 10 minutes in the room. The second image acquisition was started 30 minutes after the second injection.

Image acquisition and analysis

Fan-beam data were rebinned into parallel data. Images were reconstructed using filtered backprojection and Sorensen uniform attenuation correction. Reconstructed images were transformed into ANALYZE format with an in-house conversion program (xMedCon). The baseline and activation study of each subject were coregistered and the mean image of the coregistered images was calculated using the Statistical Parametric Mapping software package (SPM99, Wellcome Department of Imaging Neuroscience, UCL, London). This

resulted in 2 coregistered images and 1 mean image for each subject. SPM99 was also used to spatially normalize the mean images into MNI space (Montreal Neurological Institute, McGill University, Montreal, Quebec, Canada). Moderate warping with 5 iterations and $4 \times 5 \times 4$ basis functions was allowed to take intersubject variability into account. The same parameter values were applied to the corresponding coregistered images. Spatially normalized images were smoothed with a 18-mm Gaussian kernel. The final images had a 3-mm voxel size.

After spatial preprocessing, the 15 paired images were used to detect regions showing an increased or decreased brain perfusion after CSM. First, a paired t test was applied for each voxel to detect those voxels showing a significantly increased or decreased perfusion at a .001 level. Subsequently, we looked for regions of at least 3 mL composed of voxels showing an increased or decreased perfusion. No corrections for multiple comparisons were applied because of the existence of an a priori hypothesis.

Results

A comparison of the rCBF before and after manipulation revealed an area of hypoperfusion in the anterior lobe of the left cerebellum, as shown in figure 1. The voxel with Talairach coordinates $(-42, -48, -24)$ showed a P value of .001, which indicated significant hypoperfusion. The observed hypoperfusion was situated on the opposite side of the manipulation. No clusters were identified showing significantly increased perfusion.

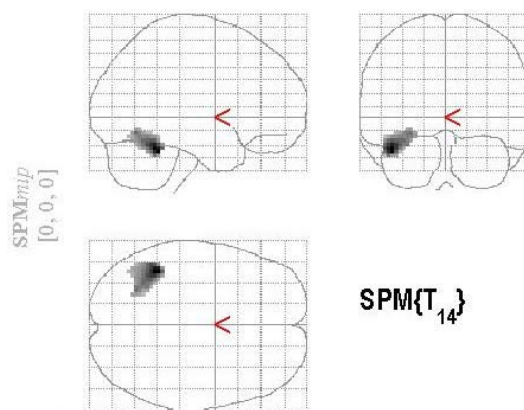


Figure 1: Reduced perfusion of the left anterior lobe of the cerebellum after cervical spine manipulation (with peak coordinates in the Talairach atlas: $-42, -48, -24$).

Discussion

This study shows that CSM to the upper cervical spine may affect the blood flow to the cerebellum. To the best of our knowledge, no other studies have ever shown these findings. Although it is difficult to test the results against the literature, this reduced perfusion may suggest potential mechanisms of the symptoms patients experience after manipulation of the cervical spine.

Before discussing the results, it is essential to view this study's results within the limitations of the study. One has to bear in mind that all patients underwent the same type of manipulation at the same level (C1 through C2 vertebrae), performed by the same manual therapist. Changes in these factors may give rise to other results. In this study, a lateral manipulation technique was used, as it was considered unethical to use the rotational technique, in view of the knowledge that this technique may be associated with the highest frequency of adverse responses.¹⁷

Secondly, we have no idea if patients experienced side effects due directly to the manipulation. Registration of these side effects would be inappropriate because other variables may have influenced these potential symptoms, such as the placing of a peripheral infusion catheter, the environment, and the scanning time and room. For example, one patient fainted during the placing of a peripheral infusion catheter and complained of lightheadedness after the study: either the placing of the catheter or the manipulation itself could have caused this.

One of the disadvantages of SPECT, in contrast to MRI, is that it cannot make statistical statements in comparing different conditions within an individual in a single session. Single photon emission computed tomography scans usually rely on making statistical statements about group differences between 2 conditions. In theory, one could subtract both images obtained for each patient and the subtraction image might show regions with a hypo- or hyperperfusion. However, we could not draw any conclusions without additional information or additional scans because we need more than 2 images per subject to perform any subject-specific statistical test. In nuclear medicine, ictal and interictal images are used to detect epileptic foci, but the subtraction image is used together with additional

information, including magnetic resonance images, electroencephalogram, clinical examination, and so on. Because SPECT gives a relative quantification and no absolute quantification, we cannot distinguish between mild or moderate perfusion changes. The advantage of this paradigm is that it allows CSM to be performed on a regular examination table outside the nuclear medicine facility, which is not possible with positron emission tomography or functional MRI where the patient must stay positioned in the camera with the head fixed to allow simultaneous image acquisition.

Little literature is available concerning the manner in which CSM may affect the cerebral blood flow.¹⁸⁻²⁰ Transient arterial spasm may be an acceptable explanation.²¹ Neck rotation may cause the artery to be momentarily compressed or stretched, which may result in spasm, without vertebral artery damage. This may persist for only a short period and produce only temporary symptoms.²¹ Spasm becomes particularly deleterious in the presence of contralateral hypoplasia of the vertebral artery, or if the contralateral vertebral artery terminates in the posterior inferior cerebellar artery. Moreover, if the spasm persists and the blood supply to the irrigated parts reduces or stagnates, such spasm, if sufficiently severe and prolonged, can result in fatal infarction.²¹

Only 3 other studies have investigated the cerebral blood flow before and after CSM. In contrast with our results, a significant increase of blood flow appeared in both vertebral arteries after 20 to 40 seconds, after which it returned to baseline values in less than 3 minutes.¹⁸⁻²⁰

The underlying mechanism why hypoperfusion occurred in the anterior lobe of the left cerebellum is questioned. The cerebellum is usually supplied by 3 paired arteries: the posterior inferior cerebellar artery, the anterior inferior cerebellar artery and the superior cerebellar artery. The posterior inferior cerebellar artery commonly arises from the vertebral artery (85%), whereas the two others most often originate from the basilar artery.²² The site of hypoperfusion in this study corresponds with the territory of the superior cerebellar artery. The superior cerebellar artery arises just caudal to the bifurcation of the basilar artery and supplies the superior surface of the cerebellum and much of the caudal midbrain and rostral pons. Hypoperfusion in this area may result in specific symptoms such as headache and dizziness. Terao et al²³ evaluated 10 patients with infarction in the anterior rostral cerebellum. Subjective symptoms at onset consisted of

nausea and vomiting in 3 patients, dizziness in 8, tinnitus in 1, and headache in 3. Marinkovic et al reported on 4 patients with an infarct in the superior cerebellar artery territory. The main symptoms and signs in all 4 patients were headache, nausea, and dizziness.²⁴ Although hypoperfusion is obviously not similar to an infarction, the subjective findings corresponding to this territory are comparable with the symptoms some patients experience after manipulation of the cervical spine.⁸⁻¹¹ This may be due to the anterior lobe of the cerebellum being closely connected to the vestibular nuclei, in which involvement of these nuclei may result in nystagmus, vertigo, nausea, and vomiting.²¹

In this study, the observed hypoperfusion was situated on the opposite side of the manipulation. Reasons for this are speculative, but a review of the work by Mann and Refshauge²⁵, and more recent studies, showed that most Doppler studies reported a diminished blood flow in the artery contralateral to the side of rotation.^{26,27} This was also found in our study, where the head was in right rotation during the manipulation maneuver, whereas the hypoperfusion occurred in the left cerebellum. This may explain the unilaterality of the hypoperfusion. Moreover, several case studies revealed an infarction in the territory of the superior cerebellar artery in combination with a stenosis of the vertebral artery at the C2 level at the same side.^{24,28}

Conclusion

In summary, these findings suggest that cerebellar hypoperfusion may occur after the type of cervical manipulation that was used in this study. This could explain why certain people experience headache, dizziness, or nausea after CSM. Further investigation into patient symptoms in the presence of cerebellar hypoperfusion and the possible link of these findings with other adverse reactions are warranted.

Acknowledgements

The authors thank Mr Axel Beernaert for performing the spinal manipulations for this study.

References

1. Coulter I. Efficacy and risks of chiropractic manipulation: what does the evidence suggest? *Integrative Medicine* 1998; 1: 61-66.
2. Vautraver P, Maigne JY. Cervical spine manipulation and the precautionary principle. *Joint Bone Spine* 2000; 67: 272-276.
3. Assendelft WJ, Bouter LM, Knipschild PG. Complications of spinal manipulation: a comprehensive review of the literature. *J Fam Pract* 1996; 42: 475-480.
4. Hufnagel A, Hammers A, Schönle P, Böhm K, Leonhardt G. Stroke following chiropractic manipulation of the cervical spine. *J Neurol* 1999; 246: 683-688.
5. Ernst E. Manipulation of the cervical spine: a systematic review of case reports of serious adverse events, 1995-2001. *Med J Aust* 2002; 176: 376-380.
6. Di Fabio RP. Manipulation of the cervical spine: risks and benefits. *Phys Ther* 1999; 79: 50-65.
7. Refshauge KM. Rotation: a valid premanipulative dizziness test? Does it predict safe manipulation? *J Manipulative Physiol Ther* 1994; 17: 15-19.
8. Ernst E. Prospective investigations into the safety of spinal manipulation. *J Pain Symptom Manage* 2001; 21: 238-242.
9. Leboeuf-Yde C, Hennius B, Rudberg E, Leufvenmark P, Thunman M. Side effects of chiropractic treatment: a prospective study. *J Manipulative Physiol Ther* 1997; 20: 511-515.
10. Cagnie B, Vinck E, Beernaert A, Cambier D. How common are side effects of spinal manipulation and can these side effects be predicted? *Manual Ther* 2004; 9(3): 151-156.
11. Senstad O, Leboeuf-Yde C, Borchgrevink C. Frequency and characteristics of side effects of spinal manipulative therapy. *Spine* 1997; 22: 435-441.
12. Rivett D, Sharples K, Milburn P. Effect of premanipulative tests on vertebral artery and internal carotid artery blood flow: A pilot study. *J Manipulative Physiol Ther* 1999; 22: 368-379.
13. Magarey M, Rebbeck T, Coughlan B, Grimmer K, Rivett D, Refshauge K. Pre-manipulative testing of the cervical spine review, revision and new clinical guidelines. *Manual Ther* 2004; 9:95-108
14. Catafau A. Brain SPECT in clinical practice. Part I: perfusion. *J Nucl Med* 2001; 42: 259-271.
15. Van Laere K, Dierckx R. Clinical nuclear imaging of the brain. *Tijdschrift voor Geneeskunde* 2001; 57: 5-16.
16. Van Laere K, Dumont F, Koole M, Dierckx R. Non-invasive methods for absolute cerebral blood flow measurement using ^{99m}Tc-ECD: a study in healthy volunteers. *Eur J Nucl Med* 2001; 28: 862-872.
17. Klougart N, Leboeuf-Yde C, Rasmussen LR. Safety in chiropractic practice. Part I: the occurrence of cerebrovascular accidents after manipulation to the neck in Denmark from 1978-1988. *J Manipulative Physiol Ther* 1996; 19: 371-377.
18. Licht P, Christensen H, Hojgaard P, Marving J. Vertebral artery flow and spinal manipulation: a randomized, controlled and observer-blinded study. *J Manipulative Physiol Ther* 1998; 21: 141-144.
19. Licht P, Christensen H, Svendsen P, Hoilund Carlsen P. Vertebral artery flow and cervical manipulation: an experimental study. *J Manipulative Physiol Ther* 1999; 22: 431-435.
20. Licht P, Christensen H, Hoilund-Carlsen P. Vertebral artery volume flow in human beings. *J Manipulative Physiol Ther* 1999; 22: 363-367.
21. Terrett A. Current concepts in vertebrobasilar complications following spinal manipulation. West Des Moines, IA: NCMIC Group Inc, 2001. p.36.
22. Adachi B. Das Arteriensystem der Japaner. Bd I. Maruzen, Kyoto, 1928. p. 119-137.
23. Terao S, Sobue G, Izumi M, Miura N, Takeda A, Mitsuma T. Infarction of superior cerebellar artery presenting as cerebellar symptoms. *Stroke* 1996; 27: 1679-1681.
24. Marinkovic S, Kovacevic M, Gibo H, Milisavljevic M, Bumbasirevic L. The anatomical basis for the cerebellar infarcts. *Surg Neurol* 1995; 44: 450-461.
25. Mann T, Refshauge K. Causes of complications from cervical spine manipulation. *Austr J Phys* 2001; 47: 255-266.

26. Mitchell J. Changes in vertebral artery blood flow following normal rotation of the cervical spine. *J Manipulative Physiol Ther* 2003; 26: 347-351.
27. Arnold C, Bourassa R, Langer T, Stoneham G. Doppler studies evaluating the effect of a physical therapy screening protocol on vertebral artery blood flow. *Manual Ther* 2004; 9: 13-21.
28. Bonkowsky V, Steinbach S, Arnold W. Vertigo and cranial nerve palsy caused by different forms of spontaneous dissections of internal and vertebral arteries. *Eur Arch Otorhinolaryngol* 2002; 259: 365-368.

GENERAL DISCUSSION

*While we support safety in practice with cervical manipulation,
the debate must be balanced and not alarmist.*

(Jull in response to Refshauge)

SUMMARY AND CLINICAL IMPLICATIONS

The overall objective of this thesis is to contribute to a better understanding of the anatomical and functional role of the vertebral artery in the occurrence of side and adverse effects after spinal manipulation and to advance the current knowledge on this topic.

Part I: Occurrence of side and adverse effects after spinal manipulation

Aim 1 of this thesis was to determine the characteristics of side and adverse effects after spinal manipulation and to identify potential risk factors. Although it is not always obvious, it is essential to make an appropriate distinction between side and adverse effects. Side effects can be described as ‘a consequence other than the one for which an agent, medium or therapy is used’, whereas adverse effects or complications can be defined as ‘a change in body function or the structures of cells due to an agent, medium or therapy that can lead to disease, health problems or even death’.³³

According to the literature review (*chapter 1*), the incidence of serious complications is generally considered to be low. Apparently they are more frequently linked to manipulation of the cervical spine than to other spinal manipulations. The published cases are probably only the ‘tip of the iceberg’, resulting in a wide variation of estimations on the rate of complications. Notwithstanding this reflection, it is obviously proven by these published cases that of all injuries after cervical manipulation, the majority (82%) can be classified as vertebrobasilar insufficiency.

With respect to transient side effects after manipulation, the results of the prospective observational survey (*chapter 2*) indicate that more than sixty percent of all patients will experience this kind of effects. The most commonly noted unwished consequences are headache, stiffness, local discomfort, radiating discomfort and fatigue. Reports of dizziness and nausea are uncommon. These side effects tend to appear within 4 hours and generally disappear within the next 24 hours. Women are more likely to report side effects than men. Also the location of treatment determines whether side effects will occur: headache,

dizziness and nausea are significantly more apparent after cervical manipulation than lumbar and thoracic treatment. Multivariate analysis revealed that upper cervical manipulation, use of medication, gender and age are independent predictors of headache after spinal manipulation.

Although side effects cannot be labelled as major risks, informing patients about possible minor reactions after spinal manipulation in order to prevent a potential feeling of concern is a professional obligation and an obvious right of the patient. This is even more important as these reactions mainly occur after the patient has left the practice room. Therefore, patients should be informed about the fact that minor reactions frequently occur, that they are mild to moderate, but in se harmless as they in general completely disappear within the next 24 hours.

Depending on their type and severity Dvorak et al. further subdivide side effects as 'adequate reactions' (i.e. subjective discomfort that does not influence the working ability with spontaneous remission completed, at the latest, 2 days after the manipulation) and 'exceeding reactions' (i.e. an objective worsening of the pre-existing state, with decreased work capacity, and spontaneous remission exceeding 2 days).⁸ It is important to differentiate between both types of side effects because the latter may indicate a need to reconsider diagnosis or therapy. According to Vautravers and Maigne (2000) cervical manipulations should be contra-indicated for patients who experience dizziness, nausea or acute headache persisting for more than two days unless these reactions can be attributed with certainty to an unrelated benign disorder such as Benign Paroxysmal Positional Vertigo (BPPV) or cervical dizziness/headache.³¹ The patient should be asked about these reactions at the next visit and should be advised to contact the practitioner earlier in case of concern.

Adverse effects as well as side effects seem to be more apparent after cervical manipulation. Therapists should recognise the potential danger of manipulating the cervical spine and it is therefore recommended to have some closer attention to this location of manipulation.

Part II: Anatomical approach of the vertebral artery

In view of the occurrence of side and adverse effects after cervical manipulation, the potential role of the vertebral artery may be crucial. Therefore, the second aim of this thesis was to gain a better insight into the anatomical factors, which may influence the course and patency of the vertebral artery. Congenital anomalies as well as intrinsic and extrinsic factors impeding the arterial blood flow were investigated in view of these adverse effects.

In an attempt to identify extrinsic risk factors, the presence of osteophytes and their influence on the course of the vertebral artery were studied in 111 dry cervical vertebrae (*chapter 3*). Osteophytes from the uncinat process of C5 and C6 were found in over 60% of dry vertebrae. Roughly half of these osteophytes partially covered the underlying transverse foramen from an anteromedial direction. Covering of the foramen by osteophytes from the zygapophyseal joints was less frequent and protruded from a dorsal direction.

As most of the research is focused on the V3 segment, the purpose of this study was to investigate the presence of osteophytes in the V2 segment. The observations suggest that other segments also might be involved in the occurrence of complications. The presence of osteophytes and their influence on the vertebral artery is of clinical importance as they force the vertebral arteries to meander around these obstructions, causing narrowing through external compression. In addition, they can traumatize the vessel during extreme movements of the cervical spine, such as manipulation, especially when arteriosclerotic plaques are situated at the same level.

Also degenerative changes in the disc may play a role in the development of a tortuous course in the vertebral artery. During the human lifespan, the intervertebral disc is exposed to many continuously recurring loads, which result in almost consequential changes in the morphological conditions. Changes in the intervertebral discs resulting in a decrease in the height of the disc may affect the course of the vertebral artery.²⁵ As the vertebral artery is fixed at the foramen of the transverse process, disc space narrowing may induce a relative elongation of the vertebral artery resulting in the development of loop formation. Secondly, a decrease in height results in loosening of the segment of motion and in unphysiological loading of the minor joints of the vertebral column, which may contribute to the

degenerative changes in the zygapophyseal joints.²⁷ As studied in chapter 3, compression by osteophytes may distort the vertebral artery laterally.

As a consequence, screening protocols should not only be restricted to the upper cervical spine, but should be performed before any cervical manipulation. Not only rotational occlusion should be considered, but stretching over uncinat osteophytes could also occur during side bending. Checking the permeability and compensatory ability of the vertebral arteries should not be done only in rotation positions, but also in the specific position from which the manipulation will be performed.

In *chapter 4*, the sites and frequency of atherosclerotic plaques as intrinsic risk factors for complications were related to the tortuous course of the vertebral artery. The vertebral arteries of 57 human cadavers were investigated. In 22.8% of the cases, no atherosclerotic plaques were present. In 35.1%, the atherosclerotic plaques were unilateral, of which 60.0% on the left side and 40.0% on the right side, and in 42.1% of the cases the occurrence was bilateral. In the V1 and V2 segment, there was a correlation between a tortuous course of the vessel and the occurrence of atherosclerotic plaques. The presence of atherosclerotic plaques and their influence on the vertebral artery is of clinical importance as they produce intrinsic narrowing of the vertebral artery. Manipulation may stimulate the development of atherosclerotic plaques, could detach an embolus with ensuing infarction, may injure the endothelium or may directly cause a dissection in the presence of atherosclerotic plaques.^{15,23}

In *chapter 5* and *6*, two case studies are reported considering anatomical variants, which are of clinical importance for the manipulative practitioner. *Chapter 5* described a simultaneous occurrence of complete developmental ossification of the left hyoid apparatus and variants of the vertebral artery in a 56-year-old male cadaver. The vertebral artery had a noticeably abnormal course at the atlanto-axial level, where the left vertebral loop was totally absent. The diameter of the left vertebral artery was much smaller than the right vertebral artery. Pathology of the hyoid apparatus is seldom included in the clinical assessment by manipulative therapists, but it is of great importance to diagnose within the scope of manipulation of the upper cervical spine. It is hypothesized that congenital ossification of the stylohyoid apparatus might be associated with anomalies in the atlantic section of the vertebral artery, resulting in disturbances of blood flow. Secondly, cervical spine

manipulation can exacerbate existing pathological conditions of the stylohyoid apparatus, thereby irritating neurovascular structures. In extreme cases, manipulation can also induce a fracture.

Chapter 6 covered a case in which the right vertebral artery did not participate in the formation of the basilar artery. The basilar artery was a continuation of the left vertebral artery only. In this event, the intracranial (V4) segment of one of the vertebral arteries is completely missing and does not contribute to the blood supply to the brain. Cases of non-union of the vertebral arteries are very rare. Including the present case, we found only 29 cases of non-union in the literature. However, the occurrence of non-union may be underestimated because on angiography, it could easily be misdiagnosed as an occlusion.

These congenital anomalies as well as the other anatomical factors (i.e. osteophytes and atherosclerotic plaques) may influence the interpretation of pre-manipulative testing and may have some clinical consequences during manipulation of the cervical spine. Several testing procedures as well as manipulation techniques place the head in a rotation-extension position, thereby occluding one vertebral artery. Vertebral artery occlusion is mostly asymptomatic as long as adequate compensation is achieved by a competent contralateral vertebral artery and anterior carotid circulation.¹⁵ When one vertebral artery is narrowed, it may not be capable to compensate for the positional occlusion of the larger one. In this case the rotation towards the narrow side may induce symptoms like dizziness and nystagmus. In cases of bilateral involvement, manipulation is an absolute contraindication.

Unless manipulation is expected to result in a significant clinical change in the patient's condition, it should be avoided, and never be performed in the advanced degenerative disease or in the presence of congenital anomalies. Consequently, the practitioner has to be attentive in examining the medical imaging of the cervical spine in order to exclude hazardous features. If there is the slightest doubt, it is better to abstain from manipulation.

Part III: Functional approach of the vertebral artery

Part III aimed to determine whether manipulation of the cervical spine could influence the cerebral perfusion. Cervical manipulation was performed at the level of C1-C2, with a slight right rotation, left side bending and an upper cervical dorsal flexion. The impulse was directed towards the right shoulder. A comparison of the regional cerebral blood flow pre- and post-manipulation revealed a significantly decreased perfusion in the anterior lobe of the left cerebellum which may clarify some of the symptoms patients experience after manipulation of the cervical spine. The anterior lobe of the cerebellum corresponds with the territory of the superior cerebellar artery. Hypoperfusion in this area may result in specific symptoms such as headache and dizziness. This may be explained by the fact that the anterior lobe of the cerebellum is closely connected to the vestibular nuclei, in which involvement of these nuclei may result in nystagmus, vertigo, nausea and/or vomiting.²

The observed hypoperfusion (left) was situated on the opposite side of the manipulation (right). Reasons for this are speculative, but can be attributed to the fact that most studies, as well as this study, demonstrate diminished blood flow in the artery contralateral to the side of rotation.^{1,20,24}

To the best of our knowledge this is the first study that investigates directly the local perfusion, rather than the blood flow of the supplying arteries. In previous studies, the blood flow was measured in the vertebral artery at a point midway between its origin and its disappearance into the foramen of the sixth transverse cervical process (V1 segment).¹⁵⁻¹⁷ Measurements of extracranial vertebral artery blood flow proximal to the point of restriction may have limited clinical value as some part of the blood flow may escape via the many collaterals of the vertebral artery (i.e. the spinal and muscular branches). Therefore, the assessment of the effect of cervical spine manipulation on the blood flow to the hindbrain may be more clinically valid if the measurements are made distal to the believed point of restriction, as is the case in transcranial Doppler or SPECT.

This reflection does not only account for the measurement of blood flow after the manipulation itself, but also for the assessment during the pre-manipulative testing procedure.

The implementation of clinical guidelines

In any patient for whom manual examination or treatment of the cervical spine is to be undertaken, the presence or development of VBI symptoms should be carefully assessed. If cervical manipulation or techniques involving end range cervical rotation (ERRT) are considered, a specific series of examination procedures is recommended.

A set of guidelines in the form of a clinical decision algorithm is preferred above a rather rigid formal protocol.¹⁹ (Figure 1) This leaves the ultimate decision on appropriate action to the therapist in the context of any particular individual presentation. It is the practitioner's decision on whether the potential risk outweighs the positive benefits. The clinical decision algorithm is based on:

Patient's history

As with any patient's complaint, a good history is essential to assess the nature of the presenting complaint and to determine whether the problem has the potential to respond to spinal manipulation or needs further referral. A range of symptoms has been reported as associated with VBI. The most important symptoms are dizziness/vertigo, diplopia, dysarthria, dysphagia, drop attacks and/or nausea.

Neck pain and headaches have been reported in association with dissection of the vertebral artery. A major difficulty for manipulative therapists in suspecting and recognising a vertebral artery injury such as dissection is that the signs and symptoms are similar to those for mechanical non-specific neck pain, for which intervention with spinal manual therapy might appear to be appropriate. The therapist must be certain that the presentation is clearly and unambiguously mechanical non-specific neck pain or headache before proceeding with vigorous manual procedures.

Dizziness is the major symptom associated with VBI although this can also be associated with other pathological entities. BPPV as well as cervical vertigo should be considered in differential diagnosis.

BPPV is the most common cause of vertigo of peripheral origin and is characterized by brief intense, but often severe, rotational vertigo when the head is moved into particular positions.^{12,30} Symptoms such as postural instability, generalized disequilibrium, unsteady gait, sensitivity to head movements and falls may also be reported in case of BPPV.

Cervical vertigo or dizziness has also been described, but its mechanisms remain controversial.^{3,4,32} It is likely to be caused by a disturbance in articular and/or muscular proprioceptive input from the neck. Typical presentation includes dysequilibrium or light-headedness, ataxia or unsteadiness combined with cervical pain and restricted movements, with symptoms provoked by movements of the head, in no particular direction. It is difficult to determine whether the dizziness results from cervical dizziness or VBI. This is however indispensable as the former is an indication for spinal manipulative therapy, whereas the latter is an absolute contra-indication. If a manipulative therapist is unsure of a diagnosis related to dizziness, referral to an otolaryngologist, neurologist or vestibular rehabilitation specialist is recommended.

Knowledge of contra-indications

Although this algorithm relates to VBI, the identification of symptomatology indicative of other conditions, which would contra-indicate cervical manipulation, is of equal importance. The absolute clinical contra-indication is non-mechanical neck pain due to a specific spinal disorder (i.e. fracture, tumor, infection, malformation, or inflammation), to a visceral disorder, or to a vascular disorder (i.e. VBI).³¹ Relative clinical contra-indications include disk protrusion, radicular symptoms with nerve root injury and segmental instability.³¹ Besides the usual clinical contra-indications, improperly performed manipulation and patient's fear are technical contra-indications to manipulation. Acquisition of the manual skills necessary to competently perform manipulation takes a long time. If the examiner has not perfectly mastered the techniques of manipulation, it is better not to manipulate than to manipulate incorrectly, as manipulation is seldom the only possible treatment.

Only with the patient's consent, a manipulation can be performed. According to Margarey et al. (2004), express consent is considered essential prior to techniques over which the patient has no control, such as cervical manipulation and should be re-established prior to every individual manipulative technique.¹⁹ Express consent means that an individual explicitly indicates agreement, either orally or in writing.

Pre-manipulative testing

In cadavers as well as in living humans, rotation has been demonstrated to apply the greatest stress to the vertebral arteries in the upper cervical spine, between the atlas and

axis transverse foramina. In contrast, lateral flexion of the neck apparently has little effect on vertebral artery blood flow. This functional ascertainment should be considered when a rationale is developed for the application of manipulative therapy to the cervical spine. A number of provocative tests have been developed that mechanically stress the vertebral artery. These tests, which are referred to by a variety of eponyms, including Maigne's, George's, Hautant's, DeKleyn's and Wallenberg's, all incorporate a combination of cervical rotation and extension.²² This position has to be sustained for a minimum of 10 seconds, unless symptoms are provoked sooner. The therapist has to examine the patient's eyes for the production of nystagmus while the head is held in the sustained position and simultaneously question the patient about the reproduction of symptoms.¹⁸

The effect of cervical movement on vertebral artery blood flow in view of these tests has been investigated *in vivo* using Doppler ultrasound. The findings of these studies are conflicting, leading some researchers to question the validity of pre-manipulative testing.^{6,10,13} The major drawback to all of the pre-manipulative testing procedures is their high rate of false-positives and false-negatives. False-positives are likely to occur because it is difficult to determine whether the dizziness results from VBI or cervical dizziness. Conversely, false-negatives are likely to occur because positional occlusion of a small vessel as is the case in hypoplasia, non-union or progressive stenosis due to atherosclerosis or osteophytes may have so little influence on the blood supply to the brain stem and cerebellum that it is easily compensated by the larger one. This gives the practitioner a false sense of safety.

Given that a change in blood flow related to rotation is detected in the majority of studies and that literature data highlight more incidents related to rotation than any other movements, sustained rotation is reasoned to be the most appropriate test to include as mandatory.¹⁹ However, in the presence of degenerative diseases, the contralateral vertebral artery may be pressed against the lateral prominent osteophytes of the uncinat process during side bending. Therefore, checking the permeability and compensatory ability of the vertebral arteries should not be done only in rotation positions, but also in the specific position from which the manipulation will be performed.

Nevertheless if the subjective examination already indicates the presence of VBI, no sustained end-range position of the head, which in itself exposes the patient to a greater risk, should be undertaken.⁷

Appropriate medical imaging

Manipulation should be avoided in the advanced degenerative disease (osteophytes and atherosclerotic plaques) or in the presence of congenital anomalies. In the suspicion of such disease and in cases of trauma, appropriate medical imaging is necessary to recognize such pathology. Routine X-rays of the cervical spine are widely available and allow the practitioner to detect uncovertebral osteophytes or ossified stylohyoid ligaments on lateral x-rays and osteophytes of zygapophysial joints on oblique views. In case of the presence of an angiography, the therapist should be aware of the possible existence of vascular problems. If there is the slightest doubt, it is better to abstain from manipulation.

Avoidance of certain techniques in patients thought to be at risk

The relatively high proportion of injuries linked to rotational manipulation has prompted some authors to recommend the abandon of upper cervical rotation procedures in favour of thrust methods that do not require rotation.^{2,14,29} Other authors have suggested that thrust techniques should be abandoned altogether or that other treatments such as low-velocity spinal mobilisation be used in place of manipulation.^{9,26,28} However, practitioners who tend to manipulate less commonly but, who frequently use through and end range mobilisation techniques, may have been conciliated into a false sense of security by literature, which suggests that non-manipulative techniques are less likely to produce cervical spine injury including arterial dissection.⁷ This assertion is challenged directly by a number of authors who argue that it is not the “thrust” that is dangerous but rather the extreme boundaries of movement.^{21,29}

On the basis of clinical and biomedical knowledge and the strength of the subjective and physical evidence presented in any particular clinical situation, the therapist must decide whether cervical manipulation or ERRT should be considered as treatment options. It is indispensable that therapists follow the algorithm step by step. If there is evidence at any time that symptoms are clearly associated with VBI, thrust manipulation or ERRT should not be undertaken. In all other situations, the final decision depends on the therapist's reasoning in any particular patient presentation.¹⁹ In further manipulation sessions, the patient should always be asked about any self-limited, undesirable effects after previous manipulation. Cervical manipulations should be contra-indicated for patients who experience dizziness, nausea or acute headache persisting for more than 2 days.³¹

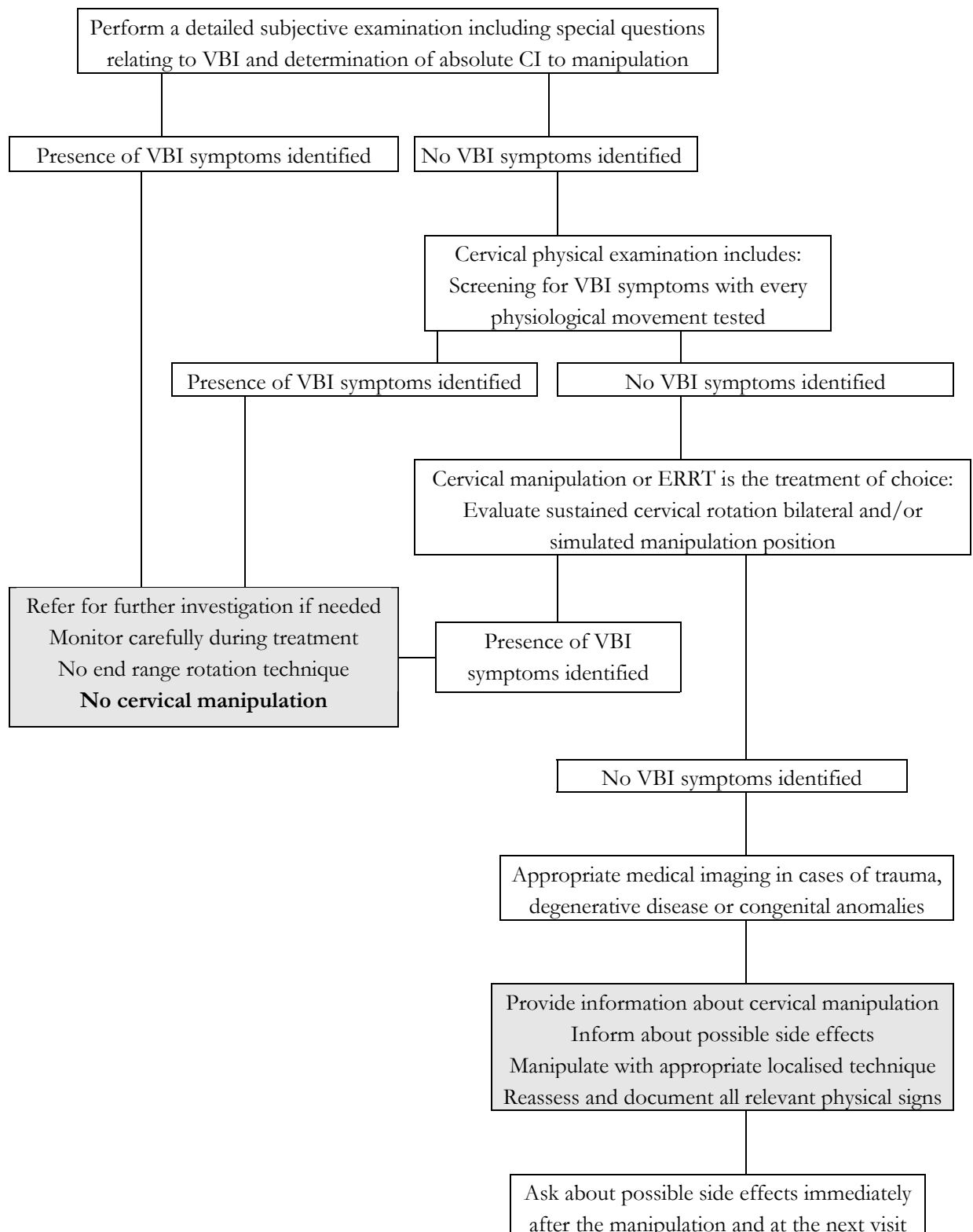


Figure 1: clinical decision algorithm for testing the presence or development of VBI symptoms in patients presenting with a cervical problem. Adapted from Magarey M. ¹⁹

Risk/benefit - analysis

In evaluating any therapy, weighing the potential risks against the potential benefits is a crucial issue. Despite the many published randomised clinical trials, a substantial number of reviews and several national clinical guidelines, much controversy still remains regarding the evidence for or against efficacy of spinal manipulation for neck pain. Nevertheless, two recent reviews by Gross et al. and Bronfort et al. come to the same conclusions: ^{5,11}

- Mobilisation and/or manipulation when used with exercise are beneficial for pain relief, functional improvement, and global perceived effect for subacute/chronic mechanical neck disorders with or without headache;
- The evidence is inconclusive for acute neck pain in the short and long term;
- Done alone, manipulation and/or mobilisation are not beneficial; When compared to one another, neither is superior;
- The evidence does not favour manipulation and/or mobilisation in combination with various other types of treatments.
- There is insufficient evidence available to draw conclusions for neck disorder with radicular findings.

The true risks are unclear. The lowest reported estimate for risk of irreversible injury when applying manipulation is one in 20.000. Estimates for serious risks following the application of mobilisation have rarely been reported.

In addition to the algorithm, the following clinical practice guidelines can be recommended: If manipulation is the choice of treatment, incorporate this technique within an overall multi-modal management strategy. The recommended multi-modal treatment strategy to use in combination with manipulation or mobilisation is exercise. A single session for manipulation or mobilisation to decrease pain is not recommended.

FUTURE DIRECTIONS

This thesis underscores the absolute claim that more investigation needs to be done regarding the safety of cervical manipulation, in view of more rigorous recommendations.

Future studies need to determine whether unambiguous sensitive and specific pre-manipulative screening protocols can be developed. The occurrence of injury following cervical manipulation in individuals without known pathology and the possibility of cumulative subclinical damage to the vertebral arteries are factors that need to be considered when using cervical manipulation. These factors complicate the assessment of sensitivity and specificity of pre-manipulative screening protocols.

There is no compelling evidence that supports the use of Doppler ultrasound as a valid clinical screening tool. It could be argued that, considering the laws of haemodynamics, the measurements of extracranial vertebral artery blood flow have limited clinical value. Therefore, the assessment of the effect of cervical spine rotation on the blood flow to the hindbrain may be more clinically valid if the measurements are made distal to the believed point of restriction at the level of the atlanto-axial joints. With the upcoming implementation of transcranial Doppler, magnetic resonance angiography and SPECT, it seems likely that there is more to learn how movements of the neck can influence arterial blood flow.

There is also a need for further investigations regarding the underlying mechanisms of side and adverse effects. The preponderance of the scientific literature supports a direct cause-and-effect mechanism between spinal manipulation and stroke. Although the relationship between both has been extensively described and discussed, little fundamental research has been done to prove this link. In addition, it would be of interest to further investigate the basic mechanisms of the occurrence of side effects.

FINAL CONCLUSIONS

Serious complications of cervical spine manipulation seem to be rare, whereas less serious side effects occur frequently. As demonstrated in the SPECT-study, some side effects may be explained by hypoperfusion in the areas perfused by the vertebrobasilar system. To the best of our knowledge this is the first study that investigates directly the local perfusion, rather than the blood flow of the supplying arteries.

Irrespective of the innocence and harmlessness of the majority of these side effects, practitioners have the professional obligation to inform patients regarding the potential consequences and/or risks of spinal manipulation. This information is a fundamental prerequisite for consenting to treatment.

The main emphasis should be placed upon assuring the safety of the patient during manipulation, in view of the seriousness of these complications and the risk of permanent neurological deficits. Premanipulative testing procedures have come under scrutiny in recent years, due to their high rate of false-positives and false-negatives. A rationale for the prevention of complications from spinal manipulation should be based on a larger entity, i.e. knowledge of patient's history and contra-indications, thorough skilled manipulative training, pre-manipulative testing, appropriate medical imaging and avoidance of certain techniques in patients thought to be at risk. A clinical decision algorithm is proposed as a guide to clinical reasoning in patient's examination and management. Subtle clues obtained during the clinical reasoning process should alert the aware clinician of a potential vascular problem, which will contribute to the decision with regard to management and potential spinal manipulative therapy.

Screening protocols should not only be restricted to the upper cervical spine, but should be performed before any cervical manipulation, as the V2 segment might also be involved in the occurrence of complications, due to osteophytes and atherosclerotic plaques.

This work underscores the flaws in a balanced manipulative approach with regard to a patient's safety. The challenge of ensuring the greatest safety of patients, who undergo

cervical spine manipulation, is substantiated. This topic certainly requires further research, as it is currently impossible to predict every individual at risk of vertebrobasilar complication from manipulation by the available tests and investigations.

One should always remember that manipulative treatment is rarely an irreplaceable therapeutic modality. It is, of course, attractive because of its rapid action and its elegance. But it is valuable only if it is well executed. It is better to do something else than to manipulate wrongly: *primum non nocere*.

References

1. Arnold C, Bourassa R, Langer T, Stoneham G. Doppler studies evaluating the effect of a physical therapy screening protocol on vertebral artery blood flow. *Man Ther* 2004; 9: 13-21.
2. Assendelft W, Bouter L, Knipschild P. Complications of spinal manipulation: a comprehensive review of the literature. *J Fam Pract* 1996; 42: 475-80.
3. Brandt T. Cervical vertigo: reality or fiction. *Audiol Neurootol* 1996; 1: 187-96.
4. Brandt T, Bronstein A. Cervical Vertigo. *J Neurol neurosurg psychiatry* 2001; 71: 8-12.
5. Bronfort G, Haas M, Evans R, Bouter L. Efficacy of spinal manipulation and mobilization for low back pain and neck pain: a systematic review and best evidence synthesis. *The spine journal* 2004; 4: 335-56.
6. Cote P, Kreitz B, Cassidy J, Thiel H. The validity of the extension-rotation test as a clinical screening procedure before neck manipulation: a secondary analysis. *J Manipulative Physiol Ther* 1996; 19(3): 159-64.
7. Di Fabio R. Manipulation of the cervical spine: risks and benefits. *Phys Ther* 1999; 79(1): 50-65.
8. Dvorak J, Kranzlin P, Muhlemann D, Walchli B. Musculoskeletal complications. In: Haldeman S, ed. *Modern developments in the practice and principles of chiropractic*. 2nd ed. East Norwalk, CT: Appleton & Lange, 1992.
9. Frisoni G, Anzola G. Vertebrobasilar ischemia after neck motion. *Stroke* 1991; 22(11): 1452-60.
10. Grant R. Professional issues. Vertebral artery testing - The Australian physiotherapy association protocol after 6 years. *Man Ther* 1996; 1(3): 149-53.
11. Gross A, Hoving J, Haines T, Goldsmith C, Kay T, Aker P, Bronfort G. A cochrane review of manipulation and mobilization for mechanical neck disorders. *Spine* 2004; 14: 1541-48.
12. Herdman S. Advances in the treatment of vestibular disorders. *Phys Ther* 1997; 77(6): 602-16.
13. Johnson C, Grant R, Dansie B, Taylor J, Spuropolous P. Measurement of blood flow in the vertebral artery using colour duplex doppler ultrasound: establishment of the reliability of selected parameters. *Man Ther* 2000; 5(1): 21-9.
14. Klougart N, Leboeuf-Yde C, Rasmussen L. Safety in chiropractic practice, part I: The occurrence of cerebrovascular accidents after manipulation to the neck in Denmark from 1978-1988. *J Manipulative Physiol Ther* 1996; 19: 371-7.
15. Licht P, Christensen H, Hojgaard P, Marving J. Vertebral artery flow and spinal manipulation: a randomized, controlled and observer-blinded study. *J Manipulative Physiol Ther* 1998; 21(3): 141-4.
16. Licht P, Christensen H, Hoiland-Carlsen P. Vertebral artery volume flow in human beings. *J Manipulative Physiol Ther* 1999; 22: 363-7.
17. Licht P, Christensen H, Svendsen P, Hoiland Carlsen P. Vertebral artery flow and cervical manipulation: an experimental study. *J Manipulative Physiol Ther* 1999; 22: 431-5.
18. Magarey M, Coughlan B, Rebbeck T. Australian Physiotherapy Association (APA). Clinical guidelines for pre-manipulative procedures for the cervical spine. Unpublished manuscript (available from the Australian Physiotherapy Association National Office, Melbourne)
19. Magarey M, Rebbeck T, Coughlan B, Grimmer K, Rivett D, Refshauge K. Premanipulative testing of the cervical spine review, revision and new clinical guidelines. *Man Ther* 2004; 9: 95-108.
20. Mann T, Refshauge K. Causes of complications from cervical spine manipulation. *Austr J Phys* 2001; 47: 255-66.
21. Michaeli A. Reported occurrence and nature of complications following manipulative physiotherapy in South Africa. *Austr J Phys* 1993; 39: 309-15.
22. Michaud T. Uneventful upper cervical manipulation in the presence of a damaged vertebral artery. *J Manipulative Physiol Ther* 2002; 25: 472-83.
23. Mitchell J. Vertebral artery atherosclerosis: a risk factor in the use of manipulative therapy? *Physiother Res Int* 2002; 7(3): 122-35.

24. Mitchell J. Changes in vertebral artery blood flow following normal rotation of the cervical spine. *J Manipulative Physiol Ther* 2003; 26: 347-51.
25. Oga M, Yuge I, Terada K, Shimizu A, Sugioka Y. Tortuosity of the vertebral artery in patients with cervical spondylotic myelopathy. Risk factor for the vertebral artery injury during anterior cervical decompression. *Spine* 1996; 21:1085-9.
26. Powell F, Hanigan W, Olivero W. A risk/benefit analysis of spinal manipulation therapy for relief of lumbar or cervical pain. *Neurosurgery* 1993; 33(1): 73-8.
27. Prescher A. Anatomy and pathology of the aging spine. *Eur J Radiol* 1998; 21:181-195.
28. Raskind R, North C. Vertebral artery injuries following chiropractic cervical spine manipulation -case reports. *Angiology* 1990; 41(6): 445-52.
29. Terrett A. Current concepts in vertebrobasilar complications following spinal manipulation. West Des Moines, IA: NCMIC Group Inc, 2001.
30. van der Velde G. Benign paroxysmal positional vertigo. Part I: background and clinical presentation. *Journal of the Canadian Chiropractic Association*. 1999; 43(1): 31-40.
31. Vautravers P, Maigne J. Cervical spine manipulation and the precautionary principle. *Joint Bone Spine* 2000; 67: 272-6.
32. Wrisley D, Sparto P, Whitney S, Furman J. Cervicogenic dizziness: a review of diagnosis and treatment. *JOSPT* 2000; 30(12): 755-66.
33. <http://www.safetyandquality.org/definition>

NEDERLANDSTALIGE SAMENVATTING

Nederlandstalige samenvatting

Het is onmiskenbaar vanuit maatschappelijk en medisch oogpunt dat manipulaties van de wervelkolom de afgelopen jaren een groeiende populariteit kennen in de klinische praktijk met het oog op de behandeling van rug- en nekpijn. Ongeacht de therapeutische effectiviteit, worden bij uitvoering van deze manipulaties regelmatig nawerkingen en zelfs complicaties vastgesteld. Nawerkingen of side effects kunnen worden gedefinieerd als onschadelijke, kortdurende nevenwerkingen. Naast deze ‘onschuldige’ nawerkingen worden in de literatuur, ook adverse-effects of complicaties beschreven: schadelijke effecten met tijdelijke of definitieve letsels en eventueel de dood voor gevolg.

Beschadiging van het vertebrobasilaire systeem, en meer specifiek van de arteria vertebralis zelf, vormt de meest ernstige, meest gekende en gevreesde complicatie na manipulaties van de cervicale wervelkolom.

De informatie over complicaties na manipulaties is schaars en dispaaraat en vereist grondige literatuurstudies en fundamenteel onderzoek om een bredere kennis te krijgen over dit onderwerp. Dit proefschrift wil een zinvolle bijdrage leveren tot het verwerven van een beter inzicht in de anatomische en functionele rol van de arteria vertebralis bij het optreden van nawerkingen en complicaties na manipulaties van cervicale wervelkolom.

Een eerste doelstelling is het bepalen van de eigenschappen van nawerkingen en complicaties na manipulaties en het identificeren van mogelijke risicofactoren. Volgens een literatuurstudie blijkt de incidentie van complicaties relatief laag te zijn. De prevalentie na een cervicale manipulatie blijkt beduidend hoger dan na een lumbale behandeling; 82% ervan kan worden ondergebracht onder de term ‘vertebrobasilaire insufficiëntie’, maar de gepubliceerde case-studies vormen waarschijnlijk enkel het topje van de ijsberg.

Anderzijds blijkt dat meer dan 60% van de patiënten voorbijgaande nawerkingen ondervindt na een eerste manipulatie. De belangrijkste nawerkingen zijn hoofdpijn, stijfheid, lokaal ongemak, uitstralingspijn en vermoeidheid, die voornamelijk beginnen in de loop van de eerste vier uur na de manipulatie en verdwijnen gedurende de volgende 24 uur. Vrouwen rapporteren gemakkelijker nawerkingen dan mannen en cervicale manipulaties blijken meer hoofdpijn, duizeligheid en misselijkheid te veroorzaken dan lumbale of thoracale manipulaties.

Hoewel nawerkingen moeilijk als risico's kunnen worden bestempeld, is het toch noodzakelijk dat de patiënt over het bestaan hiervan op de hoogte wordt gesteld. Het belang van het inlichten van de patiënt, ligt voornamelijk in het feit dat deze nawerkingen zich in hoofdzaak voordoen nadat de patiënt de praktijkruimte heeft verlaten en er dus een potentieel gevoel van onrust kan ontstaan. Patiënten moeten weten dat nawerkingen frequent voorkomen, dat ze mild tot matig zijn, maar dat ze meestal verdwijnen binnen de 24 uur.

Ten tweede is het van belang om te differentiëren tussen adequate en buitensporige nawerkingen. Duizeligheid en nausea moeten de therapeut waarschuwen als voorbodes van meer ernstige reacties. Als duizeligheid, misselijkheid of acute hoofdpijn langer dan twee dagen blijft duren dan is cervicale manipulatie een contra-indicatie, tenzij deze reacties kunnen toegewezen worden aan een andere goedaardige aandoening, zoals BPPV of cervicogene duizeligheid. Het is essentieel om de patiënt te bevragen over deze reacties bij de volgende consultatie en hem te adviseren vroeger contact op te nemen indien er ongerustheid ontstaat.

De unieke anatomie van de arteria vertebralis en de biomechanica van de (hoog)cervicale wervelkolom in relatie tot deze arterie maken de arteria vertebralis bijzonder kwetsbaar. Er zijn verschillende congenitale en structurele factoren die kunnen leiden tot een verminderde bloedstroom in de arteria vertebralis, resulterend in ischemie en eventueel neurologische symptomen. In een tweede deel van dit proefschrift werd getracht een beter inzicht te verkrijgen in de anatomische factoren die een invloed kunnen hebben op het verloop van de arteria vertebralis. Hiervoor werden zowel kadaverstudies als studies op droge wervels uitgevoerd.

Om de externe risicofactoren te identificeren, werd de aanwezigheid van osteofieten en hun invloed op het verloop van de arteria vertebralis nagegaan op 111 droge wervels. Osteofieten kwamen voornamelijk voor ter hoogte van de processus uncinatus van C5 en C6 waarbij de helft van deze osteofieten het foramen transversarium deels overlappen. Het gros van de onderzoeken naar complicaties na manipulaties focust zich op het V3 segment. Dit onderzoek bevestigt dat ook andere segmenten kunnen betrokken zijn bij het optreden van complicaties. De aanwezigheid van osteofieten en hun invloed op de arteria vertebralis zijn van klinisch belang gezien ze de arterie dwingen om zich in bochten te slingeren rond deze obstructies en de arterie door externe compressie vernauwen. In een 'worst case

scenario' kunnen ze ook mogelijke predilictieplaatsen vormen voor een trauma, resulterend in dissectie. Daarom is het belangrijk dat screening niet alleen beperkt wordt tot de hoogcervicale wervelkolom, maar wordt uitgevoerd voor elke cervicale manipulatie.

Atherosclerotische plaques vormen intrinsieke risicofactoren voor complicaties. De relatie tussen de lokalisatie en frequentie van atherosclerotische plaques en het bochtig verloop van de arteria vertebralis werd onderzocht aan de hand van een kadaverstudie. In 35.1% van de gevallen, was atherosclerose unilateraal aanwezig, in 42.1% bilateraal. In het V1 en het V2 segment was er een correlatie tussen het bochtig verloop van de arterie en de aanwezigheid van atherosclerose. De detectie van atherosclerotische plaques is van klinisch belang in het kader van manipulaties, gezien deze behandeling de ontwikkeling van atherosclerotische plaques kan stimuleren of een embolie kan veroorzaken. In het slechtste geval kan het direct een dissectie veroorzaken bij aanwezigheid van atherosclerotische plaques.

Tijdens het disseceren, werd ook één geval van non-union en één geval van een verbeend ligamentum stylohyoideum in associatie met anomalieën van de arteria vertebralis vastgesteld. Deze anomalieën zijn klinisch van belang in het kader van manipulaties en zouden premanipulatief moeten gedetecteerd worden aan de hand van medische beeldvorming om risico's te vermijden.

Daarnaast beïnvloeden deze verschillende anatomische factoren ook de interpretatie van premanipulatieve testen. De verschillende testprocedures omvatten een rotatie-extensiepositie van het hoofd, waarbij één arteria vertebralis wordt afgesloten. Zolang er voldoende compensatie wordt verkregen via de toereikende contralaterale arterie en de anterieure circulatie van de arteriae carotica, zullen er geen symptomen optreden. Wanneer één arterie echter vernauwd is, kan deze niet compenseren voor de houdingsgebonden occlusie van de andere arterie. Wanneer de arterie aan beide zijden is vernauwd, dan is manipulatie een absolute contra-indicatie.

In een derde fase werd nagegaan of na een manipulatie er een tijdelijke verandering in hersendoorbloeding optreedt die het ontstaan van nawerkingen zou kunnen verklaren. De manipulatie werd uitgevoerd bij 15 proefpersonen op het niveau C1-C2, met het hoofd in een rotatie rechts, lateroflexie links en een hoogcervicale extensie. De thrust was in de richting van de rechter schouder. Een vergelijking van de regionale bloedstroom pre- en postmanipulatief toonde een significante hypoperfusie in de anterieure lobus van het linker

cerebellum. De anterieure lobus correspondeert met het gebied van de arteria cerebellaris superior en hypoperfusie in dit gebied kan resulteren in specifieke symptomen zoals duizeligheid door de nabijheid van de vestibulaire nuclei. De kant van de hypoperfusie (links) was tegengesteld aan de richting van de manipulatie (rechts). Dit kan mogelijks te wijten zijn aan het feit dat, volgens literatuur, verminderde bloedstroom optreedt in de arteria vertebralis aan de contralaterale zijde van rotatie.

Het gebruik van investigaties waarbij de bloedstroom wordt geregistreerd in het cerebellum en de pons zelf, zoals bij SPECT, verdienen de voorkeur boven extracraniale Doppler studies. Metingen van de extracraniale bloedstroom hebben een beperkte klinische waarde gezien een groot deel van de bloedstroom kan ontsnappen via verschillende collateralen van de arteria vertebralis. Deze bemerking geldt niet alleen voor de metingen van de bloedstroom na de manipulatie zelf, maar ook voor het bepalen van de bloedstroom tijdens de premanipulatieve testen.

De verschillende subdoelen van dit proefschrift hebben uiteindelijk geleid tot het opstellen van een klinisch algoritme. Hierbij beslist de therapeut zelf welke mogelijke acties hij moet ondernemen afhankelijk van de presentatie van de individuele patiënt. De bedoeling van dit algoritme is dat een degelijke screening van de patiënt gebeurt alvorens cervicale manipulaties worden uitgevoerd om zo risicopatiënten te identificeren. De rationale voor de preventie van complicaties moet gebaseerd zijn op kennis van de contra-indicaties, het verhaal van de patiënt, de premanipulatieve testing, accurate medische beeldvorming en het vermijden van bepaalde technieken.

Als besluit kunnen we stellen dat er nog heel wat onderzoek moet worden verricht naar de veiligheid van manipulaties. Op dit moment is het niet mogelijk om elke risicopatiënt te detecteren. Het is van groot belang zoveel mogelijk de veiligheid van de patiënt bij het ondergaan van een manipulatie te waarborgen, gezien de ernst van deze verwikkelingen en het risico van permanente neurologische uitval. Men mag echter niet vergeten dat manipulaties zelden een onvervangbare behandeltechniek zijn. Deze techniek is natuurlijk wel aantrekkelijk door de snelle interventie, maar is enkel waardevol indien ze goed wordt uitgevoerd. *‘primum non nocere’*.

