

## Dysplastic elbow diseases in dogs

### *Elleboogdysplasie bij honden*

Y. Samoy, I. Gielen, H. van Bree, B. Van Ryssen

Department of Medical Imaging and Orthopedics of Domestic Animals, Faculty of Veterinary Medicine, Ghent University,  
Salisburylaan 133, B-9820 Merelbeke

yves.samoy@ugent.be

#### ABSTRACT

**Elbow dysplasia (ED) is a term used to describe the most common causes of elbow lameness. The term refers to ununited anconeal process (UAP), fragmented coronoid process (FCP), osteochondritis dissecans (OCD) and elbow incongruity, according to the International Elbow Working Group (IEWG). All conditions are polygenetic and multifactorial diseases that often occur in young, popular breeds. Elbow incongruity has been suggested as a causative factor in most of these pathologies.**

**The aim of this review was to describe the etiology and clinical appearance on radiography, computed tomography (CT) and arthroscopy, together with their treatment options and prognosis.**

#### SAMENVATTING

Elleboogdysplasie is een term die de meest voorkomende oorzaken van elleboogmanken groepeert. Volgens de International Elbow Working Group (IEWG) omvat deze groep losse processus anconeus (LPA), losse processus coronoideus (LPC), osteochondritis dissecans (OCD) en elleboogincongruentie. Iedere aandoening is polygenetisch en multifactorieel en komt vaak voor bij jonge, populaire hondenrassen. Elleboogincongruentie wordt bovendien genoemd als een oorzakelijke factor bij de meeste van deze aandoeningen.

Het doel van dit artikel is een overzicht te geven van de etiologie, van het klinisch beeld op radiografie, computer tomografie (CT) en artroscopie, en van de behandelingsopties en de prognose na de behandeling van de verschillende aandoeningen.

#### INTRODUCTION

Elbow pathology is a frequent cause of lameness and osteoarthritis in young, rapidly growing, large and giant breed dogs (Van Ryssen and van Bree, 1997; Morgan *et al.*, 1999; Gemmill and Clements, 2007). The most common causes of elbow lameness are incorporated under the term elbow dysplasia (International Elbow Working Group Protocol, 1995).

Until 1974, no distinction was made between the different types of osteoarthritis in the elbow joint. It was believed that every degenerative joint disease (DJD) in the elbow was caused by an ununited anconeal process. This theory was abandoned, when severe cartilage damage on the medial part of the humeral condyle was reported, caused by a loosely attached fragment of the medial coronoid process of the ulna (Tirgari, 1974; Olsson, 1983). More reports on other causes of DJD were made, and in 1975 fragmented coronoid process and osteochondritis dissecans were attributed to osteochondrosis, a group of disorders caused by a disturbed endochondral ossification of the growth cartilage (Olsson, 1983).

The term elbow dysplasia was introduced in the mid 80's. Several studies tried to find the underlying cause of the three conditions mentioned above, and sug-

gested an underlying mechanical stress or malarticulation of the elbow joint that was causing the fragmentation (Olsson, 1983; Wind, 1986; Wind and Packard, 1986). One histomorphometric study has reported on microfracture (fatigue microdamage) in the medial coronoid process as the initiating event for fragmentation (Danielson *et al.*, 2006). Elbow incongruity is often mentioned as a factor causing elbow fragmentation, although vast evidence of the fact that incongruity is always present upon fragmentation could not be found (Mason *et al.*, 2002; Gemmill *et al.*, 2005; Kramer *et al.*, 2006; Meyer-Lindenberg *et al.*, 2006; Gemmill and Clements, 2007).

Nowadays, elbow dysplasia is known as a polygenetic and multifactorial condition, often diagnosed in Labrador retrievers, Golden retrievers, Rottweilers, German shepherds and Bernese Mountain dogs and refers to UAP, FCP, OCD or elbow incongruity (Gron-dalen and Lingaas, 1991; Kirberger and Fourie, 1998; Janutta *et al.*, 2006). Some authors also include incomplete ossification of the humeral condyle (Rovesti *et al.*, 1998; Robin and Marcellin-Little, 2001) and medial compartment disease (Fitzpatrick, 2010), but this review is restricted to the conditions described by the IEWG. The clinical signs usually start at the age of four to eight months (Kirberger and Fourie, 1998), al-

though adult dogs and atypical breeds can also be affected (Samoy *et al.*, 2005; Vermote *et al.*, 2010).

The diagnosis of elbow dysplasia is based on different aspects. Clinical examination is of great value since muscle atrophy, joint pain, joint effusion and a decreased range of motion can indicate the localization of the problem (Kirberger and Fourie, 1998). Based on the initial clinical examination, additional imaging techniques such as radiography, CT or arthroscopy, can be performed.

Radiography is the most commonly used screening technique to diagnose elbow dysplasia. The standard projections are a mediolateral extended and flexed projection combined with a 15° oblique craniomedial-caudolateral projection (International Elbow Working Group Protocol, 1995). Unfortunately, radiography is not always sufficient to detect the lesions, especially in case of FCP (Snaps *et al.*, 1997; Wosar *et al.*, 1999; Mason *et al.*, 2002; Blond *et al.*, 2005). CT and arthroscopy can help in the diagnosis of elbow dysplasia, because both techniques allow a better visualization of the joint structures. CT provides detailed information on the bony structures of the elbow without superimposition (De Rycke *et al.*, 2002). Arthroscopy allows direct inspection of the joint cartilage and can simultaneously be used to treat the dysplastic elbow (Van Ryssen *et al.*, 1993; Van Ryssen and van Bree, 1997; Van Ryssen, 2001). An early diagnosis is not only required to solve the lameness, but also to improve the long term outcome (Thomson and Robins, 1995; Ness, 1998). The aim of this paper is to give an overview of the pathophysiology, diagnosis, treatment and prognosis of every condition classified under elbow dysplasia.

## ANATOMY OF THE ELBOW JOINT

The elbow joint is a complex, accurately matching joint, formed by the distal part of the humerus and the proximal part of the radius and ulna (Figure 1) (Samoy *et al.*, 2006). The elbow is designed for flexion and extension, although it allows limited pronation and supination. The lateral part of the humeral condyle is in contact with the radial head, while the medial part is supported by the medial coronoid process. Previously, the radial head was considered the major weight bearing structure in the joint (Fox *et al.*, 1983), but more recent studies have shown that the weight is almost equally divided between the radial head and the medial coronoid process of the ulna (Mason *et al.*, 2005).

The incisura trochlearis of the ulna bends around the humeral condyle, and thus restricting the caudal movement of the humerus. When extending the elbow, the processus anconeus is locked into the foramen supratrochleare of the humerus, and it contributes to the lateromedial stability. The radial head is enclosed by both the medial and the lateral coronoid processes and the connecting annular ligament. Because of its size and position, the medial coronoid process is more vulnerable to lesions than the lateral coronoid process (Figure 2).

The medial and lateral collateral ligaments are, together with the annular ligament, the most important soft tissue structures for the elbow stability.

## UNUNITED ANCONEAL PROCESS

### Etiology

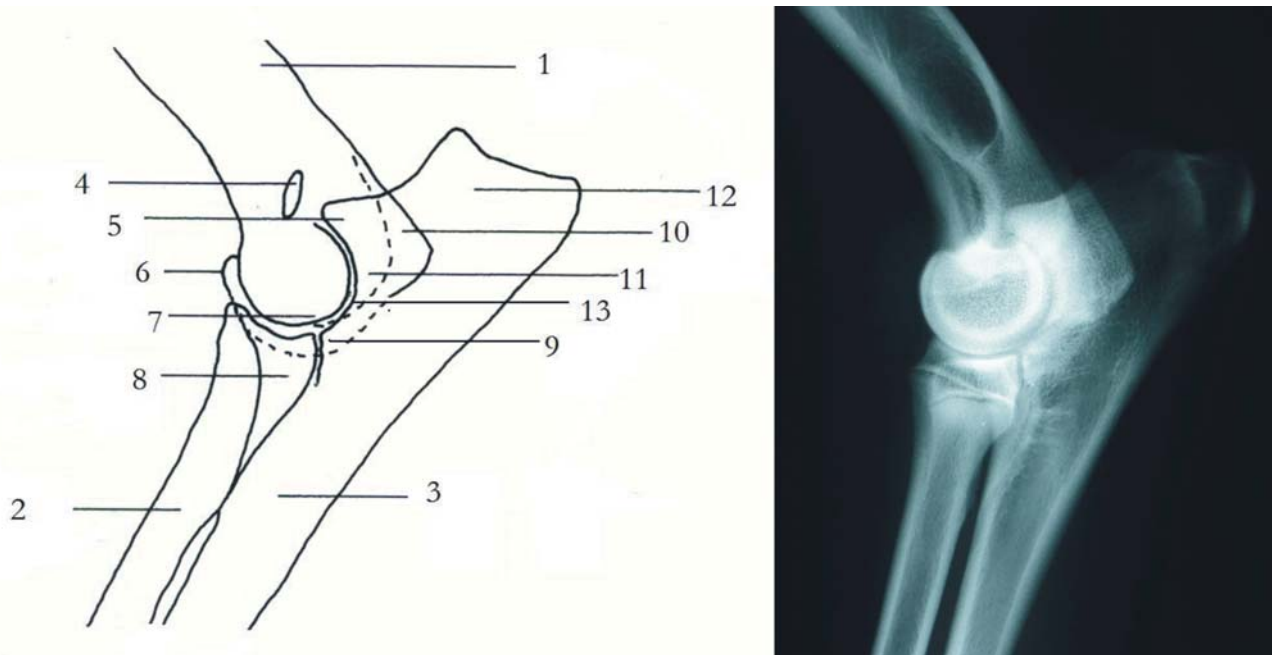
In large dogs, the anconeal process is either formed as a direct extension of the proximal ulnar growth centre, or it originates from a separate ossification centre formed between eleven and twelve weeks of age (Read, 1993; Bojrab *et al.*, 1998). In breeds that have a separate ossification centre, such as the German shepherd and chondrodystrophic breeds, fusion with the ulna occurs at the age of approximately five months. Therefore, a UAP should never be diagnosed before that age (Fox *et al.*, 1983; Read, 1993). Greyhounds should have a full fusion at fifteen weeks. When there is no radiographic fusion at twenty weeks (or fifteen weeks in Greyhounds), the finding is pathologic and is called an ununited anconeal process (Meyer-Lindenberg *et al.*, 2002; Breit *et al.*, 2004). A more recent study demonstrated that a separate ossification centre also occurs in some medium to large breed dogs, without being correlated to the development of UAP. This might allow an earlier diagnosis of UAP (Frazho *et al.*, 2010).

Ununited anconeal process was the first elbow pathology which was generally believed to induce elbow osteoarthritis (Olsson, 1983). Although the exact etiology of the disease is still unknown, a multifactorial cause is proposed. Trauma, metabolic and genetic disorders are believed to have influence on the occurrence of UAP (Wind, 1986; Wind and Packard, 1986; Breit *et al.*, 2004). The main cause, however, is a short ulna which causes stress on the anconeal process. German shepherd dogs are known to have the highest incidence of UAP (Hazewinkel *et al.*, 1988; Breit *et al.*, 2004). A recent breed susceptibility study, however, has shown that the Labrador and Golden retrievers run an equal or even a higher risk of developing UAP (LaFond *et al.*, 2002).

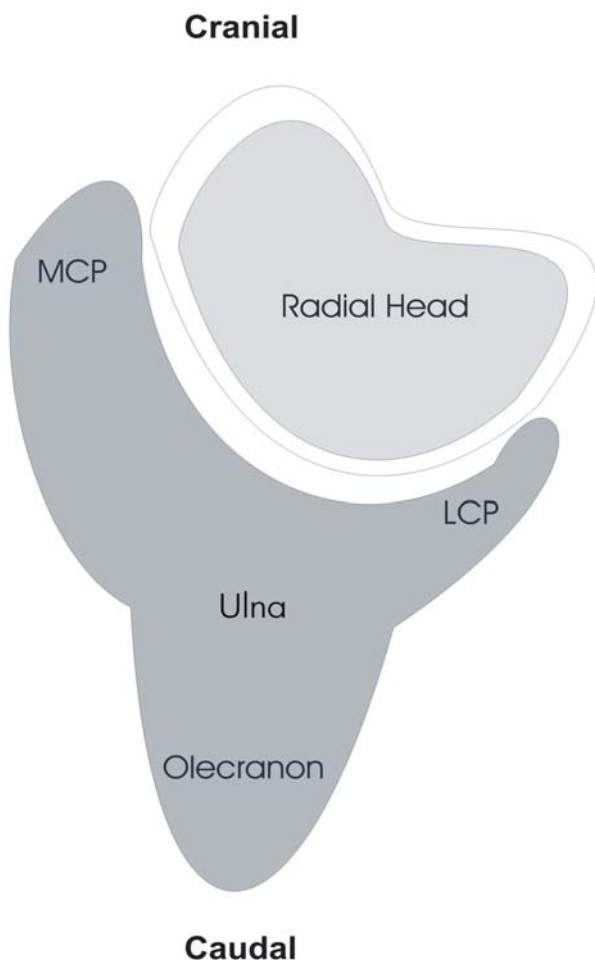
### Clinical signs

Affected dogs are often presented between two and nine months of age with uni- or bilateral front limb lameness (Fox *et al.*, 1983; Read, 1993). Since bilateral lesions occur in up to 47% of the cases, both elbows should be clinically and radiographically examined (Slatter, 2002; Burton and Owen, 2008). Clinical examination reveals a painful, distended elbow. Crepitation is frequently presented with flexion or extension of the involved joints. Due to pain and/or osteoarthritis, a decreased range of motion (ROM) can be detected (Fox *et al.*, 1983; Breit *et al.*, 2004).

Although UAP is a developmental problem, adult dogs can also be affected without any history of lameness at an early age. Signs are most frequently seen around the age of seven years and are often associated with trauma or heavy exercise. This suggests that



**Figure 1.** Schematic drawing and radiographic anatomy of the elbow (lateral position). 1. Humerus, 2. Radius, 3. Ulna, 4. Supratrochlear foramen, 5. Anconeal process, 6. Medial part of the humeral condyle (trochlea), 7. Lateral part of the humeral condyle (capitulum), 8. Medial coronoid process, 9. Lateral coronoid process, 10. Medial epicondyle, 11. Lateral epicondyle, 12. Olecranon, 13. Incisura trochlearis or trochlear notch of the ulna (Samoy *et al.*, 2006).



**Figure 2.** Schematic cross section of radius and ulna. MCP and LCP respectively stand for medial and lateral coronoid process.

young dogs may suffer from a subclinical form of UAP (Read, 1993).

**Radiographic findings**

In most cases, a lateromedial radiograph of the flexed elbow is diagnostic (Slatter, 2002). In case of a non-displaced detached or ununited anconeal process, a fracture line is visible. The fragment can also be displaced proximally. Secondary osteoarthritis is present in most cases (Figure 3).

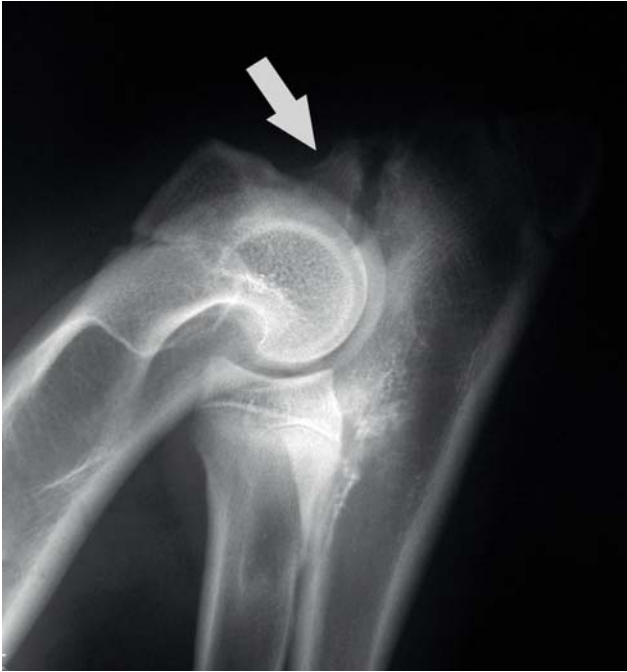**CT findings**

CT adds information about the displacement of the fragment, lesions of the medial coronoid process and the severity of incongruity (De Rycke *et al.*, 2002). The best location to diagnose an ununited anconeal process on CT is the proximal part of the incisura trochlearis (trochlear notch) on transverse slices and on sagittal reconstructions through the centre of the notch (Figure 4).

**Arthroscopic findings**

Arthroscopy can be performed using a medial approach (Van Ryssen and van Bree, 1997). Arthroscopic examination of an affected joint reveals a detached fragment in the proximal part of the trochlear notch. Additionally, erosions on the condyle of the humerus can be seen and concomitant lesions of the medial coronoid process can be diagnosed (Figure 5).





**Figure 3.** Radiographic features of a UAP in a young dog. The fragment is indicated by the arrow. In this early case, there is slight osteoarthritis.

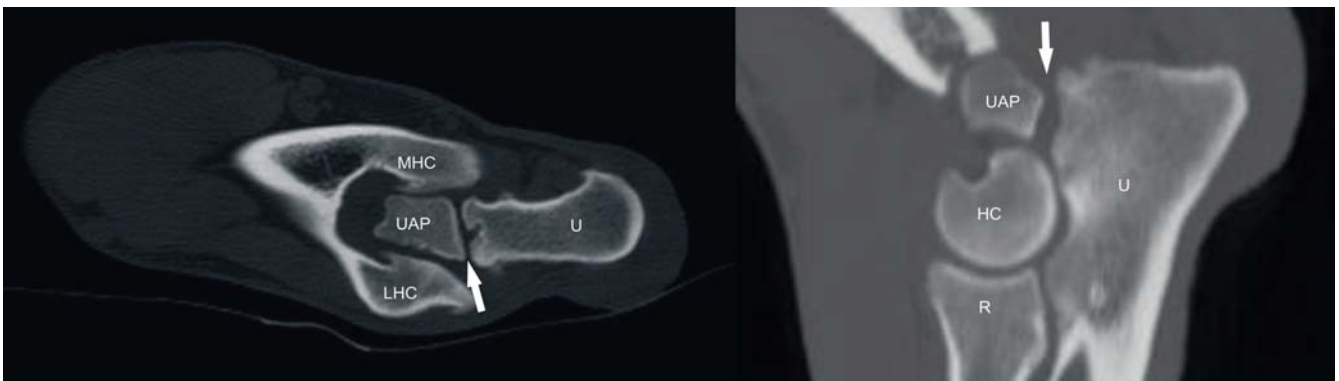### Treatment

Treatment is either conservative or surgical. When the clinical signs are minimal, a conservative treatment with rest and NSAID's can be proposed (Read, 1993). In all other cases, surgical treatment is advised. Several techniques have been described, such as fixation with a lag screw, removal of the anconeal process and a proximal ulnotomy (Fox *et al.*, 1983; Read, 1993; Thomson and Robins, 1995). In young dogs, a dynamic proximal ulnar osteotomy combined with fragment fixation yields the best results. In adult dogs, the fragment is removed via arthrotomy or arthroscopy (Grussendorf *et al.*, 2008). Prognosis is good to guarded because of subsequent joint instability and secondary osteoarthritis (Fox *et al.*, 1983; Read, 1993).

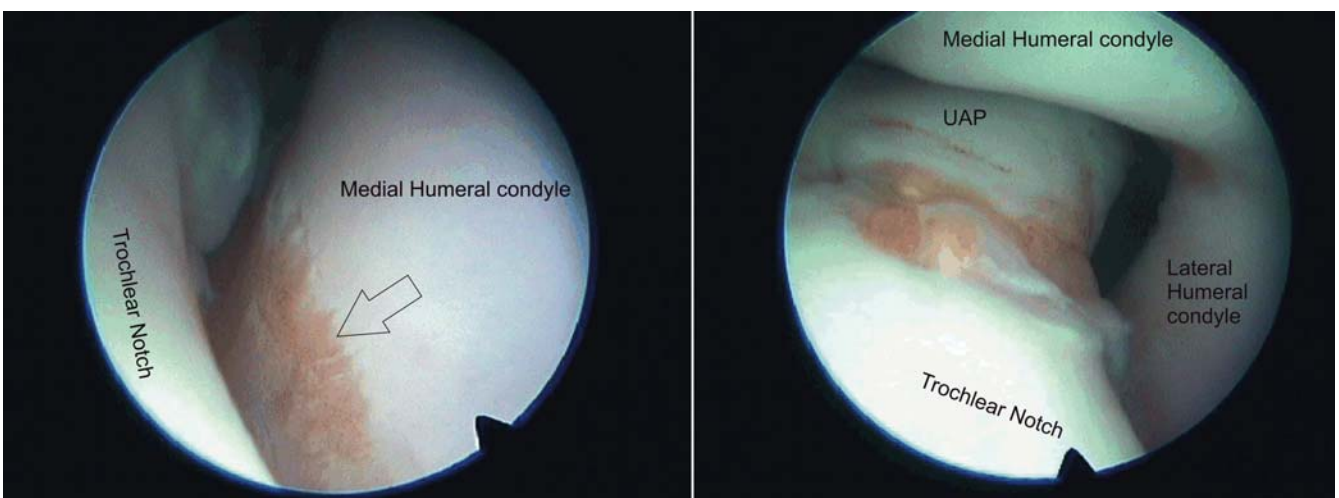
### FRAGMENTED MEDIAL CORONOID PROCESS

### Etiology

FCP is the most common disorder of the elbow dysplasia complex (Fox *et al.*, 1983; Olsson, 1983; Van Ryssen and van Bree, 1997). Unlike the anconeal



**Figure 4.** Transverse (left) and sagittal reconstruction CT images of an elbow affected with ununited anconeal process (UAP). The white arrow indicates the fragmentation line. HC= humeral condyle, MHC= medial part of the humeral condyle, LHC= lateral part of the humeral condyle, UAP= ununited anconeal process (fragment), U= ulna, R= radius.



**Figure 5.** Arthroscopic images of an elbow with UAP. The left image shows erosion on the medial part of the humeral condyle (transparent arrow). The right image shows the fragmentation line (red region) of the anconeal process. The detached fragment is located proximally (UAP).

process, the medial coronoid process never has a separate ossification centre. The exact etiology is not yet fully understood, but genetics, trauma, metabolic factors, exercise and nutrition play an important role in the development of a fragmented coronoid process (Breit *et al.*, 2004; Gemmill *et al.*, 2005; Danielson *et al.*, 2006). Before the age of five months, the coronoid process consists of cartilage, which slowly ossifies from base to tip (Olsson, 1983). It is believed that (as part of the osteochondrosis complex) the lesion starts in the cartilage and later extends to the bone. Due to a defect in the cartilage ossification, chondromalacia occurs, which leads to fissures and fragmentation in the cartilage and underlying bone (Fox *et al.*, 1983; Olsson, 1983; Kirberger and Fourie, 1998).

The current belief is that (temporary) radio-ulnar incongruity causes an increased pressure on the immature medial coronoid process, resulting in microfractures and fragmentation of the medial coronoid process (Wind, 1986; Thomson and Robins, 1995; Breit *et al.*, 2004; Danielson *et al.*, 2006; Kramer *et al.*, 2006). In smaller breed dogs, the ossification process is completed earlier than in large dogs. This may explain why FCP more often occurs in large breed dogs than in small breed dogs (Breit *et al.*, 2004). Often affected breeds are Basset hounds, Bernese mountain dogs, Bouvier des Flandres, bullmastiffs, Chow chows, German shepherd dogs, Golden retrievers, Gordon setters, Irish wolfhounds, Labrador retrievers, mastiffs, Newfoundlands, Rottweilers and Saint Bernards (LaFond *et al.*, 2002).

### Clinical signs

Dogs affected with FCP are most frequently presented with lameness between the ages of seven and nine months. Some dogs (between four and five months old) suffer from “morning stiffness”. This early lameness is often temporary and may be falsely considered as “growing pains” (Kirberger and Fourie, 1998). In a recent study, however, 12% of the presented dogs were six years or older (Vermote *et al.*, 2010). The dogs might have been chronically lame, but most of them had a recent history of lameness. The review demonstrated that the lesions were similar to those of young dogs, except for the high prevalence of extended cartilage erosions (medial compartment disease).

A typical feature on clinical examination is the mild abduction of the affected front limb(s). Lameness varies from subtle to very severe (Olsson, 1983) and palpation shows a variety of joint distension, pain and a decreased range of motion (Berzon and Quick, 2006).

### Radiographic findings

Radiographic evaluation of the medial coronoid process is often challenging and should be based on high quality mediolateral extension, mediolateral flexion and 15° oblique craniomedial-caudolateral views

(Wosar *et al.*, 1999). The primary lesion is often not visible because of the superimposition of the medial coronoid on the radial head (Kirberger and Fourie, 1998; Hornof *et al.*, 2000; Berzon and Quick, 2006). Primary and secondary changes can be subtle and thus diagnosis can be missed on plain radiographs (Samoy *et al.*, 2005).

Typical radiographic abnormalities are subtrochlear sclerosis of the trochlear notch of the ulna (Burton *et al.*, 2008), unsharp delineation of the proximal aspect of the medial coronoid process and secondary osteoarthritis (Hornof *et al.*, 2000) (Figure 6). A recent study has demonstrated that subtrochlear sclerosis is a good indication for the medial coronoid process pathology in the Labrador retriever, but is believed to be unreliable for routine use (Burton *et al.*, 2007; Burton *et al.*, 2008).

Radiography is often insufficient to reach a conclusive diagnosis, requiring further examination with CT or arthroscopy (Van Ryssen and van Bree, 1997; Hornof *et al.*, 2000).

### CT findings

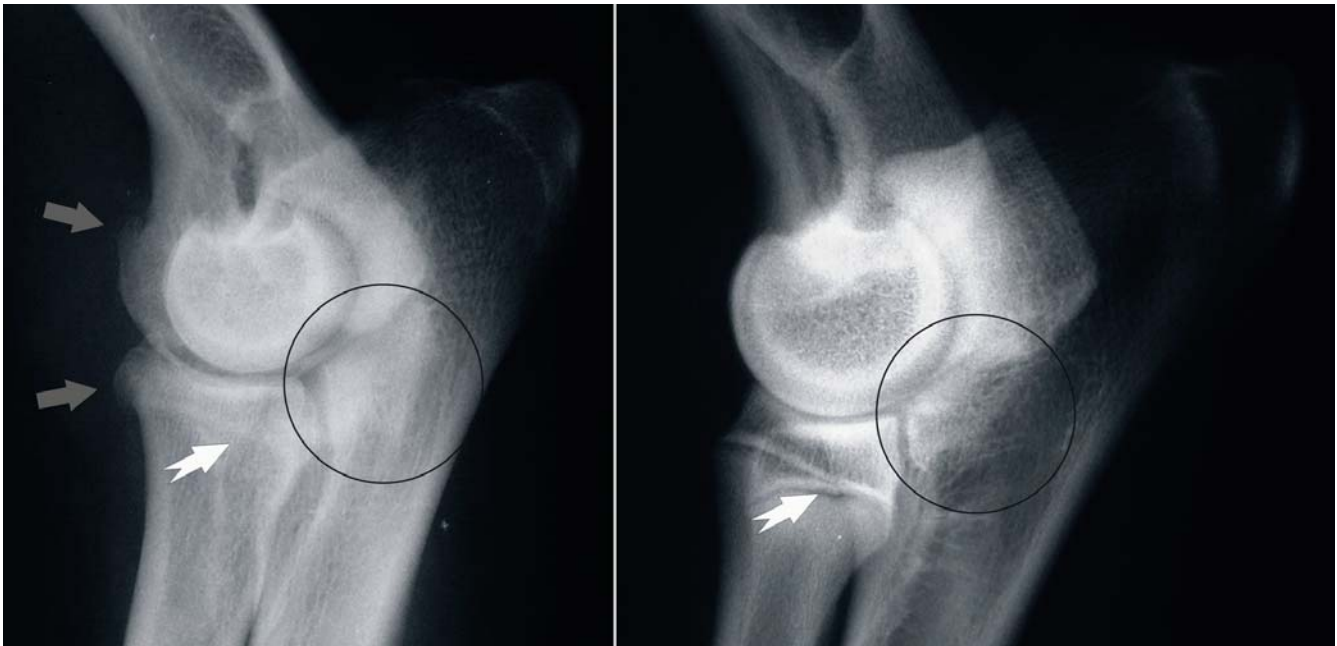CT scan is considered superior for diagnosing FCP (Carpenter *et al.*, 1993; Braden *et al.*, 1994). With the dog positioned in lateral recumbency, both elbows can easily be assessed simultaneously. In this way, the medial coronoid process can be evaluated without superimposition of the bony structures (De Rycke *et al.*, 2002) (Figure 7).

### Arthroscopic findings

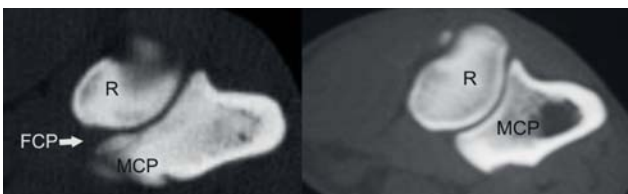
Arthroscopy allows a direct and detailed inspection of the medial coronoid process. Different types of fragmentation and cartilage lesions of the medial coronoid process can be identified, and kissing lesions or concomitant OCD of the medial part of the humeral condyle can be demonstrated (Van Ryssen and van Bree, 1997) (Figure 8).

### Treatment

In mild cases, conservative treatment with rest and NSAID's and nutroceuticals can be considered (Walde and Tellhelm, 1991). In all other cases, surgical treatment is advised. Treatment consists of the removal of the loose fragment(s). A clinical improvement in 90% of the patients is to be expected when using arthroscopy. When using arthrotomy, only 72 % of the cases show clinical improvement (van Bree and Van Ryssen, 1998; Evans *et al.*, 2008). Fragment removal can be performed via arthrotomy, but arthroscopy is the preferred technique (Walde and Tellhelm, 1991; van Bree and Van Ryssen, 1995; Van Ryssen and van Bree, 1997; Kirberger and Fourie, 1998). Surgery performed at a young age yields better results than conservative treatment (Grondalen, 1979).

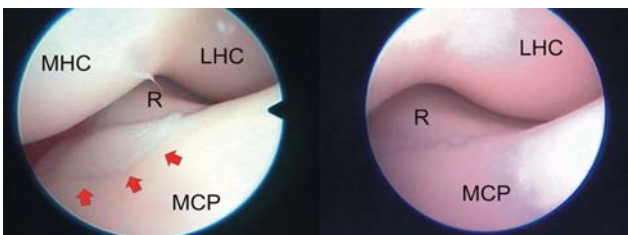


**Figure 6.** Radiographic features of FCP in the affected and normal elbow. Left image shows an elbow affected with FCP. The white arrow indicates an irregular, blurred shape. A fracture line and fragment are visible above the arrow. The grey arrows show osteoarthritic changes on the cranial border of the radial head and distal humerus. On the right image, the white arrow indicates a sharply delineated coronoid process. No osteoarthritis is present. The circles demonstrate obvious sclerosis in the affected elbow (left), while no sclerosis is visible in the normal joint (right).



**Figure 7.** Fragmentation of the medial coronoid process seen on CT. The left image shows an elbow with FCP. The white arrow indicates the detached fragment. The right image shows a normal elbow.

R= radius, U= ulna, MCP= medial coronoid process, FCP= fragmented coronoid process.



**Figure 8.** Arthroscopic image of an elbow joint affected with FCP (left) and a normal elbow (right). The red arrows indicate the fragmentation.

MHC= medial part of the humeral condyle, LHC= lateral part of the humeral condyle, R= radial head, MCP= medial coronoid process of the ulna.

## OSTEOCHONDRITIS DISSECANS

### Etiology

The exact etiology of OCD remains unclear, but a combination of genetics, age, increased birth weight, sex, breed, growth speed and nutritional factors might influence the expression of the condition (Trostel *et al.*, 2002; Burton and Owen, 2008). OCD of the elbow is

a common orthopedic condition consisting of a localized cartilage detachment of the medial part of the humeral condyle in juvenile dogs (Houlton, 2006). In at least 12% of the cases, it appears simultaneously with FCP (Carpenter *et al.*, 1993; Burton and Owen, 2008). Most likely, OCD is caused by a disturbed endochondral ossification process (Trostel *et al.*, 2002; Ytrehus *et al.*, 2007) (Figure 9), leading to cartilage retention and the formation of a flap. In some cases, the flap tends to ossify (Fox *et al.*, 1983; Olsson, 1983; Kirberger and Fourie, 1998). Because of its location, it's not always easy to differentiate an OCD lesion from a kissing lesion (Olsson, 1983). Breeds with a high susceptibility are Chow chows, German shepherd dogs, Golden retrievers, Great Danes, Labrador retrievers, Newfoundlands and Rottweilers (LaFond *et al.*, 2002).

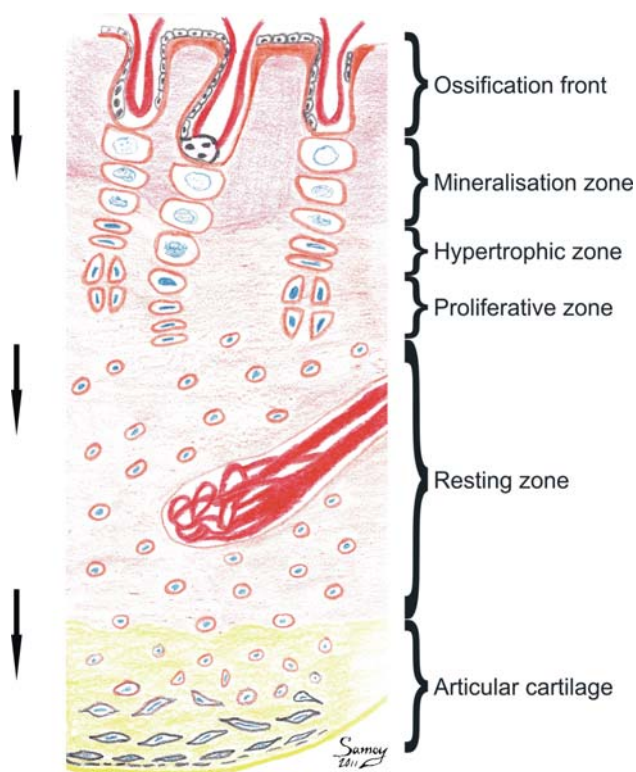
### Clinical signs

The clinical signs are very similar to those of FCP (Olsson, 1983; Kirberger and Fourie, 1998).

### Radiographic findings

OCD lesions are diagnosed on a 15° craniomedial-caudolateral oblique (pronated) view. The lesion appears from the age of five to six months, as a small, flattened or concave radiolucent lesion on the medial part of the humeral condyle (Boudrieau *et al.*, 1983) (Figure 10). Osteoarthritis or a sclerotic rim surrounding the lesion can be visible (Olsson, 1983; Kirberger and Fourie, 1998). A mediolateral projection can show a flattening of the caudal part of the humeral trochlea (Kirberger and Fourie, 1998). When OCD is accom-





**Figure 9.** Schematic drawing of endochondral ossification. Cartilage formation occurs in the direction of the arrows. In the immature animal, the invasion of cartilage by blood vessels is necessary to provide a normal endochondral ossification. A disruption of this blood flow leads to a disturbed ossification and eventually to an OCD lesion.

panied by FCP, radiographic changes of the medial coronoid process can also be present.

### CT findings

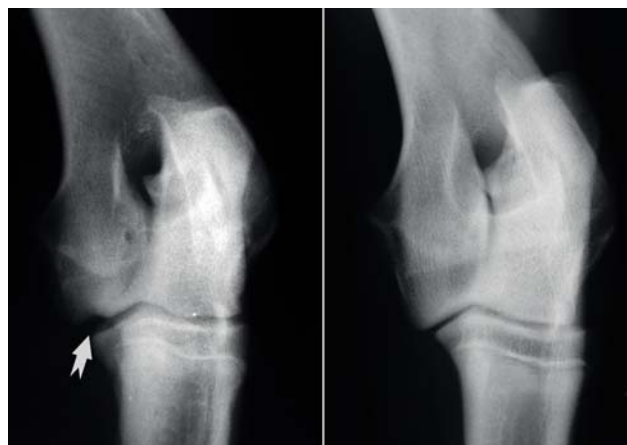The OCD lesion is characterized by a sclerotic area surrounding a region with diminished opacity on the (medial) humeral condyle. (Gielen *et al.*, 2009) (Figure 11).

### Arthroscopic findings

Arthroscopy allows the detection of the flap and simultaneous treatment (van Bree and Van Ryssen, 1995; van Bree and Van Ryssen, 1997; Van Ryssen and van Bree, 1997; van Bree and Van Ryssen, 1998) The localized pathologic cartilage of the medial part of the humeral condyle can still be attached, or partially or fully detached (Van Ryssen and van Bree, 1997) (Figure 12).

### Treatment

In cases where only small lesions are visible, a conservative treatment might be considered. In all other cases, surgical removal of the flap is advised, preferably via arthroscopy (Fox *et al.*, 1983; Walde and Tellhelm, 1991; Van Ryssen and van Bree, 1997; Kir-



**Figure 10.** Radiographic features of elbow OCD. The left radiograph shows an elbow affected with OCD. The arrow indicates the defect caused by an OCD lesion. The right radiograph is a normal elbow.

berger and Fourie, 1998). Since OCD and FCP tend to occur together, a thorough inspection of the joint is advised when treating one of both lesions (Burton and Owen, 2008). Although only limited information is available on long-term treatment results of elbow OCD, the prognosis can be considered good if early diagnosis and treatment are performed (Waelbers, 2001; Spillebeen, 2011).

## ELBOW INCONGRUITY

### Etiology

The exact impact of elbow incongruity is not yet fully understood. In both human and canine cases, reports have been made on physiological incongruity to optimize stress distribution in the fully loaded joint (Eckstein *et al.*, 1993; Preston *et al.*, 2001; Gemmill *et al.*, 2005). Two pathological types of incongruity have been described. The first is called short radius or short ulna incongruity and is caused by a disturbed growth of the distal ulnar or radial growth plate due to trauma or metabolic disorders. This leads to a short radius or short ulna. In some cases, severe limb deformity develops together with valgus or varus and severe elbow and carpal deformation (Theyse *et al.*, 2005; Samoy *et al.*, 2006). The second type of incongruity is the malformed elliptic shape of the trochlear notch of the ulna, which is caused by a difference in growth rate between the proximal part of the ulna and the humeral condyle. The slower growth of the proximal ulna results in a smaller trochlear notch that impinges the humeral trochlea. This last condition is often seen in the Bernese mountain dogs (Wind, 1986; Wind and Packard, 1986). Incongruity is visible as from the age of four to six months (Morgan *et al.*, 2003).

### Clinical signs

Because of the frequent concurrent finding of other forms of elbow dysplasia (FCP, UAP, OCD), it is impossible to link lameness uniquely to elbow incon-

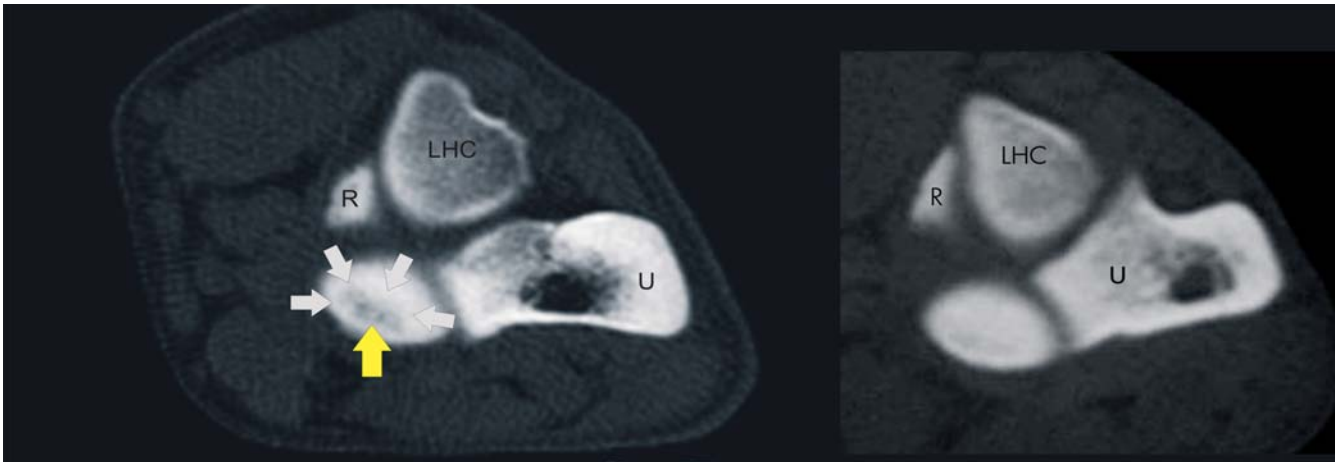


Figure 11. CT image of an elbow affected with OCD on the medial part of the humeral condyle. The white arrows indicate the sclerotic region around the OCD lesion. The yellow arrow shows the OCD lesion. The right image is a normal elbow joint.

LHC= lateral part of the humeral condyle, R= radial head, U= ulna.

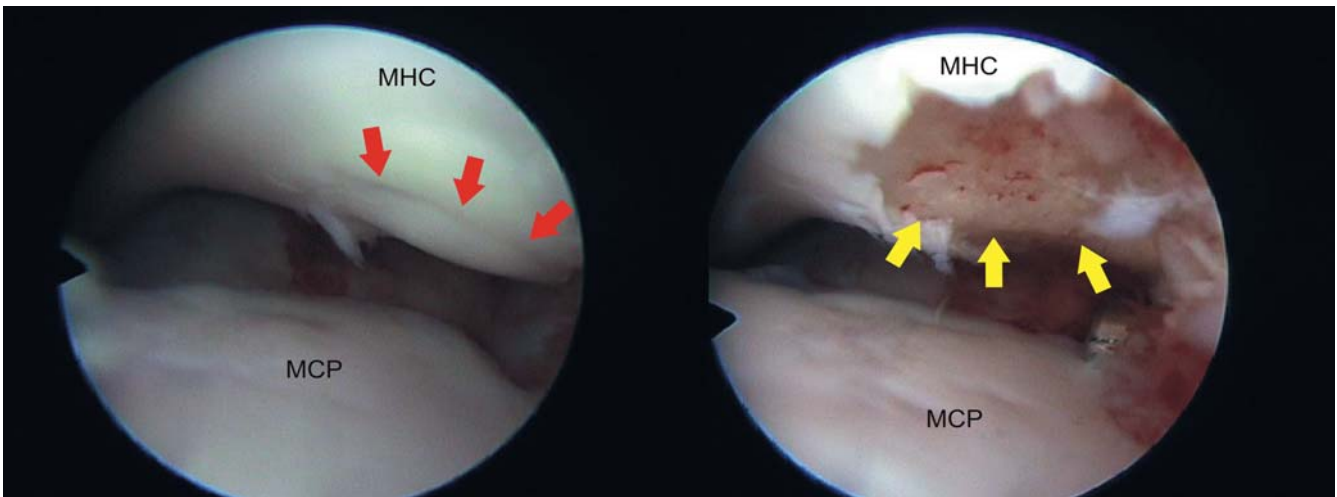


Figure 12. Arthroscopic images of an elbow affected with OCD. The red arrows on the left image indicate the location of the cartilage flap. The yellow arrows on the right image show the region after arthroscopic cartilage flap removal. Notice the petechial bleedings in the subchondral bone on the right image after curettage.

MCP= medial coronoid process, MHC= medial part of the humeral condyle.

gruity. The clinical signs are similar to the ones in other types of dysplastic elbows: lameness, joint distension, pain and muscle atrophy. The degree of incongruity also plays a role in the nature of the lameness. Severe incongruity is more likely to cause radiographic changes and coronoid pathology than mild forms of incongruity (Morgan *et al.*, 2003; Samoy *et al.*, 2006).

### Radiographic signs

Although incongruity is not always easy to detect on radiography (Blond *et al.*, 2005; Mason *et al.*, 2005), four typical features have been described on the standard mediolateral extended and the craniocaudal projections: a radio-ulnar step, an elliptic shape of the trochlear notch, an increased humero-ulnar and humero-radial joint space and a cranial displacement of the humeral condyle (Wind, 1986) (Figure 13).

The correlation between the severity of the incon-

gruity and the degree of secondary osteoarthritis is good (Keller *et al.*, 1997).

### CT findings

Several signs for incongruity have been described on CT (Gemmill *et al.*, 2005; Gemmill *et al.*, 2006; Samoy *et al.*, 2011). The most frequently seen features are shown in Figure 14.

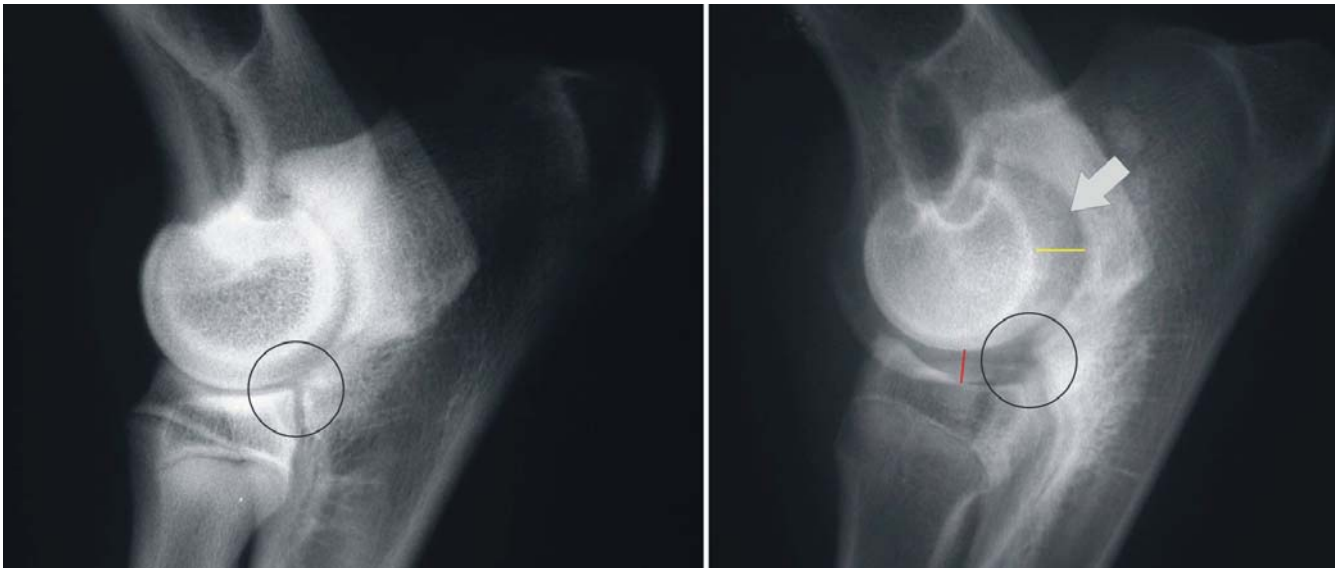### Arthroscopic findings

Arthroscopy allows the direct visualization of the level differences between radius and ulna. Additionally, typical changes are present in more severely incongruent joints (Samoy *et al.*, 2011) (Figure 15).

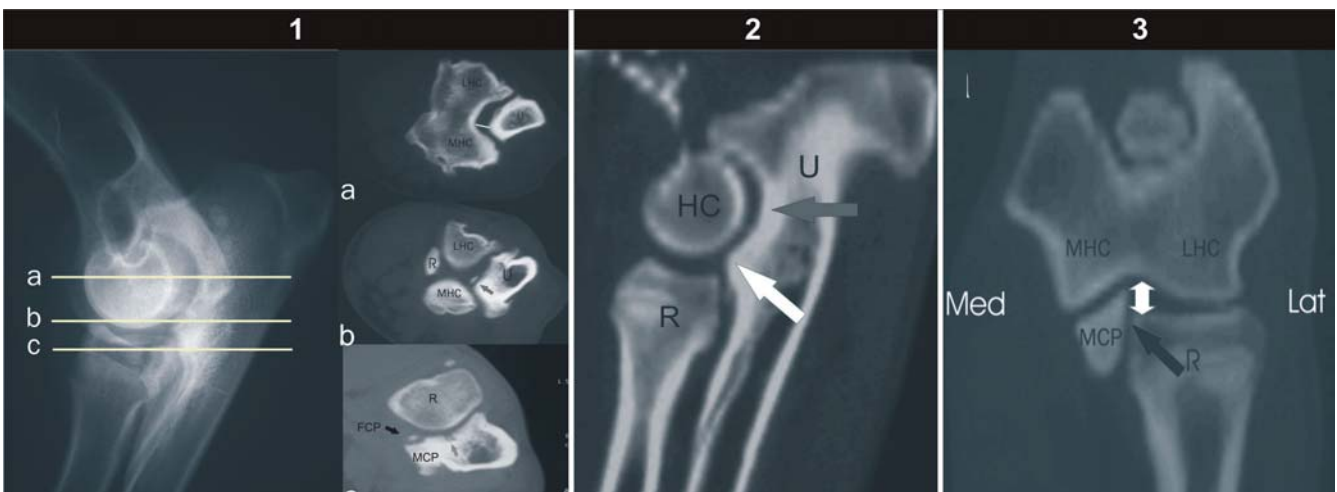### Treatment

Since incongruity is often accompanied by other el-





**Figure 13.** Radiographic features of elbow incongruity. The left image shows a severely incongruent elbow joint. The white arrow indicates the increased humero-ulnar joint space and the elliptic shape of the trochlear notch. The circle indicates a clear step between the distal border of the ulna and the radial head. Cranial displacement of the humeral condyle is seen as the relative position of the condyle to the radius and ulna. The yellow line indicates widening of the humero-ulnar joint space. The red line demonstrates the widening of the humeroradial joint space. The right image shows a normal elbow joint.



**Figure 14.** Location and comparison of the transverse (left), sagittal reconstruction (middle) and dorsal reconstruction (right) CT images in an incongruent elbow. The X-ray on the utter left shows the level of the corresponding CT images.

*Transverse slices*

Level a. Slice through the humeral condyle(s) (lateral = LHC, medial = MHC) and the trochlear notch of the ulna (U). The white line indicates the widened joint space between the humerus and the ulna where the measurement was made.  
 Level b. Transverse slice through the distal part of the trochlear notch. On this level, the proximal part of the radial head (R) is visualized. Fragmentation is indicated by the arrow.  
 Level c. Slice through the medial coronoid process (MCP) and the radial head (R). This view shows the radio-ulnar transition and visualizes the fragmented coronoid process (FCP) (black and white arrows) and the pseudocystic lesion (grey arrow).

*Sagittal reconstruction*

The white arrow shows the step between radius and ulna. The black arrow indicates the widened joint space between the humerus and the trochlear notch. Also note the widening of the humeroradial joint space.

*Dorsal reconstruction*

The black arrow indicates the step between the radius and the medial coronoid process. The double white arrow shows the abnormal medial humeroradial joint space.

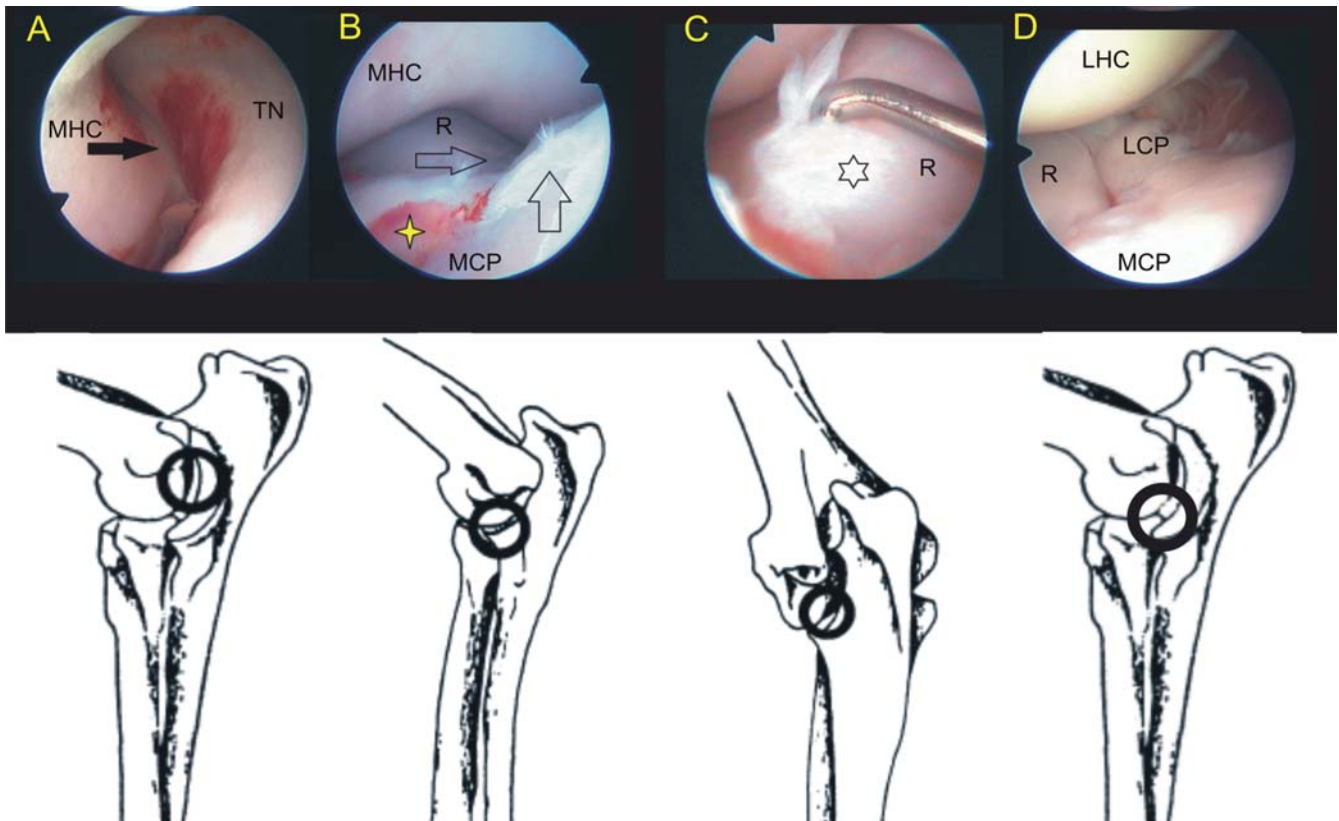


Figure 15. Arthroscopic features in an incongruent elbow. The drawings below the arthroscopic images show their locations (Samoy *et al.*, 2011).

bow pathologies, treatment should also involve these lesions.

There are several types of treatment of elbow incongruity (Samoy *et al.*, 2006). A proximal ulnectomy is the most commonly used technique to solve IC. The goal of this procedure is to relieve the pressure in the joint by tilting of the ulna. Radial lengthening shows similar results as a proximal ulnotomy. Although it was suggested as a good alternative for an ulnotomy, this technique is currently rarely used (Slocum and Pheil, 2004). Coronoidectomy has been described by one author (Puccio *et al.*, 2003).

A recent study describes the results of arthroscopic removal of the coronoid process without correction of the incongruity (Samoy *et al.*, 2011).

## CONCLUSION

Until now, elbow dysplasia has remained one of the most commonly diagnosed causes of front limb lameness (Kirberger and Fourie, 1998). Elbow dysplasia is a polygenetic, hereditary, developmental disease, which can be controlled by selective breeding. The susceptible breeds are well-known and the screening of these dogs is highly recommended, especially because not all of the affected dogs show lameness (LaFond *et al.*, 2002; Morgan *et al.*, 2003). Although treatment is often successful, the owner should be aware that the affected joint(s) remain(s) vulnerable and that this might interfere with later athletic activity (Kirberger and Fourie, 1998; Morgan *et al.*, 2003). Because of the sim-

ilar clinical signs, it is not always easy to differentiate the types of elbow dysplasia from each other. Other pathologies such as panosteitis and shoulder OCD, should also be considered in the differential diagnosis of front limb lameness (Fox *et al.*, 1983; Meyer-Lindenberg *et al.*, 2006). Thorough clinical and radiographic examination is needed to reach a proper diagnosis. In some cases, radiographic examination is not sufficient and other techniques such as computer tomography or arthroscopy, are needed to come to a definitive diagnosis. Although surgical treatment is the preferred treatment method, the owners should be warned that the affected joint(s) remain(s) vulnerable and that this might interfere with later athletic activity (Kirberger and Fourie, 1998; Morgan *et al.*, 2003).

## REFERENCES

- Berzon J. L. and Quick C. B. (2006). Fragmented coronoid process: anatomical, clinical and radiographic considerations with case analyses. *Journal of the American Animal Hospital Association* 16, 241-251
- Blond L., Dupuis J., Beauregard G., Breton L., Moreau M. (2005). Sensitivity and specificity of radiographic detection of canine elbow incongruence in an in vitro model. *Veterinary Radiology and Ultrasound* 46, 210-216
- Boudrieau R. J., Hohn R. B., Bardet J. F. (1983). Osteochondritis dissecans of the elbow in the dog. *Journal of the American Animal Hospital Association* 19, 627-635
- Braden T. D., Stickle R. L., DeJardin L. M., Mostosky U. V. (1994). The use of computed-tomography in fragmented

- coronoid disease - a case-report. *Veterinary and Comparative Orthopaedics and Traumatology* 7, 40-44
- Breit S., Kunzel W., Seiler S. (2004). Variation in the ossification process of the anconeal and medial coronoid processes of the canine ulna. *Research in Veterinary Science* 77, 9-16
- Burton N. and Owen M. (2008). Canine elbow dysplasia I. aetiopathogenesis and diagnosis. *In Practice* 30, 508-512
- Burton N. J., Comerford E. J., Bailey M., Pead M. J. and Owen M. R. (2007). Digital analysis of ulnar trochlear notch sclerosis in Labrador retrievers. *Journal of Small Animal Practice* 48, 220-224
- Burton N. J., Toscano M. J., Barr F. J., Owen M. R. (2008). Reliability of radiological assessment of ulnar trochlear notch sclerosis in dysplastic canine elbows. *Journal of Small Animal Practice* 49, 572-576
- Carpenter L. G., Schwarz P. D., Lowry J. E., Park R. D., Steyn P. F. (1993). Comparison of radiologic imaging techniques for diagnosis of fragmented medial coronoid process of the cubital joint in dogs. *Journal of the American Veterinary Medical Association* 203, 78-83
- Danielson K. C., Fitzpatrick N., Muir P., Manley P. A. (2006). Histomorphometry of fragmented medial coronoid process in dogs: a comparison of affected and normal coronoid processes. *Veterinary Surgery* 35, 501-509
- De Rycke L. M., Gielen I. M., Van B. H., Simoens P. J. (2002). Computed tomography of the elbow joint in clinically normal dogs. *American Journal of Veterinary Research* 63, 1400-1407
- Eckstein F., Lohe F., Schulte E., Muller-Gerbl M., Milz S., Putz R. (1993). Physiological incongruity of the humero-ulnar joint: a functional principle of optimized stress distribution acting upon articulating surfaces? *Anatomy and Embryology* 188, 449-455
- Evans R. B., Gordon-Evans W. J., Conzemius M. G. (2008). Comparison of three methods for the management of fragmented medial coronoid process in the dog. A systematic review and meta-analysis. *Veterinary and Comparative Orthopaedics and Traumatology* 21, 106-109
- Fitzpatrick N. (2010). How I treat medial compartment disease. In: *3rd World Veterinary Orthopaedic Congress*, September 15th - 18th, 2010, Bologna (Italy), 363-365
- Fox S. M., Bloomberg M. S., Bright R. M. (1983). Developmental anomalies of the canine elbow. *Journal of the American Animal Hospital Association* 19, 605-615
- Frazho J. K., Graham J., Peck J. N., De Haan J. J. (2010). Radiographic evaluation of the anconeal process in skeletally immature dogs. *Veterinary Surgery* 39, 829-832
- Gemmill T. J. and Clements D. N. (2007). Fragmented coronoid process in the dog: is there a role for incongruity? *Journal of Small Animal Practice* 48, 361-368
- Gemmill T. J., Hammond G., Mellor D., Sullivan M., Bennett D., Carmichael S. (2006). Use of reconstructed computed tomography for the assessment of joint spaces in the canine elbow. *Journal of Small Animal Practice* 47, 66-74
- Gemmill T. J., Mellor D. J., Clements D. N., Clarke S. P., Farrell M., Bennett D., Carmichael S. (2005). Evaluation of elbow incongruity using reconstructed CT in dogs suffering fragmented coronoid process. *Journal of Small Animal Practice* 46, 327-333
- Gielen G., Van Ryssen B., van Bree H. (2009). Computed tomographic (CT) features of elbow OCD compared with radiography and arthroscopy. In: *36th Annual Conference Veterinary Orthopedic Society*. February 28 - March 6 2009, Steamboat Springs, Colorado, 21
- Grondalen J. (1979). Arthrosis in the elbow joint of young rapidly growing dogs. III. Ununited medial coronoid process of the ulna and osteochondritis dissecans of the humeral condyle. Surgical procedure for correction and postoperative investigation. *Nordisk Veterinaermedicin* 31, 520-527
- Grondalen J. and Lingaas F. (1991). Arthrosis in the elbow joint of young rapidly growing Dogs - a Genetic Investigation. *Journal of Small Animal Practice* 32, 460-464
- Grussendorf C., Grussendorf H., Funcke C. (2008). Minimal invasive arthroscopic removal of ununited anconeal process. In: *14th ESVOT Congress*. 10 - 14 September 2008, Munich, Germany,
- Hazewinkel H. A., Kantor A., Meij B. (1988). Loose anconeal process. *Tijdschrift voor Diergeneeskunde* 113 Suppl 1, 47S-49S
- Hornof W. J., Wind A. P., Wallack S. T., Schulz K. S. (2000). Canine elbow dysplasia. The early radiographic detection of fragmentation of the coronoid process. *Veterinary Clinics of North America. Small Animal Practice* 30, 257-266
- International Elbow Working Group Protocol. (1995). *Veterinary Radiology & Ultrasound* 36, 172-173
- Janutta V., Hamann H., Klein S., Tellhelm B., Distl O. (2006). Genetic analysis of three different classification protocols for the evaluation of elbow dysplasia in German shepherd dogs. *Journal of Small Animal Practice* 47, 75-82
- Keller G. G., Kreeger J. M., Mann F. A., Lattimer J. C. (1997). Correlation of radiographic, necropsy and histologic findings in 8 dogs with elbow dysplasia. *Veterinary Radiology and Ultrasound* 38, 272-276
- Kirberger R. M. and Fourie S. L. (1998). Elbow dysplasia in the dog: pathophysiology, diagnosis and control. *Journal of the South African Veterinary Association* 69, 43-54
- Kramer A. L., Holsworth I. G., Wisner E. R., Kass P. H., Schulz K. S. (2006). Computed tomographic evaluation of canine radioulnar incongruence in vivo. *Veterinary Surgery* 35, 24-29
- LaFond E., Breur G. J., Austin C. C. (2002). Breed susceptibility for developmental orthopedic diseases in dogs. *Journal of the American Animal Hospital Association* 38, 467-477
- Mason D. R., Schulz K. S., Fujita Y., Kass P. H., Stover S. M. (2005). In vitro force mapping of normal canine humeroradial and humeroulnar joints. *American Journal of Veterinary Research* 66, 132-135
- Mason D. R., Schulz K. S., Samii V. F., Fujita Y., Hornof W. J., Herrgesell E. J., Long C. D., Morgan J. P., Kass P. H. (2002). Sensitivity of radiographic evaluation of radio-ulnar incongruence in the dog in vitro. *Veterinary Surgery* 31, 125-132
- Meyer-Lindenberg A., Fehr M., Nolte I. (2006). Co-existence of ununited anconeal process and fragmented medial coronoid process of the ulna in the dog. *Journal of Small Animal Practice* 47, 61-65
- Meyer-Lindenberg A., Langhann A., Fehr M., Nolte I. (2002). Prevalence of fragmented medial coronoid process of the ulna in lame adult dogs. *Veterinary Record* 151, 230-234
- Morgan J. P., Wind A., Davidson A. P. (1999). Bone dysplasias in the labrador retriever: a radiographic study. *Journal of the American Animal Hospital Association* 35, 332-340
- Ness M. G. (1998). Treatment of fragmented coronoid process in young dogs by proximal ulnar osteotomy. *Journal of Small Animal Practice* 39, 15-18
- Olsson S. E. (1983). The early diagnosis of fragmented coronoid process and osteochondrosis dissecans of the canine elbow joint. *Journal of the American Animal Hospital Association* 19, 616-626



- Preston C. A., Schulz K. S., Taylor K. T., Kass P. H., Hagan C. E., Stover S. M. (2001). In vitro experimental study of the effect of radial shortening and ulnar osteotomy on contact patterns in the elbow joint of dogs. *American Journal of Veterinary Research* 62, 1548-1556
- Puccio M., Marino D. J., Stefanacci J. D., McKenna B. (2003). Clinical evaluation and long-term follow-up of dogs having coronoidectomy for elbow incongruity. *Journal of the American Animal Hospital Association* 39, 473-478
- Robin D. and Marcellin-Little D. J. (2001). Incomplete ossification of the humeral condyle in two Labrador retrievers. *Journal of Small Animal Practice* 42, 231-234
- Rovesti G. L., Fluckiger M., Margini A., Marcellin-Little D. J. (1998). Fragmented coronoid process and incomplete ossification of the humeral condyle in a rottweiler. *Veterinary Surgery* 27, 354-357
- Samoy Y., de Bakker E., Van Vynckt D., Coppieters E., Van Ryssen B. (2011). Long term follow-up after the arthroscopic treatment of medial coronoid disease in dogs with severe elbow incongruity. *Veterinary and Comparative Orthopaedics and Traumatology*. In press.
- Samoy Y., Gielen G., Van Caelenberg A., van Bree H., Duchateau L., Van Ryssen B. (2011). Computed Tomography findings in 32 joints affected by severe elbow incongruity with concomitant fragmented medial coronoid process. *Veterinary Surgery*. In press.
- Samoy Y., Van Ryssen B., Gielen I., Walschot N., van Bree H. (2006). Review of the literature: elbow incongruity in the dog. *Veterinary and Comparative Orthopaedics and Traumatology* 19, 1-8
- Samoy Y., Van Ryssen B., Van Caelenberg A., Peremans K., Gielen I., van Bree H. (2005). An atypical case of fragmented medial coronoid process in a dog. *Vlaams Diergeneeskundig Tijdschrift* 74, 154-161
- Samoy Y., Van Vynckt D., Gielen G., van Bree H., Duchateau L., Van Ryssen B. (2011). Arthroscopic findings in 32 joints affected by severe elbow incongruity with concomitant fragmented medial coronoid process. *Veterinary Surgery*. In press.
- Slocum B. and Pheil I. (2004). Radius elongation for pressure relief of the coronoid process of the ulna. In: *12th ESVOT Congress*. 10 - 12 September 2004, Munich, 259
- Snaps F. R., Balligand M. H., Saunders J. H., Park R. D., Dondelinger R. F. (1997). Comparison of radiography, magnetic resonance imaging, and surgical findings in dogs with elbow dysplasia. *American Journal of Veterinary Research* 58, 1367-1370
- Spillebeen A. (2011). OCD van de elleboog: diagnostische bevindingen en resultaat na behandeling. *Vakgroep Medische Beeldvorming van de Huisdieren en Orthopedie van de Kleine Huisdieren*, Universiteit Gent, Merelbeke
- Theyse L. F. H., Voorhout G., Hazewinkel H. A. W. (2005). Prognostic factors in treating antebrachial growth deformities with a lengthening procedure using a circular external skeletal fixation system in dogs. *Veterinary Surgery* 34, 424-435
- Thomson M. J. and Robins G. M. (1995). Osteochondrosis of the elbow: a review of the pathogenesis and a new approach to treatment. *Australian Veterinary Journal* 72, 375-378
- Tirgari M. (1974). Clinical radiographical and pathological aspects of arthritis of the elbow joint in dogs. *Journal of Small Animal Practice* 15, 671-679
- Trostel C. T., McLaughlin R. M., Pool R. R. (2002). Canine lameness caused by developmental orthopedic diseases: osteochondrosis. *Compendium on Continuing Education for the Practicing Veterinarian* 24, 831-856
- van Bree H. and Van Ryssen B. (1995). Arthroscopy in the diagnosis and treatment of front leg lameness. *Veterinary Quarterly* 17 Suppl 1, S32-S34
- van Bree H. J. and Van Ryssen B. (1998). Diagnostic and surgical arthroscopy in osteochondrosis lesions. *Veterinary Clinics of North America. Small Animal Practice* 28, 161-189
- van Bree H. J. and Van Ryssen B. (1997). Value of arthroscopy in the diagnosis and treatment of osteochondrosis in dogs. *Tijdschrift voor Diergeneeskunde* 122, 710-714
- Van Ryssen B. (2001). Role of arthroscopy in elbow diseases in the dog. In: *Proceedings 12th International Small Animal Arthroscopy Workshop*.
- Van Ryssen B. and van Bree H. (1997). Arthroscopic findings in 100 dogs with elbow lameness. *Veterinary Record* 140, 360-362
- Van Ryssen B., van Bree H., Simoens P. (1993). Elbow arthroscopy in clinically normal dogs. *American Journal of Veterinary Research* 54, 191-198
- Vermote K. A., Bergenhuysen A. L., Gielen I., van Bree H., Duchateau L., Van Ryssen B. (2010). Elbow lameness in dogs of six years and older. *Veterinary and Comparative Orthopaedics and Traumatology* 23, 43-50
- Waelbers T. (2001). Arthroscopie bij OCD van de elleboog bij de hond: bevindingen en resultaat na behandeling. *Vakgroep Medische Beeldvorming van de Huisdieren en Orthopedie van de Kleine Huisdieren*, Universiteit Gent, Merelbeke
- Walde I. and Tellhelm B. (1991). Fragmented medial coronoid process of the ulna (FCP) and osteochondritis dissecans (OCD) of the canine elbow and hock joint: a review of literature, diagnosis and therapy. *Wiener Tierärztliche Monatsschrift* 78, 414-421
- Wind A. P. (1986). Elbow incongruity and developmental elbow diseases in the dog: Part I. *Journal of the American Animal Hospital Association* 22, 712-724
- Wind A. P. and Packard M. E. (1986). Elbow incongruity and developmental elbow diseases in the dog: part II. *Journal of the American Animal Hospital Association* 22, 725-730
- Wosar M. A., Lewis D. D., Neuwirth L., Parker R. B., Spencer C. P., Kubilis P. S., Stubbs W. P., Murphy S. T., Shiroma J. T., Stallings J. T., Bertrand S. G. (1999). Radiographic evaluation of elbow joints before and after surgery in dogs with possible fragmented medial coronoid process. *Journal of the American Veterinary Medical Association* 214, 52-58
- Ytrehus B., Carlson C. S., Ekman S. (2007). Etiology and pathogenesis of osteochondrosis. *Veterinary Pathology* 44, 429-448