

## Sutureless replacement of aortic valves with St Jude Medical mechanical valve prostheses and Nitinol attachment rings: Feasibility in long-term (90-day) pig experiments

Eric Berreklouw, MD, PhD,<sup>a</sup> Bart Koene, MD,<sup>a</sup> Filip De Somer, PhD,<sup>b</sup> Stefaan Bouchez, MD,<sup>b</sup> Koen Chiers, DMV, PhD,<sup>c</sup> Yves Taeymans, MD, PhD,<sup>b</sup> and Guido J. Van Nooten, MD, PhD<sup>b</sup>

**Objective:** Nitinol attachment rings (devices) used to attach mechanical aortic valve prostheses suturelessly were studied in long-term (90 days) pig experiments.

**Methods:** The aortic valve was removed and replaced by a device around a St Jude Medical mechanical valve prosthesis in 10 surviving pigs. Supravalvular angiography was done at the end of the operation. No coumarin derivatives were given.

**Results:** No or minimal aortic regurgitation was confirmed in all surviving pigs at the end of the operation. Total follow-up was 846 days. In 4 pigs, follow-up was shorter than 90 days (28–75 days); the other 6 pigs did reach 90 days' survival or more. Repeat angiography in 4 pigs at the end of follow-up confirmed the unchanged position of the device at the aortic annulus, without aortic regurgitation. At autopsy, in all pigs the devices proved to be well grown in at the annulus, covered with endothelium, and sometimes tissue overgrowth related to not using coumarin derivatives. There was no case of para-device leakage, migration, or embolization. No damage to surrounding anatomic structures or prosthetic valves was found.

**Conclusions:** Nitinol attachment rings can be used to replace the aortic valve suturelessly with St Jude Medical mechanical aortic valve prostheses, without para-device leakage, migration, or damage to the surrounding tissues, in long-term pig experiments during a follow-up of 90 days or more. Refraining from anticoagulation in pigs with mechanical valve prostheses can lead to tissue overgrowth of the valve prosthesis. Further studies are needed to determine long-term feasibility of this method in human beings. (*J Thorac Cardiovasc Surg* 2011;141:1231-7)

Supplemental material is available online.



Video clip is available online.

Hand-suturing is the current standard for attaching an aortic valve prosthesis to the anatomic aortic valve annulus. However, it consumes a relatively great deal of time, particularly in multivalve and combined procedures, and makes mini-

mally invasive valve surgery less favorable. The first valve prosthesis implanted in the human being by Hufnagel in 1952 (as reported by Hufnagel and Harvey<sup>1</sup>) was a sutureless valve, and sutureless Magovern–Cromie valves were used for aortic and mitral valve replacements for many years.<sup>2</sup> Currently, there is renewed interest in sutureless aortic valve implantation, mostly by mounting a biological aortic valve into a metal stent and compressing it into a catheter sleeve.<sup>3–8</sup> However, with this technique the diseased valve is not removed, and current valved stents do not yet result in early outcomes comparable with surgically removed and replaced heart valves.<sup>9,10</sup> Previously, we<sup>11</sup> have shown that it is feasible to use Nitinol attachment rings to attach mechanical aortic valve prostheses solidly to the aortic valve annulus after removal of the original aortic valve in acute pig studies and that such rings can withstand a high pulling force.<sup>11</sup> Our intention with this study was to investigate the long-term (90-day) outcome in pigs of using such Nitinol attachment rings to suturelessly replace the aortic valve by a St Jude Medical mechanical aortic valve prosthesis (St Jude Medical, Inc, Minneapolis, Minn) approved by the Food and Drug Administration (FDA).

### MATERIALS AND METHODS

After extensive ex vivo and short-term in vivo testing,<sup>11</sup> long-term in vivo experiments were performed in pigs from February 2007 until June

From Cardio-thoracic Surgery,<sup>a</sup> Catharina Hospital, Eindhoven, The Netherlands; Laboratory Experimental Cardiac Surgery,<sup>b</sup> UGent, Ghent, Belgium; and Laboratory of Veterinary Pathology,<sup>c</sup> UGent, Merelbeke, Belgium.

Some parts of the prototypes of the rings and applicators were provided by Endosmart GmbH (Stutensee, Germany), St Jude Medical (Minneapolis, Minn), Vascutek-Terumo (Renfrewshire, Scotland), Jotec GmbH (Hechingen, Germany), Kiki GmbH (Malsch, Germany), and Edwards Lifesciences Ltd (Irvine, Calif).

Disclosures: Authors have nothing to disclose with regard to commercial support. Received for publication March 30, 2010; revisions received June 13, 2010; accepted for publication July 3, 2010; available ahead of print Aug 23, 2010.

Address for correspondence: Eric Berreklouw, MD, PhD, Department of Cardio-thoracic Surgery, Catharina Hospital, P.O. Box 1350, 5602 ZA, Eindhoven, The Netherlands. Phone +31-40-2398680, Fax +31-40-2440268 (E-mail: berreklouw@gmail.com).

0022-5223/\$36.00

Copyright © 2011 by The American Association for Thoracic Surgery  
doi:10.1016/j.jtcvs.2010.07.014

### Abbreviations and Acronyms

FDA = Food and Drug Administration  
 LV = left ventricular  
 LVH = left ventricular hypertrophy  
 VAR = valve attachment ring

2009 (Figure E1) with Nitinol sutureless attachment rings around suturing-denuded 19- or 21-mm FDA-approved St Jude Medical demo mechanical aortic valve prostheses (device pigs). In the last experiments the aortic valve was replaced by an unchanged 19-mm FDA-approved St Jude Medical demo mechanical aortic valve prosthesis using standard hand-suturing techniques (control pigs). The follow-up of the surviving 10 device and 1 control pigs ended in September 2009 and is described in more details.

### Devices, Stretching, and Activation

The proprietary valve attachment rings (VARs) were manufactured from Nitinol memory metal (Endosmart GmbH, Stutensee, Germany) and had a sinusoidal shape with a flexible upper and lower flange. The bare Nitinol ring was almost completely covered by textile (Jotec GmbH, Hechingen, Germany), while maintaining full valve rotatability (Figure 1, A and B, Video E1). After sterilization, the device was mounted on the applicator, and the flanges were manually stretched in iced saline. Unintended early expansion during navigation at room temperature was prevented by placement of 1 to 3 stretching sutures through the textile covering of the flanges and fixation to the applicator, which was kept in iced saline until its use. After positioning and rewarming, the ring fixed itself by clamping the valve annulus tissue between its upper and lower flanges. In the first 5 pigs in the device group, 21-mm St Jude mechanical aortic valve prostheses were used, and in the last 5, 19-mm St Jude mechanical aortic valve prostheses were used. VARs with a fixed upper flange and a flexible lower flange were also developed, with the advantage that larger unchanged mechanical or biological valve prostheses can be mounted on top of such rings (Figure E2, A and B, Video E2). A fixed upper flange can work as a self-blocking mechanism to facilitate "blind" navigation of the VAR to the annulus. However, in this series of experiments only rings with flexible upper and lower flanges were used.

### Applicators

In 7 cases the device was mounted on an applicator with 2 separate holding arms (Kiki Ingenieurgesellschaft GmbH, Malsch, Germany) (Figure 2, A). In 1 case an applicator was used with a temperature-regulating fluid-recirculating closed circuit (Technical University Delft, Delft, The Netherlands) (Figure 2, B). Although this recirculating applicator proved feasible, it was not used more frequently because its large heads were obliterating the surgical view and damaging the aorta. Finally, a simple holding applicator was developed and used in 2 later cases, consisting of a holder with a ring sutured on top of the valve housing (Instrumentation Department, Catharina Hospital, Eindhoven, The Netherlands) (Figure 2, C).

### Surgical Procedures and Postoperative Investigations

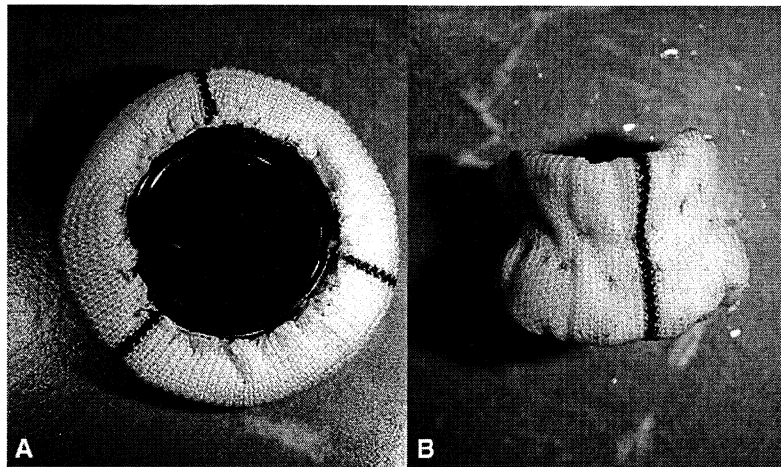
In anesthetized and ventilated young female pigs (mean weight, 74.8 kg; range, 68–77 kg), a median sternotomy was performed. After heparinization, the animal was placed on full bypass with arterial cannulation in the ascending aorta or aortic arch and venous cannulation with a single cannula through the right atrial appendage. Left ventricular (LV) decompression was achieved through the LV apex, the aorta was crossclamped, and a single shot of cold St Thomas' Hospital crystalloid cardioplegic solution was adminis-

tered. The aortic valve leaflets were completely removed. To compensate for mismatch between the diameter of the annulus and the device, having only one size prototype available per experiment, and the annular diameter being variable and flexible in young and healthy pigs, we placed a single circular annular suture. Because the view inside the small aorta was hindered by the device and applicator, and to give the device its optimal rotation, we used guiding sutures to assist in navigating the device to the annulus. These sutures were placed in the middle of sinuses, led through the textile covering of the VAR upper flange, and pulled during its positioning. After positioning, the annular suture was pulled and tied, and the stretching sutures were cut and retracted. The device was activated by warm (about 45°C) sterile saline over the heart in 5 cases, by circulation of warm saline through a recirculating applicator in 1 case, and by flushing the aorta with warm sterile saline in 4 cases. During reperfusion, inotropic and antiarrhythmic drugs were given, as indicated. Heart and valve function were evaluated by transesophageal echocardiography before bypass, before weaning off bypass, and after bypass in the initial cases. Supravalvular angiography was performed after perfusion through one of the carotid arteries by a cardiologist and was repeated under anesthesia before the pig was humanely killed in cases that reached 90 days' survival. Aortic regurgitation was graded by an independent cardiologist (Guus Breuren, MD) as 0 if absent and 1+ to 4+ if present.<sup>12</sup> During follow-up, the only anticoagulation given was 160 mg of acetylsalicylic acid twice a day and 75 mg of clopidogrel once a day. All animals underwent an autopsy, including macroscopic and histologic examination of the heart and organs. Position and function of the device were determined from both sides, and paravalvular leakage was sought with a 1-mm probe. Tissue overgrowth was graded as 0 if not covering the VAR's textile, 1 if covering the VAR's textile but not the valve ostium, 2 if covering less than 25%, 3 between 25% and 50%, and 4 more than 50% of the valve ostium. All long-term animal tests were approved along the Animal Research Ethics regulations of the institution. The animals received care in compliance with the European Convention on Animal Care and the Guide for the Care and Use of Laboratory Animals, as published by the US National Institutes of Health (NIH Publication No. 85-23, revised 1996).

## RESULTS

### Procedures and Early Outcome

In 13 device experiments and 1 control experiment the animals did not survive the operation or the first 24 hours thereafter, for different or combined reasons. In 3 cases, we could not place the device because it was too large ( $n = 2$ ) or because a valve was damaged valve leaflet during loading ( $n = 1$ ). Device-pig mismatch initially occurred often, because only 1 relatively large (21-mm valve) prototype was available, with a relatively thick self-made textile covering, which made implantation of the device impossible or very difficult, with irreparable damage of the aorta. In 5 cases there were difficulties with the aortotomy, with bleeding, or with compromised right coronary artery flow by the aorta closing sutures. In 4 cases we deviated from the operative protocol by trying to omit stretching, guiding, or annular sutures. Other problems included wrong sterilization method of the device in 2, accidental removal of the aortic cannula in 1, and retroperitoneal bleeding in another case. Also, 1 control animal did not survive as a result of a prolonged procedure owing to poor exposure of the aortic valve. There has been no early operative death directly related to the presence or action of the device, once implanted correctly. In all non-surviving pigs in which the device could be implanted, the aortic annular position of the device has been confirmed

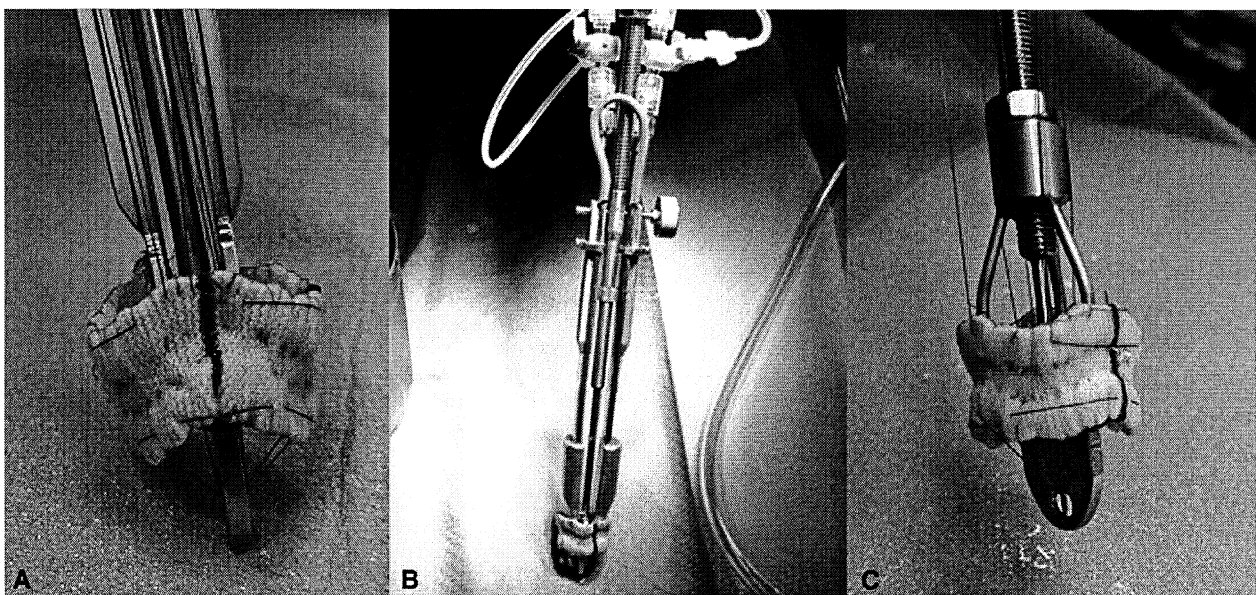


**FIGURE 1.** A, Suturing-denuded 19-mm St Jude Medical mechanical aortic valve prosthesis inside textile-covered Nitinol attachment ring with flexible upper and lower flange (device), in warm expanded shape (view from above). B, Same device as in A, in stretched cold shape (side view).

by supravalvular angiography and/or autopsy. In the long-term survivors, in 2 cases the flanges started to expand too early, and in 5 cases the aortotomy tore out, leading to its complicated closure. In 4 cases the temporary stretching sutures broke off when we attempted to retract them, and they could not be removed completely. Once the device was in place, the actuation with warm saline, or recirculating applicator, worked instantly in all cases. In the surviving pigs in the device group the average aortic crossclamp time was 49.2 minutes (range, 39–75 minutes), and the average perfusion time was 77.9 minutes (range, 54–122 minutes). Closing the aorta took at least 30 minutes in all cases.

#### Late Outcome

Among the 10 pigs surviving long term in the device group, the mean follow-up was 84.6 days (range, 28–148 days), with a total of 846 days, while 1 surviving control pig was followed up for 90 days (Table 1). Four device animals did not reach the predetermined 90 days' follow-up period. One pig was humanely killed after 28 days because of bacterial aortic valve endocarditis. One pig drowned accidentally after 62 days when it fell through a manhole cover. Two pigs were humanely killed because of congestive heart failure at 69 and 75 days. The other 6 device and 1 control pigs did reach the predetermined 90 days' follow-up period.



**FIGURE 2.** A, Applicator with 2 movable holding arms inside same device as in Figure 1, in stretched cold shape (side view). B, Recirculating fluid applicator with 2 movable holding arms inside same device as in Figure 1, in stretched cold shape (side view). C, Simple holding applicator sutured on top in the same device as in Figure 1, in stretched cold shape (side view).

TABLE 1. Outcome data

D/C	Preop weight (kg)	Grade AI			Survival (d)	Autopsy weight (kg)	Tissue overgrowth			
		Perop angio	Late angio	Cause of late death			Aortic side	LV side	LVH	Autopsy
D1	68	1	–	1	99	103	1	2	0	1
D2	75	0	1	1	91	120	2	3	1	2
D3	74	0	–	2	69	96	1	3	0	3
D4	70	1	1	1	148	99	1	2	0	0
D5	76	2	–	2	75	87	1	1	0	4
D6	77	1	–	3	62	100	2	1	0	0
D7	77	0	0	1	92	127	4	3	1	0
D8	68	1	–	4	28	75	1	1	1	5
D9	68	1	1	1	92	137	2	2	0	0
D10	72	2	1	1	90	125	1	2	0	0
C1	68	1	1	1	90	120	1	2	0	0

D, Device; C, control; AI, Aortic insufficiency; LV, left ventricular; LVH, left ventricular hypertrophy. Cause of death: 1 = humanely killed at end of follow-up, 2 = heart failure, 3 = accidental drowning, 4 = endocarditis. Autopsy: 0 = no gross abnormalities, 1 = large atrial septal defect, 2 = left ventricular and right ventricular hypertrophy, 3 = chronic heart failure with tissue overgrowth, 4 = chronic heart failure with broken stretching suture, 5 = endocarditis.

After initial recovery from surgery, all animals behaved and grew normally. There have been no signs of thromboembolic complications or other valve-related complications. The surviving pigs in the device group showed an average weight increase of 407 g per day, with mean weight of 122 kg around 90 days' survival.

#### Angiographic Examinations

In all device and control pigs (with the exception of 1 case in which it was technically not possible), supravalvular angiography was performed after weaning from bypass and confirmed that the device, with respect to the valve, was at its desired position at the aortic annulus and the coronary arteries were patent. Angiograms at surgery showed grade 0 aortic regurgitation in 3, grade 1+ in 5 (Figure 3, A), and grade 2+ in 2 surviving device pigs. It was not possible to differentiate whether regurgitation was caused by para-device leakage or by backflow through the demo valves used. In 4 of the device pigs and 1 control pig the supravalvular angiogram was repeated after 90 days of follow-up, just before

the animals were humanely killed. In all 4 of these device pigs, the late angiogram demonstrated an unchanged nonmigrated position of the device at the aortic annulus, with grade 0 regurgitation (Figure 3, B) in 1 case and grade 1+ regurgitation in 3 cases. The control pig did show grade 1+ regurgitation at the operation and when humanely killed. In 1 device pig, only fluoroscopy was performed when the animal was humanely killed, and this demonstrated an unchanged device position and normal valve blade movements (Table 1).

#### Pathologic Examinations

Autopsy of the pig with endocarditis that was humanely killed 28 days postoperatively showed a normal position of the device, with vegetations at the ventricular side of the valve prosthesis, but without para-device abscesses. There was left ventricular hypertrophy (LVH), likely caused by vegetations that almost obliterated the valve ostium from below. Autopsy of the drowned pig 62 days after the operation revealed no abnormalities of the device at its annular position. Postmortem examination of the 2 pigs with

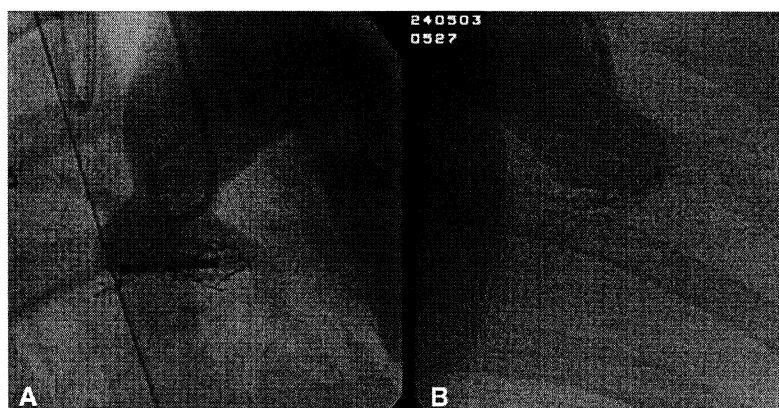
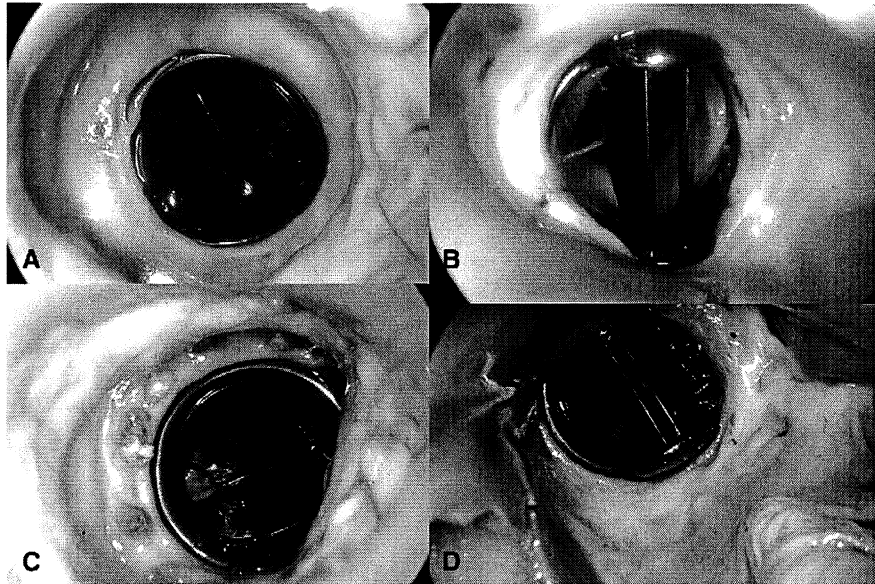


FIGURE 3. A, Peroperative supravalvular angiogram of device in aortic annular position, with grade 1+ aortic regurgitation. B, Supravalvular angiogram after 90 days, showing same device as in Figure 3, A, with grade 1+ aortic regurgitation.



**FIGURE 4.** A, Device after 94 days, from aortic side, with grade 1 tissue overgrowth. B, Same device as in Figure 4, A, from left ventricular side with grade 2 tissue overgrowth. C, Hand-sutured control valve, after 90 days, from aortic side with grade 1 tissue overgrowth. D, Same device as Figure 4, C, from left ventricular side with grade 2 tissue overgrowth.

congestive heart failure at 69 and 75 days after surgery showed normal position of the device in both. In 1 animal, grade 3 tissue overgrowth at the ventricular side was observed. In the other pig, a remaining piece of broken stretching suture was present, likely having caused aortic regurgitation. Neither animal demonstrated signs of LVH. At all autopsies, including those in the 4 pigs that did not reach 90 days' follow-up, the device remained well attached at its annular position without migration or para-device leakage. In all device cases, the textile around the VAR was covered with a layer of endothelial cells. The amount of tissue overgrowth was at the aortic side, grade 1 in 6 cases, grade 2 in 3 cases, and grade 4 in 1 case (Table 1 and Figure 4, A and B). From the LV side the tissue overgrowth was grade 1 in 3 cases, grade 2 in 4 cases, and grade 3 in 3 cases. The overgrowth was not more than grade 1 or 2 at the aortic side in 90% and at the LV side in 70% of the cases. Also, the control valve showed grade 1 tissue overgrowth at the aortic side and grade 2 at the LV side (Figure 4, C and D). It seemed that tissue overgrowth was more pronounced with an increasing duration of follow-up. Although the ostium of the valve prosthesis has been limited by tissue overgrowth in a number of cases, no intrinsic abnormalities were seen at the valve prosthesis or its leaflets. Signs of LVH were found in 3 pigs in the device group, with vegetations below the device in the pig with valvular endocarditis and in 2 pigs with more than grade 2 overgrowth at both sides of the device. In none of the device pigs was macroscopic damage found to surrounding tissues, including the coronary arteries, interventricular septum, and anterior mitral valve. No thromboemboli were found in the heart, vessels, or distal organs.

## DISCUSSION

This study demonstrates that Nitinol attachment rings around suture-denuded mechanical aortic valves remain well attached to the aortic valve annulus, without peri-device leakage or damage to the valve prosthesis or surrounding tissues, not only during acute pig studies,<sup>11</sup> but also during follow-up of 90 days or more. A certain degree of tissue overgrowth of the devices was found, but not more than grade 2 at the aortic side in 90% and at the LV side in 70% of the cases, and not apparently different from the single control case. Similar tissue overgrowth has been described in pigs in which the mitral valve was replaced by a mechanical valve prosthesis and is related to level of anticoagulation with coumarin derivatives.<sup>13</sup> High-dose anticoagulation results in low-grade tissue overgrowth with high mortality, and no coumarin derivatives, as in our study, results in high-grade tissue overgrowth with low mortality.<sup>13</sup> Although peroperative angiography of our (demo) valves demonstrated grade 2+ aortic regurgitation in 2 cases, late angiographic examinations performed in 1 of these cases did show grade 1+ regurgitation, and at autopsy no para-device leakage was demonstrated in either. In animals that did not survive the operation there was no direct relation to the sutureless valve replacement method as such, but mainly to problems with closing the aortotomy. In a number of cases these problems were related to the device-pig mismatch, inasmuch as initially we had only one relatively large device with a 21-mm valve prosthesis and relatively thick textile covering available. Subsequently, smaller 19-mm valve prostheses were used, and the thickness of the textile covering has been further diminished. Deviations from the



operative protocol by trying to omit stretching sutures, guiding sutures, or annular sutures was another reason for early failures and part of our learning process. In a number of cases the stretching sutures broke off, potentially causing prosthetic valve malfunction. This method of temporarily stretching the flanges needs to be improved by mechanical means. Although the use of guiding and annular sutures was shown to be necessary in this pig model, that is not to say that all these will be required in human beings, in whom exposure of the aortic valve is better, diseased annuli stiffer, and more device sizes will be available. In this series of experiments, only prototypes of attachment rings were used with both flexible upper and lower flanges. The valve prosthesis was positioned within the rings, which were placed within the annulus, potentially diminishing effective valve orifice, especially in small sizes. Other prototypes with fixed upper and flexible lower flanges have been developed as well. With this latter prototype it is possible to place an oversized, unchanged valve prosthesis on top of the fixed upper flange supra-annularly. Such prototypes have been successfully tested by us in the aortic position *in vitro* and in the mitral position during acute pig experiments (manuscript submitted to this *Journal*), but were not used in these experiments because of the small aorta size in our pigs. Currently, there is a strong interest in self-expanding, or balloon-dilated, catheter-based sutureless biological aortic valve implants that are mounted within a stent.<sup>6-10</sup> These valved stents are implanted by radial expansion within the calcified remnants of the pre-balloon-dilated diseased valve and show high incidence of postprocedure regurgitation.<sup>7,8,14</sup> Percutaneous balloon aortic valvuloplasty as such carries a high rate of serious complications, including cerebral.<sup>15</sup> Balloon-dilatable stents will demonstrate no active radial expansion force once they have been dilated. Also, a self-expanding stent will exert zero radial expansion force once the valve prosthesis that is sutured within the stent has fully expanded. For this reason, certain valved stents are attached distally in the ascending aorta, away from the valve annulus,<sup>16</sup> and it is common<sup>17</sup> and recommended<sup>18</sup> to oversize valved stents to diminish para-device leakage. This oversizing may result in less than full expansion of valve prostheses and, together with noncircular expansion within calcium,<sup>19</sup> these factors may lead to nonlaminar flow, potentially resulting in accelerated structural valve degeneration. Durability of (balloon-dilated) valves within a stent is currently still uncertain. On the contrary, the attachment rings are sized according to the annular diameter of the completely removed diseased valve. The ring attaches itself by clamping the annulus in a longitudinal direction, without radial expansion, which allows use of fully expanded biological or mechanical valve prostheses with proven long-term durability.<sup>20</sup>

Valved stents have a high profile that, together with the valve dilatation method as such, can cause damage to the mitral valve, coronary ostia, aorta, left ventricle, and conduc-

tion tissue.<sup>9</sup> The continuous radial expansion of (oversized) self-expandable valved stents at the aortic annular level results in a 30% to 40% incidence of conduction abnormalities, necessitating subsequent pacemaker implantation.<sup>21</sup> Recently, 2 self-expanding valved stents were introduced for clinical investigation. These stents have the advantage that they can be applied after surgical removal of the diseased valve,<sup>22,23</sup> but further these products carry potentially the same disadvantages as self-expanding catheter-based valved stents. Many of these disadvantages may be prevented by using Nitinol attachment rings to replace heart valves suturelessly.

In addition to the authors, the following persons contributed to the Sutureless Aortic Valve Project (in alphabetical order): Benjamin Berreklouw (video registration, Son, The Netherlands), Sander Bramer (Resident Catharina Hospital, Eindhoven, The Netherlands), Guus Brueren (Cardiologist Catharina Hospital, Eindhoven, The Netherlands), Lawrence Cohn (Brigham and Woman's Hospital, Boston, Mass), Guy van Dael (Audiovisual Department, Catharina Hospital, Eindhoven, The Netherlands), Trevor Dekker (Medtronic Nederland BV, The Netherlands), Bennie Drieghe (cardiologist, UZG, Ghent, Belgium), Viovanca Elisabeth (Fontys, Eindhoven, The Netherlands), Cristina Firanesco (Resident Catharina Hospital, Eindhoven, The Netherlands), Harold Fischer (Endosmart GmbH, Stutensee, Germany), Martijn van Geldorp (Resident Catharina Hospital, Eindhoven, The Netherlands), Yme Groeneveld (EPS, The Hague, The Netherlands), Piet Heesakkers (Instrumentation Catharina Hospital, Eindhoven, The Netherlands), John van de Hulst (Vascutek Nederland BV, The Netherlands), Willem-Jan Janssen (Edwards Lifesciences Nederland BV, The Netherlands), Astrid Jorna (St Jude Medical Nederland BV, The Netherlands), Henk van Kemenade (Van Kemenade Slaughterhouse, Asten, The Netherlands), Wim Krijnen (Krijnen Medical BV, Beesd, The Netherlands), Marleen Mansveld (Catharina Hospital, Eindhoven, The Netherlands), Marjan van Marle (Traffic, Son, The Netherlands), Marijke Mersman (Catharina Hospital, Eindhoven, The Netherlands), Hardy Mueller (Jotec GmbH, Hechingen, Germany), Maria Olieslagers (UZG, Ghent, Belgium), Martijn Oostendorp (Technical University Delft, Delft, The Netherlands), Wim Van Renterghem (Mediaventures, Merelbeke, Belgium), Mike Roelofs (Audiovisual Department Catharina Hospital, The Netherlands), Gerda van Rijk-Zwikker (LUMC, Leiden, The Netherlands), Cees Schot (Instrumentation, Catharina Hospital, Eindhoven, The Netherlands), Pamela Somers (UZG, Ghent, Belgium), Carl Swindle (Edwards Lifesciences Ltd, Irvine, Calif), Erik Tio (Ethicon Nederland BV, The Netherlands), Christian Velten (Endosmart GmbH, Stutensee, Germany), Jos Verbeek (Instrumentation Catharina Hospital, Eindhoven, The Netherlands), Bernd Vogel (Endosmart GmbH, Stutensee, Germany), Frederik Weinberg (Kiki GmbH, Malsch, Germany), and Sarah Van de Wiele (UZG, Ghent, Belgium)

## References

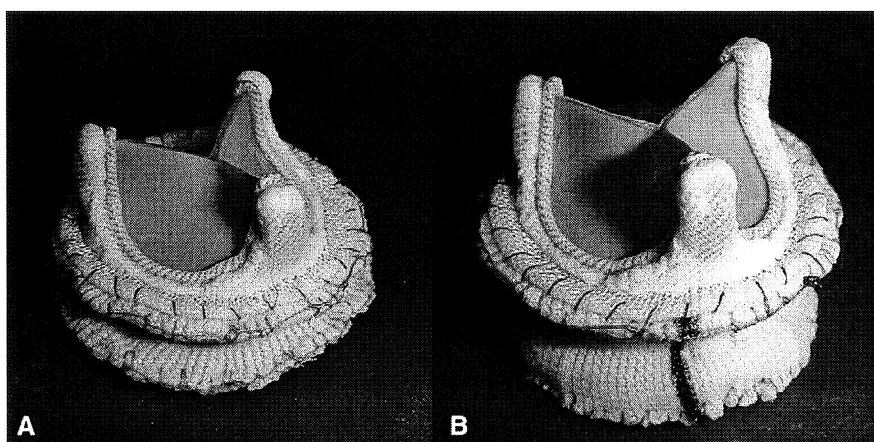
1. Hufnagel CA, Harvey WP. The surgical correction of aortic regurgitation. Preliminary report. *Bull Georgetown Univ Med Center*. 1953;6:3-6.
2. Magovern GJ, Liebler GA, Park SB, Burkholder JA, Sakert T, Simpson A. Twenty-five-year review of the Magovern-Cromie sutureless aortic valve. *Ann Thorac Surg*. 1989;48:S33-4.

3. Davies H. Catheter-mounted valve for temporary relief of aortic insufficiency. *Lancet*. 1965;1:250.
4. Mouloupoulos SD, Antopoulos L, Stamatelopoulos S, Stefadouros M. Catheter-mounted aortic valves. *Ann Thorac Surg*. 1971;11:423-30.
5. Andersen HR, Knudsen LL, Hasenkam JM. Transluminal implantation of artificial heart valves. Description of a new expandable aortic valve and initial results with implantation by catheter technique in closed chest pigs. *Eur Heart J*. 1992;13:704-8.
6. Cribier A, Eltchaninoff H, Bash A, Borenstein N, Tron C, Bauer F, et al. Percutaneous transcatheter implantation of an aortic valve prosthesis for calcified aortic stenosis: first human case description. *Circulation*. 2002;106:3006-8.
7. Webb JG, Pasupati S, Humphries K, Thompson C, Altwegg L, Moss R, et al. Percutaneous transarterial aortic valve replacement in selected high-risk patients with aortic stenosis. *Circulation*. 2007;116:755-63.
8. Walther T, Simon P, Dewey T, Wimmer-Greinecker G, Falf V, Kasimir MT, et al. Transapical minimal invasive aortic valve implantation. *Circulation*. 2007;116(suppl 1):I-240-5.
9. Hanzel GS, O'Neill WW. Complications of percutaneous aortic valve replacement: experience with the Cribier-Edwards percutaneous heart valve. *EuroIntervention Suppl*. 2006;1:A3-8.
10. Piazza N, van Gameren M, Jüni P, Wenaweser P, Carrel T, Onuma Y, et al. A comparison of patients characteristics and 30 days mortality outcome after transcatheter aortic valve implantation and surgical aortic valve replacement for the treatment of aortic stenosis: a two-centre study. *Eurointervention*. 2009;5:580-8.
11. Berreklouw E, Vogel B, Fischer H, Weinberg F, van Rijk-Zwikker GL, Van Nooten GJ, et al. Fast sutureless implantation of mechanical aortic valve prostheses using Nitinol attachment rings: feasibility in acute pig experiments. *J Thorac Cardiovasc Surg*. 2007;134:1508-12.
12. Sellers RD, Levy MJ, Amplatz K, Lillehei CW. Left retrograde cardioangiography in acquired cardiac disease; technic, indications and interpretations in 700 cases. *Am J Cardiol*. 1964;14:437-47.
13. Grehan JF, Hilbert SL, Ferrans VJ, Droel JS, Salerno CT, Bianco RW. Development and evaluation of a swine model to assess the preclinical safety of mechanical heart valves. *J Heart Valve Dis*. 2000;9:710-20.
14. De Jaegere PP, Piazza N, Galema TW, Otten A, Soliman OI, Van Dalen BM, et al. Early echocardiographic evaluation following percutaneous implantation with the self-expanding CoreValve ReValving System aortic valve bioprosthesis. *Eurointervention*. 2008;4:351-7.
15. NHLBI Balloon Valvuloplasty Registry Participants. Percutaneous balloon aortic valvuloplasty: acute and 30-day follow-up results in 674 patients from the NHLBI Balloon Valvuloplasty Registry. *Circulation*. 1991;84:2383-97.
16. Laborde JC, Borenstein N, Behr L, Farah B, Fajadet J. Percutaneous implantation of the CoreValve aortic prosthesis for patients presenting high risk for surgical valve replacement. *Eurointervention*. 2006;1:472-4.
17. Rodés-Cabau J, Webb JG, Cheung A, Ye J, Dumont E, Feindl CM, et al. Transcatheter aortic valve implantation for the treatment of severe symptomatic aortic stenosis in patients at very high or prohibitive surgical risk: acute and late outcome of the multicenter Canadian experience. *J Am Coll Cardiol*. 2010;55:1080-90.
18. Détaint D, Lepage L, Himbert D, Brochet E, Messika-Zeitoun D, Iung B, et al. Determinants of significant paravalvular regurgitation after transcatheter aortic valve implantation; impact of device and annulus discongruence. *J Am Coll Cardiol Cardiovasc Interv*. 2009;2:821-7.
19. Zegdi R, Ciobotaru V, Noghin M, Sheilaty G, Lafont A, Latrémouille C, et al. Is it reasonable to treat all calcified stenotic aortic valves with a valved stent? *J Am Coll Cardiol*. 2008;51:579-84.
20. Aupert MR, Mirza A, Meurisse YA, Sirinelli AL, Neville PH, Marchaud MA. Perimount pericardial bioprostheses for aortic calcified stenosis: 18-year experience with 1,133 patients. *J Heart Valve Dis*. 2006;15:768-76.
21. Avanzas P, Muñoz-García AJ, Segura J, Pan M, Alonso-Briales JH, Lozano I, et al. Percutaneous implantation of the CoreValve self-expanding aortic valve prosthesis in patients with severe aortic stenosis: early experience in Spain. *Rev Esp Cardiol*. 2010;63:141-8.
22. Martens S, Ploss A, Sirat S, Miskovic A, Moritz A, Doss M. Sutureless aortic valve replacement with the 3f Enable aortic bioprosthesis. *Ann Thorac Surg*. 2009;87:1914-8.
23. Shrestha M, Folliguet T, Meuris B, Dibie A, Herregods MC, Khaladj N, et al. Sutureless Perceval S aortic valve replacement: a multicenter prospective pilot trial. *J Heart Valve Dis*. 2009;18:698-702.



**FIGURE E1.** Operative research team: Maria Olieslagers, Sara van de Wiele, Stefaan Bouchez, Filip De Somer, Eric Berrekouw, and Bart Koene (left to right)

ET/BS



**FIGURE E2.** A, Unchanged 19-mm Edwards Perimount biological aortic valve prosthesis on top of textile-covered Nitinol attachment ring with rigid upper and flexible lower flange (device), in warm expanded shape (side view). B, Same device as in A, in cold stretched shape (side view).