

Canine *Angiostrongylus vasorum*

Canine Angiostrongylus vasorum

¹I. Moeremans, ¹D. Binst, ²E. Claerebout, ¹I. Van de Maele, ¹S. Daminet

¹Department of Small Animal Medicine and Clinical Biology

²Department of Virology, Parasitology and Immunology

Current working address of I. Moeremans: Department of Pathology, Bacteriology and Poultry Diseases
Faculty of Veterinary Medicine, Ghent University
Salisburylaan 133, B-9820 Merelbeke, Belgium

Ilse.Moeremans@Ugent.be

ABSTRACT

The French heartworm *Angiostrongylus vasorum* is a parasitic nematode that lives in the pulmonary vessels and the heart of canids. Transmission occurs through ingestion of infected intermediate hosts, such as snails and slugs. There are increasing reports of autochthonous infections in our neighbouring countries. Clinical signs usually relate to the respiratory system, coagulopathy and the neurologic system. Anorexia, gastrointestinal dysfunction and weight loss are also frequently observed. Diagnosis is not straightforward, but abnormalities detected by thoracic radiography, echocardiography, magnetic resonance imaging (MRI) or computed tomography (CT) scan can be helpful. Eosinophilia, regenerative anemia and thrombocytopenia with or without abnormalities in the coagulation profile can occur. Definitive diagnosis is made by demonstrating the parasite in the cerebrospinal fluid, in faeces (Baermann technique) and/or in broncho-alveolar lavage fluid. Treatment consists of anthelmintic drugs and supportive care if necessary.

SAMENVATTING

Angiostrongylus vasorum of de 'Franse hartworm' is een nematode die leeft in de longbloedvaten en het hart van hondachtigen. Honden worden besmet door de opname van geïnfecteerde slakken, die als tussengastheer fungeren. Er zijn steeds meer meldingen van autochtone infecties in de ons omringende landen. De symptomen bestaan voornamelijk uit respiratoire, neurologische en bloedingsstoornissen. Ook anorexie, gastro-intestinale problemen en gewichtsverlies worden gezien. De diagnose is niet eenvoudig maar thoraxradiografie, echocardiografie, MRI en CT-scan kunnen een hulp zijn. Eosinofilie, regeneratieve anemie en trombocytopenie, al dan niet in combinatie met abnormale stollingstijden, kunnen eveneens voorkomen. De definitieve diagnose wordt gesteld door het aantonen van de parasiet in cerebrospinaal vocht, feces (met de baerманntechniek) en/of in broncho-alveolaire spoelvoeistof. De behandeling bestaat uit een ondersteunende therapie en een toediening van antiparasitaire middelen.

INTRODUCTION

Angiostrongylus vasorum (*A. vasorum*) is a red thread-like metastrongyloid nematode (13-25 mm) living in the pulmonary vessels and the right side of the heart of canids. The natural end host is the common fox (*Vulpes vulpes*), but other species, including domestic dogs, can be infected. Other members of the *Angiostrongylus* family include *A. cantonensis* and *A. costaricensis*, which use rats as definitive hosts, although *A. cantonensis* can also cause disease in dogs. The uptake of the third stage larvae of *A. cantonensis* or *A. costaricensis* in contaminated water or food by humans (accidental definitive host) causes eosinophilic meningitis or intestinal granulomas (Wang *et al.*, 2008; Helm *et al.*, 2010).

Dogs infected with *A. vasorum* can display an array of clinical signs, including cardiopulmonary abnormalities, coagulation problems, neurological signs and general malaise. The nickname 'French heartworm'

finds its origin in the discovery and endemic presence of the parasite in France. Today, however, the endemic regions have expanded over the (sub)tropical and temperate regions of Europe, Africa and North and South America (Conboy, 2009; Helm *et al.*, 2010). To the best of our knowledge, an indigenous case of angiostrongylosis has not yet been reported in Belgium. However, the parasite has been reported in all countries surrounding Belgium. In the following article, we focus on the biology of the parasite and the clinical presentation, diagnosis, treatment and prognosis of this condition.

LIFE CYCLE AND EPIDEMIOLOGY

Life cycle

The indirect life cycle (Figure 1) of *A. vasorum* has an essential developmental phase in an intermediate (several species of slugs and snails) or paratenic host,

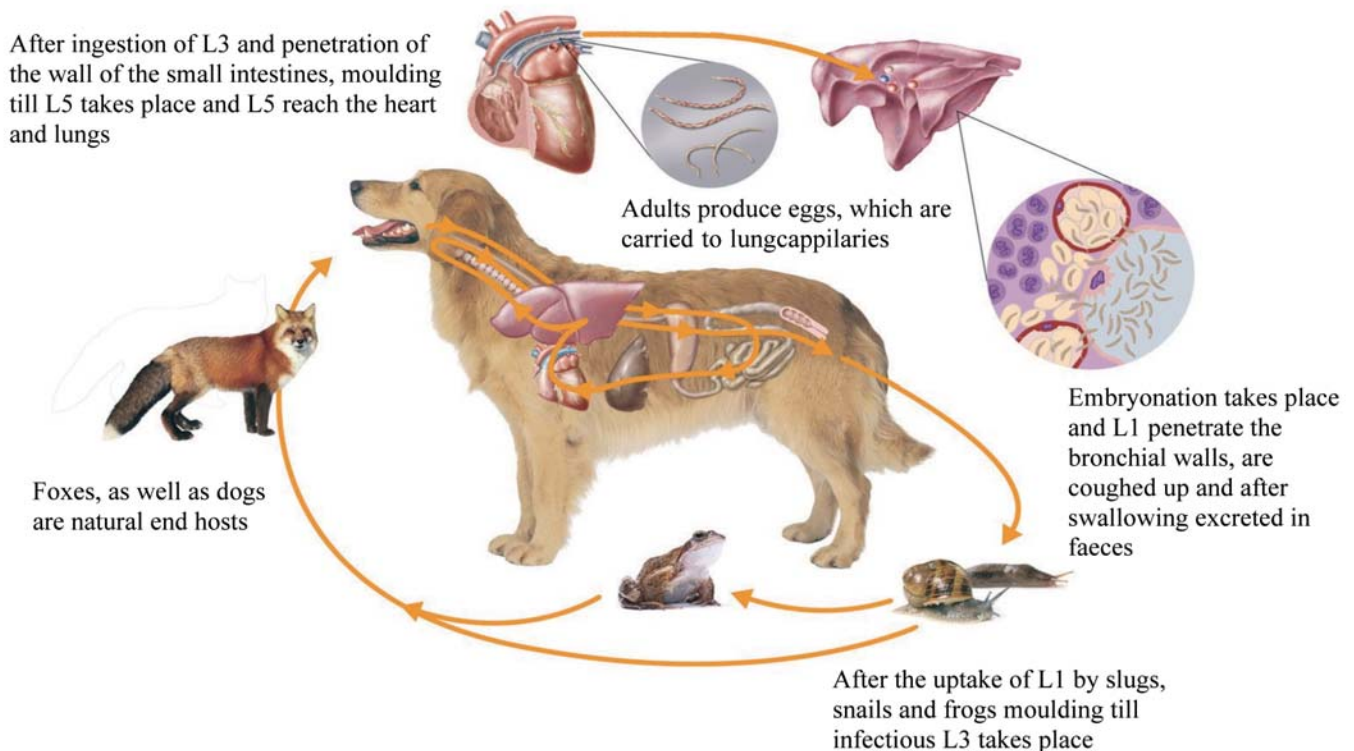


Figure 1. Life cycle of *Angiostrongylus vasorum* (with courtesy of Bayer animal Health®). L1: first stage larvae; L3: third stage larvae; L5: fifth stage larvae.

for example frogs. The term paratenic hosts is used to describe hosts which are not necessary in the life cycle of a parasite but nonetheless can serve as a source of infection for other hosts. They are also referred to as transfer or transport hosts (Wang *et al.*, 2008) (Bolt *et al.*, 1993). First stage larvae (L1) mature and moult in the intermediate hosts into infective L3 larvae (L3). The ingestion of infected intermediate or paratenic hosts results in the infection of the definitive host. The infection of the definitive host can also be caused by the ingestion of free-living L3 because L3 can leave the intermediate host and survive in water or on wet grass. The importance of this latter infection route has not yet been investigated *in vivo* (Barçante *et al.*, 2003; Denk *et al.*, 2009). Once inside the small intestine, the L3 penetrate the intestinal wall and migrate to the abdominal lymph nodes where the third and fourth moults take place. L5 larvae migrate through the lymphatics to the portal and hepatic veins and reach the right ventricle and pulmonary arteries, where they develop into adult worms. Female worms produce eggs that are carried to the lung capillaries, where embryonation takes place. L1 larvae penetrate the bronchial walls and alveoli and are coughed up and swallowed by the host. They are excreted with the faeces where they can survive for some days. After a long and variable prepatent period (28-108 days), dogs can excrete larvae for several years. Oliveira-Junior *et al.* (2006) showed that experimentally infected dogs could excrete larvae for more than 600 days, and they concluded that dogs are an important reservoir for infection, even in an urban environment.

Signalment

All dog breeds and ages can be infected as long as they scavenge outside, although young dogs seem to be predisposed to clinical infection. In the 'Copenhagen *Angiostrongylus* Survey' (CAS), more than 50% of the infected dogs were younger than one year (Koch and Willeesen, 2009), and in the study of Chapman *et al.* (2004), the clinically affected dogs, on average, were only ten months old. The reasons for this age distribution are not completely clear, but the inquisitiveness and scavenging behavior of these young dogs may be of importance. Frequently playing with and eating snails is a known risk factor. Moreover, the immune system continues to develop until the age of one, making young animals more susceptible to clinical infection (Day, 2007).

In the Danish survey, no breed predisposition was reported, although others have found a higher occurrence in Cavalier King Charles spaniels, Staffordshire Bull terriers (Chapman *et al.*, 2004) and beagles (Conboy *et al.*, 2004). The last author attributed this fact to the use of this breed as a hunting dog. Dogs used for hunting seem to be more at risk because of their exposure to infection from the fox-snail life cycle during training (Conboy *et al.*, 2004).

Epidemiology

Several factors are important in the epidemiology of *Angiostrongylus* infections, but their individual importance is not yet clear.

Geographically, an expansion of the distribution of the infection is suggested, although the majority of the information on distribution originates from case reports from Germany (Denk *et al.* 2009; Barutzki and Schaper., 2009), the Netherlands (Van Doorn *et al.*, 2009), Denmark (Taubert *et al.*, 2009), Canada (Conboy, 2004; Bourque *et al.*, 2008) and the United Kingdom (Chapman *et al.* 2004, Yamakawa *et al.* 2009). Persistently hyperendemic foci, with a region of sporadic cases around them, are described. The scattered and local appearance of the parasite suggests a difference in the microclimate in which the intermediate host thrives to a greater or lesser extent (Morgan *et al.*, 2009). Climatic factors are indeed important because slugs and snails thrive in wet and moderate climates. Slugs in particular are sensitive to lower temperatures; in cold conditions, they are less active and survive for less time (Morgan *et al.*, 2009). Climate change and the resulting increase in warm, moist winters in northern areas might contribute to the spread of infection. Another possible explanation is the influence of environmental conditions on the survival of the free-living L3 larvae (Taubert *et al.*, 2009).

For the definitive hosts, the infection prevalence is remarkably higher in foxes compared to dogs (5-56% in comparison to 1-9.8%, the higher figure in hunting dogs in Denmark) (Barutzki and Schaper, 2009; Koch and Willeesen, 2009). Wild reservoir species may be responsible for an expansion of the disease, as foxes can range over large distances and are increasingly present in (peri)urban areas (Koch and Willisen, 2009).

As a final contribution, we must note the increased travelling and non-controlled transportation of dogs, as this can result in a worldwide spreading of the infection (Jeffries *et al.*, 2010).

PATHOGENESIS AND CLINICAL SIGNS

The clinical presentation and its severity are highly variable, ranging from subclinical disease to sudden death. Respiratory symptoms are frequently reported, but neurologic signs and coagulopathy are also possible. Symptoms might already be chronic when animals are diagnosed with the infection (Chapman *et al.*, 2004).

Dogs with respiratory disease present with a (chronic) history of gagging, coughing, exercise intolerance and tachy- or dyspnea with or without cyanosis. These symptoms are caused by an interstitial pneumonia and inflammation caused by migrating L1 or can also be due to decompensated heart failure due to pulmonary hypertension in more severe cases (Chapman *et al.*, 2004; Nicolle *et al.*, 2006). An acute respiratory crisis may occur and is frequently accompanied by lung bleeding or a hemothorax (Sasanelli *et al.*, 2008).

A second manifestation of infection is bleeding abnormalities, which are mostly diagnosed in referral practices. Many types of bleeding at any possible location (petechiae and ecchymoses as well as extensive hematomas and bleedings in abdominal and thoracic cavities) may be seen and several parts of the coagu-

lation pathway can be disturbed. Prothrombin time (PT), activated partial thromboplastin time (APPT) and D-dimer levels may be elevated, and fibrinogen levels may be low (Ramsey *et al.*, 1996). It is assumed that the presence of parasites activates coagulation and clotting factors and that platelets are consumed. This is followed by intravascular fibrinolysis. Coagulation pathways are activated in two ways, the intrinsic pathway (by direct damage to the epithelium through the deposition of immune complexes) and the extrinsic pathway (by the release of tissue factors from damaged tissue) (Bourque *et al.*, 2008). Likewise, Koch and Willeesen (2009) described thrombocytopenia and elevated D-dimer levels in 80% of the cases, which may suggest a low-graded disseminated intravascular coagulopathy (DIC). Other explanations for thrombocytopenia are an autoimmune reaction with the formation of antiplatelet antibodies or platelet elimination by activated macrophages (Gould and McInnes, 1999). An acquired deficiency in von Willebrand factor (VWF) has been described in a case report of a dog affected by angiostrongylosis (Whitley *et al.*, 2005). In cases of DIC in humans, a normal or even increased level of VWF has been observed. In veterinary medicine, however, information concerning the VWF levels in DIC cases is lacking. Whitley *et al.* (2005) proposed an accelerated removal of the circulating VWF as an explanation for the lower VWF levels. The mechanism includes specific or non-specific antibodies forming complexes with VWF and the removal by Fc-receptor bearing cells. In general, one should always consider angiostrongylosis in the differential diagnosis of bleeding problems in dogs living in endemic areas (Chapman *et al.*, 2004; Helm *et al.*, 2010).

Bleeding in the brain or spinal cord can cause neurologic symptoms. Cranioventral bleeding can cause epileptic seizures, paresis and abnormal postural reactions (Wessman *et al.*, 2009). In cases of cerebellar bleeding, hypermetria, vestibular symptoms and opisthotonus are observed, and if the brainstem is affected, abnormalities of the cranial nerves can be seen (Negrin *et al.*, 2008). As in humans infected with *A. cantonensis*, inflammation has been postulated to be another potential cause of these neurologic signs. Hypoxia and parasitic emboli can also cause neurologic symptoms (Bourque *et al.*, 2008).

Finally, uveitis, depression, weight loss, anorexia and occasionally vomiting and diarrhoea are reported (Koch and Willeesen, 2009; Storms and Verdonck, 2011).

DIAGNOSIS

Clinical examination

Lung auscultation is usually normal, but in advanced cases, crackles (in most cases generalized) can be detected. With chronic pulmonary hypertension due to larval thrombosis, a systolic murmur can be heard over the tricuspid valve (Traversa and Guglielmini *et al.*, 2008). The exact position of the murmur can be varia-

ble due to a shift in the location of the heart (Nicolle *et al.*, 2006).

Medical Imaging

Thoracic radiographs reveal most commonly a multifocal/peripheral bronchointerstitial pattern with alveolar patches (Willesen *et al.*, 2009). When the disease progresses, an alveolar pattern at the periphery of the lungs appears. This is likely due to the formation of granulomas and the bleeding caused by the migration of L1 larvae (Helm *et al.*, 2010). In the more chronic stage, an interstitial pattern occurs that is caused by pulmonary consolidation and lung fibrosis. After resolution of the infection, a mild interstitial pattern can remain visible. Other abnormalities that can be seen are right-sided heart enlargement, dilatation of the truncus pulmonalis and, rarely, a rather eminent appearance of the pulmonary vessels. Pleural effusion (hemothorax) and a broadening of the mediastinum can also be present (Traversa and Guglielmini, 2008; Boag *et al.*, 2004).

High resolution computed tomography can also contribute to a more accurate evaluation of the lung lesions. Consolidation in the periphery of lung lobes (especially the caudal lobes) and a patchy multifocal opacity can be seen. In severe cases, a general diffuse attenuation throughout the entire lung can occur due to the infiltration of inflammatory cells (Koch and Willesen, 2009; Helm *et al.*, 2010).

In patients manifesting neurological signs, magnetic resonance imaging or myelography are useful diagnostic tools. In myelography, intramedullary contrast accumulation similar to that seen in myelomalacia has been reported (Wessmann *et al.*, 2006). However, the most sensitive method to detect intracranial and intramedullary bleeding is MRI. The exact appearance of the bleeding depends on the chronicity of the lesion. Although in theory it should be possible to visualize the adult parasites, they have never been reported, and the chance of observing a sufficiently long section of a parasite to make identification possible, is rather small (Whitley *et al.*, 2005).

Cardiac ultrasonography and Doppler are standard methods for the evaluation of heart morphology and function. Right atrial and right ventricular dilatations in combination with a diminution of the left ventricle size, change in the pulmonary flow profile (pulmonary arterial hypertension or PAH) and secondary regurgitation over the pulmonalis/tricuspidalis valve can be seen (Nicolle *et al.*, 2006). The occurrence of PAH in dogs affected with angiostrongylosis is estimated to be less than 5% in first-line practice but can increase to more than 33% in referral hospitals (Koch and Willisen, 2009). The abnormalities mentioned above are not always present nor are they specific for *Angiostrongylosis*.

Blood and cerebrospinal fluid (CSF) analysis

Abnormalities on routine hematology are variable and depend on the chronicity and severity of the in-

fection. Regenerative anemia (due to blood loss), eosinophilia, thrombocytopenia and, less frequently, leucocytosis and neutrophilia can be observed. The fact that these findings normalize after treatment supports the hypothesis that a low-graded immune reaction/response occurs in every dog infected with *Angiostrongylus* (Chapman *et al.*, 2004, Willesen *et al.*, 2009).

Blood biochemistry can reveal an increased serum total protein concentration, alkaline phosphatase (AP) activity, globulin, bilirubin, cholesterol and fructosamine concentrations (Chapman *et al.*, 2004; Willesen *et al.*, 2009). Other authors, however, did not find significant differences in experimentally infected dogs for serum alanine aminotransferase (ALT), gamma-glutamyl transferase (GGT) and AP activities for urea and creatinine concentrations but did report an increase in α 1-, α 2- and β -globuline concentrations in the acute phase of infection (Cury *et al.*, 2005). In experimental infections, serum aspartate aminotransferase (AST) concentrations increased slightly but not significantly. The rise of AST occurred simultaneously with creatine kinase isoenzyme MB (CK-MB). This enzyme is an indicator of heart damage, and its increase runs parallel to the arrival of the parasite in the heart (Cury *et al.*, 2005).

In cases with bleeding problems, a prolongation of coagulation times with or without thrombocytopenia and other signs of DIC can be observed. Whitley *et al.* (2005) reported a prolongation of the buccal mucosal bleeding time (BMBT) and a decreased level of VWF. After the administration of desmopressin, the BMBT normalized, and after treatment of angiostrongylosis, VWF also normalized.

Examination of CSF is often indicated in animals showing neurological signs. An abnormally high protein content, signs of erythrophagia and high red blood cell counts in combination with normal white blood cell counts are typical findings in dogs with bleeding in the central nervous system (Wessmann *et al.*, 2006).

Faecal examination

A. vasorum L1 larvae can be detected in faecal samples. L1 larvae (334-380 μ m) are recognized by the morphology of their tails (Figure 2). They have a typical indentation of the cuticle and a bulging at the dorsal surface of the tail called a dorsal notch and a dorsal spine, respectively. A smaller ventral indentation can also be seen (Deplazes, 2006; Bourque *et al.*, 2008; McGary and Morgan, 2009).

Faecal samples can be examined by faecal smear, a flotation technique or the Baermann technique. In urgent cases, an attempt to diagnose the disease can be made using a direct faecal smear for which a sensitivity of 54-61% has been reported (Humm and Adamantos, 2010). However, the Baermann method is considered the gold standard for the definitive diagnosis of angiostrongylosis. Nevertheless, the Baermann technique also has limitations. Fresh samples are required because the larvae need to migrate through a mesh wire. This is followed

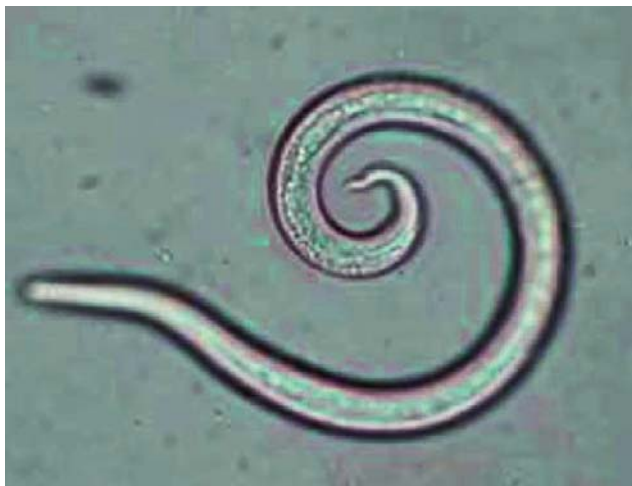

Figure 2. First stage larva (L1) visualized by light microscopy, the kinked tail with dorsal notch is the primary diagnostic feature (with courtesy of Bayer animal Health®).

by passive sedimentation in the Baermann funnel, which takes 24 to 36 hours and makes this test time consuming. More importantly, several authors have reported a negative Baermann test in dogs with angiostrongylosis (Denk *et al.*, 2008). During the long prepatent period, animals can display symptoms, but the larvae cannot yet be detected in the faeces. Moreover, the excretion of larvae is intermittent and variable. For this reason, it is advisable to collect faecal samples over a period of three consecutive days. A negative Baermann result does not exclude infection in a dog with typical symptoms living in a high-risk environment (Traversa and Guglielmini, 2008; Helm *et al.*, 2010).

Bronchoalveolar lavage

Bronchoalveolar lavage (BAL) can be useful to examine cells and material from the trachea and lungs. When lesions are present in the lungs, the parasite can be demonstrated together with an increase in neutrophils, eosinophils and giant polynuclear cells (Barçante *et al.*, 2008). The disadvantages of this technique are the potential risks, the associated morbidity (cough and crackles), the need for sedation/anesthesia and the poor sample recovery (small volumes). Furthermore, when there are no significant lesions in the lung, this test will be negative (Chapman *et al.*, 2004).

Serology and molecular techniques

Serologic testing has a few inherent problems, such as cross reactivity between several endoparasites and the lack of differentiation between past and current infections. Nevertheless, there are some promising tests that have been developed, but none are commercially available. Verzberger-Epstein *et al.* (2008) developed a sandwich ELISA for the detection of circulating antigen in sera with a specificity of 100% (no cross reactivity with *Crenosoma vulpis*) and a sensitivity of 98% (two false negatives due to a low worm burden), which is a

better result than the Baermann test. Recently, Schnyder *et al.* (2011) have developed a very sensitive (95.7%) and specific (94%) sandwich ELISA for the detection of circulating antigen. The authors believe that this test is a valid alternative for the diagnosis, follow-up and mass screening.

Molecular testing has great potential but unfortunately is currently only used in experimental models and is not yet commercially available (Al-Sabi *et al.*, 2010). A real-time PCR assay has been developed which is able to amplify a region of the second internal transcribed spacer (ITS-2) of *A. vasorum* in both definitive host samples (200 µl EDTA canine blood as well as 200 mg of canine faeces) and intermediate host tissue (Jeffries *et al.*, 2009).

Necropsy findings

Affected lungs show granulomatous pneumonia with suppurative and eosinophilic inflammation with vascular changes (thrombosis and fibrosis). Adult worms are present in the pulmonary arteries and right heart and are surrounded by fibrin. The reddish adult males are 14-18 mm in length and have a small bursa, two long spiculae and a kinked tail. Females are larger (18-25 mm), with a vulvar orifice just before the anus and long greyish ovaria coiled around the red intestine. Larvae are found in the smaller vessels of the lungs and cause inflammation. This causes the formation of caseogranulomas at the periphery of the lungs and pleura (Bourque *et al.*, 2008; Denk *et al.* 2008; Koch and Willeßen, 2009). Aberrant migration of larvae can cause caseogranulomas in other organs, such as the kidney, brain, spleen, adrenals and tracheobroncheal lymph nodes (Bourque *et al.*, 2008). The occurrence of larvae in the urinary system, the eye, pericardium, pancreas, liver, muscle and the skin has also been reported (Perry *et al.*, 1991; Oliveira-Junior *et al.*, 2004). Myocarditis and glomerulonephritis due to a type II hypersensitivity reaction and aberrant larvae was the cause of death in one dog (Gould and Mc Innes, 1999). In severe cases with extensive tissue damage, smooth muscle hypertrophy and hyperplasia of the arterial tunica media can be seen, which may be consequences of pulmonary hypertension. In cases of bleeding problems, large hematomas can be found, and if neurologic signs were present, bleeding in the brain or spinal cord can be noticed (Garosi *et al.*, 2005, Bourque *et al.*, 2008).

TREATMENT

The treatment consists of two parts: anthelmintic therapy and supportive care. Supportive care depends on the severity of the symptoms and consists of cage rest and hospitalization with oxygen supplementation in severe respiratory cases. In cases with life threatening DIC or bleeding problems, transfusions with blood, fresh frozen plasma or packed red blood cells may be life saving. Bleeding problems tend to resolve 24 hours after anthelmintic treatment, but the exact mechanism of the resolution of the bleeding pro-

Table 1. Frequently used drugs in the treatment of *Angiostrongylus vasorum* and their dosage (adapted from Helm *et al.*, 2010).

Drug	Dose
Fenbendazole	1) 20-25 mg/kg PO SID for 20 days 2) 50 mg/kg PO SID for 5-21 days
Imidacloprid/ Moxidectin	topical 0,1 ml/kg single dose
Milbemycin oxime	0,5 mg/kg PO once a week during 4 weeks
Levamisole	1) 7,5 mg/kg PO SID for 2 days then 10 mg/kg for 2 days 2) 12,5 mg/kg SC for 3 days
Ivermectin	200-400 µg/kg SC every 3 weeks 2-4 treatments

blems is not yet clear (Koch and Willesen, 2009). The use of other medications (e.g., corticosteroids, bronchodilators, diuretics, and ACE-inhibitors) is anecdotal and depends on the assessment of the clinician (Chapman *et al.*, 2004). Corticosteroids can be helpful in anaphylactic reactions and immune-mediated thrombocytopenia and can reduce pulmonary inflammation and secondary fibrosis (Gould and McInnes, 1999; Koch and Willesen, 2009).

The use of various anthelmintics has been described in the literature, among which fenbendazole, milbemycin oxime and imidacloprid/moxidectin spot-on are the most frequently used (Table 1). The treatment with ivermectin and levamisole may have side effects. Anaphylactic reactions due to the rapid killing of parasites have been described after levamisole treatment (Bourque *et al.*, 2008). Fenbendazole, milbemycin oxime and moxidectin/imidacloprid act more slowly, thereby reducing the chance of adverse reactions. There is no difference in efficacy between fenbendazole (25 mg/kg, SID for 20 days) and imidacloprid 10%/moxidectin 2.5% (single topical dose of 0.1 ml/kg). However, fenbendazole is not registered for this use in Europe (Gould and McInnes, 1999; Conboy, 2004). Imidacloprid 10%/moxidectin 2.5% (single topical dose of 0.1 ml/kg) efficiently eliminates L4 stages and immature adults and side effects are rare (Willesen *et al.*, 2007; Schnyder *et al.*, 2009). Milbemycin oxime (0.5 mg/kg p.o.) is also efficient in eliminating infection when used once a week for four weeks (Conboy, 2004).

Six weeks after the treatment with moxidectin/imidacloprid and three weeks after the fenbendazole treatment, a Baermann test should be performed on a pooled sample from faeces collected on three consecutive days. The test should confirm cure and exclude the conversion to an asymptomatic carrier status because these carriers can act as a reservoir for infection (Chapman *et al.*, 2004, Willesen *et al.*, 2007). In endemic areas, reinfections can occur, and as a consequence, regular testing (every three to six months) is advisable (Koch and Willesen, 2009).

PROGNOSIS

The majority of the dogs infected with *Angiostrongylus* have an uneventful recovery, although this is dependent on the severity of the symptoms. Respiratory symptoms disappear within 1-2 weeks, but coughing can resolve earlier. In 40% of the severe cases, residual symptoms (cough and exercise intolerance) can occur after the elimination of the infection. An early diagnosis and treatment should help to avoid this. When PAH occurs, the prognosis depends on the severity of the infection (Koch and Willesen, 2009).

Dogs displaying neurologic signs have a good long-term prognosis independent of the symptoms caused by bleeding or inflammation (Garosi *et al.*, 2005; Negrin *et al.*, 2008).

If mortality occurs, it is usually caused by severe (non-compensated) bleeding or respiratory failure. In referral hospitals, mortality rates of 10-15% have been reported (Chapman *et al.*, 2004; Koch and Willesen, 2009).

PROPHYLAXIS

Imidacloprid 10%/moxidectin 2.5% has been proven effective and is currently licensed for prophylactic use against *Angiostrongylus* (Schnyder *et al.*, 2009; Schnyder *et al.*, 2011). In hyperendemic regions, however, veterinarians should educate owners about the clinical symptoms and possible risks. They can advise removing their dogs' faeces and trying to avoid the intake of slugs and snails by putting the dog on a leash. The removal of snails is virtually impossible and ecologically not recommended (Helm *et al.*, 2010).

CONCLUSION

Because of the emerging occurrence of *A. vasorum* in our neighboring countries, it should be included in the differential diagnosis of all cases presented with unexplained bleeding tendencies, respiratory and/or neurologic signs. Unfortunately, the diagnosis is not

straightforward, and the Baermann testing of mixed faecal samples is still the gold standard. However, once the diagnosis is established, the treatment is rather simple with commercially available anthelmintic products. Clinicians' awareness of this illness and its various clinical signs is important because full recovery is possible if diagnosed at an early disease stage.

ACKNOWLEDGEMENTS

The authors would like to thank Bayer Animal Health® for supporting the research on this subject and for providing the figures of the life cycle and an L1 larva.

REFERENCES

- Al-Sabi M.N.S., Deplazes P., Webster P., Willesen J.L., Davidson K.D., Kapel C.M.O. (2010). PCR detection of *Angiostrongylus vasorum* in fecal samples of dogs and foxes. *Parasitology Research* 107, 135-140
- Barçante J.M.P., Barçante T.A., Ribeiro V.M., Oliveira-Junior S.D., Dias S.R.C., Negrão-Corrêa D., Lima W.S. (2008). Cytological and parasitological analysis of bronchoalveolar lavage fluid for the diagnosis of *Angiostrongylus vasorum* infection in dogs. *Veterinary Parasitology* 158, 93-102
- Barçante T.A., Barçante J.M.P., Dias S.R.C., Lima W.S. (2003). *Angiostrongylus vasorum* (Baillet, 1866) Kamensky, 1905: emergence of third-stage larvae from infected *Biomphalaria glabrata* snails. *Parasitology Research* 91, 471-475.
- Barutzki D., Schaper R. (2009). Natural infections of *Angiostrongylus vasorum* and *Crenosoma vulpis* in dogs in Germany (2007-2009). *Parasitology Research* 105, 39-48.
- Boag A.K., Lamb C.R., Chapman P.S., Boswood A. (2004). Radiographic findings in 16 dogs infected with *Angiostrongylus vasorum*. *Veterinary Record* 154, 426-430
- Bolt G., Monrad J., Frandsen F. (1993). The common frog (*Rana Temporaria*) as a potential paratenic and intermediate host for *Angiostrongylus vasorum*. *Parasitology Research* 79, 428-430
- Bourque A.C., Conboy G., Miller L.M., Whitney H. (2008). Pathological findings in dogs naturally infected with *Angiostrongylus vasorum* in Newfoundland and Labrador, Canada. *Journal of Veterinary Diagnostic Investigation* 20, 11-20
- Chapman P.S., Boag A.K., Guitian J., Boswood A. (2004). *Angiostrongylus vasorum* infection in 23 dogs (1999-2002). *Journal of Small Animal Practice* 45, 435-440
- Conboy G. (2004). Natural infections of *Crenosoma vulpis* and *Angiostrongylus vasorum* in dogs in Atlantic Canada and their treatment with milbemycin oxime. *Veterinary Record* 155, 16-18
- Conboy G. (2009). Helminth parasites of the canine and feline respiratory tract. *Veterinary Clinics of North America: small animal practice* 39, 1109-1126
- Cury M.C., Guimarães M.P., Lima W.S., Caldeira M.C.M., Couto T.R., Murta K., Carvalho M.G., Baptista J.M.B. (2005). Biochemical serum profiles in dogs experimentally infected with *Angiostrongylus vasorum* (Baillet, 1866). *Veterinary Parasitology* 128, 121-127
- Day M.J. (2007). Immune system development in the dog and cat. *Journal of Comparative Pathology* 137, 10-15
- Denk D., Matiasek K., Just F.T., Hermanns W., Baiker K., Herbach N., Steinberg T., Fischer A. (2009). Disseminated angiostrongylosis with fatal cerebral haemorrhages in two dogs in Germany: A clinical case study. *Veterinary Parasitology* 160, 100-108
- Deplazes T. (2006) Helminthosen von Hund und Katze. In: Boch J., Schnieder T., Supperer R. (editors). *Veterinärmedizinische Parasitologie*. 6th Edition, Parey, Berlin, p489-491
- Garosi L.S., Platt S.R., McConnell J.F., Wray J.D., Smith K.C. (2005). Intracranial haemorrhage associated with *Angiostrongylus vasorum* infection in three dogs. *Journal of Small Animal Practice* 46, 93-99
- Gould S.M., McInnes E.L. (1999). Immune-mediated thrombocytopenia associated with *Angiostrongylus vasorum* infection in a dog. *Journal of Small Animal Practice* 40, 227-232
- Helm J.R., Morgan E.R., Jackson M.W., Wotton P., Bell R. (2010). Canine angiostrongylosis: an emerging disease in Europe. *Journal of Veterinary Emergency and Critical Care* 20, 98-109
- Humm K. and Adamantos S. (2010). Is evaluation of a faecal smear a useful technique in the diagnosis of canine pulmonary angiostrongylosis? *Journal of Small Animal Practice* 51, 200-203
- Jeffries R., Morgan E.R., Shaw S.E. (2009). A SYBR green real-time PCR assay for the detection of the nematode *Angiostrongylus vasorum* in definitive and intermediate hosts. *Veterinary Parasitology* 166, 112-118
- Jeffries R., Shaw S.E., Willesen J., Viney M.E., Morgan E.R. (2010). Elucidating the spread of the emerging canid nematode *Angiostrongylus vasorum* between Palaearctic and Nearctic ecozones. *Infection, Genetics and Evolution* 10, 561-568
- Koch J., Willesen J.L. (2009). Canine pulmonary angiostrongylosis: an update. *The Veterinary Journal* 179, 348-359
- McGarry J.W., Morgan E.R. (2009). Identification of first-stage larvae of metastrongyles from dogs. *Veterinary Record* 165, 258-261
- Morgan E.R., Jeffries R., Krajewski M., Ward P., Shaw S.E. (2009). Canine pulmonary angiostrongylosis: The influence of climate on parasite distribution. *Parasitology International* 58, 406-410
- Negrin A., Cherubini G.B., Steeves E. (2008). *Angiostrongylus vasorum* causing meningitis and detection of parasite larvae in the cerebrospinal fluid of a pug dog. *Journal of Small Animal Practice* 49, 468-471
- Nicolle A.P., Chetboul V., Tessier-Vetzel D., Sampedrano C.C., Aletti E., Pouchelon J.L. (2006). Severe pulmonary arterial hypertension due to *Angiostrongylus vasorum* in a dog. *Canadian Veterinary Journal* 47, 792-795
- Oliveira-Júnior S.D., Barçante J.M.P., Barçante T.A., Ribeiro V.M., Lima W.S. (2004) Ectopic location of adult worms and first-stage larvae of *Angiostrongylus vasorum* in an infected dog. *Veterinary Parasitology* 121, 293-296
- Oliveira-Júnior S.D., Barçante J.M.P., Barçante T.A., Dias S.R.C., Lima W.S. (2006). Larval output of infected and re-infected dogs with *Angiostrongylus vasorum* (Baillet, 1866) Kamensky, 1905. *Veterinary Parasitology* 141, 101-106
- Perry A.W., Hertling R., Kennedy M.J. (1991). Angiostrongylosis with disseminated larval infection associated with signs of ocular and nervous disease in an imported dog. *Canadian Veterinary Journal* 32, 430-431
- Ramsey I.K., Littlewood J.D., Dunn J.K., Herrtage M.E. (1996). Role of chronic disseminated intravascular coagulation in a case of canine angiostrongylosis. *Veterinary Record* 138, 360-363

- Sasanelli M., Paradies P., Otranto D., Lia R.P., de Caprariis D. (2008). Haemothorax associated with *Angiostrongylus vasorum* infection in a dog. *Journal of Small Animal Practice* 49, 417-420
- Schnyder M., Fahrion A., Ossent P., Kohler L., Webster P., Heine J., Deplazes P. (2009). Larvicidal effect of imidacloprid/moxidectin spot-on solution in dogs experimentally inoculated with *Angiostrongylus vasorum*. *Veterinary Parasitology* 166, 326-332
- Schnyder M., Tanner I., Webster P., Barutzki D., Deplazes P. (2011). An ELISA for sensitive and specific detection of circulating antigen of *Angiostrongylus vasorum* in serum samples of naturally and experimentally infected dogs. *Veterinary Parasitology* 179, 152-158
- Storms G. And Verdonck D. (2011). Oftalmologische spoedgevallen bij hond en kat. *Vlaams Diergeneeskundig Tijdschrift* 80, 95-104
- Taubert A., Pantchev N., Vrhovec M.G., Bauer C., Hermosilla C. (2009). Lungworm infections (*Angiostrongylus vasorum*, *Crenosoma vulpis*, *Aelurostrongylus abstrusus*) in dogs and cats in Germany and Denmark in 2003-2007. *Veterinary Parasitology* 159, 175-180
- Traversa D. and Guglielmini C. (2008). Feline aelurostrongylosis and canine angiostrongylosis: A challenging diagnosis for two emerging verminous pneumonia infections. *Veterinary Parasitology* 157, 163-174
- Van Doorn D.C.K., van de Sande A.H., Nijse E.R., Eysker M., Ploeger H.W. (2009). Autochthonous *Angiostrongylus vasorum* infection in dogs in The Netherlands. *Veterinary Parasitology* 162, 163-166
- Verzberger-Epshtein I., Markham R.J.F., Sheppard J.A., Stryhn H., Whitney H., Conboy G.A. (2008). Serologic detection of *Angiostrongylus vasorum* infection in dogs. *Veterinary Parasitology* 151, 53-60
- Wang Q.P., Lai D.H., Zhu X.G., Lun Z.R. (2008). Human angiostrongylosis. *Lancet Infectious disease* 8, 621-630
- Wessmann A., Lu D., Lamb C.R., Smyth B., Mantis P., Chandler K., Boag A., Cherubini G.B., Cappello R. (2006). Brain and spinal cord haemorrhages associated with *Angiostrongylus vasorum* infection in four dogs. *Veterinary Record* 158, 858-863
- Wessmann A., Chandler K., Garosi L. (2009). Ischaemic and haemorrhagic stroke in the dog. *The Veterinary Journal* 180, 290-303
- Whitley N.T., Corzo-Menendez N., Carmicheal N.G., McGarry J.W. (2005). Cerebral and conjunctival haemorrhages associated with von Willebrand factor deficiency and canine angiostrongylosis. *Journal of Small Animal Practice* 46, 75-78
- Willesen J.L., Kristensen A.T., Jensen A.L., Heine J., Koch J. (2007). Efficacy and safety of imidacloprid/moxidectin spot-on solution and fenbendazole in the treatment of dogs naturally infected with *Angiostrongylus vasorum* (Baillet, 1866). *Veterinary Parasitology* 147, 258-264
- Willesen J.L., Jensen A.L., Kristensen A.T., Koch J. (2009). Haematological and biochemical changes in dogs naturally infected with *Angiostrongylus vasorum* before and after treatment. *The Veterinary Journal* 180, 106-111
- Yamakawa Y., McGarry J.W., Denk D., Dukes-McEwan J., Macdonald N., Mas A., McConnell F., Tatton B., Valentine E.G., Wayne J., Williams J.M., Hetzel U. (2009). Emerging canine angiostrongylosis in northern England: five fatal cases. *Veterinary Record* 164, 149-152



medvet
diergeneeskunde

Diergeneeskundige analyses uitgevoerd onder toezicht van **ervaren dierenartsen.**

Een team van **diergeneeskundige pathologen**, zowel voor histologie als cytologie.

Persoonlijke service en klinische interpretatie.

medvet | diergeneeskunde
Emiel Vloorsstraat 9 BE-2020 Antwerpen
T +32 3 30 30 800 F +32 3 30 30 880
S www.medvet.be E info@medvet.be