

# Transplantation of Viable Meniscal Allograft

## Surgical Technique

BY PETER C.M. VERDONK, MD, ALEX DEMURIE, MD, KARL FREDRIK ALMQVIST, MD, PhD, ERIC M. VEYS, MD, PhD, GUST VERBRUGGEN, MD, PhD, AND RENÉ VERDONK, MD, PhD

*Investigation performed at the Departments of Orthopaedic Surgery and Rheumatology, Ghent University Hospital, Ghent, Belgium*

*The original scientific article in which the surgical technique was presented was published in JBJS Vol. 87-A, pp. 715-724, April 2005*

### INTRODUCTION

In well-selected patients, viable meniscal allograft transplantation produces good clinical results with a satisfactory survival rate at ten years following the procedure<sup>1</sup>. The purpose of this technical report is to present, in detail, a viable medial and lateral meniscal allograft transplantation procedure that is performed through a parapatellar arthrotomy. The chronological sequence of an associated high tibial osteotomy or anterior cruciate ligament reconstruction is also discussed.

### SURGICAL TECHNIQUE

#### *Preoperative Considerations*

The transplantation of viable meniscal allografts implies the availability of viable donor tissues, cultured in vitro immediately following harvest. Once a patient is deemed to be a candidate for this type of procedure, 30 to 50 mL of autologous serum is prepared and frozen at  $-21^{\circ}\text{C}$ . The patient's height and weight are documented for subsequent allograft size-matching. The average waiting time for a viable meniscal allograft at our institution is two months (range, fourteen days to six months). Once an appropriately sized meniscal allograft is harvested, the patient is notified and an operation is planned within the next fourteen days. In contrast with the use of fresh-frozen or cryopreserved grafts, a strict time-schedule from harvest to transplantation is mandatory.

#### *Allograft Harvest and Culture*

The allograft is harvested within twenty-four hours post mortem, under strictly aseptic conditions in the operating theater, from donors who have died from

### ABSTRACT

#### **BACKGROUND:**

Few medium-term or long-term reports on meniscal allograft transplantations are available. In this study, we present the results of a survival analysis of the clinical outcomes of our first 100 procedures involving transplantation of viable medial and lateral meniscal allografts performed in ninety-six patients.

#### **METHODS:**

Thirty-nine medial and sixty-one lateral meniscal allografts were evaluated after a mean of 7.2 years. Survival analysis was based on specific clinical end points, with failure of the allograft defined as moderate occasional or persistent pain or as poor function. An additional survival analysis was performed to assess the results of the sixty-nine procedures that involved isolated use of a viable allograft (twenty of the thirty-nine medial allograft procedures and forty-nine of the sixty-one lateral allograft procedures) and of the thirteen viable medial meniscal allografts that were implanted in combination with a high tibial osteotomy in patients with initial varus malalignment of the lower limb.

*continued*

**ABSTRACT** | continued**RESULTS:**

Overall, eleven (28%) of the thirty-nine medial allografts and ten (16%) of the sixty-one lateral allografts failed. The mean cumulative survival time (11.6 years) was identical for the medial and lateral allografts. The cumulative survival rates for the medial and lateral allografts at ten years were 74.2% and 69.8%, respectively. The mean cumulative survival time and the cumulative survival rate for the medial allografts used in combination with a high tibial osteotomy were 13.0 years and 83.3% at ten years, respectively.

**CONCLUSIONS:**

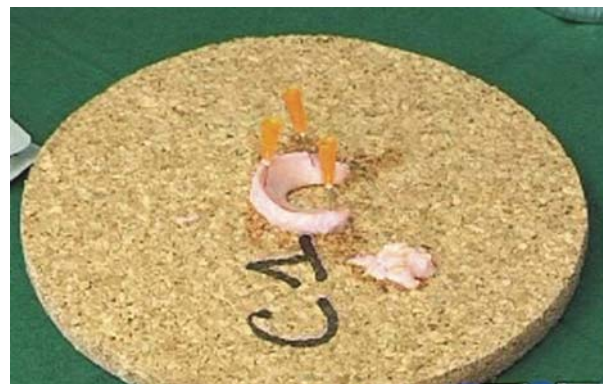Transplantation of a viable meniscal allograft can significantly relieve pain and improve function of the knee joint. Survival analysis showed that this beneficial effect remained in approximately 70% of the patients at ten years. This study identified the need for a prospective study comparing patients with similar symptoms and clinical findings treated with and without a meniscal allograft and followed for a longer period with use of clinical evaluation as well as more objective documentation tools regarding the actual fate of the allograft itself and the articular cartilage.

a disease of short duration, such as a stroke, or as the result of a motor-vehicle accident. Sizing of the allograft is based on the gender, height, and weight of the donor. Donor tissues are obtained from the Ghent University Hospital Tissue Bank, which has a strong collaboration with the Ghent University Hospital and other hospitals in the region and has experience in tissue culture. This ensures adequate background information on the donor's medical history and allows for the quick transfer of the harvested allograft material from and to the operating room, preserving tissue viability. The maximum age of the donors is set at forty-five years. Antemortem administration of cytostatic drugs or corticosteroids is an exclusion criterion for allograft harvesting as these medications could negatively influence cell viability and metabolism. The allograft is maintained in culture for two weeks in Dulbecco's Modified Eagle Medium (D-MEM; Invitrogen, Merelbeke, Belgium), supplemented with 20% autologous se-

rum, prior to transplantation. The culture medium is changed every three days, and sterility is checked at these intervals. Previous studies have demonstrated that meniscal cells remain viable and continue to synthesize their extracellular matrix molecules in this culture system<sup>2</sup>. The purpose of the meniscal tissue culture period is to allow time for screening of the donor for transmissible diseases according to the International Tissue Bank Standards and to carefully plan the surgical procedure.

**Anesthesia and Surgical Preparation**

The choice of anesthesia is made in consultation with the surgeon, the anesthesiologist, and the patient and depends on the age of the patient, comorbidities, and the patient's history with regard to previous anesthesia. Most commonly, general anesthesia is preferred at our institution. The patient is then positioned supine on the operating table. Prior to surgical preparation, the surgeon examines the involved knee to assess the range of motion; the results of the Lachman, pivot-shift, and reversed pivot-shift tests; anteroposterior laxity in 90° of flexion; and varus and valgus stability at 0° and 30° of flexion. Previous skin incisions are marked. The limb is exsanguinated and the tourniquet is inflated. The limb is then prepared with chlorhexi-

**FIG. 1**

The lateral viable meniscal allograft is fixed with three 25-gauge needles on a specially designed cork board. The synovial tissue is dissected from the allograft meniscus at the meniscosynovial junction level and is discarded.

dine gluconate-alcohol solution (Hibitane; Regent Medical Limited, Manchester, United Kingdom) and is draped at the level of the middle of the thigh.

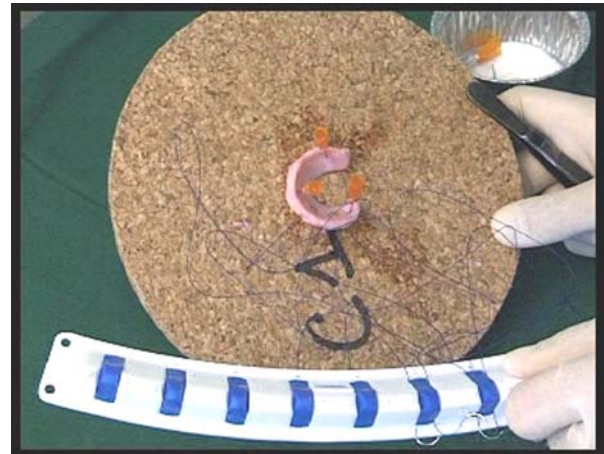### *Allograft Preparation*

Just prior to the operation, the allograft is brought to the operating room in the culture container filled with culture medium. The labels on the container (donor code, side, gender, height and weight, acceptor name, and code) are cross-referenced with the patient's identity by both an assistant surgeon and the surgeon. The container is carefully opened by the assistant surgeon, and the allograft is taken out by the surgeon with forceps. Culture specimens are obtained from the culture medium and the allograft itself for sterility control. The allograft is positioned and fixed on a specially designed cork board with three 25-gauge needles (Fig. 1). With a scalpel, the residual synovial tissue is dissected from the allograft meniscus at the meniscosynovial junction level and is discarded. The upper side of the allograft is marked with a methylene blue skin marker.

Horizontal 2-0 polydioxanone surgical sutures (PDS II; Ethicon, Somerville, New Jersey) or 2-0 nonabsorbable polypropylene sutures (Prolene; Ethicon) mounted on a double small needle are placed every 3 mm through the posterior horn, body, and anterior horn of the allograft and are fixed to a specially designed suture-holder (Holder A) (Fig. 2). The senior surgeon (R.V.) prefers the use of 2-0 Prolene sutures for the posterior horn as this suture material comes with slightly smaller needles and therefore allows for easier surgical handling in the more narrow posterior joint space. The sutures are fixed to the suture holder in sequence from posterior to anterior. Generally, six to eight sutures are needed to cover the complete allograft.

### *Lateral Meniscal Allograft Transplantation*

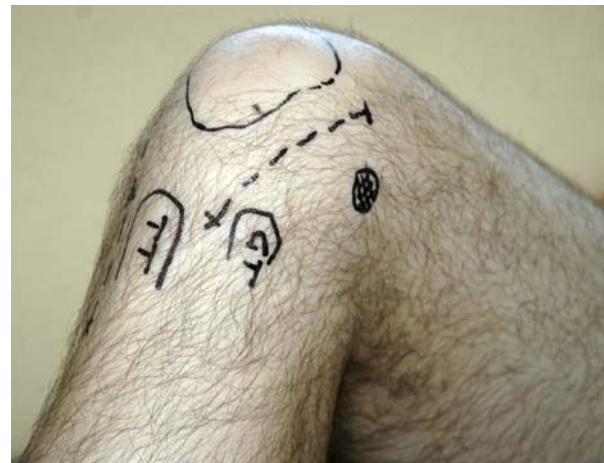A curvilinear lateral parapatellar incision, approximately 8 cm in length, is made with the knee in 90° of flexion to gain access to the lateral compartment of the knee joint (Fig. 3). Anatomical landmarks for this incision are the tibial tuberosity, Gerdy's tuber-



**FIG. 2**

Horizontal sutures are placed every 3 mm through the meniscal allograft, starting in the posterior horn. These sutures are then fixed to a suture-holder in sequence from posteriorly to anteriorly.

cle, and the superolateral corner of the patella. The incision is made 1 cm lateral to the patella, starting 2 cm proximal to its superolateral corner and ending between the tibial tuberosity and Gerdy's tubercle. The joint capsule is then opened, and the



**FIG. 3**

A curvilinear lateral parapatellar incision, approximately 8 cm in length, is made with the knee positioned in 90° of flexion. The anatomical landmarks are the tibial tuberosity (TT), Gerdy's tubercle (GT), and the superolateral corner of the patella.

## CRITICAL CONCEPTS

### INDICATIONS:

A viable meniscal allograft transplantation is indicated for a young or middle-aged patient (defined as a patient who is less than fifty years old) who has undergone a previous total meniscectomy. The patient should have moderate to severe pain due to excessive joint-loading secondary to meniscal deficiency. Professional incapacity is common. Joint-space narrowing should be limited to grade 0 (no narrowing) or 1 (<50% narrowing) as measured on plain posteroanterior weight-bearing radiographs according to the International Knee Documentation Committee system. At this time, we do not recommend prophylactic viable meniscus allograft transplantation for a patient who has had a meniscectomy

but is asymptomatic. Ideally, degenerative cartilage changes should be limited (grade III is considered borderline) and/or focal. If necessary, focal cartilage defects can be treated concomitantly with microfracture, mosaicplasty, or chondrocyte transplantation. Because of the usually mild degenerative cartilage disease, the relatively young age of the patients, and the desire of the patients to lead an active lifestyle, these patients are not candidates for unicompartmental or total knee arthroplasty. The lower limb axial alignment should be normal, and the knee joint should be stable. Otherwise, an associated corrective osteotomy or stabilization procedure is indicated.

*continued*

anterior horn of the lateral meniscus remnant is transected. The iliotibial band is released subperiosteally from its distal attachment. To allow the lateral compartment to be opened further, the insertions of the lateral collateral ligament and popliteus tendon are detached with use of a curved osteotome on the femoral side (Figs. 4-A and 4-B). The center of the osteotomy bone block is first predrilled with a 2.7-mm drill to facilitate subsequent refixation with a screw and washer. The osteotomy is performed in a clockwise direction from the 8 o'clock position to the 4 o'clock position. The osteotomy bone block is conically shaped and is approximately 1.5 cm deep. The bone block is gently folded out with use of a bone

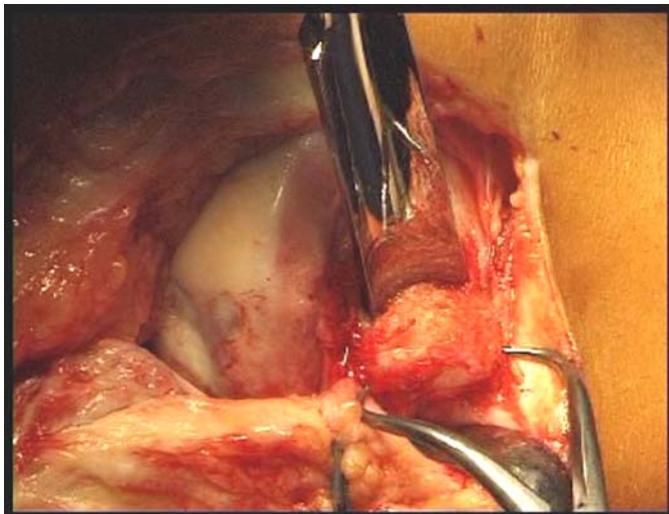


FIG. 4-A

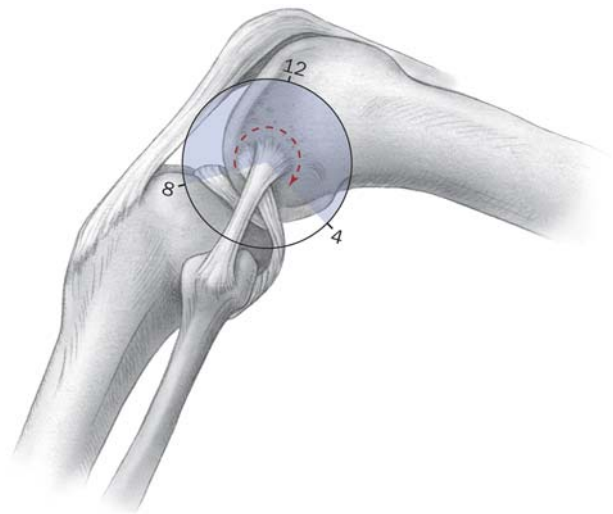


FIG. 4-B

**Fig. 4-A** To allow the lateral compartment of the knee joint to be opened, the lateral collateral ligament and the popliteus tendon are released on the femoral side through an osteotomy with use of a curved osteotome. The osteotomy is performed in a clockwise direction from the 8 o'clock position to the 4 o'clock position. The osteotomy bone block is conically shaped and is approximately 1.5 cm deep.

The bone block is gently folded out with use of a bone clamp and then is completed inferiorly from the 4 o'clock to the 8 o'clock position.

**Fig. 4-B** Line drawing depicting the osteotomy.

clamp, and then the osteotomy is completed inferiorly from the 4 o'clock to the 8 o'clock position with use of the osteotome. The lateral joint space can now be easily opened 1 to 2 cm by placing the knee in the figure-of-four position in 70° to 90° of flexion with the ipsilateral foot positioned across the contralateral limb (Figs. 5-A and 5-B). The lateral meniscus remnant is

### CRITICAL CONCEPTS | continued

#### CONTRAINDICATIONS:

- Generalized/grade-IV degenerative compartmental cartilage changes<sup>6,7</sup>
- Marked radiographic changes such as femoral condyle flattening and osteophyte formation<sup>8</sup>
- Axial malalignment<sup>6,9,10</sup>
- Ligamentous instability<sup>11</sup>
- Inflammatory joint disease
- A history of infection in the knee

*continued*

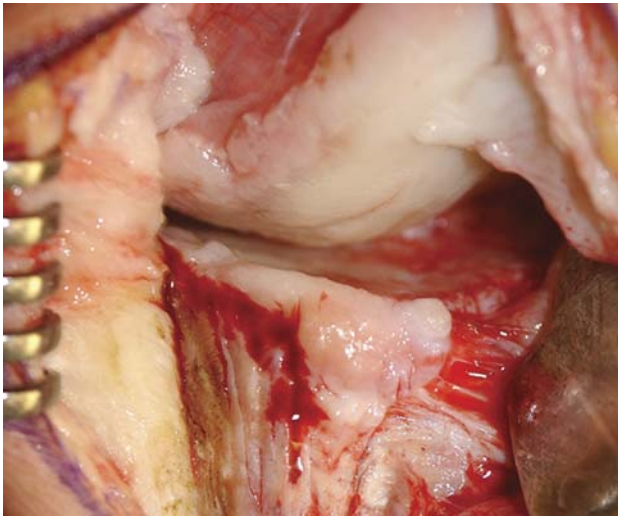


FIG. 5-A

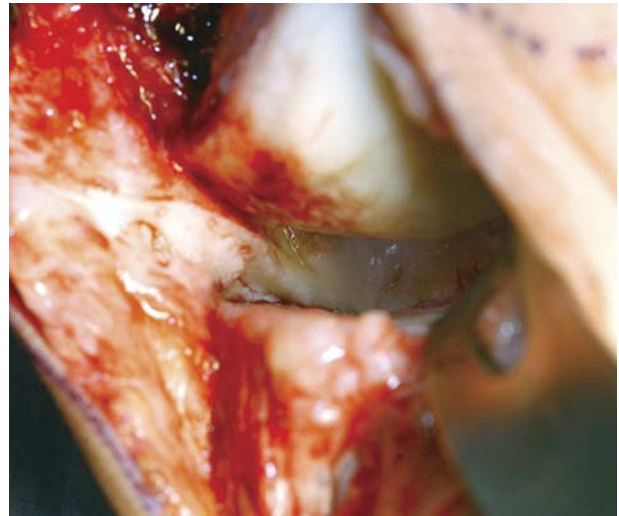


FIG. 5-B

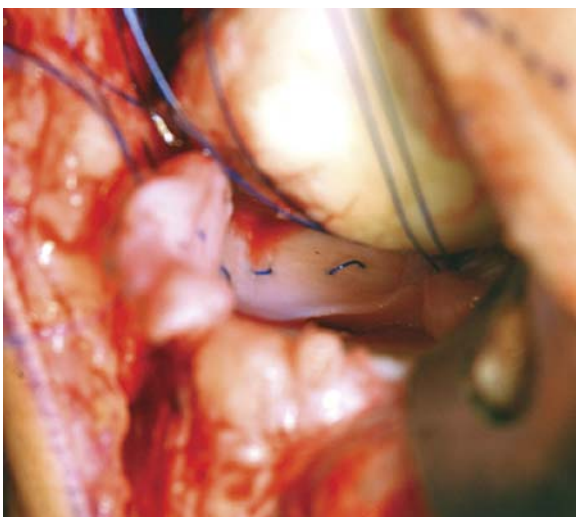


FIG. 5-C

**Fig. 5-A** The lateral joint space width prior to the osteotomy at the femoral insertion of the lateral collateral ligament. **Fig. 5-B** Widening of the lateral compartment joint space can be clearly observed after the osteotomy. The lateral compartment can be easily opened 1 to 2 cm by placing the knee in the figure-of-four position in 70° to 90° of flexion with the ipsilateral foot across the contralateral limb. **Fig. 5-C** This facilitates suture placement, especially in the positioned posterior part of the joint space, and also makes it easier to introduce the lateral allograft into the joint compartment.

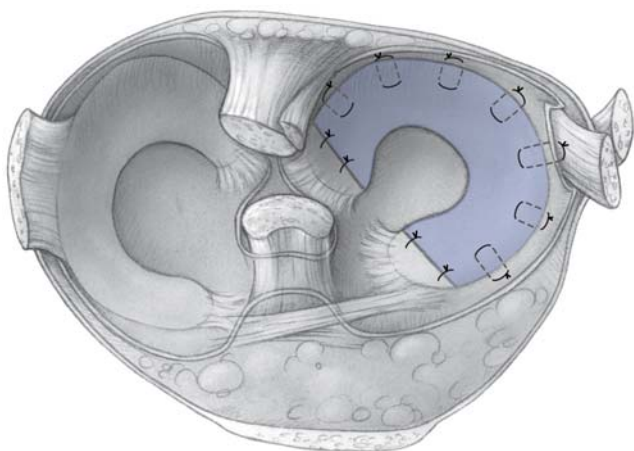


FIG. 6-A

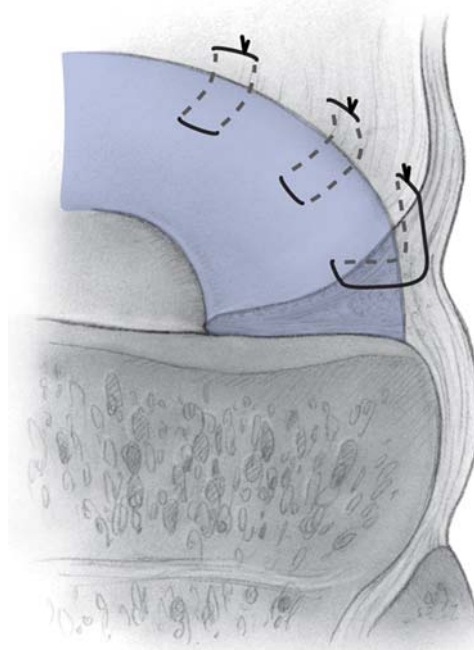


FIG. 6-B

**Fig. 6-A** The meniscal allograft is tightly sutured to the meniscal rim. **Fig. 6-B** Horizontal sutures are driven through the meniscal rim one by one in an all-inside fashion from inferior to superior in a sequence from posterior to anterior.

trimmed, preferably to a stable meniscal rim with a scalpel anteriorly and with arthroscopic instruments posteriorly. Most often, the insertion of the posterior horn is still intact and in continuity with the tibial plateau. The insertion of the posterior horn is also trimmed to fit the allograft. The meniscal rim deserves surgical attention as it serves as a strong envelope encapsulating the medial or lateral compartment of the knee.

The level of the meniscus remnant is then marked with a small mosquito clamp anteriorly as a landmark for the correct level of subsequent fixation of the allograft. Next, the previously prepared viable lateral meniscal allograft is introduced into the lateral compartment (Fig. 5-C). The sutures are taken from the holder in the correct sequence from posterior to anterior and are driven through the meniscal rim one by one in an all-inside fashion from inferior to superior and are transferred to a second suture holder (Holder B), again in a sequence from poste-

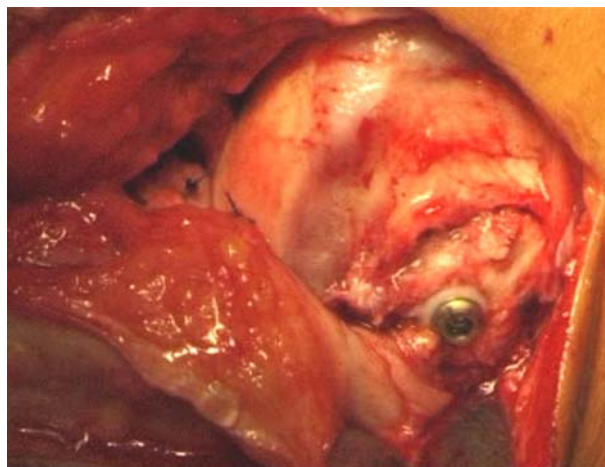
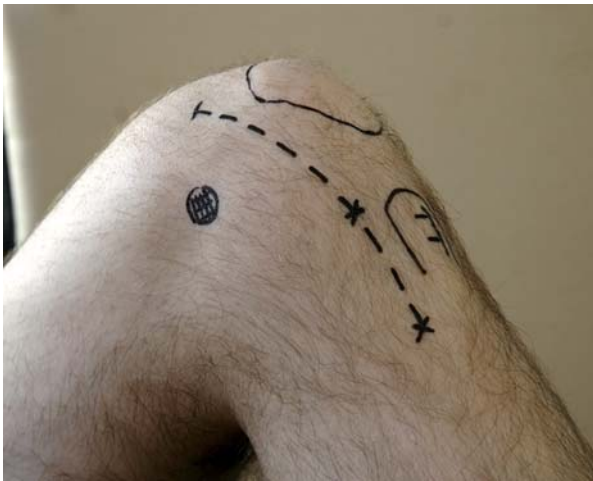

FIG. 7

The bone block with the insertions of the lateral collateral ligament and popliteus tendon is repositioned and fixed with a 35 or 40-mm 2.9 AO cancellous screw with a spiked washer.

rior to anterior (Figs. 6-A and 6-B). The allograft is also sutured to the popliteus tendon. We have found, on follow-up arthroscopy, that the popliteal hiatus will recreate itself naturally. The insertion of the anterior horn of the meniscus is not yet sutured at this stage of the operation. Once the sequence of suture transfer from Holder A through the meniscal rim (and popliteal tendon) to Holder B is completed, the allograft is introduced into the lateral compartment by gently pulling on each suture in a sequence from posterior to anterior. Generally, this procedure must be performed progressively to establish a secure fit of the allograft to the meniscal rim. The suture knots are then securely tied and cut. A fine-tipped suture-driver and knot-pusher frequently are required to securely tighten the posterior sutures. The knee is now positioned again in a normal 90° flexed position. The bone block with the insertion of the lateral collateral ligament and popliteus tendon is repositioned and fixed with use of a 35 or 40-mm 2.9 AO cancellous screw with a spiked washer (Fig. 7).

The anterior horn of the allograft is then su-



**FIG. 8**

A curvilinear medial parapatellar incision, approximately 8 cm in length, is made with the knee positioned in 90° of flexion. The anatomical landmarks for this incision are the tibial tuberosity (TT) and the superomedial corner of the patella. The incision can easily be extended distally in the case of an associated opening-wedge tibial osteotomy or an anterior cruciate ligament reconstruction procedure.

## CRITICAL CONCEPTS | continued

### PITFALLS:

The primary goal of long-term successful meniscal allograft transplantation is good fixation in order to obtain stable healing and ingrowth of the allograft. Two requirements must be fulfilled in order to achieve this goal. First, the posterior rim of the meniscal remnant should not be transected or resected during débridement. It is our conviction that this rim not only serves as an important envelope that encapsulates the knee joint compartment and thus prevents excessive extrusion of the graft, but, secondly, that it also provides a site for anatomical and stable fixation of the allograft. Several *in vitro* studies have shown that graft fixation with use of bone plugs is superior to graft fixation without use of bone plugs<sup>12-15</sup>. However, those studies did not take into account the biological healing process of the allograft to the meniscal rim. The bone-plug fixation procedure itself induces damage to the tibial articular cartilage surface and potentially damages the femoral side as a result of incongruity if the original anatomy is not duplicated<sup>16</sup>. Moreover, bone-plug fixation necessitates the need for near-perfect allograft sizing. Not using bone-plug fixation eliminates additional cartilage damage to the tibial plateau and simplifies custom tailoring of the allograft to the joint compartment. Therefore, we still prefer the use of all-inside sutures to the use of bone-plug fixation techniques or arthroscopic suture techniques with arrows or darts. This open technique also facilitates addressing small osteophytes on the femoral condyle or tibial plateau, which could cause mechanical impingement and subsequent early failure of the allograft.

Axial malalignment has been shown to result in a higher failure rate and a shorter survival time<sup>6,9,10</sup>. Therefore, a corrective osteotomy is indicated in these cases. However, caution is needed because architectural changes such as flattening of the condyle frequently already are established in varus malaligned meniscectomized knees. As these changes are believed to be contraindications to meniscal transplantation, an additional corrective osteotomy will not make these knees suitable for a meniscal allograft transplantation<sup>7</sup>.

*continued*

tured to the original insertion of the meniscus remnant with use of polypropylene or polydioxone suture material. The Hoffa fat pad and the knee capsule are closed with use of interrupted Vicryl 1-

0 cross stitches (Ethicon) after hemostasis.

### *Medial Meniscal Allograft Transplantation*

A medial parapatellar incision, approximately 8 cm in length, is made with the knee in 90° of flexion to gain access to the medial compartment of the knee joint (Fig. 8). The anatomical landmarks for this incision are the tibial tuberosity and the superomedial corner of the patella. The curvilinear incision is made 1 cm medial to these landmarks,

starting 2 cm proximal to the superomedial corner of the patella and ending at the level of the tibial tubercle. When an associated tibial osteotomy or cruciate ligament reconstruction is planned, the incision can be extended distally on the medial side of the tibia. This allows a high opening-wedge osteotomy or the harvest of the hamstrings and tibial drilling/tunneling for the cruciate ligament reconstruction.

The knee capsule is subsequently opened, and the anterior horn of the medial meniscus

remnant is transected. To allow the medial compartment to be opened further, the medial collateral ligament is detached on the femoral side with an osteotome<sup>3</sup>. A flake osteotomy (0.5 to 1 cm in thickness) is performed with a straight osteotome at the level of the medial femoral epicondyle. The soft tissues posterior to the medial collateral ligament are left in continuity. After the knee is gently placed in a valgus position, the medial compartment can be opened in a controlled fashion.

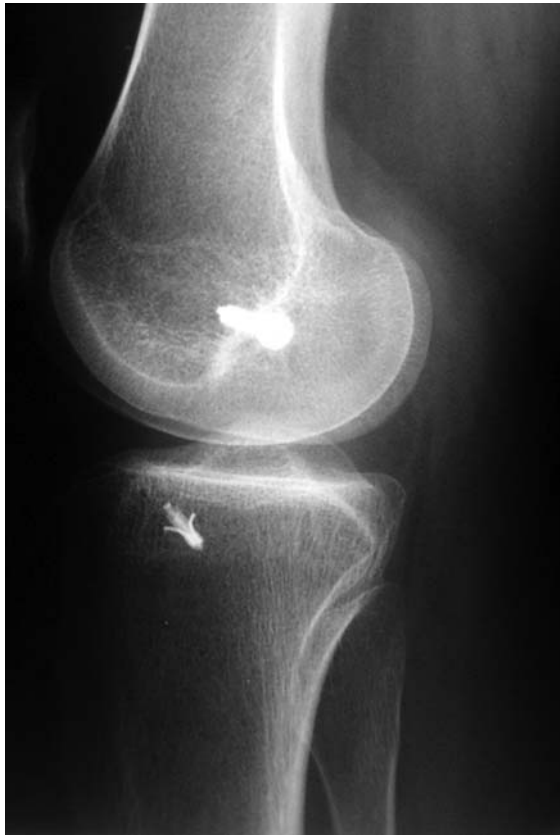

FIG. 9-A

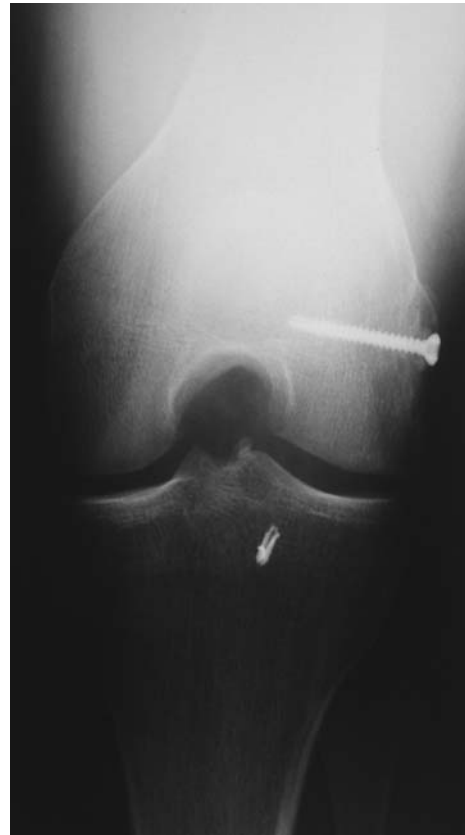

FIG. 9-B

**Figs. 9-A and 9-B** Lateral and anteroposterior standing radiographs, made one year after lateral viable meniscal allograft transplantation, showing the additional fixation of the anterior horn of the meniscal allograft with an anchor and the fixation of the lateral collateral ligament/popliteus tendon osteotomy with a screw and washer.



**CRITICAL CONCEPTS** | continued**AUTHOR UPDATE:**

To further improve the results of viable meniscal allograft transplantation, we have modified some aspects of the procedure since the time of the original study.

Initially, focal articular cartilage defects that were observed during the preoperative arthroscopic or magnetic resonance imaging evaluation would have been left untreated because no surgical treatment was considered successful at that time. Extended defects or generalized compartmental degeneration were, and still are, considered to be contraindications<sup>6,7</sup>. More recently, numerous surgical procedures have been described for the treatment of focal symptomatic articular cartilage lesions, with encouraging results. These treatments are based on the transplantation of autologous osteochondral plugs (mosaicplasty), bone marrow stimulation (microfracture), or the transplantation of isolated chondrocytes<sup>17-20</sup>. The current tendency at our department is to fully treat the associated articular cartilage defects, the correct timing of which (either prior to, in association with, or after the meniscus allograft transplantation) is still controversial and very much dependent on the intended treatment. We prefer to use a microfracture technique for smaller surface articular cartilage defects and chondrocyte implantation for larger defects. Ultimately, additional controlled studies will be needed to analyze any additional beneficial effect of such associated cartilage treatment. For now, however, the articular surface restoration techniques do not allow extension of the indications for a

meniscal allograft transplantation in patients with extended cartilage defects or generalized compartmental degeneration.

Another recent modification to the allograft transplantation procedure itself is the additional fixation of the anterior horn of the medial or lateral allograft to the original anatomical position of the native meniscus with use of an anchor (GII; DePuy Mitek, Raynham, Massachusetts) (Figs. 9-A and 9-B). A previous study at our institution demonstrated extrusion of the anterior horn of the lateral allograft compared with the position of the anterior horn of a normal meniscus<sup>21</sup>. Although the anterior horn is biomechanically less important than the posterior horn is, we hope to reduce this extrusion and thus improve the overall biomechanics of the affected compartment by using this additional fixation device. Future analysis will allow us to come to a conclusion regarding its value.

In the presence of associated mild varus malalignment of the lower limb, we now prefer an opening-wedge osteotomy to a closing-wedge tibial osteotomy<sup>22</sup>. Recent advances in surgical techniques and instrumentation have enabled us to simply extend the medial incision distally to perform this associated procedure. This obviates the need for another, laterally based incision and its potential wound problems. Furthermore, the postoperative rehabilitation protocol of viable meniscus allograft transplantation is not influenced or delayed by this associated opening-wedge osteotomy.

The remnant of the medial meniscus is trimmed, prefera-

bly to a stable meniscal rim, with use of a scalpel anteriorly

and with use of arthroscopic instruments posteriorly. The same degree of attention should be paid to this meniscal rim as is the case during a lateral meniscal transplantation.

The prepared meniscal allograft can be introduced into the medial joint compartment and fixed in a manner similar to that described previously for the lateral meniscal allograft transplantation.

The knee is then repositioned in 90° of flexion.

If an associated high tibial osteotomy<sup>4</sup> or anterior cruciate ligament reconstruction<sup>5</sup> is planned, these procedures can easily be performed after the posterior horn and body of the meniscal allograft are sutured but before refixation of the osteotomy site, fixation of the anterior meniscal allograft horn, and closure of the capsule.

Finally, the osteotomized medial collateral ligament bone block is repositioned and fixed with use of a bone staple.

The anterior horn of the medial allograft is sutured to the original meniscal remnant as is done for the lateral meniscal transplant, and the capsule is further closed with use of Vicryl 1-0.

Peter C.M. Verdonk, MD  
Alex Demurie, MD  
Karl Fredrik Almqvist, MD, PhD  
Eric M. Veys, MD, PhD  
Gust Verbruggen, MD, PhD  
René Verdonk, MD, PhD

Departments of Orthopaedic Surgery (P.C.M.V., A.D., K.F.A., and R.V.) and Rheumatology (E.M.V. and G.V.), Ghent University Hospital, De Pintelaan 185, B-9000 Ghent, Belgium. E-mail address for P.C.M. Verdonk: pverdonk@yahoo.com

In support of their research for or preparation of this manuscript, one or more of the authors received grants or outside funding from the Fund for Scientific Research (F.W.O.-Vlaanderen), Flanders, Belgium. None of the authors received payments or other benefits or a commitment or agreement to provide such benefits from a commercial entity. No commercial entity paid or directed, or agreed to pay or direct, any benefits to any research fund, foundation, educational institution, or other charitable or nonprofit organization with which the authors are affiliated or associated.

The line drawings in this article are the work of Joanne Haderer Müller of Haderer & Müller (biomedart@haderermuller.com).

doi:10.2106/JBJS.E.00875

## REFERENCES

1. Verdonk PC, Demurie A, Almqvist KF, Veys EM, Verbruggen G, Verdonk R. Transplantation of viable meniscal allograft. Survivorship analysis and clinical outcome of one hundred cases. *J Bone Joint Surg Am.* 2005;87:715-24.
2. Verbruggen G, Verdonk R, Veys EM, Van Daele P, De Smet P, Van den Abbeele K, Claus B, Baeten D. Human meniscal proteoglycan metabolism in long-term tissue culture. *Knee Surg Sports Traumatol Arthrosc.* 1996;4:57-63.
3. Goble EM, Verdonk R, Kohn D. Arthroscopic and open surgical techniques for meniscus replacement—meniscal allograft transplantation and tendon autograft transplantation. *Scand J Med Sci Sports.* 1999;9:168-76.
4. Coventry MB. Osteotomy of the upper portion of the tibia for degenerative arthritis of the knee. A preliminary report. *J Bone Joint Surg Am.* 1965;47:984-90.
5. Vorlat P, Verdonk R, Arnauw G. Long-term results of tendon allografts for anterior cruciate ligament replacement in revision surgery and in cases of combined complex injuries. *Knee Surg Sports Traumatol Arthrosc.* 1999;7:318-22.
6. Wirth CJ, Peters G, Milachowski KA, Weismeier KG, Kohn D. Long-term results of meniscal allograft transplantation. *Am J Sports Med.* 2002;30:174-81.
7. Noyes FR, Barber-Westin SD. Irradiated meniscus allografts in the human knee. A two to five year follow-up study. *Orthop Trans.* 1995;19:417.
8. Noyes FR, Barber-Westin SD, Rankin M. Meniscal transplantation in symptomatic patients less than fifty years old. *J Bone Joint Surg Am.* 2004;86:1392-404.
9. de Boer HH, Koudstaal J. Failed meniscus transplantation. A report of three cases. *Clin Orthop Relat Res.* 1994;306:155-62.
10. Cameron JC, Saha S. Meniscal allograft transplantation for unicompartmental arthritis of the knee. *Clin Orthop Relat Res.* 1997;337:164-71.
11. van Arkel ER, de Boer HH. Survival analysis of human meniscal transplantations. *J Bone Joint Surg Br.* 2002;84:227-31.
12. Paletta GA Jr, Manning T, Snell E, Parker R, Bergfeld J. The effect of allograft meniscal replacement on intraarticular contact area and pressures in the human knee. A biomechanical study. *Am J Sports Med.* 1997;25:692-8.
13. Huang A, Hull ML, Howell SM. The level of compressive load affects conclusions from statistical analyses to determine whether a lateral meniscal autograft restores tibial contact pressure to normal: a study in human cadaveric knees. *J Orthop Res.* 2003;21:459-64.
14. Chen MI, Branch TP, Hutton WC. Is it important to secure the horns during lateral meniscal transplantation? A cadaveric study. *Arthroscopy.* 1996;12:174-81.
15. Alhalki MM, Howell SM, Hull ML. How three methods for fixing a medial meniscal autograft affect tibial contact mechanics. *Am J Sports Med.* 1999;27:320-8.
16. Lazovic D, Wirth CJ, Sieg A, Gosse F, Maschek HG. [Effect of surgical technique on meniscus transplants. A histological, animal experiment study]. *Unfallchirurg.* 1997;100:541-6. German.
17. Hangody L, Fules P. Autologous osteochondral mosaicplasty for the treatment of full-thickness defects of weight-bearing joints: ten years of experimental and clinical experience. *J Bone Joint Surg Am.* 2003;85 Suppl 2:25-32.
18. Steadman JR, Briggs KK, Rodrigo JJ, Kocher MS, Gill TJ, Rodkey WG. Outcomes of microfracture for traumatic chondral defects of the knee: average 11-year follow-up. *Arthroscopy.* 2003;19:477-84.
19. Knutsen G, Engebretsen L, Ludvigsen TC, Drogset JO, Gronthvedt T, Solheim E, Strand T, Roberts S, Isaksen V, Johansen O. Autologous chondrocyte implantation compared with microfracture in the knee. A randomized trial. *J Bone Joint Surg Am.* 2004;86:455-64.
20. Peterson L, Brittberg M, Kiviranta I, Akerlund EL, Lindahl A. Autologous chondrocyte transplantation. Biomechanics and long-term durability. *Am J Sports Med.* 2002;30:2-12.
21. Verdonk P, Depaeppe Y, Desmyter S, De Muynck M, Almqvist KF, Verstraete K, Verdonk R. Normal and transplanted lateral knee menisci: evaluation of extrusion using magnetic resonance imaging and ultrasound. *Knee Surg Sports Traumatol Arthrosc.* 2004;12:411-9.
22. Franco V, Cerullo G, Cipolla M, Gianni E, Puddu G. Open wedge high tibial osteotomy. *Tech Knee Surg.* 2002;1:43-53.