

# Seminars in Cardiothoracic and Vascular Anesthesia

<http://scv.sagepub.com>

---

## The Failing Heart Under Stress: Echocardiography is an Essential Monitoring Tool in the Intensive Care Unit

Jan Poelaert

*Semin Cardiothorac Vasc Anesth* 2006; 10; 111

DOI: 10.1177/108925320601000118

The online version of this article can be found at:  
<http://scv.sagepub.com/cgi/content/abstract/10/1/111>

---

Published by:

 SAGE Publications

<http://www.sagepublications.com>

Additional services and information for *Seminars in Cardiothoracic and Vascular Anesthesia* can be found at:

**Email Alerts:** <http://scv.sagepub.com/cgi/alerts>

**Subscriptions:** <http://scv.sagepub.com/subscriptions>

**Reprints:** <http://www.sagepub.com/journalsReprints.nav>

**Permissions:** <http://www.sagepub.com/journalsPermissions.nav>

**Citations** (this article cites 28 articles hosted on the SAGE Journals Online and HighWire Press platforms):  
<http://scv.sagepub.com/cgi/content/abstract/10/1/111#BIBL>

# The Failing Heart Under Stress: Echocardiography is an Essential Monitoring Tool in the Intensive Care Unit

Jan Poelaert, MD, PhD

**Echocardiography has been evolving to play a pivotal role in hemodynamic management, both intraoperatively and at the bedside. A full assessment of hemodynamics necessitates the use of all of the options available on modern echocardiographs. This introductory review provides insight into three important issues of hemodynamic monitoring by echocardiography: evaluation of preloading conditions, assessment of systolic function, and contractility and estimation of afterload. Mastering these three features will help in a minimally invasive approach of hemodynamic instability.**

Echocardiography has evolved to become a major diagnostic tool in the practice of cardiology. In critically ill patients, however, echocardiography has progressively become a cornerstone in hemodynamic management and decision-making. The transthoracic and transesophageal approaches are of tremendous help in the daily intraoperative decision-making that occurs in all hemodynamically devastating surgery. In addition, these techniques are even more helpful in the intensive care unit (ICU), where a rapid and correct diagnosis of the cause of the hemodynamic instability is warranted.

Evaluation of hemodynamics with echocardiography is unthinkable without pulsed wave, continuous wave, and tissue Doppler. The explanation and differences between these techniques is beyond the scope of this paper, but the reader is referred to review articles.<sup>1</sup>

Circulatory failure is most often due to cardiac (ventricular) failure, usually evidenced as a

significant reduction of the pumping activity of one or both ventricles. Table 1 depicts various causes of pump failure. Circulatory failure can also be caused by sepsis and septic shock, which have been clearly related with congestive heart failure, even in patients without previous myocardial infarction.<sup>2</sup> An imbalance between preload and afterload is another example of where assessment of basic hemodynamics plays a pivotal role.<sup>3</sup>

Three variables determine left ventricular systolic performance: (1) the Frank Starling mechanism, provided by pressures and volumes, (2) heart rate, and (3) contractility as a load-independent descriptor of systolic function. Pressure monitoring is still routinely used when a patient with hemodynamic deterioration is evaluated. Nevertheless, pressures only provide a rudimentary approach of the three physiologically important features of contractility, preload, and afterload. The combined use of pressures and flows, obtained with Doppler echocardiography, provides elementary and far more interesting data on hemodynamics than pressures alone. The assessment of hemodynamics in the ICU is strongly based on these characteristics and is the main topic of this review.

## Assessment of Preloading Conditions

As already stated, intracardiac and intrapulmonary pressures provide only a limited part of the correct assessment of preload. Nevertheless, it is important to correctly characterize preloading conditions, especially in patients with large fluid shifts. Optimal preload is the first measure to be taken when stabilizing a hemodynamically unstable patient, and this is a relatively inexpensive measure. Pressure can definitively be estimated by Doppler echocardiography, as described previously in the literature.<sup>4-10</sup>

The short-axis view with two-dimensional echocardiography offers an immediate visualiza-

---

From the Cardiac Anesthesia and Postoperative Cardiac Surgical ICU, University Hospital Ghent, Ghent, Belgium

This work was supported by an unrestricted grant of the International Research Center, Ghent University, Ghent, Belgium

Address reprint requests to Jan Poelaert, MD, PhD, Cardiac Anesthesia and Postoperative Cardiac Surgical ICU, University Hospital Ghent, De Pintelaan 185, 9000 Ghent, Belgium; e-mail: jan.poelaert@ugent.be

©2006 Westminster Publications, Inc., 708 Glen Cove Avenue, Glen Head, NY 11545, USA

**Table 1.** Examples of Causes of Pump Failure of One or Both Ventricles

- 
- Ischemic heart disease
  - Myocardial disease
  - Pericardial disease
  - Pressure overload
    - o Left ventricle: high afterload: stress, high dose of vasopressor
    - o Right ventricle: pulmonary hypertension, pulmonary emboli, adult respiratory distress syndrome; asthma bronchial, chronic obstructive lung disease exacerbation
  - Volume overload
    - o Presence of intracardiac shunts (atrial septum defect, ventricular septal defect)
- 

tion of the filling of the left and right ventricles. The presence of kissing walls of the left ventricle in an adequately sedated patient, in the absence of sympathetic stimulation and without any support of inotropic drugs, is the signature of a low filling status.<sup>11</sup> In that case, a fluid challenge is the first choice of therapy, which can be readily obtained in a sedated patient by raising the legs.

Several drawbacks of the short-axis view as a measure of preloading condition have to be taken into account. The presence of regional wall motion abnormalities will certainly hamper the correct interpretation of the preloading conditions related to the end-diastolic area of the left ventricle. Another issue is the presence of dilated cardiomyopathy. In this particular case, passive leg raising could be a dangerous maneuver.<sup>12,13</sup> However, ventilation-induced systolic variation of pressure or flow across the aortic valve could be of significant help, suggesting a sign of fluid responsiveness.

The value of systolic pressure and stroke volume variation is well established and has been assessed by many authors.<sup>14-16</sup> Cyclic altering of intrathoracic pressure induces this variation of pressure and flow. It was clearly shown that the variation of the transaortic flow velocity integral increased considerably with a graded hemorrhage in an animal experimental setting.<sup>17</sup>

Finally, the variation of the inferior vena cava flow with transthoracic echocardiography and superior caval vein flow with transesophageal echocardiography<sup>18</sup> during (spontaneous) venti-

lation is another signature of low preloading conditions. Nevertheless, inferior caval vein collapsibility works only in conventionally ventilated patients and not in patients who are receiving high-frequency oscillatory ventilation.<sup>19</sup>

## Contractility

Ventricular function can be described in terms of load-dependent and load-independent variables (Table 2).<sup>20,21</sup> As described previously,<sup>22,23</sup> the short-axis view of the left ventricle is the basic view and start of each echocardiographic examination. This basic view allows the assessment of three important features of hemodynamics: global contractility, left ventricular preload, and the presence of regional wall motion abnormalities.

**Table 2.** Load-Dependent and Load-Independent Descriptors of Ventricular Function

---

### Load-dependent variables

- Ejection fraction:  $EF = (LVEDA - LVESA) / LVEDA$
- Cardiac index:  $CO = (HR \times SV) / BSA$
- Stroke volume:  $SV = TVI \times CSA$
- $(+dP/dt)_{max}$ , when a leakage of the mitral or aortic valve is present
- Myocardial performance index<sup>20</sup>:  $MPI = (ICT + IRT) / ET$
- S wave (tissue Doppler imaging)<sup>21</sup>

### Load-independent variables

- Velocity of circumferential fiber shortening
  - Preload-adjusted maximal power and preload-adjusted peak power
  - Maximal elastance  $E_{max}$
  - Preload recruitable stroke work  
 $(dP/dt)_{max} / EDV$
- 

EF, ejection fraction of the left ventricle (%); LVEDA, left ventricular end-diastolic area, taken at the short axis view ( $cm^2$ ); LVESA, left ventricular end-systolic area (same view as LVEDA) ( $cm^2$ ); CO, cardiac output ( $L/min.m^2$ ); HR, heart rate (beats/min); SV, stroke volume (mL); BSA, body surface area ( $m^2$ ); TVI, time velocity integral (cm); CSA, cross-sectional area ( $cm^2$ ); MPI, myocardial performance index; ICT, isovolumic contraction time (milliseconds); IRT, isovolumic relaxation time (milliseconds); ET, ejection time (milliseconds);  $(dP/dt)_{max} / EDV$ , maximal  $dP/dt$ , corrected for end-diastolic volume ( $mm\ Hg/s.cm^3$ ).

Although the variables explained in Table 2 provide more extensive information, it is evident that these parameters also have more scientific merits than direct routine monitoring.

In clinical practice, the intensivist relies more on direct observation to clearly identify differences between normal function, hypercontractile ventricles, and ventricles with decreased function. In any hemodynamic deterioration, an arterial pressure is warranted, offering information concerning global systolic function, stroke volume, and filling. If hypotension is combined with a normal left ventricular function in a hemodynamically unstable patient, it is evident that other causes of this hemodynamic deterioration should be explored. Furthermore, hypotension in conjunction with a hyperdynamic left ventricle suggests either an overdose of inotropic support or low filling status.

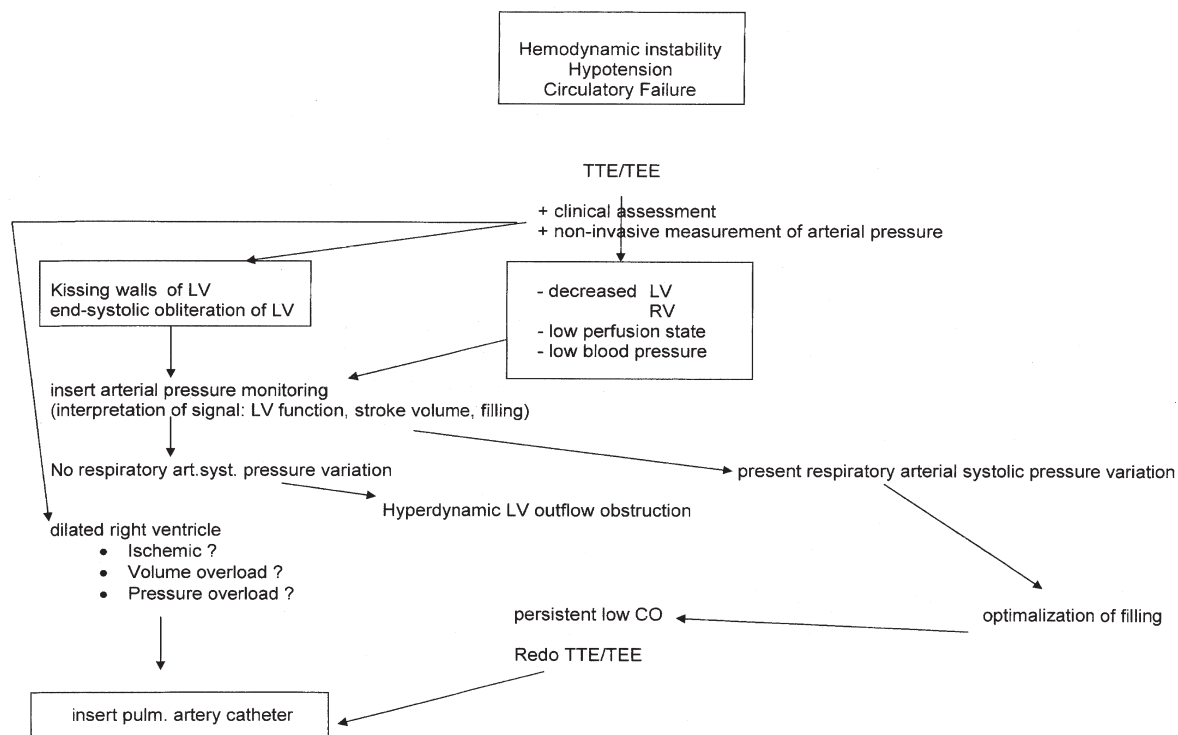
Finally, hypotension and decreased left ventricular function warrants further echocardiographic investigation, as described in Figure 1. In any case, right ventricular function also has to be assessed. A complete echocardiogram, comprising evaluation of regional wall motion abnormalities and valvular function is then justified.

After initial treatment, guided by both arterial pressure tracing and an echocardiogram, more continuous hemodynamic monitoring can be established, when appropriate. A central venous catheter, including oximetry, or a pulmonary artery catheter, including mixed venous oximetry, could further help to monitor the critically ill patient.

The combined use of arterial pressure monitoring and echocardiography provides important information for determining left ventricular systolic

### Afterload

The combined use of arterial pressure monitoring and echocardiography provides important information for determining left ventricular systolic



**Figure 1.** Working scheme to utilize echocardiography as a monitoring tool in a hypotensive patient. TTE, transthoracic echocardiography; TEE, transesophageal echocardiography; LV, left ventricle; RV, right ventricle.

function. In particular, various contractility indices and afterload can be readily described by combining pressure and flow, derived easily from these two features.

Because total arterial compliance is shown to be an important cardiovascular risk factor,<sup>24</sup> the importance of determination of afterload cannot be denied. The main determinants of afterload are systemic vascular resistance and total arterial compliance, which reflect the static and pulsatile components of arterial load, respectively.<sup>25,26</sup> Recently, Heerman et al<sup>27</sup> demonstrated that thoracic aortic compliance can be determined off-line by using local pressure and flow and by applying the arc-tangent model of Langewouters<sup>28,29</sup> in vivo.

## Conclusions

Although echocardiography provides significant help in the diagnosis of most cardiac diseases, the combined use of pressure values and echo Doppler offers pivotal information on hemodynamics in a rapid manner. The weakest factor is probably estimation of preload in a dilated left ventricle, although a positive answer to the rapid filling test with a decrease of the systolic respiratory flow variation across the aortic valve is indicative of fluid responsiveness. It is important to combine systemic pressure values and flow across the aortic valve to obtain extensive information about systolic function parameters and afterloading conditions in critically ill patients.

## References

- Garcia M, Thomas J, Klein A: New Doppler echocardiographic applications for the study of diastolic function. Review article. *J Am Coll Cardiol* 32:865-875, 1998.
- Vasan RS, Sullivan LM, Roubenoff R, et al: Inflammatory markers and risk of heart failure in elderly subjects without prior myocardial infarction: The Framingham Heart Study. *Circulation* 107:1486-1491, 2003.
- Mebazaa A, Karpati P, Renaud E, et al: Acute right ventricular failure—from pathophysiology to new treatments. *Intensive Care Med* 30:185-196, 2004.
- Appleton C, Galloway J, Gonzalez M, et al: Estimation of left ventricular filling pressures using two-dimensional and Doppler echocardiography in adult patients with cardiac disease. Additional value of analyzing left atrial size, left atrial ejection fraction and the difference in duration of pulmonary venous and mitral flow velocity at atrial contraction. *J Am Coll Cardiol* 22:1972-1982, 1993.
- Ito T, Suwa M, Otake Y, et al: Left ventricular Doppler filling pattern in dilated cardiomyopathy: Relation to hemodynamics and left atrial function. *J Am Soc Echocardiogr* 10:518-525, 1997.
- Jardin F, Fourme T, Page B, et al: Persistent preload defect in severe sepsis despite fluid loading: A longitudinal echocardiographic study in patients with septic shock. *Chest* 116:1354-1359, 1999.
- Kuecherer HF, Muhiudeen IA, Kusumoto FM, et al: Estimation of mean left atrial pressure from transesophageal pulsed Doppler echocardiography of pulmonary venous flow. *Circulation* 82:1127-1139, 1990.
- Nagueh S, Middleton K, Kopelen H, et al: Doppler tissue imaging: A noninvasive technique for evaluation of left ventricular relaxation and estimation of filling pressures. *J Am Coll Cardiol* 30:1527-1533, 1997.
- Schiller N: Pulmonary artery pressure estimation by Doppler and two-dimensional echocardiography. *Cardiol Clin* 8:277-287, 1990.
- Vieillard Baron A, Schmitt JM, Beauchet A, et al: Early preload adaptation in septic shock? A transesophageal echocardiographic study. *Anesthesiology* 94:400-406, 2001.
- Leung JM, Levine EH: Left ventricular end-systolic cavity obliteration as an estimate of intraoperative hypovolemia. *Anesthesiology* 81:1102-1109, 1994.
- Borow KM, Neumann A, Marcus RH, et al: Effects of simultaneous alterations in preload and afterload measurements of left ventricular contractility in patients with dilated cardiomyopathy: Comparisons of ejection phase, isovolumetric and end-systolic force-velocity indexes. *J Am Coll Cardiol* 20:787-795, 1992.
- De Hert S, Vander Linden P, Ten Broecke P, et al: Assessment of length-dependent regulation of myocardial function in coronary surgery patients using transmitral flow velocity patterns. *Anesthesiology* 93:374-381, 2000.
- Coriat P, Vrillon M, Perel A, et al: A comparison of systolic blood pressure variations and echocardiographic estimates of end-diastolic left ventricular size in patients after aortic surgery. *Anesth Analg* 78:46-53, 1994.
- Perel A, Pizov R, Coté S: Systolic blood pressure variation is a sensitive indicator of hypovolaemia in ventilated dogs subjected to graded hemorrhage. *Anesthesiology* 67:498-502, 1987.
- Tavernier B, Makhotine O, Lebuffe G, et al: Systolic pressure variation as a guide to fluid therapy in patients with sepsis-induced hypotension. *Anesthesiology* 89:1313-1321, 1998.
- Slama M, Ahn J, Varagic J, et al: Long-term left ventricular echocardiographic follow-up of SHR and WKY rats: Effects of hypertension and age. *Am J Physiol Heart Circ Physiol* 286:H181-185, 2004.
- Vieillard-Baron A, Chergui K, Rabiller A, et al: Superior vena caval collapsibility as a gauge of volume status in ventilated septic patients. *Intensive Care Med* 30:1734-1739, 2004.
- Hruda J, Rothuis EG, van Elburg RM, et al: Echocardiographic assessment of preload conditions does not help at the neonatal intensive care unit. *Am J Perinatol* 20:297-303, 2003.

20. Poelaert J, Heerman J, Schupfer G, et al: Estimation of myocardial performance in CABG patients. *Acta Anaesthesiol Scand* 48:973-979, 2004.
21. Amà R, Segers P, Roosens C, et al: Effects of load on systolic mitral annular velocity by tissue Doppler imaging. *Anesthesia Analgesia* 99:332-338, 2004.
22. Poelaert J, Schmidt C, Colardyn F: Transoesophageal echocardiography in the critically ill. *Anaesthesia* 53:55-68, 1998.
23. Poelaert JI, Schupfer G: Hemodynamic monitoring utilizing transesophageal echocardiography: The relationships among pressure, flow, and function. *Chest* 127:379-390, 2005.
24. Stefanadis C, Dernellis J, Tsiamis E, et al: Aortic stiffness as a risk factor for recurrent acute coronary events in patients with ischaemic heart disease. *Eur Heart J* 21:390-396, 2000.
25. Molino P, Cerutti C, Juline C, et al: Beat-to-beat estimation of windkessel model parameters in conscious rats. *Am J Physiol Heart Circ Physiol* 274:H171-177, 1998.
26. Segers P, Verdonck P, Deryck Y, et al: Pulse pressure method and the area method for the estimation of total arterial compliance in dogs: Sensitivity to wave reflection intensity. *Ann Biomed Engin* 27:480-485, 1999.
27. Heerman JR, Segers P, Roosens CD, et al: Echocardiographic assessment of aortic elastic properties with automated border detection in an ICU: In vivo application of the arctangent Langewouters' model. *Am J Physiol Heart Circ Physiol* 288:H2504-2511, 2005.
28. Langewouters G, Wesseling K, Goedhard W: The static elastic properties of 45 human thoracic and 20 abdominal aortas in vitro and the parameter of a new model. *J Biomechanics* 17:425-435, 1984.
29. Langewouters G, Wesseling K, Goedhard W: The pressure dependent dynamic elasticity of 35 thoracic and 16 abdominal human aortas in vitro described by a five component model. *J Biomechanics* 18:613-620, 1985.