

6th congress of the European College of Equine Internal Medicine, 7-9 February 2013, Le Touquet, France

ECG in horses: technique and interpretation

Prof. dr. Gunther van Loon, DVM, PhD, Dip ECEIM, Ass Member ECVDI

Dr Lesley Young, BVSc DVA DVC Dip ECEIM PhD MRCVS

Introduction

Although cardiovascular causes of poor performance are fairly infrequent, many horses have cardiovascular dysfunction, including resting arrhythmias and cardiac murmurs and consequently the significance of these abnormalities can be difficult to determine. As a result cardiac disease can be blamed for loss of performance when it is completely innocent and conversely, on the rare occasion cardiac disease is performance limiting, it is not uncommon for it to be totally overlooked.

ECGs at rest and during exercise

The technique of taking a resting electrocardiogram (ECG) using a base-apex lead configuration is well established in equine practice. The technique is important to confirm the diagnosis of an arrhythmia and establish the exact origin within the heart. Ambulatory ECGs are used in case of a sustained arrhythmia, like atrial fibrillation, or to diagnose the origin of premature beats. Twenty-four hour ECG monitoring is often used to semi-quantify premature beats or to detect more rarely occurring arrhythmias.

The limitations of a resting ECG arise because of the enormous cardiac reserve of the horse which means that performance limiting cardiac disease, or abnormal rhythms during exercise, rarely manifest themselves at rest. This is compounded by the fact that alterations in resting cardiac rhythm are common in athletic horses because of their normal high parasympathetic tone. As a result, the effect of a resting arrhythmia on performance, or the effect of exercise on an arrhythmia, can only be established, if an ECG can be taken during appropriate exercise when sympathetic tone and myocardial oxygen demand are increased and parasympathetic influence is reduced.

In the past, exercising ECG examination, though described in the equine literature, was restricted to specialist centres or performance laboratories, due very high cost of radiotelemetric equipment. However the newest digital technology is increasingly affordable for equine veterinarians in practice and is consequently becoming part of the standard equipment for all equine clinics.

Methodology

The use of limb leads for recording ECG traces is not appropriate during exercise; wires and electrodes attached to the limbs are poorly tolerated, even at rest and movement artefact during exercise renders them entirely useless. In any event, limb leads, have no practical purpose in equids because the pattern of depolarization of the equine ventricle precludes using multiple vectors to assess cardiac size and mean electrical axis. Most commonly, only a simple positive-negative lead system is

used to record cardiac rhythm. As a result the base apex-lead, in which single electrodes are placed above and below the heart, is generally used as this lead system produces large complexes, which are easy to identify. One should realise that recording of additional leads may be useful in certain cases to facilitate the identification of specific complexes or rhythms. The additional lead recordings often show more movement artefacts and are most useful for ambulatory or 24-hour recordings.

For the conventional base apex lead placement the positive electrode is placed on the sternum and the negative electrode on the right jugular furrow. This recording is very useful at rest but shows more movement artefact during exercise. Electrode position is modified slightly for exercising recordings to reduce movement artefact caused by neck flexion and extension during movement. This more vertical modification of the familiar system still produces large 'QRS' deflections, but the atrial deflection ('P' wave) is slightly smaller in amplitude than that of a true base-apex configuration. Nevertheless the P wave will still be clearly visible. **Figure 1a** shows placement of 4 silver/silver chloride adhesive electrodes in a suitable configuration for recording an electrocardiogram during ridden exercise.

Figure 1a: Configuration of electrodes to record an ECG during ridden exercise

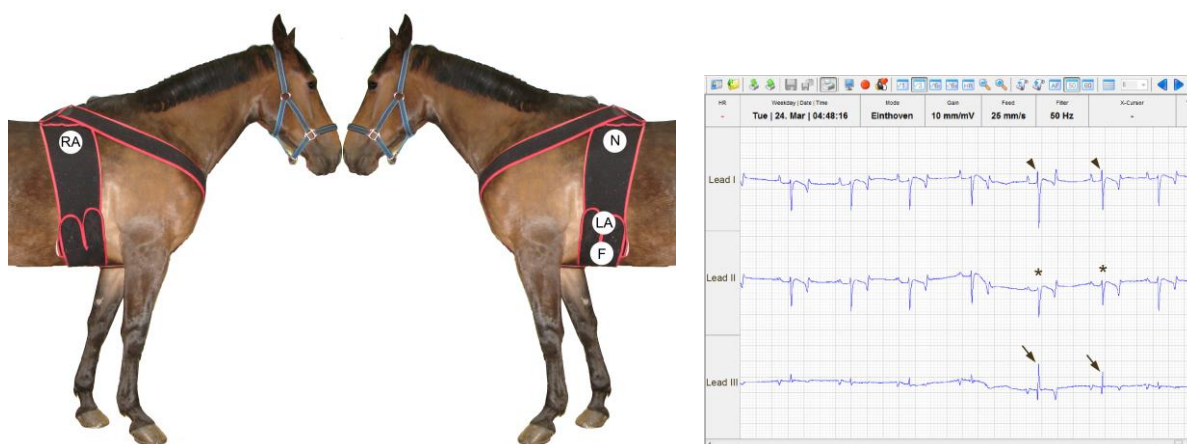

For 4- electrode systems as shown here, the foot electrode (or left leg) (usually green; European colour code) is positioned near to the left cardiac apex, and the right arm (usually red) is placed on the left shoulder area. The right arm (usually yellow) is also placed caudal to the cardiac apex. This allows 2 identical tracings to be obtained from lead 1 and lead 2 in the Einthoven 3-lead system, allowing for a "spare", should one of the ventral leads be displaced. The trace in Lead 3 which is recorded between the left arm and foot will be of no diagnostic value, due to the close apposition of these electrodes at

the cardiac apex. The fourth earth electrode, when present (usually black) is then attached on the shoulder close to the right arm electrode.

When positioning the left arm and foot electrode slightly apart (**Figure 1b**), so that the foot electrode is on the left thorax 5 cm below the elbow and the left arm is placed 15 cm dorsal to the foot electrode, lead I and II will be fairly similar but lead III can now also be used for interpretation. This configuration can be used during exercise but may show more movement artefacts, and is very useful at rest or during 24-hour ECG monitoring. The additional value of lead III facilitates differentiation between supraventricular and ventricular arrhythmias.

Figure 1b: Adapted electrode configuration that allows lead III to be of diagnostic value. The ECG on the right shows ventricular (!) ectopy (fusion beats) which is more easy to identify from lead III than from the other leads.



The precise positioning of the electrodes is of limited importance provided that the positive is below and slightly caudal to the heart, and negative above and slightly cranial to it. Ideally the electrodes should remain visible to the rider and/or the examiner, so that they can be reattached easily, should they become dislodged. A position where they are least likely to be affected by the saddle or girth slipping backwards, or by the rider's hands or legs is obviously ideal. The recording device can be attached to the metal "d" ring just below the pommel of most saddles. For lunging, harness racing, and carriage driving, the electrodes must be similarly positioned away from moving straps. The precise location of particularly the ventral electrodes or the device must often be varied slightly depending on the style of tack, or rider's leg position.

Diagnostic approach to exercising ECG's

Is essentially the same as for ECGs taken at rest and you must follow the same basic steps.

1) Is the trace of sufficient quality?

If the answer is "no", start again! Movement artefact is much greater during exercise and a bad situation is made worse in fat, barrel-chested horses, whose ECG's signal to noise ratio is already less

Lesley Young and Gunther van Loon – ECEIM Specialist day on Cardiology 2013

than in that of thin skinned athletic breeds. Use high quality, sticky electrodes, although in some hairy horses clipping will be necessary and then super glue (might result in permanent hair discoloration) will also be needed. In general it is better to avoid clipping, if at all possible, as the electrodes tend to stick better to hair. Always apply electrodes when the horse is dry and before it starts to sweat.

In some cases, trace quality may be adequate for most of the recording, but trace quality deteriorates, or an electrode becomes detached at some stage. When this happens judgement will be needed to determine whether the procedure needs to be repeated. If quality of the trace is poor be careful about making judgements about single abnormalities. Look for the same thing in a better quality section, or repeat the procedure.

2) Was the exercise you used appropriate for the horse

Try to simulate or exceed the horse's normal competition intensity, if the trainer/rider is not prepared to do this, you cannot be certain that abnormalities will not become apparent during competition and the value of the procedure is significantly limited. Including a recording during sudden stress (strange environment, excitement because of noise or another horse,...) is useful to assess cardiac rhythm as the horse is likely to face stressful situations during his on-going career.

3) Assess the horse's heart rate and determine whether it was appropriate for the work that was performed

Digital ECG units are equipped with algorithms to automatically detect the R wave, but during exercise, movement artefacts are inevitable and these automatic heart rate measurements should not be taken on trust. For horses in sinus rhythm, set the RR analysis software to detect complexes 10-15% shorter or longer than the preceding RR interval. Setting the detection at a low level will increase the sensitivity to detect arrhythmias but will also result in more detection of artefacts. However, in any case you will need visual inspection of the whole ECG trace. Wider detection limits are generally used for horses with sustained atrial fibrillation and you will need to rely on visual inspection alone. Use of a GPS speed monitor alongside the ECG, allows the horse's heart rate speed relationship to be determined simultaneously. This is invaluable to help to determine the significance of moderate acquired and congenital cardiac disease on performance and also for ruling the heart out as a cause of poor performance in many individuals.

2) Is there a P:QRS ratio of 1

Is there a P wave for every QRS complex and a QRS complex for every P wave with a stable PR relationship? P waves are harder to distinguish as heart rate increases and at very high heart rates, you will need to rely on the RR, or TT interval to determine whether underlying rhythm is sinus (Figure 2 a-d)).

3) What is the predominant rhythm?

Inspection of the regularity of the QRS complexes will indicate if there is a dysrhythmia present. Inspect the regularity and configuration of the QRS complexes and importantly the lengths of the RR intervals. The automated RR detection and summary screens greatly facilitate this processes in long recordings made during exercise (Figure 4). Remember that the normal sinus rhythm results in the narrowest QRS complex. Narrower and sharper deflections than the normal QRS complex are artefacts and these have no T-waves.

4) Equipment settings

Base-apex traces in horses at rest are normally recorded at a paper speed of 25mm/sec and a sensitivity that gives very large QRS deflections, however at high speed exercise, you may need to reduce QRS height and increase the sweep speed to 50 mm/s to make the trace easier to analyse. Use the summary screen, provided by the software to highlight irregularities and allow you to home in on abnormally shaped beats (Figure 4). Have the artefact filter set “on”, if available.

5) Get help

It takes time and lots of practice to develop the skills needed to analyse exercising ECG traces with confidence, so be prepared to get help from others who are more experienced. For a small charge, digital traces can be reviewed via email by experienced individuals, enabling you to ultimately develop the skills to analyse them yourself.

Figure 2: How does the ECG change with exercise

Figure 2a: Rest (under tack): Paper speed 25 mm/s sensitivity 10mm/mv: Normal sinus rhythm. The P waves are small due to the vertical position of the recording leads and the QRS height is also small to facilitate reading the trace once the horse starts to exercise

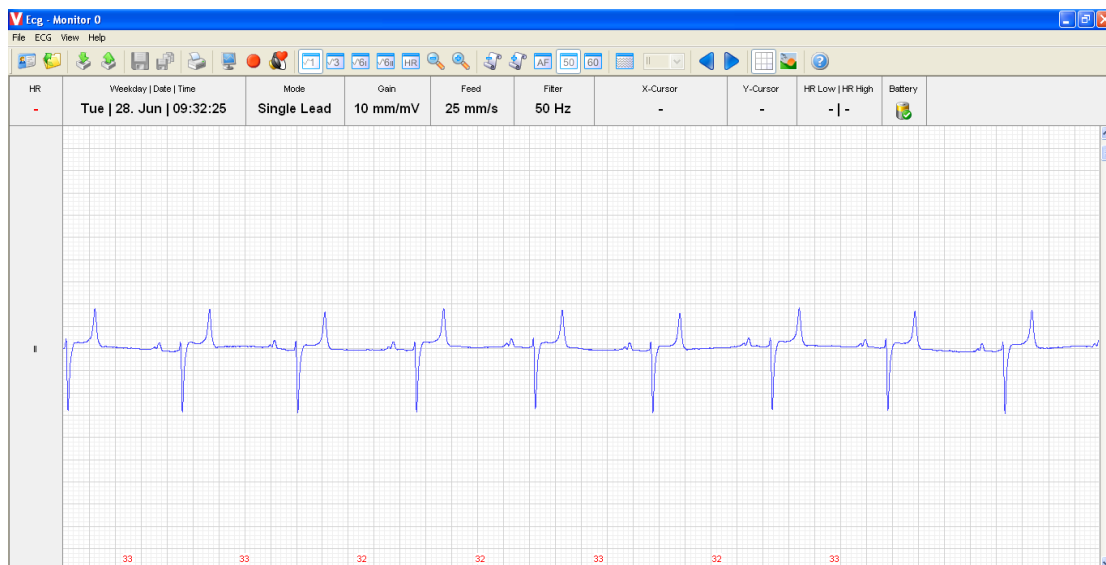

Figure 2b: Canter work to a peak speed of 11.6m/s (26 mph) on a 600m (3 furlong), inclined, all-weather gallop. The sensitivity of the ECG has been reduced yet further to reduce the impact of movement artefact. P waves are no longer visible, other than as an occasional small notch in the descending limb of the preceding T wave. Rhythm is regular and the complexes are the same shape and evenly spaced.

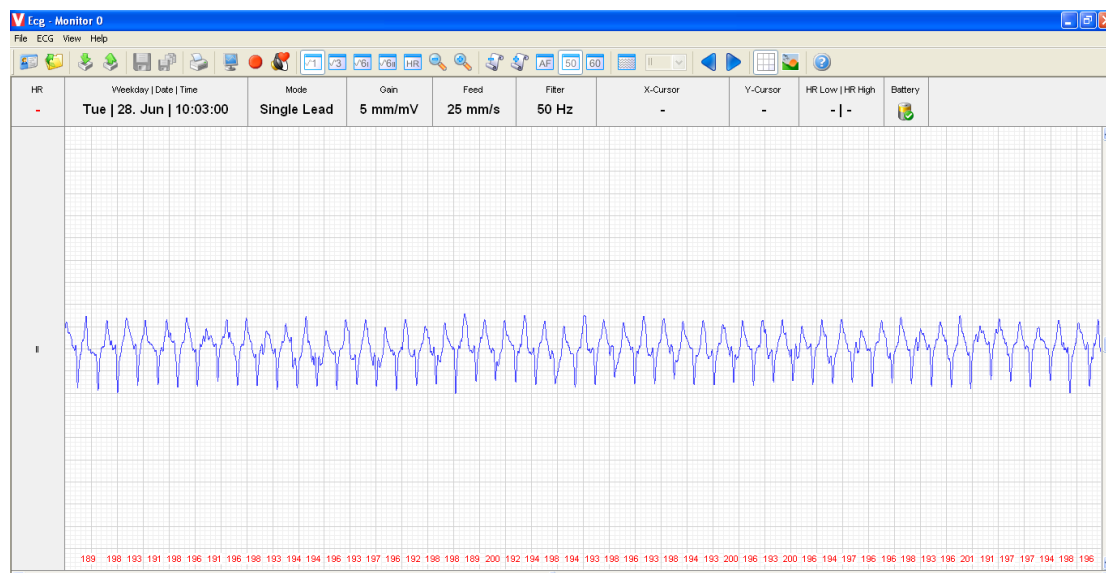


Figure 2c: Maximal speed of 17.5 m/s (39 mph) on an inclined, 1000m (5F), all-weather gallop. The paper speed has now been increased to 50 mm/sec to ensure that the RR detection system is correctly identifying the complexes. The system has identified the final complex in this segment as abnormal, but this is an artefact because the preceding complex has been missed by the system, due its smaller vertical height. Artefacts, like this, occur commonly in exercising traces, where movement will cause subtle alterations to the morphology of the QRS complex and confuse the automated RR detection system. It is therefore crucial to manually check each “abnormal” beat. In this case the RR interval is exactly double the sinus rate, so it is immediately obvious what has happened.

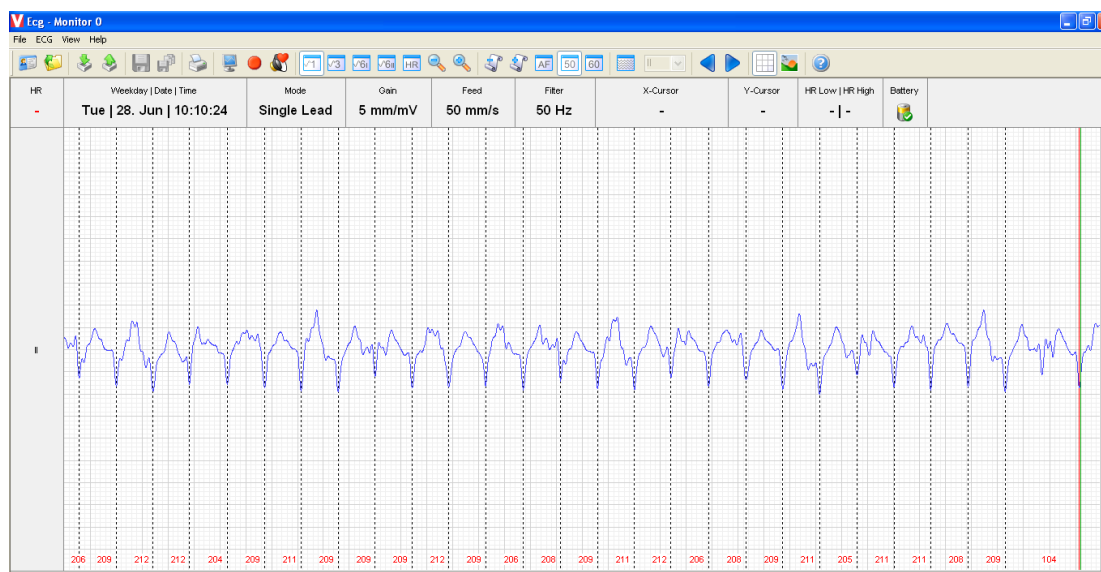


Figure 2d: 3 minutes' recovery (walk)

Despite being at a fairly good level of cardiovascular fitness, this horse's heart rate remained elevated above expected values, possibly indicating a larger than normal oxygen debt, heightened anxiety, or pain. Note that the P wave is now again visible in between the QRS complexes.

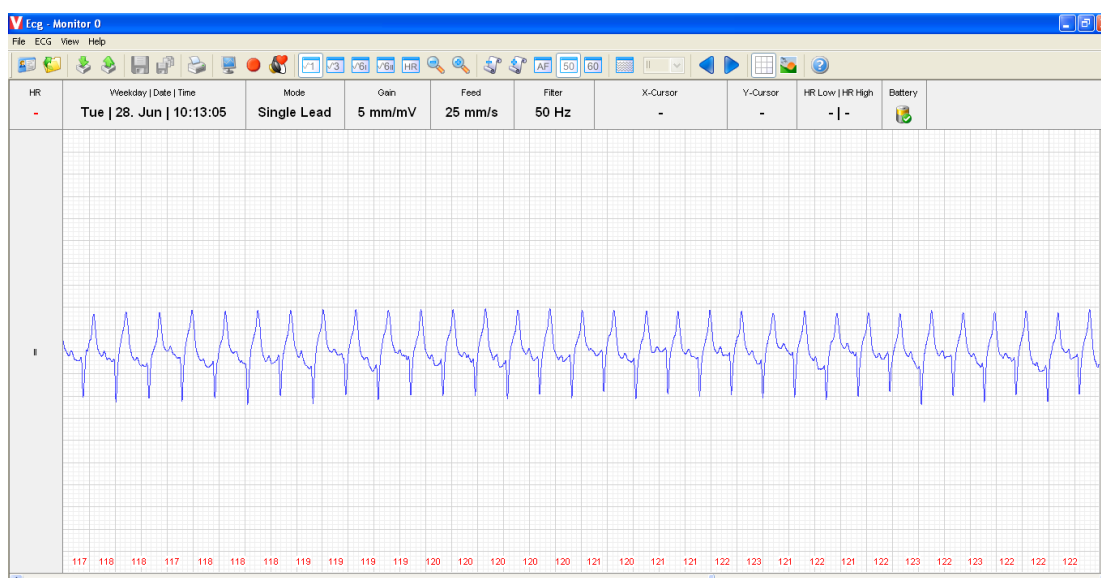


Figure 3: Concurrent heart rate speed relationship from the horse in Figure 2

As had been typical of this racehorse's recent fast work, during this procedure his jockey reported that the horse accelerated, then was unable to lengthen and became "legless" during his second piece of fast work on his usual 5 furlong inclined gallop. His jockey's verbal description is confirmed by the sudden increase and then immediate descent of his over-ground speed (blue line) at approximately 38 minutes (below). The horse's heart rate at this maximum speed of 17.5 m/s (39 miles per hour) was well below 200 beats per minute and although his heart rate continued to rise as his speed declined, it still remained at least 15 beats per minute below his age-corrected, maximum predicted value. His heart rhythm was entirely normal, despite him reproducing his clinical signs. Although a lag in heart rate versus speed is fairly typical of short bursts of anaerobic power, such as occur in sprinting, this horse's low heart rate remained below 215 beats per minute, suggesting that he was not being directly limited by his cardiovascular system. Ambulatory endoscopy was therefore recommended.

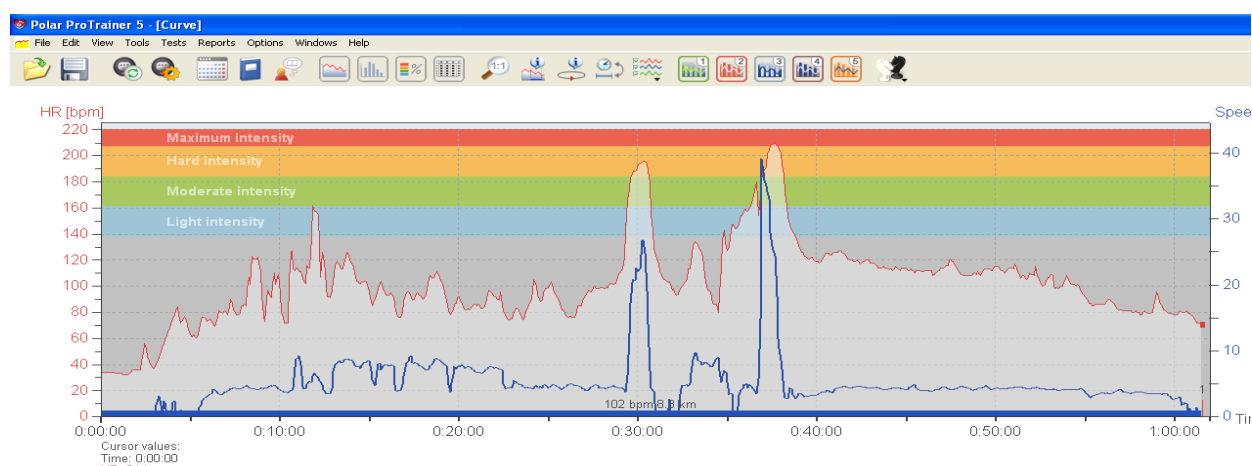
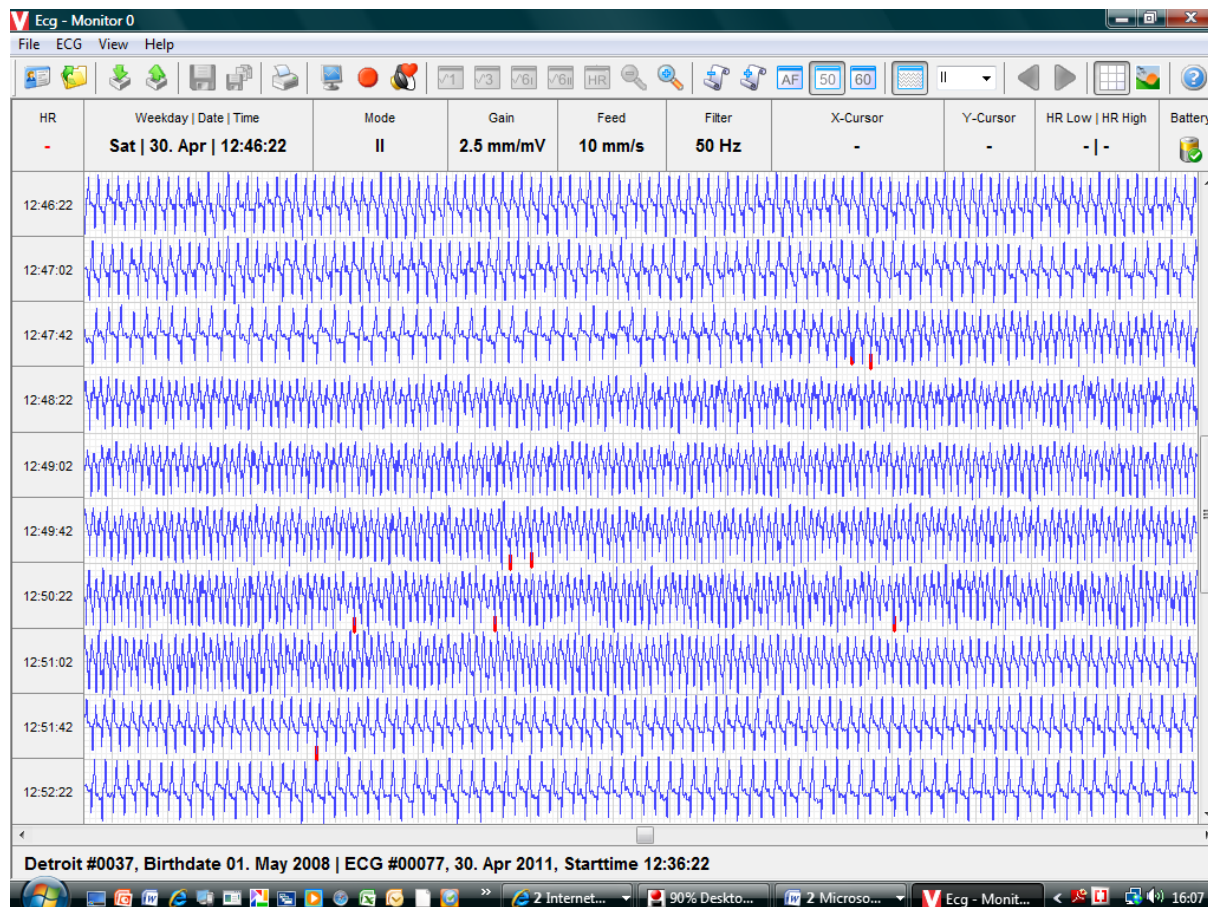


Figure 4: Televet summary screen with RR analysis employed on an exercising ECG recorded from a National Hunt Racehorse.

The Televet software has been set to detect 15% deviations from the preceding RR interval. Outlying RR intervals are identified by each red vertical line. Visual inspection of the summary trace allows abnormal complex shapes and unusual pause to be rapidly identified in long recordings. The operator can then expand the trace to assess each of the abnormal intervals identified by the software and any that appear suspicious to the eye.



Some common arrhythmias

It is well known that horses often present vagally induced arrhythmias at rest such as 2nd degree atrioventricular block, sinus (exit) block or sinus arrest. These should immediately disappear following stress or exercise.

1. Transient post exercise vagal rhythms:

Sinus arrhythmia is commonly encountered following exercise in the early recovery period. On auscultation the heart can be heard to slow in a stepwise fashion. The heart slows dramatically for a couple of beats then speeds up slightly, then slows again (Figure 5a). This sequence is repeated until a more stable rhythm is established. More unusually, atrioventricular or sinus block can resume when parasympathetic influence increases, even at a walk (Figure 5b). In isolation, these dysrhythmias are of no clinical significance.

Figure 5 a: Transient post exercise sinus arrhythmia

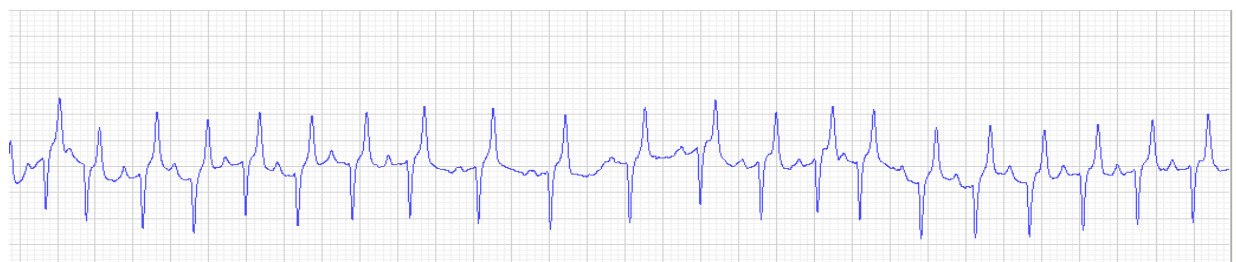
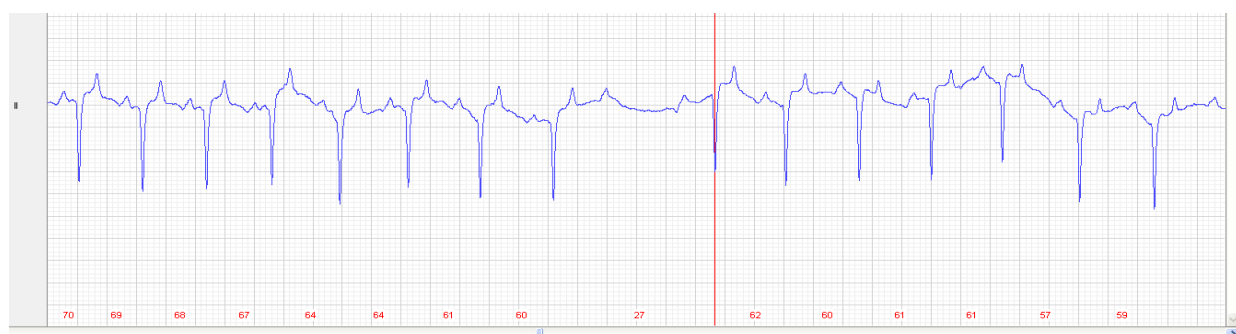
Figure 5 b: Transient post exercise atrioventricular block



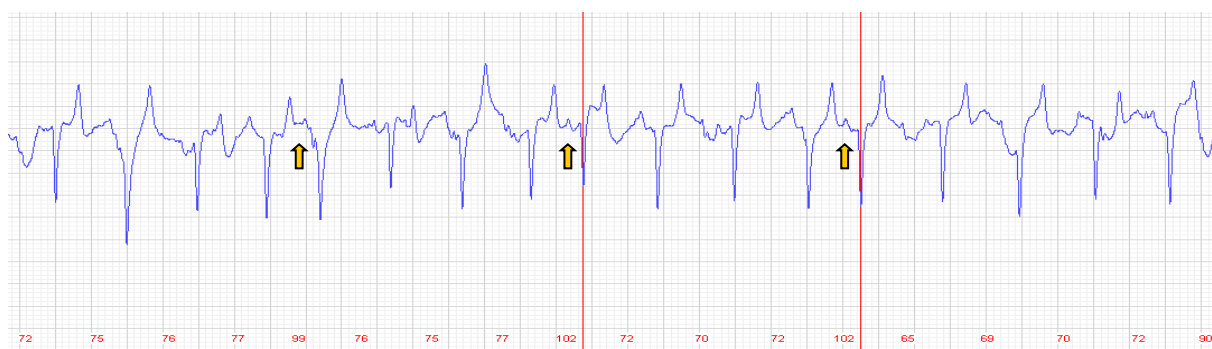
Premature atrial systoles

In horses with premature atrial systoles, P waves occur that are earlier than expected from the dominant underlying PP interval. If the P wave occurs after the refractory period of the AV node and ventricles, it is conducted and a normally configured QRS complex follows earlier than expected from the underlying R-R rhythm (Figure 6). If the P wave occurs during the refractory period of the AV node or ventricles the P wave is not conducted. In horses, like beats that are sinus in origin, the ectopic beat can also be blocked at the atrioventricular junction. The P wave of the premature complex may have a different configuration to the normal sinus P waves but can also be very similar
Lesley Young and Gunther van Loon – ECEIM Specialist day on Cardiology 2013

to it. Premature P waves are often 'lost' in the previous T wave causing it to have an abnormal configuration. An APC usually depolarises the sinoatrial node as well as the atrial myocardium so that its underlying rhythm of the node is then disrupted and it subsequently resumes its pacemaker activity earlier than it would, had the APC not occurred; this known as a non-compensatory pause. However, this sinus node resetting does not always occur, and APCs may be interlaced not disturbing the underlying rhythm, making their diagnosis sometimes challenging. At high heart rates atrial premature beats can be difficult to detect, because they are not followed by an obvious compensatory pause, which tend to be readily visible (see ventricular and junctional premature beats below). Because P waves are difficult to see anyway when heart rate and movement noise increase during exercise, identification of supraventricular arrhythmias during high speed exercise is very challenging. Finally, especially shortly coupled APCs, may result in changes in QRS amplitude (personal data). This change in morphology should not be misinterpreted as a ventricular premature beat.

Figure 6: Multiple atrial premature beats in a 6 year-old warmblood mare during dressage

Note how the automated RR detection software has failed to detect the first premature beat in this sequence because the detection limits were set too wide. At this heart rate, P waves are generally discernable, but note the normal configuration of the QRS complexes and the presence of the non-compensatory pause.



The significance of atrial premature beats

Isolated atrial premature beats are not infrequently encountered in horses and they present a serious dilemma to the veterinary surgeon. Usually specific anti-arrhythmic treatment is not indicated, as the premature beats are usually too infrequent to significantly affect cardiac output at rest. Clearly in these animals it is important to establish what happens to heart rhythm during exercise. In many cases when sinus rate exceeds the ectopic firing rate, cardiac rhythm & rate become normal. However, one should realise that atrial ectopy can be hard or even impossible to detect during exercise. Atrial premature beats are a trigger for atrial fibrillation and their presence increases the risk of the rhythm becoming established (Figure 7 a, b, c).

Figure 7a: Pre-exercise (under tack)

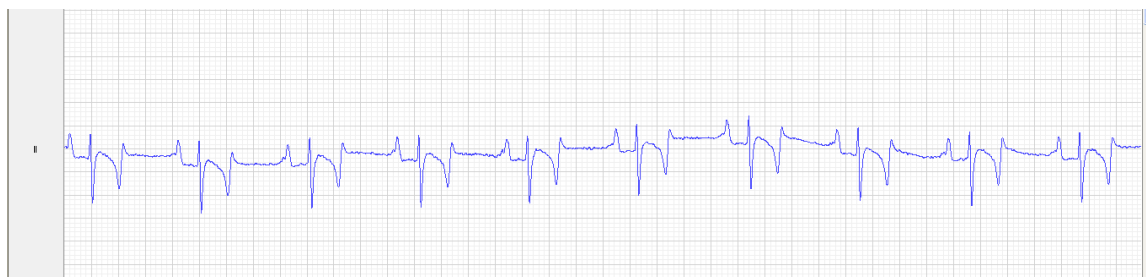

Figure 7b: Sudden acceleration (walk to gallop)

Trace quality deteriorates as the horse's speed increases towards the middle of the trace and although it is too noisy to discern P waves, the RR intervals become irregular, even though P waves were present at the start of the strip when the RR intervals are regular. Although a precise rhythm diagnosis is difficult because of the trace quality, there is a high index of suspicion that paroxysmal atrial fibrillation has developed.

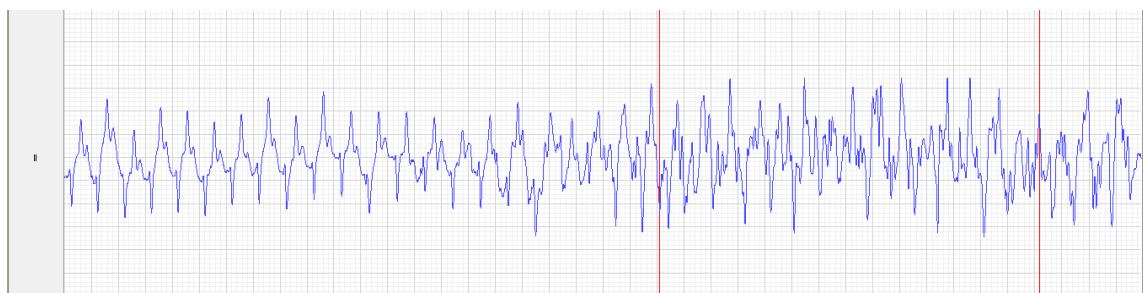
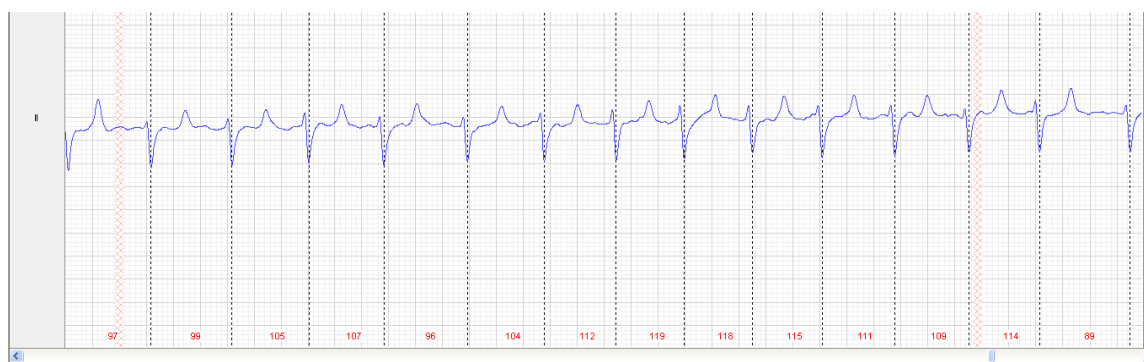


Figure 7c: The same horse as in Figure 7 c, 9 minutes' later. Irregular irregularity of the QRS complexes and an absence of P waves confirm that atrial fibrillation is indeed the dominant rhythm. By the next morning, the horse had returned spontaneously to normal sinus rhythm



Premature junctional and ventricular systoles

On ECG examination the QRS complex of a ventricular premature beat will have a wide bizarre configuration, because depolarisation does not follow the normal pathways (Figure 8a). The veterinary surgeon should realise that a normal shortening of the QRS complex occurs at shortened RR intervals. In addition, as is often the case in horses, when the complex originates from high in the His-Purkinje system or the AV junction, the ectopic complexes will not necessarily be wide and bizarre, as it will still be conducted using the normal pathways (Figure 8b). These complexes are however usually marginally taller than the normal QRSs. If the premature depolarisations are all originating from the same site, they will be of uniform shape (unifocal or uniform VPCs).

In the case of junctional and ventricular systoles the abnormal impulse will be conducted retrograde as far as the AV junction, but not across into the atria and thence to the SA node. The cardiac rhythm is broken by the premature beat of ventricular origin, but the normal sinus P wave, occurring just before, during, or just after the ventricular premature complex, falls upon the refractory period of the ventricle and therefore cannot elicit a ventricular response. Consequently and in contrast to supraventricular premature complexes, the rhythm of the sinus node has not been disrupted and the PP intervals remain constant throughout. This is known as a compensatory pause and it is this relatively long pause after the premature beat that almost always catches the eye on an ECG recording and is rarely missed by automated detection algorithms. This atrioventricular dissociation and the resultant compensatory pauses are the hallmarks of ventricular prematurity and points to a ventricular origin, regardless of complex shape. Similar as for APCs, on rare occasions, interlaced VPCs may occur, not disturbing the underlying rhythm and thus not resulting in a compensatory pause.

If there are multiple sites of ectopic activity, the abnormal QRS complexes will be of differing morphology (multifocal or multiform VPCs). If the premature QRS complex occurs during the preceding T wave, the vulnerable period of the cells, this may result in an R-on-T phenomenon. Such shortly spaced RR intervals represent a risk for the development of ventricular tachycardia and ventricular fibrillation which is a fatal rhythm. A series of 4 or more sequential premature ventricular systoles is termed ventricular tachycardia (see below) (Figure 8c).

Figure 8a: One of the single ventricular premature beats from the horse whose summary trace is shown in Figure 4. Note that the complex is wide and bizarre and it has occurred during exercise at the horse's predicted maximal heart rate of 235 bpm. Note also how the software has not detected the VPC itself but rather the pause associated with it. This is because at peak exercise, VPCs are rarely premature enough to materially affect the heart rate or fall outwith the detection limits of the RR analysis software. The second marked beat has also been wrongly identified by the analysis software, demonstrating how crucial it is to manually analyse these traces.

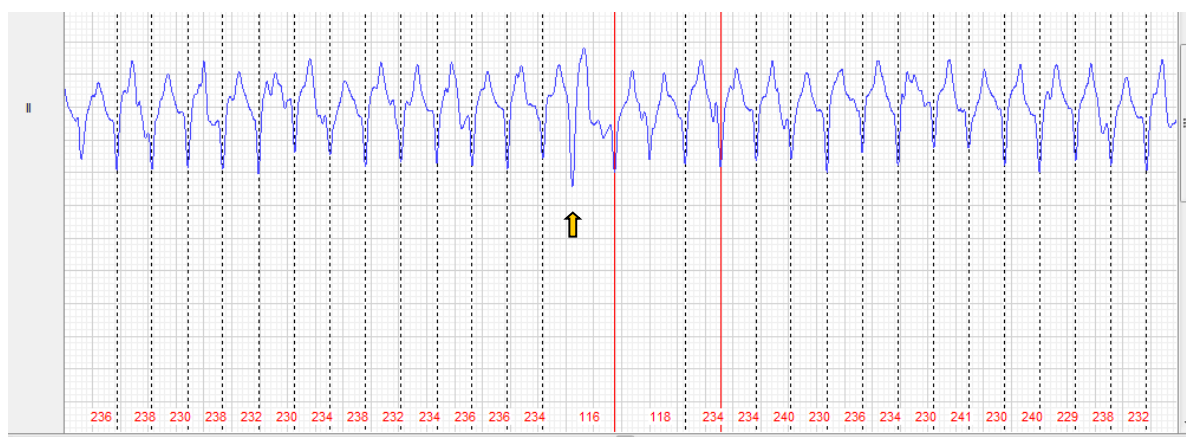


Figure 8b: A couplet (2) junctional premature beats during hack canter at submaximal heart rate

Note that the QRS complexes of these junctional premature beats are identical to the sinus beats, but the pause afterwards immediately identifies their origin to be below the Av node. As is often the case, these premature complexes are only very subtly premature, relative to the sinus rate (200 beats/minute), thus a detection limit of 15% will be insufficient for the automated detection algorithm to detect them. However use of lower values results in too many artefacts and 15% seems to represent a reasonable compromise.

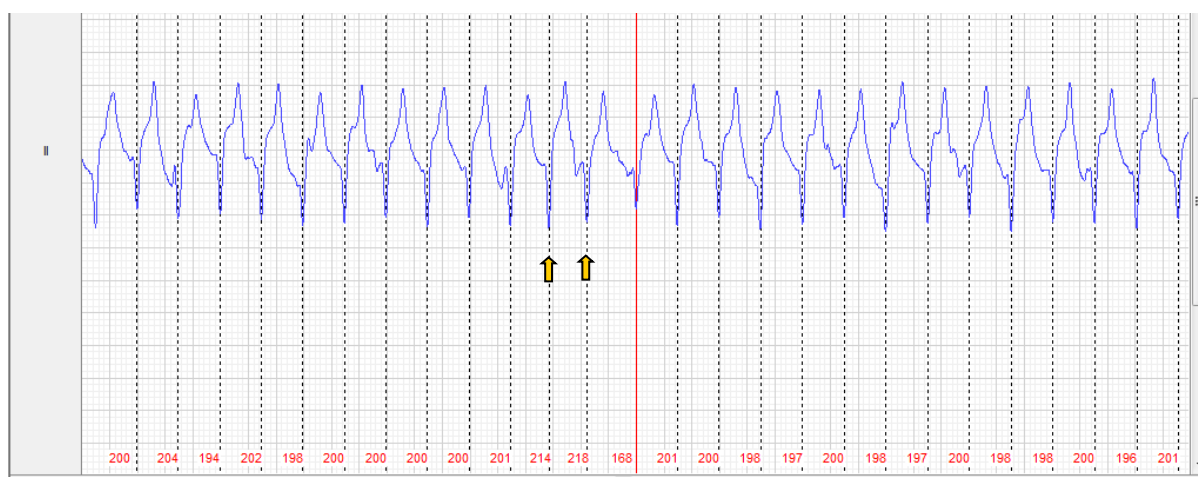


Figure 8c: Multiform ventricular tachycardia during exercise

Note the presence of runs of variable morphologies of QRS complexes.

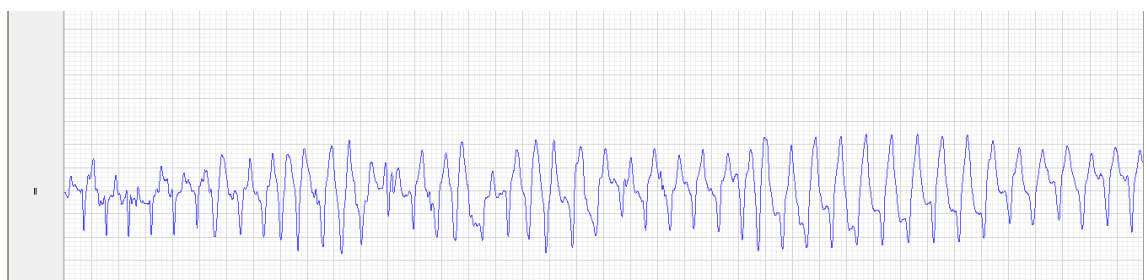
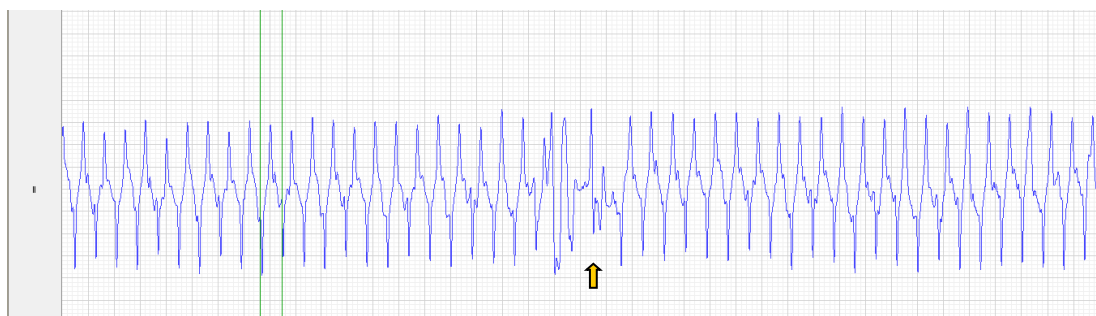


Figure 8d: A couplet of ventricular premature complexes is followed by another abnormal QRS complex (arrow) which could be a **ventricular fusion complex** (when a ventricular premature impulse and sinus impulse occur simultaneously, resulting in a morphology that is a mixture of both).



The significance of junctional and ventricular premature beats

Isolated ventricular premature beats are not infrequently encountered in horses during and after high speed exercise and occasionally in asymptomatic healthy horses at rest. Consequently they can present a serious dilemma to the veterinary surgeon. Usually specific anti-arrhythmic treatment is not indicated, as the premature beats are usually too infrequent to significantly affect cardiac output. Clearly in animals affected at rest it is very important to establish what happens to heart rhythm during exercise. In some cases when sinus rate exceeds the ectopic firing rate and parasympathetic tone is withdrawn, cardiac rhythm & rate become normal. Isolated and multiple ventricular ectopic beats are also commonly detected in horses during the immediate early slowing period after maximal exercise work and are generally considered as being normal in this context because they do not seem to be associated with primary cardiac disease and they should not be over-interpreted. Conversely, if they are present during exercise, the situation is more serious and the underlying cause should be sought and treated, if possible. In the meantime the horse must be retired from ridden work because an increased risk of ventricular fibrillation, collapse and death during exercise is potentially present. In

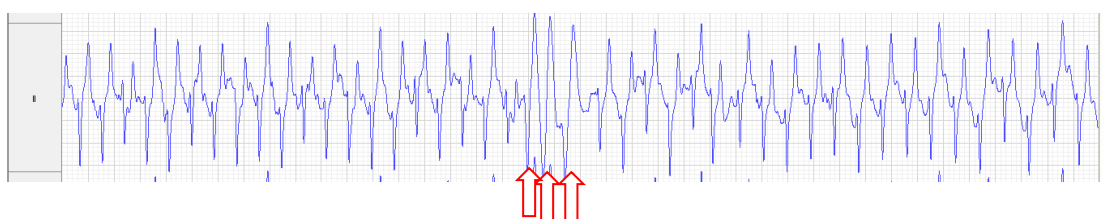
general when considering ventricular ectopic complexes, “judge them according to the company they keep”.

When is an exercising ECG indicated?

- High performance horses with **disappointing training or competition performance**. The procedure is performed to elucidate whether exercise-induced arrhythmias, such as paroxysmal atrial fibrillation or other arrhythmias are present and to ensure that the heart rate response to exercise is normal.
- Horse with **diastolic murmurs of aortic valve regurgitation** Advanced aortic valve regurgitation results in left ventricular dilation and thence increases cardiac work and afterload, thus directly increasing myocardial oxygen demand. Simultaneously, diastolic aortic pressure progressively decreases as valve dysfunction progresses, reducing coronary perfusion and myocardial oxygen delivery. Myocardial oxygen demand is yet further increased during exercise and, in advanced cases of aortic valve regurgitation, ventricular ischemia can lead to ventricular ectopic activity and increase the risk of sudden death, or collapse during exercise. These changes are often present before the onset of clinical signs of heart failure and, as a result, regular exercising ECG is mandatory in this group of patients, if they are to continue to be ridden.

Exercising electrocardiography **MUST** be performed alongside echocardiography to ensure that ventricular premature beats are not present during exercise and that these horses are not at an increased likelihood of and sudden death. If ventricular premature beats occur during appropriate ridden work these horse must be immediately retired.

Figure 9



The example shown here was taken from a 16 year-old Thoroughbred during fast work on an all-weather gallop (10mm/mV, 25 mm/s). There had been no change in the clinical characteristics of his grade 4/6 diastolic murmur over 3 years. His resting heart rate was 32 beats per minute with regular 2nd degree atrioventricular block.

The trace shows a triplet of ventricular ectopic beats. This triplet occurred at a heart rate of 168 beats per minute during hack canter. Multiple episodes of ventricular and junctional ectopic beats occurred during this exercise session, although the horse appeared clinically normal and had no history of poor performance.

- To assess the effect of exercise on an **abnormal rhythm at rest** in order to better determine the prognosis and the horse's suitability for ridden work.

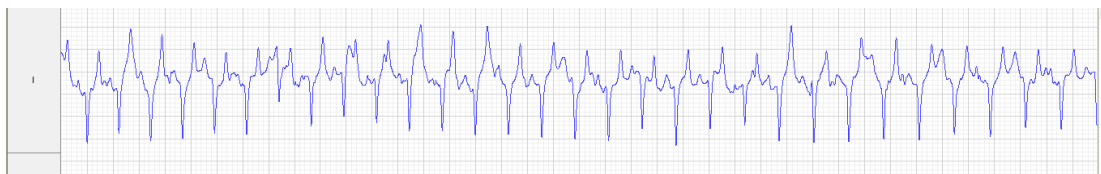
Figure 10a

This resting ECG (25mm/sec and 10mm/mV) was obtained from a 13 year-old cob after an abnormal rhythm was noted during auscultation before his annual vaccination. The horse was otherwise asymptomatic. There are multiple atrial premature beats (arrowed) present at rest.

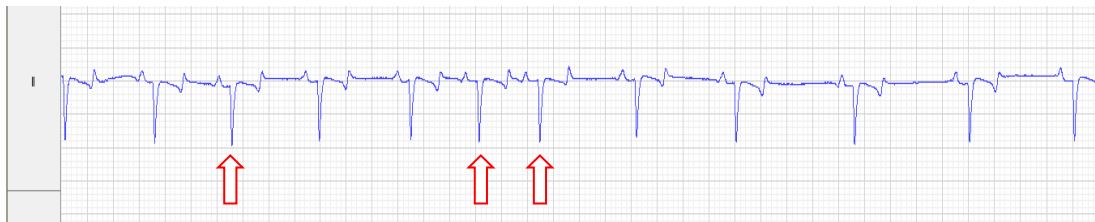

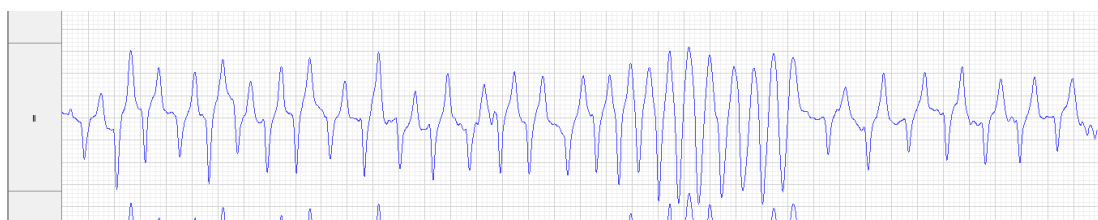
Figure 10b

The second trace comes from the same horse during strenuous lungeing exercise (heart rate 169 beats per minute). The rhythm is now entirely regular as the sinus node rate has now overridden the ectopic focus. The ectopic beats only returned some 15 minutes after the horse returned to his stable and his rate fell to below 60 beats per minute. Exercising ECG in this case allowed a favourable prognosis to be given to the owner, as the rhythm did not deteriorate during exercise and the horse remained in work.



- Assessment of horses with **sustained atrial fibrillation**. Conversion of atrial fibrillation to normal sinus rhythm is not always performed in pleasure horses as performance may be normal for the level of exercise. However, it is important to ensure that their heart rate response to exercise and stress is reasonable and that they do not suffer from uncontrolled supraventricular tachycardia and other malignant ventricular rhythms whilst ridden (**Figure 11**). This is crucial to ensure that any horse with AF is safe to continue in low intensity work without treatment, or after treatment has failed.

Figure 11



This trace was taken from a 6 year old Warmblood gelding used for dressage. An irregularly irregular rhythm was diagnosed when the horse was presented for a pre-purchase examination. There was no history of performance problems since the gelding had been imported from Holland a year previously. Resting heart rate was 38 beats per minute and resting ECG confirmed that the irregularly irregular rhythm was due to atrial fibrillation. The trace, taken during sustained canter, shows that the gelding develops a rapid supraventricular rhythm with a rate of almost 400 beats per minute that is sustained for 1.4 seconds. The complexes are wide and bizarre, but this is probably caused by aberrant conduction of the rapid supraventricular rhythm, rather than being of ventricular origin. Regardless of the actual rhythm diagnosis, ventricular filling and myocardial oxygenation would be severely compromised, if this rhythm and rate were sustained for any length of time and the horse is not therefore safe for his rider, unless his rhythm can be treated, despite the fact that the abnormal rhythm was not adversely affecting his performance. In this case, conversion to normal sinus rhythm was achieved with quinidine sulphate per os and a repeat ECG taken during similar strenuous exercise 18 weeks later was entirely normal.

- Assessment of horses affected by murmurs of mitral and tricuspid valve regurgitation and congenital heart disease in order to ensure that these horses' heart rate response to exercise is normal and that abnormal rhythms do not develop during exercise. It is unusual to find significant abnormalities in this group, but assessment of heart rate response to exercise is often useful to allay the safety and performance concerns of the owner/rider/trainer.

Conclusions

Given that the horse is endowed with a large cardiac reserve, evaluation of the equine cardiovascular system and electrocardiography (ECG) at rest only provides limited information, an ECG during exercise is an integral tool in the clinical evaluation of horses presented for episodes of exercise associated collapse, decreased exercise tolerance, poor athletic performance or cardiac murmurs. Recent technological advances now allow this technique to be easily performed in equine practice and the new devices are ideally suited to performing resting ECG and longer term monitoring. Importantly digital storage of the acquired ECG data, allows the traces to be easily transferred to a specialist cardiologist for help with interpretation, if required.

References

- Durando, M. Exercise and Stress testing. In: Marr CM and Bowen IM, editors. Cardiology of the horse 2nd Edition. Edinburgh, Elsevier, 2011, Chapter 11, 127 -139
- Ryan N, Marr CM, McGladdery AJ. Survey of cardiac arrhythmias during submaximal and maximal exercise in thoroughbred racehorses. *Equine Vet J*. May 2005;37(3):265-268
- Jose-Cunilleras E, Young LE, Newton JR, Marlin DJ. Cardiac arrhythmias during and after treadmill exercise in poorly performing thoroughbred racehorses. *Equine Vet J Suppl* 2006;163-170.
- Trachsel DS, Bitschnau C, Waldern N, Weishaupt, MA and Schwarzwald CC, Observer agreement for detection of cardiac arrhythmias on telemetric ECG recordings obtained at rest, during and after exercise in 10 Warmblood horses. *Equine Veterinary Journal* 2010, 42, (11) 208-215
- Buhl R, Meldgaard C, Barbesgaard L. Cardiac arrhythmias in clinically healthy showjumping horses. *Equine Vet J*. 2010 Nov;42 Suppl 38:196-201.
- Broux B., Verheyen T., Decloedt A., Vandervekens N., De Clercq D., van Loon G. (2013) Effect of coupling interval of atrial premature beats on S-wave amplitude variability in the horse. 6th ECEIM congress, Le Touquet, France, 8-9 February 2013
- Verheyen T., Decloedt A., van der Vekens N., Sys S., De Clercq D. (2012). Ventricular response during lungeing exercise in horses with lone atrial fibrillation. *Eq Vet J* doi: 10.1111/j.2042-3306.2012.00653.x