

WHITE NECROTIC TAIL TIPS IN ESTUARY SEAHORSES (*Hippocampus kuda* BLEEKER, 1852)

A.M. Declercq*, K. Chiers, W. Van den Broeck, A. Rekecki,
S. Teerlinck, F. Haesebrouck, A. Decostere

Faculty of Veterinary Sciences, Department Morphology,
Salisburylaan 133, 9820 Merelbeke, Belgium. Andclerc.declercq@ugent.be

White discoloration of the tail is a not seldom occurring phenomenon among seahorses kept in ornamental aquaria. In this study, three sea horses (*Hippocampus kuda*) presenting white patches on the distal part of the trunk and greyish-white necrotic tail tips were examined. Wet mount preparations of these lesions revealed ovoid to elongated ciliated protozoan structures. These ciliates could not be identified to species level but resembled species of the genus *Uronema* (Scuticociliatida). Samples of the affected skin were inoculated onto Marine agar (Difco) and *Flexibacter maritimus* medium (FMM, according to Pazos *et al.*, 1996). After 36h of incubation at 25°C, pale orange, convex colonies with a smooth surface appeared on both Marine agar and FMM in all sea horse tails. Gram-staining of these colonies showed Gram-negative, long (up to 8µm in length), slender bacterial cells. Biochemical tests designated these motile bacteria as non-fermenting, oxidase and catalase positive and resistant to the vibriostatic agent O/129. Sequence analysis of the 16SrRNA gene is on-going. Histological examination of the tail of two animals showed an ulcerative dermatitis consisting of desquamation/disappearance of the epidermis covered with necrotic debris. The latter contained numerous clusters of long (up to 8µm in length) slender bacteria, which were also invading the subcutaneous tissue. At these sites, an increase of proteoglycans, mild proliferation of blood vessels, limited to absent inflammation and invasion was noted. In areas where the epidermis was still intact, neutrophilic pustular lesions without bacterial infiltration were visible. In the third seahorse tail a granulomatous dermatitis was present. Bacteria (including acid-fast bacteria in Ziehl-Neelsen stained histological sections) were not observed. Scuticociliatosis caused by ciliates belonging to the order Scuticociliatida, is recognized as an emerging problem inflicting significant economic losses in aquaculture industry worldwide, for example, in the olive flounder farms in South Korea (Harikrishnan *et al.*, 2010). Heavy infections in Atlantic and Pacific marine fishes kept in aquaria were also reported. The significance of the isolated bacterial strain in the pathology described above remains to be elucidated and will largely depend on its ultimate identification.

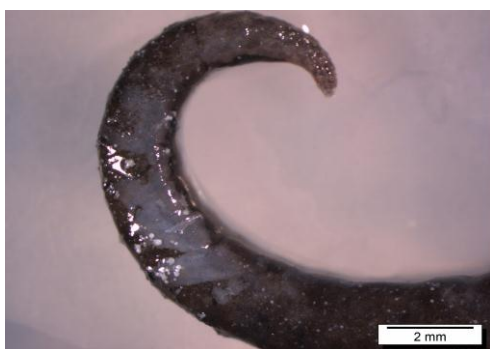

Fig. 1 : White discolored necrotic tail in a seahorse

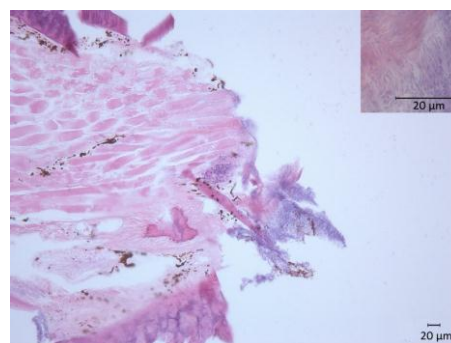


Fig. 2 : Ulcerative lesions with debris and bacterial cluster of slender, rod-shaped bacteria (inset)

References : Harikrishnan R., Balasundaram C. and Heo M.S., 2010. Scuticociliatosis and its recent prophylactic measures in aquaculture with special reference to South Korea Taxonomy, diversity and diagnosis of scuticociliatosis : Part I Control strategies of scuticociliatosis : Part II. *Fish Shellfish Immunology* 29 (1), 15-31. Pazos F., Santos Y., Núñez S. and Toranzo A.E. (1993). Characterization of *Flexibacter maritimus* isolated in northwest of Spain. Abstracts, 6th Int Conf Eur Ass Fish Pathol, Brest, France. European Association of Fish Pathologists, Brest, p. 8.

Acknowledgements : Many thanks go out to Jurgen De Craene, Lobke De Bels and Christian Puttevels for their technical assistance. We would also like to thank Prof. Simoens for critically reviewing this abstract. Financial support by the Special Research Grant (BijzonderOnderzoeksfonds, BOF, grant number 01Z06210) of Ghent University, Belgium is gratefully acknowledged.