

## Osteochondral fragments in the metacarpo- and metatarsophalangeal joint and their clinical importance

### *Osteochondrale fragmenten in het kogelgewricht en hun klinisch belang*

<sup>1</sup>J. Declercq, <sup>2</sup>S. Hauspie, <sup>2</sup>J. Saunders, <sup>1</sup>A. Martens

<sup>1</sup>Department of Surgery and Anesthesiology of Domestic Animals

<sup>2</sup>Department of Medical Imaging of Domestic Animals  
Faculty of Veterinary Medicine, University of Ghent  
Salisburylaan 133, B-9820 Merelbeke

[jeroen.declercq@UGent.be](mailto:jeroen.declercq@UGent.be)

#### ABSTRACT

The radiographic evaluation of the fetlock joint as part of a lameness or prepurchase examination often reveals osteochondral fragmentation. These fragments can either be causing lameness or have no clinical importance at the time of examination. However, they can cause lameness at a later stage. An appropriate analysis of the situation requires a correct assessment of the fragment type and an up-to-date knowledge of their possible clinical importance. In this overview, the most common types of fetlock fragments, such as dorsoproximal first phalanx (P1) and proximal synovial pad fragments, as well as fragmentation on the proximal palmar/plantar border of P1 and of the sesamoid bones are discussed. A few cases of uncommon large fragmentation on the abaxial borders of P1 are included. Fetlock fractures, obviously causing lameness, such as dorsofrontal fractures of the proximal phalanx, distal metacarpal/metatarsal and sesamoid bone fractures, are not dealt with in this review.

#### SAMENVATTING

Tijdens het radiografisch onderzoek van het kogelgewricht als onderdeel van een kreupelheids- of aankooponderzoek worden vaak osteochondrale fragmenten vastgesteld. Deze fragmenten kunnen de oorzaak van claudicatie zijn of op dat ogenblik geen enkel klinisch belang hebben. Sommige van deze fragmenten kunnen later wel aanleiding geven tot claudicatie. Om een correct advies te formuleren, moeten de verschillende types fragmenten goed van elkaar onderscheiden worden en moet men op de hoogte zijn van hun mogelijk toekomstig klinisch belang. In dit literatuuroverzicht worden de meest voorkomende types kogelfragmenten, zoals deze aan de dorsoproximale rand van P1, de proximale synoviale flapfragmenten, alsook de fragmentatie van de palmaro-/planteroproximale rand van P1 en van de sesambeenderen besproken. Daarnaast worden enkele gevallen van ongebruikelijke grote fragmentatie ter hoogte van de dorsale, abaxiale rand van P1 voorgesteld. Fracturen ter hoogte van de kogel met uitgesproken claudicatie, zoals dorsofrontale fracturen van P1, het distale pijpbeen en de sesamsbeenderen, komen hier niet aan bod.

#### INTRODUCTION

Diseases of the locomotory system are the most important cause of early retirement of horses (Rossdale *et al.*, 1985). Survey radiographs of the distal limbs are often taken as part of a lameness or a prepurchase examination. The goal of these prepurchase examinations is to identify abnormalities or potential problems that would make the horse unsuitable for the intended use (Van Hoogmoed *et al.*, 2003). Although the predictive value of certain radiographic findings is controversial, radiography has become an integral part of prepurchase examinations. As a result, the presence or absence of abnormalities on radiography has become an important economic factor in horse business (Van Hoogmoed *et al.*, 2003; Stock *et al.*, 2005).

The metacarpo-/metatarsophalangeal joint is an in-

tensely loaded, high-motion joint that is frequently injured in athletic horses (Richardson, 2003). Osteochondral fragments are frequently detected during the radiographic examination of the metacarpo-/metatarsophalangeal joint. When detecting these fragments during a lameness examination, the goal is to determine whether they are the cause of the lameness. However, they are also frequently identified in sound horses during prepurchase examinations. In a radiographical survey of 3749 young clinically healthy Warmblood horses, 20.7% had one or more fragments in one or more fetlocks (Stock *et al.*, 2005). When the fragments are identified, the examining veterinarian is asked to evaluate how these abnormalities will affect the future performance of the horse (Van Hoogmoed *et al.*, 2003).

The goal of the present paper is to summarize the different types of osteochondral fragments in the me-

tacarpometatarsophalangeal joint. Fractures obviously causing lameness, such as dorsal frontal fractures of the proximal phalanx, distal metacarpal/metatarsal and sesamoid bone fractures, are not discussed in this paper.

For all other fragment types, the prevalence, characteristics, nature and their clinical importance are discussed for different breeds of horses. The knowledge of several authors of whether these abnormalities will cause cartilage degeneration in the future is discussed. Osteochondral fragments are classified based on their localization and origin (Table 1).

## DORSAL OSTEOCHONDRAL FRAGMENTS

Osteochondral fragments at the dorsal aspect of the metacarpometatarsophalangeal joint are commonly observed in horses. Based on their location, three types of fragments have been described: osteochondral fragments originating from the dorsoproximal margin of the proximal phalanx (P1) (Carlsten *et al.*, 1993; Sandgren *et al.*, 1993; Kawcak and McIlwraith, 1994; Colon *et al.*, 2000), those originating from the distal dorsal aspect of the third metacarpal and metatarsal bones (McIII/ MtIII) (Yovich *et al.*, 1985; McIlwraith and Vorhees, 1990; Nixon, 1990; McIlwraith, 1993), and

fragments embedded in the dorsoproximal synovial pad of the fetlock joint (Declercq *et al.*, 2008).

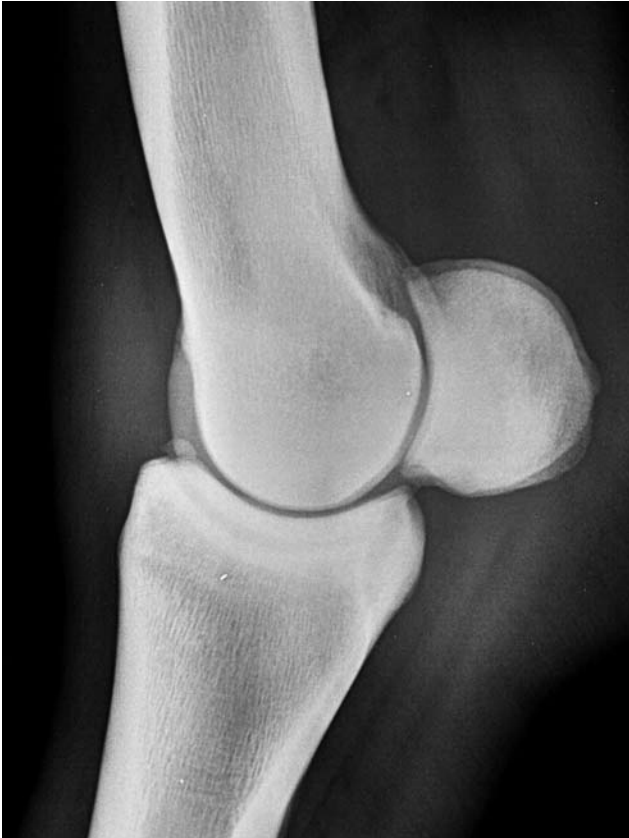## Dorsoproximal P1 fragments

The fragments at the dorsoproximal border of P1 were initially diagnosed in Thoroughbreds as 'chip fractures' responsible for lameness, pain at palpation over the fracture site and fluid distension of the fetlock joint (Adams, 1966). Typically, these fracture fragments involve the proximal eminence of P1 and are located medially to the sagittal ridge (Adams, 1966; Yovich and McIlwraith, 1986; Kawcak and McIlwraith, 1994; McIlwraith *et al.*, 2005). Acute fracture fragments show a well-defined fracture line on radiography, whereas they are more rounded in the chronic phase (McIlwraith *et al.*, 2005). Fracture fragments probably result from compression of the dorsoproximal portion of P1 against the distal dorsal third metacarpal/tarsal bone when hyperextension of the fetlock joint occurs during racing or fast training (Adams, 1966; Yovich and McIlwraith, 1986).

However, fragmentation at the dorsoproximal border of P1 (Figure 1a) is also observed in yearlings Thoroughbreds and Standardbreds that have not trained or raced before (Kane *et al.*, 2000; Torre and

**Table 1. Radiologic and clinical characteristics of the different types of osteochondral fragments in the metacarpometatarsophalangeal joint in horses**

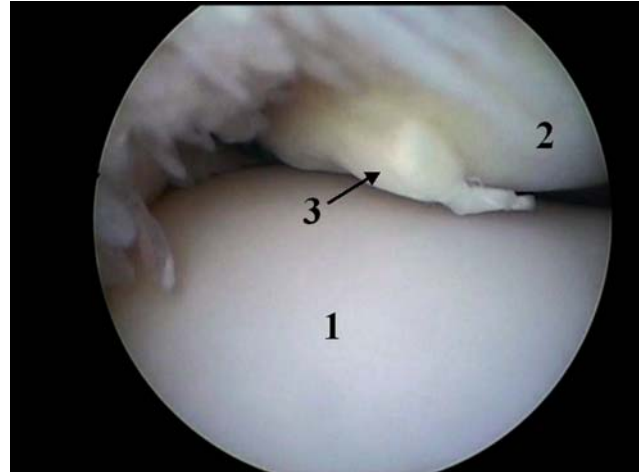
	Breed	Limb	Location	Comment
<b>DORSAL</b>				
	Thoroughbred	FL	Medial	Considered to be true 'chip' fractures
<b>Proximal border first phalanx</b>	Thoroughbred Warmblood	FL FL & HL	Medial Medial	Considered as developmental orthopedic disease Increased risk of lameness in older horses ( $\geq 7$ y) and/or presence of more than 1 fragment
<b>Distal McIII/MtIII</b>	Thoroughbred Standardbred Warmblood	FL & HL	Sag. Ridge Condyle	Manifestation of osteochondrosis
<b>Synovial pad</b>	Warmblood	FL & HL	Lateral Central Medial	Increased risk of synovial and cartilage abnormalities for large fragments ( $\geq 10$ mm)
<b>PALMAR/PLANTAR</b>				
<b>Proximal border first phalanx (Type I)</b>	Standardbred	HL>FL	Medial	Fracture at young age Clinical signs vary
<b>Ununited P1 plantarproximal tuberosity</b>	Thoroughbred Standardbred Warmblood	HL	Lateral	Rarely cause lameness Removal not recommended
<b>Sesamoid bone (SB)</b>	Thoroughbred Standardbred Warmblood	HL>FL	Medial and Lateral	Removal recommended in case of fracture (frontlimb medial SB: worst prognosis)



**Figure 1a.** Lateromedial radiograph of the fetlock joint. A dorsoproximal P1 fragment is visible.

Motta, 2000; Kane *et al.*, 2003). In these horses, dorsoproximal P1 fragments are often an incidental finding during radiographic examination of horses without lameness or joint distension (Colon *et al.*, 2000; Richardson, 2003). Oblique radiographs (45°DL-PaMO/45°DM-PaLO) and ultrasound examination are useful to determine the exact location. In a radiographic survey of yearling Standardbred horses by Grondahl (1992), dorsoproximal P1 fragments were diagnosed in 36 of 753 horses (4.8 %) and were considered to be manifestations of developmental orthopedic disease. Similar fragments are found in Warmblood horses and some of them can be OC-related (McIlwraith, 1996; McIlwraith, 2002). The vast majority (95.2%) are found medially, without predilection for front or hind limbs. In 10% of the joints, more than one fragment is present (Declercq *et al.*, 2009). In immature horses they have been described as OC, but it is rare to find histologic evidence to support these claims (Nixon, 2006). Histopathologic evaluation of 41 P1 fragments in Warmblood horses showed an osteochondral fragment without typical characteristics neither of osteochondrosis (presence of retention of cartilage cores in the central bone) nor of a healing/reactive fracture (Declercq *et al.*, 2009).

Krook and Maylin (1988) proposed that the ‘chip fractures’ as reported in Thoroughbred racehorses, are also manifestations of osteochondrosis (OC), but other authors do not support this statement (McIlwraith, 1996; McIlwraith, 2002).

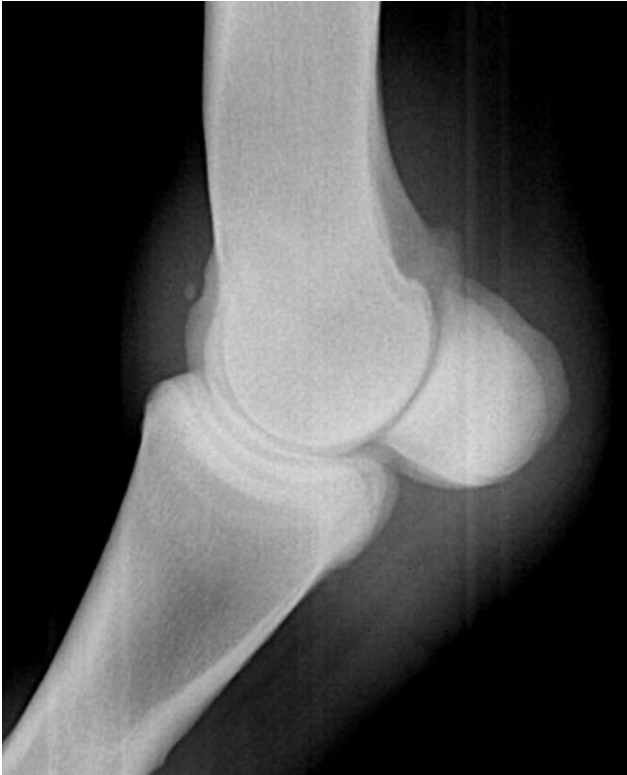

**Figure 1b.** Arthroscopic view of the dorsoproximal pouch (distal condyle MCIII (1) and dorsoproximal border P1 (2)) of the fetlock joint. A dorsoproximal P1 fragment (3) is visible.

When associated with joint distension and/or lameness, the treatment of choice is surgical removal using arthroscopy (Yovich and McIlwraith, 1986; Kawcak and McIlwraith, 1994; McIlwraith, 1996; Colon *et al.*, 2000; McIlwraith, 2002; Richardson, 2003; McIlwraith *et al.*, 2005). The prognosis after arthroscopic removal of dorsoproximal P1 chip fragments in racing Thoroughbreds is better if no other lesions (synovitis, wear lines or cartilage erosions) are present within the joint during arthroscopy (Kawcak and McIlwraith, 1994) (Figure 1b). In horses without clinical signs at the time of radiographic fragment detection, ambiguity exists concerning their future clinical significance and opinions differ whether the arthroscopic removal is indicated (Laws *et al.*, 1993; Storgaard *et al.*, 1997). Indeed, dorsoproximal P1 fragments might not cause clinical signs at this moment, but could cause problems in the future. Once degenerative arthritis ensues and clinical signs appear, the removal of the fragment does not reverse the degeneration. On the other hand one could question the causal relationship between the presence of such fragments and the development of cartilage lesions (Colon *et al.*, 2000). The evaluation of 117 Warmblood horses with P1 fragments revealed the presence of one or more abnormalities on arthroscopy in 50.7% of the joints. In eight horses, fetlock related lameness was demonstrated and the lameness was significantly more likely to occur in horses  $\geq 7$  years old and in those presenting more than one fragment. The size of the fragment appeared to have no significant influence (Declercq *et al.*, 2009).

### **Fragments at the dorsal aspect of the distal third metacarpal (MCIII) and metatarsal (MTIII) bone**

Osteochondral lesions and fragmentation of the distal sagittal ridge (Figures 2a and 2b) (sometimes extending to the adjacent condyle) of MCIII and MTIII have been classified as a form of osteochondrosis based on the histologic assessment in one horse and the



**Figure 2a.** Lateromedial radiograph of the fetlock joint. An osteochondral fragment originating from the sagittal ridge is visible.

clinical and surgical appearance of the lesions (Yovich *et al.*, 1985; Foerner and McIlwraith, 1990; Nixon, 1990). On the radiographical survey of 1127 Thoroughbred yearlings, lucencies, fragments or loose bodies were detected in 2.8% of the MCIII and 3.2% of the MTIII (Kane *et al.*, 2003). Another radiographic study (lateromedial radiograph) in Standardbred trotters revealed changes on the dorsoproximal aspect of MC/MTIII in 118 of 753 yearlings with 61 forelimbs and 147 hindlimbs affected (Grondahl, 1992). According to McIlwraith and Vorhees (1990), the condition can be divided into three types:

type I: a defect or flattening as the only visible radiographic lesion

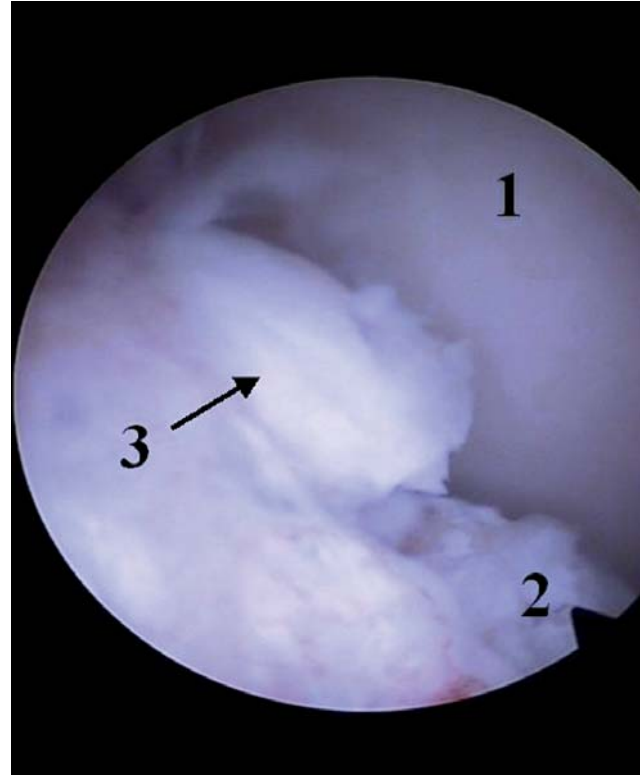
type II: a defect or flattening with fragmentation associated with the defect

type III: a defect or flattening with or without fragmentation plus one or more loose bodies.

Synovial effusion is usually the first clinical sign observed. The degree of associated lameness varies, but flexion of the fetlock will usually provoke lameness. However, in many cases, joints may be radiographically affected without clinical symptoms (Yovich *et al.*, 1985; McIlwraith and Vorhees, 1990; Nixon, 1990; McIlwraith, 1993).

Yovich *et al.* (1985) suggested that fragments of the distal sagittal ridge (no difference in types) can be treated conservatively.

Although the prognosis for horses with type I lesions is generally good with conservative management, better results are obtained after surgical management of type II and III lesions. Athletic activity is regained in a



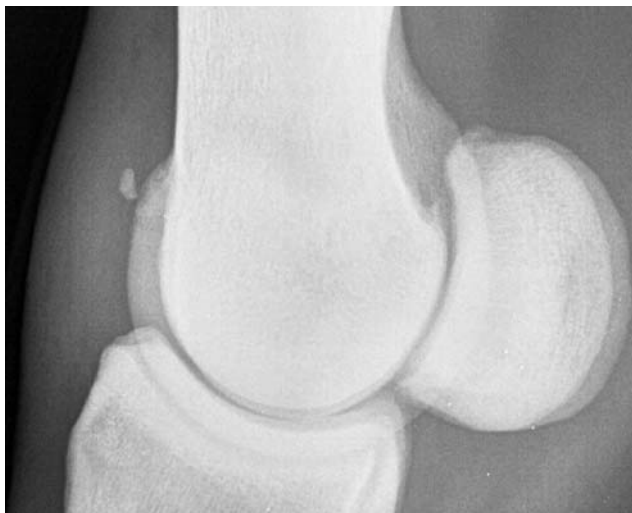**Figure 2b.** Arthroscopic view of the dorsoproximal pouch (distal condyle MCIII (1) and sagittal ridge (2)) of the fetlock joint. An osteochondral fragment (3) originating from the sagittal ridge is visible.

fair number of cases, but clinical signs will persist in 25%. Whether surgery will be successful or not depends on the extent of the lesions determined on arthroscopy (erosions and wear-lines) and on the presence of osteophytes (McIlwraith and Vorhees, 1990; Nixon, 1990; McIlwraith, 1993). The success rate has improved because of the earlier intervention due to the radiographic examination of the horse at a young age (McIlwraith *et al.*, 2005).

### Synovial pad fragments

The synovial pad of the metacarpo-/metatarso-phalangeal joint is a fold of fibrous connective tissue located in the dorsal recess of the joint capsule at its attachment to McIII or MtIII. This pad covers the transition zone between the condylar cartilage and the attachment of the joint capsule to McIII or MtIII. The synovial pad is normally 2 to 4 mm in thickness and tapers to a thin edge at its distal border (White, 1990).

In Warmblood horses, there is a broad range of radiographic presentation (Figures 3a and 3b) of synovial pad fragments going from a well separated fragment dorsoproximal to the sagittal ridge, to a fragment superimposed on the sagittal ridge but without adjacent subchondral bone depression. No predilection for front or hind limbs, or for fragment location (medial, central or lateral) has been detected. Slightly oblique radiographs (5°DL-PaMO/5°DM-PaLO) and ultrasound examination are useful to determine the exact location (Declercq *et al.*, 2008).



**Figure 3a.** Lateromedial radiograph of the fetlock joint. An osteochondral fragment in the synovial pad is visible.

The origin of synovial pad fragments still remains unclear. Histopathology revealed a bony structure covered with fibrous cartilage, both surrounded and entirely embedded in fibrous tissue. The fibrous tissue was well attached to the underlying cartilage. No characteristics of osteochondrosis, a secondary center of ossification or synovial chondromatosis could be demonstrated (Declercq *et al.*, 2008).

When associated with joint distension and/or lameness, the treatment of choice is surgical removal using arthroscopy. In horses without clinical signs at the time of radiographic fragment detection, some ambiguity exists concerning their future clinical significance and opinions differ whether arthroscopic removal is indicated. Indeed, synovial pad fragments might not cause clinical signs at this moment, but could cause problems in the future.

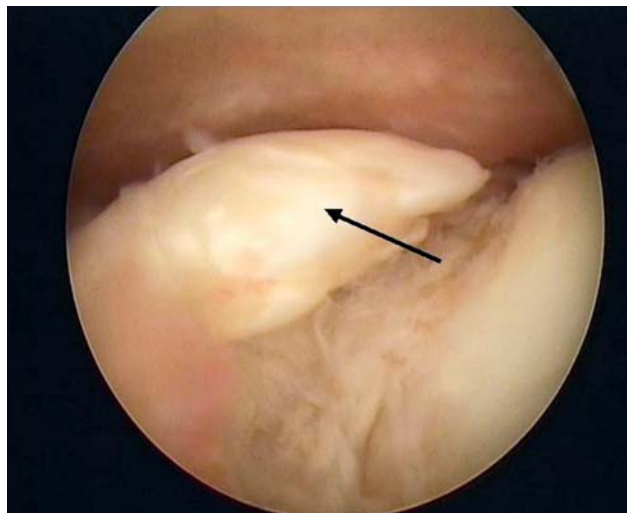
Large ( $\geq 10$ mm diameter) synovial pad fragments in Warmblood horses have been associated with synovial and cartilage abnormalities, also in horses without clinical symptoms (Declercq *et al.*, 2008).

#### **PALMAR/ PLANTAR OSTEOCHONDRAL FRAGMENTS**

Fragments at the palmar/plantar aspect of the metacarpal-/metatarsophalangeal joint occur at the palmar-/plantaroproximal border of P1 or originate from the sesamoid bones.

#### **Palmaro- and plantaroproximal P1 osteochondral fragments**

Fragments associated with the palmar or plantar portions of P1 were initially reported as chip or avulsion fractures (Birkeland, 1972; Petterson and Ryden, 1982). The fragments originate from the palmar/ plantar aspect of the proximal end of P1, just medial or lateral to the sagittal groove (Type I) (Foerner *et al.* (1987)). The incidence in the Standardbred population has been reported to be 12%-28.8% (95% in hindlimbs) (Sandgren, 1988;



**Figure 3b.** Arthroscopic view of the dorsoproximal pouch of the fetlock joint. The fragment is completely incorporated in the synovial pad (arrow).

Grondahl, 1992) and in Thoroughbreds 0.5% in front limbs and 5.9% in hind limbs (Kane *et al.*, 2003). Fragments are most commonly found on the medial side of the metatarsophalangeal joint (Figures 4a and 4b) (Pettersen and Ryden, 1982; Barclay *et al.*, 1987; Nixon and Pool, 1995). Oblique radiographs are useful to determine the exact location. The high incidence in Standardbred trotters may be caused by the outwardly rotated limb axes putting additional load on the medial part of the metatarsophalangeal joints (Dalin *et al.*, 1993).

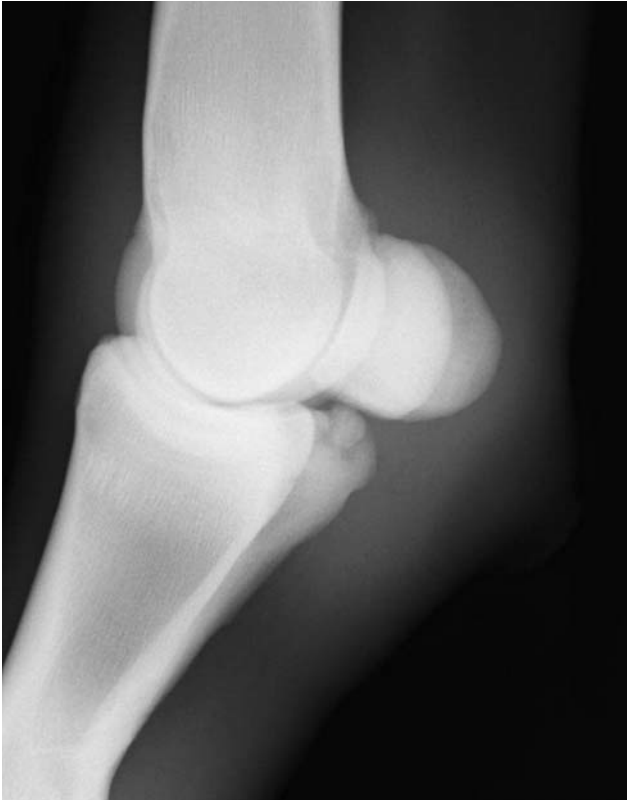The clinical significance of the palmaro- and plantaroproximal P1 fragments has been disputed. Some authors believe that they are incidental findings with no clinical relevance while others consider them as a cause of lameness (Roneus *et al.*, 1998). The reported clinical signs vary from moderate to severe lameness at slow speed to more intangible lameness manifested only at high speeds and maximum performance (inability to run straight at high speed) (Foerner *et al.*, 1987; Houttu, 1991; Whitton and Kannegieter, 1994).

In Standardbreds, they are a common cause of low-grade lameness and arthroscopic removal results in an improvement of the race performance in a high number of cases (Houttu, 1991; Whitton and Kannegieter, 1994; Fortier *et al.*, 1995). On the other hand, fragments are often removed in two-year-old horses without clinical abnormalities, as a preventive measure before they start training (Houttu, 1991).

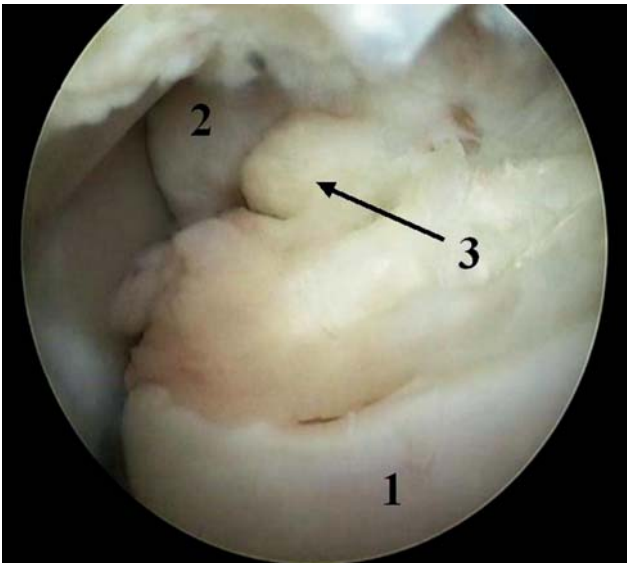
Although these fragments appear to resemble OCD clinically, histologic evidence suggests they are fractures that developed in the early postnatal period (Dalin *et al.*, 1993; Nixon and Pool, 1995).

#### **Ununited plantaroproximal tuberosity of the proximal phalanx**

Ununited plantaroproximal tuberosity fragments of P1 are not very common. In a study by Grondahl (1992), they were detected in only eighteen of 753 (2.4%) Standardbred yearlings on radiography. The

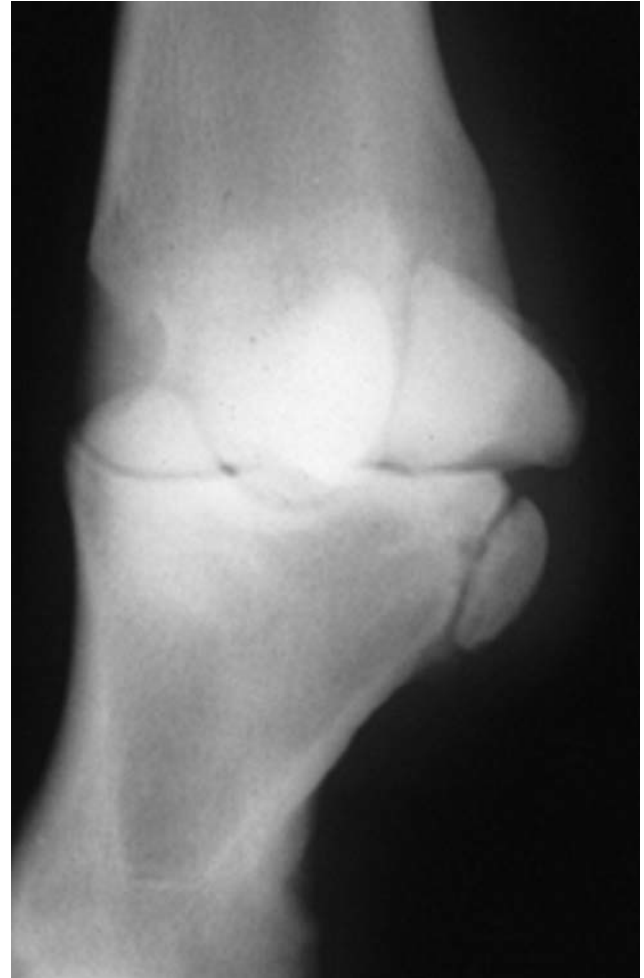

**Figure 4a.** Lateromedial (slightly dorsomedial-plantarolateral oblique) radiograph of the fetlock joint. A planteroproximal P1 fragment is visible.



**Figure 4b.** Arthroscopic view of the plantar pouch (distal border of the sesamoid bone (1) and plantaroproximal border of P1 (2)) of the fetlock joint. A plantaroproximal P1 fragment (3) is visible.

condition was only seen in hind limbs and the vast majority of the lesion was located laterally (Figure 5). Oblique radiographs are useful to determine the exact location. These fragments can be partially intra-articular or completely extra-articular. None of the horses presented lameness and on the follow-up examination of sixteen horses, twelve ununited plantaroproximal tuberosities in eleven horses had united. The incidental



**Figure 5.** Dorso45°lateral-plantaromedial oblique radiograph of the fetlock joint. An ununited planteroproximal tuberosity of the proximal phalanx is visible. Removal is not recommended.

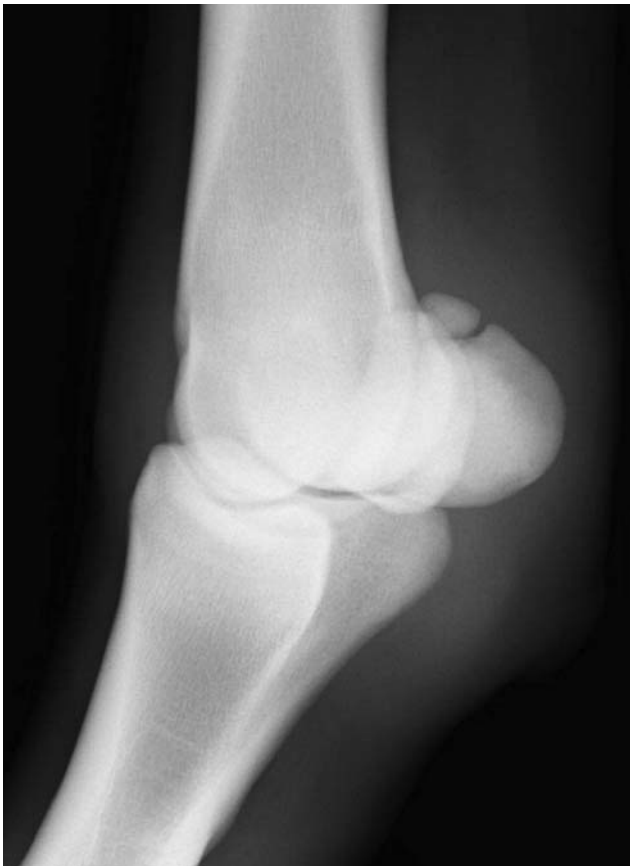finding of this condition coupled with the fact that it rarely causes lameness, and finally often unites with the proximal phalanx, would tend to indicate that the etiology is developmental (Grondahl, 1992).

Grondahl (1992) recommends a regular radiographic follow-up and advises to consider surgery only if radiographic and/ or clinical evidence indicates progression of this condition.

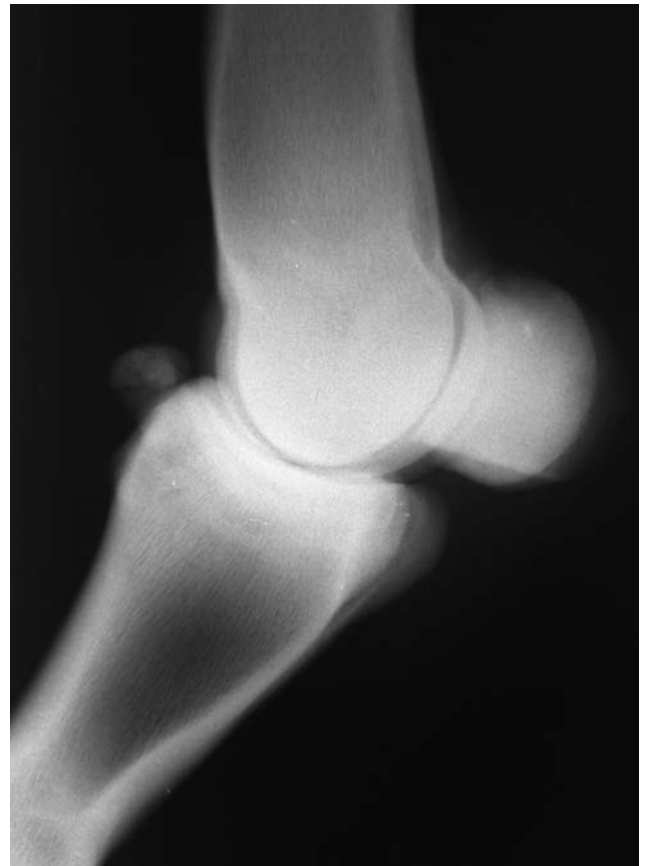### Proximal sesamoid bone fragments

Fragments at the level of the proximal sesamoid bones are considered to be fractures. They are common in racehorses and uncommon in other types of horses (Southwood and McIlwraith, 2000). Fractures have been classified as apical, basal, midbody, axial, abaxial and comminute. Many of these affected horses manifest an obvious lameness and soft tissue inflammation. Therefore these fragments are not discussed in this article.

An exception is the 'fracture' of the apex of the proximal sesamoid bone, which is often presented without clinical signs (Grondahl *et al.*, 1994; Schnabel



**Figure 6.** Dorso45°medial-plantarolateral oblique radiograph of the fetlock joint. A proximal sesamoid bone fragment is visible.

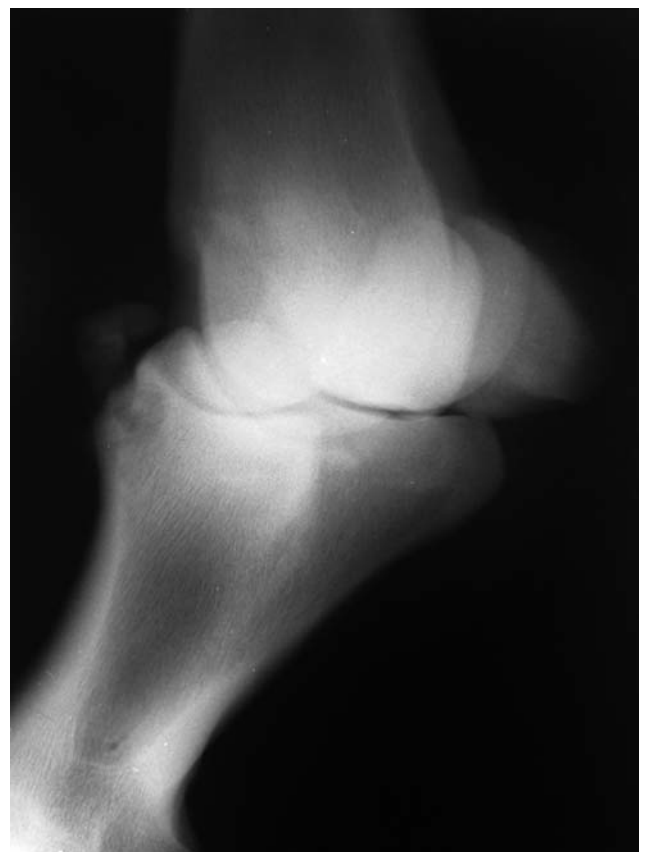

**Figure 7a.** Lateromedial radiograph of the fetlock joint. A large dorsoproximal P1 fragment is visible.

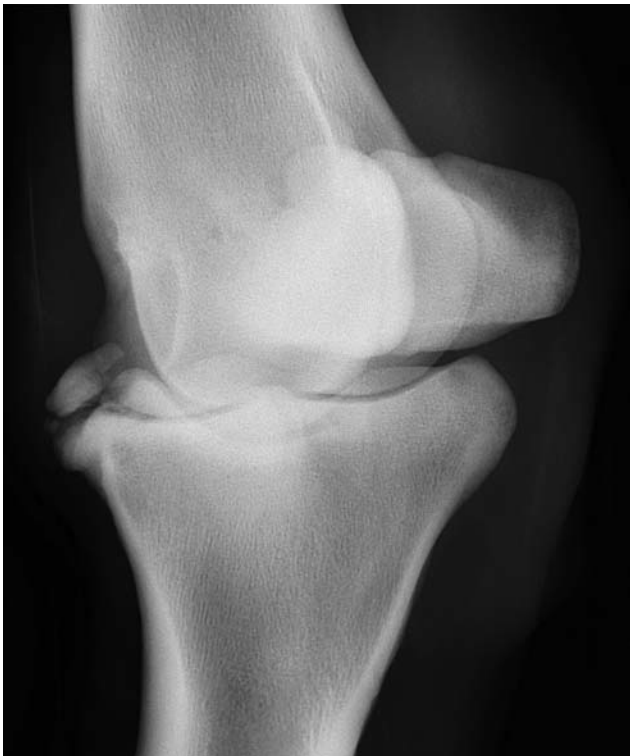*et al.*, 2007) (Figure 6). The radiographic screening of 753 young Standardbred trotters revealed four horses with apical proximal sesamoid bone fracture fragments without clinical symptoms (Grondahl *et al.*, 1994). In 151 immature Thoroughbred, 92% of these fractures occurred in the hindlimbs with a nearly equal distribution between left and right and without preferential medial or lateral sesamoid bone affected (Schnabel *et al.*, 2007). Oblique radiographs are useful to determine the exact location. Arthroscopic removal in Thoroughbred weanlings and yearlings carries an excellent prognosis for racing in horses with hindlimb fractures, and a reduced prognosis in those with forelimb fractures. Medial fractures of the forelimb carry the worst prognosis (Schnabel *et al.*, 2007).

#### OTHER TYPES OF OSTEOCHONDRAL FRAGMENTS IN THE FETLOCK

Not all osteochondral fragments can be categorized in one of the above mentioned groups. When dealing with uncommon cases of fragmentation, a correct judgement on the clinical importance and treatment is not obvious. Due to their relatively exceptional nature no literature recommendations on their management can be found. To illustrate the diversity in their clinical presentation, two examples of atypical fetlock fragments are included in this report.



**Figure 7b.** The Dorso45°medial-plantarolateral radiograph of the fetlock shows that the fragment is mainly located dorsolaterally.



**Figure 8.** Dorso45° medial-plantarolateral radiograph of the right hind fetlock joint. A large and a small dorso-lateral and proximal P1 fragment are visible.

A 3-year-old Warmblood stallion was presented without lameness, but with a distension of the right hind fetlock joint which got worse when training was increased. On palpation, the dorsolateral aspect of the joint was thickened and the radiographic examination revealed a large osteochondral fragment at the dorsal aspect of the joint (Figures 7a and 7b). Based on the radiographs, intra-articular location of the fragment was uncertain. After consideration with the owner, a diagnostic arthroscopy was performed to evaluate whether the fragment was intra-articular and whether there was an indication for removal. Arthroscopy revealed severe synovitis and the presence of a very large fragment that was partially intra-articular and largely embedded in the joint capsule. Successful removal through a small arthrotomy was performed and the horse recovered and rehabilitated uneventfully.

In another 3-year-old Warmblood horse, a very large dorsalateral fragment was detected in the metatarsophalangeal joint right hind. The surface of the fragment was irregular and new bone formation was present at the proximal border of P1 at that level (Figure 8). There was a clear joint distension, but lameness was not detected. The same strategy was followed and the fragment was successfully removed. Arthroscopy revealed synovitis and a slight cartilage erosion at the level of the lateral condyl.

In these two cases, the fragments could not be classified as standard proximodorsal P1 fragments because of their large sizes and their more proximal (case 1)/distal (case 2) and abaxial localizations. Their localization can imply that they were not detected on stan-

dard lateromedial radiograph. Their irregular shapes and the presence of periosteal reaction at the dorsal border of P1, dorsal displacement (intra-articular or not), the shape and size of the fragment are also reasons why these are not 'clear-cut' dorsal P1 fragments as described above.

Discussion will always exist about these individual cases and although experience will be gained from the past, every new case requires thorough consideration.

## CONCLUSION

The radiographic evaluation of the metacarpo-/metatarsophalangeal joint in a horse can reveal the presence of osteochondral fragmentation. It is important to define the observed fragment correctly in order to allow an estimation as accurate as possible of its present and future clinical importance.

As described in the overview, every type of fragment has its proper radiographic and clinical characteristics, but well-defined guidelines about their future significance are often lacking. Although a correlation has been shown between arthroscopic signs of cartilage degeneration and certain dorsal P1 and synovial pad fragments, a direct causal relationship has not been shown yet. Therefore controversy still exists on whether their removal is necessary in all cases. Only on the ununited plantaroproximal tuberosity of the proximal phalanx everyone agrees that the removal is not necessary and might indeed be contraindicated due to the interference ligaments attaching in that area. The final decision is based on literature, personal experience and mainly on the dialogue with the horse owner.

## REFERENCES

- Adams O.R. (1966). Chip fractures of the first phalanx in the metacarpophalangeal (fetlock) joint. *Journal of the American Veterinary Medical Association* 148, 360-363.
- Barclay W.P., Foerner J.J., Phillips T.N. (1987). Lameness attributable to osteochondral fragmentation of the plantar aspect of the proximal phalanx in horses: 19 cases (1981-1985). *Journal of the American Veterinary Medical Association* 191, 855-857.
- Birkeland R. (1972). Chip fractures of the first phalanx in the metatarsophalangeal joint of the horse. *Acta Radiologica Supplementum* 319, 73-77.
- Carlsten J., Sandgren B., Dalin G. (1993). Development of osteochondrosis in the tarsocrural joint and osteochondral fragments in the fetlock joints of Standardbred trotters. I. A radiological survey. *Equine Veterinary Journal Supplement* 16, 42-47.
- Colon J.L., Bramlage L.R., Hance S.R., Embertson R.M. (2000). Qualitative and quantitative documentation of the racing performance of 461 Thoroughbred racehorses after arthroscopic removal of the dorsoproximal first phalanx osteochondral fractures (1986-1995). *Equine Veterinary Journal* 32, 475-481.
- Dalin G., Sandgren B., Carlsten J. (1993). Plantar osteochondral fragments in the metatarsophalangeal joints in Standardbred trotters; result of osteochondrosis or trauma? *Equine Veterinary Journal Supplement* 16, 62-65.



- Declercq J., Martens A., Bogaert L., Boussauw B., Forsyth R., Boening K.J. (2008). Osteochondral fragmentation in the synovial pad of the fetlock in Warmblood Horses. *Veterinary Surgery* 37, 613-618.
- Declercq J., Martens A., Maes D., Boussauw B., Forsyth R., Boening K.J. (2009). Dorsoproximal proximal phalanx osteochondral fragmentation in 117 Warmblood Horses. *Veterinary Comparative Orthopaedics and Traumatology* 22, 1-6.
- Foerner J.J., Barclay W.P., Phillips T.N., MacHarg M.A. (1987). Osteochondral fragments of the palmar and plantar aspects of the fetlock joint. In: *Proceedings of the American Association of Equine Practitioners*. Annual Meeting, New Orleans, Louisiana 33, 739-744.
- Foerner J.J. and McIlwraith C.W. (1990). Orthopedic surgery in the racehorse. *Veterinary Clinics of North America: Equine Practice* 6, 147-177.
- Fortier L.A., Foerner J.J., Nixon A.J. (1995). Arthroscopic removal of axial osteochondral fragments of the plantar/palmar proximal aspect of the proximal phalanx in horse: 119 cases (1988-1992). *Journal of the American Veterinary Medical Association* 206, 71-74.
- Grondahl A.M. (1992). Incidence and development of ununited proximoplantar tuberosity of the proximal phalanx in Standardbred trotters. *Veterinary Radiology & Ultrasound* 33, 18-21.
- Grondahl A.M., Gaustad G., Engeland A. (1994). Progression and association with lameness and racing performance of radiographic changes in the proximal sesamoid bones of young Standardbred trotters. *Equine Veterinary Journal* 26, 152-155.
- Houttu J. (1991). Arthroscopic removal of osteochondral fragments of the palmar/plantar aspect of the metacarpometatarsophalangeal joints. *Equine Veterinary Journal* 23, 163-165.
- Kane A.J., McIlwraith C.W., Park R.D., Rantanen N.W., Morehead J.P., Bramlage L.R. (2000). The prevalence of radiographic changes in Thoroughbred yearlings. In: *Proceedings of the American Association of Equine Practitioners*. Annual Meeting, San Antonio, Texas 46, 365-369.
- Kane A.J., Park R.D., McIlwraith C.W., Rantanen N.W., Morehead J.P., Bramlage L.R. (2003). Radiographic changes in Thoroughbred yearlings. Part 1: Prevalence at the time of the yearling sales. *Equine Veterinary Journal* 35, 354-365.
- Kawcak C.E., McIlwraith C.W. (1994). Proximodorsal first phalanx osteochondral chip fragmentation in 336 horses. *Equine Veterinary Journal* 26, 392-396.
- Krook L. and Maylin G.A. (1988). Fractures in Thoroughbred racehorses. *Cornell Veterinarian* 78, 5-47.
- Laws E.G., Richardson D.W., Ross M.W., Moyer W. (1993). Racing performance of Standardbreds after conservative and surgical treatment for tarsocrural osteochondrosis. *Equine Veterinary Journal* 25, 199-202.
- McIlwraith C.W. and Vorhees M. (1990). Management of osteochondritis dissecans of the dorsal aspect of the distal metacarpus and metatarsus. In: *Proceedings of the American Association of Equine Practitioners*. Annual Meeting, Lexington 36, 547-550.
- McIlwraith C.W. (1993). Osteochondritis dissecans of the metacarpophalangeal and metatarsophalangeal (fetlock) joints. In: *Proceedings of the American Association of Equine Practitioners*. Annual Meeting, San Antonio, Texas 39, 63-67.
- McIlwraith C.W. (1996). Clinical aspects of osteochondritis dissecans. In: McIlwraith C.W. and Trotter G.W. (editors). *Joint Disease in the Horse*. 1<sup>st</sup> Ed., Saunders, Philadelphia, p. 362-383.
- McIlwraith C.W. (2002). Specific diseases of joints: osteochondritis dissecans. In: Stashak T.S. (editor). *Adams' Lameness in Horses*. 5<sup>th</sup> Ed., Lippincott Williams & Wilkins, Philadelphia, p. 556-569.
- McIlwraith C.W., Nixon A.J., Wright I.M., Boening K.J. (2005). Diagnostic and surgical arthroscopy of the metacarpophalangeal and metatarsophalangeal joints. In: McIlwraith C.W., Nixon A.J., Wright I.M., Boening K.J. (editors). *Diagnostic and Surgical Arthroscopy in the Horse*. 3<sup>rd</sup> Ed., Elsevier, Philadelphia, p. 129-196.
- Nixon A.J. (1990). Osteochondrosis and osteochondritis dissecans of the equine fetlock. *Compendium Continuing Education Practice Veterinarian* 12, 1463-1475.
- Nixon A.J. and Pool R.R. (1995). Histologic appearance of axial osteochondral fragments from the proximoplantar/proximopalmar aspect of the proximal phalanx in horses. *Journal of the American Veterinary Medical Association* 207, 1076-1080.
- Nixon A.J. (2006). Phalanges and the Metacarpophalangeal and Metatarsophalangeal Joints. In: Auer J.A. and Stick J.A. (editors). *Equine Surgery*. 3<sup>rd</sup> Ed., Saunders, Philadelphia, p. 1217-1238.
- Pettersson H. and Ryden G. (1982). Avulsion fragments of the caudoproximal extremity of the first phalanx. *Equine Veterinary Journal* 14, 333-335.
- Richardson D.W. (2003). The Metacarpophalangeal joint. In: Ross M.W. and Dyson S.J. (editors). *Diagnosis and Management of Lameness in the Horse*. 1<sup>st</sup> Ed., Saunders, Missouri, p. 348-362.
- Roneus B., Arnason T., Collinder E., Rasmussen M. (1998). Arthroscopic removal of palmar/plantar osteochondral fragments (POF) in the metacarpometatarsophalangeal joints of Standardbred trotters – Outcome and possible Genetic Background of POF. *Acta Veterinaria Scandinavica* 39, 15-24.
- Rossdale P.D., Hopes R., Wingfield Digby N.J., Offord K. (1985). Epidemiological study of wastage among racehorses 1982 and 1983. *Veterinary Record* 116, 66-69.
- Schnabel L.V., Bramlage L.R., Mohammed H.O., Embertson R.M., Ruggles A.J., Hooper S.A. (2007). Racing performance after arthroscopic removal of apical sesamoid fracture fragments in Thoroughbred horses age < 2 years: 151 cases (1989-2002). *Equine Veterinary Journal* 39, 64-68.
- Sangren B. (1988). Bony fragments in the tarsocrural and metacarpometatarsophalangeal joints in the Standardbred horse – a radiographic survey. *Equine Veterinary Journal Supplement* 6, 66-70.
- Sandgren B., Dalin G., Carlsten J. (1993). Osteochondrosis in the tarsocrural joint and osteochondral fragments in the fetlock joints in Standardbred trotters. I. Epidemiology. *Equine Veterinary Journal Supplement* 16, 31-37.
- Southwood L.L. and McIlwraith C.W. (2000). Arthroscopic removal of fracture fragments involving a portion of the base of the proximal sesamoid bone in horses: 26 cases (1984-1997). *Journal of the American Veterinary Medical Association* 217, 236-240.
- Stock K.F., Hamann H., Distl O. (2005). Prevalence of osseous fragments in the distal and proximal interphalangeal, metacarpometatarsophalangeal and tarsocrural joints of Hannoverian Warmblood Horses. *Journal of Veterinary Medicine. A Physiology, Pathology, Clinical Medicine* 52, 288-394.

- Storgaard Jorgensen H., Proschowsky H., Falk-Ronne J., Willeberg P., Hesselholt M. (1997). The significance of routine radiographic findings with respect to subsequent racing performance and longevity in Standardbred trotters. *Equine Veterinary Journal* 29, 55-59.
- Torre F, Motta M. (2000). Osteochondrosis of the tarsocrural joint and osteochondral fragments in the fetlock joints: incidence and influence on racing performance in a selected group of Standardbred trotters. In: *Proceedings of the American Association of Equine Practitioners*, San Antonio, Texas, 46, 287-294.
- Van Hoogmoed L.M., Snyder J.R., Thomas H.L., Harmon F.A. (2003). Retrospective evaluation of equine pre-purchase examinations performed 1991-2000. *Equine Veterinary Journal* 35, 375-381.
- White N.A. (1990). Synovial pad proliferation in the metacarpophalangeal joint. In: White N.A. and Moore J.N. (editors). *Current Practice of Equine Surgery*. Lipincott, Philadelphia, p. 555-558.
- Whitton R.C. and Kannegieter N.J. (1994). Osteochondral fragmentation of the plantar/palmar proximal aspect of the proximal phalanx in racing horses. *Australian Veterinary Journal* 71, 318-321.
- Yovich J.V., McIlwraith C.W., Stashak T.S. (1985). Osteochondritis dissecans of the sagittal ridge of the third metacarpal and metatarsal bones in horses. *Journal of the American Veterinary Medical Association* 186, 1186-1191.
- Yovich J.V. and McIlwraith C.W. (1986). Arthroscopic surgery for osteochondral fractures of the proximal phalanx of the metacarpophalangeal and metatarsophalangeal (fetlock) joint in horses. *Journal of the American Veterinary Medical Association* 188, 273-279.

## Persbericht

### MET CIMALGEX TILT VÉTOQUINOL DE PIJNBESTRIJDING BIJ HONDEN NAAR EEN HOGER NIVEAU

#### Cimalgex?

Cimalgex is een nieuw ontwikkeld NSAID voor kort- en langdurende pijnbehandeling bij de hond. Zowel voor de bestrijding van perioperatieve pijn tgv orthopedische of weke delen chirurgie als voor de behandeling van pijn en ontsteking geassocieerd met osteoarthritis kunt u Cimalgex uiterst doeltreffend inzetten. Langetermijnstudies en toediening van 6-voudige doseringen toonden aan dat Cimalgex veilig is.

#### Een nieuwe standaard in NSAID's

- Cimalgex betekent voor elke dierenarts een stap vooruit dankzij:
- een mogelijke behandelingsduur van 6 maanden bij osteoarthritis;
  - de bewezen tolerantie;
  - de goede werkzaamheid;
  - het gebruiksgemak.

#### Presentatie

Cimalgex bestaat in 3 groottes van zeer smakelijke tabletten, telkens in verpakkingen van 32 of 144 tabletten. Ze zorgen in alle omstandigheden voor een zeer flexibel en vlot gebruik in uw dagelijkse praktijk.

#### Meer info?

Lees meer op [www.kimydog.com](http://www.kimydog.com).