

Medial coronoid disease in an eleven-year-old Labrador retriever

Een letsel van de processus coronoïdeus medialis bij een elf jaar oude labrador-retriever

M. Dallago, E. de Bakker, E. Coppieters, J. Saunders, I. Gielen, B. Van Ryssen

Department of Medical Imaging and Orthopedics, Faculty of Veterinary Medicine,
Ghent University, Salisburylaan 133, 9820 Merelbeke, Belgium

melania.dallago@ugent.be

A BSTRACT

In this case report, the occurrence of medial coronoid disease (MCD) is described in an eleven-year-old Labrador retriever. A left frontleg lameness had started six months before presentation. Radiographs showed minimal pathology and computed tomography (CT) demonstrated a discrete fissure of the medial coronoid process. Arthroscopy confirmed the presence of a coronoid lesion, visible as chondromalacia. Treatment was performed by arthroscopic removal of the diseased cartilage and subchondral bone. Despite the successful procedure, the dog needed continuous physiotherapy to maintain an acceptable gait.

MCD is a developmental disorder mainly affecting young large breed dogs. However, the described dog was already eleven years old. Nevertheless, the duration of lameness was rather short and the imaging and arthroscopic findings could not demonstrate a chronic problem. In the literature, little information is available about the etiology, prevalence and treatment outcome of medial coronoid pathology in old dogs.

SAMENVATTING

In deze casuïstiek wordt het voorkomen van een recente aandoening van de processus coronoïdeus medialis (medial coronoid disease, MCD) bij een elf jaar oude Labrador retriever beschreven. Voordat de hond werd aangeboden, liep hij reeds zes maanden mank op de linkervoort. Radiografisch was er slechts een beperkte pathologie zichtbaar en via computertomografie werd een discrete fissuur van de mediale processus coronoïdeus aangetoond. Artroschopisch kon een letsel van de processus coronoïdeus medialis bevestigd worden, zichtbaar als chondromalacie. De behandeling bestond uit het artroschopisch verwijderen van het afwijkende kraakbeen en subchondrale been. Ondanks de geslaagde ingreep had de hond blijvend nood aan fysiotherapie om comfortabel te kunnen lopen.

MCD is een ontwikkelingsstoornis die vooral jonge honden van grote rassen aantast. De hond in deze casereport was echter al elf jaar oud. Nochtans was de duur van de mankheid vrij kort en kon er via beeldvorming en artroscopie geen chronisch probleem aangetoond worden. In de literatuur is weinig informatie beschikbaar over de etiologie, het voorkomen en het behandelingsresultaat van MCD bij oude honden.

INTRODUCTION

In 1965, developmental abnormalities of the elbow joint such as degenerative joint disease (DJD) accompanied by an ununited anconeal process (UAP) were described for the first time (Corley and Carlson, 1965). Later, fragmentation of the medial coronoid process (FCP) and osteochondritis dissecans (OCD)

of the medial humeral condyle were added as causes of early DJD in the elbow joint. Both lesions together with UAP were grouped under elbow dysplasia (ED) complex, a term that was adopted by the International Elbow Working Group (IEWG) in 1989. Nowadays, decades later, the term elbow dysplasia is still not completely and unequivocally defined. Other manifestations in the elbow joint, such as ununited medial

humeral epicondyle (UME) (Walker, 1998), elbow incongruity (INC) (Samoy et al., 2006), incomplete ossification of the humeral condyle (IOHC) (Robin et al., 2001; Ljunggren et al., 1966) and flexor enthesopathy (Meyer-Lindberg et al., 2004), are sometimes included in the ED disease complex. A new term, medial coronoid disease (MCD), has been introduced to describe the different changes in the cartilage and in the subchondral bone of the medial coronoid process (Moores et al., 2008; Fitzpatrick et al., 2009a). The lesions of MCD can be classified in five groups: chondromalacia, fissure, non-displaced fragment, displaced fragment and erosion (Figure 1). The term medial coronoid disease has replaced the former term fragmentation of the coronoid process (FCP).

The incidence of MCD in dogs ranges from 0% to 55%, depending on the breed (Lavrijsen et al., 2012; Lau et al., 2013; Coopman et al., 2014). In previous studies, it has been estimated that more than one hundred genes code for elbow dysplasia (Morgan et al., 2000; Gouth and Thomas, 2004; Temwichitr et al., 2010). Phenotypic factors, such as obesity during growth, may be important to determine whether the dog with the genes coding for ED will develop the disease. Trauma and high-energy diet during development, hormonal effects and others may also be considered as contributing factors (Guthrie and Pidduck, 1990; Morgan et al., 1999; Slatter, 2002; Fossum, 2007; Woolliams et al., 2011; Lavrijsen et al., 2012). Elbow incongruity has been reported as a possible contributor to the etiopathogenesis of ED but the exact cause has not yet been determined (Kirberger and Fourie, 1998; Ness, 1998; Puccio et al., 2003; Samoy et al., 2006).

The most affected breeds are the medium-large breed dogs, with high frequencies in the Labrador retriever, Rottweiler, Bernese mountain dog, St Bernard, Golden retriever, and German shepherd dog (Morgan et al., 2000; Ubbink et al., 2000; Fitzpatrick et al., 2009a; Lavrijsen et al., 2012; Coopman et al., 2014). MCD has mainly been described in young dogs (Mason et al., 1980; Wind, 1982; Grondalen, 1982; Morgan et al., 2000; Hazewinkel, 2003; Piermattei, Flo and DeCamp,

2006), but some studies have also reported the presence of MCD in adult and old dogs (Meyer-Lindberg et al., 2002; Hazewinkel, 2003; Samoy et al., 2005; Fitzpatrick et al., 2009b; Vermote et al., 2010).

To assess the presence and the severity of MCD, different medical imaging modalities may be used (Smith et al., 2009). Radiographic signs of MCD are not always evident and the reported sensibility of radiographic imaging ranges from 10% to 62% (Hadiquet et al., 2002). CT is a very sensitive technique as the bony structures can be examined without superimposition (Reichle, 2000; De Rycke et al., 2002; Moores et al., 2008). Arthroscopy provides information about the articular cartilage by direct inspection (Van Ryssen and van Bree, 1997; Fossum, 2007; Samoy et al., 2011).

Even though conservative treatment may lead to improvement of the dog's condition, arthrotomy and arthroscopy are the generally accepted treatment methods for MCD. Arthroscopy is the preferred technique as it is minimally invasive, allows a better visualization of the lesions and gives better functional results (Van Ryssen and van Bree, 1997; Meyer-Lindberg et al., 2003; Evans et al., 2008).

CASE REPORT

An 11-year-old, non-spayed, female Labrador retriever was presented with lameness of the left forelimb. The lameness had appeared gradually six months before consultation, and had been described as moderate, constant, and tending to aggravate after rest. The dog had received non-steroidal, anti-inflammatory drugs during two time periods, resulting in a short, temporary improvement.

On clinical examination, there was moderate lameness and mild muscle atrophy of the left forelimb. The left elbow was mildly distended and painful. The right elbow showed no abnormalities.

Radiographs of the left elbow showed a radiolucent medial coronoid process with a flattened appearance, suggestive of medial coronoid disease. The proximal




Figure 1. Arthroscopic images of the classification of the MCD lesions: chondromalacia, fissure, non-displaced fragment, displaced fragment and erosion (Images of different elbows belonging to patients treated at the Faculty of Veterinary Medicine, Ghent University).

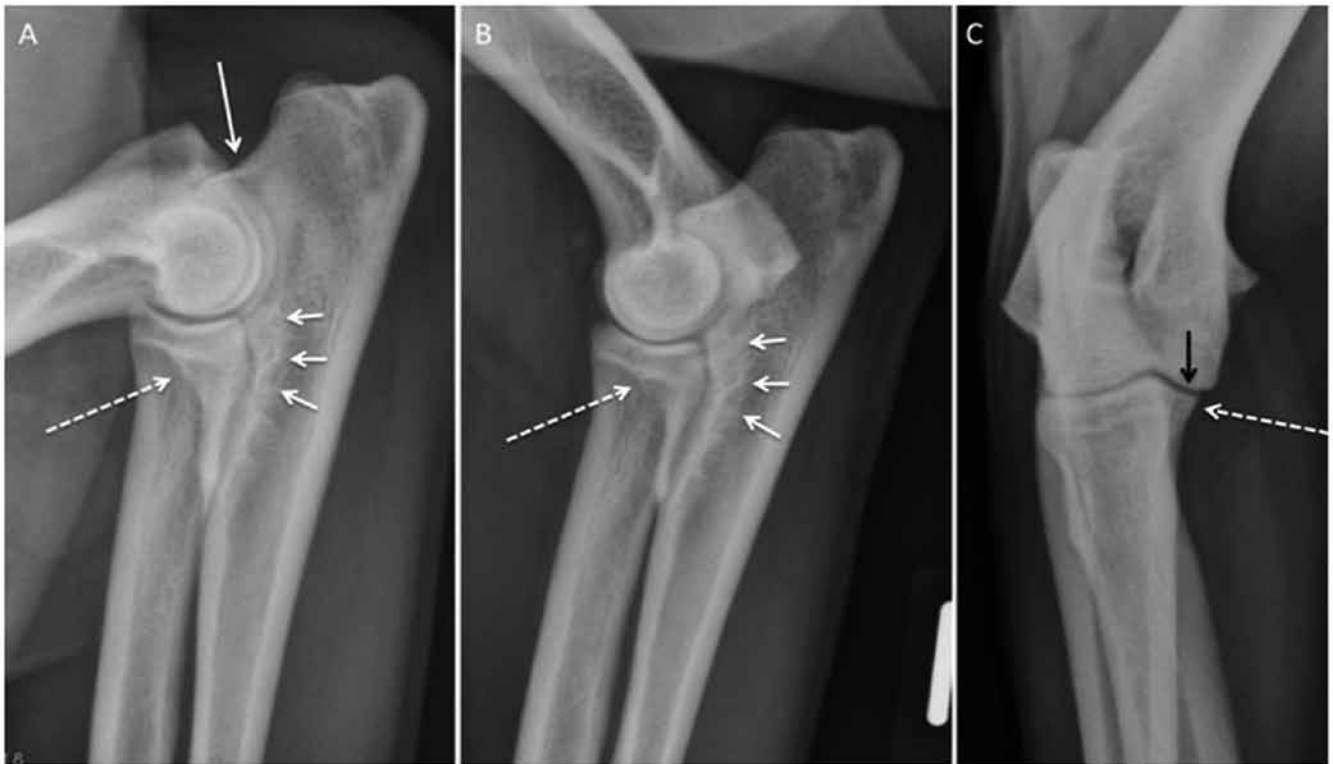

Figure 2. Three standard radiographic views of the left elbow of the presented case. A. Flexed mediolateral projection: osteophytes are absent at the anconeal process (no osteoarthritis - white arrow), the medial coronoid process is radiolucent (dotted arrow) and subtrochlear sclerosis (short arrows) is minimal. B. Extended mediolateral view. The medial coronoid process is ill-defined (dotted arrow) and mild subtrochlear sclerosis is also seen (short arrows). C. 15° Oblique craniocaudal view showing congruent joint surfaces, rounded medial humeral condyle (black arrow) and normal triangular shape of the medial coronoid process (dotted arrow).

ulna was moderately sclerotic, but there were no signs of osteoarthritis (Figure 2). The new bone formation adjacent to the ulnar trochlear notch was also evaluated by the measurement of the ulnar subtrochlear sclerosis, using a percentage scale, described in a study in Labrador retrievers (Smith et al., 2009). A result of 41% was measured, which was lower than the median value of diseased elbows (47%) observed in the study of Smith et al. (2009), which should be interpreted as not-indicative of MCD. The right elbow showed no relevant radiographic pathology.

CT of the left elbow revealed a heterogeneous aspect and a decreased opacity of the medial coronoid process, suggestive of MCD (Figure 3). There were also mild degenerative changes in the distal humerus. No signs of MCD were seen in the right elbow (Figure 3).

Arthroscopy was performed using a standard medial approach (Van Ryssen et al., 1993). There was a chronic synovitis, chondromalacia of the medial coronoid process and a limited partial thickness erosion of the radius. The medial part of the humeral condyle

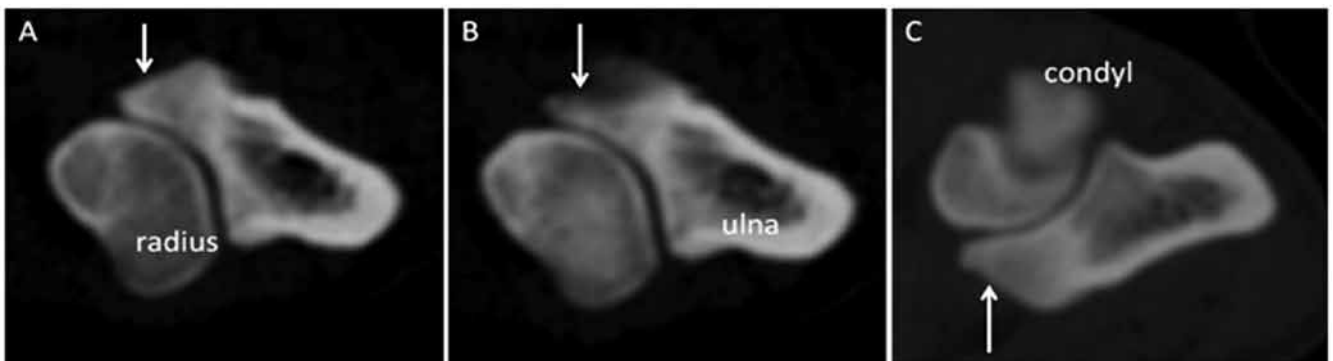

Figure 3. Transverse CT images in bone algorithm at the level of the medial coronoid process of the affected dog. A and B. In the left elbow, a radiolucent fissure line and the heterogeneous aspect of the medial coronoid process are noticed (white arrows). C. The right elbow shows the appearance of a normal coronoid process (white arrow).

showed discrete irregularities of the cartilage surface. Treatment was performed by arthroscopic removal of the affected part of the medial coronoid process, using a hand burr, a curette and small graspers. During treatment, the aspect of the subchondral bone was very brittle, pale and yellow (Figure 4).

A light-pressure bandage was applied on the left elbow, and the dog was released on the same day of the surgery. A non-steroidal anti-inflammatory drug (Rimadyl®, Pfizer Animal Health S.A., Belgium) was prescribed for a period of three weeks at a dose of 4 mg/kg during the first week and 2 mg/kg during the second and third week, which was prolonged to six weeks because of the slow healing. In this postoperative period, the dog was allowed to do short walks on the leash.

At the control visit six weeks after treatment, the dog was still moderately lame, which was comparable to the condition before surgery. Muscle atrophy was still present, the elbow was mildly distended, there was a normal range of motion and the joint was not particularly painful. Only four months after treatment and with the aid of hydrotherapy, improvement to an acceptable gait was seen when walking on a flat, soft ground. At that time, the dog could walk 1 to 1.5 hours a day and did not receive any medication. Via

a telephone questionnaire, the authors were informed that this condition remained constant during the remaining two years of the dog's life.

DISCUSSION

In this case report, the unusual appearance of medial coronoid disease is described in an old Labrador retriever with discrete pathology of the elbow. Even though MCD frequently affects Labrador retrievers, this was a challenging case because of the atypically old age and the discrete imaging findings. The lameness had been going on for six months, and only with the aid of CT and arthroscopy, the definitive diagnosis of MCD could be made.

Medial coronoid disease is known as a developmental problem affecting young dogs of large breeds. In old dogs, MCD has been described occasionally. In a study of Vermote et al. (2010), 25% of the Labrador retrievers and 9.8% of the Rottweilers and Golden retrievers in a group of 51 dogs of six years or older were reported to be affected by MCD. The Bernese mountain dog was absent in that study.

In most cases, MCD leads to secondary changes of the bone, osteoarthritis (Grondalen, 1982; Bedford,

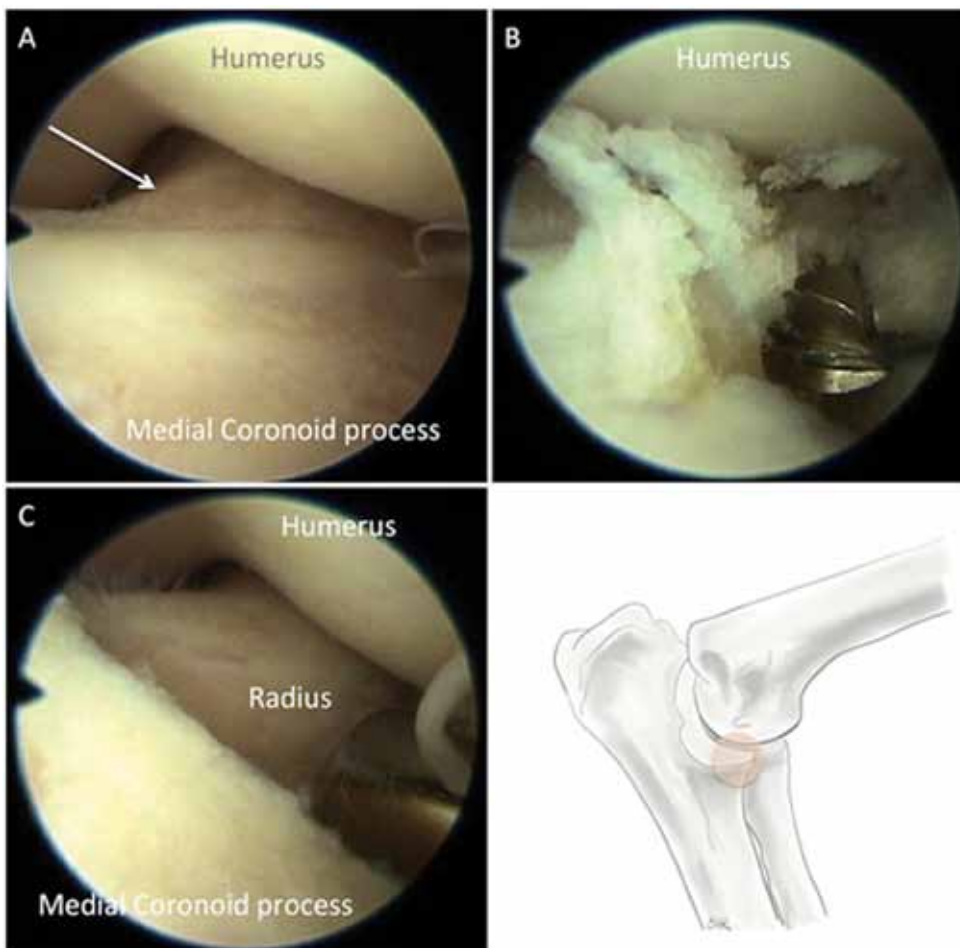


Figure 4 A, B, C. Arthroscopic images before, during and after the treatment procedure. The orange circle indicates the location of the images in the left elbow. A. The surface of the medial coronoid process is irregular (chondromalacia), the medial part of the humeral condyle is mildly irregular, and a partial thickness erosion of the radius is indicated by the white arrow. B. During treatment with a hand burr, the brittle consistency of the subchondral bone is evident. C. Image after removal of the affected part of the medial coronoid process.

1994) and to ulnar subtrochlear sclerosis (Smith et al., 2009), which are useful to determine the disease by radiography when the primary lesion is not visible. Osteoarthritis is believed to develop at the age of seven to eighth months and to progress with age (Olsson, 1983; Walde and Tellhelm, 1991). However, in the study by Vermote et al. (2010), one third of the older dogs affected by MCD showed no or only mild osteoarthritis. In a study by Fitzpatrick et al. (2009a), it was equally stated that in case of a normal radiographic appearance, the elbow might still be affected by MCD. In the present case, the radiographic changes were only partially indicative of MCD: there was no osteoarthritis and the subtrochlear sclerosis was within normal values (less than 47%) (Smith et al., 2009). However, the medial coronoid process showed discrete, yet typical pathologic changes. The combination of the clinical and radiographic findings justified the application of CT and arthroscopy to finally reveal the cause of lameness.

The etiology of MCD in older dogs has not been clarified yet. This uncommon presentation could be the consequence of a chronic, undiagnosed medial coronoid lesion. However, this explanation seems unlikely for cases with more recent clinical complaints and limited osteoarthritis as in the present case, in which lameness of the affected limb was only noticed six months before presentation. Other factors, such as trauma or overweight, were excluded in this case, as well as joint incongruity, which is another presumed cause of MCD (Fitzpatrick et al., 2009a; Vermote et al., 2010).

The arthroscopic findings in adult and old dogs have been reported in a few studies (Meyer-Lindeberg et al., 2002; Hazewinkel, 2003; Samoy et al., 2005; Fitzpatrick et al., 2009a; Fitzpatrick et al., 2009b; Vermote et al., 2010). The lesions are comparable to those of young dogs, except for the significantly higher frequency of medial compartment erosion (Vermote et al., 2010). In the described case, the arthroscopic finding was chondromalacia, referring to the irregular cartilage surface covering brittle subchondral bone containing a fissure or several microcracks (Figure 1). In both young and old dogs, chondromalacia is a rare finding, since most joints show a clear cartilage lesion, such as a fissure or fragment of the medial coronoid process (Vermote et al., 2010).

The veterinarian should consider the benefits and risks of surgical versus conservative treatment, which depends on the expected prognosis. Factors that may influence the outcome after surgical treatment of MCD are the severity and chronicity of the lesion, the presence of secondary osteoarthritis and kissing lesions of the cartilage, and the age of the animal. To date, there are no publications describing the outcome after treatment of MCD in relation to age. However, arthroscopic treatment of MCD does not lead to full

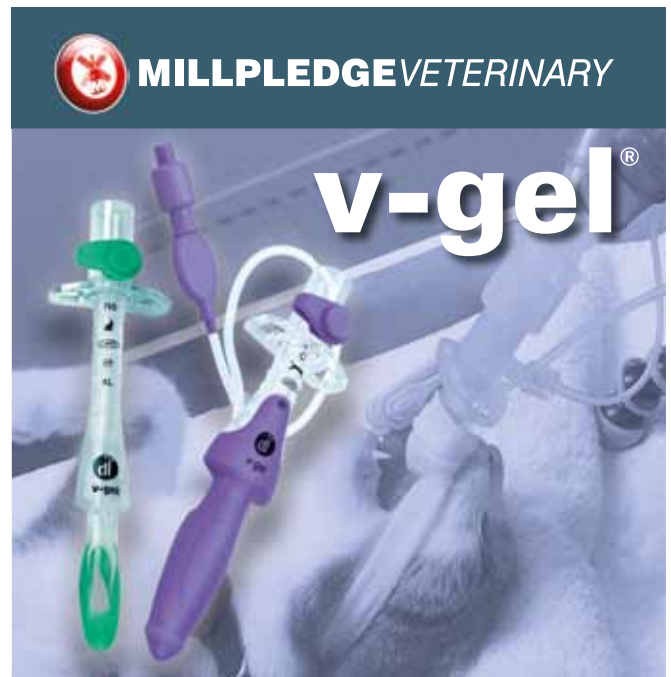recovery in all affected dogs (Gemmill and Clements, 2007; Burton et al., 2010). In the present case, arthroscopy alone was not sufficient to alleviate the lameness, and additional hydrotherapy was required. Owners should be warned for a possible unfavorable outcome, and old age might be considered as an extra risk factor.

REFERENCES

- Bedford P.G.C. (1994). Control of hereditary elbow disease in pedigree dogs. *Journal of Small Animal Practice* 35, 119-122.
- Burton N.J., Owen M.R., Kirk L.S., Toscano M.J., Colborne G.R. (2010). Conservative versus arthroscopic management for medial coronoid process disease in dogs: A prospective gait evaluation. *The British Veterinary Orthopaedic Association Meeting*. Austin Court, Birmingham, UK, 780-792.
- Coopman F., Broeckx B., Verelst E., Deforce D., Saunders J., Duchateau L., Verhoeven G. (2014). Combined prevalence of inherited skeletal disorders in dog breeds in Belgium. *Veterinary and Comparative Orthopaedics and Traumatology* 27, 395-397.
- Corley E.A., Carlson W.D. (1965). Radiographic, genetic, and pathologic aspects of elbow dysplasia. *Journal of the American Veterinary Medical Association* 174, 1651.
- De Rycke L.M., Gielen I.M., van Bree H., Simoons P.J. (2002). Computed tomography of the elbow joint in clinically normal dogs. *American Journal of Veterinary Research* 63, 1400-1407.
- Evans R.B., Gordon-Evans W.J., Conzemius M.G. (2008). Comparison of three methods for the management of fragmented medial coronoid process in the dog - A systematic review and meta-analysis. *Veterinary and Comparative Orthopaedics and Traumatology* 21, 106-109.
- Fitzpatrick N., Smith T.J., Evans R.B., Yeadon R. (2009a). Radiographic and arthroscopic findings in the elbow joints of 263 dogs with medial coronoid disease. *Veterinary Surgery* 38, 213-223.
- Fitzpatrick N., Smith T.J., Evans R.B., O'Riordan J., Yeadon R. (2009b). Subtotal coronoid ostectomy for treatment of medial coronoid disease in 263 dogs. *Veterinary Surgery* 38, 233-245.
- Fossum T.W. (2007). Canine elbow dysplasia. In: Fossum T. W. (Editor). *Small Animal Surgery*. Third edition, Mosby Elsevier, St. Louis, Missouri, 1197-1212.
- Gemmill T.J., Clements D.N. (2007). Fragmented coronoid process in the dog: is there a role for incongruity? *Journal of Small Animals Practice* 48, 361-368.
- Gouth A., Thomas A. (2010). Labrador retriever. In: Gouth A., Thomas A. *Breed Predispositions to Disease in Dogs and Cats*. 2nd Edition, Wiley-Blackwell, Oxford, United Kingdom, 127-132.
- Grondalen J. (1982). Arthrosis in the elbow joint of young rapidly growing dogs. 6. Interrelation between clinical, radiographical and pathoanatomical findings. *Nordisk Veterinaermedicin* 34, 65-75.
- Guthrie S., Pidduck H. (1990). Heritability of elbow osteochondrosis within a closed population of dogs. *Journal of Small Animal Practice* 31, 93-96.

- Hadiquet P.R., Marcellin-Little D.J., Stebbins M.E. (2002). Use of the distomedial-proximolateral oblique radiographic view of the elbow joint for examination of the medial coronoid process in dogs. *American Journal of Veterinary Research* 63, 1000-1005.
- Hazewinkel H.A. (2003). Elbow dysplasia; clinical aspects and screening programs. In: *Proceedings of the 28th World Congress of the World Small Animal Veterinary Association*; Bangkok, Thailand.
- Kirberger R.M., Fourie S.L. (1998). Elbow dysplasia in the dog; pathophysiology, diagnosis and control. *Journal of the South African Veterinary Association* 69, 43-54.
- Lau S.F., Wolschrijn C.F., Hazewinkel H.A.W., Siebelt M., Voorhout G. (2013). The early development of medial coronoid disease in growing Labrador retrievers. Radiographic, computer tomographic, necropsy and micro-computed tomographic findings. *The Veterinary Journal* 197, 724-730.
- Lavrijsen I.C., Heuven H.C. Voorhout G., Meij B.P., Theyse L.F.H., Leegwater P.A.J., Hazewinkel H.A.W. (2012). Phenotypic and genetic evaluation of elbow dysplasia in Dutch Labrador Retrievers, Golden Retrievers, and Bernese Mountain dogs. *The Veterinary Journal* 193, 486-492.
- Ljunggren G., Cawley A.J., Archibald J. (1966). The elbow dysplasias in the dog. *Journal of the American Veterinary Medical Association* 148, 887-891.
- Mason T.A., Lavelle R.B., Skipper S.C., Wrigley W. R. (1980). Osteochondrosis of the elbow joint in young dogs. *Journal of Small Animal Practice* 21, 641-656.
- Meyer-Lindeberg A., Langhann A., Fehr M., Nolte I. (2002). Prevalence of fragmented medial coronoid process of the ulna in lame adult dogs. *Veterinary Record* 151, 230-234.
- Meyer-Lindenber A., Langhann A., Fehr M., Nolte I. (2003). Arthrotomy versus arthroscopy in the treatment of the fragmented medial coronoid process of the ulna (FCP) in 421 dogs. *Veterinary and Comparative Orthopaedics and Traumatology* 16, 204-210.
- Meyer-Lindberg A., Heinen V., Hewicker-Trautwein M., Nolte I. (2004). Vorkommen und Behandlung von knöchernen Metaplasien in den am medialen Epikondylus des Humerus entspringenden Beugesehnen beim Hund. *Tierärztliche Praxis* 32, 276-285.
- Moore A.P., Benigni L., Lamb C.R. (2008). Computed tomography versus arthroscopy for detection of canine elbow dysplasia lesions. *Veterinary Surgery* 37, 390-398.
- Morgan J.P., Wind A., Davidson A.P. (1999). Bone dysplasia in the Labrador Retriever: a radiographic study. *Journal of the American Animal Hospital Association* 35, 332-340.
- Morgan J.P., Wind A., Davidson A.P. (2000). Elbow dysplasia. In: Morgan J.P., Wind A., Davidson A.P. (Editors). *Hereditary Bone and Joint Disease in the Dog: Osteochondroses, Hip Dysplasia, Elbow Dysplasia*. Eight edition, Schlütersche GmbH & Co. KG, Verlag und Druckerei, Hannover, 41-94.
- Ness M.G. (1998). Treatment of fragmented coronoid process in young dogs by proximal ulnar osteotomy. *Journal of Small Animal Practice* 39, 15-18.
- Olsson S.E. (1983). The early diagnosis of fragmented coronoid process and osteochondrosis dissecans of the canine elbow joint. *Journal of the American Animal Hospital Association* 19, 616-626.
- Piermattei D., Flo G., DeCamp C. (2006). The elbow joint. In: Piermattei D., Flo G., DeCamp C. (Editors). *Small Animal Orthopedics and Fracture Repair*. Fourth edition, Saunders Elsevier, St. Louis, Missouri, 339-354.
- Puccio M., Marino D.J., Stefanacci J.D., McKenna B. (2003). Clinical evaluation and long term follow up of dogs with coronoidectomy for elbow joint incongruity. *Journal of the American Animal Hospital Association* 39, 473-478.
- Reichle J.K., Park R.D., Bahr A.M. (2000). Computed tomographic findings of dogs with cubital joint lameness. *Veterinary Radiology & Ultrasound* 41, 125-130.
- Robin D., Marcellin-Little D.J. (2001). Incomplete ossification of the humeral condyle in two Labrador retrievers. *Journal of Small Animal Practice* 42, 231-234.
- Samoy Y., Van Ryssen B., Gielen I., Walschot N., van Bree H. (2006). Elbow incongruity in the dog – review of the literature. *Veterinary and Comparative Orthopaedics and Traumatology* 19, 1-8.
- Samoy Y., Van Ryssen B., Van Caelenberg A., Peremans K., Gielen I., van Bree H. (2005). Een atypisch geval van een losse processus coronoideus medialis bij de hond. *Vlaams Diergeneeskundig Tijdschrift* 74, 154-161.
- Samoy Y., Gielen I., van Bree H., Van Ryssen B. (2011). Dysplastic elbow diseases in dogs. *Vlaams Diergeneeskundig Tijdschrift* 80, 327-338.
- Slatter D. H. (2002). Canine elbow dysplasia. In: Slatter D. H. (Editor). *Textbook of Small Animal Surgery*. Second edition, Saunders, Philadelphia, 1927-1952.
- Smith T.J., Fitzpatrick N., Evans B.E., Read M.J. (2009). Measurement of ulnar subtrochlear sclerosis using a percentage scale in Labrador retrievers with minimal radiographic signs of periarticular osteophytosis. *Veterinary Surgery* 38, 199-208.
- Temwichitr J., Leegwater P.A., Hazewinkel H.A. (2010). Fragmented coronoid process in the dog: a heritable disease. *The Veterinary Journal* 85, 123-129.
- Ubbink G.J., van den Broek J., Hazewinkel H.A., Wolvinkamp W.T., Rothuizen J. (2000). Prediction of the genetic risk for fragmented coronoid process in Labrador retriever. *Veterinary Record* 147, 149-152.
- Van Ryssen B., van Bree H., Simoens P. (1993). Elbow Arthroscopy in Clinically Normal Dogs. *American Journal of Veterinary Research* 54, 191-198.
- Van Ryssen B., van Bree H. (1997). Arthroscopic findings in 100 dogs with elbow lameness. *Veterinary Record* 126, 360-362.
- Vermote K.A.G., Bergenhuizen A.L.R., Gielen I., van Bree H., Duchateau L., Van Ryssen B. (2010). Elbow lameness in dogs of six years and older: Arthroscopic and imaging findings of medial coronoid disease in 51 dogs. *Veterinary and Comparative Orthopaedics and Traumatology* 23, 43-50.
- Walde I., Tellhelm B. (1991). Fragmented medial coronoid process of the ulna (Fcp) and osteochondritis dissecans (Ocd) of the canine elbow joint – literature review, diagnosis and therapy. *Wiener Tierärztliche Monatschrift* 78, 414-424.
- Walker T.M. (1998). A redefined type of elbow dysplasia in the dog – two cases. *The Veterinary Journal* 39, 573-575.

- Wind A.P. (1982). Incidence and radiographic appearance of fragmented coronoid process. *California Veterinarian* 6, 19-25.
- Woolliams J.A., Lewis T.W., Blott S.C. (2011). Canine hip and elbow dysplasia in UK Labrador Retrievers. *The Veterinary Journal* 189, 169-176.



v-gel® larynx maskers voor konijn en kat.

De naam voor dit unieke product staat voor de V van veterinair en gel voor het zachte en soepele materiaal waaruit het is samengesteld.

De veterinaire varianten voor konijn en kat zijn ontwikkeld naar analogie van de humane supraglottis larynx cap die al vele jaren haar unieke eigenschappen in het humane luchtweg management heeft bewezen.

V-gel® larynx maskers zijn gevormd naar de specifieke anatomie van de oropharynx van het konijn of de kat en verkrijgbaar in verschillende maten per doeldier. Bij de juiste maatkeuze zorgt voor een veilige perfecte aansluiting op de glottis zonder risico van trauma. Dit in tegenstelling tot het traditioneel intuberen met behulp van een endotracheaal tube met of zonder cuff of het gebruik van een mond-neus masker.

De voordelen van v-gel® ten opzichte van intuberen of gebruik van mond- neus maskers:

- de anatomische vorm in combinatie met het zachte materiaal garanderen een effectieve afsluiting zonder beschadiging van trachea en larynx, resulterend in een veilige anesthesie én optimaal comfort voor de patiënt
- snelle, veilige en makkelijke insertie
- geen postoperatieve complicaties zoals hoesten en kokhalzen
- lage ademweerstand dankzij een ruim luchtkanaal
- veilige en optimale 'pasvorm' voorkomt lekkage
- geen aversie bij de patiënt door de geur van anesthesiegassen
- super zacht en anatomisch gevormde tip voorkomt aspiratie van eventueel reflux vloeistof
- voorzien van een sample port ten behoeve monitoring dus geringe dode ruimte
- geïntegreerd bijtblok ter voorkoming van beschadiging
- materiaal is geschikt om te autoclavieren ter voorkoming van kruisinfecties

Voor meer info over prijzen en afmetingen contacteer ons.

V-gel – exclusieve distributeur voor België en Luxemburg:
MILLPLEDGE VETERINARY BVBA
 Verrekijker 38 – 8750 Wingene
 Tel : 051/703021
 e-mail : gregorym@millpledge.com
 website : www.millpledgeveterinary.nl

.....
DEMO V-GEL op EXPOVET - zaterdag 24 oktober
16u30 tot 18u30 - seminariezaal