

## Favorable outcome of conservative treatment in a cat with T9T10 intervertebral disk disease

### *Succesvolle conservatieve behandeling van discus hernia ter hoogte van T9T10 bij een kat*

<sup>1</sup>S. Van Meervenne, <sup>3</sup>H. Haers, <sup>1</sup>B. Vissers, <sup>2</sup>T. Bosmans, <sup>2</sup>L. Van Ham

<sup>1</sup> AB Läckeby Djursjukhus, Örnortorp 201, 38031 Läckeby, Sweden

<sup>2</sup> Department of Small Animal Medicine and Clinical Biology, Faculty of Veterinary Medicine, Ghent University, Salisburylaan 133, 9820 Merelbeke, Belgium

<sup>3</sup> Department of Veterinary Medical Imaging and Small Animal Orthopedics, Faculty of Veterinary Medicine, Ghent University, Salisburylaan 133, 9820 Merelbeke, Belgium

sofie.vanmeervenne@hotmail.com

#### ABSTRACT

**A 12-year-old domestic shorthair was presented with acute paraplegia. On the basis of radiography and myelography, a presumable diagnosis of disk herniation at the level of T9T10 was made. The cat was treated conservatively and recovered from paraplegia with only mild residual ataxia. Follow-up for more than one year showed no changes or recurrence of the symptoms.**

#### SAMENVATTING

Een twaalfjarige korthaar werd aangeboden met een acute verlamming van de achterpoten. Op basis van radiografie en myelografie van de wervelkolom werd een vermoedelijke diagnose van discus hernia ter hoogte van T9T10 gesteld. De kat werd conservatief behandeld en herstelde met een milde ataxie van de achterpoten als restverschijnsel. Gedurende een follow-up van meer dan een jaar werd geen herval van de symptomen gezien.

#### CASE REPORT

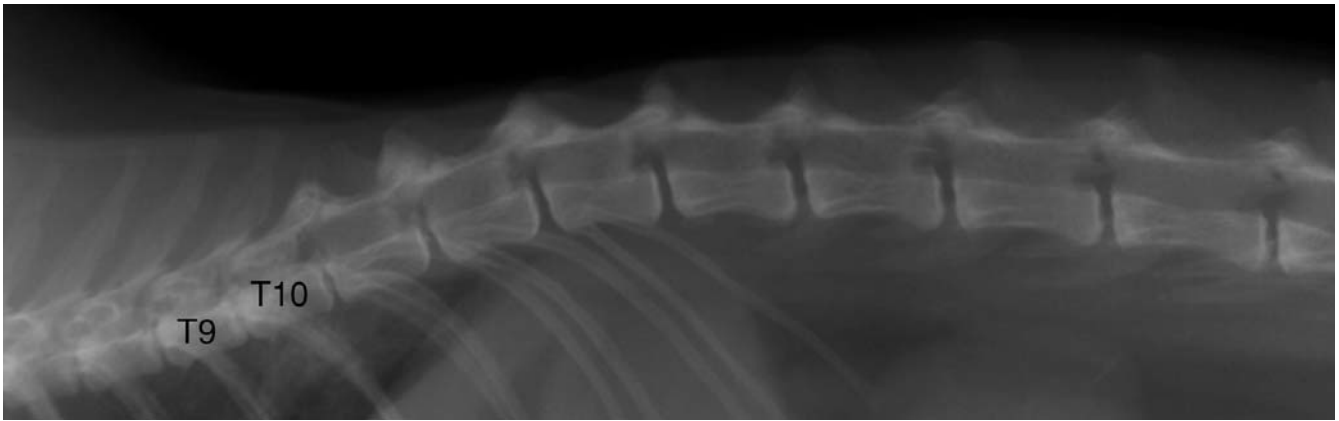
Five days before referral, a 12-year-old male neutered domestic shorthair had developed an acute onset of paraplegia. The cat lived strictly indoors and no known history of trauma or intoxication was reported by the owner. The cat had never displayed similar complaints before and he seemed to be in good general condition. The blood work and thoracic and abdominal radiographs showed no significant abnormalities, except for the narrowing of the intervertebral disk (IVD) space between T9T10 and T10T11. Treatment with dexamethasone (Rapidexon; Eurovet; 0,1 mg/kg, IM) was initiated. No improvement was observed, and in fact the condition even worsened somewhat. For this reason, the cat was referred to the Neurology Department of the Faculty of Veterinary Medicine at Ghent University.

No abnormalities were detected on general physical examination. During neurological examination, the cat appeared alert, but showed severe paraparesis. The cat was unable to stand up, but it was able to walk with the support of a sling, although it had an extremely ataxic, stilted gait in the pelvic limbs. Conscious proprioceptive deficits were noted in the pelvic limbs, with diminished hopping, which were worse on the left side than on the right side. The patellar reflexes were

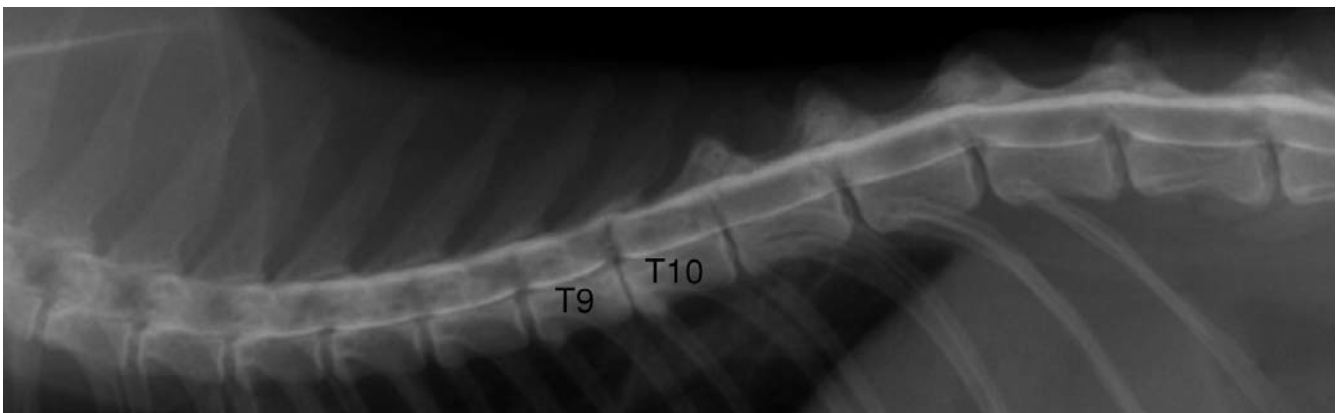
normal, while the withdrawal reflexes in the pelvic limbs were exaggerated. A crossed extensor reflex was found in the pelvic limbs. Nociception was normal in all four limbs. No neck or back pain could be elicited. The bladder function was doubtful, as the bladder was quite small but could easily be expressed manually and the cat had not urinated spontaneously. The clinical signs were ascribed to a thoracolumbar spinal cord lesion. Differential diagnoses included fibrocartilaginous embolism, myelitis caused by Feline Infectious Peritonitis (FIP) virus, neoplasia (e.g. lymphoma) of the spinal cord, spinal trauma and disk herniation.

Plain and contrast radiographs were performed under general anesthesia. The patient was premedicated with methadone (Mephenon; Federa; 0,1 mg/kg, IV). After ten minutes, the induction of anesthesia was performed with midazolam (Dormicum; Roche; 0,2 mg/kg, IV), immediately followed by propofol (Propovet; Abbott Animal Health; 3 mg/kg, IV). The cat was intubated with a 3.5 mm internal diameter endotracheal tube after 0.2 ml of lidocaine (Xylocaine 2%; AstraZeneca) was sprayed on the laryngeal mucosa to prevent the occurrence of laryngeal spasms. Anesthesia was further maintained with isoflurane in 100 oxygen, delivered by a semi-closed anesthetic rebreathing circuit.

Radiographic examination of the thoracolumbar



**Figure 1.** On plain radiographs narrowing of the intervertebral (IV) disc space between T9 and T10 with (mild) sclerosis of the adjacent endplates and less severely between T10 and T11 is observed. The IV foramen is increased in opacity at both these levels.



**Figure 2.** Lateral projection of the myelography shows a slight dorsal deviation of the ventral contrast column (10-15% the height of the vertebral canal) and a narrowing and decreased opacity of the dorsal column between the caudal third of T9 and the cranial aspect of T10. Additionally, the ventral column is slightly deviating dorsally at the IV disc spaces T12-T13 and T13-L1 but without a narrowing of the dorsal column. Between T12 and T13, a slight splitting of the contrast column is visible.

column was performed. Plain radiographs showed a narrowing of the IVD space between T9 and T10, with mild sclerosis of the adjacent endplates and a less severe narrowing between T10 and T11. The intervertebral foramen was increased in opacity at these levels (Figure 1). A lumbar myelogram was performed inserting a 22G spinal needle between L5 and L6 in the subarachnoid space. Cerebrospinal fluid (CSF) was obtained and 0.3mL/kg body weight of a non-ionic iodinated contrast medium (Ultravist; Schering; 0.3 ml/kg, subarachnoidally) was injected. On post-contrast images, the lateral projection showed a slight dorsal deviation of the ventral contrast column (10-15% the height of the vertebral canal) and a narrowing and decreased opacity of the dorsal column between the caudal third of T9 and the cranial aspect of T10. Additionally, it showed the ventral column slightly deviating dorsally at the IVD spaces T12-T13 and T13-L1, but without a narrowing of the dorsal column. Between T12 and T13, a slight splitting of the contrast column was observed (Figure 2). The ventrodorsal projection showed a slight lateral deviation of both right and left contrast columns at the IVD space between T9 and T10. The myelographic findings indicated an extradural compression of the spinal cord

at the level of the IVD space between T9 and T10, with herniation of the IVD between T9 and T10 being the most likely differential diagnosis.

CSF analysis was not conducted, as it appeared to be contaminated with blood.

Because the owner declined surgery and because the compression of the spinal cord on the myelogram seemed mild, the cat was treated conservatively. Moreover, the neurological clinical grade of the cat did not predict a bad prognosis. A short course of prednisolone in diminishing dose (Prednisolone; Kela Laboratoria; 3 days 1mg/kg, 3 days 0.5 mg/kg, 3 days 0.25 mg/kg, PO) was instituted and cage rest was advised for 4 weeks.

After one week the cat was able to walk without support, although severe ataxia made walking very difficult. After 3 weeks, the ataxic gait improved remarkably. At that time, no more proprioceptive deficits were noted. Three months later, the cat still had a discrete stilted, ataxic gait, which seemed worse in the morning and improved after some exercise during the day. According to the owner, the quality of the cat's life was no longer impaired by the neurological deficits. Follow-up after 1 year revealed no further changes.

## DISCUSSION

Although a lot of attention has recently been given to feline intervertebral disk disease (IVDD) in the veterinary literature, clinically relevant disk herniation in cats is still quite rare (Heavner, 1971; Littlewood *et al.*, 1984; Kathmann *et al.*, 2000; Knipe *et al.*, 2001; Muñana *et al.*, 2001; Lu *et al.*, 2002; Rayward, 2002; Fraser McConnell and Garosi, 2004; Smith and Jeffery, 2006; Maritato *et al.*, 2007; Harris and Dhupa, 2008). A 0.12% incidence of disk herniation has been reported in feline clinical patients and a 4% incidence of disk herniation in cats with spinal cord disease (Muñana *et al.*, 2001; Marioni-Henry *et al.*, 2004). More common causes of spinal cord disease are FIP and lymphoma (Marioni-Henry *et al.*, 2004).

The mean age of the cats with disk disease reported in the literature is 7 years, although the age ranges between 18 months and 17 years (Heavner, 1971; Seim and Nafe, 1981; Littlewood *et al.*, 1984; Kathmann *et al.*, 2000; Knipe *et al.*, 2001; Muñana *et al.*, 2001; Lu *et al.*, 2002; Rayward, 2002; Fraser McConnell and Garosi, 2004; Smith and Jeffery, 2006; Maritato *et al.*, 2007; Harris and Dhupa, 2008). Post-mortem studies of disk degeneration in cats revealed an increase in the incidence and severity in cats between 11 and 14 years of age. These changes were seen in a group of clinically normal cats. Hence, these findings were classified as insignificant disk protrusions (King *et al.*, 1958; King and Smith, 1960a; King and Smith, 1960b; King and Smith, 1964). As the cat in this report was 12 years old, it is possible that degenerative changes in older cats can become clinically significant.

Disk disease has been reported in various breeds of cats. A predisposition for pure-bred cats has been proposed, but to date, more domestic breeds have been reported to have clinically significant disk disease (Kathmann *et al.*, 2000). There seems to be no sex predisposition in cats for developing disk disease. Therefore, neither breed nor gender can specify the signalment of cats with disk disease. The cat in this report was a cat that lived indoors. In the retrospective study by Muñana *et al.* (2001), most of the cats were also kept strictly indoors, which might indicate that disk rupture happened spontaneously and no traumatic event contributed to the development of feline disk disease.

Most of the cats described in the literature with clinically relevant IVDD suffered from lumbar (16 cats), thoracolumbar (8 cats), lumbosacral (6 cats), thoracic (4 cats) or cervical disk disease (4 cats) (Heavner, 1971; Seim and Nafe, 1981; Littlewood *et al.*, 1984; Wheeler *et al.*, 1985; Kathmann *et al.*, 2000; Knipe *et al.*, 2001; Muñana *et al.*, 2001; Lu *et al.*, 2002; Fraser McConnell and Garosi, 2004; Smith and Jeffery, 2006; Maritato *et al.*, 2007; Harris and Dhupa, 2008). The cat described in this report had an uncommon localization at T9T10. It is rare for IVDD to develop on this location because of the presence of intercapitulum ligaments from T2 to T10. These ligaments connect the rib heads and usually prevent herniation of the IVD.

This location was reported in a cat once before, associated with disk herniation (Wheeler *et al.*, 1985). The Siamese cat in that case report was diagnosed with a protrusion at T9T10 and was treated surgically without improvement.

In the current case report, there was only a mild narrowing of the columns centered over the affected IV disc space with slight asymmetry. An extrusion would cause more severe and diffuse narrowing. A protrusion would present as a more chronic complaint and results most often in a symmetrical distribution of the contrast columns. Therefore, a high velocity, low volume disk herniation is suspected in which symptoms are caused by contusion and, to a lesser degree, by compression of the spinal cord.

The main differential diagnosis for this patient was fibrocartilaginous embolism (FCE). This condition is typically associated with a peracute onset and the absence of spinal pain, and it improves with time. However, FCE often causes asymmetrical deficits and does not have an extradural pattern on contrast radiographs (Mackay *et al.*, 2005).

Analysis of CSF was not conducted in this case, as it appeared very bloody. This feature is recognized in most reports where CSF was collected caudal to the lesion (Knipe *et al.*, 2001; Lu *et al.*, 2002).

The treatment of choice suggested by most authors is surgery. However, upon critically reading the studies, one cannot help but note that many patients did have residual neurological deficits after surgery. Nevertheless, the best outcomes were reported in surgically treated cats, compared to only 4 cases that were treated conservatively with variable outcomes (Littlewood *et al.*, 1984; Kathmann *et al.*, 2000; Knipe *et al.*, 2001; Muñana *et al.*, 2001; Lu *et al.*, 2002).

Considering the outcome in the cat reported here as satisfying and good with only mild residual deficits after 1 year, conservative treatment should be a valuable alternative to the surgical treatment of IVDD in cats with minimal compression of the spinal cord on imaging modalities.

## CONCLUSION

T9T10 is an unusual level for IVDD, in this case presented in a 12-year-old domestic shorthair which lived strictly indoors. This case report illustrates that conservative treatment can be a valuable alternative for surgical therapy in cases where only mild compression is visible on imaging modalities.

## REFERENCES

- Fraser McConnell J., Garosi L.S. (2004). Intramedullary intervertebral disk extrusion in a cat. *Veterinary Radiology & Ultrasound* 45, 327-330.
- Harris J.E., Dhupa S. (2008). Lumbosacral intervertebral disk disease in six cats. *Journal of the American Animal Hospital Association* 44, 109-115.
- Heavner J.E. (1971). Intervertebral disc syndrome in the cat. *Journal of the American Veterinary Medical Association* 159, 425-427.

- Kathmann I., Cizinauskas S., Rytz U., Lang J., Jaggy A. (2000). Spontaneous lumbar intervertebral disc protrusion in cats: literature review and case presentations. *Journal of Feline Medicine and Surgery* 2, 207-212.
- King A.S., Smith R.N., Kon V.M. (1958). Protrusion of the intervertebral disc in the cat. *Veterinary Record* 70, 509-515.
- King A.S., Smith R.N. (1960a). Disc protrusions in the cat: distribution of dorsal protrusions along the vertebral column. *Veterinary Record* 72, 335-337.
- King A.S., Smith R.N. (1960b). Disc protrusion in the cat: age incidence of dorsal protrusions. *The Veterinary Record* 72, 381-383.
- King A.S., Smith R.N. (1964). Degeneration of the intervertebral disc in the cat. *Acta Orthopaedica Scandinavia* 34, 139-158.
- Knipe M.F., Vernau K.M., Hornof W.J., LeCouteur R.A. (2001). Intervertebral disc extrusion in six cats. *Journal of Feline Medicine and Surgery* 3, 161-168.
- Littlewood J.D., Herrtage M.E., Palmer A.C. (1984). Intervertebral disc protrusion in a cat. *Journal of Small Animal Practice* 25, 119-127.
- Lu D., Lamb C.R., Wesselingh K., Targett M.P. (2002). Acute intervertebral disc extrusion in a cat: clinical and MRI findings. *Journal of Feline Medicine and Surgery* 4, 65-68.
- MacKay A.D., Rusbridge C., Sparkes A.H., Platt S.R. (2005). MRI characteristics of suspected acute spinal cord infarction in two cats, and a review of the literature. *Journal of Feline Medicine and Surgery* 7, 101-107.
- Marioni-Henry K., Vite C.H., Newton A.L., van Winkle T.J. (2004). Prevalence of diseases of the spinal cord of cats. *Journal of Veterinary Internal Medicine* 18, 851-858.
- Maritato K.C., Colon J.A., Mauterer J.V. (2007). Acute non-ambulatory tetraparesis attributable to cranial cervical intervertebral disc disease in a cat. *Journal of Feline Medicine and Surgery* 9, 494-498.
- Muñana K.R., Olby N.J., Sharp N.J.H., Skeen T.M. (2001). Intervertebral disk disease in 10 cats. *Journal of the American Animal Hospital Association* 37, 384-389.
- Rayward R.M. (2002). Feline intervertebral disc disease: a review of the literature. *Veterinary and Comparative Orthopaedics and Traumatology* 15, 137-144.
- Seim H.B., Nafe L.A. (1981). Spontaneous intervertebral disk extrusion with associated myelopathy in a cat. *Journal of the American Animal Hospital Association* 17, 201-204.
- Smith P.M., Jeffery N.D. (2006). A case of intervertebral disc protrusion in a cat. *Journal of Small Animal Practice* 47, 104-106.
- Wheeler S.J., Clayton Jones D.G., Wright J.A. (1985). Myelography in the cat. *Journal of Small Animal Practice* 26, 143-152.

## Errata

### Van waar de naam *Malassezia*?

E. J. Tjalsma

pp. 383-387 in Vlaams Diergeneeskundig Tijdschrift vol. 78, nr 6-2009

In dit artikel werd als voornaam van Dr. Dufait bij vergissing Roger opgegeven. Collega Mark Lauwerys maakte er ons attent op dat het René moet zijn.

Beste dierenarts,

In 2009 en de voorbije maanden verspreidde Vétoquinol via mailing en via de professionele pers informatie over de producten Ipakitine en Rubenal. De inhoud van deze informatieverstrekking zou mogelijk de indruk kunnen wekken dat Ipakitine en Rubenal diergeneesmiddelen zijn en bijgevolg zou er verwarring kunnen ontstaan omtrent de werkelijke status van deze producten.

Daarom benadrukt Vétoquinol, in overleg met FAGG, dat de producten Ipakitine en Rubenal niet als geneesmiddel vergund zijn. Bijgevolg hebben deze producten geen enkele therapeutische of profylactische eigenschap met betrekking tot ziektes bij dieren.

Met de meeste hoogachting,

Vétoquinol