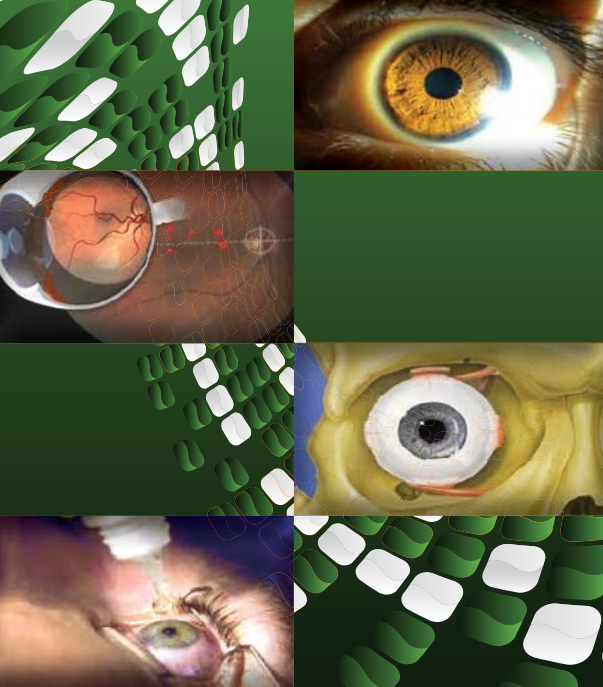















































Journal of Clinical & Experimental Ophthalmology



Editors & Editorial Board

Ophthalmology is a medical specialty dealing with the study, treatment, function and diseases of the eye. The study elaborates the surgical treatment of eye disorders ensures the care and prevention of blindness. The Journal of Clinical and Experimental Ophthalmology is a peer-reviewed ophthalmic journal; international in its scope not only renders ophthalmic studies and research advancements in surgical treatments. This journal is reliable and is freely accessible through net globally to share the innovations and advancements of ophthalmologists

ISSN: 2155-9570

 Richard B. Rosen New York Medical College, USA	 Nalini S. Bora University of Arkansas for Medical Sciences USA	 Rockefeller S. L. Young Texas Tech University Health Sciences Center Lubbock, USA	 Kuldev Singh Stanford University School of Medicine USA	 Puran S Bora University of Arkansas for Medical Sciences USA
 Ekaterini Tsilou Center for Research for Mothers and Children, USA	 Jane W. Chan University of Nevada School of Medicine USA	 Edward E. Manche Stanford University School of Medicine USA	 David Andrew Wilkie The Ohio State University Columbus OH	 Sofia Patricia Becerra Laboratory of Retinal Cell and Molecular Biology, USA
 Stephen G Schwartz Bascom Palmer Eye Institute at Naples USA	 Karsten Gronert Oregon Optometric Science University of California, USA	 Lawrence J. Rizzolo University School of Medicine, USA	 Miguel A. Materin University School of Medicine	 Michael N. Wiggins University of Arkansas for Medical Sciences USA
 Luis J. Mejico SUNY Upstate Medical University USA	 Andreas K Lauer Oregon Health & Science University USA	 Robert Noecker University of Pittsburgh USA	 Daniel Palanker Stanford University USA	 Clyde B. Schechter Albert Einstein College of Medicine USA
 Michael W Stewart Mayo School of Medicine, USA	 Jason Ng Southern California College of Optometry USA	 Nathan Radcliffe Weill Cornell Medical College, USA	 de Moraes CGV NYU School of Medicine, USA	 Gabriela Espinoza Saint Louis University Eye Institute, USA
 Gianmarco Vizzeri University of Texas Medical Branch, USA	 Roni M. Shtein University of Michigan	 Pedram Hamrah Harvard Medical School, USA	 Dongsheng Yang University of Pittsburgh School of Medicine, USA	 C S De Paiva Baylor College of Medicine, USA
 Sho-ichi Yamagishi Kurume University School of Medicine Japan	 Koh-Hei Sonoda Graduate School of Medical Science Kyushu University, Japan	 Hirohiko Kakizaki Aichi Medical University, Japan	 Burkat CN University of Wisconsin-Madison, USA	 Daniel C. Chung University of Pennsylvania School of Medicine, USA
 ZaherSbeity University of Dusseldorf Teaching Hospital, Germany	 Ingeborg Klaassen Academic Medical Center, The Netherlands	 Mark A. Babizhayev Russian Federation	 Tutomu Yasukawa Nagoya City University Graduate School of Medical Sciences, USA	 Ron A. Adelman Yale University, USA
 Nicola G Ghazi Texas Tech University Health SciencesCenter, USA	 Grazyna Adamus Oregon Health and Science University, USA	 Mencia-Gutierrez E Madrid, Spain	 Daniel Palanker Stanford University USA	 Yoko Miura University Hospital Schleswig-Holstein Germany
 KyunKeunKim Chonnam National University Medical School, South Korea	 Hyun Woong Kim Kekum-Dong, South Korea			

<http://www.omicsonline.org/jceohome.php>

Journal of Clinical & Experimental Ophthalmology - Open Access using online manuscript submission, review and tracking systems of Editorial Manager® for quality and quick review processing. Submit your manuscript at: <http://www.editorialmanager.com/clinicalgroup/>

OMICS Publishing Group
5716 Corsa Ave., Suite 110, Westlake, Los Angeles, CA
91362-7354, USA, Phone: +1-650-268-9744,
Fax: +1-650-618-1414, Toll free: +1-800-216-6499

Subretinal Lavage to Prevent Persistent Subretinal Fluid after Rhegmatogenous Retinal Detachment Surgery: A Study of Feasibility and Safety

Marc Veckeneer* , Elisabeth van Aken, David Wong, Rudolf Reyniers and Jan van Meurs

Rotterdam Eye Hospital, Schiedamsevest 180, 3011 BH Rotterdam, The Netherlands

Abstract

Purpose: To report the proof of concept of a surgical innovation.

Background: Optical coherence tomography often identifies persistent subretinal fluid (PSF) after apparently successful retinal detachment repair surgery. Based on the literature, we hypothesised that highly viscous PSF, which interferes with the normal function of the retinal pigment epithelium, can lead to these persistent blebs. We therefore devised a novel surgical manoeuvre of subretinal lavage to dilute the subretinal fluid (SRF) during surgery. We expected that this would reduce the incidence of PSF.

Methods: We report our experience with a modified surgical drainage technique carried out in 12 eyes of 12 patients with long standing retinal detachments. We implemented subretinal lavage combined with vitrectomy and gas.

Results: None of the patients developed PSF.

Conclusion: We concluded that the novel technique of subretinal lavage was safe and feasible. We propose that a controlled trial would be worthwhile.

Keywords: Persistent submacular fluid; Rhegmatogenous retinal detachment

Abbreviations: PSF: Persistent Submacular Fluid; SRF: Subretinal Fluid; RRD: Rhegmatogenous Retinal Detachment; OCT: Optical Coherence Tomography; MV: Marc Veckeneer

Introduction

After surgery for rhegmatogenous retinal detachment (RRD), although the retina appears fully attached by ophthalmoscopy, some subretinal fluid (SRF) may persist. The introduction of optical coherence tomography (OCT) resulted in multiple reports of persistent subretinal fluid (PSF) after RRD surgery [1-4].

It is currently difficult to link the incidence of PSF to any particular clinical characteristics. Both Wolfensberger and Benson et al. reported that PSF occurred more frequently after buckling than after vitrectomy [5-7]. They suggested that scleral buckling might disturb the choroidal circulation and, consequently, impair SRF absorption [8]. Others suggested that cryotherapy might break down the blood-ocular barrier. However, this seems unlikely, because various vitrectomy cases used cryotherapy and reported no blebs; but, in contrast, we avoided cryotherapy in scleral buckling surgery and, nevertheless, observed PSF in several cases. Finally, it is possible that intraocular gas bubbles might displace any SRF away from the macula; however, neither Wolfensberger nor Benson found any relationship between postoperative posturing and incidence of PSF.

We generated a new hypotheses based on the observation that PSF tended to occur in patients with long-standing retinal detachment and viscous SRF. Upon examining these SRF samples by immunohistochemistry and electron microscopy, we found high levels of cellular debris, particularly photoreceptor outer segments [9]. We therefore hypothesised that the viscous nature of the SRF interfered with its spontaneous, complete absorption by the retinal pigment epithelium, and this could lead to postoperative blebs. The aim of this interventional study was to test this hypothesis by determining whether

subretinal lavage could prevent persistent subretinal blebs, and to establish the feasibility and safety of this novel technique.

Materials and Methods

This study included non-consecutive patients with primary macula-off RRD that were scheduled for vitrectomy surgery. Selection criteria included cases of RRD that arose from retinal breaks situated away from the deepest SRF, with estimated retinal detachment (RD) duration of at least 1 week. In these cases, SRF can be highly viscous and impossible to drain completely through the existing breaks. Rather than creating an extra retinal break near the posterior pole to complete the drainage of residual fluid, transscleral drainage was performed. Patients with previous ocular history, including cataract surgery, were excluded. This study was approved by the Institutional Research Board of the Rotterdam Eye Hospital. In accordance with the IDEAL recommendations on the stages of development of surgical innovation [10], this study was defined as stage 1. Although the combination of surgical techniques was not reported before, we had previous experience with this approach. No new instruments or pharmacological aids of an experimental nature were used. All surgical procedures were performed by one surgeon (MV).

All patients underwent full ophthalmologic assessment,

***Corresponding author:** Marc Veckeneer, Rotterdam Eye Hospital, Schiedamsevest 180, 3011 BH Rotterdam, The Netherlands, Tel: 31104017642; Fax: 31104111747; E-mail: veckeneer.icare@gmail.com

Received February 23, 2011; **Accepted** April 05, 2011; **Published** April 09, 2011

Citation: Veckeneer M, van Aken E, Wong D, Reyniers R, van Meurs J (2011) Subretinal Lavage to Prevent Persistent Subretinal Fluid after Rhegmatogenous Retinal Detachment Surgery: A Study of Feasibility and Safety. J Clin Exp Ophthalmol 2:154. doi:10.4172/2155-9570.1000154

Copyright: © 2011 Veckeneer M, et al. This is an open-access article distributed under the terms of the Creative Commons Attribution License, which permits unrestricted use, distribution, and reproduction in any medium, provided the original author and source are credited.

preoperatively and 4 weeks after surgery. The assessment included best-corrected visual acuity, anterior segment examination, funduscopy with indirect ophthalmoscopy, and slit-lamp biomicroscopy with a Volk Super Quad contact lens. The extent of RD was expressed as the number of retinal quadrants that showed detachment. At the 4-week postoperative visit, we performed a Stratus OCT scan with a 6x6 mm radial line scan protocol.

The surgical procedure comprised a 23-gauge 3-port pars plana vitrectomy. Bimanual manipulation was facilitated by chandelier illumination. Rather than flattening the retina with perfluorocarbon liquids, we performed modified transscleral drainage. Briefly, a 27 gauge needle, fitted with an insertion tool (normally used for fluid drainage during conventional sclera buckling surgery) (Figure 1), was connected by tubing to a 3-way stopcock with two 5cc syringes, one filled with balanced salt solution. The needle was introduced into the subretinal space in the area of highest retinal elevation (Figure 2). The subretinal space was then inflated with BSS in order to dilute the viscous SRF. The intra-ocular pressure was normalised by venting vitreous fluid via a flute needle positioned in the mid-vitreous cavity (Figure 3). Then, after turning the stopcock, SRF was aspirated into the second syringe; this resulted in partial flattening of the RRD. At least 2 cycles of inflation and aspiration were performed. Finally, the needle was removed from the subretinal space as the retina re-attached itself. The evacuation of

Age (yrs)	68(54-80)
Gender (female, male)	3, 9
Eye (right, left)	10, 2
Duration of detachment (days)	12(7-60)
Type of detachment (round hole, horseshoe tear)	3, 9
Number of breaks	1(1-3)
Clock hours detachment	6(4-12)
BCVA, pre-op	0.033(0.003-0.16)
BCVA, post-op	0.16(0.05-0.6)
Follow up (wks)	14(6-28)

Table 1: Demographic data and outcome of 12 Patients.

any residual peripheral SRF was accelerated by raising the infusion bottle to increase the hydrostatic pressure in the vitreous cavity. For the surgeon not accustomed to transscleral drainage, alternatively, diluting the subretinal fluid could be performed by infusing fluid through a dual bore needle inserted into an existing break. The procedure is demonstrated in Video 1. The vitreous base was shaved as previously described [11].

Results

Twelve patients were recruited from March through July 2008. Demographic data and functional outcome are shown in Table 1. In two cases, minor subretinal haemorrhages (not clinically elevated) occurred at the transscleral needle introduction site. The procedure was otherwise straightforward and uncomplicated in all cases. Four weeks after surgery, ophthalmoscopy showed re-attached retinas in all twelve patients. No patients exhibited subretinal blebs or subclinical detachment on the OCT.

The values are the median(range) unless otherwise stated; BCVA: best corrected visual acuity, as tested on the Snellen chart (logMar converted); post-op: 4 weeks after surgery.

Discussion

Delayed or incomplete visual recovery after RD surgery remains an important problem involving many factors [12,13]. With OCT-facilitated diagnostics, PSF has become recognised as an additional factor. Although some visual improvement typically occurs with the disappearance of PSF, spontaneous resolution can take many months [4,6,7,16]. It is unknown whether a better outcome might be achieved by rapid fluid absorption. However, longstanding fluid between the RPE and photoreceptor layer whether it be hyaluronic acid as in experimental RD or fluid originating from the choriocapillaris as in chronic central serous chorioretinopathy causes the photoreceptor layer to progressively atrophy over time [17].

In fresh detachments, when all retinal breaks are closed, an oncotic pressure gradient and an active retinal pigment epithelium pump favour rapid fluid absorption [18]. Similarly, after a fresh bullous detachment, pneumatic retinopathy can result in complete re-attachment within 24 hours.

Longstanding detachments have a different pathophysiology. They frequently occur in phakic eyes with small breaks, particularly at inferior locations [2,19]. Non-syneretic vitreous may slow the progression of RD by tamponading the retinal breaks. Similarly, these characteristics of “young” vitreous may play a role in PSF. The highly viscous, protein-rich SRF may show enhanced adherence to retinal pigment epithelium after the excess SRF is drained.

Interestingly, the oncotic pressure in SRF increases with the

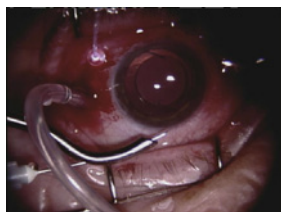

Figure 1: The insertion tool for introduction of the needle during transscleral drainage is the same as used during buckling surgery.

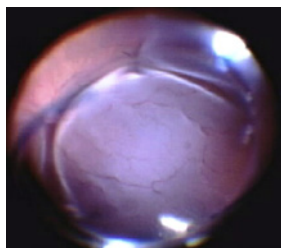


Figure 2: Lavage is performed through a 27 gauge needle inserted transsclerally into the subretinal space in the area of highest retinal elevation.

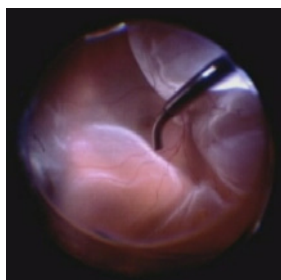

Figure 3: Maintaining stable intraocular pressure by venting vitreous fluid via a flute needle positioned in the mid-vitreous cavity.

duration of detachment [20,21]. After detachment, the loss of microvilli and the presence of hyaluronic acid can inhibit the ability of the retinal pigment epithelium to phagocytose rod outer segments; this increases the concentration of large molecules and cellular debris in the SRF [22-24].

During RRD repair, subretinal lavage may effectively lower oncotic pressure by removing most of the cellular debris and large molecules from the subretinal space. In this series, we demonstrated that subretinal lavage was feasible and safe. Also, transscleral drainage during vitrectomy allows remote SRF to be evacuated without creating an additional, often inferior, retinal break. This study improves our understanding of the pathogenesis of this relatively common condition and provides clues for improving surgical outcome. Further development of surgical technique is necessary. Lavage should preferably be isovolemic. A prototype of a dual bore cannula system to be used in non-vitreotomizing RRD repair is under development. This is particularly important since patients prone to develop PSF are mostly non-presbyopic and therefore cataract formation as a complication of RRD repair should be avoided.

References

1. Kaga T, Fonseca RA, Dantas MA, Yannuzzi LA, Spaide RF (2001) Optical coherence tomography of bleb-like subretinal lesions after retinal reattachment surgery. *Am J Ophthalmol* 132: 120-121.
2. Hagimura N, Iida T, Suto K, Kishi S (2002) Persistent foveal retinal detachment after successful rhegmatogenous retinal detachment surgery. *Am J Ophthalmol* 133: 516-520.
3. Wolfensberger TJ, Gonvers M (2002) Optical coherence tomography in the evaluation of incomplete visual acuity recovery after macula-off retinal detachments. *Graefes Arch Clin Exp Ophthalmol* 240: 85-89.
4. Baba T, Hirose A, Moriyama M, Mochizuki M (2004) Tomographic image and visual recovery of acute macula-off rhegmatogenous retinal detachments. *Graefes Arch Clin Exp Ophthalmol* 242: 576-581.
5. Wolfensberger TJ (2004) Foveal reattachment after macula-off rhegmatogenous retinal detachments occurs faster after vitrectomy than after buckle surgery. *Ophthalmology* 111: 1340-1343.
6. Benson SE, Schlottmann PG, Bunce C, Xing W, Charteris DG (2006) Optical coherence tomography analysis of the macula after vitrectomy surgery for retinal detachments. *Ophthalmology* 113: 1179-1183.
7. Benson SE, Schlottmann PG, Bunce C, Xing W, Charteris DG (2007) Optical coherence tomography analysis of the macula after scleral buckling surgery for retinal detachments. *Ophthalmology* 114: 108-112.
8. Schwartz SG, Kuhl DP, McPherson AR, Holz ER, Mieler WF (2002) Twenty-year follow-up for scleral buckling. *Arch Ophthalmol* 120: 325-329.
9. Veckeneer M, Van Aken E, Cornelissen R, Derycke L (2008) Persistent Foveal Blebs: Are They Related to the Schwartz-Matsuo Syndrome? *ARVO Meeting Abstracts* 49: 4704.
10. McCulloch P, Altman DG, Campbell WB, Flum DR, Glasziou P, et al. (2009) No surgical innovation without evaluation: the IDEAL recommendations. *Lancet* 374: 1105-1112.
11. Veckeneer M, Wong D (2009) Visualising vitreous through modified trans-scleral illumination by maximising the Tyndall effect. *Br J Ophthalmol* 93: 268-270.
12. Heimann H, Bartz-Schmidt KU, Bornfeld N, Weiss C, Hilgers RD, et al. (2007) Scleral buckling versus primary vitrectomy in rhegmatogenous retinal detachment: a prospective randomized multicenter clinical study. *Ophthalmology* 114: 2142-2154.
13. Salicone A, Smiddy WE, Venkatraman A, Feuer W (2006) Visual recovery after scleral buckling procedure for retinal detachment. *Ophthalmology* 113: 1734-1742.
14. Brazitikos PD, Androudi S, Christen WG, Stangos T (2005) Primary pars plana vitrectomy versus scleral buckle surgery for the treatment of pseudophakic retinal detachment: a randomized clinical trial. *Retina* 25: 957-964.
15. Mendrinou E, Dang-Burgener NP, Stangos AN, Sommerhalder J, Pournaras CJ (2008) Primary vitrectomy without scleral buckling for pseudophakic rhegmatogenous retinal detachment. *Am J Ophthalmol* 145: 1063-1070.
16. Seo JH, Woo SJ, Park KH, Yu YS, Chung H (2008) Influence of persistent submacular fluid on visual outcome after successful scleral buckle surgery for macula-off retinal detachment. *Am J Ophthalmol* 145: 915-922.
17. Gilbert GM, Owens SL, Smith PD, Fine SL (1984) Long-term follow-up of central serous chorioretinopathy. *Br J Ophthalmol* 68: 815-820.
18. Tsuboi S, Pederson JE (1988) Volume flow across the isolated retinal pigment epithelium of cynomolgus monkey eyes. *Invest Ophthalmol Vis Sci* 29: 1652-1655.
19. Abouzeid H, Becker K, Holz FG, Wolfensberger TJ (2009) Submacular fluid after encircling buckle surgery for inferior macula-off retinal detachment in young patients. *Acta Ophthalmol* 87: 96-99.
20. Edmund J (1968) Analysis of subretinal fluid. *Acta Ophthalmologica* 46:1184-1193.
21. Takeuchi A, Kricorian G, Marmor MF (1996) When vitreous enters the subretinal space. Implications for subretinal fluid protein. *Retina* 16: 426-430.
22. Immel J, Negi A, Marmor MF (1986) Acute changes in RPE apical morphology after retinal detachment in rabbit. A SEM study. *Invest Ophthalmol Vis Sci* 27: 1770-1776.
23. Quintyn JC, Brasseur G (2004) Subretinal fluid in primary rhegmatogenous retinal detachment: physiopathology and composition. *Surv Ophthalmol* 49: 96-108.
24. Toti P, Morocutti A, Sforzi C, De Santi MM, Catella AM (1991) The subretinal fluid in retinal detachment. A cytological study. *Doc Ophthalmol* 77: 39-46.

Submit your next manuscript and get advantages of OMICS Group submissions

Unique features:

- User friendly/feasible website-translation of your paper to 50 world's leading languages
- Audio Version of published paper
- Digital articles to share and explore

Special features:

- 100 Open Access Journals
- 10,000 editorial team
- 21 days rapid review process
- Quality and quick editorial, review and publication processing
- Indexing at PubMed (partial), Scopus, DOAJ, EBSCO, Index Copernicus and Google Scholar etc
- Sharing Option: Social Networking Enabled
- Authors, Reviewers and Editors rewarded with online Scientific Credits
- Better discount for your subsequent articles

Submit your manuscript at: www.editorialmanager.com/clinicalgroup

