

Acute hemorrhagic syndrome by bracken poisoning in cattle in Belgium

Acuut hemorragisch syndroom door adelaarsvarenintoxicatie bij runderen in België

¹E. Plessers, ²B. Pardon, ²P. Deprez, ¹P. De Backer, ¹S. Croubels

¹Department of Pharmacology, Toxicology and Biochemistry,

²Department of Large Animal Internal Medicine,

Faculty of Veterinary Medicine, Ghent University, Salisburylaan 133, B-9820 Merelbeke, Belgium

elke.plessers@UGent.be

A BSTRACT

In August 2007, two Belgian blue cows which had been on pasture for three months, showed high fever (41.4°C), epistaxis, melena, cutaneous bleeding, a stiff gait and red lesions on the udder. Blood examination revealed severe pancytopenia, and bluetongue virus serotype 8 could be demonstrated by PCR. Despite blood transfusion and supportive treatment, both animals died within 6 days after the initial symptoms. At necropsy, an explicit case of a blood coagulation disorder was observed. Inspection at pasture, one week later, showed the presence of numerous regenerated young fronds of *Pteridium aquilinum*. Whereas the stiff gait and the red lesions on the udder were likely bluetongue virus associated, other symptoms were consistent with acute bracken poisoning (acute hemorrhagic syndrome). The present report illustrates that also in Belgium, where the density of bracken fern is relatively low, pastures should be carefully screened for the presence of young fronds.

SAMENVATTING

In augustus 2007 vertoonden twee Belgisch witblauwe koeien na drie maanden weidegang hoge koorts (41,4°C), epistaxis, melena, bloedingen ter hoogte van de huid, een stijve gang en rode letsels op de uier. Het bloedonderzoek toonde ernstige pancytopenie aan en blauwtongvirus serotype 8 werd aangetoond via PCR. Ondanks een bloedtransfusie en een ondersteunende behandeling stierven beide dieren binnen de zes dagen na aanvang van de symptomen. Op autopsie werd een uitgesproken beeld van een bloedstollingsstoornis aangetoond. Bij inspectie van de weide één week later konden veel jonge bladeren van adelaarsvaren (*Pteridium aquilinum*) worden waargenomen. De stijve gang en de rode letsels op de uier waren sterk indicatief voor de blauwtongvirusinfectie, terwijl de andere symptomen overeenkwamen met een acute adelaarsvarenintoxicatie (acuut hemorragisch syndroom). Dit voorval toont aan dat het ook in België, waar de densiteit van adelaarsvarens over het algemeen relatief laag is, van belang is om weiden grondig te inspecteren op de aanwezigheid van jonge adelaarsvarens.

INTRODUCTION

Bracken fern (*Pteridium aquilinum*) is one of the most commonly distributed weed species in the world. In both ruminants and non-ruminants, the deleterious effects of the ingestion of fresh or dried plants have long been known. In cattle, both acute poisoning, presenting as a hemorrhagic syndrome due to bone marrow damage, and chronic poisoning, presenting as tumor development in the bladder (bovine enzootic hematuria) and gastro-intestinal tract have been frequently described in different parts of the world (Naftalin and Cushnie, 1951; Evans and Mason, 1965; Evans, 1968; Jarrett *et al.*, 1978; Hopkins, 1986; Smith *et al.*, 1988; Bertone, 1990; Xu, 1992; Marrero *et al.*,

2001; Gava *et al.*, 2002; Karimuribo *et al.*, 2008; Roperto *et al.*, 2010). In Belgium on the other hand, bracken fern is less ubiquitous, except on woodland soils. This might explain why the plant was not included in a review about animal poisonings in Belgium (Vandenbroucke *et al.*, 2010). Moreover, to the authors' knowledge, this is the first article describing a case of acute bracken poisoning in cattle in Belgium.

CASE DESCRIPTION

Case history

At the end of April 2007, three three-year-old Belgian blue cows were pastured in a forested area in

the province of Limburg in Belgium. Three months later (at the beginning of August 2007), one of the cows showed epistaxis, high fever, melena and a stiff gait, upon which the three animals were stabled immediately. After an initial on-site treatment with trimethoprim-sulfadoxin (Borgal[®], Virbac), flunixin meglumine (Finadyne[®], Intervet) and doramectin (Dectomax[®], Eli Lilly), the affected cow was referred to the Faculty of Veterinary Medicine of Ghent University for further examination. Five days later, a second cow developed identical symptoms, while the third cow remained clinically healthy. At that time, bluetongue virus serotype 8 (BTV8) was circulating in the region (Thiry *et al.*, 2006).

Clinical examination

The cow was anorectic, depressed, in sternal recumbency, and showed signs of dehydration (sunken eyes). Epistaxis from both nostrils (Figure 1), streaks of blood in the neck and flank regions (insect bites), scleral ecchymosis and petechial bleeding on the conjunctivae and gingival mucosae were obvious. On the udder and teats, red lesions were observed. The animal was severely pyretic (41.4°C), and had an elevated pulse and breathing rate. Regarding the gastro-intestinal tract, ruminal contractions were absent, and melena was observed.

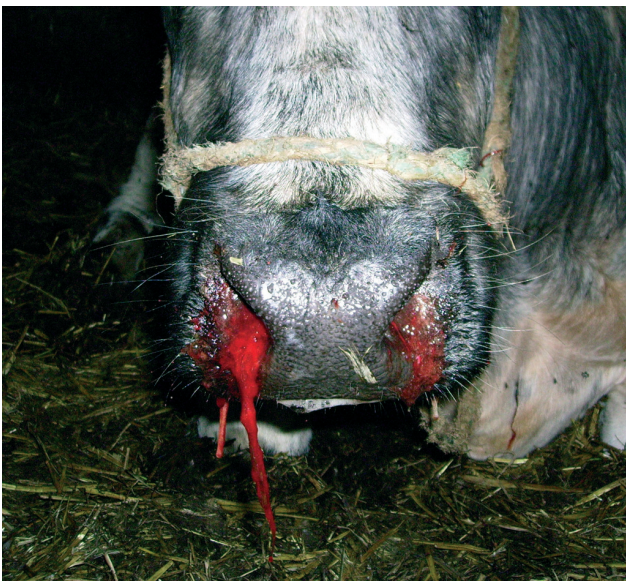

Figure 1. Epistaxis in a three-year-old Belgian blue cow suffering from coagulation disorders due to acute bracken fern poisoning.

Blood examination

Jugular plasma (ethylenediaminetetraacetic acid (EDTA) and citrate) and serum samples were collected for standard hematology, coagulation and biochemistry tests as well as for the detection of BTV8 (PCR) and bovine viral diarrhoea virus (BVDV) (ELISA) antigen.

The total white blood cell count was 0.3×10^9 cells/l (reference: $6-9 \times 10^9$), with 86% lymphocytes (45-75) and 14% granulocytes and monocytes (25-55). The packed cell volume was 0.12 l/l (0.25-0.45) and the number of platelets 17×10^9 platelets/l ($100-800 \times 10^9$). The coagulation tests (prothrombin coagulation time (PT) and activated partial thromboplastin time (APTT)), as well as fibrinogen were normal.

Total serum protein was 58 g/l (60-80), and blood potassium was 2.5 mmol/l (3.5-4). Bilirubine and ureum were considerably elevated (87 μ mol/l (2.5-6) and 26.3 mmol/l (3-8) respectively), as were the liver and muscle enzymes. The antigen detection tests reported a distinct positive result for BTV8 and a negative outcome for BVDV.

Treatment and further evolution

Upon arrival, an indwelling catheter was placed in the jugular vein, and a blood transfusion (eight liters) was performed. Further treatment consisted of perfusion with isotonic saline, cefquinome (1 mg/kg IV, Cobactan[®], Intervet) and flunixin meglumine (2 mg/kg IV, Finadyne[®], Intervet). After this treatment, an initial improvement of the clinical condition and the packed cell volume was observed. However, four days later, a second blood transfusion was required, which was followed by an intravenous administration of dexamethasone (Rapidexon[®], Eurovet) in order to control vasculitis. Despite this therapy, the cow died during the following night (six days after the onset of the symptoms).

The second cow received a blood transfusion and antimicrobial and anti-inflammatory drugs on the farm, but also died four days after the initial symptoms. The third animal did not develop any symptoms.

Post mortem examination

Necropsy demonstrated an explicit case of a blood coagulation disorder, with hemorrhagic content in the abomasum as well as in the small and large intestines. Furthermore, numerous petechial hemorrhages were observed on the serosae of the abdominal organs. The rumen contained no plants that could be identified with confidence. After necropsy, no further histological analyses were performed.

Inspection of the pasture

Based on the clinical examination and hematology, bracken fern poisoning was suspected. Upon request, it was reported by the farmer that bracken fern was indeed present next to the pasture but not on the pasture. However, the inspection one week after the animals were stabled, revealed numerous young fronds within the enclosure of the pasture (Figure 2). Outside the fence, adult plants were ubiquitous, suggesting that the two affected cows had been ingesting the young fronds systematically.



Figure 2. Adult plants of *Pteridium aquilinum* outside the pasture enclosure and regrowth of fronds within the enclosure observed one week after stabling of the animals.

DISCUSSION

Bracken fern (*Pteridium aquilinum*) belongs to the family of the *Dennstaedtiaceae*, and is an ancient and large (height: 0.5-4.0 m) plant (Figure 3). The name refers to the double-headed eagle that can be recognized at cross-section of the stem (Figure 4). Bracken is distributed worldwide, except in very cold or dry regions. In Belgium, its distribution is mainly localized in forested areas, where plants can concentrate on the borders of pastures (Van Genderen *et al.*, 1996). Bracken is a perennial fern that produces spores by the end of the third or fourth growing season. If spores have been shed under favorable conditions, new young plants will appear 6-7 weeks later. All parts of the plant, including the fronds and the rhizomes (or root-stocks), are toxic, and drying does not remove the toxicity (Osweiler, 1996). Rapid regeneration of the plant is observed in response to disturbances, such as cutting and fire (Nicholls, 2001), suggesting a similar expansion after grazing.

The toxic substances are cyanogenic glycosides (mainly prunasin), a vitamin B₁-decomposing enzyme (thiaminase) and factors with carcinogenic activity (particularly ptaquiloside) (Fenwick, 1988; Vetter, 2009). The cyanogenic glycosides have only very seldom led to cyanide poisoning in animals (Fenwick, 1988), while thiaminase induces a vitamin B₁-deficiency in non-ruminants. Horses are particularly susceptible (Evans *et al.*, 1951; Kelleway and Geovjian, 1978), while reports of acute bracken intoxication in pigs are less common, except in young animals after long term exposure (Harwood *et al.*, 2007). Affected animals initially show anorexia and ataxia, followed by convulsions and death. Ruminants on the other hand are generally resistant, due to the synthesis of vitamin B₁ by the ruminal microbiological flora. However, polioencephalomalacia associated with vitamin B₁-deficiency has been experimentally induced in sheep using bracken fern rhizomes (Bakker *et al.*, 1980). In

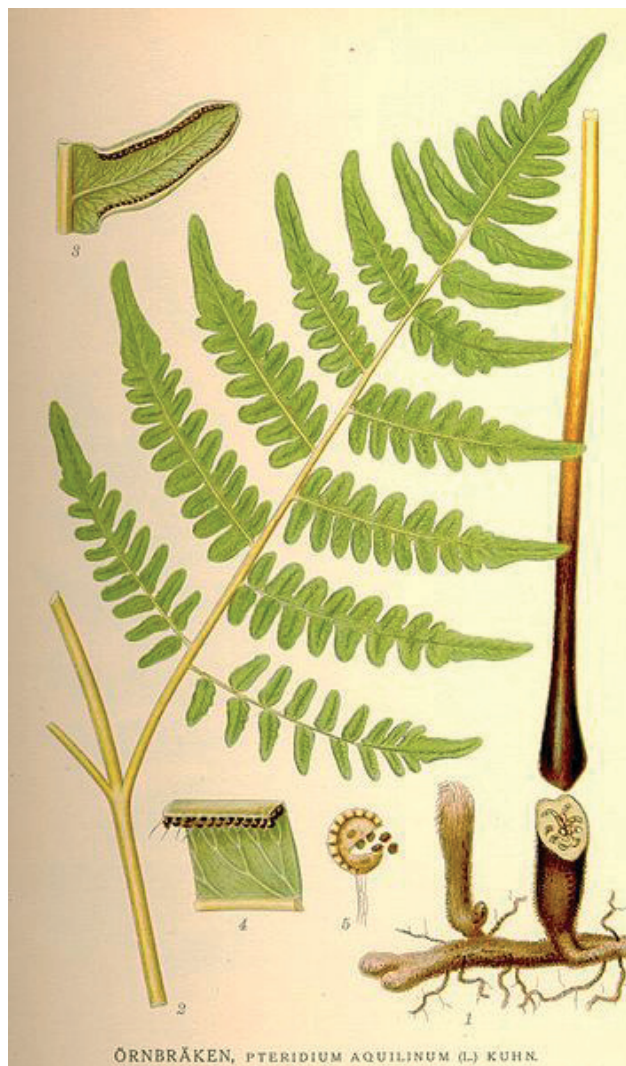

Figure 3. *Pteridium aquilinum*



Figure 4. Cross-section of the stem of bracken fern: a manner to identify *Pteridium aquilinum* (Prof. Dr. Verbeke).

cattle, the chronic uptake of the carcinogenic sesquiterpene glycoside ptaquiloside is responsible for the development of bladder tumors (referred to as bovine enzootic haematuria) and intestinal tumours (van der Hoeven *et al.*, 1983; Smith *et al.*, 1988; Potter and

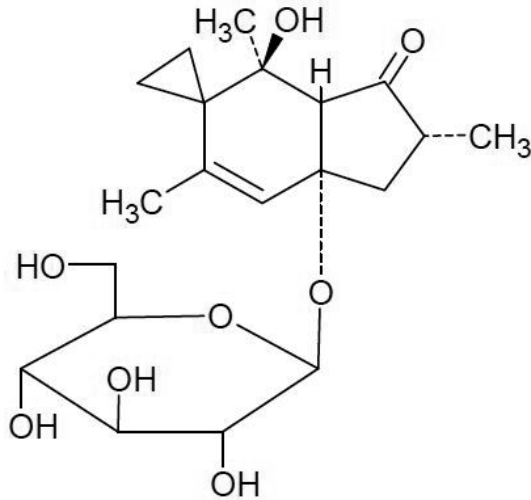


Figure 5. The structure of ptaquiloside, one of the toxic substances of bracken fern (*Pteridium aquilinum*).

Baird, 2000; Yamada *et al.*, 2007) (Figure 5). Its carcinogenicity is realized by the alkylation of DNA, resulting in ptaquilosin-DNA adducts (Prakash *et al.*, 1996). Moreover, the association with the presence of bovine papillomaviruses (type 2 and type 4) has been suggested (Jarrett *et al.*, 1978; Campo *et al.*, 1992; Borzacchiello *et al.*, 2003). The etiological agent responsible for acute bracken poisoning in cattle, causing acute hemorrhagic syndrome, has not been identified yet, and is therefore described as aplastic anemia factor (Blowey and Weaver, 2003). However, ptaquiloside has been suggested by Hirono *et al.* (1984) and Radostitis *et al.* (2007), hence applying the term osteomyelotoxic ptaquiloside poisoning. Furthermore, it has been described that ptaquiloside concentrations in bracken vary among geographic locations and that the concentrations are related to the occurrence of both acute and chronic bracken poisoning in cattle (Smith and Seawright, 1995; Rasmussen *et al.*, 2008). Also in sheep, long-term exposure to ptaquiloside induces tumors in the bladder, as well as bright-blindness, caused by progressive retinal degeneration (Hirono *et al.*, 1993; Potter and Baird, 2000). Goats on the other hand are the only livestock that appear unsusceptible. Besides the toxic effects in animals, bracken has been reported to be harmful to human health. Primarily, the inhalation and subsequent ingestion of spores can be hazardous, as it has been shown that spore extracts can damage DNA and in this way exert carcinogenic effects (Povey *et al.*, 1996; Simán *et al.*, 2000). Secondly, the passage of ptaquiloside into milk from bracken fed cows has been demonstrated (Alonso-Amelot *et al.*, 1996). However, this risk should be reduced by dilutions during dairy production (Wilson *et al.*, 1998). In geographically remote rural areas on the other hand, where locally produced milk is consumed, a larger incidence of gastric and oesophageal

cancers has been reported (Villalobos-Salazar, 1989).

Cattle generally only graze bracken in the absence of more suitable feed, although it has been observed that individual animals can develop a taste for the plant (Anonymous, 2005). Young shoots and fronds are particularly preferred, while these parts accumulate some of the toxic substances (Fenwick, 1988; Gil da Costa *et al.*, 2012). Furthermore, Hopkins (1990) noted considerably greater numbers of bracken intoxication in years with prolonged drought. Likewise, the month in which the three animals were placed on the pasture (April 2007) has been confirmed to be the driest month in Belgium since the commencement of the observations of the Royal Meteorological Institute. These data suggest poor grass availability in this period.

The toxic effects of bracken fern appear to be cumulative and symptoms of acute bracken poisoning are observed one to three months after the transfer of the herd to a bracken-infested pasture, and even up to two weeks after the animals are removed from this pasture (Evans, 1968; Xu, 1992; Anonymous, 2005; Vetter, 2009). Data on the amount of ingested bracken during this period vary from 50 to around 100% of the body weight of the animal, indicating that the uptake of small amounts are negligible (Seifert, 1996; Radostitis *et al.*, 2007; Anjos *et al.*, 2009; Vetter, 2009). The development of bovine enzootic hematuria and bladder tumors on the other hand requires a long-term bracken uptake, ranging from 225 to 550 days, depending on the provided amount of bracken (0.5-2 kg per day) (Fenwick, 1988; Vetter, 2009).

The symptoms of acute hemorrhagic syndrome include weakness, anorexia, high fever (40.5 to 42.5°C), breathing difficulties and multiple hemorrhages. Furthermore, sudden death is occasionally observed (Blowey and Weaver, 2003). A bracken-induced depression of the bone marrow sequentially leads to severe leukopenia (particularly granulocytopenia) and thrombocytopenia, explaining the hemorrhages and the subsequent anemia (Naftalin and Cushnie, 1951; Fenwick, 1988; Xu, 1992; Anjos *et al.*, 2009). Besides an acute bracken fern intoxication, blood coagulation disorders and pancytopenia can be caused by BVDV type II, auto- or allo-immune bone marrow destruction or any acute septicemic process (Braun *et al.*, 1996; Ridpath *et al.*, 2006; Pardon *et al.*, 2010; Pardon *et al.*, 2011). Based on the negative outcome of the BVDV-antigen-test, the case history, the clinical signs, the blood results, the necropsy findings and the inspection of the pasture, the most probable diagnosis for the two animals in this case was bracken fern intoxication. All symptoms described in the literature are consistent with the findings in the two affected cows, except for the stiff gait and the red lesions on the udder and teats. The latter symptoms are most likely due to the concurrent BTV8 infection (Thiry *et al.*, 2006; Elbers *et al.*, 2008; Brenner *et al.*, 2011). BTV8 induces fever as well, although the high fever observed in this case (41.4°C) is rather the consequence of the severe

leukopenia, which resulted in a higher susceptibility to infections (Fenwick, 1988; Anonymous, 2005; Gil da Costa *et al.*, 2012). The elevated liver enzymes can reflect bracken-induced liver degeneration (Xu, 1992), while the increase in muscle enzymes can be explained by the prolonged decubitus. The observed hyperbilirubinemia and uremia on the other hand can be clarified by the dehydrated condition of the animal, whereas hypokalemia could be the consequence of anorexia.

The prognosis of acute hemorrhagic syndrome is generally poor and most animals (> 90%) die within 1-10 days after the onset of the symptoms (Anonymous, 2005; Radostitis *et al.*, 2007; Anjos, 2009). Treatment with the frequently reported antidote for bovine bracken fern toxicosis, DL-batyl alcohol, is of limited value to stimulate the bone marrow, especially in clinically advanced cases, and is of course prohibited in food producing animals (Osweiler, 1996). Blood or platelet transfusion from healthy animals can be useful, yet large volumes are required (minimum of 2-4 l blood). Antimicrobial agents can be administered to prevent secondary infections, and the animals should be removed from the infested pasture (Plumlee, 2004).

Prevention is primarily based on the exclusion of animals from bracken-infested pastures or at least to limit the duration of grazing (alternated grazing on bracken-contaminated and non-contaminated pastures at three-week intervals) (Pinto *et al.*, 2004; Plumlee, 2004). The control of bracken is difficult for a variety of reasons, including the extensive rhizome system (Stewart *et al.*, 2008). Several techniques are available, such as herbicide application, cutting, rolling and burning (Stewart *et al.*, 2007). Stewart *et al.* (2008) confirmed that cutting twice a year (in June and in August) is generally the most successful treatment in the UK, although the use of the herbicide asulam (Asulox[®], United Phosphorus Limited) has been suggested to be effective as well. Besides the application of asulam by hand-operated sprayers, it can be used by ground-based vehicles and helicopters, due to its high specificity to bracken. However, multiple treatments with asulam are necessary, and 100% control is only rarely achieved (Stewart *et al.*, 2007; UPL, 2008). For this reason, UPL (2008) advises to retreat surviving plants as soon as they are fully expanded either in the year following the initial application or, more likely, in the second year. Besides the different possibilities to control bracken, it is important to inform the animal owners regarding its toxicity and to provide animals with suitable feed, particularly during dry periods.

In conclusion, the present report illustrates that despite the low density of bracken fern in Belgian pastures, lethal bracken poisoning can occur when the available forage is reduced by drought. As systematic grazing masks the presence of bracken, profound inspection of the pasture is advisable prior to the transfer of the herd.

REFERENCES

- Alonso-Amelot M.E., Castillo U., Smith B.L., Lauren D.R. (1996). Bracken ptaquiloside in milk. *Nature* 382, 587.
- Anjos B.L., Irigoyen L.F., Piazer J.V.M., Brum J.S., Figuera R.A., Barros C.S.L. (2009). Experimental acute poisoning by bracken fern (*Pteridium aquilinum*) in cattle. *Pesquisa Veterinária Brasileira* 29, 753-766.
- Anonymous (2005). Toxicology. In: Kahn C.M. (editor). *The Merck Veterinary Manual*. 9th Ed., Merck & Co., Inc., N.J., p. 2337-2543.
- Bakker H.J., Dickson J., Steele P., Nottle M.C. (1980). Experimental induction of ovine polioencephalomalacia. *The Veterinary Record* 107, 464-466.
- Bertone A.L. (1990). Neoplasms of the bovine gastrointestinal tract. *Veterinary Clinics of North America: Food Animal Practice* 6, 515-524.
- Blowey R.W., Weaver A.D. (2003). Toxicological disorders. In: *Color Atlas of Diseases and Disorders of Cattle*. 2nd Ed., Elsevier Limited, Oxford, p. 209-218.
- Borzacchiello G., Ambrosio V., Roperto S., Poggiali F., Tsirimionakis E., Venuti A., Campo M.S., Roperto F. (2003). Bovine papillomavirus type 4 in oesophageal papillomas of cattle from the south of Italy. *Journal of Comparative Pathology* 128, 203-206.
- Braun U., Thür B., Weiss M., Giger T. (1996). Bovine virus diarrhoea/mucosal disease in cattle--clinical findings in 103 calves and cattle. *Schweizer Archiv für Tierheilkunde* 138, 465-475.
- Brenner J., Batten C., Yadin H., Bumbarov V., Friedgut O., Rotenberg D., Golender N., Oura C.A.L. (2011). Clinical syndromes associated with the circulation of multiple serotypes of bluetongue virus in dairy cattle in Israel. *The Veterinary Record* 169, 389.
- Campo M.S., Jarrett W.F.H., Barron R., O'Neil B.W., Smith K.T. (1992). Association of bovine papillomavirus type 2 and bracken fern with bladder cancer in cattle. *Cancer Research* 52, 6898-6904.
- Elbers A.R.W., Backx A., Meroc E., Gerbier G., Staubach C., Hendrickx G., van der Spek A., Mintiens K. (2008). Field observations during the bluetongue serotype 8 epidemic in 2006 - I. Detection of first outbreaks and clinical signs in sheep and cattle in Belgium, France and the Netherlands. *Preventive Veterinary Medicine* 87, 21-30.
- Evans E.T.R., Evans W.C., Roberts H.E. (1951). Studies on bracken poisoning in the horse. *British Veterinary Journal* 107, 364-371.
- Evans I.A., Mason J. (1965). Carcinogenic activity of bracken. *Nature* 208, 913-914.
- Evans I.A. (1968). The radiomimetic nature of bracken toxin. *Cancer Research* 28, 2252-2261.
- Fenwick G.R. (1988). Bracken (*Pteridium aquilinum*) - Toxic effects and toxic constituents. *Journal of the Science of Food and Agriculture* 46, 147-173.
- Gava A., da Silva Neves D., Gava D., de Moura Saliba T., Schild A.L., Riet-Correa F. (2002). Bracken fern (*Pteridium aquilinum*) poisoning in cattle in southern Brazil. *Veterinary and Human Toxicology* 44, 362-365.
- Gil da Costa R.M., Bastos M.M.S.M., Oliveira P.A., Lopes C. (2012). Bracken-associated human and animal health hazards: Chemical, biological and pathological evidence. *Journal of Hazardous Materials* 203-204, 1-12.
- Harwood D.G., Palmer N.M., Wessels M.E., Woodger N.G. (2007). Suspected bracken poisoning in pigs. *The Veterinary Record* 160, 914-915.

- Hirono I., Kono Y., Takahashi K., Yamada K., Niwa H., Ojika M., Kigoshi H., Niiyama K., Uosaki Y. (1984). Reproduction of acute bracken poisoning in a calf with ptaquiloside, a bracken constituent. *The Veterinary Record* 115, 375-378.
- Hirono I., Ito M., Yagyo S., Haga M., Wakamatsu K., Kishikawa T., Nishikawa O., Yamada K., Ojika M., Kigoshi H. (1993). Reproduction of progressive retinal degeneration (bright blindness) in sheep by administration of ptaquiloside contained in bracken. *Journal of Veterinary Medical Science* 55, 979-983.
- Hopkins N.C.G. (1986). Aetiology of enzootic haematuria. *The Veterinary Record* 118, 715-717.
- Hopkins A. (1990). Bracken (*Pteridium aquilinum*): its distribution and animal health implications. *British Veterinary Journal* 146, 316-326.
- Jarrett W.F., McNeil P.E., Grimshaw W.T., Selman I.E., McIntyre W.I. (1978). High incidence area of cattle cancer with a possible interaction between an environmental carcinogen and a papilloma virus. *Nature* 274, 215-217.
- Karimuribo E.D., Swai E.S., Kyakaisho P.K. (2008). Investigation of a syndrome characterized by passage of red urine in smallholder dairy cattle in East Usambara Mountains, Tanzania. *Journal of the South African Veterinary Association* 79, 89-94.
- Kelleway R.A., Geovjian L. (1978). Acute bracken fern poisoning in a 14-month-old horse. *Veterinary Medicine, Small Animal Clinician* 73, 295-296.
- Marrero E., Bulnes C., Sánchez L.M., Palenzuela I., Stuart R., Jacobs R., Romero J. (2001). *Pteridium aquilinum* (bracken fern) toxicity in cattle in the humid Chaco of Tarija, Bolivia. *Veterinary and Human Toxicology* 43, 156-158.
- Naftalin J.M., Cushnie G.H. (1951). Pathology of bracken poisoning. *The Veterinary Record* 18, 332.
- Nicholls F. (2001). Ecological values of bracken fern. *Land for Wildlife News* 4, 11.
- Osweiler G.D. (1996). Plant-related toxicoses. In: *Toxicology*. Williams & Wilkins, Media, P.A., p. 361-407.
- Pardon B., Steukers L., Dierick J., Ducatelle R., Saey V., Maes S., Vercauteren G., De Clercq K., Callens J., De Bleecker K., Deprez P. (2010). Haemorrhagic diathesis in neonatal calves: An emerging syndrome in Europe. *Transboundary and Emerging Diseases* 57, 135-146.
- Pardon B., Stuyven E., Stuyvaert S., Hostens M., Dewulf J., Goddeeris B.M., Cox E., Deprez P. (2011). Sera from dams of calves with bovine neonatal pancytopenia contain alloimmune antibodies directed against calf leukocytes. *Veterinary Immunology and Immunopathology* 141, 293-300.
- Pinto C., Januário T., Geraldés M., Machado J., Lauren D.R., Smith B.L., Robinson R.C. (2004). Bovine enzootic haematuria on São Miguel Island – Azores. In: Acamovic T., Stewart C.S., Pennycott T.W. (editors). *Poisonous Plants and Related Toxins*. CAB International, Wallingford, p. 564-574.
- Plumlee K.H. (2004). Plants. In: *Clinical Veterinary Toxicology*. Mosby, St. Louis, p. 337-442.
- Potter D.M., Baird M.S. (2000). Carcinogenic effects of ptaquiloside in bracken fern and related compounds. *British Journal of Cancer* 83, 914-920.
- Povey A.C., Potter D., O'Connor P.J. (1996). ³²P-post-labelling analysis of DNA adducts formed in the upper gastrointestinal tissue of mice fed bracken extract or bracken spores. *British Journal of Cancer* 74, 1342-1348.
- Prakash A.S., Pereira T.N., Smith B.L., Shaw G., Seawright A.A. (1996). Mechanism of bracken fern carcinogenesis: Evidence for H-ras activation via initial adenine alkylation by ptaquiloside. *Natural Toxins* 4, 221-227.
- Radostitis O.M., Gay C.C., Hinchcliff K.W., Constable P.D. (2007). Osteomyelotoxic ptaquiloside poisoning (poisoning by bracken (*Pteridium* spp.) and mulga or rock fern (*Cheilanthes Sieberi*)). In: *Veterinary Medicine: A textbook of the Diseases of Cattle, Horses, Sheep, Pigs, and Goats*. 10th Ed., WB Saunders, Philadelphia, p. 1875-1876.
- Rasmussen L.H., Lauren D.R., Smith B.L., Hansen H.C.B. (2008). Variation in ptaquiloside content in bracken (*Pteridium esculentum* (Forst. f) Cockayne) in New Zealand. *New Zealand Veterinary Journal* 56, 304-309.
- Ridpath J.F., Neill J.D., Vilcek S., Dubovi E.J., Carman S. (2006). Multiple outbreaks of severe acute BVDV in North America occurring between 1993 and 1995 linked to the same BVDV2 strain. *Veterinary Microbiology* 114, 196-204.
- Roperto S., Borzacchiello G., Brun R., Leonardi L., Maiolino P., Martano M., Paciello O., Papparella S., Restucci B., Russo V., Salvatore G., Urraro C., Roperto F. (2010). A review of bovine urothelial tumours and tumour-like lesions of the urinary bladder. *Journal of Comparative Pathology* 142, 95-108.
- Seifert H.S.H. (1996). Plant Poisoning. In: *Tropical Animal Health*. 2nd Ed., Kluwer Academic Publisher, Dordrecht, p. 441-496.
- Simán S.E., Povey A.C., Ward T.H., Margison G.P., Sheffield E. (2000). Fern spore extracts can damage DNA. *British Journal of Cancer* 83, 69-73.
- Smith B.L., Embling P.P., Agnew M.P., Lauren D.R., Holland P.T. (1988). Carcinogenicity of bracken fern (*Pteridium esculentum*) in New Zealand. *New Zealand Veterinary Journal* 36, 56-58.
- Smith B.L., Seawright A.A. (1995). Bracken fern (*Pteridium* spp.) carcinogenicity and human health – a brief review. *Natural toxins* 3, 1-5.
- Stewart G.B., Pullin A.S., Tyler C. (2007). The effectiveness of asulam for bracken (*Pteridium aquilinum*) control in the United Kingdom: A meta-analysis. *Environmental Management* 40, 747-760.
- Stewart G., Cox E., Le Duc M., Pakeman R., Pullin A., Marrs R. (2008). Control of *Pteridium aquilinum*: Meta-analysis of a multi-site study in the UK. *Annals of Botany* 101, 957-970.
- Thiry E., Saegerman C., Guyot H., Kirten P., Losson B., Rollin F., Bodmer M., Czaplicki G., Toussaint J.F., De Clercq K., Dochy J.M., Dufey J., Gillemann J.L., Messemann K. (2006). Bluetongue in northern Europe. *The Veterinary Record* 159, 327.
- UPL – United Phosphorus Limited (2008). www.upleurope.com/Product-label%20pdf/Asulox.pdf
- Vandenbroucke V., Van Pelt H., De Backer P., Croubels S. (2010). Animal poisonings in Belgium: a review of the past decade. *Vlaams Diergeneeskundig Tijdschrift* 79, 259-268.
- van der Hoeven J.C., Lagerweij W.J., Posthumus M.A., van Veldhuizen A., Holterman H.A. (1983). Aquilide A, a new mutagenic compound isolated from bracken fern (*Pteridium aquilinum* (L.) Kuhn). *Carcinogenesis* 4, 1587-1590.
- Van Genderen H., Schoonhoven L.M., Fuchs A. (1996). Adelaarsvarenfamilie – *Hypolepidaceae*. In: *Chemisch-Ecologische Flora van Nederland en België*. Stichting

- Uitgeverij van de Koninklijke Nederlandse Natuurhistorische Vereniging, Utrecht, p. 62-66.
- Vetter J. (2009). A biological hazard of our age: Bracken fern [*Pteridium aquilinum* (L.) Kuhn] – a review. *Acta Veterinaria Hungarica* 57, 183-196.
- Villalobos-Salazar J., Meneses A., Rojas J.L., Mora J., Porras R.E., Herrero M.V. (1989). Bracken derived carcinogens as affecting animal and human health in Costa Rica. In: Taylor J.A. (editor). *Bracken Toxicity and Carcinogenicity as Related to Animal and Human Health*. UCW Aberystwyth, p. 40-51.
- Wilson D., Donaldson L.J., Sepai O. (1998). Should we be frightened of bracken? A review of the evidence. *Journal of Epidemiology and Community Health* 52, 812-817.
- Xu L.R. (1992). Bracken poisoning and enzootic haematuria in cattle in China. *Research in Veterinary Science* 53, 116-121.
- Yamada K., Ojika M., Kigoshi H. (2007). Ptaquiloside, the major toxin of bracken, and related terpene glycosides: chemistry, biology and ecology. *Natural Product Reports* 24, 798-813.