

Large Hip Impingement Area and Subspine Hip Impingement in Patients With Absolute Femoral Retroversion or Decreased Combined Version

Adam Boschung,^{*†} MD, Tiziano Antioco,^{*} MD, Eduardo N. Novais,[‡] MD, Young-jo Kim,[‡] MD, Ata Kiapour,[‡] PhD, Moritz Tannast,[†] MD, Simon D. Steppacher,[§] MD, and Till D. Lerch,^{*‡||} MD, PhD

Background: It remains unclear if femoral retroversion is a contraindication for hip arthroscopy in patients with femoroacetabular impingement (FAI).

Purpose: To compare the area and location of hip impingement at maximal flexion and during the FADIR test (flexion, adduction, internal rotation) in FAI hips with femoral retroversion, hips with decreased combined version, and asymptomatic controls.

Study Design: Cross-sectional study; Level of evidence, 3.

Methods: Twenty-four symptomatic patients (37 hips) with anterior FAI were evaluated. All patients had femoral version (FV) $<5^\circ$ according to the Murphy method. Two subgroups were analyzed: 13 hips with absolute femoral retroversion (FV $<0^\circ$) and 29 hips with decreased combined version (McKibbin index $<20^\circ$). All patients were symptomatic and had anterior groin pain and a positive anterior impingement test; all had undergone pelvic computed tomography (CT) scans to measure FV. The asymptomatic control group consisted of 26 hips. Dynamic impingement simulation of maximal flexion and FADIR test at 90° of flexion was performed with patient-specific CT-based 3-dimensional models. Extra- or intra-articular hip impingement area and location were compared between the subgroups and with control hips using nonparametric tests.

Results: Impingement area was significantly larger for hips with decreased combined version ($<20^\circ$) versus combined version ($\geq 20^\circ$) (mean \pm SD; 171 ± 140 vs 78 ± 55 mm²; $P = .012$) and was significantly larger for hips with FV $<0^\circ$ (absolute femoral retroversion) vs FV $>0^\circ$ ($P = .025$). Hips with absolute femoral retroversion had a significantly higher frequency of extra-articular subspine impingement versus controls (92% vs 0%; $P < .001$), compared to 84% of patients with decreased combined version. Intra-articular femoral impingement location was most often (95%) anterosuperior and anterior (2-3 o'clock). Anteroinferior femoral impingement location was significantly different at maximal flexion (anteroinferior [4-5 o'clock]) versus the FADIR test (anterosuperior and anterior [2-3 o'clock]) ($P < .001$).

Conclusion: Patients with absolute femoral retroversion (FV $<0^\circ$) had a larger hip impingement area, and most exhibited extra-articular subspine impingement. Preoperative FV assessment with advanced imaging (CT/magnetic resonance imaging) could help to identify these patients (without 3-dimensional modeling). Femoral impingement was located anteroinferiorly at maximal flexion and anterosuperiorly and anteriorly during the FADIR test.

Keywords: hip; femoroacetabular impingement; femoral retroversion; hip arthroscopy; femoral version; hip preservation surgery

Patients with femoral retroversion present with decreased internal rotation (IR) and with anterior hip pain attributed to femoroacetabular impingement (FAI).^{8,19} Femoral retroversion can lead to extra-articular contact between the proximal femur and the anterior inferior iliac spine (AIIS) in patients undergoing total hip arthroplasty (THA).⁴⁴ Previous studies have noted that a cam-type deformity

typically reduces IR of the hip, usually assessed at 90° of flexion.^{12,51} Femoral retroversion also decreases IR and thus theoretically can outweigh the effect of a cam deformity for IR.^{8,19,53} Before the description of FAI, Tönnis and Heinecke⁵³ investigated femoral version (FV) and acetabular version and its variance and cited normal FV and acetabular version between 10° and 25° . Femoral retroversion was investigated by them almost 30 years ago, and it was called “diminished femoral antetorsion syndrome,”⁵⁴ when they observed that patients with hip pain and early signs of osteoarthritis had femoral retroversion and exhibited

The Orthopaedic Journal of Sports Medicine, 11(2), 23259671221148502

DOI: 10.1177/23259671221148502

© The Author(s) 2023

This open-access article is published and distributed under the Creative Commons Attribution - NonCommercial - No Derivatives License (<https://creativecommons.org/licenses/by-nc-nd/4.0/>), which permits the noncommercial use, distribution, and reproduction of the article in any medium, provided the original author and source are credited. You may not alter, transform, or build upon this article without the permission of the Author(s). For article reuse guidelines, please visit SAGE's website at <http://www.sagepub.com/journals-permissions>.

decreased IR of the hip joint.^{53,54} By then, treatment with derotation osteotomy to correct femoral retroversion (proximal femoral osteotomy) was performed in adult patients⁵⁴; however, there was no detailed follow-up. More recently, good clinical results after proximal femoral derotation osteotomy have been reported for adult patients.⁶ In adolescent patients with femoral retroversion, successful treatment with rotational osteotomy was also found.^{16,54}

Surgical treatment of patients with FAI was initially performed with open hip preservation surgery or with hip arthroscopy for cam resection and/or acetabular rim trimming and later labral treatment, without detailed consideration of FV or femoral retroversion.^{12,33} In 2015, the effect of FV was investigated for patients who underwent hip arthroscopy,¹⁰ but only a few studies^{13,19} have investigated the effect of femoral retroversion thereafter. However, it has been shown that increased and decreased FV can significantly impair patient-related outcomes after hip arthroscopy for patients with FAI.¹⁰ Decreased FV has been associated with revision surgery after hip arthroscopy at 2-year follow-up,³⁶ and femoral retroversion (defined as FV <5°) has been associated with anterosuperior and subspine hip impingement²⁴ in patients with FAI. Subspine impingement was reported when the AIIS caused bony impingement contact with the proximal femur.²⁴

Abnormalities in FV are becoming increasingly recognized as important factors regarding treatment of patients with FAI.^{26,43} To date, treatment of patients with FAI with femoral retroversion remains controversial because there is conflicting evidence on whether FV affects clinical outcomes after hip arthroscopy for FAI.¹⁷ Excessive femoral retroversion was considered a relative contraindication to FAI surgery by others⁵³ because of poor outcomes after hip arthroscopy for FAI.¹⁰ In a recent systematic review evaluating whether FV influences the outcome of hip arthroscopy, the authors reported that patients with normal FV and patients with femoral retroversion (defined as FV <5°) exhibited similar failure rates but significantly different scores on the Non-arthritic Hip Score and the Hip Outcome Score–Sport Specific Subscale.⁵⁵

Decreased FV was associated with anterosuperior intra- and extra-articular subspine hip impingement in a recent study analyzing impingement conflict using 3-dimensional computed tomography (3D-CT).²⁴ But impingement conflict in maximal flexion without rotation was not analyzed. So far, the location of extra- or intra-articular hip impingement in flexion in patients with absolute femoral retroversion is unknown. In addition, it is unclear if these patients

could be identified without time-consuming 3D modeling and 3D-CT scanning.

The purpose of the current study was to compare the area and location of hip impingement in maximal flexion and during the FADIR test (flexion, adduction, internal rotation) in patients with FAI with absolute femoral retroversion versus those with decreased combined version. The hypothesis was that patients with absolute femoral retroversion will have a larger impingement area.

METHODS

The protocol for this study received institutional review board approval, and all participants provided informed consent. We conducted a retrospective analysis of 24 symptomatic patients (37 hips) with anterior FAI who were seen at our outpatient clinic between January 2014 and December 2016. The patients were part of a previous study.²⁴ Inclusion criteria were FV <5° on CT scan (termed *decreased FV*) and the absence of hip dysplasia. Exclusion criteria were a lateral center-edge angle⁴⁹ <22° or an acetabular index⁵³ >14° and Tönnis grade ≥1 osteoarthritis.⁵² All patients had undergone standardized anteroposterior and lateral radiographs as well as CT scans including the entire pelvis and the knee joint (distal femoral condyles)^{34,35} according to a previously described protocol.^{24,42} At the time of imaging, all patients were symptomatic and had anterior groin pain, a positive FADIR test result (performed at 90° of flexion and forced IR), and decreased IR during clinical examination. Some patients also reported hip pain at maximal flexion.

Considerable differences for FV measurement exist.⁴² In the current study, we measured FV on standardized pelvic CT scans using the method of Murphy et al.³⁰ This method has small interobserver variability.^{26,42} The hips with decreased FV were categorized into those with absolute femoral retroversion (FV <0°) and those with decreased combined version (McKibbin index²² <20°). Definitions of the terms used in this study are listed in Table 1.

Of the 37 hips with decreased FV, 16 (43%) had cam deformity, 7 (19%) had pincer-type deformity, 6 (16%) had combined cam and pincer deformity (mixed-type FAI), and 8 (22%) had neither cam- nor pincer-type morphology. There were 13 hips with absolute femoral retroversion (Figure 1) and 29 hips with decreased combined version (Table 2); the 2 subgroups could overlap, and some of the hips were part of both groups. Most of the 24 study patients were male (62%), with a mean ± SD age of 28 ± 9 years and FV of 1° ± 4°.

||Address correspondence to Till D. Lerch, MD, PhD, Department of Diagnostic, Interventional and Pediatric Radiology, Inselspital, Freiburgstrasse, 3010 Bern, Switzerland (email: till.lerch@insel.ch; till.lerch@childrens.harvard.edu).

*Department of Diagnostic, Interventional and Pediatric Radiology, Inselspital, University Hospital Bern, University of Bern, Bern, Switzerland.

†Department of Orthopedic Surgery and Traumatology, Fribourg Cantonal Hospital, University of Fribourg, Fribourg, Switzerland.

‡Department of Pediatric Orthopedic Surgery, Boston Children's Hospital, Harvard Medical School, Boston, Massachusetts, USA.

§Department of Orthopedic Surgery, Inselspital, University Hospital Bern, University of Bern, Switzerland.

Final revision submitted September 21, 2022; accepted September 26, 2022.

One or more of the authors has declared the following potential conflict of interest or source of funding: Funding for this study was provided from the Swiss National Science Foundation (grant P2BEP3_195241 to T.D.L.). AOSSM checks author disclosures against the Open Payments Database (OPD). AOSSM has not conducted an independent investigation on the OPD and disclaims any liability or responsibility relating thereto.

Ethical approval for this study was obtained from the regional ethics commission for the Canton of Bern (No. 2018-00078).

TABLE 1
Definitions of Terms Used^a

Term	Definition
Femoral version	Measured on standardized pelvic computed tomography scan per the Murphy method ³⁰
Combined version	Sum of the femoral and acetabular version, also called the McKibbin index ²²
Decreased femoral version	Femoral version <5°
Absolute femoral retroversion	Femoral version <0°
Decreased combined version	Combined version <20°
FAI subtype	
Cam	Alpha angle ³¹ >50° with normal acetabular coverage (LCEA 23°-33°) ⁴⁹
Mixed	Alpha angle ³¹ >50° and LCEA >34°
Pincer	
Overcoverage	LCEA ⁴⁹ 34°-39° with alpha angle <50°
Severe overcoverage	LCEA ⁵³ >39° and/or protrusio acetabuli (defined as femoral head touching or crossing the ilioischial line) and/or total femoral coverage ⁴⁹ >93%
Hip dysplasia ^b	LCEA ⁴⁹ <22°

^aFAI, femoroacetabular impingement; LCEA, lateral center-edge angle.

^bPatients with hip dysplasia were excluded from the study.

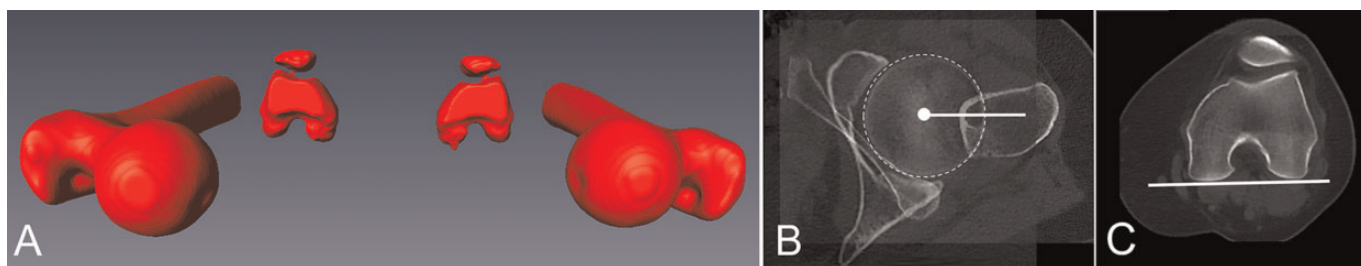


Figure 1. (A) A 3-dimensional model of the bilateral femur and (B, C) axial computed tomography images of the hip and posterior femoral condyle in a 26-year-old man with absolute femoral retroversion. (B) The femoral head center (white dot) was connected with the center of the femoral shaft on the level of the lesser trochanter to define the proximal landmarks. (C) The posterior condyles were connected with a line for the distal landmarks.

TABLE 2
Demographic Characteristics and Imaging Information of the Study Patients^a

Parameter	Decreased Femoral Version (N = 37 Hips) ^b	Absolute Femoral Retroversion (n = 13 Hips)	Decreased Combined Version (n = 29 Hips)
Age, y	28 ± 9 (17-54)	27 ± 10 (19-54)	27 ± 8 (17-54)
Sex: male	62	54	62
Side: right	57	54	59
Height, cm	175 ± 7 (162-187)	176 ± 7 (162-187)	174 ± 8 (162-187)
Weight, kg	76 ± 11 (59-100)	80 ± 6 (73-89)	80 ± 12 (59-100)
Body mass index, kg/m ²	24 ± 3 (19-30)	26 ± 2 (23-29)	26 ± 4 (21-30)
Angle, deg			
Lateral center edge	31 ± 7 (19-48)	30 ± 6 (20-37)	33 ± 8 (20-47)
Neck-shaft	129 ± 6 (111-138)	128 ± 6 (120-137)	129 ± 7 (111-138)
Alpha angle	56 ± 7 (41-68)	58 ± 8 (48-67)	57 ± 7 (44-68)
Version, deg			
Femoral	1 ± 4 (-8 to 5)	-4 ± 2 (-8 to -1)	0 ± 4 (-8 to 5)
Acetabular	14 ± 5 (6-25)	16 ± 6 (6-25)	13 ± 5 (6-25)
Combined	16 ± 6 (3-27)	12 ± 6 (3-25)	14 ± 5 (3-20)

^aData are reported as mean ± SD (range) or percentage.

^bPatients: N = 24.

TABLE 3
Details of the Collision Detection Software Based on 3-Dimensional Models of the Hip Joint

Feature	Description/Definition
Anterior pelvic plane was used as acetabular reference coordinate system	Defined by landmarks of both anterosuperior iliac spines and the pubic tubercles ⁵⁰
Femoral reference coordinate system	Defined by landmarks of the femoral head center, the knee center, and both femoral condyles ³⁰
Automatic rim detection ³⁴	For automatic detection of the osseous acetabular rim
Best-fitting sphere algorithm	For identification of the femoral head center
Equidistant method	For virtual impingement-free hip motion analysis ³⁵
Distribution of the impingement zones	Calculated with a previously described clockface system ^{48,50}
Clockface coordinate system	<ul style="list-style-type: none"> • 3 o'clock was defined anteriorly for right and left hips • 6 o'clock represented the acetabular notch^{48,50} • 1 and 2 o'clock indicated anterosuperior • 4 and 5 o'clock indicated anteroinferior
Intra-articular impingement	Intra-articular locations included the acetabular rim on the acetabular side and the femoral head and neck on the femoral side

In addition to the study groups, we included a control group of 26 unaffected hips from the contralateral side of 146 patients who had undergone THA. The mean age of the control group was 54 ± 11 years. Exclusion criteria for the control group were as follows: THA or total knee arthroplasty ($n = 10$), pain ($n = 4$), previous hip surgery ($n = 3$), Tönnis grade ≥ 1 osteoarthritis⁵² ($n = 40$), lateral center-edge angle $< 25^\circ$ ($n = 24$), pistol grip deformity⁴⁸ ($n = 13$), coxa profunda ($n = 13$), coxa vara or valga ($n = 1$), acetabular retroversion^{40,51} ($n = 4$), protrusio acetabuli ($n = 2$), alpha angle $> 50^\circ$ ($n = 4$), and femoral retroversion ($n = 2$).

Imaging

Acetabular version was calculated on axial CT scans on the level of the femoral head center¹⁴ (3-o'clock version). Morphology of the AIIIS was evaluated using 3D models of the pelvis according to a published classification system¹⁵ by 2 independent observers with 5 years of experience in musculoskeletal radiology. To build patient-specific 3D bone models of the pelvis and the femur, we performed bone segmentation using the Amira Visualization Toolkit (Viseage Imaging Inc). The acetabular reference coordinate system was the anterior pelvic plane, defined by both anterosuperior iliac spines and the pubic tubercles.^{24,50} The femoral reference coordinate system was defined by the center of the femoral head, the knee center, and both femoral condyles.³⁰ Using this 3D model generated from the CT scans, we compared the patient-specific impingement-free range of motion (ROM) and the individual acetabular and femoral impingement location of the patients.

Using personalized CT-based 3D models and software for collision detection (HipMotion; University of Bern), we evaluated all hips with the equidistant method. The software that we used has the features listed in Table 3. The equidistant method was designed for virtual FAI analysis.³⁵ Based on a cadaveric investigation including cartilage, labrum, and joint capsule, an impingement collision can be detected with a mean accuracy of $2.6^\circ \pm 2.5^\circ$.³⁵ Using this computerized analysis, we calculated the ROM for all

Impingement location for FADIR test of a patient with Absolute Femoral Retroversion $FV < 0^\circ$

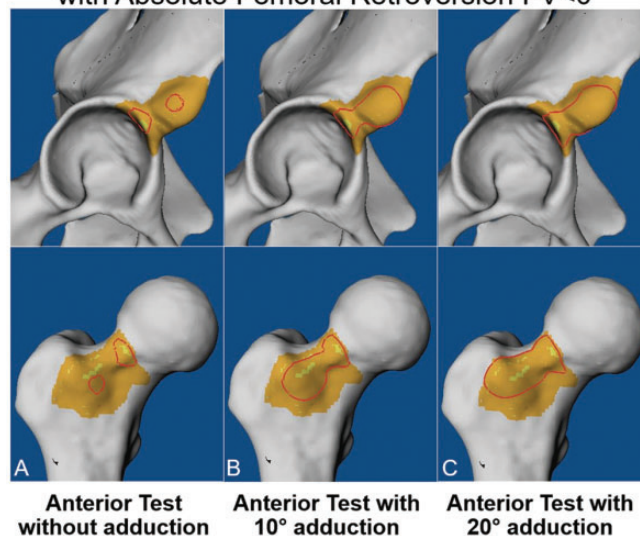


Figure 2. Determining the location of acetabular (top row) and femoral (bottom row) hip impingement during the FADIR test at 90° of flexion and 30° of internal rotation combined with (A) 0° , (B) 10° , and (C) 20° of adduction on computed tomography scans from a 23-year-old man with absolute femoral retroversion. The impingement area is outlined in red. FADIR, flexion, adduction, internal rotation.

3 groups: flexion, extension, IR, and external rotation (at 0° and 90° of flexion). In a validation study of this software, intra- and interobserver measurements for the aforementioned ROM parameters were excellent ($ICC > 0.9$) for the most important motions (maximal flexion and IR at 90° of flexion).²⁹

Furthermore, we evaluated 3 motion patterns that corresponded to the FADIR test for anterior impingement.^{7,38,39} The impingement location was studied during the FADIR test at 90° of flexion; 30° of IR; and 0° , 10° , and 20° of adduction (Figure 2).

The femoral location of impingement was compared between the FADIR test (90° of flexion and 30° of IR) and maximal flexion (no hip rotation). Impingement area was calculated using specific software (HipMotion). Evaluation of impingement area was performed via standardized views of the proximal femur and the acetabulum by 2 observers (T.D.L. and T.A.) using a brush tool to mark the area with bone-to-bone contact. Acetabular and femoral impingement area were calculated separately.

Statistical Analysis

Statistical analysis was performed using WinSTAT software (R. Fitch Software). The data were assessed for normal distribution with the Kolmogorov-Smirnov test. Because not all the parameters were normally distributed, we used nonparametric tests for comparison. To compare demographic and radiographic data, ROM, or location of impingement, we used the Mann-Whitney *U* test. To compare binominal demographic data and the prevalence of impingement, we used the Fisher exact test to compare the subgroups. Bonferroni correction was applied owing to multiple comparisons (4 groups, correction: $0.05/4 = 0.0125$). Because of the applied correction, $P < .0125$ was considered the threshold for significance to avoid false-positive results. Impingement area, location, and frequency were compared between the subgroups and with control group.

RESULTS

Almost half (49%) of the 37 hips with decreased FV underwent surgical treatment at the time of data collection. Surgical treatment included hip arthroscopy with femoral cam resection in 3 hips (8%), surgical hip dislocation with combined femoral cam resection and acetabular rim trimming in 5 hips (14%), and derotation proximal femoral osteotomies to increase FV in 10 hips (27%). Thirty percent of patients with decreased FV had type 1 AIIS morphology (11/37 hips, 30%), 70% (26/37 hips) had type 2, and none had type 3.

Impingement area was significantly larger in the hips with decreased combined version ($<20^\circ$) versus the hips with combined version ($\geq 20^\circ$) (171 ± 140 vs 78 ± 55 mm²; $P = .012$). Impingement area was slightly larger in hips of patients with FV $<0^\circ$ (absolute femoral retroversion) as compared with patients with FV $>0^\circ$ (189 ± 188 vs 132 ± 93 mm²; $P = .025$). During the FADIR test, the impingement area was slightly larger for the hips of patients with pincer-type FAI (382 ± 150 mm²) or mixed-type FAI (411 ± 129 mm²) as compared with cam-type FAI (304 ± 284 mm²), and the impingement area increased during the FADIR test from 0° of adduction (135 ± 133 mm²) to 10° (232 ± 180 mm²) and 20° (340 ± 218 mm²).

During the FADIR test, hips with decreased FV had a significantly higher frequency of extra-articular subspine impingement as compared with control hips at 20° of adduction (84% vs 0%; $P < .001$). Hips with absolute femoral retroversion had a significantly higher frequency of extra-articular subspine impingement as compared with controls

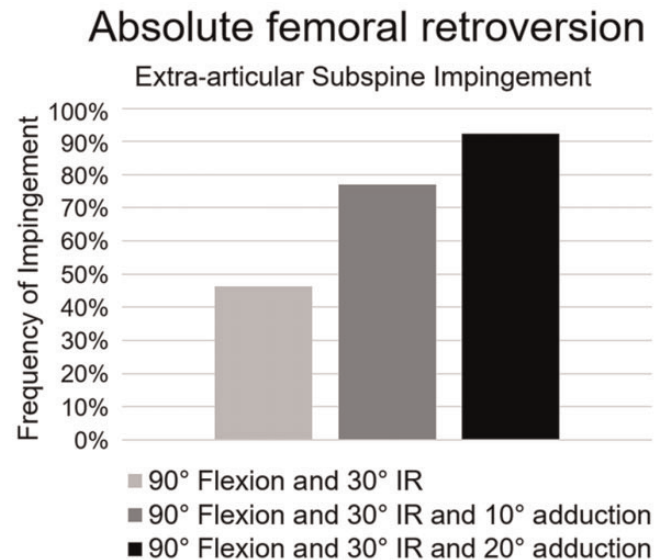


Figure 3. Frequency of extra-articular subspine hip impingement for patients with absolute femoral retroversion during the FADIR test: 90° of flexion; 30° of internal rotation (IR); and 0°, 10°, or 20° of adduction. FADIR, flexion, adduction, internal rotation.

at 20° of adduction (92% vs 0%; $P < .001$) (Figure 3), while 84% of patients with decreased combined version had extra-articular subspine impingement (Table 4).

Anteroinferior femoral impingement location was significantly different in maximal flexion (anteroinferior [4-5 o'clock]) versus the FADIR test (anterosuperior and anterior [2-3 o'clock]; $P < .001$) (Figure 4).

Intra-articular femoral impingement was most often (95%) anterosuperior and anterior (2-3 o'clock), and it extended to anterolateral, including the proximal femoral tubercle (tuberculum tertius) in one-third of hips (32%) during the FADIR test. Acetabular intra-articular impingement was located anterosuperior (1-2 o'clock) for maximal flexion and the FADIR test.

DISCUSSION

Most important, a significantly larger impingement area was found for hips of patients with combined version $<20^\circ$ versus $\geq 20^\circ$ (171 ± 140 vs 78 ± 55 mm²; $P = .012$). Analyzing the frequency of extra-articular subspine impingement, a significantly higher frequency was identified for hips with absolute femoral retroversion as compared with control hips (92% vs 0%; $P < .001$).

FAI is a known cause for hip pain and a precursor to hip osteoarthritis in young patients.¹² Hip arthroscopy is increasingly being used for treatment of FAI; a tremendous increase in hip arthroscopy to treat FAI (>4-fold) was noted between 2005 and 2013.²⁸ While use of hip arthroscopy for treatment of FAI continues to rise, there is no international consensus for the indications for this procedure. Excessive femoral retroversion is regarded as a contraindication for

TABLE 4

Prevalence of Intra- and Extra-articular Subspine Impingement During the FADIR Test at 0°, 10°, or 20° of Adduction^a

FADIR Test	Decreased Femoral Version (N = 37 hips)		Absolute Femoral Retroversion (n = 13 Hips)	
	Intra-articular	Extra-articular	Intra-articular	Extra-articular
Adduction				
0°	97	32	100	46
10°	100	68	100	77
20°	100	84	100	92

^aData are presented as percentages. FADIR, flexion, adduction, internal rotation.

Anterior Femoral Impingement Location

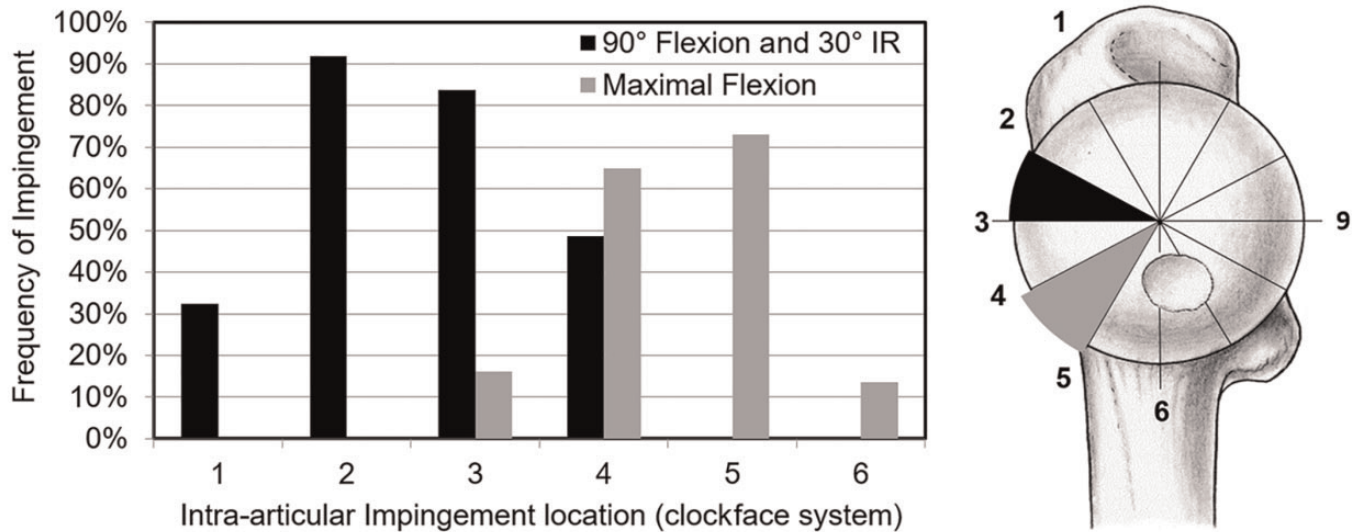


Figure 4. A clockface system was used for intra-articular impingement location, where 1 to 2 o'clock represents anterosuperior, 4 to 5 o'clock represents anteroinferior, and 3 o'clock anterior (for left and right hips). The anterior femoral impingement location was significantly different at maximal flexion (anteroinferior; 4-5 o'clock) vs during the FADIR test (anterosuperior and anterior; 2-3 o'clock) ($P < .001$). FADIR, flexion, adduction, internal rotation.

hip arthroscopy for some hip surgeons,¹⁰ while others have reported good patient-reported outcomes after hip arthroscopy for patients with femoral retroversion¹⁷ and have found no difference in outcomes as compared with patients with normal FV.¹³

Direct comparison studies are challenging, and the biomechanical effects of hip impingement for these hips are not yet fully understood. In the current study, patients with absolute femoral retroversion had a significantly higher rate (92%) of anterior extra-articular subspine impingement as compared with control hips (0%; $P < .001$). In addition, we found that patients with decreased combined version ($<20^\circ$) exhibited a significantly larger impingement area as compared with patients with combined version ($\geq 20^\circ$; $P = .012$). To our knowledge, no other study has investigated the biomechanical effects of decreased combined version.

The literature remains sparse regarding patients with FAI with femoral retroversion, and different definitions of

femoral retroversion exist.⁵⁵ Some authors have defined it using $FV < 5^\circ$,^{10,11} $FV < 10^\circ$,²⁶ or $FV < -2^\circ$.¹⁷ Different measurement methods for FV have been used, and FV has been measured on oblique axial CT or magnetic resonance imaging (MRI).^{10,17} These inconsistencies make it difficult to compare our results with previous studies. Detailed assessment of hip impingement location in maximal flexion for hips with absolute femoral retroversion ($FV < 0^\circ$) is unclear. Therefore, we investigated impingement in maximal flexion in 2 subgroups, with 1 subgroup consisting of hips with absolute femoral retroversion. For hips with anterior FAI attributed to cam- or pincer-type morphologies, similar acetabular and femoral osseous impingement locations have been reported in the anterosuperior region.^{20,50} In a recent study assessing location of labral tears in hips with abnormal FV, the tears were located anteriorly in hips with decreased FV¹⁷; those findings correspond with the results of the current study. For patients with THA and femoral retroversion, the location of impingement has been

described as between the anterior greater trochanter and the AIIS.⁴⁴ For patients with type 3 AIIS, impingement contact between the AIIS and the distal area along the anterior inferior femoral neck has been described, whereas for patients with type 2 AIIS, the impingement contact was localized between the femoral neck and the AIIS.¹⁵

Regarding the clinical assessment of ROM in patients with FAI, the method that we used in the current study is a more accurate and anatomically based quantification of ROM because clinical⁴⁶ assessment can be inaccurate.⁹ In addition, this method enables the analysis of a specific motion pattern (FADIR test) instead of isolated amplitudes of ROM (eg, maximal flexion without rotation) and the detection of the corresponding patient-specific location of acetabular and femoral impingement. We found no other study with which to compare the results of the impingement area.

This study may have some clinical implications to better understand hip impingement. The location of femoral impingement differed between maximal flexion (anteroinferior [4-5 o'clock]) and the FADIR test (anterosuperior and anterior [2-3 o'clock]). This could be important for orthopaedic surgeons performing hip arthroscopy or open hip preservation surgery. For patients with hip pain in flexion, bone resection (cam resection or acetabular rim trimming) should theoretically be adapted. Based on preoperative measurement of FV, the risk for extra-articular subspine hip impingement could be estimated if a patient with absolute femoral retroversion is identified. Preoperative assessment of decreased combined version and absolute femoral retroversion could help to identify patients with subspine extra-articular hip impingement, similar to preoperative assessment of out-toeing of the foot. Subspine extra-articular hip impingement could be diagnosed with a simple measurement of FV, eliminating the need for time-consuming 3D bone segmentation and impingement simulation for these patients. Furthermore, the study results have implications for daily activities and sports: deep flexion during squats should be avoided in patients with femoral retroversion.²¹ In addition, femoral retroversion was previously identified for patients with slipped capital femoral epiphysis.^{32,41} Subspine impingement could be a problem for those patients as well, but further studies are needed to investigate this.

Quantification of FV depends on the measurement method. Differences in FV measurements of up to 20° between methods have been described.⁴² For example, an FV of -9° measured with the Reikerås method³⁷ corresponds to an FV of 0° measured with the Murphy method used in this study (assuming a difference of 9° according to a recent study⁴²). Therefore, we propose to use the definition of -9° or -10° to avoid false-positive results for severe femoral retroversion when using the Reikerås method. Interpretation of our results is based on the Murphy method, and the applied method should be considered when reporting FV.

Limitations

This study has limitations. First, the software for collision detection calculates the osseous ROM without taking into

account soft tissue (labrum, muscles, or cartilage). This is unavoidable using pelvic CT scans for 3D modeling and could be integrated using MRI of the hip in the future^{5,47} or with CT arthrograms.^{2,18} Therefore, we believe that the clinical ROM should be even lower in these hips.² This means that a patient with absolute femoral retroversion could present clinically with 0° of IR in 90° of flexion. However, this is the case for published ROM results using other software for collision detection.²⁻⁴ This method has also been applied to hips with severe hip deformities, including hips with high FV,^{27,45} hips with slipped capital femoral epiphysis,²⁵ and hips with deformities caused by Legg-Calvé-Perthes disease.⁴⁸ The application of this method to various hip morphologies underlines the validity of the software for collision detection used in the current study.

A second limitation is that the study patients were evaluated for hip preservation surgery in a European university hospital with limited generalizability. There could be a selection bias of complex cases. Third, no detailed surgical outcome or clinical follow-up was reported, because this was not the aim of this study. However, all hips were symptomatic at the time of image acquisition. Of the patients with femoral retroversion, almost half of them (49%) underwent surgical treatment. The current analysis is intended to focus on computer-assisted simulation of ROM in patients with symptomatic anterior FAI and femoral retroversion. Based on this 3D collision detection, we changed our clinical practice and now perform CT or MRI to measure FV in all patients eligible for hip preservation surgery to detect femoral retroversion. Finally, we evaluated the pelvis in a fixed position, without evaluating the effect of pelvic tilt or pelvic incidence,²³ which can affect hip ROM¹ (eg, posterior pelvic tilting to avoid anterior FAI).

CONCLUSION

Patients with absolute femoral retroversion (FV <0°) had a large hip impingement area, and most exhibited extra-articular subspine impingement and anterolateral femoral impingement. Femoral impingement location differed significantly between maximal flexion (anteroinferior location) and the FADIR test (anterosuperior location). The study findings may have implications for hip preservation surgery, especially for the planning of hip arthroscopy and for patient-specific bone resection and potentially to improve outcomes. Preoperative assessment of FV with advanced imaging (CT or MRI) could help to identify these patients in the future without 3D modeling.

REFERENCES

1. Atkins PR, Fiorentino NM, Hartle JA, et al. In vivo pelvic and hip joint kinematics in patients with cam femoroacetabular impingement syndrome: a dual fluoroscopy study. *J Orthop Res.* 2020;38(4):823-833. doi:10.1002/jor.24509
2. Atkins PR, Hananouchi T, Anderson AE, Aoki SK. Inclusion of the acetabular labrum reduces simulated range of motion of the hip compared with bone contact models. *Arthrosc Sports Med Rehabil.* 2020; 2(6):e779-e787. doi:10.1016/j.asmr.2020.07.014

3. Bedi A, Dolan M, Hetsroni I, et al. Surgical treatment of femoroacetabular impingement improves hip kinematics: a computer-assisted model. *Am J Sports Med.* 2011;39(suppl):43S-49S. doi:10.1177/0363546511414635
4. Bouma H, Hogervorst T, Audenaert E, van Kampen P. Combining femoral and acetabular parameters in femoroacetabular impingement: the omega surface. *Med Biol Eng Comput.* 2015;53(11):1239-1246. doi:10.1007/s11517-015-1392-6
5. Breighner RE, Bogner EA, Lee SC, Koff MF, Potter HG. Evaluation of osseous morphology of the hip using zero echo time magnetic resonance imaging. *Am J Sports Med.* 2019;47(14):3460-3468. doi:10.1177/0363546519878170
6. Buly RL, Sosa BR, Poultsides LA, Caldwell E, Rozbruch SR. Femoral derotation osteotomy in adults for version abnormalities. *J Am Acad Orthop Surg.* 2018;26(19):e416-e425. doi:10.5435/JAAOS-D-17-00623
7. Casartelli NC, Brunner R, Maffiuletti NA, et al. The FADIR test accuracy for screening cam and pincer morphology in youth ice hockey players. *J Sci Med Sport.* Published online June 21, 2017. doi:10.1016/j.jsams.2017.06.011
8. Chadayammuri V, Garabekyan T, Bedi A, et al. Passive hip range of motion predicts femoral torsion and acetabular version. *J Bone Joint Surg Am.* 2016;98(2):127-134. doi:10.2106/JBJS.O.00334
9. Charbonnier C, Chagué S, Schmid J, Kolo FC, Bernardoni M, Christofilopoulos P. Analysis of hip range of motion in everyday life: a pilot study. *Hip Int.* 2015;25(1):82-90. doi:10.5301/hipint.5000192
10. Fabricant PD, Fields KG, Taylor SA, Magennis E, Bedi A, Kelly BT. The effect of femoral and acetabular version on clinical outcomes after arthroscopic femoroacetabular impingement surgery. *J Bone Joint Surg Am.* 2015;97(7):537-543. doi:10.2106/JBJS.N.00266
11. Ferro FP, Ho CP, Briggs KK, Philippon MJ. Patient-centered outcomes after hip arthroscopy for femoroacetabular impingement and labral tears are not different in patients with normal, high, or low femoral version. *Arthroscopy.* 2015;31(3):454-459. doi:10.1016/j.arthro.2014.10.008
12. Ganz R, Parvizi J, Beck M, Leunig M, Nötzli H, Siebenrock KA. Femoroacetabular impingement: a cause for osteoarthritis of the hip. *Clin Orthop Relat Res.* 2003;(417):112-120. doi:10.1097/01.blo.0000096804.78689.c2
13. Hartigan DE, Perets I, Walsh JP, Chaharbakhsi EO, Yuen LC, Domb BG. Clinical outcomes of hip arthroscopic surgery in patients with femoral retroversion: a matched study to patients with normal femoral anteversion. *Orthop J Sports Med.* 2017;5(10):2325967117732726. doi:10.1177/2325967117732726
14. Hetsroni I, Dela Torre K, Duke G, Lyman S, Kelly BT. Sex differences of hip morphology in young adults with hip pain and labral tears. *Arthroscopy.* 2013;29(1):54-63. doi:10.1016/j.arthro.2012.07.008
15. Hetsroni I, Poultsides L, Bedi A, Larson CM, Kelly BT. Anterior inferior iliac spine morphology correlates with hip range of motion: a classification system and dynamic model. *Clin Orthop Relat Res.* 2013;471(8):2497-2503. doi:10.1007/s11999-013-2847-4
16. Huber H, Haefeli M, Dierauer S, Ramseier LE. Treatment of reduced femoral anteversion by subtrochanteric rotational osteotomy. *Acta Orthop Belg.* 2009;75(4):490-496.
17. Jackson TJ, Lindner D, El-Bitar YF, Domb BG. Effect of femoral anteversion on clinical outcomes after hip arthroscopy. *Arthroscopy.* 2015;31(1):35-41. doi:10.1016/j.arthro.2014.07.009
18. Kapron AL, Aoki SK, Peters CL, Anderson AE. Subject-specific patterns of femur-labrum contact are complex and vary in asymptomatic hips and hips with femoroacetabular impingement. *Clin Orthop Relat Res.* 2014;472(12):3912-3922. doi:10.1007/s11999-014-3919-9
19. Kraeutler MJ, Chadayammuri V, Garabekyan T, Mei-Dan O. Femoral version abnormalities significantly outweigh effect of cam impingement on hip internal rotation. *J Bone Joint Surg Am.* 2018;100(3):205-210. doi:10.2106/JBJS.17.00376
20. Kubiak-Langer M, Tannast M, Murphy SB, Siebenrock KA, Langlotz F. Range of motion in anterior femoroacetabular impingement. *Clin Orthop Relat Res.* 2007;458:117-124. doi:10.1097/BLO.0b013e318031c595
21. Lerch TD, Antioco T, Boschung A, et al. Hip impingement location in maximal hip flexion in patients with femoroacetabular impingement with and without femoral retroversion. *Am J Sports Med.* 2022;50(11):2989-2997. doi:10.1177/03635465221110887
22. Lerch TD, Antioco T, Meier MK, et al. Combined abnormalities of femoral version and acetabular version and McKibbin Index in FAI patients evaluated for hip preservation surgery. *J Hip Preserv Surg.* 2022;9(2):67-77. doi:10.1093/jhps/hnac016
23. Lerch TD, Boschung A, Schmaranzer F, et al. Lower pelvic tilt, lower pelvic incidence, and increased external rotation of the iliac wing in patients with femoroacetabular impingement due to acetabular retroversion compared to hip dysplasia. *Bone Jt Open.* 2021;2(10):813-824. doi:10.1302/2633-1462.210.BJO-2021-0069.R1
24. Lerch TD, Boschung A, Todorski IAS, et al. Femoroacetabular impingement patients with decreased femoral version have different impingement locations and intra- and extraarticular anterior subspine FAI on 3D-CT-based impingement simulation: implications for hip arthroscopy. *Am J Sports Med.* Published online September 20, 2019. doi:10.1177/0363546519873666
25. Lerch TD, Kim YJ, M Kiapour A, et al. Limited hip flexion and internal rotation resulting from early hip impingement conflict on anterior metaphysis of patients with untreated severe SCFE using 3D modelling. *J Pediatr Orthop.* Published online September 13, 2022. doi:10.1097/BPO.0000000000002249
26. Lerch TD, Todorski IAS, Steppacher SD, et al. Prevalence of femoral and acetabular version abnormalities in patients with symptomatic hip disease: a controlled study of 538 hips. *Am J Sports Med.* Published online September 1, 2017. doi:10.1177/0363546517726983
27. Lerch TD, Zwingelstein S, Schmaranzer F, et al. Posterior extra-articular ischiofemoral impingement can be caused by the lesser and greater trochanter in patients with increased femoral version: dynamic 3D CT-based hip impingement simulation of a modified FABER test. *Orthop J Sports Med.* 2021;9(5):2325967121990629. doi:10.1177/2325967121990629
28. Maradit Kremers H, Schilz SR, Van Houten HK, et al. Trends in utilization and outcomes of hip arthroscopy in the United States between 2005 and 2013. *J Arthroplasty.* 2017;32(3):750-755. doi:10.1016/j.arth.2016.09.004
29. Montgomery AA, Graham A, Evans PH, Fahey T. Inter-rater agreement in the scoring of abstracts submitted to a primary care research conference. *BMC Health Serv Res.* 2002;2(1):8.
30. Murphy SB, Simon SR, Kijewski PK, Wilkinson RH, Griscom NT. Femoral anteversion. *J Bone Joint Surg Am.* 1987;69(8):1169-1176.
31. Nötzli HP, Wyss TF, Stoecklin CH, Schmid MR, Treiber K, Hodler J. The contour of the femoral head-neck junction as a predictor for the risk of anterior impingement. *J Bone Joint Surg Br.* 2002;84(4):556-560.
32. Novais EN, Millis MB. Slipped capital femoral epiphysis: prevalence, pathogenesis, and natural history. *Clin Orthop Relat Res.* 2012;470(12):3432-3438. doi:10.1007/s11999-012-2452-y
33. Peters CL, Erickson JA. Treatment of femoro-acetabular impingement with surgical dislocation and débridement in young adults. *J Bone Joint Surg Am.* 2006;88(8):1735-1741. doi:10.2106/JBJS.E.00514
34. Puls M, Ecker TM, Steppacher SD, Tannast M, Siebenrock KA, Kowal JH. Automated detection of the osseous acetabular rim using three-dimensional models of the pelvis. *Comput Biol Med.* 2011;41(5):285-291. doi:10.1016/j.combiomed.2011.03.004
35. Puls M, Ecker TM, Tannast M, Steppacher SD, Siebenrock KA, Kowal JH. The Equidistant Method—a novel hip joint simulation algorithm for detection of femoroacetabular impingement. *Comput Aided Surg.* 2010;15(4-6):75-82. doi:10.3109/10929088.2010.530076
36. Redmond JM, Gupta A, Dunne K, Humayun A, Yuen LC, Domb BG. What factors predict conversion to THA after arthroscopy? *Clin Orthop Relat Res.* Published online July 7, 2017. doi:10.1007/s11999-017-5437-z
37. Reikerås O, Bjerkreim I, Kolbenstvedt A. Anteversion of the acetabulum and femoral neck in normals and in patients with osteoarthritis of the hip. *Acta Orthop Scand.* 1983;54(1):18-23.

38. Reiman MP, Goode AP, Cook CE, Hölmich P, Thorborg K. Diagnostic accuracy of clinical tests for the diagnosis of hip femoroacetabular impingement/labral tear: a systematic review with meta-analysis. *Br J Sports Med*. 2015;49(12):811. doi:10.1136/bjsports-2014-094302
39. Reiman MP, Mather RC, Cook CE. Physical examination tests for hip dysfunction and injury. *Br J Sports Med*. 2015;49(6):357-361. doi:10.1136/bjsports-2012-091929
40. Reynolds D, Lucas J, Klaue K. Retroversion of the acetabulum: a cause of hip pain. *J Bone Joint Surg Br*. 1999;81(2):281-288.
41. Schmaranzer F, Kallini JR, Ferrer MG, et al. How common is femoral retroversion and how is it affected by different measurement methods in unilateral slipped capital femoral epiphysis? *Clin Orthop Relat Res*. 2021;479(5):947-959. doi:10.1097/CORR.0000000000001611
42. Schmaranzer F, Lerch TD, Siebenrock KA, Tannast M, Steppacher SD. Differences in femoral torsion among various measurement methods increase in hips with excessive femoral torsion. *Clin Orthop Relat Res*. Published online January 7, 2019. doi:10.1097/CORR.0000000000000610
43. Schmaranzer F, Todorski IAS, Lerch TD, Schwab J, Cullmann-Bastian J, Tannast M. Intra-articular lesions: imaging and surgical correlation. *Semin Musculoskelet Radiol*. 2017;21(5):487-506. doi:10.1055/s-0037-1606133
44. Shoji T, Yasunaga Y, Yamasaki T, Izumi S, Hachisuka S, Ochi M. Low femoral antetorsion and total hip arthroplasty: a risk factor. *Int Orthop*. 2015;39(1):7-12. doi:10.1007/s00264-014-2452-5
45. Siebenrock KA, Steppacher SD, Haefeli PC, Schwab JM, Tannast M. Valgus hip with high antetorsion causes pain through posterior extraarticular FAI. *Clin Orthop Relat Res*. 2013;471(12):3774-3780. doi:10.1007/s11999-013-2895-9
46. Steppacher SD, Anwander H, Zurmühle CA, Tannast M, Siebenrock KA. Eighty percent of patients with surgical hip dislocation for femoroacetabular impingement have a good clinical result without osteoarthritis progression at 10 years. *Clin Orthop Relat Res*. 2015; 473(4):1333-1341. doi:10.1007/s11999-014-4025-8
47. Steppacher SD, Lerch TD, Gharanzadeh K, et al. Size and shape of the lunate surface in different types of pincer impingement: theoretical implications for surgical therapy. *Osteoarthritis Cartilage*. 2014;22(7): 951-958. doi:10.1016/j.joca.2014.05.010
48. Tannast M, Hanke M, Ecker TM, Murphy SB, Albers CE, Puls M. LCPD: reduced range of motion resulting from extra- and intraarticular impingement. *Clin Orthop Relat Res*. 2012;470(9):2431-2440. doi:10.1007/s11999-012-2344 -1
49. Tannast M, Hanke MS, Zheng G, Steppacher SD, Siebenrock KA. What are the radiographic reference values for acetabular under- and overcoverage? *Clin Orthop Relat Res*. 2015;473(4):1234-1246. doi:10.1007/s11999-014-4038-3
50. Tannast M, Kubiak-Langer M, Langlotz F, Puls M, Murphy SB, Siebenrock KA. Noninvasive three-dimensional assessment of femoroacetabular impingement. *J Orthop Res*. 2007;25(1):122-131. doi:10.1002/jor.20309
51. Tannast M, Siebenrock KA, Anderson SE. Femoroacetabular impingement: radiographic diagnosis—what the radiologist should know. *AJR Am J Roentgenol*. 2007;188(6):1540-1552. doi:10.2214/AJR.06.0921
52. Tönnis D. General radiography of the hip joint. In: Tönnis D, ed. *Congenital Dysplasia and Dislocation of the Hip*. Springer; 1987.
53. Tönnis D, Heinecke A. Acetabular and femoral anteversion: relationship with osteoarthritis of the hip. *J Bone Joint Surg Am*. 1999;81(12):1747-1770.
54. Tönnis D, Heinecke A. Diminished femoral antetorsion syndrome: a cause of pain and osteoarthritis. *J Pediatr Orthop*. 1991;11(4):419-431.
55. Wang C, Sun Y, Ding Z, Lin J, Luo Z, Chen J. Influence of femoral version on the outcomes of hip arthroscopic surgery for femoroacetabular impingement or labral tears: a systematic review and meta-analysis. *Orthop J Sports Med*. 2021;9(6):23259671211009190. doi:10.1177/23259671211009192