

Case Series - General Neurology

Serial Magnetic Resonance Imaging and Magnetic Resonance Angiographic Findings of Reversible Cerebral Vasoconstriction Syndrome Associated with Postpartum

Yumiko Nakano^{a, b} Shunya Fujiwara^a Yoshio Omote^a
Motonori Takamiya^a Hisashi Narai^a Yasuhiro Manabe^a

^aDepartment of Neurology, National Hospital Organization Okayama Medical Center, Okayama, Japan; ^bDepartment of Neurology, Graduate School of Medicine, Dentistry and Pharmaceutical Sciences, Okayama University, Okayama, Japan

Keywords

Reversible cerebral vasoconstriction syndrome · Postpartum · Magnetic resonance imaging · Magnetic resonance angiography

Abstract

We report 2 cases of reversible cerebral vasoconstriction syndrome (RCVS) associated with postpartum. In case 1, a 26-year-old woman developed sudden-onset headache, nausea, and vomiting 1 h after an uncomplicated vaginal delivery. In case 2, a 27-year-old woman developed generalized seizures 9 days after an uncomplicated vaginal delivery. In both cases, initial angiographic studies showed no significant vasoconstriction; however, repeat studies revealed reversible vasoconstriction. Serial magnetic resonance imaging (MRI) revealed transient brain lesions during 6 months. RCVS remains poorly characterized, misdiagnosed, and under-recognized. Serial MRI and magnetic resonance angiographic findings may contribute to diagnosis of RCVS.

© 2022 The Author(s).
Published by S. Karger AG, Basel

Introduction

Reversible cerebral vasoconstriction syndrome (RCVS) is a clinical-angiographic syndrome characterized by the abrupt onset of severe headaches, seizures, focal neurological deficits, and segmental narrowing and dilatation of medium- and large-sized cerebral arteries, which recovers within 3 months [1–10]. The vasoconstriction can be idiopathic or associated with conditions such as migraine, vasoactive drug use, head trauma, surgery, tumors, and pregnancy [1–10]. Serial magnetic resonance imaging (MRI) and magnetic resonance angiography (MRA) findings of RCVS associated with postpartum have not been fully investigated. Herein, we present 2 cases of RCVS associated with postpartum.

Case Report

Case 1

A 26-year-old woman developed sudden-onset headache, nausea, and vomiting 1 h after an uncomplicated vaginal delivery. She had no history of migraines. On admission to our hospital (day 3 after onset), her blood pressure was 125/69 mm Hg. She had a Glasgow Coma Scale score of 14 (E3V5M6). Neurological examination revealed recent memory disturbance, right homonymous hemianopia, dysarthria, right facial nerve palsy, right hemiparesis, and sensory disturbance on right upper and lower limbs. Nose-finger-nose test was poor on left arm. All deep tendon reflexes were normal. Babinski and Chaddock signs were negative. Her initial National Institutes of Health Stroke Scale (NIHSS) score was 13. Laboratory tests showed a white blood cell count of 16,700/ μ L, a C-reactive protein level of 5.49 mg/dL, and a D-dimer level of 6.0 μ g/mL. The results of extensive tests for vasculitis were negative, including tests for antinuclear and lupus anticoagulant. Protein C and S were normal. Cerebrospinal fluid analysis showed normocytosis with an increased protein concentration of 78 mg/dL. Cerebrospinal culture was negative. Brain MRI on day 3 after onset demonstrated high signal intensity in bilateral hippocampus, left thalamus, splenium of corpus callosum, bilateral occipital lobe, pons, and left cerebellum on diffusion-weighted imaging (DWI) (Fig. 1a, b) and fluid-attenuated inversion recovery (FLAIR) (Fig. 1c, d) with a decrease of the apparent diffusion coefficient (ADC). MRA showed no significant vasoconstriction (Fig. 1e, arrowheads). She was treated with glycerol and edaravone (free radical scavenger). Brain MRI on day 7 after onset demonstrated a slight enlargement of high signal intensity on DWI (Fig. 1f, g) and FLAIR (Fig. 1h, i). MRA showed segmental vasoconstriction in the bilateral posterior cerebral arteries and basilar artery (Fig. 1j, arrowheads). The patient gradually improved recent memory disturbance, right hemiparesis, and left arm ataxia. Her NIHSS was 9. Brain MRI on day 14 after onset demonstrated a reduction of high signal intensity on DWI (Fig. 1k, l) and FLAIR (Fig. 1m, n). MRA revealed segmental vasoconstriction in the bilateral posterior cerebral arteries and basilar artery (Fig. 1o, arrowheads). Her NIHSS was 7. Brain MRI on day 24 after onset demonstrated a well reduction of high signal intensity on DWI (Fig. 1p, q) and FLAIR (Fig. 1r, s). MRA showed slight segmental vasoconstriction in the bilateral posterior cerebral arteries and basilar artery (Fig. 1t, arrowheads). Her NIHSS was 4. Brain MRI on day 159 after onset was normal (Fig. 1u–x). MRA showed complete resolution of the vasoconstriction (Fig. 1y, arrowheads). Her NIHSS was 0, but recent memory disturbance persisted.

Case 2

A 27-year-old woman developed generalized seizures 9 days after an uncomplicated vaginal delivery. On admission to our hospital, her blood pressure was 142/92 mm Hg. She had a Glasgow Coma Scale score of 12 (E3V4M5). She had no neurological deficits on admission.

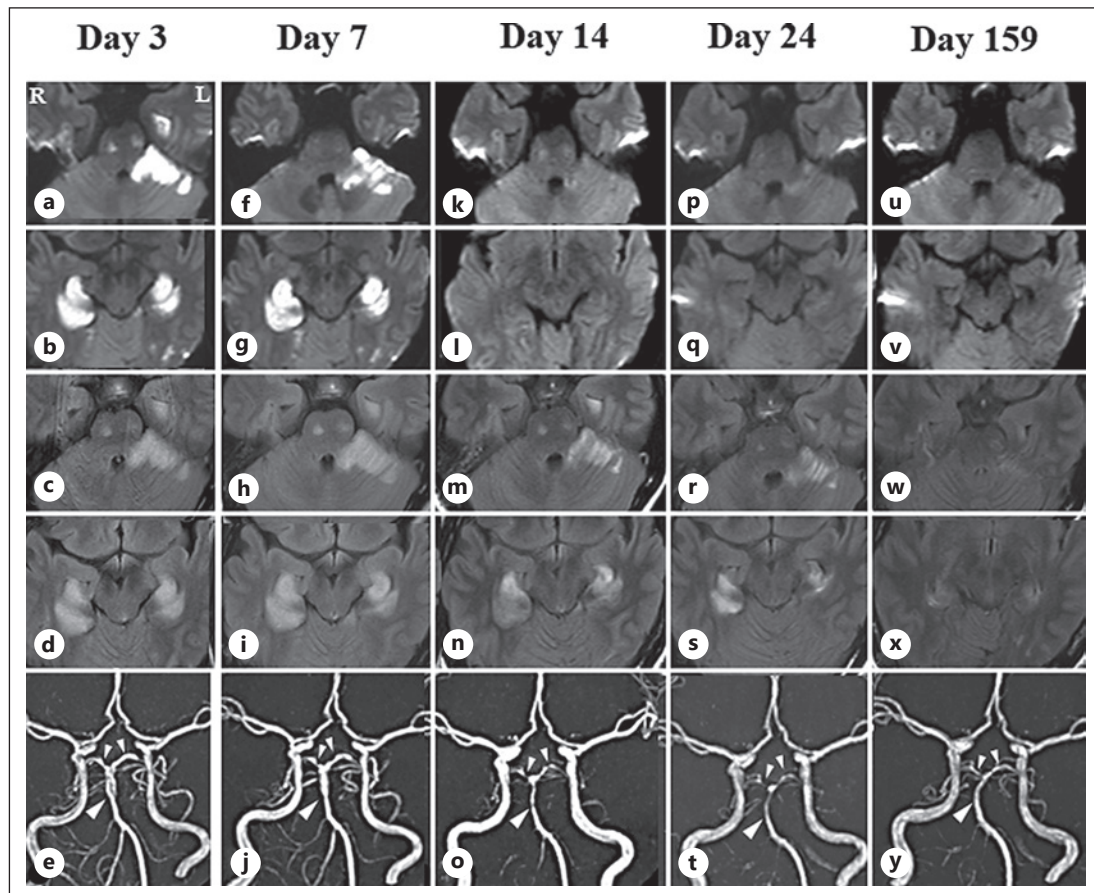


Fig. 1. Serial MRI and MRA findings in case 1. Brain MRI on day 3 after onset showing high signal intensity in bilateral hippocampus, left thalamus, splenium of corpus callosum, bilateral occipital lobe, pons, and left cerebellum on DWI (**a, b**) and FLAIR (**c, d**). MRA showing no significant vasoconstriction (**e**, arrowheads). Brain MRI on day 7 after onset showing slight enlargement of high signal intensity on DWI (**f, g**) and FLAIR (**h, i**). MRA showing segmental vasoconstriction in the bilateral posterior cerebral arteries and basilar artery (**j**, arrowheads). Brain MRI on day 14 after onset showing a reduction of high signal intensity on DWI (**k, l**) and FLAIR (**m, n**). MRA showing segmental vasoconstriction in the bilateral posterior cerebral arteries and basilar artery (**o**, arrowheads). Brain MRI on day 24 after onset showing a well reduction of high signal intensity on DWI (**p, q**) and FLAIR (**r, s**). MRA showing slight segmental vasoconstriction in the bilateral posterior cerebral arteries and basilar artery (**t**, arrowheads). Brain MRI on day 159 after onset was normal (**u–x**). MRA showing complete resolution of the vasoconstriction (**y**, arrowheads).

Laboratory tests showed creatine kinase of 424 U/L, C-reactive protein level of 1.17 mg/dL, and D-dimer level of 1.17 µg/mL. Cerebrospinal fluid analysis was normal. Cerebrospinal culture was negative. The results of extensive tests for vasculitis were negative. Brain MRI on day 2 after onset demonstrated high signal in bilateral frontal and occipital lobes on DWI (Fig. 2a) and FLAIR (Fig. 2b) with a decrease of ADC. MRA was normal (Fig. 2c). Electroencephalography revealed polyspikes in the right frontal and parietal lobes. She was treated with phenytoin (250 mg/day) and levetiracetam (1,000 mg/day). She developed confusion on day 3 after onset. She was treated with phenytoin (250 mg/day) and levetiracetam (1,500 mg/day). Brain MRI on day 8 after onset demonstrated a slight reduction of high signal intensity on DWI (Fig. 2d) and FLAIR (Fig. 2e). MRA showed segmental vasoconstriction in the bilateral middle and posterior cerebral arteries (Fig. 2f, arrowheads). She was alert on day 5 after onset.

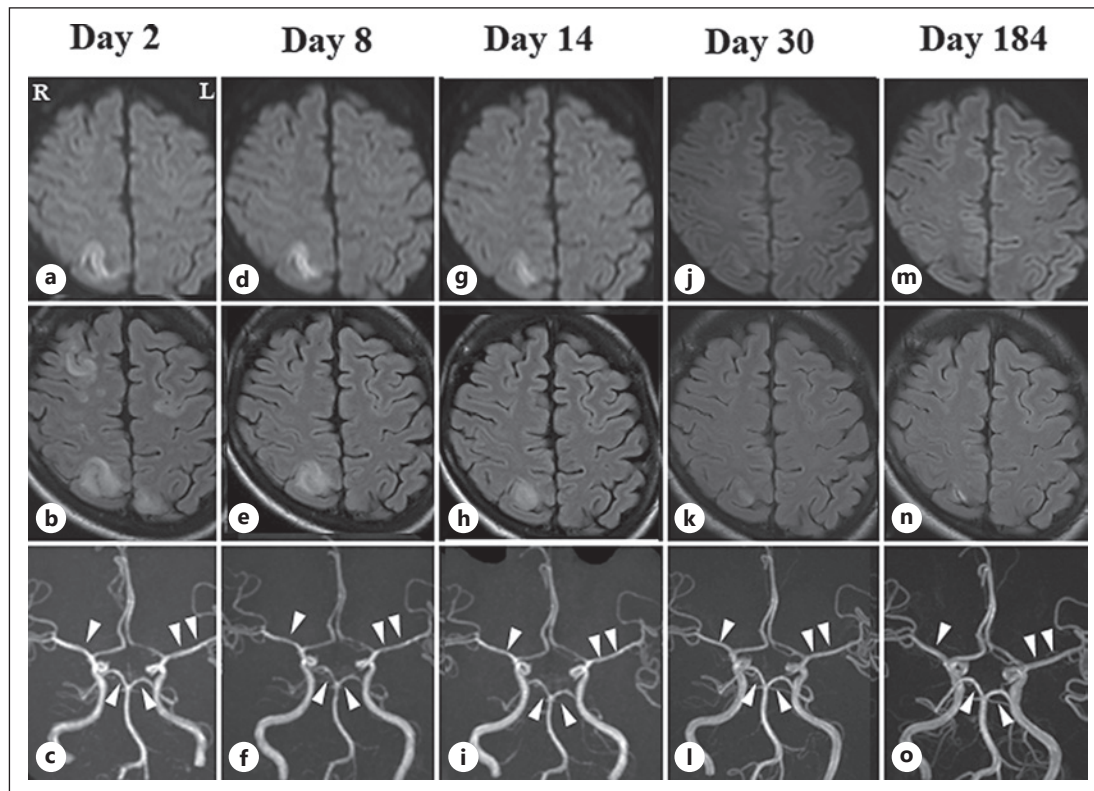


Fig. 2. Serial MRI and MRA findings in case 2. MRI on day 2 after onset showing high signal in bilateral frontal and occipital lobes on DWI (**a**) and FLAIR (**b**). MRA was normal (**c**). Brain MRI on day 8 after onset showing a slight reduction of high signal intensity on DWI (**d**) and FLAIR (**e**). MRA showing segmental vasoconstriction in the bilateral middle and posterior cerebral arteries (**f**, arrowheads). Brain MRI on day 14 after onset showing a reduction of high signal intensity on DWI (**g**) and FLAIR (**h**). MRA showing slight segmental vasoconstriction in the bilateral middle and posterior cerebral arteries (**i**, arrowheads). Brain MRI on days 30 and 184 after onset demonstrated a reduction of high signal intensity on DWI (**j**, **m**) and FLAIR (**k**, **n**). MRA on days 30 and 184 showing complete resolution of the vasoconstriction (**l**, **o**, arrowheads).

Brain MRI on day 14 after onset demonstrated a reduction of high signal intensity on DWI (Fig. 2g) and FLAIR (Fig. 2h). MRA revealed slight segmental vasoconstriction in the bilateral middle and posterior cerebral arteries (Fig. 2i, arrowheads). Brain MRI on days 30 and 184 after onset demonstrated a reduction of high signal intensity on DWI (Fig. 2j, m) and FLAIR (Fig. 2k, n). MRA on days 30 and 184 showed complete resolution of the vasoconstriction (Fig. 2l, o, arrowheads). The patient recovered completely.

Discussion

We report 2 cases of RCVS associated with postpartum. RCVS is possibly caused by a transient dysregulation of cerebral vascular tone, leading to multifocal arterial constriction and dilation [1–3]. Recent studies revealed that endothelial dysfunction may affect the regulation of cerebral arterial tone and trigger vasoconstriction with subsequent hypoperfusion, breakdown of the blood-brain barrier, and vasogenic edema [4–7]. Approximately 60% of the cases are secondary to a known likely cause, mainly occurring during the postpartum period or after exposure to vasoactive drugs [1]. Our cases did not have a history of such drugs.

As sudden decreases in concentrations of estrogen and progesterone were implicated, our cases suggest that hormonal fluctuations may trigger the syndrome.

The most difficult diagnostic dilemma clinicians face is distinguishing RCVS and primary angiitis of the central nervous system (CNS) [4, 10]. In contrast with RCVS, primary angiitis of the CNS usually has an insidious onset. Headaches are frequent but not of the thunderclap type and are followed by a stepwise deterioration with transient deficits, several infarcts, or cognitive decline [3, 10]. In the present 2 patients, symptoms developed rapidly, improved quickly, and vasoconstriction was resolved, whereas arterial irregularities in primary angiitis of the CNS do not improve so rapidly.

In case 1, brain MRI showed high signal intensity in bilateral hippocampus, left thalamus, splenium of corpus callosum, bilateral occipital lobe, pons, and left cerebellum on DWI and FLAIR with a decrease of ADC. MRA showed segmental vasoconstriction in the bilateral posterior cerebral arteries and basilar artery. In case 2, brain MRI revealed high signal in bilateral frontal and occipital lobes on DWI and FLAIR with a decrease of ADC. MRA revealed segmental vasoconstriction in the bilateral middle and posterior cerebral arteries. In both cases, initial angiographic studies showed no significant vasoconstriction; however, repeat studies revealed reversible vasoconstriction. Vasoconstriction is not always present at the onset of symptoms, may fluctuate, and resolves within days. Repeat studies 1–2 weeks later may be required to demonstrate abnormalities although occasionally the initial study may be negative. Cerebral vasoconstriction is at a maximum on angiograms 2–3 weeks after clinical onset [6]. Ducros suggested that the pathological process first includes distal arteries and then progresses toward the branches of the circle of Willis [6]. Early normal angiography suggested that the pathological process has started but is not evidenced by routine imaging techniques [6]. RCVS remains poorly characterized, misdiagnosed, and under-recognized, mainly owing to the lack of specific diagnostic tests, diagnostic criteria, and clinical trials [4]. Serial MRI and MRA findings may contribute to diagnosis of RCVS.

Statement of Ethics

This study was conducted in line with the principles of the Declaration of Helsinki. Written informed consent was obtained from each patient for publication of this case report and any accompanying images. Ethical approval is not required for this study in accordance with local guideline.

Conflict of Interest Statement

The authors state that they have no conflicts of interest.

Funding Sources

The authors have nothing to disclose.

Author Contributions

Yumiko Nakano and Yasuhiro Manabe designed the case report and wrote the manuscript. Yumiko Nakano, Shunya Fujiwara, Yoshio Omote, Motonori Takamiya, Hisashi Narai, and Yasuhiro Manabe contributed to the diagnosis, physical examination, and testing of the patient. All authors read and approved the final manuscript.

Data Availability Statement

All data generated or analyzed during this study are included in this article. Future inquiries can be directed to the corresponding author.

References

- 1 Singhal AB. Postpartum angiopathy with reversible posterior leukoencephalopathy. *Arch Neurol*. 2004;61(3):411–6.
- 2 Calabrese LH, Dodick DW, Schwedt TJ, Singhal AB. Narrative review: reversible cerebral vasoconstriction syndromes. *Ann Intern Med*. 2007;146(1):34–44.
- 3 Ducros A, Fiedler U, Porcher R, Boukobza M, Stapf C, Bousser MG. Hemorrhagic manifestations of reversible cerebral vasoconstriction syndrome: frequency, features, and risk factors. *Stroke*. 2010;41(11):2505–11.
- 4 Sattar A, Manousakis G, Jensen MB. Systematic review of reversible cerebral vasoconstriction syndrome. *Expert Rev Cardiovasc Ther*. 2010;8(10):1417–21.
- 5 Singhal AB, Hajj-Ali RA, Topcuoglu MA, Fok J, Bena J, Yang D. Reversible cerebral vasoconstriction syndrome: analysis of 139 cases. *Arch Neurol*. 2011;68(8):1005–12.
- 6 Ducros A. Reversible cerebral vasoconstriction syndrome. *Lancet Neurol*. 2012;11(10):906–17.
- 7 Togha M, Babaei M, Ghelichi PG. Reversible cerebral vasoconstriction syndrome (RCVS): an interesting case report. *J Headache Pain*. 2021;22(1):20.
- 8 Pacheco K, Ortiz JF, Parwani J, Cruz C, Yépez M, Buj M, et al. Reversible cerebral vasoconstriction syndrome in the postpartum period: a systematic review and meta-analysis. *Neurol Int*. 2022;14(2):488–96.
- 9 Perillo T, Paoletta C, Perrotta G, Serino A, Caranci F, Manto A. Reversible cerebral vasoconstriction syndrome: review of neuroimaging findings. *Radiol Med*. 2022 Aug 6;127(9):981–90.
- 10 de Boysson H, Parienti J-J, Mawet J, Arquizan C, Boulouis G, Burcin C, et al. Primary angiitis of the CNS and reversible cerebral vasoconstriction syndrome: a comparative study. *Neurology*. 2018;91(16):e1468–e1478.