

Prevalence of radiographic findings in candidate sires (2001-2008)

Prevalentie van radiografische bevindingen bij kandidaat-dek hengsten (2001-2008)

¹D. Verwilghen, ^{1,5}D. Serteyn, ³F. Pille, ²G. Bolen, ⁴J. Saunders, ¹S. Grulke, ²V. Busoni

¹Equine Clinic, Department of Companion Animals and Equids, Faculty of Veterinary Medicine, University of Liège, Sart-Tilman B41, B-4000 Liège, Belgium

²Medical Imaging, Department of Companion Animals and Equids, Faculty of Veterinary Medicine, University of Liège, Sart-Tilman B41, B-4000 Liège, Belgium

³Department of Surgery and Anesthesiology of Domestic Animals, Faculty of Veterinary Medicine, Ghent University, Salisburylaan 133, B-9820 Merelbeke, Belgium

⁴Department of Medical Imaging, Faculty of Veterinary Medicine, Ghent University, Salisburylaan 133, B-9820 Merelbeke, Belgium

⁵Centre Européen du Cheval de Mont le Soie, Mont le Soie, Belgium

denis.verwilghen@ulg.ac.be

ABSTRACT

Radiographic screening of horses prior to purchase or admission to studbooks has become an important tool for evaluating the osteo-articular status of the animals. Developmental orthopedic disorders (DOD) are the main cause of potential lameness in youngsters. The genetic factor associated with DOD has been established, and specific selection schemes have been developed to diminish the prevalence of lesions. Increasing knowledge of prevalence in different breeds may help in developing specific breeding strategies.

This article presents the results of the radiographic screening of 676 stallions presented for sire admission to the Royal Belgian Sports Horse Society (Studbook sBs). On average, two radiographic findings were noted per horse. The prevalence of DOD in this population was 38.9%. A high percentage of horses showed radiographic signs of effusion of the distal interphalangeal joint. An uncommon fragment location at the proximal tubercle of the talus was found in 7 horses. The present paper presents a review and discussion of all the radiographic findings.

SAMENVATTING

De radiologische screening van paarden voor de aankoop of de keuring van hengsten is een algemeen onderdeel geworden van de evaluatie van de osteoarticulaire toestand van het dier. Orthopedische ontwikkelingsaandoeningen (DOD) zijn een belangrijke oorzaak van kreupelheid op latere leeftijd. Een vroegtijdige detectie ervan is dus belangrijk. Door de genetische achtergrond van deze aandoeningen moeten specifieke fokstrategieën opgesteld worden. De kennis van de algemene prevalentie van de aandoeningen kan de fokker en de dierenarts helpen bij het reduceren van de prevalentie van de aandoeningen. In dit artikel worden de resultaten besproken van een radiologische screening van 676 hengsten die aangeboden werden voor een keuring bij de Koninklijke Vereniging van het Belgische Sportpaard (Studbook sBs) tussen 2001 en 2008. De prevalentie van DOD in deze populatie bedroeg 38,9%. Bij deze paarden werd een hoog percentage radiografisch merkbare synoviale opzetting van het hoefgewricht opgemerkt. Bovendien werd bij 7 paarden een fragmentatie van het proximale tuberculum van de talus vastgesteld. Er wordt een overzicht van de radiografische afwijkingen gegeven.

INTRODUCTION

Diseases leading to lameness are of major concern to the breeding industry because they not only affect performance but they also lead to direct economic losses for the owners and breeders (Olivier *et al.*, 1997). Joint disease is the most common cause of potential lameness, not only in the adult but also in younger horses. Developmental orthopedic disorders (DOD), one of the main causes of future joint disease (Jeffcott, 1996; Todhunter and Lust, 1990), can jeopardize the future athletic careers and sale values of the affected animals (van Hoogmoed *et al.*, 2003). The prevention

of DOD by eliminating those factors that are known or thought to be causative is of fundamental importance. Higher rates of osteoarticular disorders have been demonstrated in the offspring of particular sires in different breeds, a fact which strongly suggests the genetic basis and heritability of some joint diseases (Philipsson *et al.*, 1993; Pieramati *et al.*, 2003; Ricard *et al.*, 2002; Stock *et al.*, 2005a). The development of specific breeding strategies appears to be an effective way to decrease the prevalence of orthopedic health traits in horses. The careful selection of breeding products is therefore an essential part of combating the problem (Pieramati *et al.*, 2003). Selection schemes

involving only performance-based selection have led to stabilization or slight decreases in the prevalence of osteochondral fragments of the fetlock and hock joints, together with significant increases in tarsal osteoarthritis and navicular disease (Stock and Distl, 2005a). In contrast, selection schemes involving performance parameters in combination with orthopedic health traits have been shown to be more effective (Stock and Distl, 2005a). Nevertheless, even though the progeny of non-affected sires cannot be guaranteed to be free of lesions, studbooks are intended to minimize the presence of orthopedic health traits through the veterinary screening of the sires. In addition, radiographic screening seems to be useful on an individual basis, especially because radiographic findings are considered to be useful predictors of the future soundness of the individual horse (van Hoogmoed *et al.*, 2003). Increasing knowledge relating to the prevalence of different osteoarticular disorders in different breeds may help breeders and veterinarians in the establishment of breeding strategies. Moreover, these types of reports may also serve as a basis for longitudinal studies investigating the clinical significance of radiographic abnormalities.

The aim of this paper is to present the results of the radiographic screening of horses presented for admission as a sire to the Royal Belgian Sports Horse Society (Studbook sBs) from the 2001 to the 2008 season. A description will be given of the radiographic osteoarticular findings, and the prevalence of DOD lesions in this group of horses will be discussed.

MATERIALS AND METHODS

The horses

All stallions presented for veterinary screening for admission to the sBs Studbook in Belgium from the 2001 to the 2008 admission season were included in the study. They were presented either at the Faculty of Veterinary Medicine of the University of Liège or at the Faculty of Veterinary Medicine of Ghent University. All the stallions underwent the same clinical and radiographic protocol performed by the same experienced group of clinicians. During clinical examination, they were checked for signs of general sickness, and the presence of lameness was graded according to the AAEP grading system. Due to lack of cooperation in some cases, not all the horses underwent flexion tests. Horses presenting a lameness of grade III or higher were excluded from the remaining examination protocol.

Radiographic examination

All the horses were sedated using detomidine (10 µg/kg) either alone or in combination with butorphanol (0.02 mg/kg IV) for the radiographic examination.

The following projections were obtained: dorso 60° proximal-palmarodistal oblique (DPr-PaDiO) and lateromedial (LM) projections of the front feet; LM pro-

jection of the 4 fetlocks; LM, dorsoplantar (DP), 45° plantarolateral-dorsomedial oblique (PLDMO) and 45° dorsolateral-plantaromedial oblique (DLPMO) projections of the tarsi, and LM projection of the stifles. The carpi were not examined radiographically. LM radiographs of the front feet were taken in Liège with the foot weight-bearing on a flat block, whereas the LM views taken in Ghent were taken on the non-weight bearing foot positioned on the 55° and 65° block used for the DPr-PaDiO view. Additional projections were taken when a radiographic abnormality was suspected and standard radiographs were inconclusive.

The radiographs were read by means of paired lecture by a senior ECVDI board-certified radiologist and a radiology resident. In the event of doubtful interpretation of lesions, consensus was obtained between both senior radiologists of both faculties before classifying the lesion.

A review was drawn up of the most common radiographic findings, and the following findings were retained for further study. For the feet: more than 4 enlarged synovial fossa in the navicular bone, osteochondral fragments at the distal border of the navicular bone (Figure 1) and at the extensor process of the distal phalanx, degenerative joint disease (DJD) of the distal interphalangeal joint synovial effusion of the distal interphalangeal joint (Figure 2) (not recorded at Ghent University). For the fetlock: remodeling of the proximal border of the proximal phalanx (PI), irregularity (Figure 3) or well defined defect of the sagittal ridge of the third metacarpal (McIII) or metatarsal (MtIII) bone, osteochondral fragments on either the dorsal (Figure 4), the palmar or the plantar side (Figure 5) of the fetlock. For the hock: osteochondrosis with or without the presence of fragments (distal intermediate ridge of the tibia (DIT)) (Figure 6), lateral (LTT) or medial (MTT) trochlear ridge of the talus, medial (MMT) or lateral (LMT) malleolus of the tibia and the proximal tubercle of the talus (PTT) (Figure 7)), cyst-like lesions in the third tarsal bone, tarsometatarsal DJD. Presence of dorsal bony spurs (Figure 8) on the proximal third metatarsus without any change in the joint space or in the subchondral bone was classified separately from DJD. For the stifle: trochlear ridge osteochondrosis (Figure 9) and cyst-like lesions.

Osteochondrosis, cyst-like lesions, osteochondral fragments at the distal border of the navicular bone, the extensor process of the distal phalanx and in the fetlock, together with well-defined defects of the sagittal ridge of the third metacarpus/tarsus were considered DOD. All other findings were noted separately.

RESULTS

Horses

The group reviewed consisted of 676 stallions of mainly sBs (n = 222) and BWP (n = 145, Belgian

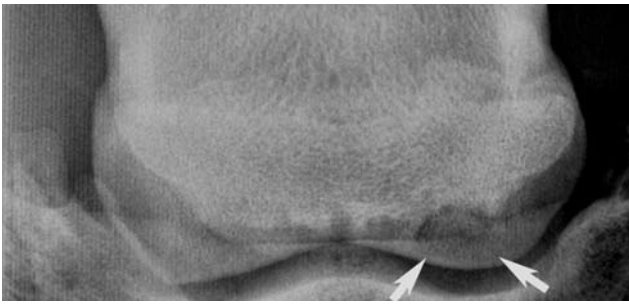

Figure 1. 55° Dorsoproximal-Planterodistal Oblique view of the navicular bone. The arrows point at the fragment of the distal border of the navicular bone.

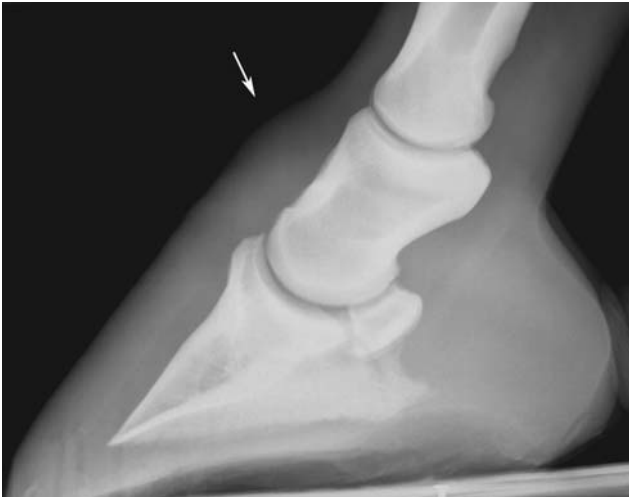


Figure 2. Lateromedial view of the foot. Note the convex appearance of the dorsal profile of the skin dorsal to the middle phalanx (arrow) in the region of the dorsal recess of the distal interphalangeal joint (DIPJ). This radiographic sign is indicative of synovial effusion of the DIPJ.

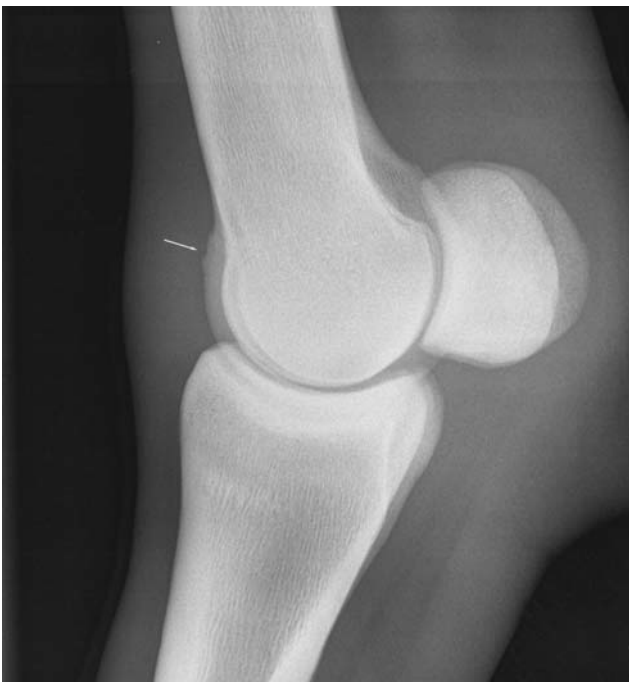

Figure 3. Lateromedial view of a front fetlock showing a mild irregularity of the proximal part of the sagittal ridge of the third metacarpal bone condyle.

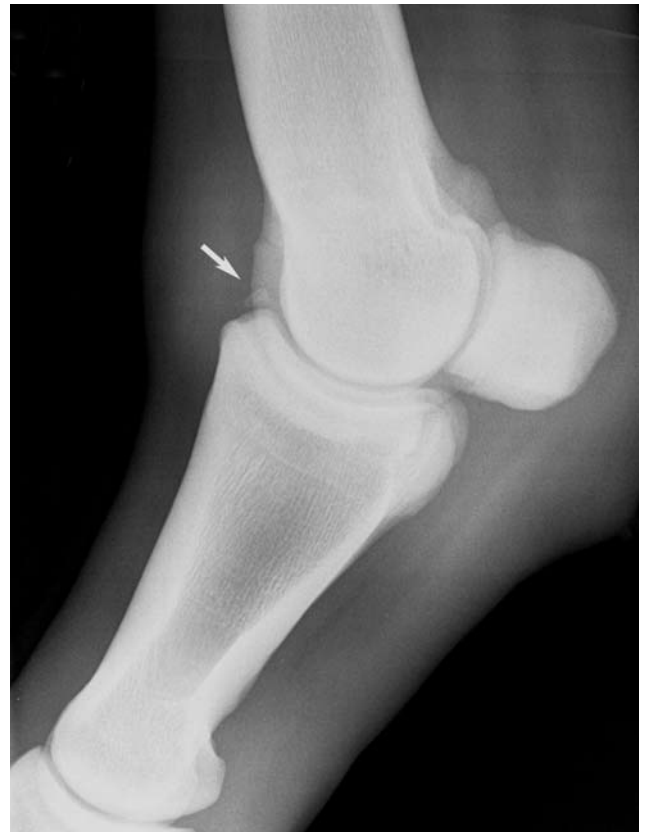

Figure 4. Lateromedial view of a hind fetlock. The arrow points at an osteochondral fragment located at the dorso-proximal border of the proximal phalanx.

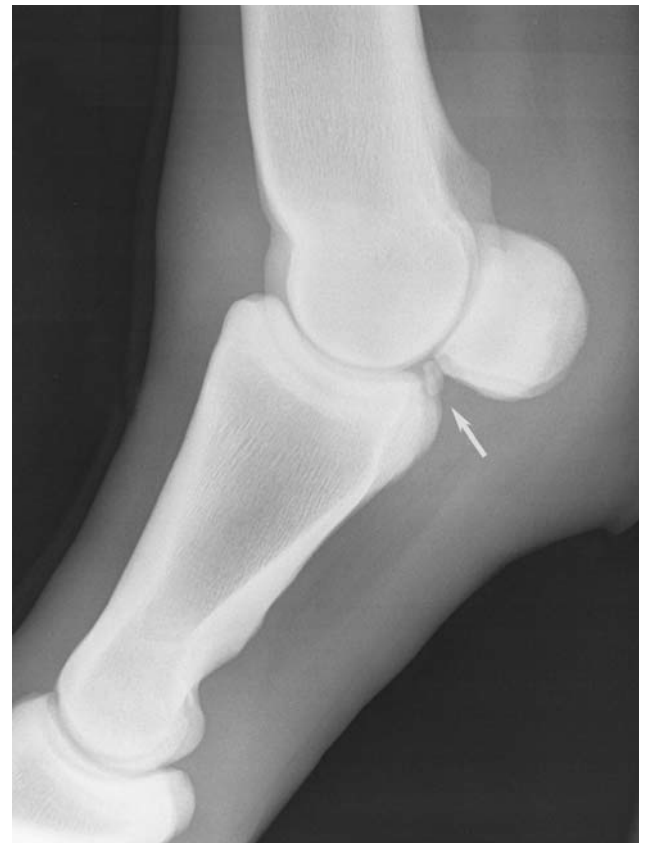

Figure 5. Lateromedial view of a hind fetlock. There is a radiopaque plantar bony fragment in the sesamoido-phalangeal space (arrow).

Warmblood Horse) origin. Other breeds included were Dutch Warmbloods (n=54, KWPN), Hanoverian (n=27), Holstein (n=49), Zangersheide (n=34), Oldenburger (n=15), and Selle Francais (n=72). Fifty-eight horses originated from a variety of other breeds. The average age of the stallions was 3.27 ± 2.04 years old (median 3 year old), with the youngest being 16 months old and the oldest 19 years.

Radiographic examination

Of all the examinations, 511 were performed at Liège, and 165 at Ghent.

The average number of radiographic abnormalities found per horse was 2.39, with a maximum of 12. One

hundred and eighty-two horses (26.92%) had no radiographic abnormality detected. The prevalence of DOD in this population was 38.91%.

The most common finding was synovial effusion of the distal interphalangeal joint (45% of horses), followed by "more than 4 or enlarged synovial fossa" (21% of the horses) and "mild surface irregularity of the proximal border of the sagittal ridge of the metacarpus/metatarsus" (16.1% of the horses). A full review of the radiographic findings is reported in Table 1, and the distribution of the findings can be found in Figure 10.

All other findings not listed in Table 1 were noted separately. They were included in the sum of radiological findings, but, apart from two horses showing a

Table 1. Summary of the radiographic findings in 676 horses. DJD: degenerative joint disease. DIPJ: distal interphalangeal joint.

Region examined	Finding	Number of joints affected	% of joints affected	Number of horses affected	% of horses affected
Feet (n=1352)					
	More than 4 or enlarged synovial fossa	236	17.4	145	21.0
	Osteochondral fragment at the distal border of the navicular bone	70	5.2	58	8.6
	Osteochondral fragment at the proximal border of the extensor process of the pedal bone	18	1.3	15	2.2
	DJD of the DIPJ	9	0.7	6	0.9
	Synovial effusion of the DIPJ*	378*	37	230*	45.0*
	*Findings recorded only at Liège on 511 horses, 1022 feet.				
Fetlock (n=2704)					
	Remodeling of the proximal border of the first phalanx	179	6.6	103	15.2
	Mild surface irregularity of the proximal border of the sagittal ridge of the metacarpus/tarsus	183	6.8	109	16.1
	Well defined osteochondral defect of the proximal border of the sagittal ridge of the metacarpus/tarsus	28	1	21	3.1
	Dorsal osteochondral fragment originating from the metacarpal/tarsal bone	47	1.7	39	5.8
	Osteochondral fragment of the dorsal proximal border of the first phalanx	48	1.7	40	5.9
	Palmar fragments of the proximal first phalanx	4	0.1	3	0.4
	Plantar fragments of the proximal phalanx	35	1.3	33	4.9
Hock (n=1352)					
	Osteochondral defects in total	80	5.9	64	9.5
	Osteochondral defects including fragments	38	2.8	32	4.7
	Localization				
	Osteochondral defect at the distal intermediate ridge of the tibia	43	3.2	32	4.7
	Osteochondral defect at the lateral trochlear ridge of the talus	6	0.4	5	0.7
	Osteochondral defect at the medial trochlear ridge of the talus	21	1.5	17	2.5
	Osteochondral defect at the medial malleolus of the tibia	1	0.07	1	0.1
	Osteochondral defect at the lateral malleolus of the tibia	2	0.1	2	0.3
	Osteochondral defect at the proximal tuberculum of the talus	7	0.5	7	1.0
	DJD	37	2.7	28	4.1
	Dorsal bony spur (osteophytes/enthesiophyte) at the tarsometatarsal joint	83	6.1	54	8.0
	Cystic lesion at the third tarsal bone	6	0.4	6	0.9
Stifle (n=1352)					
	Cystic-like lesions	0	0	0	0
	Osteochondral defects of the femoral ridges	48	3.5	34	5.0
	Osteochondral defects of the femoral ridges, including fragments	27	2	23	3.4

subchondral bone cyst-like lesion in the distal phalanx, these findings were not considered a sign of DOD and thus were not included in the prevalence calculation. One horse had bilateral signs of linear lysis of the abaxial border of the proximal sesamoid bones in the front legs. One horse showed a fracture of the solar margin of the distal phalanx (type VI) on the medial aspect of the left fore foot and on the lateral aspect on the right fore foot. One horse showed an osseous fragment at the proximal border of the medial proximal se-

samoid bone in one hind limb and on the lateral proximal sesamoid bone in the other hind limb. These fragments were considered to be of traumatic origin and therefore not considered as DOD.

DISCUSSION

The objective of this study was to determine the prevalence of abnormal radiographic findings related to DOD in limb joints of stallions presented for

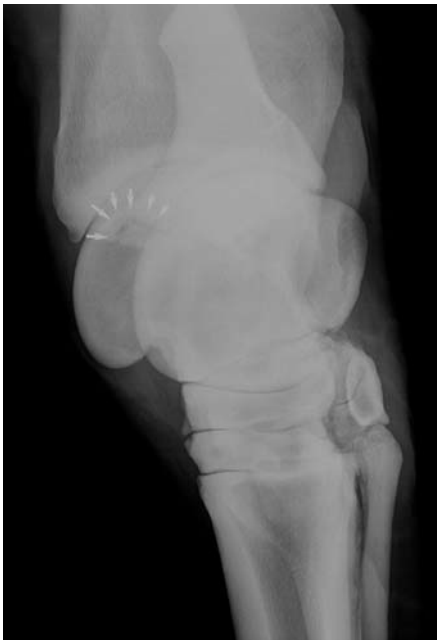

Figure 6. Plantarolateral-Dorsomedial Oblique view of the hock. The arrows point at a radiolucent line separating an osteochondral fragment of the distal intermediate ridge of the tibia.

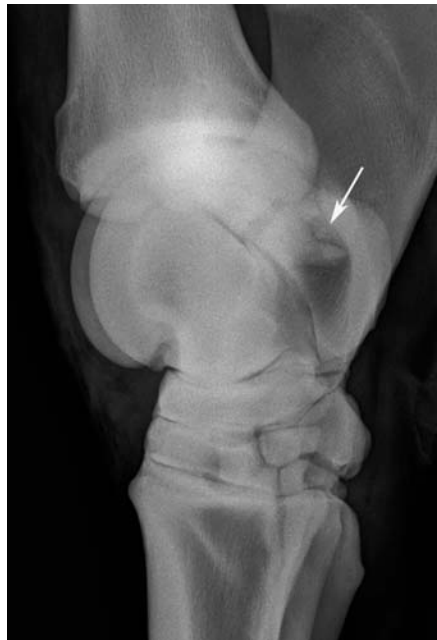

Figure 7. Lateromedial view of a hock. There is a faint radiolucent line in the region of the proximal tubercle of the talus separating a plantar bony fragment (arrow).

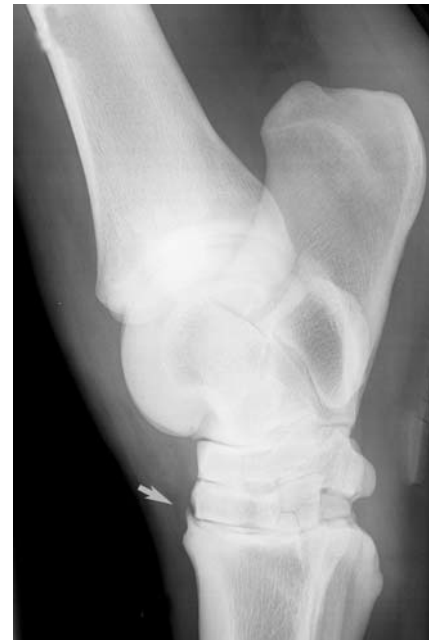

Figure 8. Lateromedial view of the hock. The arrow points at a bony spur with well defined contour on the dorsoproximal aspect of the third metatarsus without any change of opacity either in the joint margins or in the subchondral bone. This radiographic finding is not considered a DJD sign, but rather an incidental finding without clinical significance.

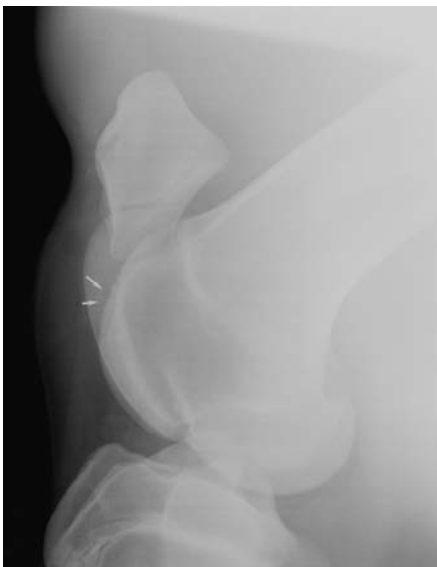

Figure 9. Lateromedial view of the stifle. There is an area (arrow) with irregular surface of the subchondral bone and decreased and heterogeneous radiopacity in the proximal half of the lateral trochlear ridge of the femur.

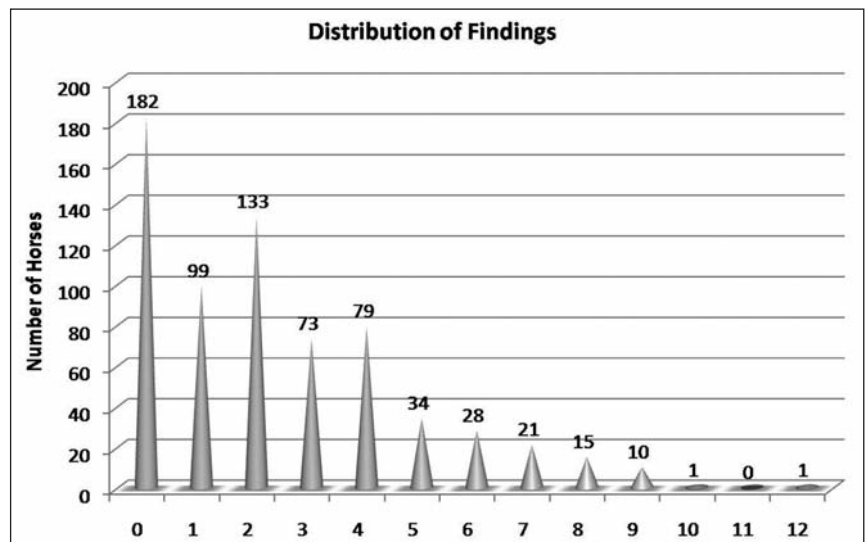


Figure 10. Distribution of the number of findings in 676 horses.

Studbook admission. A total of 676 stallions were included in this study. Although the oldest horse included in this report was 19 years old, the mean and median ages were both approximately 3 years old. This review therefore describes radiographic findings in a relatively young population in which degenerative changes due to intensive use would not yet be expected. Considering the fact that the sBs Studbook does not exclusively admit sires from their own breed, a variety of European Warmblood horses were included in the study. The population presented here can therefore be considered similar to populations in other reports on the subject (Stock and Distl, 2005a, 2006; Stock *et al.*, 2005b; Stock *et al.*, 2004; Vos, 2008; Wittwer *et al.*, 2006).

The vast majority of horses (57.7%) showed 1 to 4 radiographic findings, and only 26.9% were free of radiographic findings. The overall prevalence of DOD lesions in this population was 38.9%. Prevalences of between 8% and 79% have been cited in the literature, depending on the horse population and the joints investigated (Grondahl, 1991, 1992; Kane *et al.*, 2003; Philipsson *et al.*, 1993; Stock *et al.*, 2005b; Stock *et al.*, 2004; Wittwer *et al.*, 2006). Compared to similar Warmblood populations, this overall prevalence is far less than the 76.9% described in Selle Français horses (Denoix *et al.*, 2000), but is quite similar to the 44.3% and 35.6% recently described in Dutch and German Warmbloods, respectively (Arnan and Hertsch, 2005; Vos, 2008). It should be pointed out that the wide variety of prevalence values described in the literature could partly be due to the difficulties and differences in classifying radiographic findings. In this study, paired reading of the radiographs was used, and when there was disagreement, consensus was sought between senior radiologists as to whether or not to include the lesion in the DOD group. On the other hand, considering the limited number of radiographs taken per joint and the fact that DOD lesions have been described in almost every diarthrodial joint (Van Weeren, 2006), the overall prevalence of DOD may be underestimated in this population because neither the cervical, nor the carpal, nor the humeroradial nor the scapulohumeral joints were assessed. Effusion of the distal interphalangeal joint (Figure 2) was the most common radiographic finding (45% of horses), and it correlates with findings in clinically sound horses where distal interphalangeal joints are often found distended, either unilaterally or bilaterally (Dyson, 2003). This high prevalence may indicate that this joint is subjected to high workload in young horses at the beginning of their training. However, an overestimation of this radiographic abnormality may have also occurred and contributed to the high prevalence. A recent study performed on the same population evidenced decreased plasma insulin-like growth factor-I (IGF-I) and elevated Coll2-1 (fragment of collagen 2) levels in horses with distal interphalangeal joint effusion detected by radiography (Verwilghen *et al.*, 2009a), possibly confirming the hypothesis of high workload as the cause of high prevalence of effusion. This hypothesis

was further supported by the findings by Jackson *et al.* (2003), where similar lower serum IGF-I levels were encountered in a group of 2-year-old Thoroughbreds that had been exercised on a treadmill for 20 weeks compared to controls. Moreover, the higher values of Coll2-1 (Verwilghen *et al.*, 2009a) suggest collagen type II degradation in this group, which is similar to the increased levels of cartilage degradation biomarkers that human researchers in sports medicine (O’Kane *et al.*, 2006) found in heavily exercised human athletes compared to non-athletic controls. No comparison with clinical findings or with other imaging techniques to estimate the amount of synovial filling of the distal interphalangeal joint has been done in this study, but the results of an *ex-vivo* study comparing injected volume and radiographic diagnosis of distal interphalangeal joint effusion revealed a good sensitivity of the radiographic examination for detection of this abnormality (Mendoza, 2009).

Different studies provide evidence that fragments at the distal border of the navicular bone (Figure 1) are likely to cause lameness, especially if they are associated with other abnormalities of the navicular bone and if radiolucent or sclerotic zones are present in the adjacent navicular bone (Dyson, 2008). However, in a clinically sound horse, these fragments can turn out to be an incidental finding, especially if the opacity contour of the navicular bone is normal. They may be a reflection either of a distal border fracture of the navicular bone, or of a fracture, of an enthesophyte at the origin of the distal sesamoidean impar ligament, or of an ectopic mineralization in the sesamoidean impar ligament (Dyson, 2008). In the present review these fragments were found in 70 of the 1352 feet examined (5.2% of the feet examined, 8.6% of the horses examined), which is similar to their prevalence in a group of clinically normal horses examined during pre-purchase (Kaserhotz and Ueltschi, 1992). These fragments are most easily detected on the DPr-PaDiO – 60° view, but are diagnostically challenging using radiography. Repeating views varying the DPr-PaDiO angle from 55° to 65° and adding a skyline of the navicular bone may increase diagnostic confidence in revealing the presence of such fragments. MRI and CT have proven to be much more sensitive in the detection of this type of lesion, but are technically not useable in the context of pre-purchase or stallion screening (Schramme *et al.*, 2005).

In 9.5% of the horses, osteochondral lesions were found in the tarsocrural joint, and in only half of this 9.5% did the lesion include a fragment. This is less than the 15%, 16% and 13.3% observed in Swedish, Dutch and French Warmblood horses, respectively (Denoix *et al.*, 2000; Hoppe, 1984; Vos, 2008). In only 4.7% of the horses examined were osseous fragments found in the tarsocrural joint, which is less than the 9.6% reported in Hanoverian Warmbloods (Stock *et al.*, 2005b). This difference may be explained by the nature of the population examined. In fact, most of the professional breeders have their sires pre-screened before they are presented for the official Studbook scree-

ning. Fragments in the tarsocrural joint are easily recognized on radiographs and may have been removed before the horse is presented for the official screening, leaving only an osteochondral defect. With 4.7% of horses affected, the distal intermediate ridge of the tibia (Figure 6) was the most common location for osteochondrosis in the tarso-crural joint in the present study, as has previously been reported by other authors as well (Carlsten *et al.*, 1993; Hoppe, 1984; Richardson, 2003; Vos, 2008). The 2.5% prevalence of osteochondral defects at the level of the medial trochlear ridge is also in accordance with previous reports (Vos, 2008). Some atypical locations for osteochondral lesions, such as the proximal articular margin of the medial trochlear ridge, have been previously reported (Simpson and Lumsden, 2001), although osteochondral fragments at the proximal tubercle of the talus (Figure 7) have not been previously noted in screening studies. In the present review, 7 tarsi from 7 different horses included an osteochondral fragment at the proximal tubercle of the talus, making this location more prevalent (1%) than the lateral trochlear ridge of the talus (0.7%), the medial malleolus of the tibia (0.1%) and the lateral malleolus of the tibia (0.3%).

With its 5.32% of horses affected, this Warmblood population seems far less affected by palmar/plantar osteochondral fragments of the fetlock than are Standardbred Trotters, where occurrences of 11.8% to 19.2% have been described (Courouce-Malblanc *et al.*, 2006; Grondahl, 1992; Jacquet *et al.*, 2003). Only in 4 front fetlocks of three different horses (0.44%) were palmar fragments of the proximal phalanx found, although plantar fragments (Figure 5) were found in 35 joints of 33 horses (4.88%). This predilection for the hind limb seems to be in accordance with previous reports in Warmbloods (Vos, 2008) and in Standardbreds (Grondahl, 1992). In this study, palmar/plantar osteochondral fragments of the fetlock were included in the overall DOD prevalence, as was also done in a similar study on Dutch Warmbloods (Vos, 2008) and as suggested by other authors (Britt and Tucker, 2007; Douglas, 2003). However, it has been hypothesized that plantar osteochondral fragments may have a biomechanical origin linked to repeated trauma caused by training and tension on the distal sesamoidean ligaments rather than caused by troubles in the endochondral ossification (Dalín *et al.*, 1993; Nixon and Pool, 1995). If this hypothesis is retained, alone or in association with abnormal endochondral ossification, the discrepancy in prevalences of this finding between Trotters and Warmbloods of the same age range may be explained by the less intense exercise regime of the Warmbloods at that young age. If this type of fragment is not included in the overall prevalence of DOD lesions in this population, a prevalence of 34.12% of DOD is obtained. This consequently addresses the major controversies regarding the etiology of fragments in the fetlock. It is generally accepted that fragments originating from the sagittal ridge of metacarpal and metatarsal bone are the result of a process called dyschondroplasia, which is characterized by a failure

in endochondral ossification (Douglas, 2003). To the contrary, it has been suggested that other fragments of the fetlock may have other etiologies than dyschondroplasia. However, as already suggested by Declercq *et al.* (2009) for dorsoproximal fragments of the first phalanx, all fetlock fragments may be included in DOD. In fact, as stated by McIlwraith (2004), the term developmental orthopedic disorder (DOD), which is not a synonym for osteochondrosis, should encompass all orthopedic problems seen in the growing horse. Two hundred and fifty-eight fetlocks (25% of the horses) had radiographic findings located at the proximal border of the sagittal ridge of the metacarpal/metatarsal bones. The large majority of these mild surface irregularities (Figure 3) were found in 70.93% of the joints. Only 28 joints in 21 horses (3.86%) showed a well-defined defect, and in another 47 joints and 39 horses (5.76%) this defect was associated with an osteochondral fragment. This data is far less impressive than that of Wittwer *et al.* (2006), who reported radiographic abnormalities at the sagittal ridge of the third metacarpal/tarsal bone in 53.9% of 167 horses examined. In that study, an irregular bone margin was reported in only 33% of the cases (Wittwer *et al.*, 2006). Osteochondral lesions have been shown to evolve and even to disappear, as demonstrated in the stifle and the tarsus by Dik *et al.* (1999). Considering that 41% of the population examined by Wittwer *et al.* (2006) was below the age of 10 months, it can be conceived that some of the lesions were still active and were either in progression or regression. Some of the lesions characterized as radiolucencies, proximal concavities or isolated radiopaque areas in that study may therefore end up as moderate irregularities of the proximal sagittal ridge of metacarpal and metatarsal bone, as found in a large number of cases in the older population of the present study.

The 8.4% prevalence of osteochondrosis of the femoral trochlea is in accordance with findings in other sport horse populations (Ricard *et al.*, 2002; Vos, 2008), and it is higher than the prevalence found in stifles of Thoroughbred (5.4%) (Kane *et al.*, 2003). In the present population, no cyst-like lesions were found in the femoral condyles. This is in accordance with the literature, where it seems to be an uncommon finding in radiographic surveys, as illustrated by a study of 600 Thoroughbreds at yearling sales, in which no cystic lesions were found (Kane *et al.*, 2003). However, in that study, only 170 series of stifle radiographs were of sufficient quality for evaluation, thus probably making the figure non-reliable. The low prevalence of this finding may also be related to the onset of lameness that is usually associated with cyst-like lesions. In fact, unlike other findings reported here, cyst-like lesions are commonly associated with lameness (Walmsley, 2003), even before the start of training. Horses suffering from this condition may therefore be selected out of this type of study because they are never presented by the owners for stallion expertise. The distal phalanx is reported as the second most prevalent location for cyst-like lesions, especially in Warmblood

horses, in which this location is overrepresented (Von Rechenberg and Auer, 2006). In this report, two horses showed evidence of a cyst-like lesion in the distal phalanx.

Fifty-four horses showed dorsal bony spurs (Figure 8) in 83 tarsometatarsal joints (7.99% of the horses). This prevalence is far lower than the 17.5% found in Thoroughbreds by Kane *et al.* (2003). Thirty-seven horses (4.1%) showed radiographic signs of tarsal DJD. The occurrence of tarsal DJD is rarely reported in sire admission screening if it is not extensive and/or associated with current lameness. Still, tarsal DJD can dramatically impair a horse's career, and the heritability of this finding has been shown at $h^2=0.22$ (Stock and Distl, 2005b). Moreover, the occurrence of this finding can be drastically reduced by selecting horses on the basis of their not having this orthopedic health threat, together with their performance in dressage and/or show jumping (Stock and Distl, 2005a). Selection on this basis should probably be considered in the future.

Considering the multifactorial origin, including heritability of osseous fragments in horses, selection could be used to reduce the incidence of lesions. Unfortunately, reported heritability estimates for osteochondral lesions in the horse vary greatly (0.02–0.64), and in many cases the estimates of similar studies have high standard errors (Wittwer *et al.*, 2007). Recent research in a Dutch Warmblood population (van Grevenhof *et al.*, 2009) reported an overall heritability of 0.23 for osteochondral lesions in general. When focused on the joint level, heritability was greatest in the tarsocrural joints, intermediate in the metacarpo- and metatarsophalangeal joints, and least in the femoropatellar joints. The authors of this study emphasize the fact that, despite the low heritability of osteochondrosis lesions in the femoropatellar joint, selection based on this joint should not be underestimated, as it is an important cause of stifle lameness. This is in contrast to the tarsocrural joint, where osteochondrosis only occasionally leads to lameness and has an excellent prognosis after surgery. Wittwer *et al.* (2007) found a very interesting difference in heritability for the different locations of fragments in the fetlock in a coldblood population. The higher heritability ($h^2=0.21$) found for plamar/plantar fetlock fragments compared to dorsal metacarpal/metatarsal fragments ($h^2 = 0.04$) means that selection should be directed towards eliminating horses with this radiological threat.

The impact of pre-selection on overall prevalence of DOD lesions may be considered a limitation to this study. Especially stallions presented by professional horsemen may have been screened radiographically beforehand and even operated on. For most locations, it is still possible to identify sites with previous localization of fragments due to the remaining depression in the subchondral bone bed. However, in a certain amount of these operated horses, radiographic findings may have not been clear enough to be conclusive and therefore not included as DOD lesions. Moreover, horse owners who are aware of the presence of lesions

may not present their stallions at all for sire admission, especially those affected with tarsocrural and stifle osteochondrosis, which are most commonly screened by field veterinarians.

The correlation between body weight, height at withers, breed, age and/or future performance and the presence and location of lesions has not been studied, but such a study could reveal interesting results for evaluation in the future. This is especially the case in the light of the relationships previously established between body condition and the occurrence of osteochondral lesions (Jeffcott and Henson, 1998; Stanier *et al.*, 2007; Verwilghen *et al.*, 2009b).

In conclusion, this study describes radiographic findings and their prevalence in a young male horse population without clinical signs of disease. Increasing knowledge about DOD and its prevalence and about the radiographic appearance of the lesions will help veterinarians in the screening of horses and in the establishment of adequate management protocols.

REFERENCES

- Arnan P., Hertsch B. (2005). Osteochondrosis of the fetlock, hock and stifle joint in comparison between foals and two-year-old horses. *Pferdeheilkunde* 21, 322-326.
- Britt L., Tucker J.R. (2007). Metacarpophalangeal/metatarsophalangeal Articulation. In: Thrall, D.E. (editor). *Textbook of Veterinary Diagnostic Radiology*. 5th Ed., Saunders Elsevier, St. Louis, Mo., p. 409-420.
- Carlsten J., Sandgren B., Dalin G. (1993). Development of osteochondrosis in the tarsocrural joint and osteochondral fragments in the fetlock joints of Standardbred trotters. I. A radiological survey. *Equine Veterinary Journal Supplement* 16, 42-47.
- Courouze-Malblanc A., Leleu C., Bouchilloux M., Geffroy O. (2006). Abnormal radiographic findings in 865 French standardbred trotters and their relationship to racing performance. *Equine Veterinary Journal Supplement* 36, 417-422.
- Dalin G., Sandgren B., Carlsten J. (1993). Plantar osteochondral fragments in the metatarsophalangeal joints in Standardbred trotters: a result of osteochondrosis or trauma? *Equine Veterinary Journal Supplement* 16, 62-65.
- Declercq J., Martens A., Maes D., Boussauw B., Forsyth R., Boening K.J. (2009). Dorsoproximal proximal phalanx osteochondral fragmentation in 117 Warmblood horses. *Veterinary and Comparative Orthopaedics and Traumatology* 22, 1-6.
- Denoix J.M., Valette J.P., Heiles P., Ribot X., Tavernier L. (2000). Etude radiographique des affections ostéo-articulaires juvéniles (AOAJ) chez des chevaux de races Françaises, âgés de trois ans: présentation globale des résultats sur 1180 sujets. *Pratique Vétérinaire Equine* 32, 35-41.
- Dik K.J., Enzerink E., van Weeren P.R. (1999). Radiographic development of osteochondral abnormalities, in the hock and stifle of Dutch Warmblood foals, from age 1 to 11 months. *Equine Veterinary Journal Supplement* 31, 9-15.
- Douglas J. (2003). Pathogenesis of osteochondrosis, developmental orthopaedic diseases and Lameness. In: Ross M.W., Dyson S.J. (eds.). *Diagnosis and Management of*

- Lameness in the Horse*. W. B. Saunders, Philadelphia, Pa.; London, p. 534-543.
- Dyson S. (2003). The distal phalanx and distal interphalangeal joint. In: Ross M.W., Dyson S. (editors). *Diagnosis and Management of Lameness in the Horse*. 1st Ed., W. B. Saunders, Philadelphia, Pa.; London, p. 310-316.
- Dyson S. (2008). Radiological interpretation of the navicular bone. *Equine Veterinary Education* 20, 268-280.
- Grondahl A.M. (1991). The incidence of osteochondrosis in the tibiotarsal joint of Norwegian Standard-Bred Trotters – a radiographic study. *Journal of Equine Veterinary Science* 11, 272-274.
- Grondahl A.M. (1992). The incidence of bony fragments and osteochondrosis in the metacarpophalangeal and metatarsophalangeal joints of Standard-Bred Trotters – a radiographic study. *Journal of Equine Veterinary Science* 12, 81-85.
- Hoppe F. (1984). Radiological investigations of osteochondrosis dissecans in Standardbred Trotters and Swedish Warmblood horses. *Equine Veterinary Journal* 16, 425-429.
- Jackson B.F., Goodship A.E., Eastell R., Price J.S. (2003). Evaluation of serum concentrations of biochemical markers of bone metabolism and insulin-like growth factor I associated with treadmill exercise in young horses. *American Journal of Veterinary Research* 64, 1549-1556.
- Jacquet S., Robert C., Courtin G., Valette J.P., Coudry V., Denoix J.M. (2003). Corrélatons entre le status ostéoarticulaire et les performances sportives de 129 Trotteurs Français de Basse Normandie. In: *29ième Journée d'Etude des Haras Nationaux*, 83-92.
- Jeffcott L.B. (1996). Osteochondrosis - an international problem for the horse industry. *Journal of Equine Veterinary Science* 16, 32-37.
- Jeffcott L.B., Henson F.M.D. (1998). Studies on growth cartilage in the horse and their application to aetiopathogenesis of dyschondroplasia (osteochondrosis). *Veterinary Journal* 156, 177-192.
- Kane A.J., Park R.D., McIlwraith C.W., Rantanen N.W., Morehead J.P., Bramlage L.R. (2003). Radiographic changes in Thoroughbred yearlings. Part 1: prevalence at the time of the yearling sales. *Equine Veterinary Journal* 35, 354-365.
- Kaserhotz B., Ueltschi G. (1992). Radiographic appearance of the navicular bone in sound horses. *Veterinary Radiology & Ultrasound* 33, 9-17.
- Mendoza P. 2009. Relative values of radiography and ultrasonography for the evaluation of synovial effusion in the ex-vivo equine distal interphalangeal joint. *Complementary Master Thesis*. Equine Clinic, Department of Clinical Sciences of the Compagnon Animals and Equids. University of Liège, Liège, p. 45.
- Nixon A.J., Pool R.R. (1995). Histologic appearance of axial osteochondral fragments from the proximoplantar proximopalmar aspect of the proximal phalanx in horses. *Journal of the American Veterinary Medical Association* 207, 1076-1080.
- O'Kane J.W., Hutchinson E., Atley L.M., Eyre D.R. (2006). Sport-related differences in biomarkers of bone resorption and cartilage degradation in endurance athletes. *Osteoarthritis and Cartilage* 14, 71-76.
- Olivier A., Nurton J.P., Guthrie A.J. (1997). An epizootiological study of wastage in thoroughbred racehorses in Gauteng, South Africa. *Journal of the South African Veterinary Association* 68, 125-129.
- Philipsson J., Andréasson E., Sandgren B., Dalin G., Carlsten J. (1993). Osteochondrosis in the tarsocrural joint and osteochondral fragments in the fetlock joints in Standardbred trotters. II. Heritability. *Equine Veterinary Journal Supplement* 16, 38-41.
- Pieramati C., Pepe M., Silvestrelli M., Bolla A. (2003). Heritability estimation of osteochondrosis dissecans in Maremmano horses. *Livestock Production Science* 79, 249-255.
- Ricard A., Valette J.P., Denoix J.M. (2002). Heritability of juvenile osteo-articular lesions of sport horses in France. In: *7th World Congress on Genetics Applied to Livestock Production*. Montpellier, France.
- Richardson D.W. (2003). Diagnosis and Management of Osteochondrosis and Osseous Cyst-like Lesions. In: Ross M.W., Dyson S.J. (editors). *Diagnosis and Management of Lameness in the Horse*. 1st Ed., W. B. Saunders, Philadelphia, Pa., London, p. 549-554.
- Schramme M.C., Murray R.C., Blunden A.S., Dyson S.J. (2005). A Comparison between magnetic resonance imaging, pathology, and radiology in 34 limbs with navicular syndrome and 25 control limbs. In: *51th Annual Convention of the AAEP*. Seattle, WA, USA.
- Simpson C.M., Lumsden J.M. (2001). Unusual osteochondral lesions of the talus in a horse. *Australian Veterinary Journal* 79, 752-755.
- Staniar W.B., Kronfeld D.S., Akers R.M., Harris P.A. (2007). Insulin-like growth factor I in growing thoroughbreds. *Journal Animal Physiology and Animal Nutrition* 91, 390-399.
- Stock K.F., Distl O. (2005a). Evaluation of expected response to selection for orthopedic health and performance traits in Hanoverian Warmblood horses. *American Journal of Veterinary Research* 66, 1371-1379.
- Stock K.F., Distl O. (2005b). Prediction of breeding values for osseous fragments in fetlock and hock joints, deforming arthropathy in hock joints, and pathologic changes in the navicular bones of Hanoverian Warmblood horses. *Livestock Production Science* 92, 77-94.
- Stock K.F., Distl O. (2006). Genetic analyses of the radiographic appearance of the distal sesamoid bones in Hanoverian Warmblood horses. *American Journal of Veterinary Research* 67, 1013-1019.
- Stock K.F., Hamann H., Distl O. (2005a). Estimation of genetic parameters for the prevalence of osseous fragments in limb joints of Hanoverian Warmblood horses. *Journal of Animal Breeding and Genetics* 122, 271-280.
- Stock K.F., Hamann H., Distl O. (2005b). Prevalence of osseous fragments in distal and proximal interphalangeal, metacarpo- and metatarsophalangeal and tarsocrural joints of Hanoverian Warmblood horses. *Journal of Veterinary Medicine. A. Physiology, Pathology, Clinical Medicine* 52, 388-394.
- Stock K.F., Meiners F., Hamann H., Distl O. (2004). Analysis of the distribution of radiographic findings among Hanoverian Warmblood horses selected for sale by auction. Part 1: osseous fragments in different limb joints. *Tierärztliche Praxis Ausgabe Grosstiere Nutztiere* 32, 157-168.
- Todhunter R.J., Lust G. (1990). Pathophysiology of synovitis - clinical signs and examination in horses. *Compendium on Continuing Education for the Practicing Veterinarian* 12, 980-992.
- van Grevenhof E.M., Schurink A., Ducro B.J., van Weeren P.R., van Tartwijk J.M., Bijma P., van Arendonk J.A. (2009). Genetic variables of various manifestations of osteochondrosis and their correlations between and within

- joints in Dutch warmblood horses. *Journal of Animal Science* 87, 1906-1912.
- van Hoogmoed L.M., Snyder J.R., Thomas H.L., Harmon F.A. (2003). Retrospective evaluation of equine prepurchase examinations performed 1991-2000. *Equine Veterinary Journal* 35, 375-381.
- Van Weeren P.R. (2006). Osteochondrosis. In: Auer J.A., Stick J.A. (editors). *Equine Surgery*. 3rd Ed., Elsevier Saunders, St. Louis, Mo., p. 1166-1178.
- Verwilghen D.R., Busoni V., Gangl M., Franck T., Lejeune J.P., Vanderheyden L., Detilleux J., Grulke S., Deberg M., Henrotin Y., Serteyn D. (2009a). Relationship between biochemical markers and radiographic scores in the evaluation of the osteoarticular status of Warmblood stallions. *Research in Veterinary Science* 87, 319-328.
- Verwilghen D.R., Vanderheyden L., Franck T., Busoni V., Enzerink E., Gangl M., Lejeune J.P., van Galen G., Grulke S., Serteyn D. (2009b). Variations of plasmatic concentrations of Insulin-like Growth Factor-I in post-pubescent horses affected with developmental osteochondral lesions. *Veterinary Research Communications*, 33, 701-709.
- Von Rechenberg B., Auer J.A. (2006). Subchondral cystic lesions. In: Auer J.A., Stick J.A. (editors). *Equine Surgery*. 3rd Ed., Elsevier Saunders, St. Louis, Mo., p. 1178-1184.
- Vos N.J. (2008). Incidence of osteochondrosis (dissecans) in Dutch Warmblood horses presented for prepurchase examination. *Irish Veterinary Journal* 61, 33-37.
- Walmsley J.P. (2003). The stifle. In: Ross M.W., Dyson S.J. (editors). *Diagnosis and Management of Lameness in the Horse*. 1st Ed., W. B. Saunders, Philadelphia, Pa., London, p. 455-470.
- Wittwer C., Hamann H., Rosenberger E., Distl O. (2006). Prevalence of osteochondrosis in the limb joints of south German coldblood horses. *Journal of Veterinary Medicine. A, Physiology, Pathology, Clinical Medicine* 53, 531-539.
- Wittwer C., Hamann H., Rosenberger E., Distl O. (2007). Genetic parameters for the prevalence of osteochondrosis in the limb joints of South German coldblood horses. *Journal of Animal Breeding and Genetics* 124, 302-307.

Uit het verleden

RUNDVEEPLAAG IN 810 N.C.

Toen Karel de Grote in 810 tegen de Saksen optrok, dit volk bijna uitmoordde en tot het uiterste vernederde, brak een verschrikkelijke runderplaag uit. Karels biograaf, Eginhardus (Einhard), schreef in zijn *Vita Caroli*: *Zo groot was tijdens deze legerexpeditie de pest van de runderen (boum pestilentia) dat bijna geen enkel rund in het hele leger overbleef, dat ze op een enkele na allen crepeerden. En niet alleen daar: ook in alle onderworpen provincies van de keizer heeft de sterfte bij de dieren van dit soort (illius generis) uiterst geweldig gewoed.*

Grote veroveringen gingen niet zelden gepaard met zware uitbraken van veeplagen. Zoals ook uit deze tekst blijkt, trokken de legers op samen met hele troepen levend vee in de legeretros om in hun bevoorrading te voorzien. In de veroverde gebieden bleven contacten met endemische ziekteagentia niet uit ...

Bij dit alles moet men bedenken dat dergelijke rundveeplagen dikwijls gevolgd werden door hongersnood, simpelweg omdat de trekossen van de landlieden stierven en de akkers niet goed meer konden bewerkt worden.

Naar Van Nieuwenhuyze, D. *Bronnen van de geschiedenis van de landbouw*, Ministerie van Landbouw, Brussel, 1993, deel 3, p. 333.

Luc Devriese