

Endoscopic Ultrasound Reduces Surgical Mediastinal Staging in Lung Cancer

A Randomized Trial

Kurt G. Tournoy¹, Frederic De Ryck¹, Lieve R. Vanwalleghem¹, Frank Vermassen¹, Marleen Praet¹, Joachim G. Aerts², Georges Van Maele³, and Jan P. van Meerbeeck¹

¹Long Oncologisch Netwerk Gent, Ghent University Hospital, Ghent, Belgium; ²Department of Respiratory Medicine, Amphia Hospital, Breda, The Netherlands; and ³Department of Medical Statistics, Ghent University Hospital, Ghent, Belgium

Rationale: Assessment of mediastinal lymph nodes is recommended in patients with non-small cell lung cancer without distant metastases. Linear transesophageal endoscopic ultrasound with real-time guided fine-needle aspiration (EUS-FNA) is a promising, nonsurgical tool for mediastinal staging.

Objectives: We conducted a randomized controlled trial comparing surgical staging with EUS-FNA.

Methods: Patients with proven or suspected non-small cell lung cancer in whom mediastinal exploration was required were randomly assigned to undergo EUS-FNA or the appropriate surgical staging procedure. When EUS-FNA did not show malignant lymph node invasion, a confirmatory surgical staging procedure was done. A negative surgical staging procedure was followed by thoracotomy with systematic lymph node sampling. The primary endpoint was the rate of surgical staging interventions. The secondary endpoints were test performance of EUS-FNA and surgical staging, morbidity, and length of hospital stay, considering surgical staging was performed as an in-patient procedure.

Measurements and Main Results: A total of 40 patients were randomized: 19 to EUS-FNA, and 21 to surgical mediastinal staging. Patient and tumor characteristics were well balanced between both groups. For patients allocated to EUS-FNA, surgical staging was needed in 32% ($P < 0.001$). The sensitivity to detect malignant lymph node invasion was 93% (95% confidence interval, 66–99%) for EUS-FNA and 73% (95% confidence interval, 39–93%) for surgical staging ($P = 0.29$). Complication rate was 0% for EUS-FNA and 5% for surgical staging ($P = 1.0$). The median hospital stay was significantly shorter for EUS-FNA than for surgical staging (0 vs. 2 nights; $P < 0.001$).

Conclusions: EUS-FNA reduces the need for surgical staging procedures in patients with (suspected) lung cancer in whom a mediastinal exploration is needed.

Clinical trial registered with www.clinicaltrials.gov (NCT 00119470).

Keywords: lung cancer; staging; mediastinoscopy; endoscopic ultrasound with fine-needle aspiration

In patients with non-small cell lung cancer (NSCLC) in whom there is no evidence for extrathoracic metastasis, assessment of the mediastinal lymph nodes for malignancy is of utmost importance (1–4). Mediastinal staging by surgical techniques (mainly cervical mediastinoscopy) is considered the gold standard (5, 6), although the sensitivity to detect malignant lymph node invasion was shown earlier to be only 81% (7). In addition, surgical staging is invasive, requires general anesthesia, and is subject to potential serious complications (8).

(Received in original form August 22, 2007; accepted in final form October 25, 2007)

Correspondence and requests for reprints should be addressed to Kurt Tournoy, M.D., Ph.D., Ghent University Hospital, Department of Respiratory Medicine, Building 7K12 I.E, De Pintelaan 185, 9000 Ghent, Belgium. E-mail: kurt.tournoy@ugent.be

Am J Respir Crit Care Med Vol 177, pp 531–535, 2008

Originally Published in Press as DOI: 10.1164/rccm.200708-1241OC on October 25, 2007
Internet address: www.atsjournals.org

AT A GLANCE COMMENTARY

Scientific Knowledge on the Subject

Patient series have suggested that endoscopic ultrasound with real-time guided fine-needle aspiration (EUS-FNA) could reduce surgical staging of the mediastinum in lung cancer. This has never been demonstrated prospectively with a randomized, controlled trial comparing EUS-FNA with the gold standard, surgical staging.

What This Study Adds to the Field

This randomized controlled trial shows that EUS-FNA reduces the need for surgery, but also indicates its limitations. The data implicate EUS-FNA can be used in staging guidelines.

Linear transesophageal endoscopic ultrasound with real-time guided fine-needle aspiration (EUS-FNA) is a promising, minimally invasive outpatient technique for the diagnosis and staging of mediastinal lymph nodes in patients with lung cancer. Prospective series show a high sensitivity (0.72–1.00) and specificity (1.00) in computed tomography and/or positron emission tomography (PET) scan-selected patients (9), document the advantage of rapid on site evaluation by a cytopathologist (10, 11), and suggest that EUS-FNA could eliminate the need for surgery in a substantial number of patients (12, 13).

We conducted a randomized, controlled trial comparing surgical mediastinal staging with EUS-FNA in patients with (suspected) NSCLC requiring mediastinal lymph node exploration. We compared the number of surgical staging procedures, hospital stay, number of lymph node stations assessed, complication rates, and test characteristics of both approaches.

METHODS

Patients

After approval of the study by the Medical Ethics Committee of the Ghent University Hospital (study no. ECP2004276) and after protocol registration (NCT 00119470), patients were recruited in December 2005 through January 2007 from the institutional thoracic oncology outpatient clinic. Consent to perform all procedures (including thoracotomy) in the Ghent University Hospital was required before screening. Eligible patients had proven or suspected NSCLC, and had a suspected mediastinal lymph node invasion based on computed tomography and/or fluorodeoxyglucose (FDG)-PET scan data. Our guidelines for invasive mediastinal exploration were enlarged (≥ 1 -cm short axis) mediastinal lymph nodes and/or FDG uptake in the mediastinal lymph nodes, tumors abutting the mediastinum regardless of FDG uptake in the lymph nodes, and absence of FDG uptake in the primary tumor (14, 15). In addition,

the tumor had to be resectable, and the patients had to be functionally operable. A multidisciplinary team approval preceded a possible inclusion. The selection criteria are shown in Table 1. Written informed consent was obtained from all patients before enrolment. The patients were randomly allocated between the following approaches: immediate surgical staging (arm A—gold standard) and EUS-FNA, followed by surgical staging in case of negative EUS-FNA result (arm B).

EUS-FNA

EUS-FNA was performed in an out-patient setting under local anesthesia (with or without moderate sedation) using the curved linear scanning ultrasound endoscope (GF-UCT160-OL5; Olympus, Aartselaar, Belgium) connected to the ultrasound unit (Aloka, Mechelen, Belgium) (10), with monitoring of heart rate and oxygen saturation (16). Punctures were performed with a 22-gauge fine needle (EUS-needle; Olympus). Smears of the aspirates obtained by EUS-FNA were processed on site to evaluate the cellular contents of the air-dried specimens with a quick-staining method (Diff-Quick; Medion Diagnostics, Düringen, Switzerland). If necessary, several lymph nodes were sampled. Specimens were categorized as positive (tumor cells), negative (lymphoid but no tumor cells), or not representative (necrosis, no lymphoid cells). Punctures were continued until the cytopathologist (L.R.V. or M.P.) was able to make a formal conclusion.

Surgical Staging

Surgical staging for mediastinal exploration included cervical mediastinoscopy, anterior mediastinotomy, video-assisted thoracoscopy, or explorative thoracotomy, and was performed by dedicated thoracic surgeons (F.D.R. or F.V.). The surgical technique for staging was determined according to the preceding multidisciplinary team meeting. For cervical mediastinoscopy, a systematic search of the lymph node stations 2R/L, 4R/L, and 7 was performed (1, 8) according to the Mountain-Dressler lymph node map (17). The sampled lymph nodes were separately collected and stored for histological analysis. According to local practice, all patients undergoing surgical staging had at least 1 night of postoperative observation.

Thoracotomy

In the case that no malignant lymph node invasion was shown with either surgical staging or EUS-FNA followed by surgical staging, the patient went for thoracotomy with systematic lymph node resampling within 2 weeks (3, 15).

Data Collection

Data were obtained by the study coordinator during the visit at baseline and at the time of subsequent intervention(s). Standardized evaluation forms recording demographic characteristics, technical investigations, and procedural characteristics, tumor and stage characteristics, and data regarding admission to the hospital were noted.

TABLE 1. SELECTION CRITERIA

Category	Description
Inclusion criteria	Patients with a histological or cytological proof of NSCLC or with a high clinical suspicion for lung cancer in whom the next step is a surgical technique (cervical mediastinoscopy, anterior mediastinotomy, thoracoscopy, or explorative thoracotomy) for mediastinal staging purposes. No distant metastasis after routine clinical work up (including optional FDG-PET scan)
Exclusion criteria	Contraindications for esophageal endoscopy (e.g., Zenker diverticle) Contraindications for surgery (irresectable tumor or inoperable patient) Former therapy for lung cancer or concurrent other malignancy

Definition of abbreviations: FDG = fluorodeoxyglucose; NSCLC = non-small cell lung cancer; PET = positron emission tomography.

Next, the data were transferred into an electronic database (Access; Microsoft, Inc., Redmond, WA).

Outcome Measures and Statistical Analysis

Randomization (1:1) was performed based on an automated assignment system generated before the study and only accessible by the involved data managers. A stratification based on lymph node size was applied to counter the possibility of lymph node size-dependent segregation in one study arm, as large lymph nodes (arbitrarily designated as having one axis of at least 2 cm) are technically easier to sample. The primary outcome measure was the number of surgical interventions in both study arms. A surgical procedure was considered avoided when it did not occur after allocation to the EUS-FNA arm. Calculation of the sample size was based on the estimated difference in the number of surgical interventions needed for invasive mediastinal staging. Inclusion of 20 patients in each arm was estimated to demonstrate a 40% absolute reduction of surgical interventions with the use of the Fisher's exact test (power, 80%; type 1 error, 5%; two-sided testing). The secondary outcome measures were: evaluation of test characteristics (sensitivity-specificity); complication rates; and length of hospital stay. All endpoints were analyzed in the intention-to-treat (or to-diagnose) population. For the analysis of the test characteristics, we took into account only those patients in whom a formal mediastinal pathology report was available. Continuous variables were compared using the Mann-Whitney U test or Student's *t* test, whereas categorical data were compared with Fisher's exact test. All data were analyzed with SPSS 15.0 (SPSS, Inc., Chicago, IL).

RESULTS

Enrollment and Baseline Characteristics of the Patients

We screened 44 patients, and 40 underwent randomization (Figure 1). The demographic and clinical characteristics of the patients in the two study groups were well balanced (Table 2). Imaging of the mediastinum suggested N2 disease in 29 (73%) and N3 in 11 (27%) subjects. PET data were available for 38 patients (95%), and suggested malignant lymph node invasion (FDG uptake) in 33 (83%). A total of 25 patients (63%) had proven NSCLC; in the others, there was a high clinical suspicion based on their presentation and imaging studies.

Procedural Characteristics and Tumor Data

The surgical technique for staging the lymph nodes was cervical mediastinoscopy in 20 patients and an anterior mediastinotomy in 1 patient for a solitary paraaortic lymph node (lymph node station 6) (Table 3). Both EUS-FNA and surgical staging procedures took about 35 minute to be completed. With EUS-FNA, it was possible to observe the primary tumor in about one-third of the cases, which was significantly more than with surgical staging. Significantly more lymph nodes were sampled with surgical techniques than with EUS-FNA.

The distribution of the primary lung tumor pathology shows that the majority of the patients had NSCLC (Table 3). However, four patients (10%) had small cell lung carcinoma. In one patient, thoracotomy after a negative mediastinal evaluation showed the presence of a benign schwannoma. The distribution of tumor histology was comparable between the two arms, as was the prevalence of malignant lymph node invasion.

Primary and Secondary Outcomes

The primary and secondary outcomes are summarized in Table 4. Surgical staging in the patients randomized to the EUS-FNA arm occurred in 32%. This reflects a reduction of 68% of surgical interventions for staging the mediastinum (primary endpoint, $P < 0.001$).

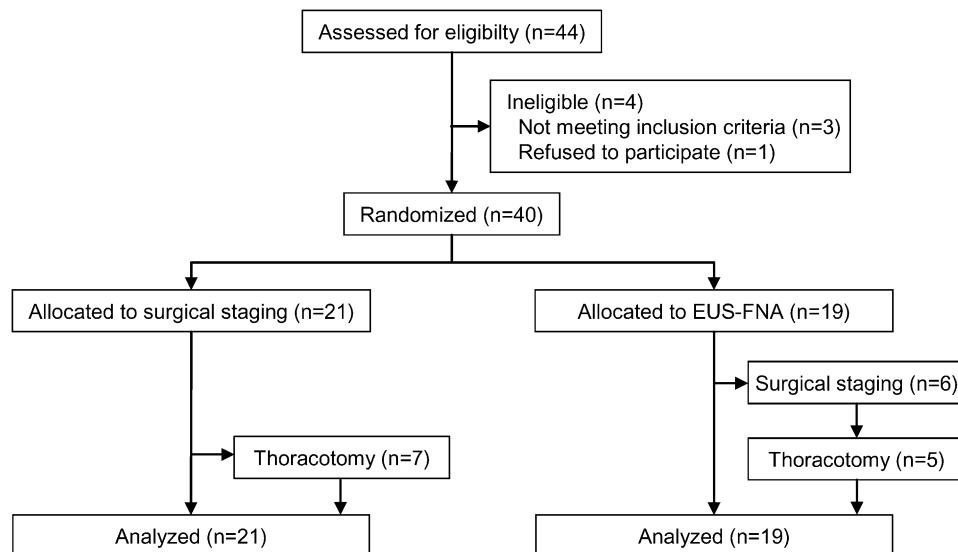


Figure 1. Study design—CONSORT (Consolidated Standards of Reporting Trials) diagram. Patients were randomly assigned and staged, as per protocol, with either a surgical technique or linear transesophageal endoscopic ultrasound with real-time guided fine-needle aspiration (EUS-FNA) followed by a surgical technique when EUS-FNA was reported negative.

No complications were noted in the patients investigated with EUS-FNA. In the patient group randomized for surgical staging, one esophageal perforation was noted. Other complications (e.g., infection or hoarseness) were not noted. Because EUS-FNA is performed under local anesthesia as an outpatient procedure, the length of hospital stay was significantly shorter as compared with surgical staging techniques, which require general anesthesia. The test characteristics were not different between the staging approaches (Table 5). When calculating the sensitivity of the surgical staging technique, also taking into account the six patients of the EUS-FNA study arm who underwent an additional surgical staging, the sensitivity becomes 75% (95% confidence interval, 42–94%), which is also not statistically different from the value obtained with EUS-FNA only (93%; 95% confidence interval, 66–99%).

DISCUSSION

This study shows that, in patients with (presumed) NSCLC without extrathoracic metastasis, in whom mediastinal lymph node exploration is required, EUS-FNA reduces the need for surgical staging procedures by two-thirds (68%). We consider this a relevant clinical benefit for the lung cancer patient, because implementation of EUS-FNA avoids the need for general anesthesia and the potential complications associated with surgical staging. At the time the current trial was designed (2004), some retrospective and prospective series already suggested a benefit of EUS-FNA for staging mediastinal lymph nodes in lung cancer (18, 19). Larger series have since been published, mainly focusing on the diagnostic performance of EUS-FNA in the staging of lung cancer (10, 12, 20). These studies invariably suggested a higher accuracy for EUS-FNA as compared with imaging techniques, and reported on the reduction in the number of surgical staging procedures. However, these studies all had similar flaws in their lack of comparison with the current standard of care (being surgical staging) (5, 6). These uncontrolled accuracy studies are important in the process of generating evidence of feasibility and effectiveness, but are, from a conceptual point of view, not suited to provide information on the difference between the gold standard and a new diagnostic technique (21). Randomized studies are therefore of importance to study advancing diagnostic techniques beyond the level of accuracy analyses. We are aware of only one published prospective, randomized trial in this field, comparing EUS-FNA

with “conventional” diagnostic workup of patients with NSCLC (22). The authors showed in their preliminary results that the patients investigated with EUS-FNA had less futile thoracotomies, the latter defined as explorative thoracotomy or recurrent disease after resection. However, the design of that study makes the interpretation of results difficult. Because the investigation technique was tailored to the patient despite randomization, EUS-FNA was performed in the majority of the patients. In

TABLE 2. DEMOGRAPHIC AND CLINICAL CHARACTERISTICS OF PATIENTS AT RANDOMIZATION

Variable	Surgical Staging (n = 21)	EUS-FNA (n = 19)	P Value
Sex, n (%)			0.60
Male	20 (95)	17 (89)	
Female	1 (5)	2 (11)	
Age, mean (range), yr*	61 (42–74)	67 (47–78)	0.06
PET-CT, n (%)	20 (95)	18 (95)	1.00
FDG-positive MLN, n (%)	18 (90)	15 (83)	0.65
T stage at registration†, n (%)			1.00
cT1	2 (10)	1 (5)	
cT2	16 (76)	16 (84)	
cT3	1 (5)	0 (0)	
cT4	2 (10)	2 (11)	
N stage at registration‡, n (%)			0.49
cN2	14 (67)	15 (79)	
cN3	7 (33)	4 (21)	
N size (stratification), n (%)			1.00
Small, <20 mm	11 (52)	9 (47)	
Large, ≥20 mm	10 (48)	10 (53)	
Aim of procedure, n (%)			0.10
Diagnosis and staging	5 (24)	10 (53)	
Staging only (known NSCLC)	16 (76)	9 (47)	

Definition of abbreviations: CT = computed tomography; EUS-FNA = linear transesophageal endoscopic ultrasound with real-time guided fine-needle aspiration; FDG = fluorodeoxyglucose; MLN = mediastinal lymph node; NSCLC = non-small cell lung cancer; PET = positron emission tomography.

* The difference between the mean age was compared with the Student’s t test.

† Compared with Fisher’s exact test for cT1–cT2 vs. cT3–cT4. Some values add up to 101% because of rounding.

‡ A mediastinal lymph node was considered suspect for invasion if its short axis was 10 mm or greater measured on the CT scan, or if it accumulated FDG on the PET-CT scan, regardless of its size. Mediastinal lymph nodes were also suspect if the primary tumor did not accumulate FDG, if the tumor was centrally located, or if hilar lymph nodes were FDG positive (see METHODS).

TABLE 3. DESCRIPTION OF THE STAGING PROCEDURES AND TUMOR AND LYMPH NODE CHARACTERISTICS

Characteristic	Surgical Staging (n = 21)	EUS-FNA (n = 19)	P Value
Type of surgical staging			1.00
Cervical mediastinoscopy	20 (95)	6 (100)	
Anterior mediastinotomy	1 (5)	0 (0)	
Procedure duration; median (range), min	35 (20–120)	35 (20–75)	0.61
T stage			0.04
Primary tumor observed, n (%)	1 (5)	6 (32)	
N stage			
No. of MLN seen; median (range)	NA	2 (1–4)	NA
Enlarged MLN with EUS, n (%) [*]	NA	18 (90)	NA
No. of MLN sampled, median (range) [†]	4 (1–5)	1 (1–3)	<0.0001
Cancer type [‡]			
Squamous cell	9 (45)	7 (37)	1.00 [§]
Nonsquamous	10 (50)	9 (47)	
Small cell	1 (5)	3 (16)	0.34
MLN status [¶]			
Malignant	11 (58)	14 (74)	0.50
Benign	8 (42)	5 (26)	
N2/N3	7/4	11/3	0.66

Definition of abbreviations: EUS/FNA = linear transesophageal endoscopic ultrasound with real-time guided fine-needle aspiration; MLN = mediastinal lymph node; NA = not applicable.

^{*} Defined as a short axis of at least 10 mm.

[†] MLN stations sampled for mediastinal staging (before thoracotomy)

[‡] Upon resection, one patient with presumed non-small cell lung cancer (NSCLC) had not a carcinoma, but a benign schwannoma.

[§] The distribution was comparable between squamous and nonsquamous lung cancers.

^{||} The distribution was comparable between NSCLC and small cell lung cancer.

[¶] Two patients had a negative mediastinoscopy, but underwent neither a thoracotomy, nor a systematic LN sampling. These patients were not taken into account here. In one patient in whom the surgical staging was negative, EUS-FNA instead of thoracotomy was performed, demonstrating NSCLC in MLN 4L.

addition, there are several methodological differences: EUS-FNA was variably performed under general anesthesia, and there was no on-site evaluation of the samples. The latter has been shown to be valuable for EUS-FNA, especially when performed by a dedicated cytopathologist (10, 11).

In the present study, patients were all candidates for radical surgery after a diagnostic work-up adhering to the available guidelines. Furthermore, and in contrast with previous series, the pathology assessment of the mediastinal lymph nodes was strictly defined. As such, we provide solid evidence that EUS-FNA should be implemented in the preoperative staging

TABLE 4. OUTCOMES OF ULTRASOUND AND SURGICAL STAGING: PRIMARY AND SECONDARY ENDPOINTS

Procedure Variable	Surgical Staging (n = 21)	EUS-FNA (n = 19)	P Value
Surgical staging procedure, n (%)			
No	0 (0)	13 (68)	<0.0001
Yes	21 (100)	6 (32)	
Complications, n (%) [*]			
Perforation/bleeding	1 (5)	0 (0)	1.00
Hospital stay, nights, median (range) [†]	2 (1–22)	0 (0–5)	<0.0001

For definition of abbreviations, see Table 3 footnote.

^{*} One esophageal perforation.

[†] Hospital stay for staging only. All patients staged with EUS-FNA as a single procedure were investigated as an outpatient procedure. The figure for the EUS-FNA arm includes the hospitalization for the subsequent surgical staging in case this was required.

TABLE 5. ANALYSIS OF TEST CHARACTERISTICS ACCORDING TO ALLOCATED APPROACH

Characteristics	Surgical Staging [*] (n = 19)	EUS-FNA (n = 19)	P Value
Sensitivity	73 (39–93)	93 (66–99)	0.29
Specificity	100 (69–100)	100 (47–100)	NA
Positive predictive value	100 (63–100)	100 (75–100)	NA
Negative predictive value	73 (39–93)	83 (35–99)	1.00

For definition of abbreviations, see Table 3 footnote.

^{*} Two patients had an unconfirmed negative mediastinoscopy and were not included in this analysis (see METHODS).

algorithm of patients with (presumed) lung cancer who have no evidence of extrathoracic metastasis. In addition, the current data show that the implementation of EUS-FNA in the staging algorithm of lung cancer results in less complications and a shorter hospital stay as compared with conventional staging. However, the latter statement might not be applicable when surgical staging is performed as an outpatient procedure (23–25).

No difference was found in the diagnostic performance between study arms. Although the sensitivity of rapid on-site examination-assisted EUS-FNA to detecting malignant lymph node invasion tended to be higher than that with surgical staging (10, 26), this difference was not statistically significant, even when taking into account the patients who underwent both procedures. Together, the present data are in agreement with the test characteristics that have been published for these techniques (7), and indicate that implementing EUS-FNA does not result in a lower sensitivity. The negative predictive value of EUS-FNA is too low to preclude further lymph node sampling in case of a negative result. This is in agreement with published data (12). The results of the present study do not allow a conclusion about the preferred diagnostic method in the case of negative EUS-FNA. Because it was shown, in a prospective series, that the combination of mediastinoscopy and EUS-FNA improves the sensitivity and negative predictive value (27), we opted to use a mediastinoscopy before referring the patient to thoracotomy. It is impossible to rule out false-positive findings either for EUS-FNA or for surgical staging procedures. This is related to the current study design. However, it seems reasonable to assume that the false-positive rate is low in mediastinal staging (6), although one study showed that sampling a left lower lobe tumor instead of a mediastinal lymph node might result in overstaging (27).

Another finding with potential implications is a difference in the completeness of mediastinal staging between the two studied techniques, as the number of sampled lymph nodes was significantly lower in the patients investigated only with EUS-FNA. This has to do with the anatomy of the mediastinum and the interposition of the trachea impeding the investigation of solitary lymph nodes located strictly in the lower right-sided paratracheal area (region 4R). A weakness of this study lies in EUS-FNA missing malignant N3 invasion whenever only N2 is shown. However, this has no implication for treatment allocation, as combination chemoradiotherapy, especially delivered concurrently, is the preferred treatment for locally advanced NSCLC, regardless of the level of mediastinal lymph node involvement (28). Moreover, even if one should consider surgery after induction chemotherapy for IIIA NSCLC, invasive restaging of the mediastinum is currently advocated. Remediastinoscopy has been shown to be inaccurate (29), which is an additional reason for assessing the mediastinum with minimally invasive techniques before any treatment is given.

Nevertheless, early data based on selected patients suggest that endobronchial ultrasound with real-time guided transbronchial needle aspiration could overcome the problem of incomplete mediastinal sampling (30–32). Whether the combination of this method and EUS-FNA will become an alternative for overcoming the aforementioned problem is currently under investigation (32, 33).

Based on the outcomes of this study, we conclude that EUS-FNA reduces the need for surgical staging procedures in patients with (suspected) lung cancer in whom a mediastinal exploration is needed. Therefore, we propose that, in these patients, the mediastinum should be first investigated with EUS-FNA, followed by surgical staging in the case of negative findings.

Conflict of Interest Statement: None of the authors has a financial relationship with a commercial entity that has an interest in the subject of this manuscript.

Acknowledgment: The authors wish to thank the patients who participated in this trial. We are grateful for the referring clinicians (J. Boie, K. Carron, S. Fieremans, M. Mallet, S. Marien, D. Ommeslagh, H. Ottervaere, A. van Boxem, J. Van Den Bergh). We also thank our data managers (F. Vandewalle and I. Derudder), nurses (Y. Loyaen, V. Vermont, B. De Burchgraeve and G. Van Severen) and lab technician (Y. Sturtewagen), whose contributions were very important.

References

- Catarino PA, Goldstraw P. The future in diagnosis and staging of lung cancer: surgical techniques. *Respiration* 2006;73:717–732.
- Hollings N, Shaw P. Diagnostic imaging of lung cancer. *Eur Respir J* 2002; 19:722–742.
- National Collaborating Centre for Acute Care. Clinical guideline 24. Lung cancer: the diagnosis and treatment of lung cancer [Internet]. London: National Institute for Clinical Excellence; 2005 [accessed 2007 Aug 20]. Available from: <http://www.nice.org.uk/CG024NICEguideline>
- American Thoracic Society; European Respiratory Society. Pretreatment evaluation of non-small-cell lung cancer. *Am J Respir Crit Care Med* 1997;156:320–332.
- Detterbeck FC, DeCamp MM Jr, Kohman LJ, Silvestri GA. Lung cancer: invasive staging: the guidelines. *Chest* 2003;123:1675–1755.
- Detterbeck FC, Jantz MA, Wallace MB, Vansteenkiste J, Silvestri GA; American College of Chest Physicians. Invasive mediastinal staging of lung cancer: ACCP evidence-based clinical practice guidelines, 2nd ed. *Chest* 2007;132:202S–220S.
- Tolosa EM, Harpole L, Detterbeck F, McCrory DC. Invasive staging of non-small cell lung cancer: a review of the current evidence. *Chest* 2003;123:157S–166S.
- Semik M, Netz B, Schmidt C, Scheld HH. Surgical exploration of the mediastinum: mediastinoscopy and intraoperative staging. *Lung Cancer* 2004;45:S55–S61.
- Herth FJ, Rabe KF, Gasparini S, Annema JT. Transbronchial and transoesophageal (ultrasound-guided) needle aspirations for the analysis of mediastinal lesions. *Eur Respir J* 2006;28:1264–1275.
- Tournoy KG, Praet MM, Van Maele G, van Meerbeeck JP. Esophageal endoscopic ultrasound with fine-needle aspiration with an on-site cytopathologist: high accuracy for the diagnosis of mediastinal lymphadenopathy. *Chest* 2005;128:3004–3009.
- Savoy AD, Raimondo M, Woodward TA, Noh K, Pungpapong S, Jones AD, Crook J, Wallace MB. Can endosonographers evaluate on-site cytologic adequacy? A comparison with cytotechnologists. *Gastrointest Endosc* 2007;65:953–957.
- Annema JT, Versteegh MI, Veselic M, Voigt P, Rabe KF. Endoscopic ultrasound-guided fine-needle aspiration in the diagnosis and staging of lung cancer and its impact on surgical staging. *J Clin Oncol* 2005; 23:8357–8361.
- Singh P, Camazine B, Jadhav Y, Gupta R, Mukhopadhyay P, Khan A, Reddy R, Zheng Q, Smith DD, Rhode R, et al. Endoscopic ultrasound as a first test for diagnosis and staging of lung cancer: a prospective study. *Am J Respir Crit Care Med* 2007;175:345–354.
- Gould MK, Kuschner WG, Rydzak CE, Maclean CC, Demas AN, Shigemitsu H, Chan JK, Owens DK. Test performance of positron emission tomography and computed tomography for mediastinal staging in patients with non-small-cell lung cancer: a meta-analysis. *Ann Intern Med* 2003;139:879–892.
- van Meerbeeck JP, Koning CC, Tjan-Heijnen VC, Boekema AG, Kaandorp CJ, Burgers JS. Guideline on “non-small cell lung carcinoma; staging and treatment” [in Dutch]. *Ned Tijdschr Geneesk* 2005;149:72–77.
- Kramer H, van Putten JW, Douma WR, Smidt AA, van Dullemen HM, Groen HJ. Technical description of endoscopic ultrasonography with fine-needle aspiration for the staging of lung cancer. *Respir Med* 2005;99:179–185.
- Mountain CF, Dresler CM. Regional lymph node classification for lung cancer staging. *Chest* 1997;111:1718–1723.
- Annema JT, Hoekstra OS, Smit EF, Veselic M, Versteegh MI, Rabe KF. Towards a minimally invasive staging strategy in NSCLC: analysis of PET positive mediastinal lesions by EUS-FNA. *Lung Cancer* 2004; 44:53–60.
- Kramer H, van Putten JW, Post WJ, van Dullemen HM, Bongaerts AH, Pruim J, Suurmeijer AJ, Klinkenberg TJ, Groen H, Groen HJ. Oesophageal endoscopic ultrasound with fine needle aspiration improves and simplifies the staging of lung cancer. *Thorax* 2004;59: 596–601.
- Eloubeidi MA, Cerfolio RJ, Chen VK, Desmond R, Syed S, Ojha B. Endoscopic ultrasound-guided fine needle aspiration of mediastinal lymph node in patients with suspected lung cancer after positron emission tomography and computed tomography scans. *Ann Thorac Surg* 2005;79:263–268.
- van Tinteren H, Hoekstra OS, Boers M. Do we need randomised trials to evaluate diagnostic procedures? *Eur J Nucl Med Mol Imaging* 2004;31:129–131.
- Larsen SS, Vilmann P, Krasnik M, Dirksen A, Clementsen P, Maltbaek N, Lassen U, Skov BG, Jacobsen GK. Endoscopic ultrasound guided biopsy performed routinely in lung cancer staging spares futile thoracotomies: preliminary results from a randomised clinical trial. *Lung Cancer* 2005;49:377–385.
- Cybulsky IJ, Bennett WF. Mediastinoscopy as a routine outpatient procedure. *Ann Thorac Surg* 1994;58:176–178.
- Vallieres E, Page A, Verdant A. Ambulatory mediastinoscopy and anterior mediastinotomy. *Ann Thorac Surg* 1991;52:1122–1126.
- Bonadies J, D’Agostino RS, Ruskis AF, Ponn RB. Outpatient mediastinoscopy. *J Thorac Cardiovasc Surg* 1993;106:686–688.
- Klapman JB, Logrono R, Dye CE, Waxman I. Clinical impact of on-site cytopathology interpretation on endoscopic ultrasound-guided fine needle aspiration. *Am J Gastroenterol* 2003;98:1289–1294.
- Annema JT, Versteegh MI, Veselic M, Welker L, Mauad T, Sont JK, Willems LN, Rabe KF. Endoscopic ultrasound added to mediastinoscopy for preoperative staging of patients with lung cancer. *JAMA* 2005;294:931–936.
- Robinson LA, Ruckdeschel JC, Wagner H Jr, Stevens CW. Treatment of non-small cell lung cancer stage IIIA. *Chest* 2007;132: 243S–265S.
- De Leyn P, Stroobants S, De Wever W, Lerut T, Coosemans W, Decker G, Naftoux P, Van Raemdonck D, Mortelmans L, Nackaerts K, et al. Prospective comparative study of integrated positron emission tomography-computed tomography scan compared with mediastinoscopy in the assessment of residual mediastinal lymph node disease after induction chemotherapy for mediastinoscopy-proven stage IIIA-N2 Non-small-cell lung cancer: a Leuven Lung Cancer Group study. *J Clin Oncol* 2006;24:3333–3339.
- Herth FJ, Eberhardt R, Vilmann P, Krasnik M, Ernst A. Real-time endobronchial ultrasound guided transbronchial needle aspiration for sampling mediastinal lymph nodes. *Thorax* 2006;61:795–798.
- Yasufuku K, Nakajima T, Motoori K, Sekine Y, Shibuya K, Hiroshima K, Fujisawa T. Comparison of endobronchial ultrasound, positron emission tomography, and CT for lymph node staging of lung cancer. *Chest* 2006;130:710–718.
- Herth FJ, Lunn W, Eberhardt R, Becker HD, Ernst A. Transbronchial versus transoesophageal ultrasound-guided aspiration of enlarged mediastinal lymph nodes. *Am J Respir Crit Care Med* 2005;171: 1164–1167.
- Vilmann P, Krasnik M, Larsen SS, Jacobsen GK, Clementsen P. Transoesophageal endoscopic ultrasound-guided fine-needle aspiration (EUS-FNA) and endobronchial ultrasound-guided transbronchial needle aspiration (EBUS-TBNA) biopsy: a combined approach in the evaluation of mediastinal lesions. *Endoscopy* 2005; 37:833–839.