

CARDIOLOGY FOR DUMMIES

Prof. dr. Gunther van Loon, DVM, PhD, Dipl ECEIM

Dept. of Large Animal Internal Medicine, Fac. of Veterinary Medicine, Ghent University,
Salisburylaan 133, B-9820 Merelbeke, Belgium

Abstract

Knowledge of cardiac anatomy and physiology is mandatory in order to understand normal cardiac function and cardiac disease. Although many similarities in cardiac anatomy and physiology exist with other species, a number of features are different in horses, such as the position of the heart in the thorax, high vagal tone and the ventricular depolarisation process. A thorough clinical exam is always a prerequisite for correct diagnosis and for selection of further diagnostic tools.

Keywords: cardiac function, physiology, auscultation, electrocardiography, clinical exam

Anatomy

The heart occupies a large portion of the cranial thorax and has an almost vertical position, whereby the atria are positioned dorsally and the ventricles ventrally. Nomenclature is somewhat confusing as the right heart is positioned rather cranially and the left heart more caudally. The caval veins and pulmonary veins enter the right and left atrium, and aorta and pulmonary artery leave the left and right ventricle dorsally. Due to the large size of all structures and vessels stenosis is rare in horses.

The heart acts as a large pump. Deoxygenated blood enters the right atrium and right ventricle and is ejected through the pulmonary arteries into the lungs. Pressure in this part of the circulation is low. Oxygenated blood from the lungs enters the left atrium and left ventricle and is pumped through the aorta into the systemic circulation. Pressure in this part of the circulation is high.

Electrical impulses and the equine electrocardiogram

The sinus node is the natural pacemaker of the heart as it generates all electrical impulses under normal conditions. From the sinus node the impulse spreads over the atria. Both atria, as well as the ventricles, act as a pseudo-synctium which means that they always depolarise 'as a whole'. After depolarisation of the atria, the impulse reaches the atrioventricular (AV) node, which is the only connection between atria and ventricles. Electrical conduction through the AV node is relatively slow and leads to a short 'pause' between atrial and ventricular depolarisation. From the AV node specialised conduction tissue (His – Purkinje system) transports the electrical impulse rapidly over the whole ventricular myocardium. This route of depolarisation results in the most efficient, rapid and organised ventricular contraction and produces a small and sharp QRS complex on the electrocardiogram (ECG). Any other route of electrical activation (e.g. premature beat) results in a broadening of the QRS complex because the myocardial cell-to-cell conduction is slower compared to the specialised conduction tissue.

The surface ECG reflects the electrical activity of the heart but artefacts (muscle artefacts, electrical interference,...) are frequently found and must be differentiated from the real cardiac activity. It is essential to realize that in horses the Purkinje fibre system is much more extended than in humans and small animals. Therefore, the equine QRS complex provides little or no information about heart size or the exact origin of an ectopic beat within the ventricular myocardium. Basically, it only provides information regarding heart rate and rhythm.

Simply spoken, there are 4 regions of interest, through which the electrical signal travels consecutively during one normal cardiac cycle. These regions are (1) sinus node, (2) atrial myocardium, (3) AV node and (4) ventricular myocardium. Only depolarisation of a large mass will result in a visible deflection on the ECG. This means that depolarisation (and even repolarisation) of atrial myocardium and also ventricular myocardium results in deflections on the surface ECG. The sinus node and AV node are too small for their depolarisation to be seen on the surface ECG.

Often the cardiac rhythm or rate is described referring to the site of origin of the impulses. A ventricular or supra-ventricular rhythm indicates that impulses originate from the ventricular myocardium or any tissue 'above' that, respectively. A sinus rhythm or atrial rhythm originates from the sinus node or the atrial myocardium, respectively. Sinus tachycardia, atrial tachycardia and ventricular tachycardia, or bradycardia, indicate a high, or low, heart rate coming from the sinus node, atrial myocardium or ventricular myocardium, respectively.

During a normal cardiac cycle, impulse formation starts at the sinus node which is not visible on the ECG. This impulse enters the atrial myocardium and depolarises both atria, producing a P wave on the surface ECG. This P wave is often bifid (or biphasic), especially at slow rates. After its spread over the atria, the electrical impulse enters the AV node. The slow AV node conduction produces a short time-delay between atrial and ventricular contraction, the isoelectric PQ segment. Once through the AV node, the electrical impulse is rapidly conducted over the His-Purkinje system to result in a massive, organised depolarisation of the ventricular myocardium, resulting in a QRS complex. Because of the large mass of the ventricles, also repolarisation is clearly seen on the ECG as a T wave. The T wave can be positive, negative or biphasic in normal horses. At high heart rates, the T wave will become opposite (positive) to the QRS complex. This means that T wave polarity may suddenly shift depending on heart rate.

Cardiac cycle

The cardiac cycle is divided into ventricular systole (contraction) and ventricular diastole (relaxation). The onset of ventricular systole is the onset of the QRS complex. Shortly after that, both ventricles start to contract. After the isovolumic contraction (whereby all valves are closed) semilunar valves (aortic and pulmonary valves) will open and ejection of blood into the large vessels occurs. At the end of systole, semilunar valves close which indicates the start of diastole. After a brief isovolumic relaxation phase, atrioventricular (AV) valves (mitral and tricuspid valves) open and ventricular filling starts. Ventricular filling is passive in early diastole. At the end of diastole, atrial contraction results in an extra, active ventricular filling. This additional filling of the ventricle results in a small amount of backflow towards the atria, thereby putting the AV valves in closed position before the onset of ventricular contraction.

Normal heart sounds

Heart sounds are generated by vibrations that occur during the cardiac cycle. In a normal horse two, three or four heart sounds can be heard. The first and second heart sound, which are heard in all horses, mark beginning and end of ventricular systole. In many animals a third heart sound can be heard shortly after the second. The fourth sound will be heard immediately before the first in many animals.

The first heart sound: S1

The first heart sound represents the beginning of ventricular systole and occurs shortly after the beginning of the QRS complex of the ECG. The sound, generally described as a 'Lub', has a relatively low frequency and is longer and louder than the second heart sound. It is generated by semilunar valve opening, motion of the ventricular walls and acceleration of blood into the great arteries. Occasionally, AV valve closure can contribute to the sound, but in normal animals the presystolic AV valve closure will be achieved by an appropriate atrial contraction.

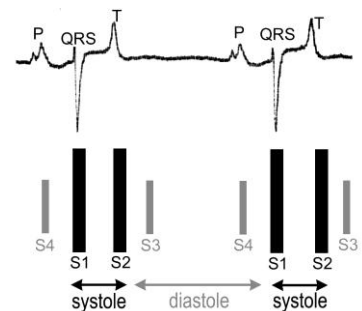
The first heart sound is loudest over the apex beat area on the left side of the chest. An increased intensity of the first heart sound may occur when the ventricles begin to contract while the AV valves are open, as during a ventricular premature contraction, atrial fibrillation or AV dissociation.

The second heart sound: S2

The second heart sound or 'Dup' is higher in frequency and shorter in duration than S1. It marks the end of ventricular systole and usually occurs shortly after the T wave of the ECG. It is produced by a sudden deceleration of blood in the great arteries just after semilunar valve closure. The second heart sound is best heard more dorsal and cranial to the apex beat, over the pulmonary and aortic valve area. Auscultation over the pulmonary valve area may reveal a splitting of S2 in many normal horses and occurs when there is a short delay between the closure of the aortic and pulmonary valves. The intensity of S2 may be reduced when stroke volume is reduced (e.g. ventricular premature contraction) or may be increased in pulmonary hypertension.

The third heart sound: S3

The third heart sound generally is low in frequency, quieter than S1 and S2 and occurs shortly after S2. It is best heard around the apex beat area, slightly ventral to the point of maximal intensity of S1 but is not present in all horses. The sound is produced by the deceleration of blood that occurs at the end of the rapid filling phase of the ventricles. S3 is often heard in fit athletic animals but the intensity of the sound varies at different heart rates. It is also loud in animals with left ventricular volume overload as a result of significant mitral valve regurgitation.



The fourth heart sound or atrial sound: S4

The fourth heart sound is heard immediately before S1 and is caused by the atrial contraction and presystolic AV valve closure. S4 is best heard cranial and dorsal to the apex beat. The fourth heart sound is often closely linked to S1 and is best heard at slow heart rates and long PQ intervals. S4 is most clearly heard during a period of second degree AV block, where it occurs in isolation. The atrial sound is absent in animals with atrial fibrillation.

Practical guide to auscultation

Auscultation is started on the left hemithorax at the location where the apex beat is best felt with the flat hand. This is the mitral valve area and here S1 is loud and S3 may be heard. Without losing contact with the skin the stethoscope is moved around the whole mitral valve area in all directions until S1 is no longer audible. The stethoscope is then advanced slightly dorsal and cranial. As we enter the area of the aortic valves, S2 becomes louder and the intensity of S1 decreases. After auscultation of the aortic valve area, the stethoscope is advanced slightly more cranial and ventral towards the pulmonary valve area. At the pulmonary valve area, S2 is at its loudest and a splitting of S2 may be present. Although cardiac sounds are more difficult to hear, right thoracic auscultation should always be performed. Cranial placement of the forelimb is necessary in most horses because the auscultation area of the tricuspid valve is located more cranial, in the third intercostal space, approximately midway between the level of the olecranon and the shoulder. Similarly, the stethoscope is moved over the whole area without losing contact with the chest wall.

Murmurs

Murmurs are protracted noises heard during a normally silent period of the cardiac cycle. Murmurs arise when blood flow becomes turbulent, causing vibration of cardiovascular structures. Turbulent flow occurs when blood flows at high velocity in wide tubes, as in the great arteries during the normal ejection phase. The murmur appears thus in a normal functioning heart as a result of a high flow during the ejection phase and is therefore called 'functional murmur', 'flow murmur' or 'ejection-type murmur'. Turbulent flows are also produced when blood flows through narrow orifices into wide channels, as occurs in valvular regurgitation or congenital deformation. These murmurs are caused by an abnormal situation and are called 'pathological murmurs'.

When a murmur is diagnosed, we first need to identify the source of the murmur and then assess its significance. We therefore need to classify murmurs based upon their timing and duration, location and radiation, intensity (1 to 6 scale) and character.

Functional, physiological or flow murmurs are not caused by an underlying cardiac disease. They are often present in young, athletic horses, especially Thoroughbreds. It should be noted that these murmurs often change in intensity depending on heart rate.

Up to 60% of normal horses presents an ejection-type murmur in early to mid-systole. These murmurs are usually crescendo-decrescendo and are low-graded (1-3/6). They are best heard on the left side of the chest over the semilunar valve area. Usually they finish before S2. Mild exercise often increases the intensity of the murmur. These murmurs can also be encountered in foals and in animals with colic, sepsis, fever or anaemia. In some animals the functional ejection murmur may occur later in systole or may be holosystolic, making it difficult to separate it from a murmur of mitral regurgitation. Early in diastole, between S2 and S3, a short murmur may be heard in some horses. The murmur may be soft and blowing or may be rather musical ('whoop'), especially in young horses. Although it is

often referred to as '2-year old squeak' it may occur at any age. This murmur can be heard from the left and right hemithorax and is believed to be associated with rapid ventricular filling. It may increase in intensity after mild exercise.

Late diastolic or presystolic murmurs are short, occur between S4 and S1 and may sometimes be difficult to distinguish from S4 and S1. The murmur can be heard at either side of the chest.

Clinical examination

Mucous membrane colour and capillary refill time should be assessed in all animals but are insensitive indicators of cardiac dysfunction. Animals with complex congenital malformations as tetralogy of Fallot, may present central cyanosis. Generally, only severe cardiac disease, such as congestive heart failure or endocarditis, will lead to overt clinical signs. Most animals, however, will present with mild clinical signs or poor performance, or even no clinical signs at all.

The arterial pulse should be palpated to assess rate, rhythm and quality. Pulses can usually be easily palpated from the facial artery. Pulse quality reflects the difference between systolic and diastolic pressures: this is the pulsation that we feel. A normal pulse is biphasic at normal heart rates in resting animals. Assessment of pulse quality is particularly useful in aortic regurgitation when it may become a strong but short lasting bounding pulse ('water-hammer pulse') if the condition is advanced. Pulse deficits may occur when there is a very short R-R interval as during a premature beat or atrial fibrillation.

Peripheral oedema (ventral abdomen, prepuce or sometimes the distal limbs) may be associated with congestive heart failure and indicates depressed *right* heart function. However, this is only occasionally seen in advanced stages and other potential causes should be ruled out (hypoproteinaemia, vasculitis, local venous or lymphatic obstruction). Acute *left-sided* heart failure may result in pulmonary oedema and, in severe cases, in frothy white or blood-tinged fluid at the nostrils. In most animals, however, and also in more chronic cases, lung auscultation will fail to reveal crackles.

The jugular vein acts as a manometer of central venous pressure (right atrial pressure). The higher the pressure in the right atrium the greater the vertical distance up the neck that the jugular veins are filled. It is essential to observe the jugular veins for distension or pulsation when the horse's head is in the normal upright position! Some pulsation of the vein is observed at the thoracic inlet in the normal horse.

In severe tricuspid regurgitation, the contraction of the ventricles ejects blood retrograde into the right atrium and the jugular vein and produces a pulsation in the jugular vein. During right-sided congestive heart failure, the vein is continuously distended rather than distended by pulsation. However, additional pulsation may be present owing to tricuspid valve regurgitation (which often accompanies the right-sided volume overload) or because of transmission of atrial contraction or carotid pulsation to the distended vein. During atrial fibrillation very long R-R intervals may occur whereby the jugular

veins show a passive filling. Only after a ventricular contraction the blood from the jugular veins will flow toward the heart and the vein collapses. This passive filling of the jugular veins should not be mistaken as a pathologic venous distension.

In cases of 3rd degree AV block, atria and ventricles are contracting independently. Atrial rate (usually 60-90/min) is higher than ventricular rate (usually less than 30/min). Long pauses may result in passive filling of the jugulars and rapid atrial contractions may result in pulsation. In addition, there are occasions that atria and ventricles contract simultaneously. At that moment, the tricuspid valve is closed (because of the stronger ventricular contraction) and the atria contract against this closed valve. The content of the atrium is forced in a retrograde fashion, resulting in a pulse wave in the jugular veins. These are called 'cannon waves'.

Conclusion

Profound understanding of cardiac morphology and physiology is essential to understand pathological disease processes. Detailed history and thorough clinical exam are mandatory. Cardiac auscultation should be performed meticulously paying special attention to the presence of a murmur or arrhythmia. A standardized approach and characterisation of auscultatory findings usually allows to make a diagnosis. Further fine-tuning of diagnosis and formulation of a prognosis is done by electrocardiography, ultrasound and blood exams.

References

- Blissitt, K.J. (1999). Auscultation. In *Cardiology of the horse*, Marr, C.M. (ed) pp. 73-92. Saunders: London.
- Bonagura, J.D. (1985). Equine heart disease. An overview. *Vet Clin North Am Equine Pract* **1**, 267-274.
- Marr, C.M. & Reef, V.B. (1995). Physiological valvular regurgitation in clinically normal young racehorses: prevalence and two-dimensional colour flow Doppler echocardiographic characteristics. *Equine Vet J Suppl*, 56-62.
- Patteson, M.W. (1996). *Equine cardiology*. Blackwell Science: Oxford.
- Reef, V.B. (1985). Evaluation of the equine cardiovascular system. *Vet Clin North Am Equine Pract* **1**, 275-288.