


# Accepted Manuscript

Emergencies after endoscopic procedures

Carla Rolanda, MD, PhD Ana C. Caetano, MD M<sup>2</sup> rio Dinis-Ribeiro, MD, PhD



PII: S1521-6918(13)00160-1

DOI: [10.1016/j.bpg.2013.08.012](https://doi.org/10.1016/j.bpg.2013.08.012)

Reference: YBEGA 1194

To appear in: *Best Practice & Research Clinical Gastroenterology*

Received Date: 14 July 2013

Revised Date: 25 July 2013

Accepted Date: 11 August 2013

Please cite this article as: Rolanda C, Caetano AC, Dinis-Ribeiro M, Emergencies after endoscopic procedures, *Best Practice & Research Clinical Gastroenterology* (2013), doi: 10.1016/j.bpg.2013.08.012.

This is a PDF file of an unedited manuscript that has been accepted for publication. As a service to our customers we are providing this early version of the manuscript. The manuscript will undergo copyediting, typesetting, and review of the resulting proof before it is published in its final form. Please note that during the production process errors may be discovered which could affect the content, and all legal disclaimers that apply to the journal pertain.

**EMERGENCIES AFTER ENDOSCOPIC PROCEDURES**

By

**Carla Rolanda, MD, PhD<sup>1,2,3</sup>; Ana C. Caetano, MD<sup>1,2,3</sup>; Mário Dinis-Ribeiro, MD, PhD<sup>4,5</sup>**<sup>1</sup> Department of Gastroenterology, Hospital Braga, Portugal.<sup>2</sup> Life and Health Sciences Research Institute (ICVS), School of Health Sciences, University of Minho, Braga, Portugal.<sup>3</sup> ICVS/3B's – PT Government Associate Laboratory, Braga/Guimarães, Portugal.<sup>4</sup> Portuguese Oncology Institute of Porto, Portugal.<sup>5</sup> CIDES/CINTESIS, Faculty of Medicine of University of Porto.**Corresponding author:**

Carla Rolanda, MD, PhD

Surgical Sciences Research Domain

Life and Health Sciences Research Institute (ICVS)

School of Health Sciences, University of Minho

Campus de Gualtar

4709-057 Braga, Portugal

Tel: +351 939912301; Email: [crolanda@ecsaude.uminho.pt](mailto:crolanda@ecsaude.uminho.pt)

**Abstract**

Endoscopy adverse events (AEs), or complications, are a rising concern on the quality of endoscopic care, given the technical advances and the crescent complexity of therapeutic procedures, over the entire gastrointestinal and bilio-pancreatic tract. In a small percentage, not established, there can be real emergency conditions, as perforation, severe bleeding, embolization or infection. Distinct variables interfere in its occurrence, although, the awareness of the operator for their potential, early recognition, and local organized facilities for immediate handling, makes all the difference in the subsequent outcome. This review outlines general AEs' frequencies, important predisposing factors and putative prophylactic measures for specific procedures (from conventional endoscopy to endoscopic cholangio-pancreatography and ultrasonography), with comprehensive approaches to the management of emergent bleeding and perforation.

**Keywords**

GI Endoscopy adverse events; GI emergencies; bleeding; haemorrhage; perforation; infection; embolization; diagnosis and management of severe complications.

## Introduction

Both patients and practitioners expect their endoscopy procedures go according to plan. However, for several reasons some patients experience complications or, as correctly mentioned, adverse events (AEs).<sup>1</sup> Even though there is substantial literature describing series of AEs, well-designed prospective trials and a standardized nomenclature with agreed-on definitions are lacking.<sup>1-3</sup>

Recently an AE was defined as a situation that prevents completion of the planned procedure and/or results in admission to hospital, prolongation of existing hospital stay, another procedure (needing sedation/anesthesia), or subsequent medical consultation. AEs are distinct from incidents, also unplanned events, but that do not interfere with completion of the procedure; an example of this includes bleeding that stops spontaneously or with endoscopic therapy during the procedure. Concerning the timing, AEs can occur pre-, intra- (from entering the preparation area through leaving the endoscopy room), post- (up to 14 days), and late-procedure (any time after 14 days, usually up to 30 days).<sup>1,2</sup>

In this manuscript, we will discuss emergent AEs after endoscopic procedures - serious and unexpected situations that demands immediate action. Although cardiopulmonary and sedation-related events account for more than 50% of the severe morbidity and mortality related to gastrointestinal (GI) endoscopy,<sup>4</sup> this document will focus only on major AEs related to endoscopic equipment direct harm, mainly hemorrhage, perforation, infection and embolization. Even though no sufficient consensus exists in most cases, we outlined the predisposing factors and putative prophylactic measures with comprehensive approaches to their management.

### **AEs during diagnostic vs therapeutic GI endoscopy**

Diagnostic GI endoscopy is generally safe. For upper GI endoscopy, the overall AEs and mortality rates were reported as 0,13% and 0,004% respectively, being 10 times higher for therapeutic interventions.<sup>5</sup> General AEs in diagnostic *colonoscopy* ranges from 0,02% to 0,07%.<sup>6</sup> See table 1 which summarizes the frequencies, described in literature, of severe/emergent AEs. Considering the main complications under discussion, although there is no question about the emergent character of perforation, we are not able to discriminate the real severity of hemorrhage rates reported in literature; this fact is even more remarkable when looking for infection and embolization as a result of its rarity.

Hemorrhage – is a rare in diagnostic procedures. In upper GI endoscopy, Mallory-Weiss tears cause bleeding in less than 0,5% when excessive retching and struggling occur, however those are not clinically significant.<sup>7</sup> Globally, it may be more likely in individuals with thrombocytopenia and/or coagulopathy. Therefore, some authors recommend that diagnostic endoscopy can be performed when the platelet level is 20000/ml or greater and that a threshold of 50000/ml should be considered before performing biopsies.<sup>3,8</sup>

Perforation – may occur in less than 0,04% of the diagnostic upper GI endoscopy, and is usually associated to operator inexperience and some patient-related risk factors, such as: cervical osteophytosis, Zenker's or duodenal diverticulum, pharyngeal pouches, malignant/benign strictures and eosinophilic esophagitis.<sup>9-12</sup> In colonoscopy the risk of perforation ranges from 0,11% in diagnostic, up to 10% in therapeutic procedures.<sup>6,13-15</sup> There are 3 main mechanisms for the occurrence: pneumatic/barotrauma, mechanical pressure, and post-therapeutic fragile wall. The patient-related risk factors contributing to perforation are well established and include: advanced age, female sex, diverticular disease, previous abdominal surgery, colonic strictures and therapeutic procedures.<sup>13,16</sup> The main location is the rectosigmoid in more than 2/3 of perforations.<sup>16,17</sup>

Infection – is a rare AE that can result from the procedure itself (translocation or failure to follow guidelines for the reprocessing) and the use of endoscopic devices and accessories. Transient bacteremia has been reported at high rates, but the frequency of endocarditis or other clinical infections is extremely low.<sup>18-20</sup> Antibiotic prophylactic regimens are only recommended for specific interventions and should be strictly followed: suspected incomplete

biliary drainage, puncture of fluid collections or cysts, percutaneous endoscopic feeding tube placement, and cirrhotic patients with upper GI bleeding.<sup>21</sup>

Embolization – is mainly related to specific therapeutic interventions. Variceal sclerosis may cause extension of thrombus into the portal and mesenteric venous systems<sup>22</sup> and cyanoacrylate injection has been reported as a cause of systemic emboli to lung, spleen and portal vein.<sup>23,24</sup> ERCP-induced air embolism is extremely rare although severe fatal complications, causing immediate cardiopulmonary collapse has been reported.<sup>25</sup>

### **Specific therapeutic procedures**

#### *Polypectomy*

The main AE in polypectomy is bleeding. Usually intra-procedure in gastric lesions, occurring in 3,4% to 7,2% and delayed in duodenum, reported in 3,1% to 22% of patients.<sup>2,26</sup> In colorectal polypectomy, bleeding occurs in 0,3% to 6,1%.<sup>27</sup> Evidence that aspirin or NSAIDs increase the risk of bleeding after polypectomy is lacking. The reader is referred to guidelines concerning the management of anticoagulation and antiagregant therapy during endoscopy.<sup>28</sup> The bleeding risk also depends on the type and the size of the polyp and the technique of polypectomy. Immediate bleeding can be prevented by the use of pure coagulation, epinephrine injection, clipping or endolooping the stalk, but no prophylactic measures have proved to be efficient in preventing delayed bleeding.<sup>5</sup>

#### *Endoscopic Mucosal Resection (EMR)/ Endoscopic Submucosal dissection (ESD)*

EMR (snare, cap, and ligature) is used to resect focal lesions of the mucosa up to the submucosal layer. The overall incidence of serious AEs such as bleeding, perforation and stricture was estimated to be between 0,5% and 5%.<sup>29</sup> Bleeding occurs more often with multifocal EMR and gastric EMR, however delayed bleeding is rare (<5%) in these locations comparing to duodenum which rate is between 4% to 33%.<sup>30</sup> It can be prevented by revision of the site of resection at the end of the procedure, coagulating any visible vessel, closing mucosal defects with clips and by therapy with proton pump inhibitor (PPI). Gastric EMR perforation is reported more frequently than in esophageal EMR, possibly because of greater lesions in the stomach.<sup>31</sup>

In ESD AEs are similar to those described for EMR, although with greater frequency given the larger areas of resection. The overall incidence of bleeding and perforation with ESD is 11%

and 6% respectively.<sup>32-34</sup> Due to the widespread acceptance of gastric and esophageal ESDs, the number of medical facilities that perform colorectal ESDs grew in recent years.<sup>35,36</sup> The reported rate of perforation is 1,4-10,4% which is associated with large tumor size (>30mm) and the presence of fibrosis. In order to reduce the perforation rate for colorectal ESD, the use of specialized knives, distal attachments and hypertonic solutions, are necessary because of the thinner colonic wall.<sup>35</sup>

### *Dilation*

The most common AEs related to dilation are perforation, haemorrhage, aspiration and bacteraemia. Aspiration of retained food and fluid can be an emergency, thus it should be prevented by prolonged fasting, suction, drainage, an anti-Trendelenburg position, or airway tube protection. Bleeding is usually self-limited. Despite the high frequency of bacteraemia, infectious sequelae are rare.<sup>37,38</sup> Thus, perforation is the most relevant AE in dilation.

In the esophagus, the risk of perforation in malignant, radiation-induced and post-caustic-ingestion strictures is twice that of peptic strictures. Complex strictures (asymmetric, longer, <12mm in diameter) are also associated with increased rates of complications.<sup>39</sup> Dilation of eosinophilic esophagitis is frequently associated with mucosal tears, but not perforation.<sup>40</sup> Although the wire-guided polyvinyl dilators and through-the-scope balloons have similar rates of efficacy and AEs, the operator's experience level alters significantly the perforation risk.<sup>9</sup> Stepwise increase of balloon diameter may help reducing the risk. In achalasia, perforation rates up to 4% were described for pneumatic dilation. These rates may be reduced by starting with a 30 mm balloon, progressing only if symptoms do not improve and never using a balloon larger than 35 mm.<sup>41</sup> Perforation rates in benign gastric outlet obstruction are high as 7,4%, risk factors are dilation in the setting of active ulceration and balloon size greater than 15 mm.<sup>42</sup> In lower gastrointestinal strictures' dilation, mostly in anastomosis and in Crohn's disease, the perforation is more often reported with 25 mm balloons.<sup>43,44</sup>

### *Stenting*

Stents can be deployed in any part of the GI tract and are currently used for malignant, benign stenosis, and closing fistulas.<sup>45</sup> Immediate AEs of esophageal self-expandable metal stents (SEMSs) occur in 2 to 12% of patients and include aspiration, pain, respiratory compromise and improper positioning. These AEs may be minimized by adequate patient preparation and positioning, familiarity with the stent, use of soft-tipped guide-wires, and avoidance of aggressive dilation.<sup>46</sup> Late AEs occur in 20 to 40% of patients: regurgitation when the gastroesophageal junction is bridged, occlusion, migration and perforation. The risk of late

perforation and bleeding seems to be higher with larger stents, although larger stents decrease the rate of migration and tumor ingrowth.<sup>47</sup> Pre-treatment with chemoradiotherapy was reported to increase the incidence of AEs by some authors, but not by others. Gastroduodenal stents are associated with similar AEs, and severe events as bleeding and perforation occur in 1 to 5% of patients.<sup>48,49</sup> Also colonic stents have similar particularities; they are applied in acute malignant obstruction as bridge to surgery, with an high rate of clinical (6,9%) and silent (14%) perforation,<sup>50</sup> and as long term palliation where perforation, and migration, have also been reported; bevacizumab therapy increases the risk of perforation in these cases.<sup>51</sup>

#### *Variceal ligation/sclerosis*

The overall AEs from endoscopic variceal sclerotherapy (EVS) have been estimated between 35% and 78%, with a mortality rate of 1 to 5%.<sup>52</sup> Significant immediate and delayed bleeding, stricture formation, perforation, systemic bacterial infection, or even portal thrombosis, were reported.<sup>53</sup> However, endoscopic band ligation (EBL) was progressively considered the treatment of choice, with significant lower rates of AEs.<sup>54,55</sup> Effective endoscopic treatment for gastric varices is still a sclerosant, properly the cyanoacrylate. Although considered relatively safe and effective, it is associated with systemic embolization, end-organ infarction, visceral fistula, abscess formation and bacteraemia.<sup>23,24</sup> Recent studies highlight only 1% rate of severe complications, as embolization.<sup>56</sup> It seems that the severity of AEs is related to pre-existing liver condition and infections complications.<sup>57</sup>

#### *Percutaneous endoscopic gastric and jejunal (PEG/PEJ) access*

Serious AEs occur in 1,5 to 9,4% of PEG procedures and include bleeding, injury of internal organs, perforation, “buried bumper syndrome”, wound infection, and necrotizing fasciitis.<sup>58</sup> Peristomal wound infections occur in 7 to 47% of patients receiving placebo in clinical trials, a single dose of cephalosporin or penicillin-based prophylaxis resulted in a significant reduction.<sup>59</sup> Pneumoperitoneum is a benign and frequent occurrence. Bleeding from gastric or abdominal wall vessels is reported in less than 1% of procedures, it is important to reverse or held anticoagulants before. Prevention of injury to internal organs may be best achieved by ensuring adequate transillumination and finger indentation, and by use of the “safe-tract” technique. AEs associated with PEJ are similar to those of standard PEG placement, although their rate is higher.<sup>60</sup>

#### *Ablation techniques*



Argon plasma coagulation (APC) is frequently used to treat vascular ectasia or for mucosal lesions ablation, as Barrett's esophagus. Randomized trials report up to 4% of bleeding, 2% of esophageal perforation and 6% of stricture formation in esophagus.<sup>61</sup> Colonic use of APC, can be associated with a rare but dreaded event - colon explosion - that may lead to perforation and emergency surgery. Meticulous full bowel cleansing with preparation without sugar compounds should be carried out before any APC in the colon.<sup>62</sup>

Radiofrequency ablation (RFA) of Barrett's epithelium has a relatively favourable profile. Bleeding requiring endoscopic therapy occur in less than 2% and strictures in 2 to 8%, perforation has also been reported.<sup>63,64</sup>

#### *Endoscopic submucosal tunnelling procedures*

Peroral Endoscopic Myotomy (POEM) and subepithelial lesions resection

Common described complications include subcutaneous and mediastinal emphysema, pneumothorax, pneumoperitoneum, immediate or delayed haemorrhage, and infection. Caution should be taken when implementing these techniques. There are no specific recommendations until now.<sup>65,66</sup>

#### **Enteroscopy**

Enteroscopy using double-balloon (DBE), single-balloon or spiral enteroscopy have the potential for unique AEs. A meta-analysis of 9047 DBE found major AEs in 0,7% (perforation, pancreatitis, bleeding).<sup>67</sup> The mechanisms of pancreatitis remain poorly understood, and the main way to prevent it is avoiding balloon inflation at duodenal level. The AEs rate is higher for therapeutic (4,3%) than for diagnostic DBE (0,8%). The rate of bleeding or perforation may be as high as 10,8% for patients undergoing polypectomy during DBE.<sup>67,68</sup>

#### **Endoscopic retrograde cholangiopancreatography (ERCP)**

ERCP is a demanding procedure associated with significant morbidity (6,85% of AEs) and occasional mortality (0,33%).<sup>69-71</sup> AEs can be divided into general (in common with upper GI endoscopy) and specifically related to bilio-pancreatic handling (bleeding, perforation, infection and pancreatitis). Factors modulating the risk of complications are the indication for ERCP and type of intervention, case-volume of operator, age and co-morbidities of the patient.<sup>72</sup> Pancreatitis is the most prevalent cause of morbidity and mortality after ERCP, but it will not be discussed in this issue.

Bleeding is mainly linked to sphincterotomy and in half of the cases is recognized immediately.<sup>69</sup> Clinically significant haemorrhage occurs in 0,1% to 2% of sphincterotomies. It

can be attenuated by identifying patients at risk and adapting the sphincterotomy technique, limiting pure-cut current, using endocut mode or balloon sphincteroplasty, according to situations.

Perforation occurs in 0,6% of procedures, with an estimated mortality rate of 0,06%,<sup>69</sup> however delayed diagnosis and intervention increase mortality up to 23%. The most commonly used classification of ERCP-induced perforation was suggested by Stapfer et al. according to that, perforations can be categorized into four types. Bowel perforation is more frequent in patients with Billroth II gastrectomy or Roux-en-Y operation, duodenal stricture, parapapilar diverticulum, while sphincterotomy perforation is more common during needle knife precut.<sup>25,73</sup> It can be prevented by ensuring the correct orientation of the cutting wire during sphincterotomy, following a step-by-step incision, tailoring the size of the papilla and bile ducts, and using balloon dilation of the papilla after a small sphincterotomy in cases of large stones.<sup>5</sup>

Cholangitis and cholecystitis are potential infectious AEs. Risk factors for cholangitis are failed or incomplete biliary drainage or combined percutaneous-endoscopic procedures.<sup>70</sup> Prophylactic antibiotics can reduce the rate of bacteraemia but few studies showed a reduction in clinical sepsis.<sup>74</sup> Therefore the main recommendation regarding prevention and treatment of cholangitis is successful and complete biliary drainage. Post-ERCP acute cholecystitis has an incidence rate of <0,5% and can be related to the non-sterile introduction of contrast medium. The use of cleaned and disinfected scopes, sterile contrast medium and temporary bile duct drainage when definitive drainage cannot be achieved are required. Antibiotic prophylaxis has proven to be effective in patients at risk for infective endocarditis, in patients with pancreatic pseudocyst and in patients with cholestasis or enlarged bile ducts.<sup>5</sup> ERCP-induced air embolism is a rare but severe complication<sup>25</sup> that possibly occurs due to sphincterotomy or high intra-mural pressure of insufflated air, disrupting the gastrointestinal or hepatobiliary structure and creating connection to the veins in the duodenal walls. Other reported mechanisms include portal vein puncture due to guide-wire cannulation and erroneous placement of nasobiliary drainage tube to the portal vein.<sup>75,76</sup> Special care should be taken for possible air embolism in relation to the recent wide application of peroral cholangioscopy.<sup>77</sup> Other potential very rare complications are splenic injury, hepatic hematoma, pneumothorax and basket impaction.<sup>25</sup>

### **Endoscopic ultrasound (EUS)**

The non-interventional diagnostic EUS AEs rate of 0,03% to 0,15% is comparable to that of upper GI diagnostic endoscopy. Although due to specific mechanical and optical properties of

echoendoscopes, the risk of esophageal or duodenal perforation seems somewhat higher. Patients undergoing EUS-fine needle biopsy (EUS-FNB) are approximately ten times more likely to develop AEs.<sup>78</sup> In a recent systematic review the overall complication rate and mortality was 0.98% and 0,02% respectively. Significant AEs were acute pancreatitis (34%), fever and infectious complications (16%), bleeding (13%) and perforation or bile/pancreatic leaks (3%). Serious infections were described in published reports following biopsy of mediastinal lymph nodes, cystic lesions, ascitis or pleural fluid.<sup>78</sup> Antibiotic prophylaxis should be administered in patients undergoing EUS-FNB of cystic lesions and fluid collections.<sup>79</sup> Self-limited mild intraluminal bleeding was reported in up to 4% and extraluminal bleeding in 1,3% of cases, the last can be visualized clearly by EUS.<sup>80</sup> Patients with highly vascularized lesions (mesenchymal, neuroendocrine tumors, and some metastases) and cystic lesions may be at greater risk.<sup>78</sup> According to guidelines, EUS-FNB of solid masses and lymph nodes may be performed in patients taking acetyl salicylic acid (ASA) or NSAIDs, but not in patients receiving other anticoagulant or antiagregant drugs. However, EUS-FNB of cystic lesions should be avoided in patients taking any antiplatelet agent.<sup>28,81</sup>

At this moment, EUS is an increasing reference for a range of therapeutic procedures with specific complications risk, as drainage of pancreatic pseudocysts, abscess and necrosis debridement,<sup>82,83</sup> celiac plexus neurolysis,<sup>84</sup> biliary drainage,<sup>85</sup> or even research vascular procedures.<sup>86</sup>

### **Detection and management of the two main emergencies**

#### Hemorrhage

Bleeding during therapeutic endoscopy can be part of the procedure, especially during polypectomies, EMR or ESD.<sup>5</sup> Immediate and late bleeding (by definition is hematemesis and/or melena or hemoglobin drop  $>2 \text{ g}^1$ ) can be controlled with conventional hemostatic tools (figure 1), under simultaneous attention to resuscitation and conservative management. Reader is referred to the chapter of acute non-variceal bleeding in this volume.

Patients with upper GI resection of tumoral lesions should be treated with intravenous PPI as for Forrest IIa ulcers:<sup>5</sup> High-dose PPI therapy improves healing rates and reduces the risk of delayed bleeding.<sup>33</sup> There are small successful series of over-the-scope-clips (OTSC) use in acute GI bleeding unresponsive to conventional methods, which is becoming a consistent approach.<sup>87</sup> The hemospray, a highly absorbent powder that when in contact with blood becomes cohesive and forms a stable mechanical plug, is also a promising hemostatic agent as demonstrated in early studies.<sup>88</sup>

Also in post-sphincterotomy bleeding, the first line treatment is injection of dilute epinephrine. Ballon-tamponade using standard dilating balloons for temporary control of bleeding and improve visualization of the bleeding point. Thermal therapy or placement of clips can follow the initial measures. Caution should be taken to avoid thermal injury or clip closure over the pancreatic sphincter.<sup>74</sup> Self-expandable metal stents have also been used as a rescue technique if other methods fail.<sup>89</sup> Very rarely, angiography or surgery is required for refractory bleeding.

### Perforation

Luminal perforation still is the most feared AEs of GI endoscopy, even after some advances and demystification brought by natural orifices transluminal endoscopic surgery (NOTES). The rationale for that is multifactorial.<sup>1,90</sup> A recent review by Baron et al. pointed out some main commandments of acute endoscopic perforation: 1) prompt recognition (preferably during the procedure) is essential to improve outcome; 2) extraluminal air does not automatically mean the need for surgery as it is not infectious and is not necessarily proportional to the size of the perforation; 3) extraluminal air under pressure is a medical emergency; 4) residual extraluminal air may persist without clinical significance; 5) perforations tend to close after drainage or diversion of luminal contents; 6) failed endoscopic closure generally requires surgical intervention.

### *General approach*

In therapeutic procedures is very important a final careful examination, in this case diagnosis or suspicious is frequently immediate and allows prompt closure attempt. In certain circumstances symptoms may be masked, as in sedated or elderly patients with multiple comorbidities, small perforations, or in case of transmural burn syndrome with progressive wall fragility. Whenever there is a clinical deterioration hours after an endoscopic procedure, delayed perforation should be considered. Late recognition may be from 1 hour to several weeks later. Clinical suspicious should be heightened in the presence of ongoing abdominal distension/pain, chest pain, shortness of breath, subcutaneous emphysema or fever.<sup>91</sup> Once suspected, besides closure attempt, immediate general measures should take place, as administration of intravenous broad-spectrum antibiotics, vital signs motorization, blood tests, surgeon contact and counseling, placement of a nasogastric tube (except in esophageal perforation, because it may exit the perforated site), and cessation of oral intake. At the same time, if periprocedure perforation, switch as much as possible to CO<sub>2</sub> insufflation. If perforation is suspected later, an initial imaging assessment should include a chest and

flat/upright abdominal radiography, if unrevealing computerized tomography CT with water-soluble contrast (orally, via nasogastric or nasoduodenal tube, or per rectum) may show contained or free contrast material extravasation. Endoscopic closure should then be attempted if feasible (figures 2 and 3).<sup>5,90,92</sup>

An essential and lifesaving attitude is emergent decompression when extraluminal air is under pressure. Tension pneumothorax requires immediate needle catheter inserted along the midclavicular line in the second intercostal space of the affected side. Then a chest tube should be placed. Subcutaneous emphysema usually resolve spontaneously, however attention should be given when massive air is tracking into soft tissues of the neck as it can result in airway obstruction, needing endotracheal intubation. Avoid abdominal compartment syndrome (drop in blood-pressure levels, related to a decreased cardiac preload caused by peritoneal hypertension) in tension pneumoperitoneum, with a 18 or 20 gauge trocar needle in either lower abdominal quadrants, just at or inferior to the umbilicus. The needle should be removed but the plastic sheath is left in situ to allow continuous decompression of the peritoneal cavity, while the procedure resumes and endoscopic intervention is ongoing even under air insufflation (figure 4).<sup>5,90,93</sup>

#### *Endoscopic closure methods*

Endoscopic closure methods include clips, stents and suturing devices. Its selection relies on defect location, dimension and conformation, occurrence situation, equipment availability and operator preference. Through-the-scope endoclips (QuickClip - Olympus®, Resolution Clip – Boston Scientific®, Tri-clip – Cook Medical®) are the most used and currently the standard method for endoscopic closure of perforations.<sup>94</sup> It has been suggested that for defects smaller than the width of the open clip it should be clipped in a “side to center” manner; when the defect is slightly larger than the width of the open clip, the diameter can be reduced by air suction. In case of large defects, the first clip is the most critical and a recent proposal for certain cases is to perform small incisions around to provide a better grip for the clip.<sup>95</sup> Combined methods are also a good approach for larger defects, for instances, hemoclips plus Endoloop,<sup>96,97</sup> plus omental patch<sup>93</sup> or plus band ligation.<sup>98</sup> OTSC system, initially developed for hemostasis, but extensively explored for ‘otomies’ closure in NOTES<sup>99</sup> are ultimately applied in perforation’s closure, using or not specific grasping or anchoring devices to approximate margins before clip release. Stents are an alternative method (fully or partially covered metal stents and plastic stents) for luminal diversion, mainly in esophageal malignant rupture. Stents can also be used in benign perforation, and removed 4 to 12 weeks later. Several endoscopic

suturing prototypes were developed in the context of NOTES, anti-reflux and bariatric procedures<sup>90,100</sup> namely: T-tags (Ethicon endo-Surgery and Cook Endoscopy), Overstitch (Apollo Endosurgery), pursed-string-suturing device (LSI Solutions), flexible endostitch (Covidien), NDO plicator (NDOSurgicalInc), flexible stapler (Power Medical Interventions), nevertheless its application remains limited in humans, and some of them only tested in animal models.

#### *Location particularities*

In *esophagus*, non-surgical treatment is indicated only in highly well selected.<sup>101</sup> Primary repair is feasible if without intrinsic esophageal disease, absence of sepsis, and especially when the time interval is less than 24h.<sup>102</sup> Endoscopic stenting represents a successful treatment option in perforated non-resectable esophageal malignancy. In cases of benign rupture, the stent placement for a period of 5-6 weeks is effective in 76% of patients, with no significant difference between stents.<sup>103</sup> Nevertheless, complication rate can be as high as 20 to 72%, thus the stent choice should depend on expected risk of stent migration (mostly with fully covered SEMs, and less frequent in presence of any stricture) and to a minor degree, on expected risk of tissue in- or overgrowth (mostly with partially covered SMESs). In this situation a fully covered stent of the same diameter can be placed inside (stent-in-stent method) allowing uneventful removal of both after 10-14 days. This can also be precluded with the initial application of large diameters fully covered stents (22-23 in the body).<sup>103</sup> Finally, standard through-the-scope clips are successful in the closure of perforations up to 12 mm, in a pooled analysis where the median healing time was 18 days.<sup>104</sup> Vacuum-assisted therapy is also a possible technique.<sup>105</sup> OTSC brings technical difficulties in esophageal application because of narrow lumen and oblique orientation.<sup>106</sup>

In *gastric* perforations, the main closure approach is endocliping alone or in combination, which can achieve 98% of success if immediate diagnosis.<sup>93</sup> Shi et al. described a new combination technique of metallic clips and endoloops as interrupted suture after endoscopic full-thickness resection of gastric submucosal tumors in 20 patients;<sup>97</sup> when the defect is large (25 mm) it can as well be managed by the omental-patch method or the OTSC system.<sup>93,106</sup>

In ERCP-related *duodenal* perforations, different approaches are made according to the type and the severity of the leak and clinical manifestations.<sup>107</sup> In type I and type II perforations, surgical treatment was generally recommended, although recent successful reports of endoscopic closure with endoclips,<sup>108</sup> combined clips and endoloops or OTSC were published;<sup>109</sup> particularly in type II perforations, self-expandable metal stents seems to be effective.<sup>110</sup> Type III and IV perforations tend to be a controlled retroperitoneal perforation; in case of leak with fluid collection, the recognizing and quick plastic stents placing for

appropriate drainage, associated with antibiotics are essential.<sup>107</sup> In retroperitoneal perforations, 87.9% of patients recovered with conservative treatment (total mortality was 2.9%), and 80.8% of patients with free air peritoneal perforations received surgery (total mortality was 24.7%).

*Small bowel* enteroscopy related perforations often lead to surgical management.

In *colon* perforations, endoscopic closure in association with conservative management is successful in 60-100% of patients, avoiding the morbidity of surgery and shortening the length of hospital stay, provided that perforation is immediately recognized and closed. Initial series showed success with endoclips for small perforations,<sup>111,112</sup> in absence of peritoneal irritation. Subsequently also diagnostic, large perforations, in the presence of free air or moderately inflammatory signs, were also successfully treated with multiple clipping, OTSC or even band ligation.<sup>90</sup> Bowel preparation status is in general an important factor that may influence clinical management. In delayed recognition, clipping should be considered only if the patient is stable and a specific site is highly suspected, mainly in rectosigmoid location.<sup>112</sup> When comparing therapeutic and diagnostic colonoscopy-associated perforation, the former are usually larger, irregular and sometimes not immediately recognized in terms of location, thus they are more prompt for surgical approach.<sup>113</sup> Surgery is indicated in patients with large perforations, generalized peritonitis or ongoing sepsis as well as in patients with concomitant pathology, such as a large sessile polyp likely to be a carcinoma, unremitting colitis, or obstructing colonic lesion. Although rare, extraperitoneal colonic perforation (subcutaneous emphysema, pneumoretroperitoneum, pneumomediastinum, pneumopericardium) should be managed conservatively, and the air is commonly reabsorbed within 72 hours.<sup>114</sup> In rectum, located below the peritoneal reflection air leakage can develop through next or distal soft tissues. Penetration to perirectal tissue is a better designation and is treated with broad spectrum antibiotics and nothing by mouth even though endoscopic clips can also be applied.<sup>90</sup>

In all these cases a coordinated surveillance by the surgical and medical team is essential in the first 48 hours. In case of no improvement or any sign of deterioration, surgery should be considered in a case-by-case decision.

**Conclusion**

Endoscopic complications are a pertinent feature of patient care that has been receiving great attention, due to increased technical advances and complexity of therapeutic endoscopy. Three main factors contribute to endoscopic adverse events - patient, operator, and type of procedure. Thus a comprehensive knowledge of the techniques and materials, experience acquisition and maintenance in specific procedures, standardization of treatments and training are important issues for prevention of AEs. When facing an AE, early recognition and prompt approach by endoscopic or multidisciplinary management, are essential for a successful outcome. No rule suits all, hence endoscopic complication approach must be customized to individual patients.

**Practice points**

- Adverse event (AE) is a situation that prevents completion of the planned procedure.
- Be prepared for the endoscopic procedure and furthermore its possible AEs – theoretical knowledge, equipment, team, and environment conditions.
- According to indications prevent infection and bleeding risk.
- Early recognition is a determining factor of the general outcome results.
- Bleeding (early and delayed) is usually controlled by endoscopic hemostasis.
- In perforation, an endoscopic plus conservative treatment, under multidisciplinary surveillance should always be attempted, if possible.
- Emergent needle decompression is an essential and lifesaving attitude when extraluminal air is under tension.
- Review AEs as part of continuing quality improvement.

**Research agenda**

- Multicenter studies to define associated risk factors of AEs for each newly-introduced procedure.
- Comparative studies between the newly appearing tools for hemostasis and closure.
- Effective, user-friendly and cheaper suture devices for endoscopy.
- Safer tools for endoluminal dissection (knives and coagulation graspers).
- Increment biodegradable tools - protective plug, spray and stents.
- Image fusion systems for safer approach in more aggressive procedures.



**Disclosure Statement**

Regarding this manuscript - "EMERGENCIES AFTER ENDOSCOPIC PROCEDURES" - none of the authors (Carla Rolanda, Ana C. Caetano e Mário Dinis-Ribeiro) have any disclosures to make.

**Legends**

**Table 1.** Available frequencies of severe/emergent AEs (%).

ESD – endoscopic submucosal dissection; APC – argon plasma coagulation; RFA – radiofrequency; FNB – fine needle biopsy. \*Infection – rates resolved under adequate antibiotic prophylaxis for specific procedures.

**Figure 1.** Management of post-endoscopic procedures' bleeding.

**Figure 2.** Management of upper GI perforations

(Adapted from Blero D, Devière J. Nat Rev Gastroenterol Hepatol. 2012)

**Figure 3.** Management of lower GI perforations

(Adapted from Blero D, Devière J. Nat Rev Gastroenterol Hepatol. 2012)

**Figure 4.** Acute decompression of tension pneumothorax and pneumoperitoneum.

## Bibliography

1. Cotton PB, Eisen GM, Aabakken L, Baron TH, Hutter MM, Jacobson BC, Mergener K et al. A lexicon for endoscopic adverse events: report of an ASGE workshop. *Gastrointest Endosc.* 2010;71(3):446-454.
2. Cotton PB, Eisen G, Romagnuolo J, Vargo J, Baron T, Tarnasky P, Schutz S [http://www.ncbi.nlm.nih.gov/pubmed?term=Jacobson%20B%5BAuthor%5D&cauthor=true&cauthor\\_uid=21377673](http://www.ncbi.nlm.nih.gov/pubmed?term=Jacobson%20B%5BAuthor%5D&cauthor=true&cauthor_uid=21377673) et al. Grading the complexity of endoscopic procedures: results of an ASGE working party. *Gastrointest Endosc.* 2011;73(5):868-974.
3. ASGE Standards of Practice Committee. Adverse events of upper GI endoscopy. *Gastrointest Endosc.* 2012;76(4):707-718.
4. Sharma VK, Nguyen CC, Crowell MD et al. A national study of cardiopulmonary unplanned events after GI endoscopy. *Gastrointest Endosc.* 2007 Jul;66(1):27-34.
5. Blero D, Devière J. Endoscopic complications--avoidance and management. *Nat Rev Gastroenterol Hepatol.* 2012;9(3):162-172.
6. Bowles CJ, Leicester R, Romaya C et al. A prospective study of colonoscopy practice in the UK today: are we adequately prepared for national colorectal cancer screening tomorrow? *Gut.* 2004;53(2):277-283.
7. Montalvo RD, Lee M. Retrospective analysis of iatrogenic Mallory-Weiss tears occurring during upper gastrointestinal endoscopy. *Hepatology.* 1996;43(7):174-177.
8. Van Os EC, Kamath PS, Gostout CJ et al. Gastroenterological procedures among patients with disorders of hemostasis: evaluation and management recommendations. *Gastrointest Endosc.* 1999;50(4):536-543.
9. Quine MA, Bell GD, McCloy RF et al. Prospective audit of upper gastrointestinal endoscopy in two regions of England: safety, staffing, and sedation methods. *Gut.* 1995;36(3):462-467.
10. Straumann A, Bussmann C, Zuber M et al. Eosinophilic esophagitis: analysis of food impaction and perforation in 251 adolescent and adult patients. *Clin Gastroenterol Hepatol.* 2008;6(5):598-600.
11. Vogel SB, Rout WR, Martin TD et al. Esophageal perforation in adults: aggressive, conservative treatment lowers morbidity and mortality. *Ann Surg.* 2005;241(6):1016-1021.
12. Abbas G, Schuchert MJ, Pettiford BL, Pennathur A, Landreneau J, Landreneau J, Luketich JD et al. Contemporaneous management of esophageal perforation. *Surgery.* 2009;146(4):749-755.
13. Lohsiriwat V. Colonoscopic perforation: incidence, risk factors, management and outcome. *World J Gastroenterol.* 2010;16(4):425-430.
14. Yoshida N, Yagi N, Naito Y et al. Safe procedure in endoscopic submucosal dissection for colorectal tumors focused on preventing complications. *World J Gastroenterol.* 2010;16(14):1688-1695.
15. Stock C, Ihle P, Sieg A et al. Adverse events requiring hospitalization within 30 days after outpatient screening and nonscreening colonoscopies. *Gastrointest Endosc.* 2013;77(3):419-429.
16. Tam MS, Abbas MA. Perforation following colorectal endoscopy: what happens beyond the endoscopy suite? *Perm J.* 2013;17(2):17-21.
17. Garbay JR, Suc B, Rotman N et al. Multicentre study of surgical complications of colonoscopy. *Br J Surg.* 1996;83(1):42-44.
18. ASGE Quality Assurance In Endoscopy Committee. Multisociety guideline on reprocessing flexible gastrointestinal endoscopes: 2011. *Gastrointest Endosc.* 2011;73(6):1075-1084.
19. Nelson DB. Infectious disease complications of GI endoscopy: part II, exogenous infections. *Gastrointest Endosc.* 2003;57(6):695-711.

20. Nelson DB. Infectious disease complications of GI endoscopy: Part I, endogenous infections. *Gastrointest Endosc.* 2003;57(4):546-556.
21. Endoscopy Committee of the British Society of Gastroenterology. Antibiotic prophylaxis in gastrointestinal endoscopy. *Gut.* 2009;58(6):869-880.
22. Deboever G, Elegeert I, Defloor E. Portal and mesenteric venous thrombosis after endoscopic injection sclerotherapy. *Am J Gastroenterol.* 1989;84(10):1336-1337.
23. Alexander S, Korman MG, Sievert W. Cyanoacrylate in the treatment of gastric varices complicated by multiple pulmonary emboli. *Intern Med J.* 2006;36(7):462-465.
24. Neumann H, Scheidbach H, Mönkemüller K et al. Multiple cyanoacrylate (Histoacryl) emboli after injection therapy of cardiavarices. *Gastrointest Endosc.* 2009;70(5):1025-1026.
25. Kwon CI, Song SH, Hahm KB et al. Unusual complications related to endoscopic retrograde cholangiopancreatography and its endoscopic treatment. *Clin Endosc.* 2013;46(3):251-259.
26. Lépilliez V, Chemaly M, Ponchon T et al. Endoscopic resection of sporadic duodenal adenomas: an efficient technique with a substantial risk of delayed bleeding. *Endoscopy.* 2008;40(10):806-810.
27. Sorbi D, Norton I, Conio M et al. Postpolypectomy lower GI bleeding: descriptive analysis. *Gastrointest Endosc.* 2000;51(6):690-696.
28. Boustière C, Veitch A, Vanbiervliet G, Bulois P, Deprez P, Laquiere A, Laugier R [http://www.ncbi.nlm.nih.gov/pubmed?term=Lesur%20G%5BAuthor%5D&cauthor=true&cauthor\\_uid=21547880](http://www.ncbi.nlm.nih.gov/pubmed?term=Lesur%20G%5BAuthor%5D&cauthor=true&cauthor_uid=21547880) et al. Endoscopy and antiplatelet agents. European Society of Gastrointestinal Endoscopy (ESGE) Guideline. *Endoscopy.* 2011;43(5):445-461.
29. Cao Y, Liao C, Tan A et al. Meta-analysis of endoscopic submucosal dissection versus endoscopic mucosal resection for tumors of the gastrointestinal tract. *Endoscopy.* 2009;41(9):751-757.
30. Apel D, Jakobs R, Spiethoff A et al. Follow-up after endoscopic snare resection of duodenal adenomas. *Endoscopy.* 2005;37(5):444-448.
31. Dinis-Ribeiro M, Pimentel-Nunes P. Should antiplatelets be stopped before gastric mucosectomy? For how long and in whom? *Endoscopy.* 2012 Feb;44(2):111-113.
32. Dinis-Ribeiro M, Pimentel-Nunes P, Afonso M et al. A European case series of endoscopic submucosal dissection for gastric superficial lesions. *Gastrointest Endosc.* 2009;69(2):350-355.
33. Kakushima N, Fujishiro M. Endoscopic submucosal dissection for gastrointestinal neoplasms. *World J Gastroenterol.* 2008;14(19):2962-2967.
34. Tamiya Y, Nakahara K, Kominato K, Serikawa O, Watanabe Y, Tateishi H, Takedatsu H et al. Pneumomediastinum is a frequent but minor complication during esophageal endoscopic submucosal dissection. *Endoscopy.* 2010;42(1):8-14.
35. Saito Y, Otake Y, Sakamoto T, Nakajima T, Yamada M, Haruyama S, So E [http://www.ncbi.nlm.nih.gov/pubmed?term=Abe%20S%5BAuthor%5D&cauthor=true&author\\_uid=23710305](http://www.ncbi.nlm.nih.gov/pubmed?term=Abe%20S%5BAuthor%5D&cauthor=true&author_uid=23710305) et al. Indications for and technical aspects of colorectal endoscopic submucosal dissection. *Gut Liver.* 2013;7(3):263-269.
36. Kobayashi N, Yoshitake N, Hirahara Y, Konishi J, Saito Y, Matsuda T, Ishikawa T et al. Matched case-control study comparing endoscopic submucosal dissection and endoscopic mucosal resection for colorectal tumors. *J Gastroenterol Hepatol.* 2012;27(4):728-733.
37. Piotet E, Escher A, Monnier P. Esophageal and pharyngeal strictures: report on 1,862 endoscopic dilatations using the Savary-Gilliard technique. *Eur Arch Otorhinolaryngol.* 2008;265(3):357-364.
38. Nelson DB, Sanderson SJ, Azar MM. Bacteremia with esophageal dilation. *Gastrointest Endosc.* 1998;48(6):563-567.

39. Hernandez LV, Jacobson JW, Harris MS. Comparison among the perforation rates of Maloney, balloon, and savary dilation of esophageal strictures. *Gastrointest Endosc.* 2000;51:460-462.
40. Jacobs JW Jr, Spechler SJ. A systematic review of the risk of perforation during esophageal dilation for patients with eosinophilic esophagitis. *Dig Dis Sci.* 2010;55(6):1512-1515.
41. Boeckxstaens GE, Annese V, des Varannes SB, Chaussade S, Costantini M, Cuttitta A, Elizalde JI et al. European Achalasia Trial Investigators. Pneumatic dilation versus laparoscopic Heller's myotomy for idiopathic achalasia. *N Engl J Med.* 2011;364(19):1807-1816.
42. Fukami N, Anderson MA, Khan K, Harrison ME, Appalaneni V, Ben-Menachem T, Decker GA  
[http://www.ncbi.nlm.nih.gov/pubmed?term=Fanelli%20RD%5BAuthor%5D&cauthor=true&cauthor\\_uid=21704805](http://www.ncbi.nlm.nih.gov/pubmed?term=Fanelli%20RD%5BAuthor%5D&cauthor=true&cauthor_uid=21704805) et al. The role of endoscopy in gastroduodenal obstruction and gastroparesis. *Gastrointest Endosc.* 2011;74(1):13-21.
43. Stienecker K, Gleichmann D, Neumayer U et al. Long-term results of endoscopic balloon dilatation of lower gastrointestinal tract strictures in Crohn's disease: a prospective study. *World J Gastroenterol.* 2009;15(21):2623-2627.
44. Hassan C, Zullo A, De Francesco V, Lerardi E, Giustini M, Pitidis A, Taggi F  
[http://www.ncbi.nlm.nih.gov/pubmed?term=Winn%20S%5BAuthor%5D&cauthor=true&cauthor\\_uid=17903236](http://www.ncbi.nlm.nih.gov/pubmed?term=Winn%20S%5BAuthor%5D&cauthor=true&cauthor_uid=17903236) et al. Systematic review: Endoscopic dilatation in Crohn's disease. *Aliment Pharmacol Ther.* 2007;26(11-12):1457-1464.
45. Sgourakis G, Gockel I, Radtke A, Dedemadi G, Goumas K, Mylona S, Lang H  
[http://www.ncbi.nlm.nih.gov/pubmed?term=Tsiamis%20A%5BAuthor%5D&cauthor=true&cauthor\\_uid=20440646](http://www.ncbi.nlm.nih.gov/pubmed?term=Tsiamis%20A%5BAuthor%5D&cauthor=true&cauthor_uid=20440646) et al. The use of self-expanding stents in esophageal and gastroesophageal junction cancer palliation: a meta-analysis and meta-regression analysis of outcomes. *Dig Dis Sci.* 2010;55(11):3018-3030.
46. Baron TH. Minimizing endoscopic complications: endoluminal stents. *GastrointestEndoscClin N Am.* 2007;17(1):83-104.
47. Verschur EM, Steyerberg EW, Kuipers EJ et al. Effect of stent size on complications and recurrent dysphagia in patients with esophageal or gastric cardia cancer. *Gastrointest Endosc.* 2007;65(4):592-601.
48. Gaidos JK, Draganov PV. Treatment of malignant gastric outlet obstruction with endoscopically placed self-expandable metal stents. *World J Gastroenterol.* 2009;15(35):4365-4371.
49. Maetani I, Ukita T, Tada T et al. Metallic stents for gastric outlet obstruction: reintervention rate is lower with uncovered versus covered stents, despite similar outcomes. *Gastrointest Endosc.* 2009;69(4):806-812.
50. Tan CJ, Dasari BV, Gardiner K. Systematic review and meta-analysis of randomized clinical trials of self-expanding metallic stents as a bridge to surgery versus emergency surgery for malignant left-sided large bowel obstruction. *Br J Surg.* 2012;99(4):469-476.
51. Bonin EA, Baron TH. Update on the indications and use of colonic stents. *Curr Gastroenterol Rep.* 2010;12(5):374-382.
52. Schuman BM, Beckman JW, Tedesco FJ et al. Complications of endoscopic injection sclerotherapy: a review. *Am J Gastroenterol.* 1987;82(9):823-830.
53. Yuki M, Kazumori H, Yamamoto S et al. Prognosis following endoscopic injection sclerotherapy for esophageal varices in adults: 20-year follow-up study. *Scand J Gastroenterol.* 2008;43(10):1269-1274.
54. Laine L, Cook D. Endoscopic ligation compared with sclerotherapy for treatment of esophageal variceal bleeding. A meta-analysis. *Ann Intern Med.* 1995;123(4):280-287.
55. Schmitz RJ, Sharma P, Badr AS et al. Incidence and management of esophageal stricture formation, ulcer bleeding, perforation, and massive hematoma formation from sclerotherapy versus band ligation. *Am J Gastroenterol.* 2001;96(2):437-441.

56. Fry LC, Neumann H, Olano C et al. Efficacy, complications and clinical outcomes of endoscopic sclerotherapy with N-butyl-2-cyanoacrylate for bleeding gastric varices. *Dig Dis*. 2008;26(4):300-303.
57. Prachayakul V, Aswakul P, Chantarojanasiri T et al. Factors influencing clinical outcomes of Histoacryl® glue injection-treated gastric variceal hemorrhage. *World J Gastroenterol*. 2013;19(15):2379-2387.
58. McClave SA, Chang WK. Complications of enteral access. *Gastrointest Endosc*. 2003;58(5):739-751.
59. Jafri NS, Mahid SS, Minor KS et al. Meta-analysis: antibiotic prophylaxis to prevent peristomal infection following percutaneous endoscopic gastrostomy. *Aliment Pharmacol Ther*. 2007;25(6):647-656.
60. Zopf Y, Rabe C, Bruckmoser T et al. Percutaneous endoscopic jejunostomy and jejunal extension tube through percutaneous endoscopic gastrostomy: a retrospective analysis of success, complications and outcome. *Digestion*. 2009;79(2):92-97.
61. Manner H, May A, Miehlke S, Dertinger S, Wigglinghaus B, Schimming W, Krämer W [http://www.ncbi.nlm.nih.gov/pubmed?term=Niemann%20G%5BAuthor%5D&cauthor=true&cauthor\\_uid=16817835](http://www.ncbi.nlm.nih.gov/pubmed?term=Niemann%20G%5BAuthor%5D&cauthor=true&cauthor_uid=16817835) et al. Ablation of nonneoplastic Barrett's mucosa using argon plasma coagulation with concomitant esomeprazole therapy (APBANEX): a prospective multicenter evaluation. *Am J Gastroenterol*. 2006;101(8):1762-1769.
62. Manner H, Plum N, Pech O et al. Colon explosion during argon plasma coagulation. *Gastrointest Endosc*. 2008;67(7):1123-1127.
63. Shaheen NJ, Sharma P, Overholt BF, Wolfsen HC, Sampliner RE, Wang KK, Galanko JA et al. Radiofrequency ablation in Barrett's esophagus with dysplasia. *N Engl J Med*. 2009;360(22):2277-2288.
64. Lyday WD, Corbett FS, Kuperman DA, Kalvaria I, Mavrelis PG, Shughoury AB, Pruitt RE. Radiofrequency ablation of Barrett's esophagus: outcomes of 429 patients from a multicenter community practice registry. *Endoscopy*. 2010;42(4):272-278.
65. Inoue H, Ikeda H, Hosoya T, Onimaru M, Yoshida A, Eleftheriadis N, Maselli R [http://www.ncbi.nlm.nih.gov/pubmed?term=Kudo%20S%5BAuthor%5D&cauthor=true&cauthor\\_uid=22354822](http://www.ncbi.nlm.nih.gov/pubmed?term=Kudo%20S%5BAuthor%5D&cauthor=true&cauthor_uid=22354822) et al. Submucosal endoscopic tumor resection for subepithelial tumors in the esophagus and cardia. *Endoscopy*. 2012;44(3):225-230.
66. Ren Z, Zhong Y, Zhou P, Xu M, Cai M, Li L, Shi Q, Yao L. Perioperative management and treatment for complications during and after peroral endoscopic myotomy (POEM) for esophageal achalasia (EA) (data from 119 cases). *Surg Endosc*. 2012;26(11):3267-3272.
67. Xin L, Liao Z, Jiang YP et al. Indications, detectability, positive findings, total enteroscopy, and complications of diagnostic double-balloon endoscopy: a systematic review of data over the first decade of use. *Gastrointest Endosc*. 2011;74(3):563-570.
68. Mensink PB, Haringsma J, Kucharzik T, Cellier C, Pérez-Cuadrado E, Mönkemüller K, Gasbarrini A et al. Complications of double balloon enteroscopy: a multicenter survey. *Endoscopy*. 2007;39(7):613-615.
69. Andriulli A, Loperfido S, Napolitano G, Niro G, Valvano MR, Spirito F, Pilotto A [http://www.ncbi.nlm.nih.gov/pubmed?term=Forlano%20R%5BAuthor%5D&cauthor=true&cauthor\\_uid=17509029](http://www.ncbi.nlm.nih.gov/pubmed?term=Forlano%20R%5BAuthor%5D&cauthor=true&cauthor_uid=17509029) et al. Incidence rates of post-ERCP complications: a systematic survey of prospective studies. *Am J Gastroenterol*. 2007;102(8):1781-1788.
70. Williams EJ, Taylor S, Fairclough P, Hamlyn A, Logan RF, Martin D, Riley SA et al. Risk factors for complication following ERCP; results of a large-scale, prospective multicenter study. *Endoscopy*. 2007;39(9):793-801.
71. Wang P, Li ZS, Liu F, Ren X, Lu NH, Fan ZN, Huang Q et al. Risk factors for ERCP-related complications: a prospective multicenter study. *Am J Gastroenterol*. 2009;104(1):31-40.
72. Freeman ML. Complications of endoscopic retrograde cholangiopancreatography: avoidance and management. *Gastrointest Endosc Clin N Am*. 2012;22(3):567-586.

73. Stapfer M, Selby RR, Stain SC, Katkhouda N, Parekh D, Jabbour N, Garry D. Management of duodenal perforation after endoscopic retrograde cholangiopancreatography and sphincterotomy. *Ann Surg.* 2000;232(2):191-198.
74. Kahaleh M, Freeman M. Prevention and management of post-endoscopic retrograde cholangiopancreatography complications. *Clin Endosc.* 2012;45(3):305-312.
75. Finsterer J, Stöllberger C, Bastovansky A. Cardiac and cerebral air embolism from endoscopic retrograde cholangio-pancreatography. *Eur J Gastroenterol Hepatol.* 2010;22(10):1157-1162.
76. Bisceglia M, Simeone A, Forlano Ret al. Fatal systemic venous air embolism during endoscopic retrograde cholangiopancreatography. *Adv Anat Pathol.* 2009;16(4):255-262.
77. Efthymiou M, Raftopoulos S, AntonioChirinos J et al. Air embolism complicated by left hemiparesis after direct cholangioscopy with an intraductal balloon anchoring system. *Gastrointest Endosc.* 2012;75(1):221-223.
78. Jenssen C, Alvarez-Sánchez MV, Napoléon B et al. Diagnostic endoscopic ultrasonography: assessment of safety and prevention of complications. *World J Gastroenterol.* 2012;18(34):4659-4676.
79. Adler DG, Jacobson BC, Davila RE, Hirota WK, Leighton JA, Qureshi WA, Rajan E et al. ASGE guideline: complications of EUS. *Gastrointest Endosc.* 2005;61(1):8-12.
80. Affi A, Vazquez-Sequeiros E, Norton IDet al. Acute extraluminalhemorrhage associated with EUS-guided fine needle aspiration: frequency and clinical significance. *Gastrointest Endosc.* 2001;53(2):221-225.
81. Polkowski M, Larghi A, Weynand B, Boustière C, Giovannini M, Pujol B, Dumonceau JM et al. Learning, techniques, and complications of endoscopic ultrasound (EUS)-guided sampling in gastroenterology: European Society of Gastrointestinal Endoscopy (ESGE) Technical Guideline. *Endoscopy.* 2012;44(2):190-206.
82. Giovannini M. Endoscopic ultrasonography-guided pancreatic drainage. *Gastrointest Endosc Clin N Am.* 2012;22(2):221-230.
83. Bakker OJ, van Santvoort HC, van Brunschot S, Geskus RB, Besselink MG, Bollen TL, van Eijck CH et al. Endoscopic transgastricvs surgical necrosectomy for infected necrotizing pancreatitis: a randomized trial. *JAMA.* 2012;307(10):1053-1061.
84. Doi S, Yasuda I, Kawakami H, Hayashi T, Hisai H, Irisawa A, Mukai T et al. Endoscopic ultrasound-guided celiac ganglia neurolysis vs. celiac plexus neurolysis: a randomized multicenter trial. *Endoscopy.* 2013;45(5):362-369.
85. Gupta K, Perez-Miranda M, Kahaleh M, Artifon EL, Itoi T, Freeman ML, de-Serna C et al. In EBD STUDY GROUP. Endoscopic Ultrasound-assisted Bile Duct Access and Drainage: Multicenter, Long-term Analysis of Approach, Outcomes, and Complications of a Technique in Evolution. *J Clin Gastroenterol.* 2013 Apr 29. [Epub ahead of print]
86. Bokun T, Grgurevic I, Kujundzic M et al. EUS-Guided Vascular Procedures: A Literature Review. *Gastroenterol Res Pract.* 2013;2013:865945.
87. Manta R, Galloro G, Mangiavillano B, Conigliaro R, Pasquale L, Arezzo A, Masci E et al. Over-the-scope clip (OTSC) represents an effective endoscopic treatment for acute GI bleeding after failure of conventional techniques. *Surg Endosc.* 2013 Feb 23. [Epub ahead of print]
88. Sung JJ, Luo D, Wu JC, Ching JY, Chan FK, Lau JY, Mack S [http://www.ncbi.nlm.nih.gov/pubmed?term=Ducharme%20R%5BAuthor%5D&cauthor=true&cauthor\\_uid=21455870](http://www.ncbi.nlm.nih.gov/pubmed?term=Ducharme%20R%5BAuthor%5D&cauthor=true&cauthor_uid=21455870) et al. Early clinical experience of the safety and effectiveness of Hemospray in achieving hemostasis in patients with acute peptic ulcer bleeding. *Endoscopy.* 2011;43(4):291-295.
89. Itoi T, Yasuda I, Doi S et al. Endoscopic hemostasis using covered metallic stent placement for uncontrolled post-endoscopic sphincterotomy bleeding. *Endoscopy.* 2011;43(4):369-372.

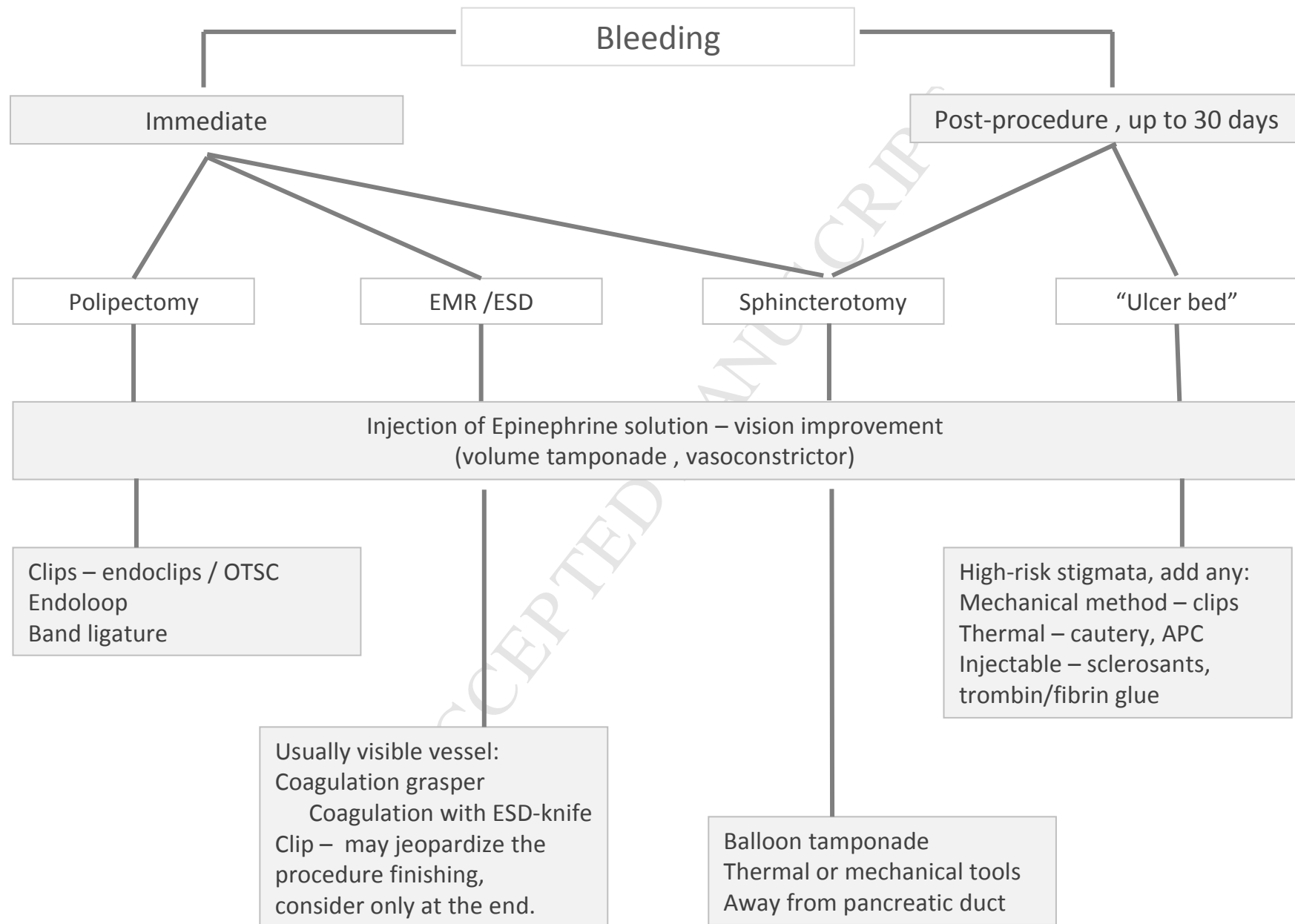
90. Baron TH, Wong Kee Song LM, Zielinski MD et al. A comprehensive approach to the management of acute endoscopic perforations (with videos). *Gastrointest Endosc.* 2012;76(4):838-859.
91. Tam WY, Bertholini D. Tension pneumoperitoneum, pneumomediastinum, subcutaneous emphysema and cardiorespiratory collapse following gastroscopy. *Anaesth Intensive Care.* 2007;35(2):307-309.
92. Kowalczyk L, Forsmark CE, Ben-David K, Wagh MS, Chauhan S, Collins D, Draganov PV. Algorithm for the management of endoscopic perforations: a quality improvement project. *Am J Gastroenterol.* 2011;106(6):1022-1027.
93. Minami S, Gotoda T, Ono H et al. Complete endoscopic closure of gastric perforation induced by endoscopic resection of early gastric cancer using endoclips can prevent surgery (with video). *Gastrointest Endosc.* 2006;63(4):596-601.
94. Mangiavillano B, Viaggi P, Masci E. Endoscopic closure of acute iatrogenic perforations during diagnostic and therapeutic endoscopy in the gastrointestinal tract using metallic clips: a literature review. *J Dig Dis.* 2010;11(1):12-18.
95. Otake Y, Saito Y, Sakamoto T, Aoki T, Nakajima T, Toyoshima N, Matsuda T et al. New closure technique for large mucosal defects after endoscopic submucosal dissection of colorectal tumors (with video). *Gastrointest Endosc.* 2012;75(3):663-667.
96. Matsuda T, Fujii T, Emura F, Kozu T, Saito Y, Ikematsu H, Saito D. Complete closure of a large defect after EMR of a lateral spreading colorectal tumor when using a two-channel colonoscope. *Gastrointest Endosc.* 2004;60(5):836-838.
97. Shi Q, Chen T, Zhong YS, Zhou PH, Ren Z, Xu MD, Yao LQ. Complete closure of large gastric defects after endoscopic full-thickness resection, using endoloop and metallic clip interrupted suture. *Endoscopy.* 2013;45(5):329-334.
98. Han JH, Lee TH, Jung Y, Lee SH, Kim H, Han HS, Chae H et al. Rescue endoscopic band ligation of iatrogenic gastric perforations following failed endoclip closure. *World J Gastroenterol.* 2013;19(6):955-959.
99. Rolanda C, Lima E, Silva D, Moreira I, Pêgo JM, Macedo G, Correia-Pinto J. In vivo assessment of gastrotomy closure with over-the-scope clips in an experimental model for varicolectomy (with video). *Gastrointest Endosc.* 2009;70(6):1137-1145.
100. Moreira-Pinto J, Lima E, Correia-Pinto J et al. Natural orifice transluminal endoscopy surgery: A review. *World J Gastroenterol.* 2011;17(33):3795-3801.
101. Vanuytsel T, Lerut T, Coosemans W, Vanbeckevoort D, Blondeau K, Boeckxstaens G, Tack J. Conservative management of esophageal perforations during pneumatic dilation for idiopathic esophageal achalasia. *Clin Gastroenterol Hepatol.* 2012;10(2):142-149.
102. Lindenmann J, Matzi V, Neuboek N, Anegg U, Maier A, Smolle J, Smolle-Juettner FM. Management of esophageal perforation in 120 consecutive patients: clinical impact of a structured treatment algorithm. *J Gastrointest Surg.* 2013;17(6):1036-1043.
103. Van Boeckel PG, Dua KS, Weusten BL, Schmits RJ, Surapaneni N, Timmer R, Vleggaar FP et al. Fully covered self-expandable metal stents (SEMS), partially covered SEMS and self-expandable plastic stents for the treatment of benign esophageal ruptures and anastomotic leaks. *BMC Gastroenterol.* 2012;12:19.
104. Qadeer MA, Dumot JA, Vargo JJ et al. Endoscopic clips for closing esophageal perforations: case report and pooled analysis. *Gastrointest Endosc.* 2007;66(3):605-611.
105. Kuehn F, Schiffmann L, Rau BM et al. Surgical endoscopic vacuum therapy for anastomotic leakage and perforation of the upper gastrointestinal tract. *J Gastrointest Surg.* 2012;16(11):2145-2150.
106. Hagel AF, Naegel A, Lindner AS, Kessler H, Matzel K, Dauth W, Neurath MF et al. Over-the-scope clip application yields a high rate of closure in gastrointestinal perforations and may reduce emergency surgery. *J Gastrointest Surg.* 2012;16(11):2132-2138.

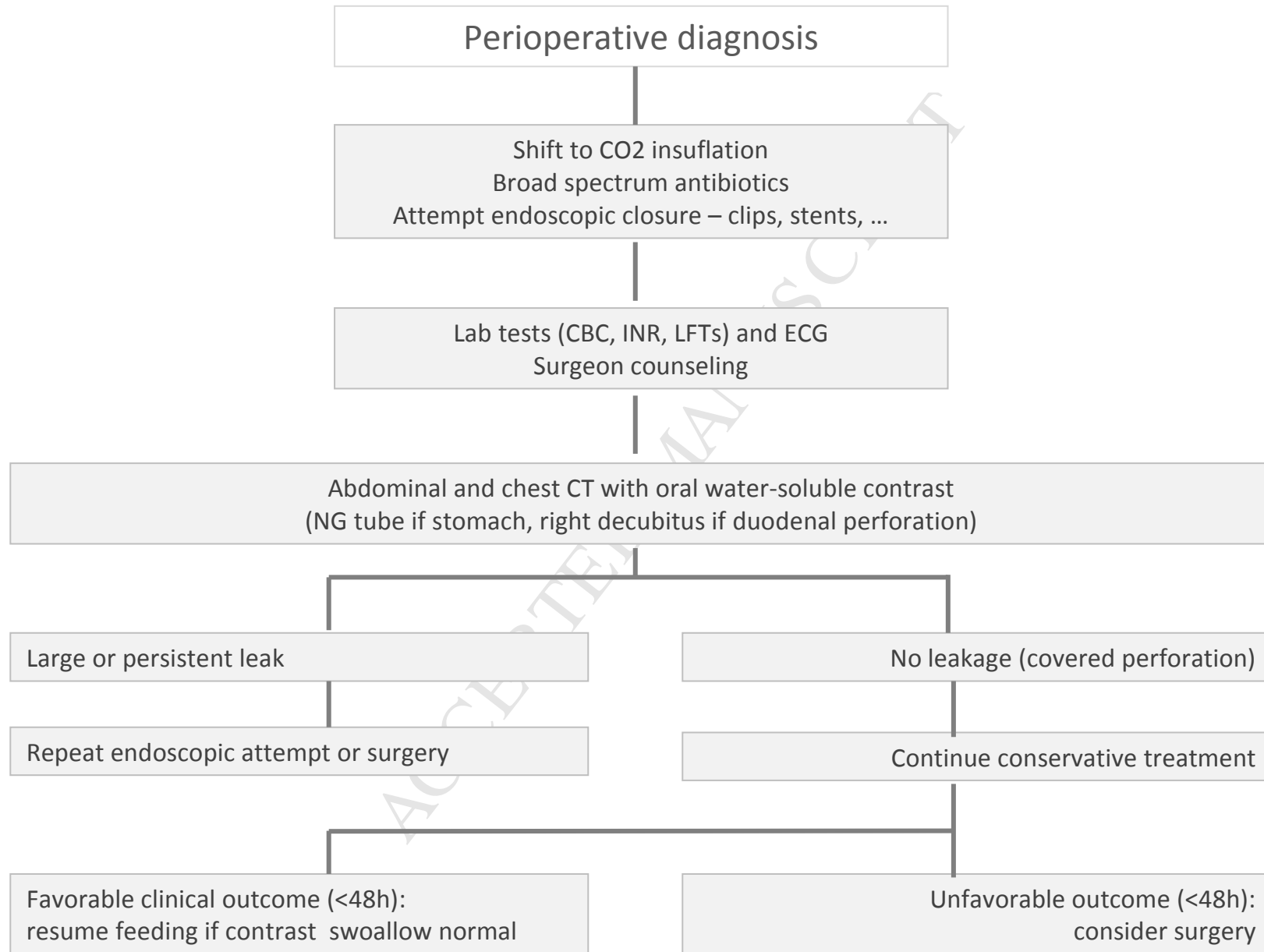


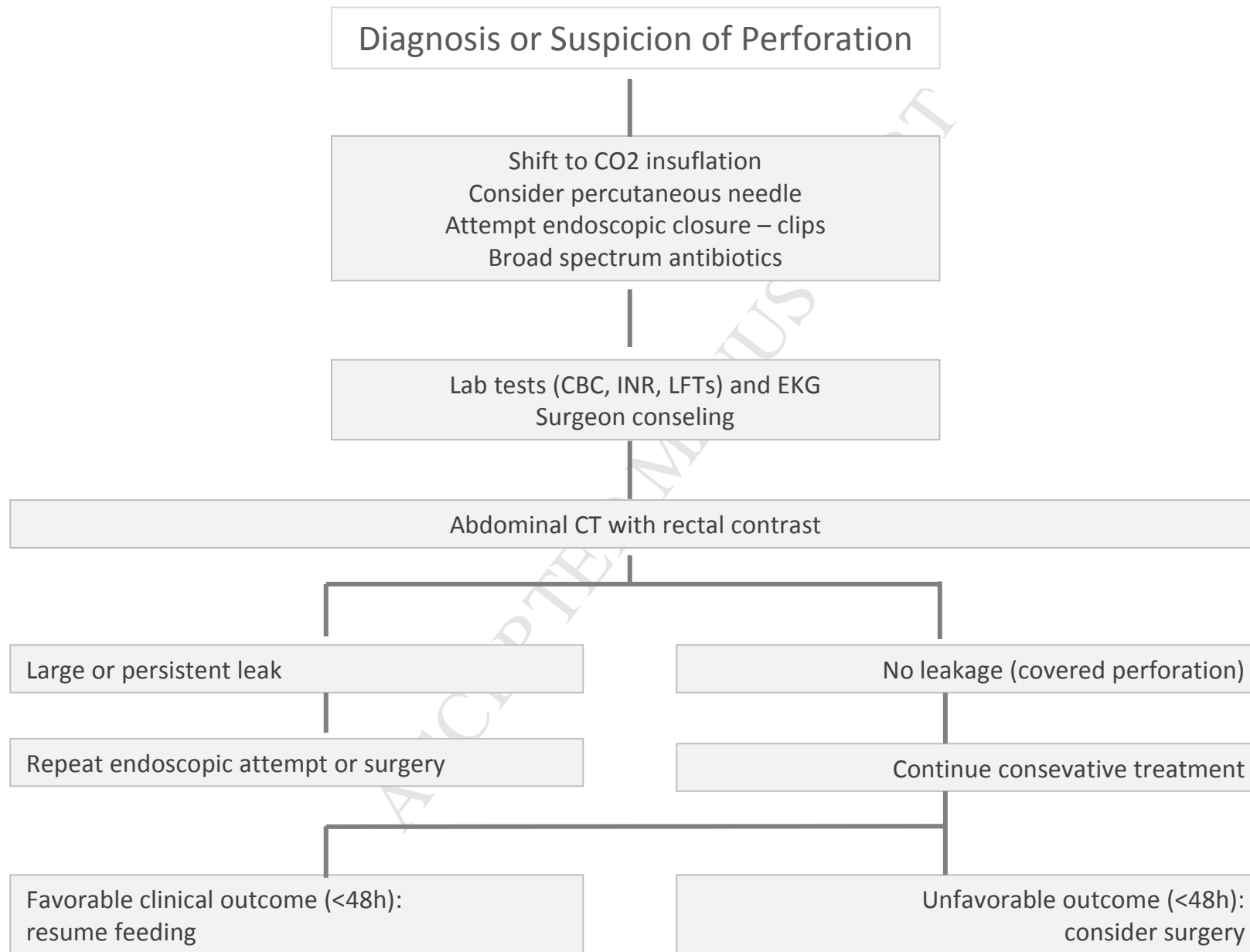
107. Balmadrid B, Kozarek R. Prevention and management of adverse events of endoscopic retrograde cholangiopancreatography. *Gastrointest Endosc Clin N Am*. 2013;23(2):385-403.
108. Lee TH, Bang BW, Jeong JI, Kim HG, Jeong S, Park SM, Lee DH [http://www.ncbi.nlm.nih.gov/pubmed?term=Park%20SH%5BAuthor%5D&cauthor=true&cauthor\\_uid=20458771](http://www.ncbi.nlm.nih.gov/pubmed?term=Park%20SH%5BAuthor%5D&cauthor=true&cauthor_uid=20458771) et al. Primary endoscopic approximation suture under cap-assisted endoscopy of an ERCP-induced duodenal perforation. *World J Gastroenterol*. 2010;16(18):2305-2310.
109. Voermans RP, Le Moine O, von Renteln D, Ponchon T, Giovannini M, Bruno M, Weusten B [http://www.ncbi.nlm.nih.gov/pubmed?term=Seewald%20S%5BAuthor%5D&cauthor=true&cauthor\\_uid=22361277](http://www.ncbi.nlm.nih.gov/pubmed?term=Seewald%20S%5BAuthor%5D&cauthor=true&cauthor_uid=22361277) et al. CLIPPER Study Group. Efficacy of endoscopic closure of acute perforations of the gastrointestinal tract. *Clin Gastroenterol Hepatol*. 2012;10(6):603-608.
110. Canena J, Liberato M, Horta Det al. Short-term stenting using fully covered self-expandable metal stents for treatment of refractory biliary leaks, postsphincterotomy bleeding, and perforations. *Surg Endosc*. 2013;27(1):313-324.
111. Magdeburg R, Collet P, Post S et al. Endoclippping of iatrogenic colonic perforation to avoid surgery. *Surg Endosc*. 2008;22(6):1500-1504.
112. Kang HY, Kang HW, Kim SG, Kim JS, Park KJ, Jung HC, Song IS et al. Incidence and management of colonoscopic perforations in Korea. *Digestion*. 2008;78(4):218-223.
113. Yang DH, Byeon JS, Lee KH, Yoon SM, Kim KJ, Ye BD, Myung SJ et al. Is endoscopic closure with clips effective for both diagnostic and therapeutic colonoscopy-associated bowel perforation? *Surg Endosc*. 2010;24(5):1177-1185.
114. Murariu D, Tatsuno BK, Tom MK et al. Subcutaneous emphysema, pneumopericardium, pneumomediastinum and pneumoretroperitoneum secondary to sigmoid perforation: a case report. *Hawaii J Med Public Health*. 2012;71(3):74-77.

Table 1

	<b>Hemorrhage</b>	<b>Perforation</b>	<b>Infection*</b>	<b>Embolization</b>
<b>Diagnostic GI Endoscopy</b>				
Upper GI	0,002-0,06	0,0009-0,04	-	-
Colonoscopy	0-0,03	0,005-0,2	-	-
<b>Therapeutic Procedures</b>				
Polypectomy (upper/lower)	3,4-10,0 / 0,26-6,1	0,06-1,1	-	-
ESD (upper/lower)	1,8-15,6 / 0-12,0	1,3-4,0 / 1,4-10,4	-	-
Stenting (upper/lower)	0-3,9	0-0,8 / 3,8-10,0	-	-
Dilation	-	0-4,0	-	-
Gastrostomy (jejunostomy)	0-1,0	-	7,0-47,0	-
Variceal ligation / sclerosis		0-0,7 / 2,0-5,0	-	0-1,0
APC / RFA ablation	0-4,0 / 0-2,0	0-2,0	-	-
<b>Enteroscopy</b>				
Diagnostic	0-0,8	0-0,3	-	-
Therapeutic	0-3,0	0-4,0	-	-
<b>ERCP</b>				
Diagnostic	0	0,11	-	-
Therapeutic	0,49-2,0	0,3-0,8	0,5-3,0	rare reports
<b>EUS</b>				
Diagnostic plus FNB	0,15-3,7	0,03-0,86	0-16,0	-







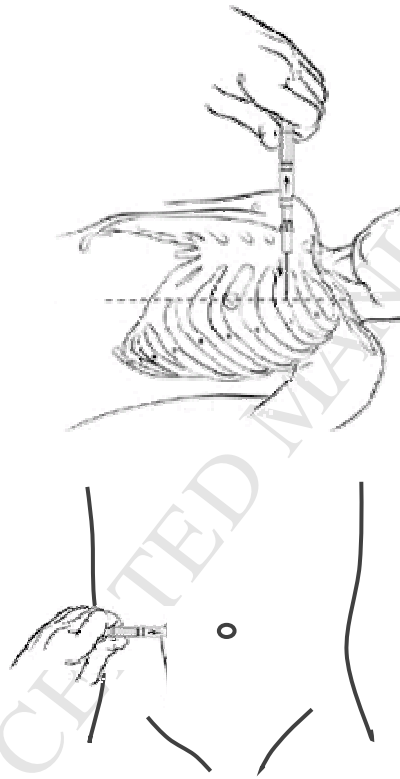


Figure 4