

D-12-02961R1

S0140-6736(12)60830-7

Supplementary videos

Video 1 caption: Video capsule endoscopy staging Peutz-Jeghers disease. Pedunculated polyp in the stomach.**Video 2 caption:** Video capsule endoscopy staging Peutz-Jeghers disease. Pedunculated polyp in the proximal jejunum

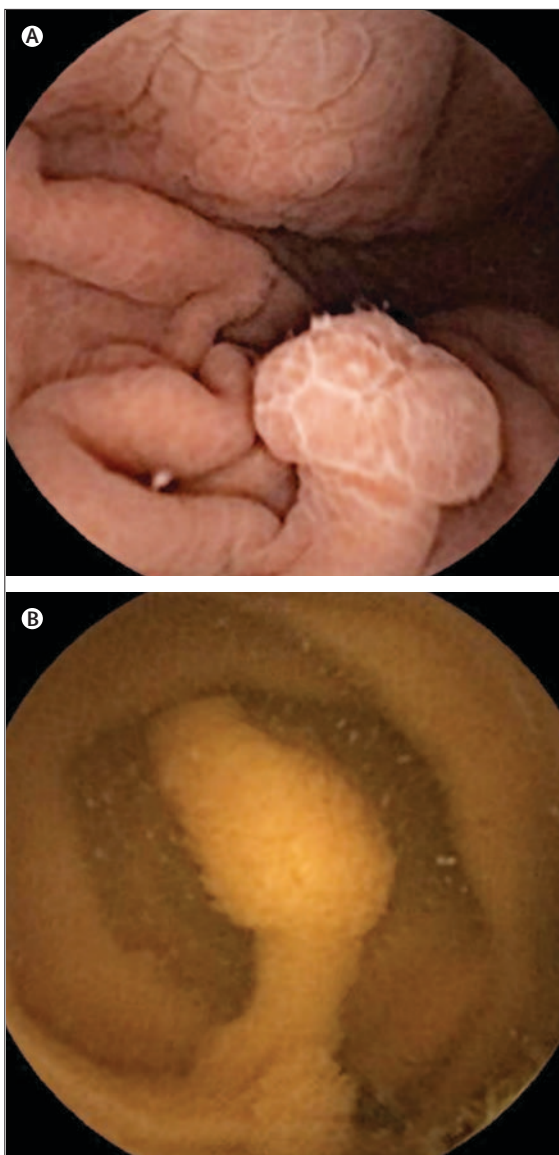
Embargo: Oct 5, 2012—00.01 (BST)

Peutz-Jeghers syndrome: capsule endoscopy to stage disease



Henedina Antunes, João Nascimento, Paula Peixoto

A 13-year-old girl with recurrent abdominal pain and rectal bleeding was referred to our department. Her 36-year-old father had been diagnosed with Peutz-Jeghers syndrome (PJS) after previous surgical interventions for intestinal occlusion. On physical examination, she had hyperpigmented macules on her lips and buccal mucosa. Genetic testing showed a mutation in exon 6 of the gene *STK11*. A video capsule endoscopy was done to stage the disease. A 7 mm polyp in the stomach (figure A; video 1), and a 12 mm pedunculated polyp in the proximal jejunum, were seen (figure B; video 2). Smaller polyps were found sparsely in the jejunum and proximal ileum. Screening and surveillance is crucial in Peutz-Jeghers syndrome because of the risk of complications related to polyps, and the association with cancers. Our patient's case shows the feasibility, security, and sensitivity of use of capsule endoscopy to stage disease.

**Figure: Peutz-Jeghers syndrome**

Video capsule endoscopy showing (A) pedunculated polyp in the stomach; and (B) pedunculated polyp in the proximal jejunum.

Published Online

October 5, 2012

[http://dx.doi.org/10.1016/](http://dx.doi.org/10.1016/S0140-6736(12)60830-7)

S0140-6736(12)60830-7

Gastroenterology, Hepatology
and Nutrition Unit,
Department of Pediatrics
(Prof H Antunes MD,
J Nascimento MD) and
Department of

Gastroenterology
(P Peixoto MD), Braga Hospital,
Braga, Portugal; Life and
Health Sciences Research
Institute (ICVS), School of
Health Sciences, University of
Minho, Braga, Portugal
(Prof H Antunes); and
ICVS/3B's—PT Government
Associate Laboratory,
Braga/Guimarães, Portugal
(Prof H Antunes)

Correspondence to:

Prof Henedina Antunes,
Gastroenterology, Hepatology
and Nutrition Unit, Department
of Pediatrics, Hospital de Braga
Apartado 2056, 4701-901 Braga,
Portugal

henedinaantunes@gmail.com