



Endoscopic Evacuation of Massive Intraventricular Hemorrhages Reduces Shunt Dependency: A Meta-Analysis

Alessandro Fiorindi¹ Giorgio Saraceno¹ Luca Zanin¹ Lodovico Terzi di Bergamo² Alberto Feletti³
Francesco Doglietto⁴ Marco Maria Fontanella¹

¹Department of Neurosurgery, Department of Medical and Surgical Specialties, Radiological Sciences and Public Health, University of Brescia, Italy

²Institute of Oncology Research, Bellinzona, Switzerland

³Department of Neurosciences, Biomedicine and Movement Sciences, Institute of Neurosurgery, University of Verona, AOUI Verona, Polo Chirurgico "P. Confortini," Italy

⁴Institute of Neurosurgery, Catholic University School of Medicine, Rome, Italy

Address for correspondence Giorgio Saraceno, MD, Neurosurgery, Department of Medical and Surgical Specialties, Radiological Sciences and Public Health, University of Brescia, Spedali Civili di Brescia, Piazzale Spedali Civili, 1, Brescia 25124, Italy (e-mail: g.saraceno@unibs.it).

AJNS 2022;17:541–546.

Abstract

Intraventricular hemorrhage (IVH) is characterized by severe prognosis. The amount of intraventricular blood is the most important, disease-specific, prognostic factor, as acute complications are strictly dependent on clot formation. Although external ventricular drain (EVD) placement is the standard treatment, in the past 15 years neuroendoscopic (NE) evacuation of IVH has been advocated, but available comparative data are limited. A systematic review of the literature was performed according to Preferred Reporting Items for Systematic Reviews and Meta-Analyses (PRISMA) guidelines. Included articles compare the treatment of primary and secondary IVH with NE and EVD. The meta-analysis was performed in terms of shunt dependency. Cochran's Q-test and I² statistics were used to assess heterogeneity in the studies. No heterogeneity was considered for *p* greater than 0.05 and I² less than 20%. A random-effect model was used, with restricted maximum likelihood to estimate the heterogeneity variance. After screening 744 articles, 5 were included in the meta-analysis. A total of 303 patients presenting with primary or pure (50 patients) and secondary (253 patients) IVH, undergoing either NE (151) or EVD (152), were included in the metanalysis. The risk of ventriculoperitoneal (VP) shunt was higher in the EVD group (relative risk: 1.93, 95% confidence interval: 1.28–2.92, *p* = 0.0094). The risk of VP shunt was higher in the EVD group, but the overall outcome remains poor for patients with IVH, with a moderate-to-high disability. Large randomized controlled trials are needed to evaluate more deeper both advantages and effects on the outcome of NE over EVD.

Keywords

- ▶ intraventricular hemorrhage
- ▶ neuroendoscopy
- ▶ ventriculoperitoneal shunt
- ▶ external ventricular drainage
- ▶ hydrocephalus

article published online
December 5, 2022

DOI <https://doi.org/10.1055/s-0042-1757220>.
ISSN 2248-9614.

© 2022. Asian Congress of Neurological Surgeons. All rights reserved.

This is an open access article published by Thieme under the terms of the Creative Commons Attribution-NonDerivative-NonCommercial-License, permitting copying and reproduction so long as the original work is given appropriate credit. Contents may not be used for commercial purposes, or adapted, remixed, transformed or built upon. (<https://creativecommons.org/licenses/by-nc-nd/4.0/>)

Thieme Medical and Scientific Publishers Pvt. Ltd., A-12, 2nd Floor, Sector 2, Noida-201301 UP, India

Key Messages

- EVD placement is the standard emergency management for intraventricular hemorrhage.
- Blood clots hinder the proper functioning of the EVD and the pathophysiology of IVH-related damage is not resolved.
- NE procedures allow to rapidly and totally restore cerebrospinal fluid dynamic if also the fourth ventricle is freed from blood clots, reduce the rate of VP shunts, risk of intracranial rebleeding, and risk of infection.

Introduction

Intraventricular hemorrhage (IVH), primary or secondary to intracerebral hemorrhage (ICH) and subarachnoid hemorrhage (SAH), is commonly recognized as a poor prognostic factor, with an estimated mortality of 50 to 80% and less than 40% of patient alive at 1-year follow-up.^{1–4} Together with neurological status at admission, the amount of intraventricular blood is the main prognostic factor, as it causes multiple noxious effects: impairment of cerebrospinal fluid (CSF) circulation, intracranial hypertension, and acute or delayed hydrocephalus.^{5–7} As an emergency procedure, external ventricular drain (EVD) placement is the standard management.^{1,8–11} However, particularly in the presence of large quantities of blood, different authors adopted neuroendoscopy (NE) as more aggressive treatment to evacuate IVH, advocating a rapid removal of intraventricular clots with an immediate resolution of intracranial hypertension and, consequently, substantial advantage on both short- and long-term prognosis over EVD.^{1,12–16} Different studies have indeed shown that NE can positively impact the outcome of IVH, especially lowering the shunt-dependency rate compared with EVD, but the small sample size did not allow to reach statistically significant results.^{12,16,17} This meta-analysis summarizes the data of available comparative studies and comprehensively evaluates the ventriculoperitoneal (VP) shunt rate (SR) in patients with IVH treated with NE or EVD.

Materials and Methods

Search Strategy

We searched MEDLINE (Ovid), EMBASE (Ovid), Science Citation Index (SCI-E), and Web of Science for articles published between Jan 1, 2000, and Dec 31, 2021, with the terms “intraventricular hemorrhage,” “intracerebral hemorrhage,” “intraparenchymal hemorrhage,” “typical brain hemorrhage,” “external ventricular drain,” “neuroendoscopy,” “shunt dependency” and “ventriculoperitoneal shunt,” with “AND” and “OR” combinations. The systematic review is reported in ► **Fig. 1** according to the Preferred Reporting Items for Systematic Reviews and Meta-Analyses (PRISMA) guidelines.¹⁸

Inclusion and Exclusion Criteria

Inclusion criteria were (1) studies comparing the treatment of spontaneous (primary and secondary) IVH with NE and

EVD only, (2) use of SR in the outcome, and (3) English language. Exclusion criteria were (1) IVH of the newborn and (2) application of simultaneous intraventricular fibrinolytic.

Quality Assessment and Data Extraction

Articles were imported into the reference management software Mendeley (version 1.19.4) and duplicates were removed. Titles and abstracts of retrieved records were examined by S.G. and nonrelevant citations were excluded; 20% of randomly selected excluded citations were double-checked by F.A. and Z.L. For each study, the following data were extracted: (1) authors and year of publication, (2) number of patients included in NE and EVD groups, (3) Glasgow Coma Scale (GCS) and Graeb score at admission, (4) VP SRs in both groups, (5) postoperative complications (i.e., ventriculitis and rebleeding) and outcomes defined as modified Rankin Scale (mRS) and Glasgow Outcome Scale (GOS).

Statistical Methods

Descriptive statistics were used to analyze postoperative complications and outcomes. The meta-analysis was performed to investigate the VP SRs, in the statistical software R version 3.6.3 (R Foundation for Statistical Computing, Vienna, Austria), using the meta-packages.^{19,20} Cochran's Q-test and I² statistics were used to assess heterogeneity in the studies included in the meta-analysis.

No heterogeneity was considered for *p*-value greater than 0.05 and I² less than 20%. A random-effect model was therefore used for the meta-analysis, with restricted maximum likelihood to estimate the heterogeneity variance.

Results

Literature Review

The initial literature search yielded 731 articles. On review of titles and abstracts, 706 articles were excluded. Twenty-five articles were selected for full-text screening, of which five met inclusion criteria. Twenty articles were excluded as they included pediatric and newborn patients (6 articles), evacuation of ICH and not IVH (6 articles) or because not comparing the two treatments (8 articles). ► **Fig. 1** shows the flow chart according to the PRISMA statement.¹⁸

Study Characteristics

Of the included studies, three were randomized controlled trials^{10,12,17} and the remaining two were retrospective studies.^{1,21} A total of 303 patients were considered for statistical analysis. The main variables of the included studies are reported in ► **Table 1**.

Demographics and Presentation

Baseline demographic data and clinical presentation of the patient population are summarized in ► **Table 1**. The mean age was 61.7 years (range: 51.3–70.6 years). GCS at presentation ranged from 5 to 9 in the NE group (mean: 7.5) and from 5 to 10 (mean: 8) in the EVD one. Graeb score ranged from 6 to 10 in the NE group (mean Graeb score 8) and from 4 to 9 in the EVD group (mean Graeb score 6). Only Di Rienzo et al specified

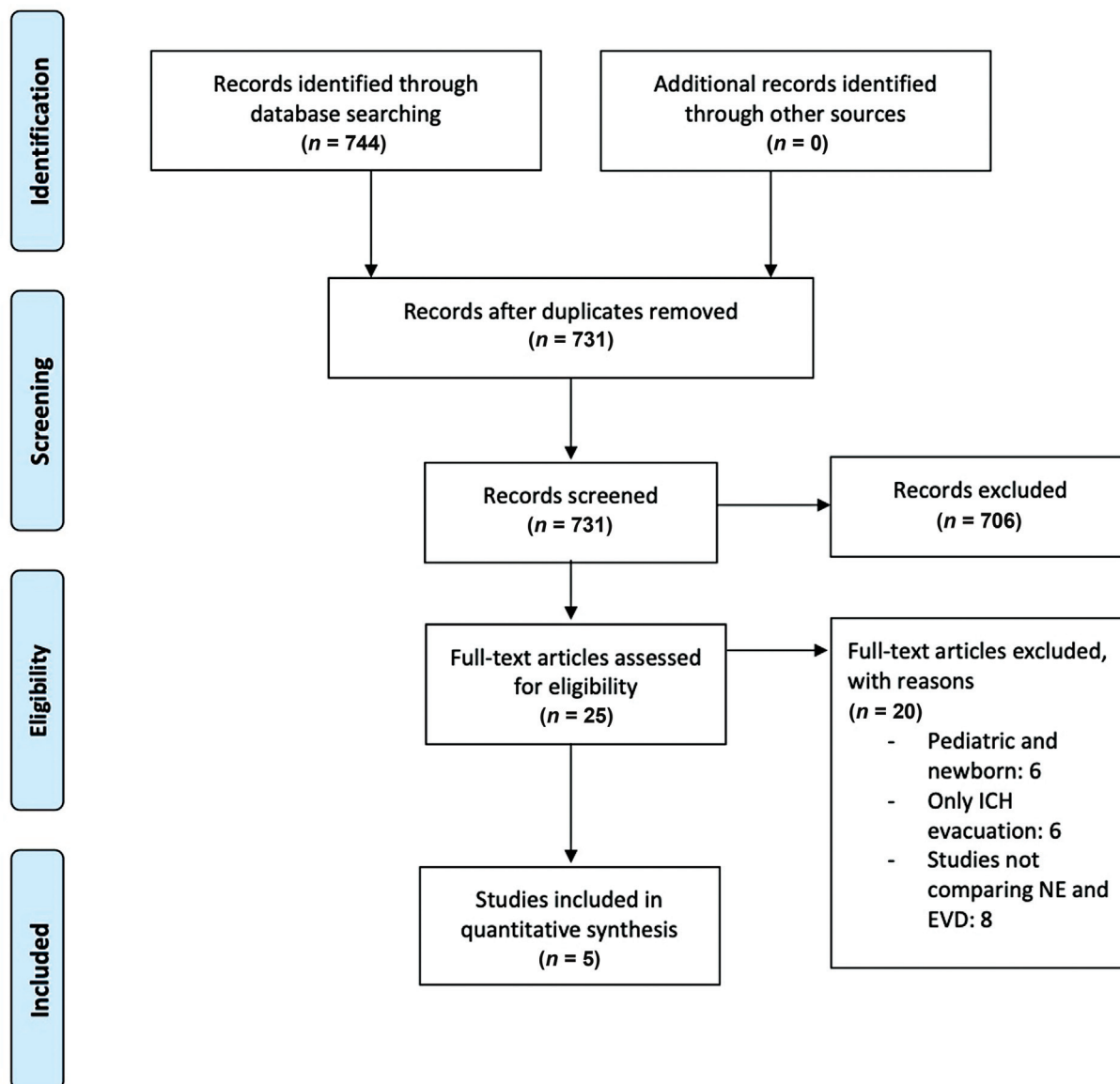


Fig. 1 Preferred Reporting Items for Systematic Reviews and Meta-Analyses (PRISMA) flowchart about the articles included in this study. EVD, external ventricular drain; ICH, intracerebral hemorrhage; NE, neuroendoscopy.

Table 1 Baseline and demographics characteristics of the studies

Author, year	Study	Year	Patients	Age	GCS NE	GCS EVD	Graeb NE	Graeb EVD
Chen et al, 2011 ¹²	RCT	2011	48	63.9	8.54	9.83	6.9	4.54
Johnson et al, 2017 ¹⁷	RCT	2017	39	51.3	9.8	9.2	–	–
Shimizu et al 2019 ¹⁰	RCT	2019	68	70.6	7.59	8.05	6.17	5.74
Di Rienzo et al 2020 ²¹	Retrospective	2020	52	65.5	4.96	5.22	–	–
Basaldella et al, 2012 ¹	RCT	2012	96	57.1	6.6	7.2	9.75	8.5

Abbreviations: EVD, external ventricular drain group; GCS, Glasgow Coma Scale; NE, neuroendoscopy group; RCT, randomized controlled trial.

patients' drug assumption, reporting 15 patients who were on antiplatelet or anticoagulant therapy.²¹

Shunt Rate and Overall Outcome

The metaanalysis showed a higher risk of VP shunt in the EVD group than the NE one (relative risk [RR] 1.93, confidence

interval [CI] 95% 1.28–2.92, $p = 0.0094$) (► **Fig. 2**). The 70.4 (range: 50.0–91.7%) and 37.2 (range: 16.7–76%) of patients treated with EVD only and NE, respectively, required a VP shunt (► **Table 2**). Chen et al reported a SR of 47.62% in the NE group and 90.48% in the EVD group (RR: 2.0).¹² Di Rienzo et al reported SR of 28.35% in the NE group and 35.93% in the EVD

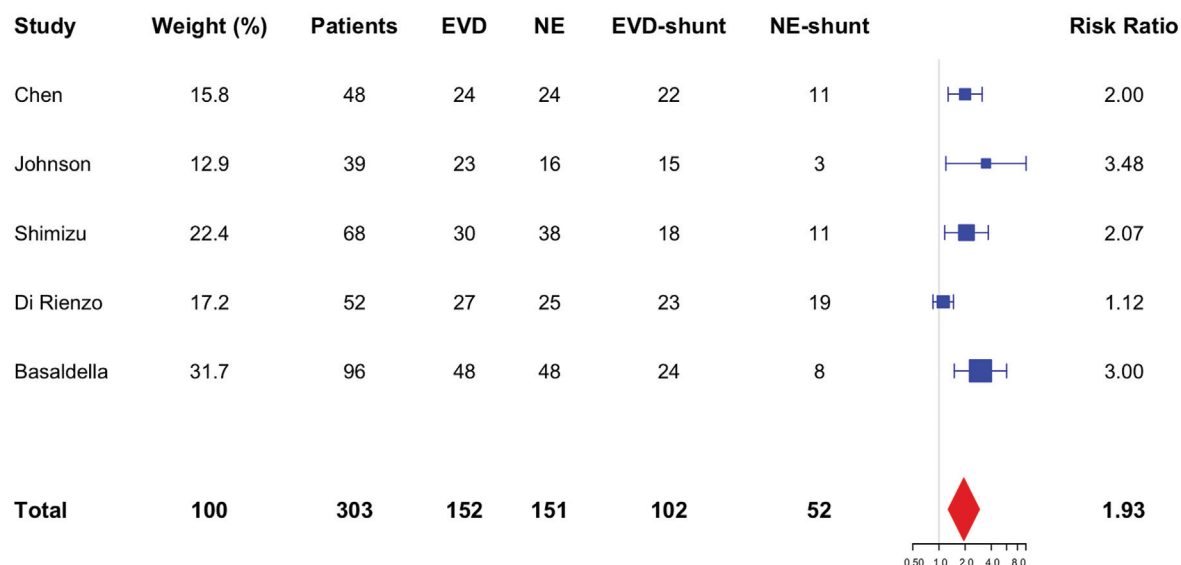


Fig. 2 Forest plot of estimated results of the meta-analysis comparing EVD and NE in terms of VP shunt rate. NE, neuroendoscopy; EVD, external ventricular drain; VP shunt, ventriculoperitoneal shunt.

group (RR: 1.12).²¹ Shimizu et al reported at 3 months the shunt dependency was 27.8% in patients treated with NE as compared with 60.0% in patients treated with EVD (RR: 2.07).¹⁰ A retrospective analysis from Basaldella et al reported a SR of 17% in the NE group and 50% in the EVD group (RR: 3.0).¹ Johnson et al reported at 3 months that the drainage dependency was 18.8% in patients treated with NE as compared with 65.2% in patients treated with EVD (RR: 3.48).¹⁷ The mean follow-up duration was 5.6 months (range: 3–12). Heterogeneous data were reported about the outcome: a mRS of 0 to 4 was documented in the 50 and 56% of patients treated with EVD and NE, respectively. On the other hand, half of the patients treated with EVD and only 43.8% of those treated with NE were described with a mRS of 5 to 6 at the last follow-up. The mean GOS was 3.1 and 3.2 for the EVD and NE patients, respectively. The mean mortality at 30 days was 14.1% for EVD and 19.6% for the NE group (→ **Table 2**).

Treatment Modality and Complications

A total of 151 patients underwent NE evacuation of IVH with the consequent insertion of the ventricular catheter and 152 patients underwent only EVD placement (→ **Table 2**). Only Basaldella et al used a flexible endoscope to remove blood clots.¹ Two studies reported data about the duration of EVD

catheter: in the EVD group the duration was 9.5 days (range: 5.15–14 days) and 7 days (range: 3.9–10 days) in the NE group. Three patients in the EVD group and one patient treated with NE procedures developed ventriculitis. No sufficient data were available to describe the postprocedure Graeb score. Di Rienzo et al reported an EVD occlusion of 0% in the NE group but in the EVD-only group, 26 and 18.5% of patients present temporary or permanent occlusion, respectively.²¹ Regarding the length of stay, Chen et al and Basaldella et al reported a mean intensive care unit (ICU) stay of 18.5 and 12 days in the EVD and NE group, respectively.^{1,12}

Heterogeneity and Sensitivity Analysis

Statistical heterogeneity across all the included studies was generally high. Significant heterogeneity with I^2 greater than 50% was observed in the meta-analysis of SR ($I^2 = 66.31\%$). In detail, the sensitivity analysis showed that the heterogeneity for SR was reduced to $I^2 = 0\%$ after omitting the study by Di Rienzo et al.

Discussion

IVH is a serious condition with very high mortality of more than 50% and a high percentage of disability among

Table 2 Outcome measures at the last follow-up

Author	VP shunt EVD (%)	VP shunt NE (%)	Follow-up	mRS EVD	mRS NE	GOS EVD	GOS NE
Chen et al, 2011 ¹²	90.5	47.6	3	–	–	3.3	3.1
Johnson et al, 2017 ¹⁷	65.2	18.8	–	–	–	–	–
Shimizu et al, 2019 ¹⁰	60	27.8	–	–	–	–	–
Di Rienzo et al, 2020 ²¹	85.2	76	6	3.6	3.4	–	–
Basaldella et al, 2012 ¹	50	16.6	12	2.8	3.7	–	–

Abbreviations: EVD, external ventricular drain; GOS, Glasgow Outcome Scale; mRS, modified Rankin Scale; NE, neuroendoscopy group; VP shunt, ventriculoperitoneal shunt.

survivors.²² The ever-increasing use of anticoagulant and antithrombotic drugs worsens the prognosis, especially in elderly patients.^{9,14,23} Even though there is a substantial lacking of standardized data and hence major evidence is needed to support the use of NE procedure in the evacuation of intraventricular hematoma, our meta-analysis suggests that the posthemorrhagic shunt-dependency rate is significantly lower in the NE group than in the EVD group.

Classically, EVD placement is adopted both to monitor and treat ICP in the setting of IVH. Blood clots, however, hinder the proper functioning of the EVD, and the physiopathology of IVH-related damage is not resolved anyway. Indeed, EVD placement is recognized as a factor predicting shunt-dependent hydrocephalus in aneurysmal SAH.²⁴ Other techniques have been described in the literature, with the main purpose of rapidly evacuating hematoma and avoiding blood clot formation. Intraventricular injection of fibrinolytic agents (intraventricular fibrinolysis [IVF]) was initially reported as an effective and safe procedure to ameliorate prognosis in IVH.^{25–28} However, the CLEAR III trial concluded that irrigation with alteplase, although lowering the mortality rate, did not improve outcome with more patient presenting mRS grade 5 at follow-up.²⁹

Endoscopic removal of ventricular hematoma is not a novelty: the first case was reported by Ritschl and Auer in 1987.³⁰ In the first years, only rigid endoscopes were used with variable success rates determined first by technical limitations. With the advent of flexible endoscopic instruments, ventricular hemorrhages removal through NE procedures gained significance.^{1,13–15,31} Different authors reported a reduction in shunt-dependency rate,^{1,12,16} length of stay in ICU,³² and hydrocephalus resolution in patients treated with NE techniques.³³ Two randomized-controlled trials did not find statistically significant differences in the mortality rate between EVD and NE groups,^{12,16} while two nonrandomized controlled trials concluded that patients treated with NE procedures had a lower mortality rate than the EVD group.^{11,34} A network meta-analysis by Mei et al concluded that, in patients treated for IVH, NE and EVD + IVF resulted in better survival and prognosis.⁹ Moreover, NE had the lowest rate of VP shunts, risk of intracranial rebleeding, and risk of infection. As a network meta-analysis, the statistical method requires that all procedures are equally indicated to all populations and contexts: however, high-level evidence for the choice of EVD only, EVD + IF, and NE procedures is lacking. As the sole example, fibrinolysis is contraindicated in the case of secondary IVH due to a vascular malformation rupture.

NE procedures allow to rapidly and totally restore CSF dynamic if also the fourth ventricle is freed from blood clots.¹³ The use of the flexible endoscope, reaching deeper ventricles region than the rigid one, could potentially bring greater benefit. Unfortunately, because of the extremely low number of patients, no statistical comparison is feasible in our analysis between flexible and rigid endoscope.

Regarding the potential complications of IVH surgery, the postsurgical meningitis related to a ventricular device placement is one of the most severe ones with an estimated

mortality of approximately 30%.³⁵ In this setting, NE could provide serious benefits lowering the infection rate because of a potential reduction in the EVD length of stay.

Limitations of the Study

Our meta-analysis has several limitations. First, the study is limited by both the retrospective nature of two studies and the small number of publications in the specific domain (i.e., NE removal of ventricular hemorrhage). Moreover, both the demographic data and the outcome measures are highly heterogeneous in the articles and no stratification or conclusions could be defined about the functional outcome. Only one of the five papers specified drugs assumption (i.e., antiplatelets or anticoagulant therapy), and their potential interaction with the outcome could not be investigated. The meta-analysis includes patients treated both with rigid and flexible endoscope: given the capability of fiberscopes to remove blood clots from the fourth ventricle, the results with this technique could be improved than the rigid instrument. However, a large-high-quality prospective study is mandatory to investigate this possibility. Another limitation is related to the decision making in VP shunt positioning: indications for permanent shunt placement are, in fact, highly institutional and surgeon dependent and this could impact the reported SR.

Conclusion

This study, through a meta-analysis, directly compares the results of NE and EVD in the setting of IVH treatment. NE evacuation of IVH led to a significantly lower shunt-dependency rate. Moreover, shorter catheter duration and fewer cases of infection were reported in the NE group. The overall outcome remains poor for patients with IVH, with a moderate-to-high disability.

New advances in IVH treatment with endoscope could deeper differences between classical EVD techniques and NE ones. However, large randomized controlled trials are needed to evaluate effects on the outcome. Moreover, the potentially higher advantage of flexible endoscope technology needs to be investigated.

Funding

None.

Conflict of Interest

None declared.

Authors' Contributions

Fiorindi Alessandro was involved in conceptualization, designing, definition of intellectual content, manuscript preparation, editing and review. Saraceno Giorgio contributed to designing, literature search, data acquisition, and manuscript preparation and editing. Zanin Luca contributed to literature search, data acquisition, and manuscript preparation. Terzi di Bergamo Lodovico did data analysis and statistical analysis. Feletti Alberto and Doglietto Francesco prepared and reviewed the manuscript. Fontanella

Marco Maria was involved in conceptualization, definition of intellectual content, manuscript preparation and review. Fiorindi Alessandro and Fontanella Marco Maria have provided guarantee for the manuscript.

Summary of work done by the first author, who has great experience in endoscopic neurosurgery, particularly in endoscopic IVH evacuation with more than 60 cases of intraventricular hemorrhage and an important influence in literature.

References

- Basaldella L, Marton E, Fiorindi A, Scarpa B, Badreddine H, Longatti P. External ventricular drainage alone versus endoscopic surgery for severe intraventricular hemorrhage: a comparative retrospective analysis on outcome and shunt dependency. *Neurosurg Focus* 2012;32(04):E4
- Bhattathiri PS, Gregson B, Prasad KSM, Mendelow ADSTICH Investigators. Intraventricular hemorrhage and hydrocephalus after spontaneous intracerebral hemorrhage: results from the STICH trial. *Acta Neurochir Suppl (Wien)* 2006;96:65–68
- Halleivi H, Albright KC, Aronowski J, et al. Intraventricular hemorrhage: anatomic relationships and clinical implications. *Neurology* 2008;70(11):848–852
- Longatti P, Fiorindi A, Di Paola F, Curtolo S, Basaldella L, Martinuzzi A. Coiling and neuroendoscopy: a new perspective in the treatment of intraventricular haemorrhages due to bleeding aneurysms. *J Neurol Neurosurg Psychiatry* 2006;77(12):1354–1358
- Graeb DA, Robertson WD, Lapointe JS, Nugent RA, Harrison PB. Computed tomographic diagnosis of intraventricular hemorrhage. Etiology and prognosis. *Radiology* 1982;143(01):91–96
- Hanley DF, Naff NJ, Harris DM. Intraventricular hemorrhage: presentation and management options. *Semin Cerebrovasc Dis Stroke* 2005;5:209–216
- Young WB, Lee KP, Pessin MS, Kwan ES, Rand WM, Caplan LR. Prognostic significance of ventricular blood in supratentorial hemorrhage: a volumetric study. *Neurology* 1990;40(04):616–619
- Idris Z, Raj J, Abdullah JM. Early experience in endoscopic management of massive intraventricular hemorrhage with literature review. *Asian J Neurosurg* 2014;9(03):124–129
- Mei L, Fengqun M, Qian H, Dongpo S, Zhenzhong G, Tong C. Exploration of efficacy and safety of interventions for intraventricular hemorrhage: a network meta-analysis. *World Neurosurg* 2020;136:382–389.e6
- Shimizu Y, Tsuchiya K, Fujisawa H. Endoscopic surgery for thalamic hemorrhage with intraventricular hemorrhage: effects of combining evacuation of a thalamic hematoma to external ventricular drainage. *Asian J Neurosurg* 2019;14(04):1112–1115
- Song P, Duan F-L, Cai Q, et al. Endoscopic surgery versus external ventricular drainage surgery for severe intraventricular hemorrhage. *Curr Med Sci* 2018;38(05):880–887
- Chen C-C, Liu C-L, Tung Y-N, et al. Endoscopic surgery for intraventricular hemorrhage (IVH) caused by thalamic hemorrhage: comparisons of endoscopic surgery and external ventricular drainage (EVD) surgery. *World Neurosurg* 2011;75(02):264–268
- Longatti P, Fiorindi A, Martinuzzi A. Neuroendoscopic aspiration of hemocephalus totalis: technical note. *Neurosurgery* 2005;57(4, Suppl):E409, discussion E409
- Longatti PL, Martinuzzi A, Fiorindi A, Maistrello L, Carteri A. Neuroendoscopic management of intraventricular hemorrhage. *Stroke* 2004;35(02):e35–e38
- Toyooka T, Kageyama H, Tsuzuki N, Ishihara S, Oka K. Flexible endoscopic aspiration for intraventricular casting hematoma. *Acta Neurochir Suppl (Wien)* 2016;123:17–23
- Zhang Z, Li X, Liu Y, Shao Y, Xu S, Yang Y. Application of neuroendoscopy in the treatment of intraventricular hemorrhage. *Cerebrovasc Dis* 2007;24(01):91–96
- Johnson JR, Idris Z, Abdullah JM, Alias A, Haspani MSM. Prevalence of shunt dependency and clinical outcome in patients with massive intraventricular haemorrhage treated with endoscopic washout and external ventricular drainage. *Malays J Med Sci* 2017;24(01):40–46
- Moher D, Liberati A, Tetzlaff J, Altman DGPRISMA Group. Preferred reporting items for systematic reviews and meta-analyses: the PRISMA statement. *PLoS Med* 2009;6(07):e1000097
- Balduzzi S, Rucker G, Schwarzer G. How to perform a meta-analysis with R: a practical tutorial. *Evid Based Ment Health* 2019;22(04):153–160
- R Core Team. (2013). R: A language and environment for statistical computing. R Foundation for Statistical Computing, Vienna, Austria. URL <http://www.R-project.org/>
- Di Rienzo A, Colasanti R, Esposito D, et al. Endoscope-assisted microsurgical evacuation versus external ventricular drainage for the treatment of cast intraventricular hemorrhage: results of a comparative series. *Neurosurg Rev* 2020;43(02):695–708
- Horstmann S, Rizos T, Lauseker M, et al. Intracerebral hemorrhage during anticoagulation with vitamin K antagonists: a consecutive observational study. *J Neurol* 2013;260(08):2046–2051
- Nieuwkamp DJ, de Gans K, Rinkel GJ, Algra A. Treatment and outcome of severe intraventricular extension in patients with subarachnoid or intracerebral hemorrhage: a systematic review of the literature. *J Neurol* 2000;247(02):117–121
- Xie Z, Hu X, Zan X, Lin S, Li H, You C. Predictors of shunt-dependent hydrocephalus after aneurysmal subarachnoid hemorrhage? A systematic review and meta-analysis. *World Neurosurg* 2017;106:844–860.e6
- Akdemir H, Selçuklu A, Paşaoğlu A, Oktem IS, Kavuncu I. Treatment of severe intraventricular hemorrhage by intraventricular infusion of urokinase. *Neurosurg Rev* 1995;18(02):95–100
- Findlay JM, Grace MG, Weir BK. Treatment of intraventricular hemorrhage with tissue plasminogen activator. *Neurosurgery* 1993;32(06):941–947, discussion 947
- Mayfrank L, Lippitz B, Groth M, Bertalanffy H, Gilsbach JM. Effect of recombinant tissue plasminogen activator on clot lysis and ventricular dilatation in the treatment of severe intraventricular haemorrhage. *Acta Neurochir (Wien)* 1993;122(1-2):32–38
- Rohde V, Schaller C, Hassler WE. Intraventricular recombinant tissue plasminogen activator for lysis of intraventricular haemorrhage. *J Neurol Neurosurg Psychiatry* 1995;58(04):447–451
- Hanley DF, Lane K, McBee N, et al; CLEAR III Investigators. Thrombolytic removal of intraventricular haemorrhage in treatment of severe stroke: results of the randomised, multicentre, multiregion, placebo-controlled CLEAR III trial. *Lancet* 2017;389(10069):603–611
- Ritschl E, Auer LM. Endoscopic evacuation of an intracerebral and intraventricular haemorrhage. *Arch Dis Child* 1987;62(11):1163–1165
- Hamada H, Hayashi N, Kurimoto M, et al. Neuroendoscopic removal of intraventricular hemorrhage combined with hydrocephalus. *Minim Invasive Neurosurg* 2008;51(06):345–349
- Oertel JMK, Mondorf Y, Baldauf J, Schroeder HWS, Gaab MR. Endoscopic third ventriculostomy for obstructive hydrocephalus due to intracranial hemorrhage with intraventricular extension. *J Neurosurg* 2009;111(06):1119–1126
- Yadav YR, Mukerji G, Shenoy R, Basoor A, Jain G, Nelson A. Endoscopic management of hypertensive intraventricular haemorrhage with obstructive hydrocephalus. *BMC Neurol* 2007;7:1
- Du B, Shan A-J, Peng Y-P, et al. A new modified neuroendoscope technology to remove severe intraventricular haematoma. *Brain Inj* 2018;32(09):1142–1148
- Soavi L, Rosina M, Stefini R, et al. Post-neurosurgical meningitis: Management of cerebrospinal fluid drainage catheters influences the evolution of infection. *Surg Neurol Int* 2016;7(Suppl 39):S927–S934