

Western University

Scholarship@Western

Obstetrics & Gynaecology Publications

Obstetrics & Gynaecology Department

12-1-2022

Extramedullary plasmacytoma of the uterine cervix arising in an asymptomatic 46-year-old female

Nicole Wiebe

Schulich School of Medicine & Dentistry

Nikhil Sangle

Schulich School of Medicine & Dentistry


Jacob McGee

Schulich School of Medicine & Dentistry, jacob.mcgee@lhsc.on.ca

Follow this and additional works at: <https://ir.lib.uwo.ca/obsgynpub>

Citation of this paper:

Wiebe, Nicole; Sangle, Nikhil; and McGee, Jacob, "Extramedullary plasmacytoma of the uterine cervix arising in an asymptomatic 46-year-old female" (2022). *Obstetrics & Gynaecology Publications*. 96. <https://ir.lib.uwo.ca/obsgynpub/96>



Case report

Extramedullary plasmacytoma of the uterine cervix arising in an asymptomatic 46-year-old female

Nicole Wiebe^{a,*}, Nikhil Sangle^{a,b}, Jacob McGee^{a,c}

^a Schulich School of Medicine & Dentistry, Western University, London, Ontario, Canada

^b Department of Pathology & Laboratory Medicine, University Hospital, Western University, London, Ontario, Canada

^c Department of Obstetrics & Gynecology, London Health Sciences Centre, Victoria Hospital, 800 Commissioners Road East, London, Ontario N6A 5W9, Canada

ARTICLE INFO

Keywords:

Solitary plasmacytoma of uterine cervix
Extramedullary plasmacytoma
Plasma cell neoplasm
Bone marrow biopsy
Hysterectomy
Cervical polypectomy

ABSTRACT

An extramedullary plasmacytoma is a rare type of plasma cell tumour that can be found in soft tissues throughout the body. The most common location for an extramedullary plasmacytoma is in the head and neck region. Few case reports have previously documented patients with an extramedullary plasmacytoma within the female genital tract. We report a case of a healthy and asymptomatic 46-year-old female who presented to Colposcopy Clinic with a finding of low-grade squamous intraepithelial lesion seen on a routine Pap smear. She was found to have a cervical polyp that was excised. Pathology revealed diffuse sheets of atypical plasma cells with lambda light chain restriction. She was referred to Hematology for extensive work-up as the pathology finding was concerning for a plasma cell neoplasm. Staging investigations, including bone marrow biopsy, skeletal survey, whole body PET-CT scan, serum protein electrophoresis, and serum free light chain testing, were all negative. Surgical resection with a hysterectomy was recommended as the most appropriate course of management. The treatment approach is consistent with guidelines outlined in the literature, whereby extramedullary plasmacytomas, which arise outside of the head and neck region and have clear margins, should undergo surgical resection. Extramedullary plasmacytomas carry a risk of progressing to systemic disease, such as multiple myeloma, making it crucial that these patients be followed with routine surveillance to achieve the most optimal long term survival outcome.

1. Introduction

A solitary plasmacytoma is a plasma cell neoplasm composed of a discrete proliferative mass of monoclonal plasma B cells without any evidence of systemic disease. Plasma cell neoplasms can be classified according to their site of origin, as they can either be found within the bone, termed a solitary bone plasmacytoma (SBP), or within soft tissue, termed an extramedullary plasmacytoma (EMP) (Dagan et al., 2009). Solitary plasmacytomas are estimated to represent between 5 and 10 % of all plasma cell dyscrasias (Dagan et al., 2009; Kilciksiz et al., 2012). The difference between a primary plasmacytoma and multiple myeloma is that the former dyscrasia lacks the systemic findings that are characteristic of multiple myeloma, including lytic bony lesions, hypercalcemia, anemia, and renal disease (Codorniz et al., 2017). It is critical to extensively investigate all findings of a plasma cell population in order to exclude the possibility of multiple myeloma.

SBPs are more common than their counterpart and often involve the

axial skeleton. Patients with a SBP may present with bone pain, fractures, and neurologic manifestations (Dagan et al., 2009). EMPs make up about 3–4 % of all plasma cell neoplasms (Schor et al., 2010; Gerry and Lentsch, 2013; Alexiou et al., 1999). EMPs are more common in males and are typically diagnosed between the fourth and seventh decades of life (Alexiou et al., 1999). EMPs are generally found in the upper respiratory and digestive tracts, however, they have also been reported at several other sites such as the urogenital tract, skin, lungs, breast, lymph nodes, and central nervous system (Schor et al., 2010; Wang et al., 2021). This type of neoplasm rarely develops in the female genital tract. Ten cases describing a primary cervix plasmacytoma have been reported since 1949 (Codorniz et al., 2017; Schor et al., 2010; Wang et al., 2021; Johansen et al., 1989; Huang et al., 2008; Fischer et al., 2003). These patients initially presented with vaginal bleeding, coital bleeding, pelvic pain, vaginal discharge, or they were asymptomatic (Wang et al., 2021). Biopsy confirmation of a monoclonal plasma cell population is required to diagnose a primary plasmacytoma of the cervix (Huang et al., 2008).

* Corresponding author.

E-mail address: nwiebe4@uwo.ca (N. Wiebe).

<https://doi.org/10.1016/j.gore.2022.101087>

Received 6 September 2022; Received in revised form 8 October 2022; Accepted 11 October 2022

Available online 13 October 2022

2352-5789/© 2022 Published by Elsevier Inc. This is an open access article under the CC BY-NC-ND license (<http://creativecommons.org/licenses/by-nc-nd/4.0/>).

Radiation therapy is the treatment of choice for solitary plasmacytomas as they are known to be highly radiosensitive (Schor et al., 2010; Huang et al., 2008). In some cases, the location and size of the tumour may make surgery a more favourable treatment option. There is the potential for a solitary plasmacytoma to progress to multiple myeloma, and this risk is greater for SBPs versus EMPs (Wang et al., 2021; Fischer et al., 2003). Therefore, close monitoring and surveillance of patients with a plasmacytoma is important to allow for early detection of a more deadly plasma cell neoplasm. The following case describes a 46-year-old female who was incidentally found to have a solitary plasmacytoma of the cervix through regular Pap smear testing.

2. Case

A 46-year-old G2P2 female who was previously healthy presented to the Colposcopy Clinic with a low-grade squamous intraepithelial lesion identified on a routine Pap smear. She had a history of regular menses with no intermenstrual bleeding and normal Pap smears. Past medical and surgical history was unremarkable. Her family history included breast cancer in a grandmother and aunt. At the time of colposcopy examination, a cervical polyp was found, however, the remainder of the examination was normal. A polypectomy was performed using a loop electrical excision procedure. Pathology results from the excisional biopsy showed diffuse sheets of atypical plasma cells with lambda light chain restriction concerning for a plasma cell neoplasm, such as an EMP (Fig. 1). The patient was then referred to Hematology for further work-up.

Staging was performed to determine the most appropriate course of treatment, which consisted of a bone marrow biopsy, baseline bloodwork, skeletal survey, and whole body PET-CT scan. Pathology from the bone marrow aspirate and core biopsy found normocellular marrow and no evidence of a plasma cell dyscrasia. The patient's initial bloodwork results at the time of consultation with Hematology were unremarkable (Table 1).

Further, serum protein electrophoresis and serum free light chain testing was negative for any monoclonal gammopathy (Table 1). The

Table 1

Patient laboratory values upon presentation to Hematology.

Laboratory Test	Initial Result	Reference Range
Leukocytes ($\times 10^9/L$)	5.5	4.0–10.0
ERC ($\times 10^{12}/L$)	4.47	4.00–5.60
Hemoglobin (g/L)	142	115–160
MCV (fL)	96.6	80.0–100.0
Thrombocytes ($\times 10^9/L$)	258	150–400
Urea (mmol/L)	4.4	<8.3
Creatinine (umol/L)	72	55–100
Albumin (g/L)	45	35–52
Calcium (mmol/L)	2.31	2.15–2.50
Total Protein (g/L)	74	64–83
LDH (U/L)	166	<214
IgG (g/L)	12	7–16
IgA (g/L)	3.5	0.7–4.0
IgM (g/L)	1	0.4–2.3
Alpha-1 Globulins (g/L)	2.7	1.9–4.1
Alpha-2 Globulins (g/L)	6.1	4.5–9.8
Beta-1 Globulins (g/L)	4.7	3.0–6.0
Beta-2 Globulins (g/L)	4.3	2.0–5.4
Gamma Globulins (g/L)	11.8	7.1–15.6
Free Ig Kappa Chains (mg/L)	14.8	3.3–19.4
Free Ig Lambda Chains (mg/L)	15.2	5.7–26.3
Free Light Chain Kappa/Lambda Ratio	0.97	0.26–1.65
Urine Protein (g/L)	0.09	<0.15

skeletal survey did not find any lytic bone lesions. Finally, the whole body PET-CT scan showed no evidence of plasmacytoma and reported physiologic uptake in the endometrium and cervix. In the case of this patient, the unusual location of the plasmacytoma indicated that a surgical approach, in addition to postoperative radiotherapy, may be more suitable.

The case was presented at a Multidisciplinary Cancer Conference. Myeloma subspecialists advised that the patient proceed with surgical management and recommended that radiotherapy was not necessary. The patient was referred back to the Gynecology Oncology Clinic for consideration of definitive treatment with a hysterectomy. She had remained asymptomatic over a four month time period since her initial

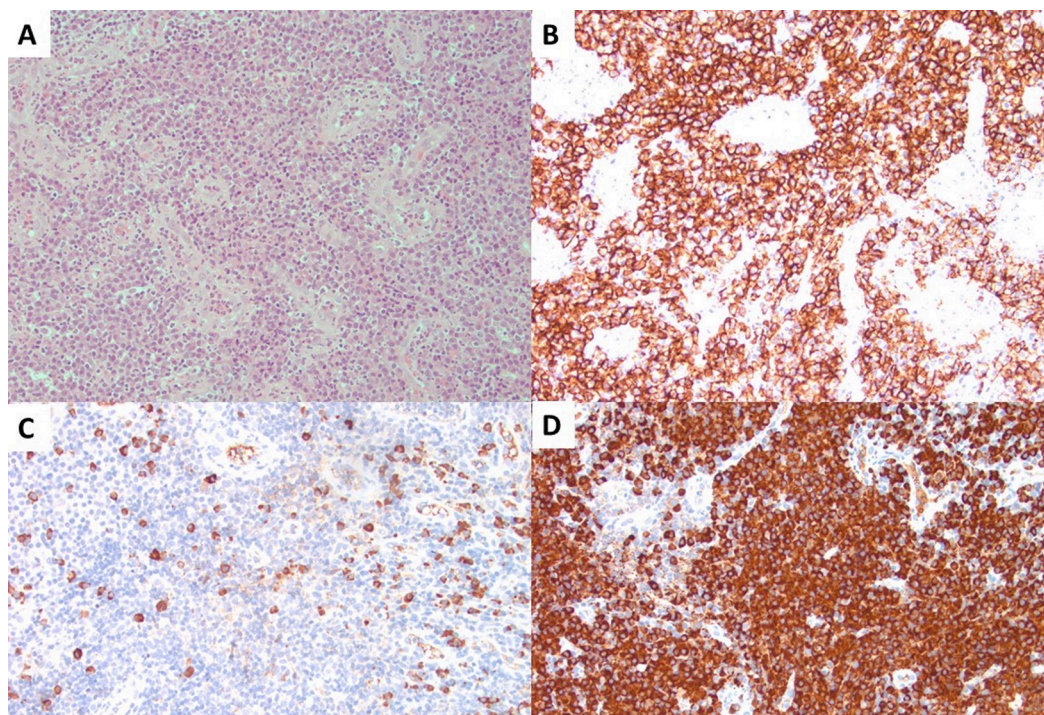


Fig. 1. Pathology findings from cervical biopsy. There are diffuse sheets of plasma cells (A), which show intense membranous staining for CD138 (B). There are scattered plasma cells showing cytoplasmic staining for kappa (C) with numerous lambda positive (D) cells, confirming lambda light chain restriction.

visit at the Colposcopy Clinic. She denied any vaginal bleeding, pelvic pain, bony pain, or constitutional symptoms. She had benign abdominal and pelvic examinations. The cervix was normal in appearance with some erythema surrounding the cervical os. The patient underwent surgical management with a total laparoscopic hysterectomy, right salpingo-oophorectomy, left salpingectomy, and omental biopsy. There were no operative complications and there was no evidence of extracervical disease. A bulky right ovary was removed and a normal appearing contralateral ovary was left to maintain hormone production. The patient experienced an uneventful post-operative course and was discharged from the Gynecology Oncology Clinic four weeks after surgery. Pathology results were negative and did not identify any residual atypical plasma cells within the cervix or omentum. Hematology will follow the patient with bloodwork every-three months for two years following surgery, and will then transition to annual surveillance. The patient is currently free of disease at follow-up more than five months following her initial treatment.

3. Discussion

Solitary plasmacytomas can be categorized as either having no clonal bone marrow plasma cells (BMPCs) or having <10 % clonal BMPCs, termed “low marrow involvement” (Rajkumar et al., 2014). Multiple myeloma is diagnosed in patients with a solitary plasmacytoma and 10 % or more clonal BMPCs. Extramedullary plasma cell disorders are quite rare and comprise 3–4 % of all plasma cell malignancies (Schor et al., 2010; Gerry and Lentsch, 2013; Alexiou et al., 1999). The establishment of plasma cells outside of the bone marrow and in soft tissues throughout the body is postulated to be related to the actions of adhesion molecules (Alexiou et al., 1999). The diagnostic criteria for an EMP include the presence of a tissue biopsy displaying monoclonal plasma cell histology, BMPC infiltration <5 % of all nucleated cells, in addition to the absence of bone lesions, hypercalcemia, renal failure, and a low serum M protein concentration (Kilciksiz et al., 2012). The clinical work-up for patients with a suspected EMP must include a bone marrow biopsy and serum electrophoresis to exclude the diagnosis of multiple myeloma, as this is the most common cause of death in patients with a diagnosed EMP.

Approximately 80 % of reported EMPs have been found in the head and neck region, such as the nasal cavity, sinuses, nasopharynx, and larynx, while other less commonly reported sites include the gastrointestinal tract, urogenital tract, skin, lung, and breast (Codorniz et al., 2017; Wang et al., 2021). There have been few reports of EMPs in the female reproductive system (Schor et al., 2010). The literature has described plasma cell neoplasms within the vagina, ovaries, and cervix. To our knowledge, this is the eleventh case report to describe an EMP of the cervix. The previously reported patients with a plasma cell lesion at the cervix ranged in age from 21 to 79 years and their clinical history included symptoms such as irregular vaginal bleeding, coital bleeding, pelvic pain, and vaginal discharge (Codorniz et al., 2017; Schor et al., 2010; Wang et al., 2021; Johansen et al., 1989; Huang et al., 2008; Fischer et al., 2003). Our patient is the third reported case to be asymptomatic at time of presentation.

EMPs are generally localized low grade malignant neoplasms so the main treatment goal is to achieve local control. Radiation therapy is the standard treatment offered to patients with a SBP or EMP as solitary plasmacytomas are very sensitive to radiation therapy (Wang et al., 2021; Huang et al., 2008). The current treatment guidelines followed by health practitioners for treating solitary plasmacytomas are based off of previous case reports, case series, or retrospective studies, as the data is limited. Head and neck EMPs should be treated only with radiation therapy because surgery can be invasive (Thumallapally et al., 2017). However, complete surgical resection should be considered for patients with an EMP that is outside of the head and neck region and has clear margins. Following surgical resection, radiation therapy may be indicated if inadequate surgical margins were achieved or complete removal was not possible (Kilciksiz et al., 2012; Thumallapally et al., 2017).

Previous cases have found that adjuvant chemotherapy does not provide any benefit in successfully treating solitary plasmacytomas or preventing progression to multiple myeloma (Kilciksiz et al., 2012; Wang et al., 2021). In our case, the patient was treated with surgery as complete removal of the EMP location was possible. Our patient was advised to not have radiation therapy. The other published cases of plasma cell neoplasms at the cervix have documented various forms of treatment including local radiation, cervical conization, hysterectomy, and hysterectomy with post-operative radiotherapy (Schor et al., 2010; Wang et al., 2021; Fischer et al., 2003). The evidence regarding the risk of EMP progression to multiple myeloma after treatment with surgical resection alone or with a combination of surgery and radiotherapy is inconclusive (Alexiou et al., 1999; Wang et al., 2021).

Patient factors that may predict an increased risk of progression from solitary plasmacytoma to systemic disease include tumour size, persistence of serum monoclonal protein following treatment, and an abnormal serum free light chain ratio (Wang et al., 2021; Thumallapally et al., 2017). SBPs are more likely to progress to multiple myeloma than EMPs, as roughly 50 % of patients with a SBP and 30 % of patients with an EMP develop multiple myeloma within ten years of their diagnosis (Caers et al., 2018). After progression from localized solitary plasmacytoma to systemic multiple myeloma, the 5-year survival rate for EMPs and SBPs are 100 % and 33 %, respectively (Kilciksiz et al., 2012). EMPs therefore carry a promising prognosis, especially when found at an earlier stage of disease. Surveillance recommendations to monitor plasmacytoma recurrence include complete blood count, serum protein electrophoresis, and serum free light chain testing.

In conclusion, this case report describes a rare case of an EMP of the uterine cervix in an asymptomatic 46-year-old female and its treatment with surgical resection. Health care providers should remain suspicious for the possibility of discovering a neoplastic disease after an atypical plasma cell population has been identified on a Pap smear or cervical biopsy. The literature is scant on solitary plasmacytomas in unusual locations. It is critical that physicians observe and follow their patients closely in order to frequently assess for disease recurrence or progression to a deadlier form of plasma cell dyscrasia.

Informed consent

Written informed consent was obtained from the patient for publication of this case report. A copy of the written consent is available for review by the Editor-in-Chief of this journal on request.

CRedit authorship contribution statement

Nicole Wiebe: Writing – original draft, Writing – review & editing.
Nikhil Sangle: Writing – original draft, Writing – review & editing.
Jacob McGee: Supervision, Writing – review & editing.

Declaration of Competing Interest

The authors declare that they have no known competing financial interests or personal relationships that could have appeared to influence the work reported in this paper.

Acknowledgements

This work was supported by the Gynecologic Oncology Research fund at Western University.

References

- Alexiou, C., Kau, R.J., Dietzfelbinger, H., Kremer, M., Spieß, J.C., Schratzenstaller, B., Arnold, W., 1999. Extramedullary plasmacytoma—tumor occurrence and therapeutic concepts. *Cancer* 85 (11), 2305–2314.
- Caers, J., Paiva, B., Zamagni, E., Leleu, X., Blade, J., Kristinsson, S.Y., et al., 2018. Diagnosis, treatment, and response assessment in solitary plasmacytoma: updated

- recommendations from a European Expert Panel. *J. Hematol. Oncol.* 11 (10) <https://doi.org/10.1186/s13045-017-0549-1>.
- Codorniz, A., Cunha, R., Fernandes, F., Pais, M.J., Neves, T., Quintana, C., 2017. Uterine extramedullary plasmacytoma as a primary manifestation of multiple myeloma. *Rev. Bras. Ginecol. Obstet.* 39, 516–520. <https://doi.org/10.1055/s-0037-1605373>.
- Dagan, R., Morris, C.G., Kirwan, J., Mendenhall, W.M., 2009. Solitary plasmacytoma. *Am. J. Clin. Oncol.* 32 (6), 612–617. <https://doi.org/10.1097/COC.0b013e31819cca18>.
- Fischer, E.G., Bocklage, T.J., Rabinowitz, I., Smith, H.O., Viswanatha, D.S., 2003. Primary plasmacytoma arising in an endocervical polyp with detection of neoplastic cells on Papanicolaou test—a case report and review of the literature. *Arch. Pathol. Lab. Med.* 127, e28–e31.
- Gerry, D., Lentsch, E.J., 2013. Epidemiologic evidence of superior outcomes for extramedullary plasmacytoma of the head and neck. *J. Otolaryngol.-Head Neck.* 148 (6), 974–981. <https://doi.org/10.1177/0194599813481334>.
- Huang, C.C., Liu, M.T., Pi, C.P., Chung, C.Y., 2008. Primary plasmacytoma of the uterine cervix treated with three-dimensional conformal radiotherapy. *Singapore Med. J.* 49 (12), e361–e364.
- Johansen, B., Ahlbom, G., Ostergard, B., 1989. Extramedullary solitary plasmacytoma at the uterine cervix as a cause of postcoital bleeding. *Acta Obstet. Gynecol. Scand.* 68, 279–280.
- Kilciksiz, S., Karakoyun-Celik, O., Agaoglu, F.Y., Haydaroglu, A., 2012. A review for solitary plasmacytoma of bone and extramedullary plasmacytoma. *Sci. World J.* 2012, 1–6.
- Rajkumar, S.V., Dimopoulos, M.A., Palumbo, A., Blade, J., Merlini, G., Mateos, M.V., et al., 2014. International myeloma working group updated criteria for the diagnosis of multiple myeloma. *Lancet Oncol.* 15, e538–e548.
- Schor, A.P.T., Moraes, M.P.T., Bisson, F.W., Bisson, M.A.M., Luiz, O.M.R., Bacchi, C.E., 2010. Primary plasmacytoma of the cervix in a 21-year-old female patient. *Int. J. Gynecol. Pathol.* 29, 290–293. <https://doi.org/10.1097/PGP.0b013e3181c070b4>.
- Thumallapally, N., Meshref, A., Mousa, M., Terjanian, T., 2017. Solitary plasmacytoma: population-based analysis of survival trends and effect of various treatment modalities in the USA. *BMC Cancer.* 17 (13) <https://doi.org/10.1186/s12885-016-3015-5>.
- Wang, J., Jiang, L., Ma, X., Li, T., Liu, H., Chen, X., et al., 2021. Case report: solitary extramedullary plasmacytoma in the cervix misdiagnosed as cervical cancer. *Front. Oncol.* 11. <https://doi.org/10.3389/fonc.2021.685070>.