



UvA-DARE (Digital Academic Repository)

Fatal gastrointestinal complications in Pitt-Hopkins syndrome

Koppen, I.J.N.; Menke, L.A.; Westra, W.M.; Struik, F.; Mesman, S.; van Wijk, M.P.; Huisman, S.A.

DOI

[10.1002/ajmg.a.63079](https://doi.org/10.1002/ajmg.a.63079)

Publication date

2023

Document Version

Final published version

Published in

American Journal of Medical Genetics. Part A

License

CC BY

[Link to publication](#)

Citation for published version (APA):

Koppen, I. J. N., Menke, L. A., Westra, W. M., Struik, F., Mesman, S., van Wijk, M. P., & Huisman, S. A. (2023). Fatal gastrointestinal complications in Pitt-Hopkins syndrome. *American Journal of Medical Genetics. Part A*, 191(3), 855-858. <https://doi.org/10.1002/ajmg.a.63079>

General rights

It is not permitted to download or to forward/distribute the text or part of it without the consent of the author(s) and/or copyright holder(s), other than for strictly personal, individual use, unless the work is under an open content license (like Creative Commons).


Disclaimer/Complaints regulations

If you believe that digital publication of certain material infringes any of your rights or (privacy) interests, please let the Library know, stating your reasons. In case of a legitimate complaint, the Library will make the material inaccessible and/or remove it from the website. Please Ask the Library: <https://uba.uva.nl/en/contact>, or a letter to: Library of the University of Amsterdam, Secretariat, Singel 425, 1012 WP Amsterdam, The Netherlands. You will be contacted as soon as possible.

UvA-DARE is a service provided by the library of the University of Amsterdam (<https://dare.uva.nl>)

CASE REPORT

Fatal gastrointestinal complications in Pitt-Hopkins syndrome

Ilan J. N. Koppen¹  | Leonie A. Menke² | Wytske M. Westra^{3,4} | Femke Struik⁵ | Simone Mesman⁶ | Michiel P. van Wijk⁷ | Sylvia A. Huisman^{2,8}

¹Department of Pediatric Gastroenterology and Nutrition, Emma Children's Hospital, Amsterdam UMC, University of Amsterdam, Amsterdam, The Netherlands

²Department of Pediatrics, Emma Children's Hospital, Amsterdam UMC, University of Amsterdam, Amsterdam, The Netherlands

³Department of Gastroenterology and Hepatology, Amsterdam UMC, University of Amsterdam, Amsterdam, The Netherlands

⁴Department of Gastroenterology and Hepatology, Meander Medisch Centrum, Amersfoort, The Netherlands

⁵Department of Radiology and Nuclear Medicine, Amsterdam UMC, University of Amsterdam, Amsterdam, The Netherlands

⁶Swammerdam Institute for Life Sciences, FNWI, University of Amsterdam, Amsterdam, The Netherlands

⁷Department of Pediatric Gastroenterology and Nutrition, Emma Children's Hospital, Amsterdam UMC, Vrije Universiteit Amsterdam, Amsterdam, The Netherlands

⁸Zodiak, Prinsensichting, Purmerend, The Netherlands

Correspondence

Ilan J. N. Koppen, Department of Pediatric Gastroenterology and Nutrition, Emma Children's Hospital, Amsterdam UMC, location University of Amsterdam, Meibergdreef 9, Amsterdam, The Netherlands.
Email: ij.koppen@amsterdamumc.nl

Abstract

Pitt-Hopkins syndrome (PTHS) is a rare neurodevelopmental disorder caused by mutations of the transcription factor 4 (Tcf4) gene. Individuals with PTHS often suffer from severe abdominal bloating and constipation. In this short communication, we discuss two individuals with PTHS who died unexpectedly due to gastrointestinal complications. We aim to increase awareness among healthcare professionals who care for individuals with PTHS, to ensure adequate screening and management of gastrointestinal symptoms in this population. Moreover, we discuss how fatal gastrointestinal complications may be related to PTHS and provide an overview of the literature.

KEYWORDS

aerophagia, bloating, volvulus, constipation, pitt-hopkins, tcf4

1 | INTRODUCTION

Pitt-Hopkins syndrome (PTHS; OMIM #610954) is a rare neurodevelopmental disorder caused by mutations of the transcription factor 4 (Tcf4) gene. PTHS was first described in 1978, it is rare and estimated to occur in 1:34,000 to 1:41,000 (Goodspeed et al., 2018). PTHS is characterized by intellectual disability, specific dysmorphic features, and marked autonomic nervous system dysfunction (Zollino et al., 2019). Associated physical problems include myopia, strabismus,

epilepsy, constipation, and abnormal breathing characterized by episodes of hyperventilation and apneic spells (Zollino et al., 2019). Many individuals with PTHS have autism spectrum disorders, and language acquisition is generally limited to single words or short phrases.

We present two young adults with PTHS who suffered from severe abdominal bloating and constipation since childhood. One individual had a percutaneous endoscopic gastrostomy (PEG) via which she received enteral feeding and a Chait percutaneous cecostomy catheter used to treat her constipation with antegrade continence

This is an open access article under the terms of the [Creative Commons Attribution](https://creativecommons.org/licenses/by/4.0/) License, which permits use, distribution and reproduction in any medium, provided the original work is properly cited.

© 2022 The Authors. *American Journal of Medical Genetics Part A* published by Wiley Periodicals LLC.

enemas. Both adults died unexpectedly due to gastrointestinal complications. Mortality related to gastrointestinal symptoms has not yet been described in individuals with PTHS. We point out how fatal gastrointestinal complications may be related to PTHS and provide a brief overview of the literature. With this report, we aim to increase awareness among healthcare professionals who care for individuals with PTHS or other syndromes with similar comorbidities.

2 | CASE 1

A 21-year old woman with PTHS caused by a deletion of exon 7–11 in *TCF4* (NM_001083962.1, c.370-?_922 +?; p.?), lived at home with her parents. She had a severe intellectual disability, did not communicate verbally and had limited walking abilities. She had suffered from epilepsy as a child but had not experienced seizures since the age of 10 years. She suffered from severe abdominal bloating, her PEG was used both for feeding and to deflate and decompress the stomach intermittently. For severe refractory constipation, she received oral laxatives (polyethylene glycol), and antegrade continence enemas via a Chait percutaneous cecostomy catheter. The Chait was also used to deflate the colon during moments of severe abdominal distension. Abdominal distension often followed episodes of hyperventilation, which resulted in episodic irritability and discomfort. Because the episodes of abnormal breathing seemed to be related to her abdominal distension, she was considered to suffer from aerophagia.

On the day of her death, antegrade colonic irrigation was more difficult than usual; the irrigation fluid (2–2.5 L) was not evacuated as usual. After the irrigation, she was clearly uncomfortable and in pain. Later, she began to vomit and a red, dark fluid was aspirated from the Chait cecostomy catheter. Upon arrival at the emergency department, she was in circulatory shock, with a painful, distended abdomen, and laboratory tests showing a metabolic acidosis in a venous blood sample (pH 7.07, pCO₂ 8.5 kPa, HCO₃ 18 mmol/L, BE –13.5, and lactate 8.1 mmol/L). A CT scan of the abdomen (Figure 1) confirmed a correct position of the PEG tube in the stomach and of the Chait cecostomy catheter in the cecum. Abnormal findings included free air and free

fluid, consistent with fecal peritonitis. Most of the small bowel was dilated except for the distal ileum. The duodenum and the duodenojejunal junction were located on the right side, consistent with a malrotation. The duodenum was not dilated. In addition to the malrotation, a whirl sign of the mesentery was seen in the right hemi abdomen suggesting a volvulus or an internal herniation. There was a close relation of this whirl sign with the distal ileum and the ascending colon, suggesting a possible obstruction in this region. A perforation was suspected in this area, but could not be identified. Furthermore, the CT showed an interposition of the colon between the right hemidiaphragm and the liver (Chilaiditi sign).

The option of emergency surgery was considered and discussed with the parents. However, due to the severity of her clinical condition and the fact that parents had previously decided not to resuscitate her in life threatening circumstances, palliative management was initiated. She died that same day, autopsy was offered to the family, but not performed.

3 | CASE 2

A 25-year old woman with PTHS caused by a deletion of exon 15 (c.1341_1344delTTCA; p.(Leu449Trpfs12)) in *TCF4*, was living at a residential home. She had a profound intellectual disability, absent speech and limited walking abilities. Her severe constipation was treated with oral laxatives (polyethylene glycol and bisacodyl). Over the course of her life, she was repeatedly found to have a severely distended stomach, small bowel and colon upon abdominal radiography (Figure 2).

She had been less active for 2 days, with normal vital signs. On the third day she was found in bed, ill-appearing. Upon arrival at the emergency department, she was in a circulatory shock, with an acute abdomen with severe abdominal distension. A venous blood sample showed a metabolic acidosis (pH 7.01, pCO₂ 7.1 kPa, HCO₃ 14 mmol/L, BE –26.5, and lactate 13.9 mmol/L). An intestinal perforation and sepsis were suspected. The medical team and the parents discussed the option of emergency surgery but decided to opt for

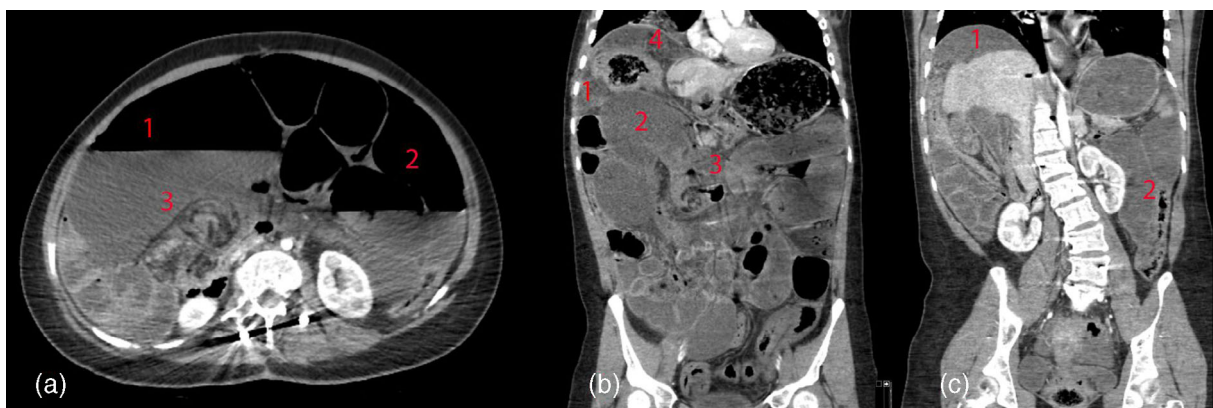


FIGURE 1 Case 1—CT imaging studies. (1) Free intraperitoneal air and fluid; (2) distended bowel; (3) whirl sign/mesenteric rotation; and (4) Chilaiditi sign

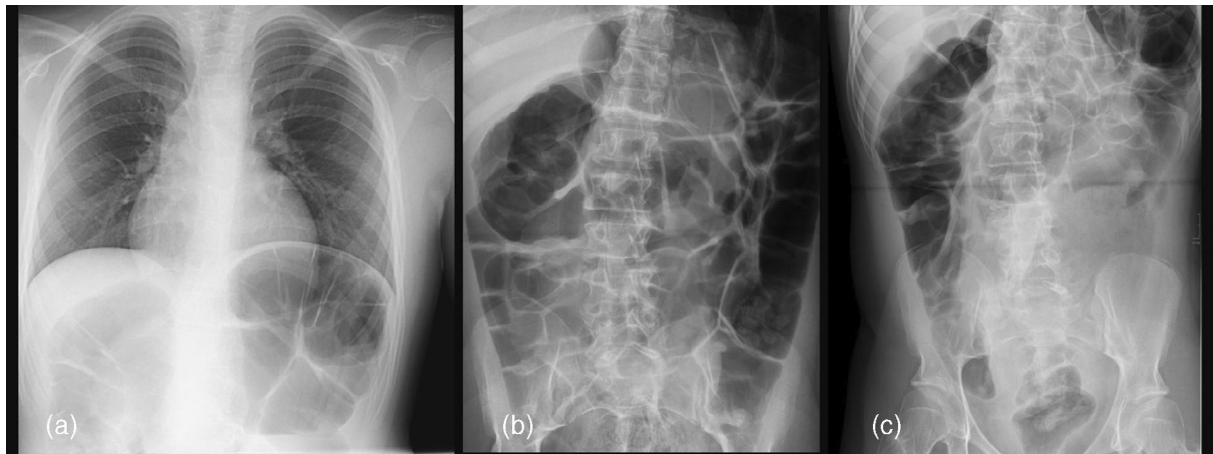


FIGURE 2 Case 2—Imaging studies at 13, 18, and 19 years of age

palliative management given the severity of her underlying condition in combination with her unstable current situation. She died that same day; autopsy was offered to the family, but not performed.

4 | DISCUSSION

We present two young adults with PTHS and a history of constipation and abdominal distension, who died due to gastrointestinal complications. In both cases, these fatal gastrointestinal complications were likely related to PTHS. Among other health problems, individuals with PTHS have severely impaired communication skills to express pain and discomfort, which compromises early warning signals and makes them susceptible for fulminant complications of chronic health problems.

Gastrointestinal problems are commonly seen in PTHS and often present as severe abdominal bloating and constipation (Zollino et al., 2019). The etiology of abdominal bloating in PTHS is not entirely understood, but has been reported to coincide with episodes of dysregulated breathing (Zollino et al., 2019). This could suggest that individuals with PTHS are prone to suffer from aerophagia. Aerophagia is a functional gastrointestinal disorder, involving excessive air swallowing, resulting in abdominal distension (Hyams et al., 2016). Aerophagia is generally considered to be a relatively benign condition, but has been associated with colonic volvulus (Trillis Jr. et al., 1986; van der Kolk et al., 1999) and colonic perforation (Basaran et al., 2007; Lopez et al., 2020; Zvizdic et al., 2019), sometimes even resulting in death. These severe complications of aerophagia are more commonly reported in individuals with intellectual disabilities. Another common gastrointestinal symptom in individuals with PTHS is constipation, which may be so severe that Hirschsprung disease is frequently suspected (de Winter et al., 2016; Goodspeed et al., 2018). Conventional management of constipation is recommended for individuals with PTHS (Zollino et al., 2019). In one of the reported cases, severe constipation had required treatment with antegrade continence enemas

via a Chait percutaneous cecostomy catheter. Severe constipation is also a known risk factor for developing a sigmoid volvulus (Altaf et al., 2009).

The association between PTHS and gastrointestinal symptoms, such as abdominal bloating or constipation, is incompletely understood. A study by Grubišić et al. has shown that mice heterozygous for the deletion of the DNA-binding domain of TCF4, show specific gut malfunctions (Grubišić et al., 2015). Although no gross malformations were detected in intestinal length or pellet output, upper gastrointestinal and distal colon transit velocities were significantly reduced compared to wild-type animals. This indicates that the PTHS mouse model shows similar gut problems as seen in humans with PTHS. However, currently no other studies have investigated the molecular and cellular mechanisms underlying the specific gut problems seen upon a heterozygous depletion of TCF4.

Post-mortem examination was not performed in the two reported cases and therefore the cause of death remains uncertain. In the first case, a CT-scan revealed severely distended small bowels, evidence of a malrotation, and a whirl sign suggesting a volvulus or an internal herniation. Malrotation has been described in up to 16% of individuals with PTHS (Goodspeed et al., 2018; Hasi et al., 2011). In this specific case, malrotation may have played a role in the etiology of severe constipation and has likely predisposed to the development of volvulus, resulting in a fatal complication. Therefore, we suggest that individuals with PTHS who suffer from severe constipation should be carefully screened for underlying causes, including malrotation, to enable early detection and surgical management if needed. One of the cases suffered from long-standing severe abdominal bloating despite the fact that her PEG and Chait percutaneous cecostomy catheter were used to deflate the gastrointestinal tract. This suggests that despite these two catheters, the bowel could not be adequately vented and decompressed. We suspect that this severe form of intraluminal airtrapping could be related to hyperventilation and air swallowing in combination with an underlying motility disorder, and malrotation, which may all have contributed to the development of a

volvulus (Goodspeed et al., 2018; Zollino et al., 2019). Another hypothesis is that the treatment with antegrade continence enemas via the Chait percutaneous cecostomy catheter could have resulted in an intestinal perforation. In the other case, severe bloating had been present for several years, with distended bowel loops on previous abdominal radiographs. Due to the lack of imaging studies at presentation and due to the fact that no autopsy was performed, the cause of death remains inconclusive. However, we suspect that aerophagia and constipation may have resulted in severe abdominal distension, and perforation with or without a volvulus. Autopsy could have provided a better understanding of the etiology of the gastrointestinal complications in these cases, but was not performed. In similar future cases, autopsy may help to unravel underlying pathogenical mechanisms in more detail.

In conclusion, healthcare professionals involved in the treatment of individuals with PTHS should always be aware that dangerous complications can occur as a consequence of severe abdominal distension and constipation. A disordered breathing pattern and motility disorders are likely to be risk factors for severe abdominal distension in PTHS. Although mortality related to functional gastrointestinal disorders is very rare in the general population, based on the report of these two cases the incidence may be higher in individuals with PTHS, although other causes of death were not fully excluded. Therefore, in individuals with PTHS or other syndromic entities with similar comorbidities, careful monitoring and proactive treatment of gastrointestinal symptoms such as severe constipation or abdominal bloating are of key importance.

AUTHOR CONTRIBUTIONS

Ilan J. N. Koppen: Acquisition of data; interpretation of data; literature review; drafted and revised the manuscript; Approved the final version of the manuscript. **Leonie A. Menke:** Literature review; critically revised the manuscript; Approved the final version of the manuscript. **Wyske M. Westra:** Acquisition of data; critically revised the manuscript; Approved the final version of the manuscript. **Femke Struik:** Acquisition of data; Creation of figures; Critically revised the manuscript; Approved the final version of the manuscript. **Simone Mesman:** Interpretation of data; literature review; critically revised the manuscript; Approved the final version of the manuscript. **Michiel P. van Wijk:** Literature review; critically revised the manuscript; Approved the final version of the manuscript. **Sylvia A. Huisman:** Acquisition of data; interpretation of data; literature review; drafted and revised the manuscript; Approved the final version of the manuscript.

ACKNOWLEDGMENTS

We thank the parents of the individuals who are discussed in this manuscript for their cooperation. Parental consent was obtained for publication of the case details.

CONFLICT OF INTEREST

The authors declare that there is no conflict of interest.

DATA AVAILABILITY STATEMENT

The data that support the findings of this study are available on request from the corresponding author. The data are not publicly available due to privacy or ethical restrictions.

ORCID

Ilan J. N. Koppen  <https://orcid.org/0000-0002-1856-0968>

REFERENCES

- Altaj, M. A., Werlin, S. L., Sato, T. T., Rudolph, C. D., & Sood, M. R. (2009). Colonic volvulus in children with intestinal motility disorders. *Journal of Pediatric Gastroenterology and Nutrition*, 49(1), 59–62.
- Basaran, U. N., Inan, M., Aksu, B., & Ceylan, T. (2007). Colon perforation due to pathologic aerophagia in an intellectually disabled child. *Journal of Paediatrics and Child Health*, 43(10), 710–712.
- de Winter, C. F., Baas, M., Bijlsma, E. K., van Heukelingen, J., Routledge, S., & Hennekam, R. C. (2016). Phenotype and natural history in 101 individuals with Pitt-Hopkins syndrome through an internet questionnaire system. *Orphanet Journal of Rare Diseases*, 11, 37.
- Goodspeed, K., Newsom, C., Morris, M. A., Powell, C., Evans, P., & Golla, S. (2018). Pitt-Hopkins syndrome: A review of current literature, clinical approach, and 23-patient case series. *Journal of Child Neurology*, 33(3), 233–244.
- Grubišić, V., Kennedy, A. J., Sweatt, J. D., & Parpura, V. (2015). Pitt-Hopkins mouse model has altered particular gastrointestinal transits In vivo. *Autism Research*, 8(5), 629–633.
- Hasi, M., Soileau, B., Sebold, C., Hill, A., Hale, D. E., O'Donnell, L., et al. (2011). The role of the TCF4 gene in the phenotype of individuals with 18q segmental deletions. *Human Genetics*, 130(6), 777–787.
- Hyams, J. S., Di Lorenzo, C., Saps, M., Shulman, R. J., Staiano, A., & van Tilburg, M. (2016). Functional disorders: Children and adolescents. *Gastroenterology*, 150, 1456–1468.e2.
- Lopez, C. M., Kovler, M. L., & Jelin, E. B. (2020). Case report of extreme gastric distention and perforation with pathologic *Sarcina ventriculi* colonization and Rett syndrome. *International Journal of Surgery Case Reports*, 73, 210–212.
- Trillis, F., Jr., Gauderer, M. W., Ponsky, J. L., & Morrison, S. C. (1986). Transverse colon volvulus in a child with pathologic aerophagia. *Journal of Pediatric Surgery*, 21(11), 966–968.
- van der Kolk, M. B., Bender, M. H., & Goris, R. J. (1999). Acute abdomen in mentally retarded patients: Role of aerophagia. Report of nine cases. *The European Journal of Surgery*, 165(5), 507–511.
- Zollino, M., Zweier, C., Van Balkom, I. D., Sweetser, D. A., Alaimo, J., Bijlsma, E. K., Cody, J., Elsea, S. H., Giurgea, I., Macchiaiolo, M., Smigiel, R., Thibert, R. L., Benoist, I., Clayton-Smith, J., De Winter, C. F., Deckers, S., Gandhi, A., Huisman, S., Kempink, D., ... Hennekam, R. C. (2019). Diagnosis and management in Pitt-Hopkins syndrome: First international consensus statement. *Clinical Genetics*, 95(4), 462–478.
- Zvizdic, Z., Jonuzi, A., Djuran, A., & Vranic, S. (2019). Gastric necrosis and perforation following massive gastric dilatation in an adolescent girl: A rare cause of acute abdomen. *Frontiers in Surgery*, 6, 3.

How to cite this article: Koppen, I. J. N., Menke, L. A., Westra, W. M., Struik, F., Mesman, S., van Wijk, M. P., & Huisman, S. A. (2023). Fatal gastrointestinal complications in Pitt-Hopkins syndrome. *American Journal of Medical Genetics Part A*, 191A: 855–858. <https://doi.org/10.1002/ajmg.a.63079>