



UvA-DARE (Digital Academic Repository)

Looking at the bigger picture: Cortical volume, thickness and surface area characteristics in borderline personality disorder with and without posttraumatic stress disorder

Vatheuer, C.C.; Dzionsko, I.; Maier, S.; Näher, T.; van Zutphen, L.; Sprenger, A.; Jacob, G.A.; Arntz, A.; Domes, G.

DOI

[10.1016/j.psychresns.2021.111283](https://doi.org/10.1016/j.psychresns.2021.111283)

Publication date

2021

Document Version

Final published version

Published in

Psychiatry Research - Neuroimaging

License

Article 25fa Dutch Copyright Act

[Link to publication](#)

Citation for published version (APA):


Vatheuer, C. C., Dzionsko, I., Maier, S., Näher, T., van Zutphen, L., Sprenger, A., Jacob, G. A., Arntz, A., & Domes, G. (2021). Looking at the bigger picture: Cortical volume, thickness and surface area characteristics in borderline personality disorder with and without posttraumatic stress disorder. *Psychiatry Research - Neuroimaging*, 311, [111283]. <https://doi.org/10.1016/j.psychresns.2021.111283>

General rights

It is not permitted to download or to forward/distribute the text or part of it without the consent of the author(s) and/or copyright holder(s), other than for strictly personal, individual use, unless the work is under an open content license (like Creative Commons).

Disclaimer/Complaints regulations

If you believe that digital publication of certain material infringes any of your rights or (privacy) interests, please let the Library know, stating your reasons. In case of a legitimate complaint, the Library will make the material inaccessible and/or remove it from the website. Please Ask the Library: <https://uba.uva.nl/en/contact>, or a letter to: Library of the University of Amsterdam, Secretariat, Singel 425, 1012 WP Amsterdam, The Netherlands. You will be contacted as soon as possible.



Research Report



Looking at the bigger picture: Cortical volume, thickness and surface area characteristics in borderline personality disorder with and without posttraumatic stress disorder

C. Carolyn Vatheuer^a, Inga Dzionsko^a, Simon Maier^b, Tim Näher^a, Linda van Zutphen^c, Andreas Sprenger^d, Gitta A. Jacob^e, Arnoud Arntz^f, Gregor Domes^{a,g,*}

^a Department of Biological and Clinical Psychology, University of Trier, Johanniterufer 15, 54290 Trier, Germany

^b Department of Psychiatry and Psychotherapy, Section for Experimental Neuropsychiatry, Medical Center, University of Freiburg, Freiburg, Germany

^c Department of Clinical Psychological Science, Faculty of Psychology and Neuroscience, Maastricht University, Maastricht, The Netherlands

^d Department of Neurology, University of Lübeck, Lübeck, Germany

^e Department of Clinical Psychology and Psychotherapy, University of Freiburg, Freiburg, Germany

^f Department of Clinical Psychology, University of Amsterdam, Amsterdam, The Netherlands

^g Institute of Psychobiology, University of Trier, Trier, Germany

ARTICLE INFO

Keywords:

Borderline personality
Comorbidity
Magnetic resonance imaging
Voxel-based morphometry
Cortical complexity
Gyrification

ABSTRACT

Borderline personality disorder (BPD) is a severe psychiatric disorder accompanied by multiple comorbidities. Neuroimaging studies have identified structural abnormalities in BPD with most findings pointing to gray matter volume reductions in the fronto-limbic network, although results remain inconsistent. Similar alterations were found in posttraumatic stress disorder (PTSD), a common comorbidity of BPD. Only a small number of studies have investigated structural differences in BPD patients regarding comorbid PTSD specifically and studies conducting additional surface analyses are scarce. We investigated structural differences in women with BPD with and without PTSD and non-patient controls. Automated voxel-based and region-based volumetric analyses were applied. Additionally, four surface-based measures were analyzed: cortical thickness, gyrification index, fractal dimension, and sulcus depth. Analyses did not identify cortical volume alterations in the fronto-limbic network. Instead, hypergyrification was detected in the right superior parietal cortex in BPD patients compared to non-patient controls. No distinction was revealed between BPD patients with and without PTSD. These findings underline the importance of a holistic investigation examining volumetric and surface measures as these might enhance the understanding of structural alterations in BPD.

1. Introduction

Borderline personality disorder (BPD) is a severe psychiatric disorder characterized by affective instability, unstable and intense interpersonal relationships, identity disturbances, and impulsive and recurrent suicidal behavior (American Psychiatric Association, 2013; Lieb et al., 2004). Prevalence estimates range between 1.6% (Torgersen, 2009) and 5.9% (Grant, 2009). Up until recently, BPD was assumed to be three times more common in women (Leichsenring et al., 2011; Lieb et al., 2004). Growing evidence suggests that these sex differences might be mediated by concomitant factors of BPD such as comorbidities (Grant, 2009).

BPD is often accompanied by multiple comorbid clinical and

personality disorders, with posttraumatic stress disorder (PTSD) being one of the most prevalent (diagnosed in 39.2% of BPD patients), especially among women (Grant, 2009). In the etiology of BPD, the experience of traumatic events such as ongoing sexual abuse during childhood and adolescence interacting with genetics has been identified as potential influences on both onset and symptom severity of BPD (Amad et al., 2014; O'Neill and Frodl, 2012; Zanarini et al., 2002). Due to the typically diagnosed cumulative disorders, BPD patients face many challenges in their everyday life affecting their social network, frequently leading to unemployment. Successful treatment remains a great challenge and has led to high costs for the public health system (e.g. Fassbinder et al., 2016; Jerschke et al., 1998; van Asselt et al., 2007; Wunsch et al., 2014).

* Corresponding author.

E-mail address: domes@uni-trier.de (G. Domes).

<https://doi.org/10.1016/j.psychresns.2021.111283>

Received 13 November 2020; Received in revised form 5 March 2021; Accepted 19 March 2021

Available online 22 March 2021

0925-4927/© 2021 Elsevier B.V. All rights reserved.

Brain imaging studies have attempted to contribute towards overcoming the treatment challenge by clarifying the neurological profiles specific to the disorder. Automated gray matter volume (GMV) methods, which have greatly improved over the past two decades, are used to attempt to identify structural brain abnormalities key to BPD and elucidate patterns of abnormalities across regions of the brain. Contrary to manual tracing methods which require the definition of regions of interest by trained physicians, voxel-based morphometry (VBM) enables an objective and more time-efficient investigation of group differences in local GMV with high regional specificity across the brain (Kurth et al., 2015).

Several studies on BPD have identified structural alterations in the fronto-limbic system (Yang et al., 2016), but results are very heterogeneous and diverging patterns have been reported. For instance, reduced GMVs have been found in the hippocampus, amygdala, right anterior cingulate cortex (ACC) and left orbitofrontal cortex (OFC; Tebartz van Elst et al., 2003), while reduced right OFC but no reductions in hippocampus and amygdala have been reported recently (Nenadić et al., 2020). An older meta-analysis reported only bilateral hippocampus and amygdala reductions (Nunes et al., 2009), but a recent meta-analysis highlighted decreased GMV in the amygdala, medial prefrontal cortex (mPFC), right parahippocampal gyrus and bilateral ACC (Yu et al., 2019). Yet another meta-analysis reported a different and more extensive pattern of reduced bilateral medial temporal gyrus (MTG), right inferior frontal gyrus (IFG), right insula, left hippocampus, left middle occipital gyrus (MOG), left superior frontal gyrus (SFG), and left OFC and increased supplementary motor area (SMA), right posterior cingulate cortex (PCC), bilateral primary motor cortex (PMC), right middle frontal gyrus (MFG) and bilateral precuneus, but no alterations in amygdala and ACC GMVs (Yang et al., 2016). One review of studies reported that reduced hippocampal volumes have been found more consistently in BPD patients (O'Neill and Frodl, 2012), while findings in the amygdala have been varied, with decreases, increases and no volumetric differences being reported (O'Neill and Frodl, 2012). Meta-analyses have appeared to struggle with encompassing a more complete combination of studies due to varying methods and samples. It has been suggested that inconsistencies in the pattern of structural alterations may also be due to existing comorbid disorders such as PTSD (Nenadić et al., 2020; O'Neill and Frodl, 2012).

Similarly to findings in BPD, GMV reduction patterns comprising the hippocampus, amygdala and ACC (bilaterally) have been reported in PTSD patients (Kitayama et al., 2005; O'Doherty et al., 2015). To identify common and distinct patterns of GMV, a small number of studies investigated groups of BPD patients with and without comorbid PTSD. However, results from these studies are also heterogeneous. One study reported reduced hippocampal volumes only in BPD patients with PTSD (Schmahl et al., 2009), while another found similar reduction patterns regardless of comorbid PTSD or experienced trauma (Weniger et al., 2009). In contrast, Niedtfeld and colleagues (2013) reported increased GMV in the superior temporal gyrus and the dorsolateral prefrontal cortex (DLPFC), but only in BPD patients with PTSD. The results of these few studies indicate that structural abnormalities in BPD patients might indeed vary depending on comorbidity. Nevertheless, findings remain inconsistent and further studies are needed to specify the characteristics of these alterations.

While volumetric abnormalities in BPD patients have been investigated more extensively, studies employing surface measures in the investigation of structural abnormalities in BPD remain sparse. Surface-based morphometry (SBM) can be used to analyze cortical thickness (CT) as well as cortical complexity (referring to the degree of cortical folding) with gyrification index (GI), fractal dimension (FD), and sulcus depth (SD) measures. The development of cortical complexity occurs early in life, rendering GI and SD to be candidate measures of pre- and postnatal brain development (de Araujo Filho et al., 2014; Depping et al., 2018; Yotter et al., 2011b). Previous BPD studies have mainly focused on CT; for instance, cortical thinning has been reported in the

left mPFC, lateral PFC, left temporoparietal junction, temporal poles and paracentral lobules (Boen et al., 2014), as well as the right medial OFC (de Araujo Filho et al., 2014). Contrary to these findings, other studies found no differences in CT in BPD compared to non-patient controls (Richter et al., 2014) or reported increased CT in the DLPFC (Bruehl et al., 2013). Additionally, in healthy individuals, CT has been negatively associated with impulsivity, one of the traits of BPD (Kubera et al., 2018). Although these findings are even more inconsistent than reported volumetric differences, most studies point to cortical thinning in BPD.

Similarly, findings regarding PTSD-related abnormalities in surface measures mainly report a pattern of reduced CT, e.g. in the bilateral superior and middle frontal gyri, left inferior frontal gyrus and left superior temporal gyrus (Geuze et al., 2008). Additionally, studies found a negative association between PTSD symptom severity and CT in the postcentral gyri and middle temporal gyri (Lindemer et al., 2013), as well as the PFC (Heyn and Herringa, 2019; Wrocklage et al., 2017). In contrast, a recent study found no difference in CT in adolescents with PTSD compared to controls, more specifically in the ventromedial PFC, ACC, insula, as well as the middle and superior temporal gyrus (Rinne-Albers et al., 2020). In the same vein, normal CT was also reported in women with a history of sexual abuse and PTSD (Landré et al., 2010).

Only a small number of studies have investigated surface measures other than CT in BPD. Despite using different methods, these studies also point to reductions: one study found reduced SD in the right mOFC (de Araujo Filho et al., 2014), while another reported hypogyrfication in the precuneus, superior parietal gyrus and parahippocampal gyrus (Depping et al., 2018). The only study of BPD patients with and without PTSD (that the authors are aware of to date) found increased CT in the DLPFC only in women with BPD but without PTSD (Bruehl et al., 2013).

Taken together, similar structural reduction patterns can be found in BPD and PTSD, indicating the importance of investigating differences in BPD patients with and without PTSD (Schmahl et al., 2003). In addition to volume-based measures, there is a high need for studies investigating surface-based measures which hold an incremental value to VBM (Anticevic et al., 2008).

Therefore, we aimed to examine the structural reduction pattern in BPD compared to non-patient controls (NPC), using both volume and surface measures. Furthermore, this study incorporates a more specific comparison of BPD patients with and without PTSD. We hypothesized that 1) BPD patients will show reductions in volume, thickness and cortical folding measures compared to NPC, with GMV reductions being expected especially in the bilateral hippocampus, amygdala, ACC, and DLPFC, and 2) these reductions will be more pronounced in BPD patients with PTSD compared to BPD patients without PTSD.

We conducted voxel-wise and region-based approaches to investigate GMV and surface measure differences. We also implemented a small volume correction (SVC) method to provide a comparison to studies that additionally restricted voxel-wise analysis to specific pre-selected regions (Labudda et al., 2013; Niedtfeld et al., 2013).

2. Methods

2.1. Participants

Brain images were acquired from $n = 110$ females of which 11 were excluded due to insufficient image quality ($n = 6$), incidental neurological findings ($n = 2$), missing psychometric data ($n = 2$), and $IQ < 70$ ($n = 1$). Of the remaining sample, $n = 18$ were BPD patients with comorbid PTSD (BPDwPTSD), $n = 39$ were BPD patients without comorbid PTSD (BPDwoPTSD), and $n = 42$ were NPC. BPD patients were diagnosed using the Structural Clinical Interview I (SCID I; First et al., 1994) and II (SCID II; First et al., 1997), assessed by trained interviewers. PTSD and additional comorbid clinical and personality disorders were also assessed with the SCID I and II, and the current medication status of the patients was acquired. BPD patients were excluded if they presented with additional full or subthreshold narcissistic or antisocial personality

disorders.

Further disease-specific diagnostic instruments were used to assess symptom severity and trauma experiences. These instruments included the Borderline Personality Disorder Severity Index (BPDSI, inclusion at score > 20; Arntz et al., 2003; Giesen-Bloo et al., 2010), the BPD checklist (Arntz, A. and Dreesen, L., 1995), the Brief Symptom Inventory (BSI; Derogatis, 1993; Derogatis and Melisaratos, 1983), and the Interview for Trauma Events in Childhood (ITEC; Lobbetael et al., 2009; Lobbetael et al., 2006). NPC also underwent a diagnostic screening using the SCID I and II and the assessment of the BSI, the BPD checklist and the ITEC, in order to rule out any clinical or personality disorders and clinical abnormalities.

Group comparisons of psychometric data were analyzed in SPSS (v26, IBM Corp., Armonk, NY, USA). Sample characteristics and distribution of participants scanned at the different sites are displayed in Table 1.

Groups did not significantly differ in age or estimated IQ and the majority of participants were right-handed. Welch-ANOVAs for the BSI, BPD checklist and ITEC were followed up by Games-Howell post-hoc tests. NPC had significantly lower scores than both BPD groups in the BSI, BPD checklist and ITEC ($p < .001$). BPD patients did not differ in the BPD checklist ($p = .245$) depending on PTSD diagnosis. However, BPDwPTSD showed significantly higher scores than BPDwoPTSD in the BSI ($p = .004$) and the ITEC ($p = .012$). Overall medication usage did not differ between BPDwPTSD and BPDwoPTSD ($\chi^2(1) = 2.176, p = .140$).

Obtaining equal samples from different centers was not achieved; an aspect that is difficult to accomplish in multicenter patient studies. See Supplemental Materials for further information on sample exclusions and characteristics including detailed medication status (Table S1) and additional comorbid disorders of BPD patients (Table S2).

Table 1
Sample characteristics.

Variable	BPDwPTSD (n = 18)	BPDwoPTSD (n = 39)	NPC (n = 42)	Statistical Test	P
Age in years	31.6 (11.7)	29.2 (7.09)	28.6 (10.3)	$F(2,96) = 0.639$.530
Estimated IQ	95.0 (8.2)	99.3 (10.3)	101.6 (11.4)	$F(2,96) = 2.520$.086
BPDSI Total	30.57 (6.31)	32.33 (7.54)	–	$t(55) = -0.861$.393
BSI Total ^a	2.09 (0.57)	1.54 (0.46)	0.19 (0.25)	$F(2,38.0) = 193.32$	<0.001
BPD Checklist ^{a,b}	128.17 (24.59)	116.39 (26.79)	53.81 (10.07)	$F(2,36.3) = 153.67$	<0.001
ITEC Total ^a	86.77 (36.85)	56.14 (30.26)	6.7 (8.5)	$F(2,33.8) = 83.83$	<0.001
Handedness (n, left/ right/ mixed)	1/15/2	3/35/1	1/41/0	$\chi^2(4) = 6.633$.157
Scanner site (n)					
Freiburg (GER)	3	13	16		
Lübeck (GER)	14	15	17		
Maastricht (NL)	1	11	9		

^a Tested with Welch-ANOVA due to heteroscedasticity.

^b Data unavailable for one NPC. **Abbreviations:** BPD = Borderline Personality Disorder, PTSD = Posttraumatic Stress Disorder, NPC = non-patient controls. BPDSI = Borderline Personality Disorder Severity Index; BSI = Brief Symptom Inventory; ITEC = Interview for Trauma Events in Childhood.

2.2. MRI acquisition

This study is part of an international multicenter RCT and data comes from the baseline scanning session (Baczkowski et al., 2017; van Zutphen et al., 2019, 2018). Participants were scanned in Freiburg (GER), Lübeck (GER), and Maastricht (NL) and gave written informed consent at the beginning of the testing session.

The following 3T scanners were used for MRI acquisition: Maastricht: Magnetom Allegra (Siemens Healthineers, Erlangen, Germany) head-only scanner, birdcage head coil; Freiburg: Tim-Trio Magnetom (Siemens Healthineers, Erlangen, Germany) whole body scanner, 8-channel head coil; Lübeck: Achieva (Philips Healthcare, Best, Netherlands) whole body scanner, 8-channel head coil. The structural T1-weighted sequences were acquired with the following parameters: TE = 2.6 ms, TR = 2250 ms, flip angle = 9°, FOV = 256 × 256 mm², voxel size = 1 × 1 × 1 mm³. Importantly, quality assurance measures from Computational Anatomy Toolbox (CAT12; <http://dbm.neuro.uni-jena.de/cat/>) demonstrated that there was no difference in quality of scans between the different scanner sites. Detailed descriptions on recruitment and scanning procedure can be found in Supplemental Materials. The study was approved by the local ethics committees at each site.

2.3. Voxel-based GMV and surface-based morphometry

Data pre-processing and analysis of structural images were carried out using CAT12 for SPM12 (rev7487; <https://www.fil.ion.ucl.ac.uk/spm/>) in MATLAB R2018a (MathWorks, MA, USA). Pre-processing steps were applied as described in the CAT12 manual (Gaser and Kurth, 2017). Affine-registered images were segmented into GM, white matter (WM), and cerebrospinal fluid (CSF) after denoising and bias-correction (Ashburner and Friston, 2005). Segmentation was refined by using the Adaptive Maximum-A-Posteriori (AMAP) estimation approach, extended by accounting for partial volume effects. The Diffeomorphic Anatomic Registration Through Exponentiated Lie (DARTEL) algorithm was used for spatial normalization. Normalized segmented images were then modulated by linear and non-linear deformation (Jacobian determinant). Accordingly, estimated total intracranial volume was extracted in order correct of individual brain size in analysis. Next, surface and thickness projection-based estimations (Dahnke et al., 2013; Gaser and Kurth, 2017) with topological correction of brain surface meshes (Yotter et al., 2011a) were carried out in order to acquire the four surface measures CT, GI (based on absolute mean curvature, Luders et al., 2006), FD (Yotter et al., 2011b), and SD (Gaser and Kurth, 2017). Finally, data was checked for sample homogeneity and images were smoothed with an 8 mm kernel for GMV, 15 mm kernel for CT and 20 mm kernel for cortical folding measures (GI, SD, FD), as recommended (Gaser and Kurth, 2017). An absolute gray matter threshold of 0.1 was applied for excluding edge effect artefacts.

2.4. Region-based analysis of GMV and surface data

Automated analyses were conducted using a region-based approach, carried out in CAT12 for both volume-based and surface-based measures for all brain regions. This type of approach estimates mean values (cm³) of regions by averaging across voxels within each region of an atlas, allowing detection of differences regardless of whether specific voxels overlap. For GMV the Neuromorphometrics atlas (provided in CAT12 by Neuromorphometrics, Inc. under academic subscription, <http://Neuromorphometrics.com/>) in DARTEL space was used and for the surface measures the “Desikan-Killiany-Tourville” Brain Atlas (Desikan et al., 2006) was applied.

2.5. Voxel-based GMV analysis of preselected regions (SVC)

Additionally, we conducted GMV analysis restricted to specific volumes using a voxel-based SVC approach that has been implemented by

previous studies (Kuhlmann et al., 2013; Labudda et al., 2013; Niedtfeld et al., 2013). To attempt replication of previous findings from this approach, four masks were applied to the whole brain using the Neuromorphometrics atlas in DARTEL space corresponding to the preselected regions: the bilateral hippocampus, amygdala, ACC, and DLPFC (the middle frontal gyrus and inferior frontal gyrus combined).

As the goal of including this approach was specifically to attempt replication of the dominant fronto-limbic VBM findings (and especially in subcortical regions) in this field, the SVC method was only applied to GMV data and not surface data.

2.6. Statistical analysis

Whole brain voxel-based analyses were carried out in CAT12 using the full factorial option to set up five ANCOVA models with factor group (BPDwPTSD, BPDwoPTSD, NPC), one for each of the dependent variables GMV, CT, GI, FD, and SD. Age and scanner site were added as covariates of no interest. For GMV, TIV was also added as a covariate to account for different brain sizes. Differences between all BPD patients and NPC were examined via *t*-contrasts (first hypothesis). In order to investigate PTSD comorbidity effects in BPD patients (second hypothesis), firstly an overall *F*-test of group differences was examined. If significant overall group differences were found via this *F*-test, *t*-contrasts between BPDwPTSD and BPDwoPTSD were examined, masked by the *F*-test result. These analyses were corrected for multiple comparisons using the family-wise error rate (FWE) at voxel level at a threshold of $p < .05$, following the procedure of previous studies (e.g. Besteher et al., 2017; Nickel et al., 2018; Spalthoff et al., 2018).

The same statistical models were applied for all region-based analyses in CAT12. The SVC analyses for the preselected volumes were conducted for GMV in SPM12. If these analyses revealed significant results, corrections for multiple comparisons were applied using the false discovery rate (FDR) at a threshold of $p < .05$, again following the procedure of previous studies (Nickel et al., 2018). *T*- and *F*-tests computed in CAT12 and SPM12 can be found in Supplemental Table S3.

3. Results

3.1. BPD patients vs. non-patient controls

Neither the whole brain voxel-based VBM analysis (FWE-corrected at voxel level), nor the region-based analyses (FDR-corrected) revealed

significant differences between BPD patients and NPCs. The additional SVC method analysis did not reveal significant differences. For completeness, uncorrected results of the SVC analyses of the preselected regions can be found in Supplemental Table S4.

While the whole brain voxel-based analyses for all surface measures did not lead to significant group differences after correction for multiple comparisons (FWE), the region-based analysis in CAT12 revealed hypergyrification in BPD patients compared to NPC in the right superior parietal cortex ($t = 3.43$, $p_{FDR} = 0.03$; Fig. 1). The patient group has a smaller distribution of GI values with a more distinct peak. The distributions of the two groups overlap substantially.

3.2. BPD patients with comorbid PTSD vs. BPD patients without comorbid PTSD

The *F*-test for overall group differences was not significant for GMV in both whole brain voxel-based (FWE-corrected at voxel level) and region-based (FDR-corrected) analyses. Again, SVC analysis did not reveal significant differences between groups in preselected regions. Uncorrected results from the SVC analysis can be found in Supplemental Table S5.

The analysis of surface measures did not reveal any significant group differences in whole brain voxel-based (FWE-corrected at voxel level) and region-based (FDR-corrected) analyses.

4. Discussion

We aimed to replicate the frequently reported volume reduction patterns in fronto-limbic regions in BPD (Nunes et al., 2009; Schmah and Bremner, 2006), with automated procedures for voxel-based and region-based analyses. In our study, which set out to achieve larger clinical sample sizes from a multicenter RCT, group differences were not found between BPD patients and NPC in GMV. Some previously reported GMV alterations were suggested to be gender-specific, for example, with ACC reductions being more common in men (Mancke et al., 2015), which might explain why ACC alterations were not detected in this solely female sample. We are, however, not alone in reporting a lack of findings (e.g. Labudda et al., 2013). Nevertheless, although the pattern of abnormalities has been inconsistent across studies, with some reports of alterations in single areas such as the left amygdala but not in prefrontal regions (Rüsch et al., 2003) or the right orbitofrontal cortex but not the amygdala or hippocampus (Chanen et al., 2008), reductions in the amygdala and hippocampus have been found fairly consistently across studies (Nunes et al., 2009; Ruocco et al., 2012; Schmah and Bremner, 2006), especially in women with BPD (Mancke et al., 2015) and remain the more dominant finding in the literature. Despite a thorough examination that set out to encompass approaches that have been implemented in morphology studies, we could not replicate this pattern of volumetric reduction in fronto-limbic regions.

Our extension with cortical surface analyses did however reveal differences between BPD patients and NPCs. Hypergyrification was found in the right superior parietal cortex in BPD patients compared to NPCs. The superior parietal cortex has been associated with functional properties of cognitive processing, such as attention processes (Corbetta et al., 1995), conscious perception (Kanai et al., 2011), interhemispheric visuo-motor integration (Iacoboni, 2004) and working memory (Coull and Frith, 1998) as well as manipulation of the latter (Koenigs et al., 2009). BPD patients typically show a maladaptation of these cognitive processes resulting in heightened attention to negative stimuli, a negatively biased interpretation of neutral or ambiguous stimuli, as well as better access to negative memories (Baer et al., 2012). Additionally, hypergyrification in the right superior parietal cortex has been associated with increased impulsivity in healthy individuals (Hirjak et al., 2017), which represents a key characteristic of BPD. However, the only other study to our knowledge that investigated abnormalities in cortical complexity in BPD found bilateral hypogyrification in the same region

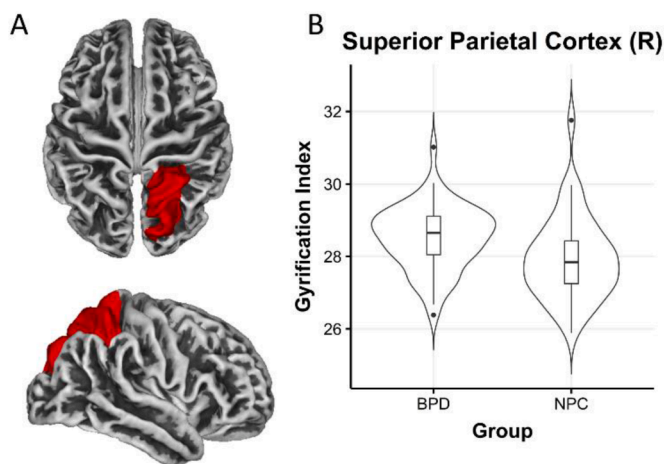


Fig 1. A. The right superior parietal cortex depicted in red (superior and lateral views) where differences in estimated mean values of GI were found in the region-based analysis for the BPD > NPC contrast. Results were FDR-corrected at a threshold of $\alpha = 0.05$. B. Violin plots depicting the distribution of GI values of the right superior parietal cortex region (extracted from region-based analysis in CAT12) for BPD and NPC groups.

(Depping et al., 2018). Although it is difficult to determine contributing factors to the discrepancy, that study included a smaller BPD group without PTSD with a low rate of lifetime MDD comorbidity (5 from 17 patients), and with limited additional information, as the focus was on a separate MDD patient group. Methodological differences could have also played a part, as a different technique was utilized to extract gyrification indices and a more generous smoothing kernel of 25 mm was applied to the data. Abnormal gyrification in BPD and its association with impulsivity and other core symptoms of BPD will need to be investigated more extensively in future studies.

Regarding group comparisons of BPD patients with and without comorbid PTSD, the analyses did not reveal any significant differences in GMV. Although structural reduction patterns were initially expected to be more pronounced in BPDwPTSD, these findings are in line with some previous studies that found many similarities in GMV in PTSD and BPD; that is, in the hippocampus, amygdala and ACC (Kitayama et al., 2005; O'Doherty et al., 2015). Studies comparing GMV in BPD patients with and without PTSD remain scarce but show somewhat similar results regarding reduction patterns, in which the groups did not always differ significantly. For instance, Schmahl and colleagues (2009) found reduced hippocampal volumes exclusively in BPD patients with PTSD compared to NPC while reporting no differences in amygdala volumes. However, Weniger et al. (2009) found reductions in both hippocampus and amygdala in BPD patients compared to NPC, which did not differ depending on comorbid PTSD. Similarly, Niedtfeld et al. (2013) also found reduced GMV in the hippocampus, amygdala, fusiform gyrus, and cingulate gyrus in BPD patients regardless of a diagnosis of comorbid PTSD. These findings suggest that structural differences between BPD patients with and without PTSD might be too subtle to be detected with VBM. Additionally, since no distinction in GMV in BPD patients compared to NPC was identified, it is not surprising that the second more exclusive group comparison did not reveal any significant results either.

It was of special interest to investigate amygdala volumes in this study, as it has also been suggested that alterations in the amygdala might be the key to differentiate between BPD and PTSD, since reductions have been reported in BPD but not in PTSD (Schmahl and Bremner, 2006). Increased volumes of the amygdala have been suggested to be a key characteristic of MDD and thus may be a confounding factor when investigating amygdala volumes in BPD (Nunes et al., 2009). Notably, 88% of BPD patients in this study were diagnosed with comorbid MDD. As highlighted by a study that also had a patient group with high MDD comorbidity rate and reported a lack of volumetric differences between patient and control groups, the absence of reduced amygdala findings might be due to a counter effect of an increased amygdala resulting from MDD (Schmahl et al., 2009). However, MDD comorbidity is very common and other studies with similarly high comorbid MDD prevalence have reported reduced amygdala volumes (Rüsch et al., 2003; Weniger et al., 2009).

This leads to discussing a limitation of studies involving complex patient populations. BPD patients are often diagnosed with more than one comorbid disorder and need medication due to their severe symptomatology (Leichsenring et al., 2011). First, our BPD patients presented with multiple comorbid disorders in addition to PTSD (see Supplemental Table S2), which were unable to be included in the analysis. Thus, it cannot be ruled out that the findings in this study may be confounded by effects of other disorders. Similarly, medication can also influence results in studies with patient populations and in this study, most BPD patients reported taking medication (mainly antidepressants) regularly. Nonetheless, the proportion of patients taking medication in the BPDwPTSD group compared to BPDwPTSD did not differ (see Supplemental Table S2).

Furthermore, the generalizability of results is restricted because an all-female sample was investigated. BPD and PTSD may be more common in women, although this remains debatable as there may be confounding effects with comorbidities and other features of the disorder (Grant, 2009; Leichsenring et al., 2011). For these reasons, a more

homogeneous group with only women was recruited, following the concept of several previous studies (Bøen et al., 2014; Bruehl et al., 2013; de Araujo Filho et al., 2014; Depping et al., 2018; Labudda et al., 2013; Niedtfeld et al., 2013; Richter et al., 2014; Schmahl et al., 2009, 2003). Nevertheless, future studies should consider investigating samples of BPD patients with males as well to identify sex differences in BPD.

Structural brain imaging is frequently used as a tool to investigate the neural underpinnings of BPD and its methods are constantly evolving. VBM is one of these methods and could replace manual tracing approaches in the long run as its automated technique highly improves objectivity of measuring brain volume, substantially shortens the time needed for analysis, and enhances comparisons between imaging studies (Voormolen et al., 2010). Importantly, region-based analyses can still be conducted with an automated approach in addition to whole brain voxel-wise analysis (Gaser and Kurth, 2017). Interestingly, a previous research group that reported the same lack of reduced volumetric findings from a VBM study additionally traced the hippocampus manually, but still found normal volumes in BPD patients (Kreisel et al., 2015; Labudda et al., 2013). However, it could be argued that for smaller structures, especially the amygdala, where small normalization errors could lead to substantial effects on results, adding manual tracing methods for specific regions could still be beneficial in addition to automated methods (Yoshikawa et al., 2006).

GMV reductions in the hippocampus and amygdala have been associated with trauma experience in early childhood, such as severe sexual abuse (Nunes et al., 2009). It has been suggested that traumatic stress might play an important role in the development of these structural reduction patterns in BPD, as the experience of trauma is quite common in this disorder (Nunes et al., 2009). This was indeed the motivation for investigating distinctions arising from PTSD diagnosis. While one traumatic event may be sufficient for a manifestation of PTSD (American Psychiatric Association, 2013), the number and intensity of traumatic experiences might vary extensively between individuals and further impact structural changes. A post hoc exploration of the ITEC scores of all patients did not reveal correlations with any of the pre-selected regions. However, investigating the characteristics and severity of trauma experiences in a larger sample of patients with comorbid PTSD as an additional factor in the development of BPD, its symptom severity, and its corresponding structural differences is an important task for future studies.

SBM is a more novel approach which could have an incremental value to VBM. For example, the measures for cortical complexity have been associated with different implications than alterations in volume measures (Anticevic et al., 2008). For this reason, it has been suggested to combine VBM and SBM (Depping et al., 2018) to gain a more complex insight in structural abnormalities of clinical disorders. A recent study examining different multimodal models for predicting outcomes from therapy in BPD patients did report better prediction accuracy from combining functional MRI and region-based morphometry measures (Schmitgen et al., 2019). Their proof of principle could be enhanced by investigating the potential benefit of adding SBM measures to improve prediction of therapy outcomes even further.

Our study revealed hypergyrification in the superior parietal cortex in female BPD patients in the absence of volumetric differences but no distinction in volumetric and surface measures with regard to PTSD diagnosis. Altogether, this study sets an example for investigating structural abnormalities in psychiatric disorders such as BPD in light of the bigger picture regarding the complexity of symptomatology and is one of the few studies to report both volume-based and surface-based measures. Validation of a standard procedure for combining these measures in future studies is needed and will be an important task in the research to come.

Author Contributions

C.C.V., I.D., S.M., and T.N. processed the data. C.C.V., I.D. performed

the statistical analyses, and drafted the manuscript. C.C.V., I.D., L.v.Z., A.A. and G.D. interpreted the data. L.v.Z., A.S., G.A.J., A.A. and G.D. contributed to conceiving and designing the multicenter RCT, planning, funding, and data collection. All authors revised the manuscript and approved the final manuscript version.

Conflict of Interest

None.

Acknowledgements

Preparation of this manuscript was in part supported by the University of Trier Research Priority Program “Psychobiology of Stress” (G. D.), funded by the State Rhineland-Palatinate, Germany. Data acquisition was supported by a grant from the “Open Research Area in the Social Sciences”, awarded by the Netherlands Organization for Scientific Research (NWO) to A.A. and Rainer Goebel [464–10–080]; and the German Research Foundation to G.A.J., Brunna Tuschen-Caffier and G. D. [JA1785/3–1]. We thank Dr. Gerhard Zarbock for his support at the study center Hamburg. We are also grateful to an anonymous reviewer for their constructive comments and time.

Supplementary materials

Supplementary material associated with this article can be found, in the online version, at [doi:10.1016/j.psychres.2021.111283](https://doi.org/10.1016/j.psychres.2021.111283).

References

- Amad, A., Ramoz, N., Thomas, P., Jardri, R., Gorwood, P., 2014. Genetics of borderline personality disorder: systematic review and proposal of an integrative model. *Neurosci. Biobehav. Rev.* 40, 6–19. <https://doi.org/10.1016/j.neubiorev.2014.01.003>.
- American Psychiatric Association, 2013. *Diagnostic and Statistical Manual of Mental Disorders*, 5th ed. American Psychiatric Publishing, Washington, DC.
- Anticevic, A., Dierker, D.L., Gillespie, S.K., Repovs, G., Csernansky, J.G., Van Essen, D.C., Barch, D.M., 2008. Comparing surface-based and volume-based analyses of functional neuroimaging data in patients with schizophrenia. *Neuroimage* 41, 835–848. <https://doi.org/10.1016/j.neuroimage.2008.02.052>.
- Arntz, A., Dreessen, L., 1995. BPD Klachtenlijst [BPD Checklist].
- Arntz, A., van den Hoorn, M., Cornelis, J., Verheul, R., van den Bosch, W.M.C., de Bie, A. J.H.T., 2003. Reliability and Validity of the Borderline Personality Disorder Severity Index. *J. Personal. Disord.* 17, 45–59. <https://doi.org/10.1521/pedi.17.1.45.24053>.
- Ashburner, J., Friston, K.J., 2005. Unified segmentation. *Neuroimage* 26, 839–851. <https://doi.org/10.1016/j.neuroimage.2005.02.018>.
- Baczowski, B.M., van Zutphen, L., Siep, N., Jacob, G.A., Domes, G., Maier, S., Sprenger, A., Senft, A., Willenborg, B., Tüscher, O., Arntz, A., van de Ven, V., 2017. Deficient amygdala–prefrontal intrinsic connectivity after effortful emotion regulation in borderline personality disorder. *Eur. Arch. Psychiatry Clin. Neurosci.* 267, 551–565. <https://doi.org/10.1007/s00406-016-0760-z>.
- Baer, R.A., Peters, J.R., Eisenlohr-Moul, T.A., Geiger, P.J., Sauer, S.E., 2012. Emotion-related cognitive processes in borderline personality disorder: a review of the empirical literature. *Clin. Psychol. Rev.* 32, 359–369. <https://doi.org/10.1016/j.cpr.2012.03.002>.
- Besteher, B., Gaser, C., Spalthoff, R., Nenadić, I., 2017. Associations between urban upbringing and cortical thickness and gyrification. *J. Psychiatr. Res.* 95, 114–120. <https://doi.org/10.1016/j.jpsychires.2017.08.012>.
- Bøen, E., Westlye, L.T., Elvsåshagen, T., Hummelen, B., Hol, P.K., Boye, B., Andersson, S., Karterud, S., Malt, U.F., 2014. Regional cortical thinning may be a biological marker for borderline personality disorder. *Acta Psychiatr. Scand.* 130, 193–204. <https://doi.org/10.1111/acps.12234>.
- Bruehl, H., Preißler, S., Heuser, I., Heekeren, H.R., Roepke, S., Dziobek, I., 2013. Increased prefrontal cortical thickness is associated with enhanced abilities to regulate emotions in PTSD-free women with borderline personality disorder. *PLoS ONE* 8, e65584. <https://doi.org/10.1371/journal.pone.0065584>.
- Chanen, A.M., Velakoulis, D., Carison, K., Gaunson, K., Wood, S.J., Yuen, H.P., Yücel, M., Jackson, H.J., McGorry, P.D., Pantelis, C., 2008. Orbitofrontal, amygdala and hippocampal volumes in teenagers with first-presentation borderline personality disorder. *Psychiatry Res. Neuroimaging* 163, 116–125. <https://doi.org/10.1016/j.psychres.2007.08.007>.
- Corbetta, M., Shulman, G.L., Miezin, F.M., Petersen, S.E., 1995. Superior parietal cortex activation during spatial attention shifts and visual feature conjunction. *Science* 270, 802–805. <https://doi.org/10.1126/science.270.5237.802>.
- Coull, J.T., Frith, C.D., 1998. Differential activation of right superior parietal cortex and intraparietal sulcus by spatial and nonspatial attention. *Neuroimage* 8, 176–187. <https://doi.org/10.1006/nimg.1998.0354>.
- Dahnke, R., Yotter, R.A., Gaser, C., 2013. Cortical thickness and central surface estimation. *Neuroimage* 65, 336–348. <https://doi.org/10.1016/j.neuroimage.2012.09.050>.
- de Araujo Filho, G.M., Abdallah, C., Sato, J.R., de Araujo, T.B., Lisondo, C.M., de Faria, Á. A., Lin, K., Silva, I., Bressan, R.A., da Silva, J.F.R., Coplan, J., Jackowski, A.P., 2014. Morphometric hemispheric asymmetry of orbitofrontal cortex in women with borderline personality disorder: a multi-parameter approach. *Psychiatry Res. Neuroimaging* 223, 61–66. <https://doi.org/10.1016/j.psychres.2014.05.001>.
- Depping, M.S., Thomann, P.A., Wolf, N.D., Vasic, N., Sosis-Vasic, Z., Schmitgen, M.M., Sambataro, F., Wolf, R.C., 2018. Common and distinct patterns of abnormal cortical gyrification in major depression and borderline personality disorder. *Eur. Neuropsychopharmacol.* 28, 1115–1125. <https://doi.org/10.1016/j.euroneuro.2018.07.100>.
- Derogatis, L.R., 1993. *BSI Brief Symptom Inventory: Administration, Scoring, and Procedure Manual*, 4th ed. National Computer Systems, Minneapolis, MN.
- Derogatis, L.R., Melisaratos, N., 1983. The Brief Symptom Inventory: an introductory report. *Psychol. Med.* 13, 595–605. <https://doi.org/10.1017/S0033291700048017>.
- Desikan, R.S., Ségonne, F., Fischl, B., Quinn, B.T., Dickerson, B.C., Blacker, D., Buckner, R.L., Dale, A.M., Maguire, R.P., Hyman, B.T., Albert, M.S., Killiany, R.J., 2006. An automated labeling system for subdividing the human cerebral cortex on MRI scans into gyral based regions of interest. *Neuroimage* 31, 968–980. <https://doi.org/10.1016/j.neuroimage.2006.01.021>.
- Fassbinder, E., Schuetze, M., Kranich, A., Sips, V., Hohagen, F., Shaw, I., Farrell, J., Arntz, A., Schweiger, U., 2016. Feasibility of group schema therapy for outpatients with severe borderline personality disorder in Germany: a pilot study with three year follow-up. *Front. Psychol.* 7, 1–9. <https://doi.org/10.3389/fpsyg.2016.01851>.
- First, M.B., Spitzer, R.L., Gibbon, M., Williams, J.B.W., 1994. *Structural Clinical Interview For DSM-IV Axis I disorders (SCID-I)*. Biometric Research Department, New York.
- First, M.B., Spitzer, R.L., Gibbon, M., Williams, J.B.W., Benjamin, L., 1997. *Structural Clinical Interview For DSM-IV Axis II Personality Disorders (SCID-II)*. Biometric Research Department, New York.
- Gaser, C., Kurth, F., 2017. *Manual Computational Anatomy Toolbox (CAT12)*.
- Geuze, E., Westenberg, H.G.M., Heinecke, A., de Kloet, C.S., Goebel, R., Vermetten, E., 2008. Thinner prefrontal cortex in veterans with posttraumatic stress disorder. *Neuroimage* 41, 675–681. <https://doi.org/10.1016/j.neuroimage.2008.03.007>.
- Giesen-Bloo, J.H., Wouters, L.M., Schouten, E., Arntz, A., 2010. The Borderline Personality Disorder Severity Index-IV: psychometric evaluation and dimensional structure. *Personal. Individ. Differ.* 49, 136–141. <https://doi.org/10.1016/j.paid.2010.03.023>.
- Grant, B.F., 2009. Prevalence, correlates, disability, and comorbidity of DSM-IV borderline personality disorder: results from the wave 2 national epidemiologic survey on alcohol and related conditions. *J. Clin. Psychiatry* 64, 533.
- Heyn, S.A., Herring, R.J., 2019. Longitudinal cortical markers of persistence and remission of pediatric PTSD. *NeuroImage Clin.* 24, 102028. <https://doi.org/10.1016/j.nicl.2019.102028>.
- Hirjak, D., Thomann, A.K., Kubera, K.M., Wolf, R.C., Jeung, H., Maier-Hein, K.H., Thomann, P.A., 2017. Cortical folding patterns are associated with impulsivity in healthy young adults. *Brain Imaging Behav.* 11, 1592–1603. <https://doi.org/10.1007/s11682-016-9618-2>.
- Iacoboni, M., 2004. Interhemispheric visuo-motor integration in humans: the role of the superior parietal cortex. *Neuropsychologia* 42, 419–425. <https://doi.org/10.1016/j.neuropsychologia.2003.10.007>.
- Jerschke, S., Meixner, K., Richter, H., Bohus, M., 1998. The treatment history of patients with borderline personality disorder in the Republic of Germany. *Fortschr. Neurol. Psychiatr.* 66, 545–552.
- Kanai, R., Carmel, D., Bahrami, B., Rees, G., 2011. Structural and functional fractionation of right superior parietal cortex in bistable perception. *Curr. Biol.* 21, R106–R107. <https://doi.org/10.1016/j.cub.2010.12.009>.
- Kitayama, N., Vaccarino, V., Kutner, M., Weiss, P., Bremner, J.D., 2005. Magnetic resonance imaging (MRI) measurement of hippocampal volume in posttraumatic stress disorder: a meta-analysis. *J. Affect. Disord.* 88, 79–86. <https://doi.org/10.1016/j.jad.2005.05.014>.
- Koenigs, M., Barbey, A.K., Postle, B.R., Grafman, J., 2009. Superior parietal cortex is critical for the manipulation of information in working memory. *J. Neurosci.* 29, 14980–14986. <https://doi.org/10.1523/JNEUROSCI.3706-09.2009>.
- Kreisel, S.H., Labudda, K., Kurlandchikov, O., Beblo, T., Mertens, M., Thomas, C., Rullkötter, N., Wingenfeld, K., Mensebach, C., Woermann, F.G., Driessen, M., 2015. Volume of hippocampal substructures in borderline personality disorder. *Psychiatry Res. Neuroimaging* 231, 218–226. <https://doi.org/10.1016/j.psychres.2014.11.010>.
- Kubera, K.M., Schmitgen, M.M., Maier-Hein, K.H., Thomann, P.A., Hirjak, D., Wolf, R.C., 2018. Differential contributions of cortical thickness and surface area to trait impulsivity in healthy young adults. *Behav. Brain Res.* 350, 65–71. <https://doi.org/10.1016/j.bbr.2018.05.006>.
- Kuhlmann, A., Bertsch, K., Schmidinger, I., Thomann, P.A., Herpertz, S.C., 2013. Morphometric differences in central stress-regulating structures between women with and without borderline personality disorder. *J. Psychiatry Neurosci.* JPN 38, 129–137. <https://doi.org/10.1503/jpn.120039>.
- Kurth, F., Luders, E., Gaser, C., 2015. Voxel-Based Morphometry, in: *Brain Mapping*. Elsevier 345–349. <https://doi.org/10.1016/B978-0-12-397025-1.00304-3>.
- Labudda, K., Kreisel, S., Beblo, T., Mertens, M., Kurlandchikov, O., Bien, C.G., Driessen, M., Woermann, F.G., 2013. Mesiotemporal volume loss associated with disorder severity: a vbm study in borderline personality disorder. *PLoS ONE* 8, e83677. <https://doi.org/10.1371/journal.pone.0083677>.

- Landré, L., Destrieux, C., Baudry, M., Barantin, L., Cottier, J.-P., Martineau, J., Hommet, C., Isingrini, M., Belzung, C., Gaillard, P., Camus, V., El Hage, W., 2010. Preserved subcortical volumes and cortical thickness in women with sexual abuse-related PTSD. *Psychiatry Res. Neuroimaging* 183, 181–186. <https://doi.org/10.1016/j.pscychres.2010.01.015>.
- Leichenring, F., Leibing, E., Kruse, J., New, A.S., Leweke, F., 2011. *Borderline personality disorder*. The Lancet 377, 74–8411.
- Lieb, K., Zanarini, M.C., Schmahl, C., Linehan, M.M., Bohus, M., 2004. Borderline personality disorder. The Lancet 364, 453–461. [https://doi.org/10.1016/S0140-6736\(04\)16770-6](https://doi.org/10.1016/S0140-6736(04)16770-6).
- Lindemer, E.R., Salat, D.H., Leritz, E.C., McGlinchey, R.E., Milberg, W.P., 2013. Reduced cortical thickness with increased lifetime burden of PTSD in OEF/OIF Veterans and the impact of comorbid TBI. *Neuroimage Clin* 2, 601–611. <https://doi.org/10.1016/j.nicl.2013.04.009>.
- Lobbestael, J., Arntz, A., Harkema-Schouten, P., Bernstein, D., 2009. Development and psychometric evaluation of a new assessment method for childhood maltreatment experiences: the interview for traumatic events in childhood (ITEC). *Child Abuse Negl.* 33, 505–517. <https://doi.org/10.1016/j.chiabu.2009.03.002>.
- Lobbestael, J., Arntz, A., Kremers, I., Sieswerda, S., 2006. The Interview For Traumatic Events in Childhood. Maastricht University, Maastricht.
- Luders, E., Thompson, P.M., Narr, K.L., Toga, A.W., Jancke, L., Gaser, C., 2006. A curvature-based approach to estimate local gyrification on the cortical surface. *Neuroimage* 29, 1224–1230. <https://doi.org/10.1016/j.neuroimage.2005.08.049>.
- Mancke, F., Bertsch, K., Herpertz, S.C., 2015. Gender differences in aggression of borderline personality disorder. *Borderline Personal. Disord. Emot. Dysregulation* 2, 7. <https://doi.org/10.1186/s40479-015-0028-7>.
- Nenadić, I., Voss, A., Besteher, B., Langbein, K., Gaser, C., 2020. Brain structure and symptom dimensions in borderline personality disorder. *Eur. Psychiatry* 63, e9. <https://doi.org/10.1192/j.eurpsy.2019.16>.
- Nickel, K., Joos, A., Tebartz van Elst, L., Matthis, J., Holovics, L., Endres, D., Zeeck, A., Hartmann, A., Tüscher, O., Maier, S., 2018. Recovery of cortical volume and thickness after remission from acute anorexia nervosa. *Int. J. Eat. Disord.* 51, 1056–1069. <https://doi.org/10.1002/eat.22918>.
- Niedtfeld, I., Schulze, L., Krause-Utz, A., Demirakca, T., Bohus, M., Schmahl, C., 2013. Voxel-based morphometry in women with borderline personality disorder with and without comorbid posttraumatic stress disorder. *PLoS ONE* 8, e65824. <https://doi.org/10.1371/journal.pone.0065824>.
- Nunes, P.M., Wenzel, A., Borges, K.T., Porto, C.R., Caminha, R.M., de Oliveira, I.R., 2009. Volumes of the hippocampus and amygdala in patients with borderline personality disorder: a meta-analysis. *J. Personal. Disord.* 23, 333–345. <https://doi.org/10.1521/pedi.2009.23.4.333>.
- O'Doherty, D.C.M., Chitty, K.M., Saddiqui, S., Bennett, M.R., Lagopoulos, J., 2015. A systematic review and meta-analysis of magnetic resonance imaging measurement of structural volumes in posttraumatic stress disorder. *Psychiatry Res. Neuroimaging* 232, 1–33. <https://doi.org/10.1016/j.pscychres.2015.01.002>.
- O'Neill, A., Frodl, T., 2012. Brain structure and function in borderline personality disorder. *Brain Struct. Funct.* 217, 767–782. <https://doi.org/10.1007/s00429-012-0379-4>.
- Richter, J., Brunner, R., Parzer, P., Resch, F., Stieltjes, B., Henze, R., 2014. Reduced cortical and subcortical volumes in female adolescents with borderline personality disorder. *Psychiatry Res. Neuroimaging* 221, 179–186. <https://doi.org/10.1016/j.pscychres.2014.01.006>.
- Rinne-Albers, M.A., Boateng, C.P., van der Werff, S.J., Lamers-Winkelmann, F., Rombouts, S.A., Vermeiren, R.R., van der Wee, N.J., 2020. Preserved cortical thickness, surface area and volume in adolescents with PTSD after childhood sexual abuse. *Sci. Rep.* 10, 3266. <https://doi.org/10.1038/s41598-020-60256-3>.
- Ruocco, A.C., Amirthavasagam, S., Zakzanis, K.K., 2012. Amygdala and hippocampal volume reductions as candidate endophenotypes for borderline personality disorder: a meta-analysis of magnetic resonance imaging studies. *Psychiatry Res. Neuroimaging* 201, 245–252. <https://doi.org/10.1016/j.pscychres.2012.02.012>.
- Rüsch, N., Tebartz van Elst, L., Ludascher, P., Wilke, M., Huppertz, H.-J., Thiel, T., Schmahl, C., Bohus, M., Lieb, K., Heßlinger, B., Hennig, J., Ebert, D., 2003. A voxel-based morphometric MRI study in female patients with borderline personality disorder. *Neuroimage* 20, 385–392. [https://doi.org/10.1016/S1053-8119\(03\)00297-0](https://doi.org/10.1016/S1053-8119(03)00297-0).
- Schmahl, C., Berne, K., Krause, A., Kleindienst, N., Valerius, G., Vermetten, E., Bohus, M., 2009. Hippocampus and amygdala volumes in patients with borderline personality disorder with or without posttraumatic stress disorder. *J. Psychiatry Neurosci* 7.
- Schmahl, C., Bremner, J., 2006. Neuroimaging in borderline personality disorder. *J. Psychiatr. Res.* 40, 419–427. <https://doi.org/10.1016/j.jpsychires.2005.08.011>.
- Schmahl, C.G., Vermetten, E., Elzinga, B.M., Douglas Bremner, J., 2003. Magnetic resonance imaging of hippocampal and amygdala volume in women with childhood abuse and borderline personality disorder. *Psychiatry Res. Neuroimaging* 122, 193–198. [https://doi.org/10.1016/S0925-4927\(03\)00023-4](https://doi.org/10.1016/S0925-4927(03)00023-4).
- Schmitgen, M.M., Niedtfeld, I., Schmitt, R., Mancke, F., Winter, D., Schmahl, C., Herpertz, S.C., 2019. Individualized treatment response prediction of dialectical behavior therapy for borderline personality disorder using multimodal magnetic resonance imaging. *Brain Behav.* 9, e01384. <https://doi.org/10.1002/brb3.1384>.
- Spalthoff, R., Gaser, C., Nenadić, I., 2018. Altered gyrification in schizophrenia and its relation to other morphometric markers. *Schizophr. Res.* 202, 195–202. <https://doi.org/10.1016/j.schres.2018.07.014>.
- Tebartz van Elst, L., Hesslinger, B., Thiel, T., Geiger, E., Haegele, K., Lemieux, L., Lieb, K., Bohus, M., Hennig, J., Ebert, D., 2003. Frontolimbic brain abnormalities in patients with borderline personality disorder: a volumetric magnetic resonance imaging study. *Biol. Psychiatry* 54, 163–171. [https://doi.org/10.1016/S0006-3223\(02\)01743-2](https://doi.org/10.1016/S0006-3223(02)01743-2).
- Torgersen, S., 2009. The nature (and nurture) of personality disorders. *Scand. J. Psychol.* 50, 624–632. <https://doi.org/10.1111/j.1467-9450.2009.00788.x>.
- van Asselt, T., Dirksen, C.D., Arntz, A., Severens, J.L., 2007. The cost of borderline personality disorder: societal cost of illness in BPD-patients. *Eur. Psychiatry* 22, 345–361.
- van Zutphen, L., Siep, N., Jacob, G.A., Domes, G., Sprenger, A., Willenborg, B., Goebel, R., Arntz, A., 2018. Always on guard: emotion regulation in women with borderline personality disorder compared to nonpatient controls and patients with cluster-C personality disorder. *J. Psychiatry Neurosci.* 43, 37–47. <https://doi.org/10.1503/jpn.170008>.
- van Zutphen, L., Siep, N., Jacob, G.A., Domes, G., Sprenger, A., Willenborg, B., Goebel, R., Tüscher, O., Arntz, A., 2019. Impulse control under emotion processing: an fMRI investigation in borderline personality disorder compared to non-patients and cluster-C personality disorder patients. *Brain Imaging Behav.* <https://doi.org/10.1007/s11682-019-00161-0>.
- Voormolen, E.H.J., Wei, C., Chow, E.W.C., Bassett, A.S., Mikulis, D.J., Crawley, A.P., 2010. Voxel-based morphometry and automated lobar volumetry: the trade-off between spatial scale and statistical correction. *Neuroimage* 49, 587–596. <https://doi.org/10.1016/j.neuroimage.2009.07.018>.
- Weniger, G., Lange, C., Sachse, U., Irle, E., 2009. Reduced amygdala and hippocampus size in trauma-exposed women with borderline personality disorder and without posttraumatic stress disorder. *J. Psychiatry Neurosci.* 6.
- Wrocklage, K.M., Averill, L.A., Cobb Scott, J., Averill, C.L., Schweinsburg, B., Trejo, M., Roy, A., Weisser, V., Kelly, C., Martini, B., Harpaz-Rotem, I., Southwick, S.M., Krystal, J.H., Abdallah, C.G., 2017. Cortical thickness reduction in combat exposed U.S. veterans with and without PTSD. *Eur. Neuropsychopharmacol.* 27, 515–525. <https://doi.org/10.1016/j.euroneuro.2017.02.010>.
- Wunsch, E.M., Kliem, S., Kröger, C., 2014. Population-based cost-offset estimation for the treatment of borderline personality disorder: projected costs in a currently running, ideal health system. *Behav. Res. Ther.* 60, 1–7.
- Yang, X., Hu, L., Zeng, J., Tan, Y., Cheng, B., 2016. Default mode network and frontolimbic gray matter abnormalities in patients with borderline personality disorder: a voxel-based meta-analysis. *Sci. Rep.* 6, 34247. <https://doi.org/10.1038/srep34247>.
- Yoshikawa, E., Matsuoka, Y., Yamasue, H., Inagaki, M., Nakano, T., Akechi, T., Kobayakawa, M., Fujimori, M., Nakaya, N., Akizuki, N., Imoto, S., Murakami, K., Kasai, K., Uchitomi, Y., 2006. Prefrontal cortex and amygdala volume in first minor or major depressive episode after cancer diagnosis. *Biol. Psychiatry* 59, 707–712. <https://doi.org/10.1016/j.biopsych.2005.08.018>.
- Yotter, R.A., Dahnke, R., Thompson, P.M., Gaser, C., 2011a. Topological correction of brain surface meshes using spherical harmonics. *Hum. Brain Mapp.* 32, 1109–1124. <https://doi.org/10.1002/hbm.21095>.
- Yotter, R.A., Nenadić, I., Ziegler, G., Thompson, P.M., Gaser, C., 2011b. Local cortical surface complexity maps from spherical harmonic reconstructions. *Neuroimage* 56, 961–973. <https://doi.org/10.1016/j.neuroimage.2011.02.007>.
- Yu, H., Meng, Y., Li, X., Zhang, C., Liang, S., Li, M., Li, Z., Guo, W., Wang, Q., Deng, W., Ma, X., Coid, J., Li, T., 2019. Common and distinct patterns of grey matter alterations in borderline personality disorder and bipolar disorder: voxel-based meta-analysis. *Br. J. Psychiatry* 215, 395–403. <https://doi.org/10.1192/bjp.2019.44>.
- Zanarini, M.C., Yong, L., Frankenburg, F.R., Hennen, J., Reich, D.B., Marino, M.F., Vujanovic, A.A., 2002. Severity of reported childhood sexual abuse and its relationship to severity of borderline psychopathology and psychosocial impairment among borderline inpatients. *J. Nerv. Ment. Dis.* 190, 381–387.