



## UvA-DARE (Digital Academic Repository)

### The Effect of Functional Pelvic Tilt on the Three-Dimensional Acetabular Cup Orientation in Total Hip Arthroplasty Dislocations

Snijders, T.E.; Schlösser, T.P.C.; Heckmann, N.D.; Tezuka, T.; Castelein, R.M.; Stevenson, R.P.; Weinans, H.; de Gast, A.; Dorr, L.D.

**DOI**

[10.1016/j.arth.2020.12.055](https://doi.org/10.1016/j.arth.2020.12.055)

**Publication date**

2021

**Document Version**

Final published version

**Published in**

Journal of Arthroplasty

**License**

CC BY

[Link to publication](#)

**Citation for published version (APA):**

Snijders, T. E., Schlösser, T. P. C., Heckmann, N. D., Tezuka, T., Castelein, R. M., Stevenson, R. P., Weinans, H., de Gast, A., & Dorr, L. D. (2021). The Effect of Functional Pelvic Tilt on the Three-Dimensional Acetabular Cup Orientation in Total Hip Arthroplasty Dislocations. *Journal of Arthroplasty*, 36(6), 2184-2188.  
<https://doi.org/10.1016/j.arth.2020.12.055>

**General rights**

It is not permitted to download or to forward/distribute the text or part of it without the consent of the author(s) and/or copyright holder(s), other than for strictly personal, individual use, unless the work is under an open content license (like Creative Commons).

**Disclaimer/Complaints regulations**

If you believe that digital publication of certain material infringes any of your rights or (privacy) interests, please let the Library know, stating your reasons. In case of a legitimate complaint, the Library will make the material inaccessible and/or remove it from the website. Please Ask the Library: <https://uba.uva.nl/en/contact>, or a letter to: Library of the University of Amsterdam, Secretariat, Singel 425, 1012 WP Amsterdam, The Netherlands. You will be contacted as soon as possible.

*UvA-DARE is a service provided by the library of the University of Amsterdam (<https://dare.uva.nl>)*



ELSEVIER

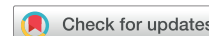Contents lists available at ScienceDirect

## The Journal of Arthroplasty

journal homepage: [www.arthroplastyjournal.org](http://www.arthroplastyjournal.org)

Complications - Other

## The Effect of Functional Pelvic Tilt on the Three-Dimensional Acetabular Cup Orientation in Total Hip Arthroplasty Dislocations



Thom E. Snijders, MD <sup>a, b, \*</sup>, Tom P.C. Schlösser, MD, PhD <sup>b</sup>,  
 Nathanael D. Heckmann, MD <sup>c</sup>, Taro Tezuka, MD <sup>d</sup>, Rene M. Castelein, MD, PhD <sup>b</sup>,  
 Rob P. Stevenson, PhD <sup>e</sup>, Harry Weinans, PhD <sup>b, f</sup>, Arthur de Gast, MD, PhD <sup>a</sup>,  
 Lawrence D. Dorr, MD <sup>g</sup>

<sup>a</sup> Clinical Orthopedic Research Center Midden-Nederland, Zeist, the Netherlands

<sup>b</sup> Department of Orthopaedic Surgery, University Medical Center Utrecht, Utrecht, the Netherlands

<sup>c</sup> Department of Orthopaedic Surgery, Rush University Medical Center, Chicago, IL

<sup>d</sup> Department of Orthopaedic Surgery, Yokohama City University, Yokohama, Japan

<sup>e</sup> Korteweg-de Vries Institute for Mathematics, University of Amsterdam, Amsterdam, the Netherlands

<sup>f</sup> Department of Biomechanical Engineering, Delft, the Netherlands

<sup>g</sup> Department of Orthopedic Surgery, Keck Medical Center of the University of Southern California, Los Angeles, CA

## ARTICLE INFO

## Article history:

Received 18 September 2020

Received in revised form

14 December 2020

Accepted 30 December 2020

Available online 8 January 2021

## Keywords:

total hip arthroplasty

pelvic tilt

3-d acetabular cup orientation

transverse version

sagittal ante-inclination

dislocation

## ABSTRACT

**Background:** Anterior and posterior pelvic tilt appears to play a role in total hip arthroplasty (THA) stability. When changing from the standing to the sitting position, the pelvis typically rotates posteriorly while the hips flex and this affects the femoro-acetabular positions. This case-control study compares changes in 3-D acetabular cup orientation during functional pelvic tilt between posterior THA dislocations vs stable THAs.

**Methods:** Standing and sitting 3-D cup orientation was compared between fifteen posterior dislocations vs 233 prospectively followed stable THAs. 3-D cup orientation was calculated using previously validated trigonometric algorithms on biplanar radiographs. Those algorithms combine the angles in the three anatomical planes (coronal inclination, transverse version, and sagittal ante-inclination) in the standing position with the change in sagittal pelvic tilt from standing to sitting to calculate the 3-D orientation in the sitting position.

**Results:** The standing cup orientation of the dislocated THAs was only characterized by a lower coronal inclination ( $P = .039$ ). Compared with the controls, from standing to sitting, they showed less posterior pelvic tilt ( $P < .001$ ). This led to a significant lower coronal inclination ( $P < .001$ ) and sagittal ante-inclination ( $P < .001$ ) in the sitting position but similar transverse version ( $P = .366$ ).

**Conclusions:** Comparing posterior THA dislocations to stable THAs, there is a lower increase of all three orientation angles from standing to sitting. This leads to a decreased sitting coronal inclination and sagittal ante-inclination which may lead to an increased risk of impingement ensued by THA instability. By contrast, the transverse version was not significantly different in both positions. This confirms the importance of biplanar data on functional cup orientation.

**Level of Evidence:** Diagnostic, Level III.

© 2021 The Authors. Published by Elsevier Inc. This is an open access article under the CC BY license (<http://creativecommons.org/licenses/by/4.0/>).

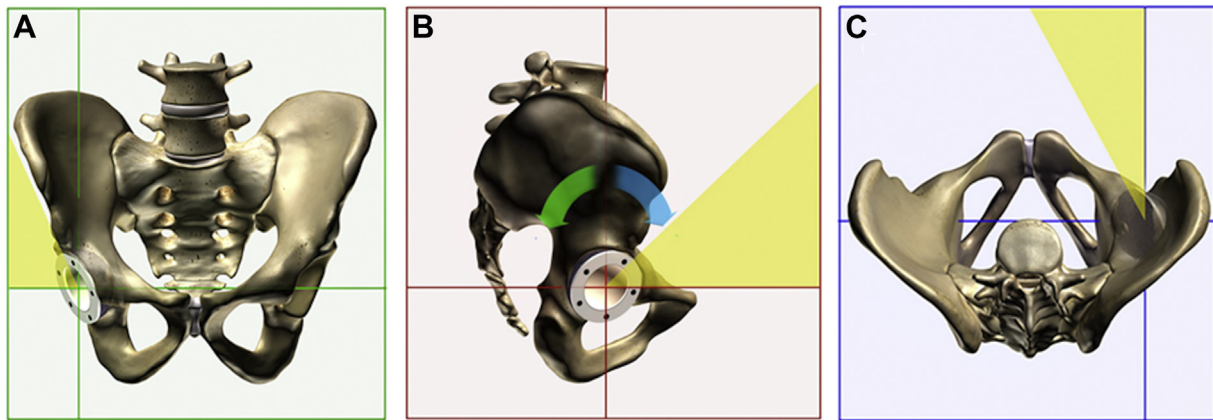
No author associated with this paper has disclosed any potential or pertinent conflicts which may be perceived to have impending conflict with this work. For full disclosure statements refer to <https://doi.org/10.1016/j.arth.2020.12.055>.

\* Reprint requests: Thom E. Snijders, MD, Clinical Orthopedic Research Center – mN., Diakonessenhuis Zeist, Professor Lorentzlaan 76, 3707 HL Zeist, the Netherlands.

<https://doi.org/10.1016/j.arth.2020.12.055>

0883-5403/© 2021 The Authors. Published by Elsevier Inc. This is an open access article under the CC BY license (<http://creativecommons.org/licenses/by/4.0/>).

For more than four decades, the “safe zone of Lewinnek”, for acetabular cup placement, which is based on supine pelvic radiographs, has been implemented to limit the dislocation rate [1]. Recently, however, this has been called into question because most total hip arthroplasty (THA) dislocations seem to occur within this proposed “safe zone” [2]. Furthermore, recent studies stated that sagittal pelvic dynamics could play a significant role in the stability of THAs [3–6].



**Fig. 1.** Coronal inclination (a) and sagittal ante-inclination (b) of the cup are measured in relation to the horizontal plane and transverse version (c) of the cup in relation to the anterior-posterior axis. Pelvic tilt is described as a rotation around the transverse hip-axis. The blue arrow in B describes anterior pelvic tilt; the green arrow in B describes posterior pelvic tilt. A change of 1° of pelvic tilt, gives a change of 1° of the sagittal ante-inclination of the cup.

The normal posterior pelvic tilt from standing to sitting results in an opening of the acetabulum anteriorly so it can accommodate flexion of the femur. With degenerative spinal pathology, the pelvis is most often already retroverted because lordosis is lost and if pelvic mobility is stiff, further posterior tilt is restricted during postural change from standing to sitting [7–11]. To date, it has been recognized by multiple studies that variations in sagittal pelvic dynamics potentially play a role in implant stability in THAs [10–13]. Owing to the hemispherical shape of most acetabular cups, anterior and posterior pelvic tilt in the sagittal plane will also change the orientation in the other two anatomical planes, the coronal and transverse plane [14]. For better understanding the relevance of spino-pelvic-femoral dynamics in THA implant stability, the purpose of this study is to describe the effect of functional pelvic tilt on the 3-D acetabular cup orientation for posterior THA dislocations vs a cohort of stable THAs. We postulate that posterior dislocated THAs will have a reduction in pelvic tilt from standing to sitting and a decrease in functional acetabular cup position.

## Materials and Methods

### Study Population

Patients who presented with a posterior dislocation of a THA to our practice between 2011 and 2017 were included in this study. Posterior dislocations are defined as a posterior position of the femoral head relative to the acetabular cup [15,16]. Fifteen patients with a posterior THA dislocation were included. The control group consisted of 233 subjects of a prospective cohort of 238 THA patients enrolled between 2011 and 2017 with complete

postoperative radiographic data at three months; 5 of the 238 had a dislocations within the first year. Patients who received a dual mobility cup or where the data were not complete were excluded. In the fifteen dislocated and 233 control patients, the THA was placed by a posterolateral approach. Previously, these patients were included in the publications by Heckmann et al. and Tezuka et al., but assessment of the exact 3-D reorientation of the acetabular cup during functional pelvic tilt was not previously performed [10,17]. Institutional review board approval was obtained before the data collection.

### Functional 3-D Acetabular Cup Orientation

Patients from the prospective cohort study (controls and early dislocations) underwent standing and sitting lateral spine-pelvis-hip radiographs as well as a supine anteroposterior pelvis radiograph including the proximal femur with the beam centered on the symphysis 3 months postoperatively, as previously described [4]. For the late dislocations, the same radiographs were collected at the first outpatient follow-up after the late dislocation. The 3-D acetabular cup orientation (coronal inclination (CI), transverse version (TV), and sagittal ante-inclination (AI)) was calculated for the supine, standing, and sitting positions. These mathematical models were previously validated for pelvic tilt using multiplanar 3-D reconstruction on pelvic CT scans in multiple orientations and had an interobserver reliability of 0.953 for CI, 0.982 for TV, 0.985 for AI, 0.963 for CI' and 0.990 for TV' [14,18]. These algorithms combine the orientation of the hemispherical acetabular cup in the three anatomical, orthogonal planes in the supine position plus the sagittal change in pelvic tilt to calculate the 3-D acetabular cup

**Table 1**  
Demographics.

Demographics	Stable THA (n = 233)	Posterior Dislocations (n = 15)	P
Mean age (range)	62.6 (27-85)	66.1 (39-94)	.342
Male or female (M: F)	119:114	10:5	.380
Right or left (R: L)	131:102	6:9	.221
Mean body mass index (range)	28.1 (16.7-51.5)	25.6 (18.3-36.3)	.047 <sup>a</sup>
Time to dislocation (range)	-	37.8 (1-108)	
Mean follow-up (range)	3.3 (2.85-3.87)	5.0 (0.01-18)	.674
Mean pelvic incidence (range)	54.5 (25-87)	48.1 (36-60)	.010 <sup>a</sup>
Mean sacral slope in degrees (range)	38.5 (10-62)	32.8 (24-44)	.004 <sup>a</sup>

Age in years, body mass index in kg/m<sup>2</sup>, time to dislocation in months, follow-up in years, pelvic incidence in degrees, sacral slope in degrees (measured in the standing position).

<sup>a</sup> Indicates  $P < .05$ , a statistically significant difference between the posterior dislocation group and the stable THAs.

**Table 2**  
Standing 3-D Acetabular Cup Orientation.

Angle	Stable	Posterior Dislocations	P
CI	46.3 ± 4.9	43.5 ± 5.9	.039 <sup>a</sup>
TV	33.5 ± 6.5	36.3 ± 10.7	.133
AI	34.8 ± 8.0	34.9 ± 9.6	.805

CI, coronal Inclination; TV, transverse version; AI, sagittal ante-inclination.

<sup>a</sup> Indicates  $P < .05$ , a statistically significant difference between the dislocation group and the stable THAs.

orientation in the standing and sitting body positions. The algorithms can be seen in the [supplemental material](#) or can be used with the developed tool available at [www.3d-hip.com](http://www.3d-hip.com). ([Supplemental material](#)) For evaluation of the supine pelvic and acetabular cup orientation a mean difference of 5.5° of posterior pelvic tilt between standing and supine was used, based on the studies of Buckland et al. and Pierrepont et al. [19,20] In accordance with the decisions of the Hip-Spine Workgroup, the following definitions were used to describe the sagittal pelvic parameters and acetabular cup orientation and dynamics in the three anatomical planes ([Fig. 1](#)) [6]:

- Pelvic incidence (PI): the angle between one line connecting the center of the femoral heads and the center of the sacral plate, and a second line perpendicular to the sacral plate.
- Sacral slope (SS): the angle between a horizontal reference line and a line parallel to the sacral plate.
- Coronal inclination (CI): the rotation of inclination of the cup around the anterior-posterior axis in the coronal plane.
- Sagittal ante-inclination (AI): the sagittal angle of the cup that includes inclination and anteversion that changes with posterior and anterior tilt of the pelvis.
- Transverse version (TV): the anteversion angle of the cup around the craniocaudal axis in the transverse plane.

### Statistical Analysis

Statistical analyses were performed using IBM-SPSS Statistics 23 (SPSS Inc., Chicago, Illinois). Chi-squared test was used for categorical parameters. For the continuous parameters (follow-up, PI, SS, body mass index (BMI), CI, AI, and TV in standing and sitting position), box plots were used to identify any outliers and

Kolmogorov-Smirnov test to test for normality. In non-normality parameters the Mann-Whitney U test was used and in normality the independent t-test. The level of statistical significance was set at 0.05.

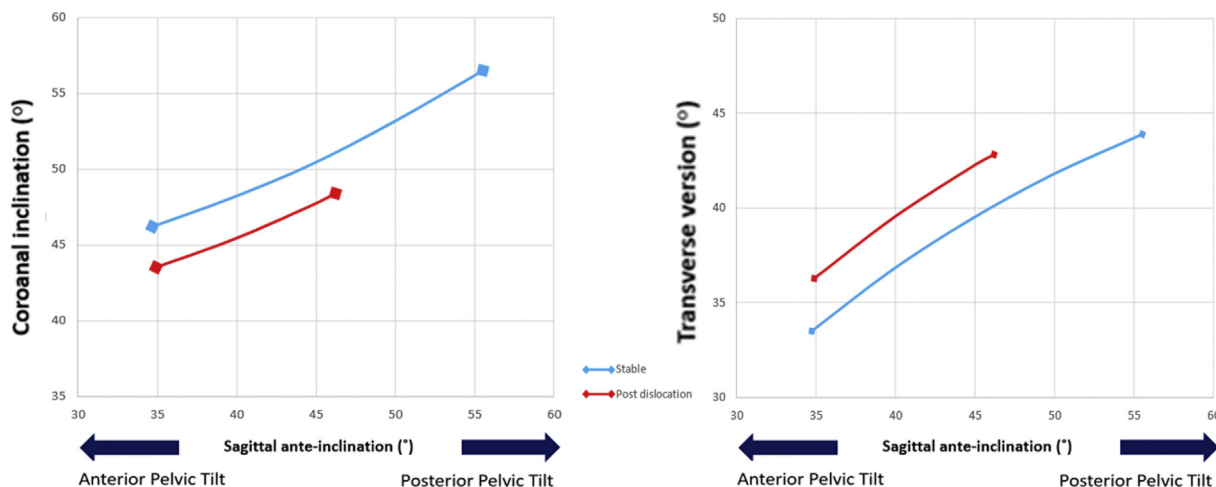
### Results

Five of fifteen posterior dislocations occurred within one year postoperative (mean 2.3 months, range 0.3–4 months). Ten of fifteen occurred past 1 year (mean 52.2 months, range 12–108 months). Comparing both groups in terms of BMI, PI, and SS showed no significant differences ( $P = .711$ ,  $P = .760$ ,  $P = .474$ , respectively). Standing CI, TV, and AI showed no significant differences ( $P = .165$ ,  $P = .956$ ,  $P = .326$ , respectively). Sitting CI, TV, and AI showed also no significant differences ( $P = .051$ ,  $P = .530$ ,  $P = .059$ , respectively).

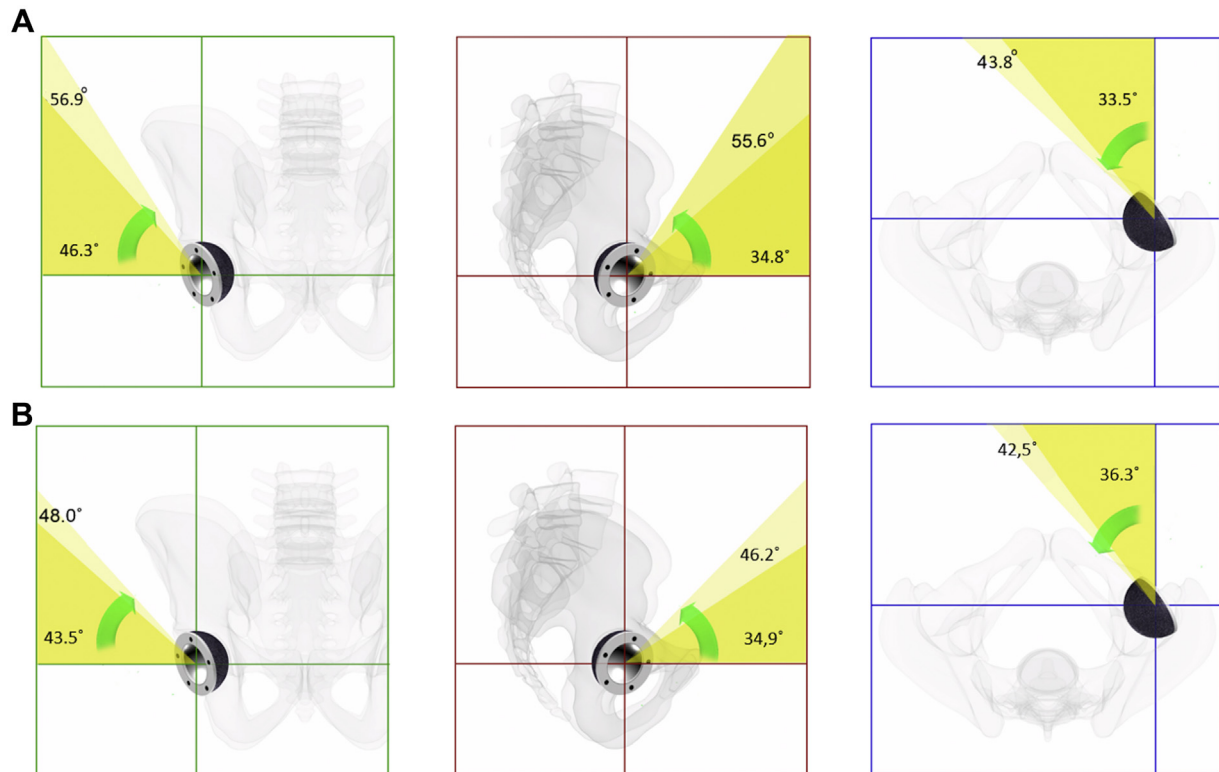
Hips with posterior dislocation differed significantly from stable THAs by a lower BMI ( $P = .047$ ), lower PI ( $P = .010$ ), and lower SS ( $P = .004$ ) ([Table 1](#)). The change of SS and PT from standing to sitting was significantly different between the posterior dislocations and the stable group ( $-11.5$  vs  $-21.1$ ;  $P = .000$  and  $11.2$  vs  $21.1$ ;  $P = .000$ , respectively). In the standing position, the posterior dislocations had a lower statistical CI compared to the stable THAs (43.5 vs 46.3;  $P = .039$ ). ([Table 2](#), [Figs. 2 and 3](#)). In the sitting position, dislocated hips had a statistically significant lower CI and AI, but similar TV as compared with stable THAs ([Table 3](#), [Figs. 2 and 3](#)). From standing to sitting, the posterior dislocations had both statistical and clinically significant less posterior pelvic tilt reflected by the change in AI ( $+11.3$  vs  $+20.8$ ,  $P = .000$ ). These were similar to the change in SS and PT of both groups. The reduced posterior pelvic tilt thus results in decreased sitting CI with a consequent lesser increase in AI ( $+11.3$  vs  $+20.8$ ;  $P = .000$ ) ([Table 4](#)) which represents the functional acetabular cup position.

### Discussion

Dislocation of a THA can be either by implant-implant (stem-cup) impingement, by bone-bone (femur pelvis) impingement or implant-bone impingement. Posterior pelvic tilt from standing to sitting accommodates flexion of the femur. Whether a lack of pelvic tilt, an increase of hip flexion, malposition of acetabular or femoral implant, or a combination of these lead to one of the forms of impingement during postural change, depends on the amount of reorientation in 3-D [3,12,14,17,21]. Although the Lewinnek safe



**Fig. 2.** Functional 3-D acetabular cup orientation from standing to sitting in stable THAs or THA with a late posterior dislocation.



**Fig. 3.** The mean 3-D acetabular component in the standing (dark yellow) and sitting (light yellow) position in the two groups: A. patients with a stable THA, B. patients with a posteriorly dislocated THA. Green, coronal inclination; red, sagittal ante-inclination; blue, transverse version.

zone is based on static coronal and transverse plane cup orientation in the supine position, recent studies demonstrated the importance of functional sagittal pelvic tilt and sagittal cup reorientation for THA stability [3,8,13,17]. We studied the changes in the orientation of the acetabular cup in all three orthogonal anatomical planes during functional pelvic tilt in THA patients with posterior dislocations compared with stable THAs. It demonstrates that the 3-D orientation of the acetabular cup changes with changing body position, but degree of changes and 3-D orientation in the sitting position differs between stable and unstable THAs [8,10,13]. Compared with stable THAs, hips with posterior dislocations had less difference between standing and sitting in CI, TV, and AI because of reduced pelvic mobility [10,20,22]. With less pelvic mobility, less increase in AI enlarges the risk of impingement, especially in patients with spinal pathology with pre-existent pelvic retroversion and diminished pelvic mobility [7–10,13,17,21]. The altered spinal pelvic mechanics in patients with a dislocation could have been developed years after THA placement. A lower PT from standing to sitting could be a result of progressive degenerative pathology of the spine, combined with muscle atrophy in the aging patient making them prone for a dislocation. Otherwise, there could also be patients who already have a degenerative spine

with coexisting muscle atrophy when the THA is placed. Both patients might benefit from optimizing acetabular cup orientation by increasing the AI in the sitting position, preventing anterior impingement.

A recent study established the mathematical relationship between the orientation angles of the acetabular cup on the three orthogonal, anatomical planes (ie, CI, TV, and AI) [18]. In this study, 1° of pelvic tilt around the hip-axis equals 1° of change in the cup orientation (AI) in the sagittal plane [10]. In contrast to earlier assumptions in the literature, the degree of change in CI and TV, however, is not linearly related, because it is dependent on an individuals' pelvic mobility as well as the initial 3-D cup positioning [23–25]. The effect of sagittal pelvic tilt on the TV is much greater in acetabular cups with relatively low CI compared to high CI, and *vice versa* [14]. This explains the comparable TV in the sitting position in contrast to CI and AI in this study. Hips with posterior dislocation have less CI in the standing position, so with less pelvic tilt from standing to sitting compared with stable THAs, TV still changes considerably [14]. Thus, each acetabular cup responds differently to an individuals' functional spino-pelvic-femoral dynamics based on its initial

**Table 3**  
Sitting 3-D Acetabular Cup Orientation.

Angle	Stable	Posterior Dislocations	P
CI	56.9 ± 7.3	49.0 ± 9.7	.000 <sup>a</sup>
TV	43.8 ± 5.2	42.5 ± 8.7	.366
AI	55.6 ± 9.1	46.2 ± 12.1	.000 <sup>a</sup>

CI, coronal inclination; TV, transverse version; AI, sagittal ante-inclination.

<sup>a</sup> Indicates  $P < .05$ , a statistically significant difference between the dislocation group and the stable THAs.

**Table 4**  
Functional 3-D Acetabular Cup Orientation; Difference Between Standing and Sitting.

Angle	Stable	Posterior Dislocations	P
CI	+10.7 ± 5.7	+5.5 ± 6.2	.000 <sup>a</sup>
TV	+10.3 ± 5.0	+6.2 ± 3.4	.002 <sup>a</sup>
AI	+20.8 ± 9.3	+11.3 ± 7.2	.000 <sup>a</sup>

CI, coronal inclination; TV, transverse version; AI, sagittal ante-inclination.

<sup>a</sup> Indicates  $P < .05$ , a statistically significant difference between the dislocation group and the stable THAs.

position, and could create significant risk for implant impingement/instability.

The lower standing and sitting AI, found in this study, is consistent with a lower functional sagittal safe zone which signifies risk of dislocation. The finding that TV, which does not differentiate in the standing or in the sitting position in both groups, is not the most important angle is an important contribution of this study. This finding confirms the data from two plane measurements studies by Stefl [17,26]. Therefore, the cup in the CI and AI position, implanted by the surgeon, is important for controlling impingement risk.

From the spine literature, it is well known that individuals with a sagittal pelvic morphology characterized by a low PI (a more vertical position of the sacrum within the pelvic ring and the femoral heads under the sacrum) normally have more pelvic retroversion (lower SS) because of less lumbar lordosis. With spinal imbalance and stiffness, there is less increase in acetabular opening as expressed by our data of CI and AI in hips with a dislocation which means more hip flexion is needed that increases the risk of bony impingement [8,17]. Our data does not include the femur but previous studies of femur mobility can be interpolated with our 3-D cup data. Because the hip functions as a joint, our 3-D cup data are important additional knowledge for the orthopedic surgeon in understanding stability of the joint. It is also important because it confirms 2-D findings, thereby confirming the validity of these previous studies [3,4,8,13,17].

We had limitations. Although we observed clear associations of altered pelvic-femoral dynamics, changes in implant orientation and THA stability, this study did not investigate other factors involved in THA dislocation, such as surgical approach and technique, muscle tension, femoral head size, femoral component orientation, combined anteversion, long-term wear, head-neck ratio, and impingement. All of these factors do have a role in dislocation in spite of a well-positioned acetabular cup [27–29]. Long-term wear of the bearing has also been described as having a role in THA dislocation [30,31]. Another limitation is that this study did not address factors involved in impingement, like individual differences in bony anatomy, extreme range of motion of the hip, protrusion of the acetabular cup or stem positioning. Despite the different confounders that certainly play a role in the onset of different types of dislocations, we believe that our observations of associations of altered pelvic-femoral dynamics and the consequent changes in implant orientation with THA stability hold true.

## Conclusion

In patients with a posterior THA dislocation, restricted pelvic tilt combined with a lower PI, results in a lower increase of CI, TV, and AI from the standing to the sitting position. Our data show that stability is dependent on a decreased orientation of CI and AI, in contrast to TV. In hips with dislocation, the 3-D orientation of these angles reveals a compromised functional safe zone which increases the risk of impingement and instability. Dependent on the initial operative cup position, the risk can be increased by reduced postero-inferior acetabular restraint.

## References

- [1] Lewinnek GE, Lewis JL, Tarr R, Compere CL, Zimmerman JR. Dislocations after total hip-replacement arthroplasties. *J Bone Joint Surg Am* 1978;60:2.
- [2] Abdel M, von Roth P, Jennings M, Hanssen A, Pagnano M. What safe zone? The vast majority of dislocated THAs are within the Lewinnek safe zone for acetabular component position. *Clin Orthop Relat Res* 2016;474:2.

- [3] Lazennec JY, Brusson A, Rousseau M-. THA Patients in standing and sitting positions: a prospective evaluation using the low-dose "full-body" eosA® imaging system. *Semin Arthroplasty* 2012;23:4.
- [4] Kanawade V, Dorr L, Wan Z. Predictability of acetabular component angular change with postural shift from standing to sitting position. *J Bone Joint Surg Am* 2014;96:12.
- [5] Halawi MJ, Haddad FS. Functional acetabular component alignment. *Bone Joint J* 2018;100-B:10.
- [6] Eftekhary N, Shimmin A, Lazennec JY, Buckland A, Schwarzkopf R, Dorr LD, et al. A systematic approach to the hip-spine relationship and its applications to total hip arthroplasty. *Bone Joint J* 2019;101-B:7.
- [7] Larkin B, van Holsbeeck M, Koueiter D, Zaltz I. What is the impingement-free range of motion of the asymptomatic hip in young adult males? *Clin Orthop Relat Res* 2015;473:4.
- [8] Esposito C, Gladnick B, Lee Y, Lyman S, Wright T, Mayman D, et al. Cup position alone does not predict risk of dislocation after hip arthroplasty. *J Arthroplasty* 2015;30:1.
- [9] Pierrepoint JW, Feyen H, Miles BP, Young DA, Bare JV, Shimmin AJ. Functional orientation of the acetabular component in ceramic-on-ceramic total hip arthroplasty and its relevance to squeaking. *Bone Joint J* 2016;98-B:7.
- [10] Heckmann N, McKnight B, Stefl M, Trasolini N, Ike H, Dorr L. Late dislocation following total hip arthroplasty: spinopelvic imbalance as a causative factor. *J Bone Joint Surg Am* 2018;100:21.
- [11] Sultan A, Kholpas A, Piuzei N, Chughtai M, Sodhi N, Mont M. The impact of spino-pelvic alignment on total hip arthroplasty outcomes: a critical analysis of current evidence. *J Arthroplasty* 2018;33:5.
- [12] Esposito C, Miller T, Kim H, Barlow B, Wright T, Padgett D, et al. Does degenerative lumbar spine disease influence femoroacetabular flexion in patients undergoing total hip arthroplasty? *Clin Orthop Relat Res* 2016;474:8.
- [13] Pierrepoint JW, Feyen H, Miles BP, Young DA, Bare JV, Shimmin AJ. Functional orientation of the acetabular component in ceramic-on-ceramic total hip arthroplasty and its relevance to squeaking. *Bone Joint J* 2016;98-B:7.
- [14] Snijders T, Schlösser T, van Stralen M, Castelein RM, Stevenson RP, Weinans H, et al. The effect of postural pelvic dynamics on the three-dimensional orientation of the acetabular cup in total hip arthroplasty. *Clin Orthop Relat Res* 2020.
- [15] Dawson Amoah K, Raszewski J, Duplantier N, Waddell B. Dislocation of the hip: a review of types, causes, and treatment. *Ochsner J* 2018;18:3.
- [16] Zahar A, Rastogi A, Kendoff D. Dislocation after total hip arthroplasty. *Curr Rev Musculoskelet Med* 2013;6:4.
- [17] Tezuka T, Heckmann N, Bodner R, Dorr L. Functional safe zone is superior to the Lewinnek safe zone for total hip arthroplasty: why the Lewinnek safe zone is not always predictive of stability. *J Arthroplasty* 2019;34:1.
- [18] Snijders TE, Schlösser TPC, van Gaalen SM, Castelein RM, Weinans H, de Gast A. Trigonometric algorithm defining the true three-dimensional acetabular cup orientation: correlation between measured and calculated cup orientation angles. *JB JS Open Access* 2018;3:3.
- [19] Pierrepoint J, Hawdon G, Miles BP, O'Connor B, Baré J, Walter LR, et al. Variation in functional pelvic tilt in patients undergoing total hip arthroplasty. *Bone Joint J* 2017;99-B:2.
- [20] Buckland A, Vigdorichik J, Schwab F, Errico T, Lafage R, Ames C, et al. Acetabular anteversion changes Due to spinal deformity correction: bridging the gap between hip and spine surgeons. *J Bone Joint Surg Am* 2015;97:23.
- [21] Heckmann H, Tezuka T, Bodner R, Dorr L. Functional anatomy of the hip joint. *J Arthroplasty* 2020;1:5.
- [22] Buckland A, Ayres E, Shimmin A, Bare J, McMahon S, Vigdorichik J. Prevalence of sagittal spinal deformity among patients undergoing total hip arthroplasty. *J Arthroplasty* 2020;35:1.
- [23] Lembeck B, Mueller O, Reize P, Wuelker N. Pelvic tilt makes acetabular cup navigation inaccurate. *Acta Orthop* 2005;76:4.
- [24] Kalteis T, Handel M, Herbst B, Grifka J, Renkawitz T. In vitro investigation of the influence of pelvic tilt on acetabular cup alignment. *J Arthroplasty* 2009;24:1.
- [25] Ranawat CS, Ranawat AS, Lipman JD, White PB, Meftah M. Effect of spinal deformity on pelvic orientation from standing to sitting position. *J Arthroplasty* 2016;31:6.
- [26] Stefl M, Lundergan W, Heckmann N, McKnight B, Ike H, Murgai R, et al. Spinopelvic mobility and acetabular component position for total hip arthroplasty. *Bone Joint J* 2017;99-B(1 Suppl A).
- [27] Berry D, von Knoch M, Schleck C, Harmsen W. Effect of femoral head diameter and operative approach on risk of dislocation after primary total hip arthroplasty. *J Bone Joint Surg Am* 2005;87:11.
- [28] McCollum DE, Gray WJ. Dislocation after total hip arthroplasty. Causes and prevention. *Clin Orthop Relat Res* 1990;261.
- [29] Padgett DE, Warashina H. The unstable total hip replacement. *Clin Orthop Relat Res* 2004;420.
- [30] Coventry MB. Late dislocations in patients with Charnley total hip arthroplasty. *J Bone Joint Surg Am* 1985;67:6.
- [31] Daly PJ, Morrey BF. Operative correction of an unstable total hip arthroplasty. *J Bone Joint Surg Am* 1992;74:9.

## Appendix

### Supplemental material

The effect of functional pelvic tilt on the three-dimensional acetabular cup orientation in late total hip arthroplasty dislocations. The 3-D acetabular cup orientation can be defined by the following angles according to the definitions of the Hip-Spine Workgroup [6]:

- Coronal inclination (CI): the rotation of inclination of the cup around the anterior-posterior axis in the coronal plane.
- Sagittal ante-inclination (AI): the sagittal angle of the cup that includes inclination and anteversion that changes with posterior and anterior tilt of the pelvis.
- Transverse version (TV): the anteversion angle of the cup around the cranio-caudal axis in the transverse plane.

Two of these angles measured on biplanar radiographs can be used to calculate the third by using previously validated trigonometric algorithms. [16,22].

The first algorithm is based on an equation that the orientation of the hemispherical cup given in the three orthogonal anatomical planes in a static situation is given by:

$$\tan(AI) = \tan(TV) * \tan(CI) \quad [1]$$

With the second algorithm, the standing and sitting 3-D cup orientations can be calculated, considering that sagittal pelvic tilt is a rotation of the pelvis and acetabular cup around the transverse hip-axis and that 1° change of sagittal pelvic tilt equals 1° of change in the sagittal orientation of the cup [12]. Therefore, a new AI position ( $AI'$ ), is related to a new CI ( $CI'$ ) and new TV ( $TV'$ ) by:

With the auxiliary variable

$$t(CI, TV) = \sqrt{(\tan TV)^2 + 1} / (\tan CI)^2 \quad [2]$$

the tangent of the other two new angles are given by

$$\tan(CI') = \frac{1}{t * \cos SI'} \quad [3]$$

$$\tan(TV') = t * \sin AI' \quad [4]$$

The algorithms are incorporated in a developed tool available at, [www.3d-hip.com](http://www.3d-hip.com).

