



## UvA-DARE (Digital Academic Repository)

### Optical diagnostics in upper urinary tract carcinoma

Bus, M.T.J.

**Publication date**

2019

**Document Version**

Final published version

**License**

Other

[Link to publication](#)

**Citation for published version (APA):**

Bus, M. T. J. (2019). *Optical diagnostics in upper urinary tract carcinoma*. [Thesis, fully internal, Universiteit van Amsterdam].


**General rights**

It is not permitted to download or to forward/distribute the text or part of it without the consent of the author(s) and/or copyright holder(s), other than for strictly personal, individual use, unless the work is under an open content license (like Creative Commons).

**Disclaimer/Complaints regulations**

If you believe that digital publication of certain material infringes any of your rights or (privacy) interests, please let the Library know, stating your reasons. In case of a legitimate complaint, the Library will make the material inaccessible and/or remove it from the website. Please Ask the Library: <https://uba.uva.nl/en/contact>, or a letter to: Library of the University of Amsterdam, Secretariat, Singel 425, 1012 WP Amsterdam, The Netherlands. You will be contacted as soon as possible.

# OPTICAL DIAGNOSTICS IN UPPER URINARY TRACT CARCINOMA

A stylized, light blue anatomical diagram of the upper urinary tract is positioned in the lower right quadrant of the cover. It shows the kidneys, ureters, and the bladder in a simplified, rounded style.

**Mieke T.J. Bus**



# Optical Diagnostics in Upper Urinary Tract Carcinoma

Mieke Theodora Jenneke Bus

Optical Diagnostics in Upper Urinary Tract Carcinoma  
Academic Thesis, University of Amsterdam, the Netherlands

Copyright © M.T.J. Bus 2019

All rights reserved. No part of this thesis may be reproduced, stored or transmitted in any form or by any means without prior permission of the author

Cover: Jose Llopis, SOOAK  
Lay-out: Sandra Tukker, Ridderprint  
Printed by: Ridderprint  
ISBN: 978-94-6375-483-5

The preparation of this thesis was generously funded by AMC, Astellas Pharma B.V., Chipsoft B.V., KARL STORZ Endoscopie Nederland B.V., Olympus Nederland B.V., Stöpler Medical B.V.

Optical Diagnostics in Upper Urinary Tract Carcinoma

ACADEMISCH PROEFSCHRIFT

ter verkrijging van de graad van doctor

aan de Universiteit van Amsterdam

op gezag van de Rector Magnificus

prof. dr. Ir. K.I.J. Maex

ten overstaan van een door het College voor Promoties ingestelde commissie,

in het openbaar te verdedigen in de Agnietenkapel

op donderdag 3 oktober 2019, te 12.00 uur

door Mieke Theodora Jenneke Bus

geboren te Brummen

## Promotiecommissie

Promotores:	Prof. dr. A.G.J.M. van Leeuwen	AMC-UvA
	Dr. T.M. de Reijke	AMC-UvA
Co-promotor:	Dr. D.M. de Bruin	AMC-UvA
Overige leden:	Prof. dr. M.J. van de Vijver	AMC-UvA
	Prof. dr. J.J.G.H.M. Bergman	AMC-UvA
	Prof. dr. ir. H.J.C.M. Sterenborg	AMC-UvA
	Dr. P.I. Bonta	AMC-UvA
	Prof. dr. R.J.A. van Moorselaar	Vrije Universiteit Amsterdam
	Dr E.P. van Haarst	OLVG

## Faculteit der Geneeskunde

*Voor mijn ouders*





## Table of Contents

Chapter 1	General introduction & Outline of this thesis.....	9
Chapter 2	Current position of diagnostics and surgical treatment for upper urinary tract urothelial carcinoma.....	17
Chapter 3	Optical diagnostics for upper urinary tract urothelial cancer: technology, thresholds and clinical applications.....	31
Chapter 4	Volumetric in-vivo visualization of upper urinary tract tumors using optical coherence tomography: a pilot study.....	51
Chapter 5	Optical coherence tomography as a tool for in vivo staging and grading of upper urinary tract urothelial carcinoma: a study for diagnostic accuracy.....	67
Chapter 6	Three-dimensional ex-vivo visualization of the ureter and urothelial carcinoma using optical coherence tomography and endoluminal ultrasound.....	85
Chapter 7	Discussion and future perspectives.....	103
Chapter 8	Summary.....	115
	Samenvatting.....	119
Chapter 9	List of Publications.....	127
	Portfolio.....	131
	Dankwoord.....	133
	Curriculum Vitae.....	137



# GENERAL INTRODUCTION & OUTLINE OF THIS THESIS


*Based on:*

*Ontwikkelingen bij de diagnose, behandeling en follow-up van  
urotheelcelcarcinoom in de hoge urinewegen*

*Bus MT, Kamphuis GM, Zondervan PJ, Laguna Pes MP,  
de la Rosette JJ, de Reijke ThM*

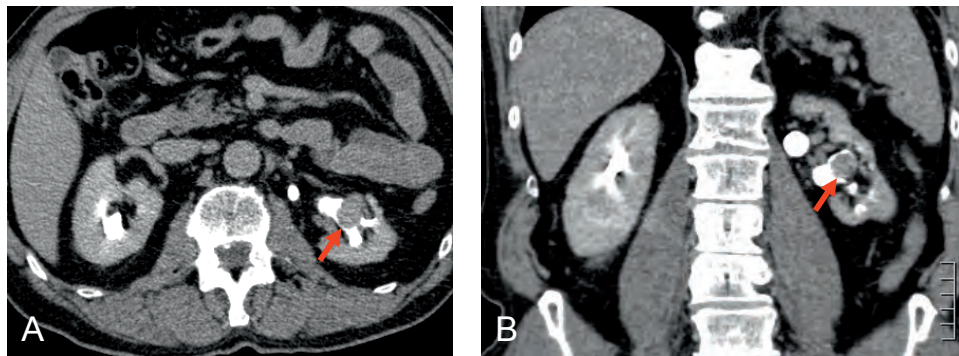
*Nederlands Tijdschrift voor Geneeskunde 2014;158(0):A7347*

---



## Urothelial carcinoma of the upper urinary tract

The urinary tract is divided in the lower and upper urinary tract. The lower urinary tract encompasses the urinary bladder and the proximal urethra in females and the prostatic urethra in males. The upper urinary tract encompasses the renal calyces, pelvis and ureter. The epithelial lining of the urinary tract is called the urothelium and it is from this cell layer that urothelial carcinoma derives (figure 1).



**Figure 1:** CT-urography showing contrast excretion phase. (a) axial cross-sectional imaging demonstrating a filling defect in the left pyelum, suggestive for tumour growth (red arrow). (b) the same tumour in coronal cross-sectional imaging (red arrow). Ureterorenoscopy following the CT scan demonstrated a tumour in the pyelum.

Urothelial carcinoma can occur at any site of the urinary tract. Upper tract tumours are rare compared to bladder tumours. Ninety five percent of all urothelial cancers occur in the bladder versus 5% in the upper urinary tract. Upper urinary tract urothelial carcinoma (UTUC) and urothelial carcinoma (UC) of the bladder can develop synchronously or metachronously in a multifocal way. Identified risk factors for urothelial cancer apply to both the upper urinary tract and lower urinary tract. However, the natural course and genetical characteristics of UTUC differ from UC of the bladder and the anatomy of the upper urinary tract requires a different approach to diagnosis and therapy compared to bladder tumours. Moreover, there are upper urinary tract specific risk factors identified for developing UTUC, underlying the different pathogenesis.<sup>1</sup> For these reasons UTUC cannot be considered as a bladder tumour in the upper urinary tract and should be considered as a distinct entity from bladder carcinoma. Diagnosis, treatment and follow-up should be specified to UTUC.

Over the past decades, radical nephroureterectomy is considered the gold standard in the treatment of UTUC. Surgery consists of extrafascial dissection of the kidney and entire length of ureter including a bladder cuff (figure 2).

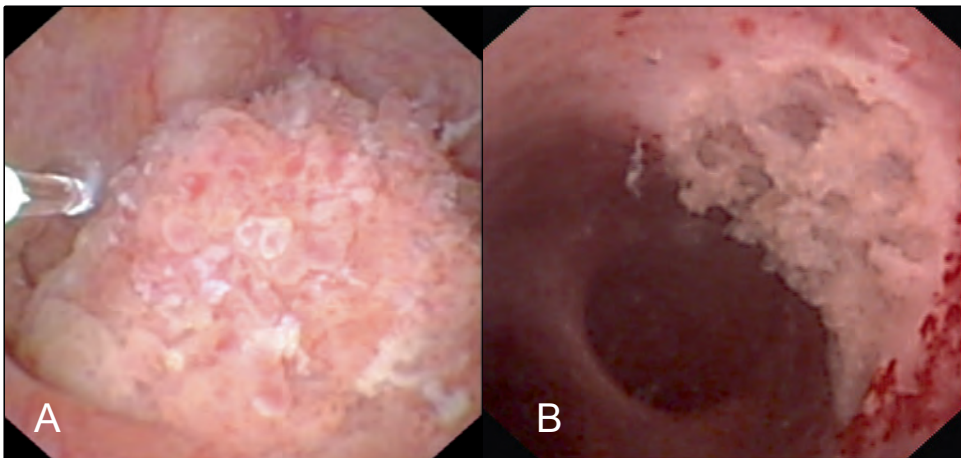


**Figure 2:** Radical Nephroureterectomy specimen, including bladder cuff.

This surgery provides excellent disease control since the complete affected system is removed. Unfortunately, estimated Glomerular Filtration Rate (eGFR) decreases significantly in patients with UTUC following nephroureterectomy. The ultimate chronic kidney disease (CKD) is associated with a significant increase in cardiovascular events and death of any cause, independent of co-existing comorbidities.<sup>2-5</sup>

Because of this significant increase in mortality and morbidity due to CKD, renal parenchyma sparing endoscopic treatment by laser ablation is nowadays accepted in a selected group of patients (figure 3).

Major advantage of this treatment is preservation of renal function. In addition, the patient is spared the morbidity associated with radical surgery. Historically, endoscopic treatment of UTUC was preserved for imperative cases like renal insufficiency, anatomical or functional solitary-kidney, bilateral disease and for those who are not fit to undergo radical surgery. Nowadays, conservative endoscopic treatment becomes also more accepted in elective cases of patients with a normal functioning contralateral kidney.



**Figure 3:** Upper urinary tract tumour on Ureterorenoscopy. (a) pyelumtumour visualized during diagnostic URS before laser vaporisation. In the left the laser fiber is visible. (b) pyelum lesion after laser vaporisation of the tumour.

This treatment can only be applied without compromising survival rates, in a strictly selected patient group with low-grade, non-invasive disease who is able to undergo a stringent surveillance following treatment, since conservative treatment is at risk of recurrences and progression.<sup>1</sup>

For tumour classification both tumour stage and tumour grade will be assessed by the pathologist.

**Table 1:** Tumour classification (T-stage) of ureter and pyelum tumours according the TNM classification system of the UICC (2009).

stage	ureter	pyelum
Tx	Primary tumour cannot be assessed	Primary tumour cannot be assessed
T0	No evidence of primary tumour	No evidence of primary tumour
Ta	Non-invasive papillary tumour	Non-invasive papillary tumour
Tis	carcinoma <i>in situ</i>	carcinoma <i>in situ</i>
T1	tumour invades lamina propria	tumour invades lamina propria
T2	tumour invades muscularis propria	tumour invades muscularis propria
T3	tumour invades beyond muscularis into periureteral fat	tumour invades beyond muscularis into peripelvic fat or renal parenchyma
T4	tumour invades adjacent organs	tumour through the kidney into perinephric fat or adjacent organs

UICC = Union for International Cancer Control.

The TNM classification of the Union for International Cancer Control (UICC) is currently the most used system for staging of upper urinary tract tumours (Table 1).

For tumour grading two systems exist, the system of the World Health Organisation (WHO) dating from 1973 and the system dating from 2004 of the WHO and International Society of Urological Pathology (ISUP).

### What are the challenges in UTUC?

Now endoscopic treatment using ureterorenoscopy has been recognized as a kidney sparing treatment of low risk UTUC, knowledge of tumour stage and grade is needed for clinical decision making to decide which patients are eligible for endoscopic treatment.<sup>6</sup> Overall consensus is that this technique can only be applied in patients with low-grade and low stage disease.<sup>1</sup> However, adequate identification and diagnosis of all UTUC lesions is challenging with the available diagnostic methods. One of the main challenges in patient selection for endoscopic treatment of UTUC is to obtain a reliable histopathological diagnosis.

Unfortunately, current methods to obtain histopathological diagnosis are limited. Biopsy specimens retrieved during ureterorenoscopy are frequently minute, because of the

application of small caliber instruments, and may, therefore, be difficult to examine by the pathologist.<sup>7</sup>

The difficulty to obtain a reliable histopathological diagnosis leads to a high rate of tumour upgrading/upstaging following nephroureterectomy.<sup>7</sup> Optimizing endoscopic visualization and diagnosis of UTUC is therefore needed. Optical diagnostics are new techniques that have potential to improve the diagnosis of UTUC. Optical diagnostics are based on the interaction of light with tissue. These differences are caused by interactions such as scattering, absorption and fluorescence, all of which are characteristic for certain tissue types. Techniques like NBI, IMAGE1 S™ (formerly known as SPIES) and PDD aim at better visualisation of urothelial tumours and therefore, increased tumour detection rates, while techniques like OCT and CLE aim at providing real time intra-operative information about tumour grade and stage. By detecting differences between the incident and detected light, they can provide information on tissue that is under investigation. Developments in optical diagnostics might reduce the limitations of the current diagnostic methods. Most research on the application of optical diagnostics on urothelium has been done in the field of bladder cancer.<sup>8,9</sup> One can presume that results on bladder urothelium resemble upper urinary tract urothelium and can be extrapolated to the upper urinary tract. However, the limited space in the upper urinary tract and the difficulty reaching the upper urinary tract creates a whole new spectrum of challenges for the urologists, the technique and result interpretation. The attitude towards the treatment of UTUC has been changed dramatically over the past decades by the acceptance of conservative treatment for low-risk UTUC in patients with a healthy contralateral kidney. Therefore, treatment should be carefully tailored for each individual patient, based on tumour grade, tumour stage, cytology, multifocality, and tumour size. One of the main challenges in patient selection for conservative treatment of UTUC is to obtain a reliable histopathological diagnosis. Current methods have all their inherent limitations. Recent developments in optical diagnostics showed potential to improve the diagnostic work-up of UTUC.

In this thesis we aim to assess the possibilities of optical techniques to optimize diagnosis of upper urinary tract tumours.

In the first part of this thesis we explore the application of optical diagnostics in the upper urinary tract. To that end, we determine the need for new diagnostic techniques in the diagnostic work-up of UTUC patients. A survey among (endo)urologists is presented in **Chapter 2**. If we understand this need, future studies can be specifically designed to meet the needs for new diagnostic studies. In **Chapter 3** we provide an overview of technology, applications and limitations of five recently developed optical diagnostics in the upper urinary tract and outline their potential for future applications.



One of these techniques, Optical Coherence Tomography (OCT), can hypothetically provide the urologist with real-time intra-operative information on tumour grade and stage. In the second part of the thesis we aim to evaluate the diagnostic accuracy of OCT for grading and staging of UTUC. For this aim, both in vivo and ex vivo studies were carried out in the urological clinic.

In **Chapter 4**, we present a pilot study where eight patients were examined in vivo with UTUC with OCT. We analysed the images in a qualitative way by visually inspecting OCT images and dividing visible lesions in invasive and non-invasive lesions by identifying the basement membrane. Furthermore, we analysed the images in a quantitative way by means of the attenuation coefficient and we tested if the attenuation coefficient could discriminate between high-grade and low-grade lesions. In **Chapter 5** we examined the ability of OCT as a tool for grading and staging of low-grade, high-grade and carcinoma in situ (CIS) lesions in the upper urinary tract. Next, we evaluated sensitivity and specificity of OCT in UTUC and established the inter-observer variability of OCT. Although OCT produces high resolution cross-sectional images of the ureter, its imaging depth is limited to 1-2 mm. Therefore, tumour sizes that transcend OCT imaging depth range cannot be reliably examined using OCT. Endoluminal Ultrasound (ELUS) has an increased imaging depth range compared to OCT, but produces images of a low resolution. In **Chapter 6** we examined if combined OCT and ELUS improves the capability to visualize and distinguish the anatomical layers of the human ureter and if both investigations could discriminate between normal and suspicious tissue. Therefore, we performed an OCT and ELUS measurement of the complete pyelum and ureter in five nephroureterectomy specimens.

Finally, based on the results described in this thesis and on the literature, a reflection on the current position of optical diagnostics, in particular OCT, for the upper urinary tract is discussed in **Chapter 7**.

## Reference list

1. Roupert M, Babjuk M, Comperat E, et al. European Association of Urology Guidelines on Upper Urinary Tract Urothelial Cell Carcinoma: 2015 Update. *Eur Urol* 2015; 68(5): 868-79.
2. Lane BR, Smith AK, Larson BT, et al. Chronic kidney disease after nephroureterectomy for upper tract urothelial carcinoma and implications for the administration of perioperative chemotherapy. *Cancer* 2010; 116(12): 2967-73.
3. Go AS, Chertow GM, Fan D, McCulloch CE, Hsu CY. Chronic kidney disease and the risks of death, cardiovascular events, and hospitalization. *NEnglJMed* 2004; 351(13): 1296-305.
4. Xylinas E, Rink M, Margulis V, et al. Impact of renal function on eligibility for chemotherapy and survival in patients who have undergone radical nephro-ureterectomy. *BJUInt* 2013; 112(4): 453-61.
5. Kaag MG, O'Malley RL, O'Malley P, et al. Changes in renal function following nephroureterectomy may affect the use of perioperative chemotherapy. *EurUrol* 2010; 58(4): 581-7.
6. Ristau BT, Tomaszewski JJ, Ost MC. Upper tract urothelial carcinoma: current treatment and outcomes. *Urology* 2012; 79(4): 749-56.
7. Wang JK, Tollefson MK, Krambeck AE, Trost LW, Thompson RH. High rate of pathologic upgrading at nephroureterectomy for upper tract urothelial carcinoma. *Urology* 2012; 79(3): 615-9.
8. Cauberg EC, de Bruin DM, Faber DJ, van Leeuwen TG, de la Rosette JJ, de Reijke TM. A new generation of optical diagnostics for bladder cancer: technology, diagnostic accuracy, and future applications. *EurUrol* 2009; 56(2): 287-96.
9. Liu JJ, Droller MJ, Liao JC. New optical imaging technologies for bladder cancer: considerations and perspectives. *JUrol* 2012; 188(2): 361-8.



# CURRENT POSITION OF DIAGNOSTICS AND SURGICAL TREATMENT FOR UPPER URINARY TRACT UROTHELIAL CARCINOMA

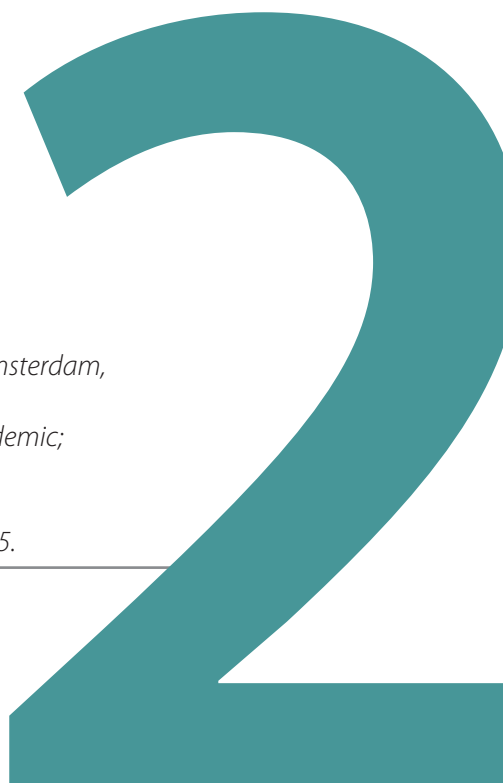MT Bus<sup>1</sup>, DM de Bruin<sup>2</sup>, GM Kamphuis<sup>1</sup>,  
PJ Zondervan<sup>1</sup>, MP Laguna Pes<sup>1</sup>, TM de Reijke<sup>1</sup>,  
TG van Leeuwen<sup>2</sup>, JJ de la Rosette<sup>1</sup>

<sup>1</sup> Department of Urology; Academic Medical Center, Amsterdam,  
the Netherlands

<sup>2</sup> Department of Biomedical Engineering & Physics Academic;  
Medical Center, Amsterdam, the Netherlands

*Minerva Urologica e Nefrologica* 2017 Apr;69(2):159-165.

---



## **Abstract**

### **Introduction**

The applicability of urinary biomarkers and optical diagnostics in upper urinary tract carcinoma (UTUC) are increasingly debated. To receive insight in the opinion of the urological community involved in this field, a survey was sent out to identify the most promising techniques and understand the need for new diagnostics. Primary objective of this study was to provide an overview of current diagnostics in upper urinary tract urothelial carcinoma. Secondary objectives of this study was to assess the need for additional diagnostic techniques in the current diagnostic work-up for UTUC and to assess knowledge of novel techniques

### **Methods**

An electronic survey was distributed to all participants of the upper urinary tract tumour registration study by the Clinical Research Office of the Endourological Society. Additionally, based on publications, experts in the field were contacted. Analysis was performed on the results overviewed by the survey monkey website.

### **Results**

In total 81 of the 112 invited individuals responded resulting in a response rate of 72.3%. Most urologists involved in the treatment of upper urinary tract tumours follow the guidelines in their diagnostic work-up of patients suspected for UTUC. 61.4% of all responders consider current available diagnostic methods insufficient to select patient candidates for conservative renal sparing surgery. According to the responders, digital endoscopes for retrograde intrarenal surgery (RIRS) including narrow band imaging (NBI) are best known and most likely to be beneficial compared to all evaluated diagnostic tools currently available.

### **Conclusions**

Urologists consider current diagnostic techniques for upper urinary tract tumours insufficient for optimal patient selection for conservative renal sparing surgery. Among the new techniques, NBI and digital RIRS are best known and considered to be beneficial in the diagnostic work-up.

## Introduction

At present, the applicability of urinary biomarkers and optical diagnostic methods are explored in UTUC.<sup>1,2</sup> Accuracy in predicting grade and stage of the current diagnostic techniques is limited, making optimal patient selection for nephron sparing surgery difficult.<sup>2</sup> However, most of the results on novel techniques for UTUC are still preliminary or with low level of evidence.<sup>2</sup> The rarity of the disease hampers patient inclusion to reach adequate sample sizes to prove diagnostic accuracy, especially in a short time.

Optical diagnostics is a collective term for methods based on the interaction of light with tissue. These interactions include scattering, absorption and fluorescence, all of which are characteristic for certain tissue types. Narrow band imaging (NBI), STORZ® professional imaging enhancement system (SPIES<sup>1</sup>), digital endoscopes for retrograde intrarenal surgery (RIRS) and photodynamic imaging (PDD) aim at improved visualization of tumours. NBI is already successfully implemented in the field of gastroenterology to improve tumour detection rate during gastroscopy and colonoscopy.<sup>3,4</sup> PDD has established its position in the diagnosis of tumours in the urinary bladder and NBI has been implemented in both the urinary bladder and upper urinary tract.<sup>5-7</sup> Optical coherence tomography (OCT) and confocal laser endomicroscopy (CLE), provide real-time high-resolution histology-like images. Favorable results with CLE and OCT have been obtained in the urinary bladder. Although results on both CLE and OCT in the upper urinary tract are preliminary, application of OCT and CLE in the upper urinary tract is technically feasible and first results are positive.<sup>8-11</sup>

Finally, a biomarker that supports a reliable diagnosis of UTUC would make most of the current techniques redundant. In UTUC, the best studied biomarker is fluorescence in situ hybridisation (FISH), also used in gastroenterology and bladder cancer.<sup>12,13</sup> In 2000, a FISH probe assay on voided urine specimen was designed for bladder cancer, called UroVysion, which was demonstrated to be a reliable method in the diagnosis of UTUC in cases with clinical suspicion.<sup>14</sup>

To gain insight in the current practice pattern and meaning of urologists for additional diagnostics we sent out a web-based survey.

Primary objective of this study was to provide an overview of current diagnostics in upper urinary tract urothelial carcinoma. Secondary objectives of this study were to assess the need for additional diagnostic techniques in the current diagnostic work-up for UTUC and to assess knowledge of novel techniques.

## Methods

### *Survey*

An electronic survey was generated ([www.surveymonkey.com](http://www.surveymonkey.com)) based on recommendations in the guidelines, recent literature on novel diagnostics and expert opinion. The survey was distributed by email to all registered participants (September 30<sup>th</sup>, 2014) of the UTUC registry study coordinated by the Clinical Research Office of the Endourological Society (CROES) and to experts in the field based on their publications. Four emails were sent containing a link to the electronic survey between October 1<sup>th</sup> 2014 and October 24<sup>th</sup> 2014.<sup>15</sup> The survey contained three demographic questions, six questions regarding patterns of practice, two questions regarding the influence of literature and nine questions regarding new diagnostic techniques. Only multiple-choice questions were used. Based on previous replies, non-applicable questions were automatically omitted. Answers of responders who did not perform endoscopic treatment were also omitted.

### *Survey Analysis*

Statistical analysis was carried out using SPSS version 21. The Pearson chi-square test was applied on cross tables to assess distribution of numerical data between the different groups of responders. Responses on knowledge and additional benefit of new diagnostics (Yes, No, I am not familiar with this technique and I do not know) were expressed in percentages of the total response.

## Results

In total 81 of the 112 invited individuals responded (72.3%). Overall 70 responders performed endoscopic treatment in UTUC patients. Demographic data are listed in table 1. Responders were mostly working in Europe (65.4%) and in University Hospitals (71.6%).

### *Patterns in practice*

The majority of the responders see more than 5 new cases per year with UTUC (91%). Among the responders, the majority has experience with endoscopic treatment of UTUC. Only 5.1% of the responders refer patients for endoscopic treatment and 3.9% of the responders always perform radical nephroureterectomy. Most responders (74.3%) perform endoscopic treatment in patients with a healthy contralateral kidney (table 2). The specific setting of performed endoscopic treatment related to the type of patients and tumour characteristics was not captured by the survey.

**Table 1:** Demographic details of the respondents

<b>Region of Practice</b>	
North America	18.5%
Europe	65.4%
Asia	3.7%
South America	6.2%
N Africa	2.5%
Subsaharan Africa	1.2%
Middle East	2.5%
Australia	0%
<b>Type of Practice</b>	
University Hospital	71.6%
Non-university training hospital	22.2%
Non-university non-training hospital	4.9%
Private practice	1.2%
<b>Years of Endourologic experience</b>	
1-5 yr	17.3%
6-10 yr	16.0%
11-15 yr	18.5%
16-20 yr	17.3%
> 20 yr	30.9%



**Table 2:** Patterns in practice of the respondents

<b>How many new cases per year do you see with UTUC?</b>	
<5	9.0%
6-10	34.6%
11-15	20.5%
16-20	19.2%
21-25	2.6%
>25	14.1%
<b>Do you perform endoscopic treatment yourself?</b>	
Yes, but only in a palliative setting	1.3%
Yes, but only in imperative cases	15.4%
Yes, in selected patients with a normal contralateral kidney	12.8%
Yes, in all the above	61.5%
No, I refer patients for endoscopic treatment	5.1%
No	3.9%
<b>How often do you perform endoscopic treatment in patients with a healthy contralateral kidney?</b>	
Never	5.7%
In rare cases	27.1%
In up to 25% of the cases	34.3%
In up to 50% of the cases	18.6%
In up to 75% of the cases	8.6%
In up to 100% of the cases	5.7%

*Diagnostics in UTUC*

CT urography (97.2%), Ureterorenoscopy (94.4%), Biopsy (87.3%), Cytology (selective cytology 80.3% and urine cytology 74.6%) and Cystoscopy (80.3%) are routinely used in the diagnostic work-up of patients suspected of UTUC. MRI, Intravenous pyelogram and retrograde pyelogram are less frequently used (table 3).

**Table 3:** Responses on diagnostics in patients with UTUC

<b>Selective Cytology</b>		80.3%
	Using a ureter catheter	76.7%
	Using renal pelvis washing during URS	63.3%
	other	0%
<b>Urine Cytology</b>		74.6%
	Spontaneous	74.6%
	Bladder wash out	34.3%
	other	7.5%
<b>Cystoscopy</b>		80.3%
<b>Ureterorenoscopy</b>		94.4%
	Semi Rigid	62.0%
	Rigid	8.5%
	Flexible	90.1%
<b>CT-urography</b>		97.2%
<b>MRI</b>		9.9%
<b>Intravenous Pyelogram</b>		12.7%
<b>Retrograde Pyelogram</b>		53.5%
<b>Biopsy of upper urinary tract lesion/tumour</b>		87.3%

### *Literature*

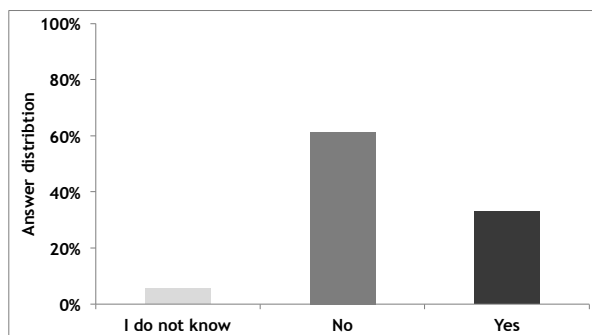
The influence of the literature for performing conservative management of UTUC is depicted in table 4. Literature has changed the attitude towards conservative management of UTUC in 70.6% of the responders. The guideline of the European Association of Urology (EAU) is the best known of all guidelines <sup>16</sup>.

**Table 4:** Influence and knowledge of the recent literature of the respondents

Do you have a changed attitude towards conservative treatment of UTUC by recent literature?	
Not at all	29.6%
Yes, for patients with (functional) solitary kidney	21.3%
Yes, for patients with a healthy contralateral kidney	49.3%
Are you familiar with the following guidelines?	
AUA guidelines on UTUC	47.8%
EAU guidelines on UTUC	91.0%
ICUD consensus on UTUC, 2013, Vancouver, Canada	22.4%

*New Techniques*

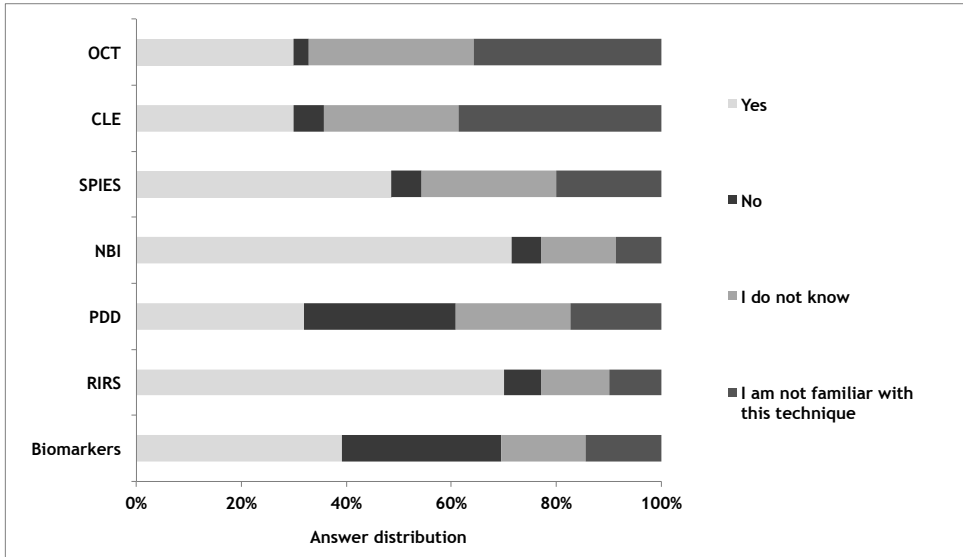
Of all responders, 61.4% consider current available diagnostic methods insufficient for an optimal patient selection (figure 1). Pearson chi-square test showed equal distribution over the knowledge of the guidelines and type of practice (p-value = 0.124).



**Figure 1:** Graphic displaying the distribution of the question (number 14) “do you consider the current diagnostic techniques sufficient for optimal patient selection?” “No”; 61.4% (n=43), “Yes”; 32.9% (n=23) and “I do not know” by 5.7% (n=4) of the responders.

OCT and CLE, both aiming for real-time histopathology, are less known among urologists. Optical techniques that aim to improve tumour detection (NBI 71.4%, PDD 31.9%, SPIES 48.6%, digital RIRS 70.0%), are widely known and most techniques are promising according to the responders, except for PDD. Around one third of responders (29%) see no additional benefit of PDD in the diagnostic work up of upper urinary tract tumours. From the responders, 30.4% see no additional benefit on the use of urinary biomarkers (figure 2). Pearson chi-square tests showed equal distribution over the knowledge of the different optical diagnostics and urinary biomarkers and type of practice (University al vs. non-university

hospital); (OCT p-value = 0.320, CLE p-value = 0.435, SPIES p-value 0.435, NBI p-value = 0.949, PDD p-value 0.877, digital RIRS p-value = 0.722, urinary biomarkers p-value = 0.748).



**Figure 2:** Additional benefit of techniques in the diagnostic work-up of upper urinary tract tumours. The answers are grouped in four categories; “Yes”, “No”, “I do not know and I am not familiar with this technique”.

## Discussion

Over the past decade, conservative endoscopic treatment has gained increased interest for a selected group of patients with UTUC. Not only in case of a mandatory indication (patients with (functional) solitary kidney) but also for patients with low-volume, low-grade, low-stage disease and a healthy contralateral kidney. This radical change in treatment of low-risk UTUC requires high demands on the armamentarium and the expertise of the urologist. Our survey demonstrates an overview of current used techniques among urologists treating UTUC. Most urologists involved in the treatment of upper urinary tract tumours follow the guidelines in their diagnostic work-up of patients suspected for UTUC. Urologists participating in this survey consider the current available diagnostics insufficient to select patients for endoscopic management. 70.6% of the urologists participating in this survey responded that recent literature has changed their attitude towards conservative management of UTUC, underlining that the diagnosis and treatment of UTUC is rapidly changing. For this reason, the opportunity for endoscopic treatment (and therefore novel diagnostic techniques) will increase in the future.

### *Diagnostic work-up of UTUC*

The EAU guideline recommends performing a diagnostic URS including biopsy, urinary cytology, CT-urography and retrograde pyelography in patients with UTUC.<sup>16</sup> Most urologists involved in the treatment of upper urinary tract tumours follow the guidelines in their diagnostic work-up of patients suspected for UTUC as showed in table 3. Current diagnostics have several limitations, withholding a safe patient selection for conservative treatment of UTUC. During URS, carcinoma in situ (CIS) is easily missed and histopathological diagnosis obtained during URS is often inconclusive due to the difficulties of tissue sampling hampering adequate pathological diagnosis.<sup>17,18</sup> Additionally, cytology yields a low sensitivity and specificity and the diagnostic accuracy of CT urography decreases in case of small and/or flat lesions.<sup>19-21</sup> These facts underline the need for new diagnostic techniques in order to reliably select patients for endoscopic treatment.

### *Advancements in diagnostics for the upper tract*

Most research on the application of diagnostics on urothelium has been done in the field of bladder cancer.<sup>22-24</sup> However, recent technological improvements have made the optical techniques feasible in the upper urinary tract. We asked the responders if there is an additional benefit in the diagnostic work-up for optical technologies. Many urologists answered that they do not know if the technique is beneficial (12.9-31.43%) or that they are not familiar with the technique (8.6-38.7%). Consequently, we conclude that the knowledge on novel techniques is limited, in particular for OCT and CLE. This is possibly due to the fact that only one pilot study has been published, while for CLE just recently a probe became commercially available.<sup>25,26\_ENREF\_26</sup> Therefore the choice for the most promising technique on which we should focus in future studies is difficult. Yet, PDD and urinary biomarkers are likely to be least beneficial in the diagnostic work-up according to the responders.

NBI and digital RIRS were best known and scored both high as the most promising technique. PDD was considered not to be beneficial in the diagnosis of UTUC.<sup>27</sup> Surprisingly, SPIES scored well among the responders, while no results have been published to date. The endoscopic imaging modalities (NBI, digital RIRS, SPIES and PDD) allow for integration with OCT and CLE. For this reason, CLE or OCT can be studied in combination with a technique that improves tumour detection in a single study protocol, which can be helpful to assess the summed diagnostic accuracy of several diagnostics in a limited study population. A urinary biomarker, which could reliably diagnose UTUC, would make many of the current and optical diagnostics unnecessary. Although various promising predictive and prognostic biomarkers have been identified, no such validated biomarker is yet available.<sup>28</sup> Therefore, most urologists may not see value of them for the use in UTUC. For this reason we conclude that the existent urinary biomarkers are not likely to be beneficial in the diagnosis of UTUC.

### *Limitations and strengths of our study*

The fact that most of our responders are working in a university hospital (71.6%) may be considered a limitation. Our study cannot rule out the bias that diagnostic work-up is usually more extensive in a university hospital compared to non-university hospitals. Statistical analysis showed that the knowledge of new techniques between urologists working in University hospital and urologists working in a non-university hospital did not differ. A second limitation is the scarce number of questions of the survey. The survey design was deliberately chosen, since a concise survey is more likely to be responded. This limitation resulted in one of the strengths of our study; the high response rate of 72.3%.

### **Conclusion**

Most urologists involved in the treatment of upper urinary tract tumours follow the guidelines in their diagnostic work-up of patients suspected for UTUC. Urologists treating UTUC consider current diagnostic techniques insufficient to select suitable patients with upper tract urothelial cancer for endoscopic management. Recently, several new diagnostic techniques for upper urinary tract carcinoma have emerged, from which NBI and digital RIRS are best known among urologists and are considered among urologists to be most likely beneficial in the diagnostic work-up.

Before successful implementation of these new diagnostics in daily routine, more methodologically correct research should be directed to reach reliable diagnostic accuracy and high levels of evidence.

### **Acknowledgements**

The authors would like to thank all the responders of our survey for their time and effort.

## Reference List

1. Yates DR, Catto JW. Distinct patterns and behaviour of urothelial carcinoma with respect to anatomical location: how molecular biomarkers can augment clinico-pathological predictors in upper urinary tract tumours. *World JUrol* 2013; 31(1): 21-9.
2. Bus MT, de Bruin DM, Faber DJ, et al. Optical diagnostics for Upper Urinary Tract Urothelial cancer: technology, thresholds and clinical applications. *JEndourol* 2014.
3. Savarino E, Corbo M, Dulbecco P, et al. Narrow-band imaging with magnifying endoscopy is accurate for detecting gastric intestinal metaplasia. *World JGastroenterol* 2013; 19(17): 2668-75.
4. McGill SK, Evangelou E, Ioannidis JP, Soetikno RM, Kaltenbach T. Narrow band imaging to differentiate neoplastic and non-neoplastic colorectal polyps in real time: a meta-analysis of diagnostic operating characteristics. *Gut* 2013; 62(12): 1704-13.
5. O'Brien T, Ray E, Chatterton K, Khan MS, Chandra A, Thomas K. Prospective randomized trial of hexylaminolevulinate photodynamic-assisted transurethral resection of bladder tumour (TURBT) plus single-shot intravesical mitomycin C vs conventional white-light TURBT plus mitomycin C in newly presenting non-muscle-invasive bladder cancer. *BJUInt* 2013; 112(8): 1096-104.
6. Cauberg EC, Mamoulakis C, de la Rosette JJ, de Reijke TM. Narrow band imaging-assisted transurethral resection for non-muscle invasive bladder cancer significantly reduces residual tumour rate. *World J Urol* 2011; 29(4): 503-9.
7. Cordeiro ER, Anastasiadis A, Bus MT, Alivizatos G, de la Rosette JJ, de Reijke TM. Is photodynamic diagnosis ready for introduction in urological clinical practice? *ExpertRevAnti-cancer Ther* 2013; 13(6): 669-80.
8. Ren H, Waltzer WC, Bhalla R, et al. Diagnosis of bladder cancer with microelectromechanical systems-based cystoscopic optical coherence tomography. *Urology* 2009; 74(6): 1351-7.
9. Ren H, Yuan Z, Waltzer W, Shroyer K, Pan Y. Enhancing detection of bladder carcinoma in situ by 3-dimensional optical coherence tomography. *JUrol* 2010; 184(4): 1499-506.
10. Sonn GA, Jones Sn Fau - Tarin TV, Tarin Tv Fau - Du CB, et al. Optical biopsy of human bladder neoplasia with in vivo confocal laser endomicroscopy. (1527-3792 (Electronic)).
11. Wu K, Liu Jj Fau - Adams W, Adams W Fau - Sonn GA, et al. Dynamic real-time microscopy of the urinary tract using confocal laser endomicroscopy. (1527-9995 (Electronic)).
12. Timmer MR, Brankley SM, Gorospe EC, et al. Prediction of response to endoscopic therapy of Barrett's dysplasia by using genetic biomarkers. *GastrointestEndosc* 2014.
13. Bubendorf L, Grilli B. UroVysion multiprobe FISH in urinary cytology. *Methods MolMed* 2004; 97: 117-31.
14. Mian C, Mazzoleni G, Vikoler S, et al. Fluorescence in situ hybridisation in the diagnosis of upper urinary tract tumours. *EurUrol* 2010; 58(2): 288-92.

15. Cormio L, de la Rosette J. The upper tract-transitional-cell carcinoma global study: a prospective observational study exploring indications, treatment modalities, and outcomes worldwide. *JEndourol* 2014; 28(5): 500-1.
16. Roupret M, Babjuk M, Comperat E, et al. European guidelines on upper tract urothelial carcinomas: 2013 update. *EurUrol* 2013; 63(6): 1059-71.
17. Tavora F, Fajardo DA, Lee TK, et al. Small endoscopic biopsies of the ureter and renal pelvis: pathologic pitfalls. *AmJSurgPathol* 2009; 33(10): 1540-6.
18. Wang JK, Tollefson MK, Krambeck AE, Trost LW, Thompson RH. High rate of pathologic upgrading at nephroureterectomy for upper tract urothelial carcinoma. *Urology* 2012; 79(3): 615-9.
19. Messer J, Shariat SF, Brien JC, et al. Urinary cytology has a poor performance for predicting invasive or high-grade upper-tract urothelial carcinoma. *BJUInt* 2011; 108(5): 701-5.
20. Gogus C, Baltaci S, Sahinli S, Turkolmez K, Beduk Y, Gogus O. Value of selective upper tract cytology for recognition of upper tract tumors after treatment of superficial bladder cancer. *IntJUrol* 2003; 10(5): 243-6.
21. Xu AD, Ng CS, Kamat A, Grossman HB, Dinney C, Sandler CM. Significance of upper urinary tract urothelial thickening and filling defect seen on MDCT urography in patients with a history of urothelial neoplasms. *AJR AmJRoenngenol* 2010; 195(4): 959-65.
22. Cauberg EC, de Bruin DM, Faber DJ, van Leeuwen TG, de la Rosette JJ, de Reijke TM. A new generation of optical diagnostics for bladder cancer: technology, diagnostic accuracy, and future applications. *EurUrol* 2009; 56(2): 287-96.
23. Liu JJ, Droller MJ, Liao JC. New optical imaging technologies for bladder cancer: considerations and perspectives. *JUrol* 2012; 188(2): 361-8.
24. Krabbe LM HR, Margulis V. Urothelial cancer of the urinary bladder: can lessons learned be applied to the upper urinary tract? *Minerva urologica e nefrologica* 2016; 68(4).
25. Bus MT, Muller BG, de Bruin DM, et al. Volumetric in vivo visualization of upper urinary tract tumors using optical coherence tomography: a pilot study. *J Urol* 2013; 190(6): 2236-42.
26. Chen SP, Liao JC. Confocal laser endomicroscopy of bladder and upper tract urothelial carcinoma: a new era of optical diagnosis? *CurrUrolRep* 2014; 15(9): 437.
27. Aboumarzouk Om Fau - Mains E, Mains E Fau - Moseley H, Moseley H Fau - Kata SG, Kata SG. Diagnosis of upper urinary tract tumours: Is photodynamic diagnosis assisted ureterorenoscopy required as an addition to modern imaging and ureterorenoscopy? ; (1873-1597 (Electronic)).
28. Mathieu R VM, Mbeutcha A, Karakiewicz PI, Briganti A, Roupret M, Shariat SF. Urothelial cancer of the upper urinary tract: emerging biomarkers and integrative models for risk stratification. *minerva urologica e nefrologica* 2016; 68(4).





# OPTICAL DIAGNOSTICS FOR UPPER URINARY TRACT UROTHELIAL CANCER: TECHNOLOGY, THRESHOLDS AND CLINICAL APPLICATIONS

MT Bus<sup>1</sup>, DM de Bruin<sup>2</sup>, DJ Faber<sup>2</sup>,  
GM Kamphuis<sup>1</sup>, PJ Zondervan<sup>1</sup>, MP Laguna Pes<sup>1</sup>,  
TM de Reijke<sup>1</sup>, O Traxer<sup>3</sup>, TG van Leeuwen<sup>2</sup>,  
JJ de la Rosette<sup>1</sup>

<sup>1</sup>*Department of Urology*

<sup>2</sup>*Department of Biomedical Engineering & Physics*

*Academic Medical Center*

*Meibergdreef 9*

*1105 AZ, Amsterdam ZO*

*The Netherlands*

<sup>3</sup>*Department of Urology*

*Tenon Hospital Pierre and Marie Curie University*

*Paris, France*

*Journal of Endourology 2015 Feb;29(2):113-23.*

---



## **Abstract**

### **Introduction**

Developments in optical diagnostics have potential for less invasive diagnose of upper urinary tract urothelial carcinoma (UTUC).

This systematic review provides an overview of technology, applications and limitations of recently developed optical diagnostics in the upper urinary tract and outlines their potential for future clinical applications. In addition, current evidence was evaluated.

### **Literature search**

A PubMed literature search was performed and papers on Narrow Band Imaging (NBI), Photodynamic Diagnosis (PDD), Storz Professional Imaging Enhancement System (SPIES), Optical Coherence Tomography (OCT) and Confocal Laser Endomicroscopy (CLE) regarding UTUC were reviewed for data extraction. Study quality was reviewed according to QUADAS and IDEAL standards.

### **Results**

Four articles available for quality assessment, demonstrated high level of evidence but low level of IDEAL stage. NBI and SPIES enhance contrast of mucosal surface and vascular structures, improving tumour detection rate. A first in-vivo study showed promising results. PDD uses fluorescence to improve tumour detection rate. However, due to the acute angle of the ureterorenoscopes there is an increased risk of false-positives. OCT produces cross-sectional high-resolution images, providing information on tumour grade and stage. A pilot study showed promising diagnostic accuracy. CLE allows ultra-high resolution microscopy of tissue resulting in images of the cellular structure. CLE cannot be applied in-vivo in the upper urinary tract yet, due to technical limitations.

### **Conclusions**

NBI, SPIES and PDD aim at improving visualisation of UTUC through contrast enhancement. OCT and CLE aim at providing real-time prediction of histopathological diagnosis. For all techniques, more research has to be conducted before these techniques can be implemented in the routine management of UTUC. All techniques might be of value in specific clinical scenarios and allow for integration, e.g. OCT with NBI, and could therefore improve tumour detection and staging and help selecting the optimal treatment for the individual patient.

## Introduction

Contemporary steps in the diagnosis of Upper Urinary Tract Urothelial Carcinoma (UTUC) are based on imaging, ureterorenoscopy and obtaining histology/cytology. Although these techniques are considered “standard of care”, they have limitations.

Radiological and cytological evidence on small and/or flat lesions are reported with a low accuracy.<sup>(1-3)</sup> Secondly ureterorenoscopy (URS) requires anaesthesia and does not provide real time information on stage and grade of the disease. Pathological diagnosis is often inconclusive due to the small samples that are obtained, mainly because of the limitations of the equipment.<sup>(4)</sup> Furthermore, carcinoma in situ (CIS) lesions are easily missed on URS due to their flat appearance. Consequently, a high rate of tumour upgrading and upstaging is reported following nephroureterectomy.<sup>(5)</sup>

The standard treatment for UTUC has been open or laparoscopic nephroureterectomy. Recently, the EAU guidelines accepted conservative endoscopic treatment using ureterorenoscopy for a select group of UTUC patients with low-volume, low-grade and low-stage disease.<sup>(6)</sup> To select patients eligible for endoscopic treatment, information on tumour stage and grade is essential. With the current diagnostic tools selection of patients for conservative treatment is still suboptimal. Novel optical diagnostic techniques, based on the interaction between light and tissue, have the potential to improve UTUC visualization. These interactions include scattering, absorption and fluorescence, all of which are characteristic for certain tissue types. Some of these techniques aim at improved visualisation of urothelial tumours (NBI, SPIES<sup>1</sup>, PDD), while other techniques aim at providing real time intra-operative information on tumour grade and stage (OCT, CLE). Most research on the application of optical diagnostics on urothelium has been done in the field of bladder cancer.<sup>(7,8)</sup> In case of the upper tract however, the limited space in the ureter and the difficulty to reach the upper urinary tract creates an entire new spectrum of challenges for new optical techniques. In this systematic review the principles of these new optical techniques are described and their applicability in the diagnosis and treatment of UTUC and outline their feasibility and current clinical applications. In addition, we evaluate the relevant literature according to standard classifications.<sup>(9-12)</sup>

---

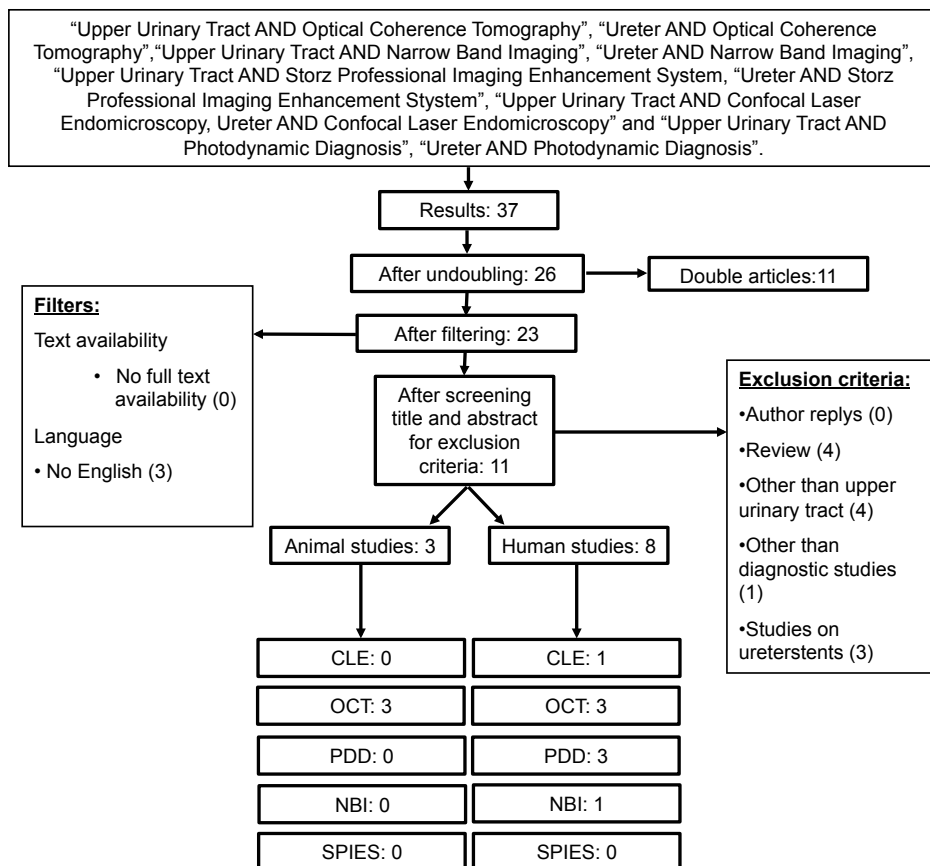
1

Currently known as IMAGE1 S™

## Material and Methods

### Literature search

A literature search was conducted (May 22, 2014) in PubMed and Cochrane library using as search terms: "Upper Urinary Tract OR ureter AND Narrow Band Imaging", "Upper Urinary Tract OR ureter AND Photodynamic Diagnosis", "Upper Urinary Tract OR ureter AND Storz Professional Imaging Enhancement System (SPIES)", "Upper Urinary Tract OR ureter AND Optical Coherence Tomography" and "Upper Urinary Tract OR ureter AND Confocal Laser Endomicroscopy". Original English written articles were selected. Review articles, reply to author and articles describing other than upper urinary tract were excluded (Figure 1).



**Figure 1:** Diagram outlining study selection process.

## Data extraction

Full text articles were reviewed for data extraction by two authors (MTJB and MPLP). Study quality of human, in-vivo diagnostic studies was reviewed according to QUADAS standards.<sup>(11)</sup> IDEAL stage and level of evidence according to the Oxford Center of Medicine for diagnostic tests was subsequently assessed.<sup>(9, 10, 12)</sup> Ex-vivo and animal studies were not included for quality assessment. In case a single research group published multiple articles on a specific optical diagnostic technique, only the most recent publication was taken into account.

## Results

The literature search rendered in total 37 articles. After undoubling, filtering and applying exclusion criteria, 11 articles remained for analyses on study quality and data extraction (Figure 1). Confocal laser endomicroscopy rendered 1 article, Narrow band imaging rendered 1 article, Optical Coherence Tomography rendered 6 articles, Storz Professional Imaging Enhancement System (SPIES) rendered 0 articles and Photodynamic Diagnosis rendered 3 articles. In total 8 articles reported on human studies, the other 3 articles were conducted in animals.

## Quality assessment

Of the 11 articles, 4 articles in human in-vivo setting were suitable for quality assessment (Figure 2). These prospective studies all have a 2B level of evidence. However, all studies have been conducted according to the first steps of the IDEAL standards (1-2a), Evaluating by the QUADAS standards to assess the quality of diagnostic accuracy, showed minimal bias of the four studies available for quality assessment.

## Techniques based on light absorption

### *Narrow Band Imaging*

Narrow Band Imaging (NBI) Olympus® is an optical image enhancement technique for endoscopic applications, with demonstrated value in gastroenterology and urology (bladder).<sup>(13-15)</sup> NBI is based on the principle that the depth of light penetration into the mucosa increases with increasing wavelength and enhances contrast between mucosa and microvascular structures (table 1). By illuminating the tissue with specific wavelengths (blue 415nm and green 540nm), both strongly absorbed by haemoglobin, the vascular structures appear dark brown/green against a pink/white mucosal background. (Figure 3).<sup>(13, 16)</sup> New digital flexible endoscopes with integrated WL and NBI are already commercially available allowing the application also in the upper urinary tract. Until now, only one report is published on NBI in the upper urinary tract that consisted of 27 patients undergoing URS. Of these 27 patients, only 15 had UTUC. NBI improved tumour detection rate by 22.7% compared with white

	1. Representative spectrum?	2. acceptable reference standard?	3. Acceptable delay between tests?	4. Partial verification avoided?	5. Differential verification avoided?	6. Incorporation avoided?	7. Reference standard results blinded?	8. Index test results blinded?	9. Relevant clinical information?	10. Uninterpretable results?	11. Explanation withdrawals?	IDEAL stage	Level of Evidence
Bus et al, OCT, 2013	Yes	Yes	Unclear	Yes	Yes	Yes	No	Yes	Yes	Yes	Yes	1	2B
Traxer et al, NBI, 2011*	Yes	Yes	Yes	Yes	Yes	Yes	No	No	Yes	No	Yes	2A	2B
WU et al, CLE, 2011 **	Yes	Yes	Yes	Yes	Yes	Yes	No	No	Yes	Unclear	Yes	2A	2B
Aboumarzouk et al, PDD, 2013*	Unclear	Yes	Yes	Yes	Yes	Yes	No	No	Yes	Unclear	Yes	2A	2B

**Figure 2:** Quality assessment according to QUADAS and IDEAL standards and Level of Evidence of human in-vivo studies. Only one OCT study was included, since two other studies were conducted ex-vivo. Only one study on PDD was included, since the other two studies were conducted by the same study group and likely to be conducted in the same patient group. \* reference test: white light URS. \*\* This study was conducted in vivo in the bladder and ex vivo in the upper urinary tract. Since we can imagine that the results of the bladder resemble results in the upper urinary tract, we included this study for quality assessment.

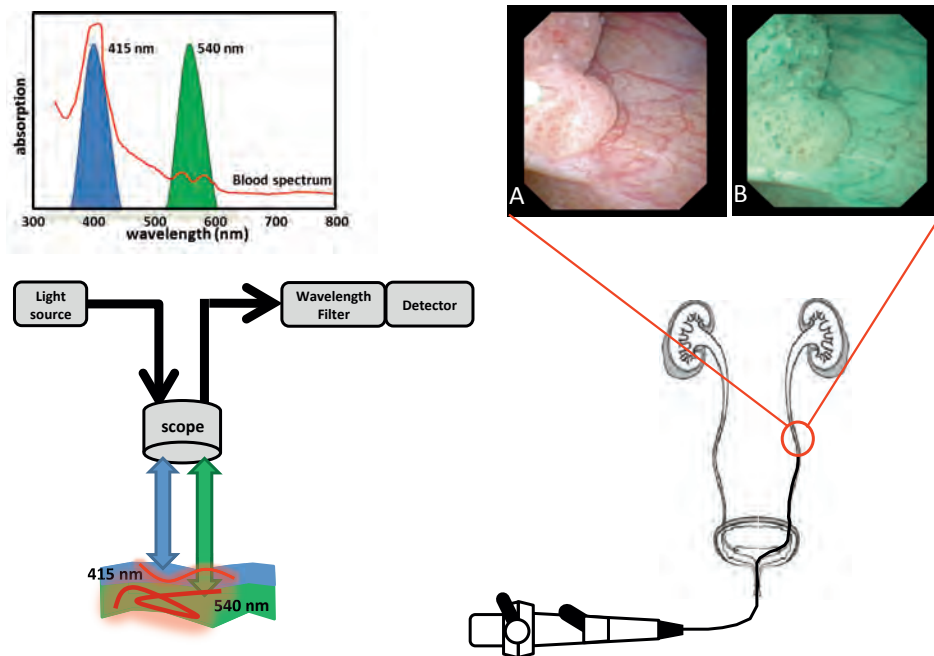
light by diagnosing five additional tumours and identifying border extension in another three tumours.<sup>(17)</sup> Although promising, this study could be subject to observer bias because of its design, in which WL and NBI ureterorenoscopy were performed subsequently by the same urologist.

**Table 1:** Overview of five optical techniques, microscopy and white light ureterorenoscopy.

	<b>optical principle</b>	<b>aim</b>	<b>stage of research</b>	<b>maximal imaging depth</b>	<b>advantage</b>	<b>limitations</b>
OCT	scattering	real time information on pathohistological diagnosis	human ureter in vivo	2-3mm	information on tumour grade and stage, suitable for screening purposus of complete ureter	diminished imaging depth range
NBI	absorption	improved visualisation of tumours	human ureter in vivo	na	improved tumour detection, no need of additional agents	high rate of false positives (on bladder urothelium)
SPIES	absorption	improved visualisation of tumours	human ureter in vivo trial starting	na	improved tumour detection, no need of additional agents	high rate of false positives (on bladder urothelium)
PDD	fluorescence	improved visualisation of tumours	human ureter in vivo	na	improved tumour detection	administration of fluorescence agents needed, high rate of false positives
CLE	absorption/ reflection	real time information on pathohistological diagnosis	human ureter ex vivo	400 µm	in vivo microscopy with high resolution images	sensitivity to tissue movement
Microscopy	absorption/ reflection	pathohistological diagnosis		20 µm	high resolution, gold standard	no real time information
White light URS		visualisation of urothelium		na	visualisation of tumours, treatment and biopsies in same session possible	CIS lesions are easily missed, biopsies are often inconclusive, no real time information on tumour grade and stage

OCT: Optical Coherence Tomography, NBI: Narrow Band Imaging, SPIES: Storz Professional Image Enhancement System, PDD: Photodynamic Diagnosis, CLE: Confocal Laser Endomicroscopy. NBI, SPIES and PDD have previously demonstrated a high rate of false positives on bladder urothelium. Future research should reveal if this high rate of false positives is also found in the upper urinary tract.

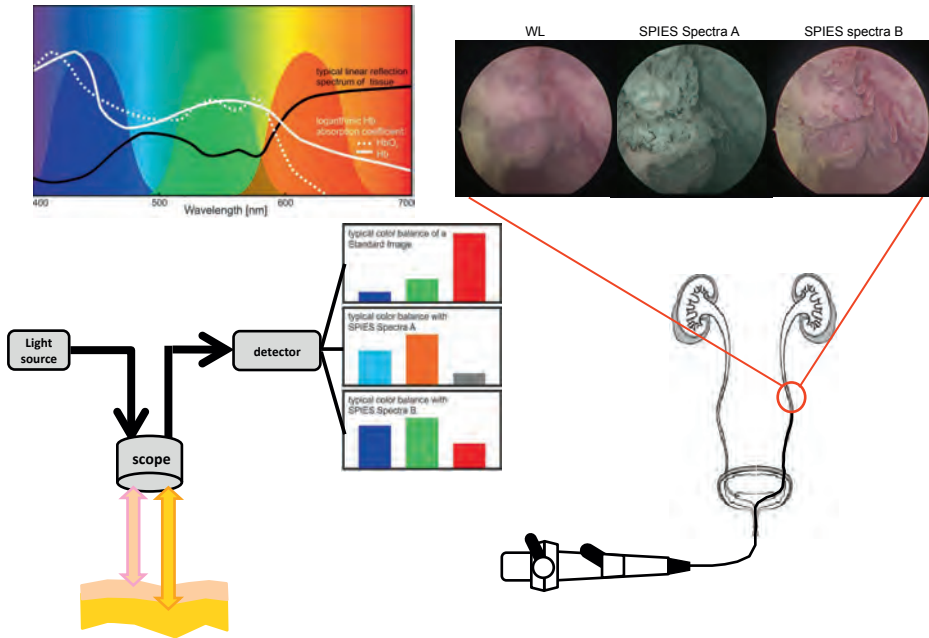




**Figure 3:** Narrow-band imaging is based on the phenomenon that the depth of light penetration increases with wavelength. Tissue is illuminated with light centred on 415 nm (blue) and 540 nm (green), which are both absorbed by haemoglobin more strongly than other tissue. The blue light enhances the superficial capillary network, whereas the green light enhances the visibility of deeper vessels. (WL: white light (A). NBI: narrow band imaging (B))

#### *Storz Professional Image Enhancement System*

A new technology using spectral separation is recently introduced called Storz Professional Image Enhancement System (SPIES®) (Table 1). White light images are acquired with a RGB camera, after which several different digital imaging modes can be used to modify the displayed image (Figure 4). The system comprises of two modes (SPECTRA A/B), which pronounce the imaging spectral separation via different colour renderings, highlighting the contrast between different tissues and structures. A third mode (CLARA) uses a local brightness adaptation to achieve clearer visibility of darker regions within the image and a fourth mode (CHROMA) enhances the structures within the displayed image via an increased colour contrast. The clinical value of SPIES is currently under investigation and no clinical data of the upper urinary tract are yet available.

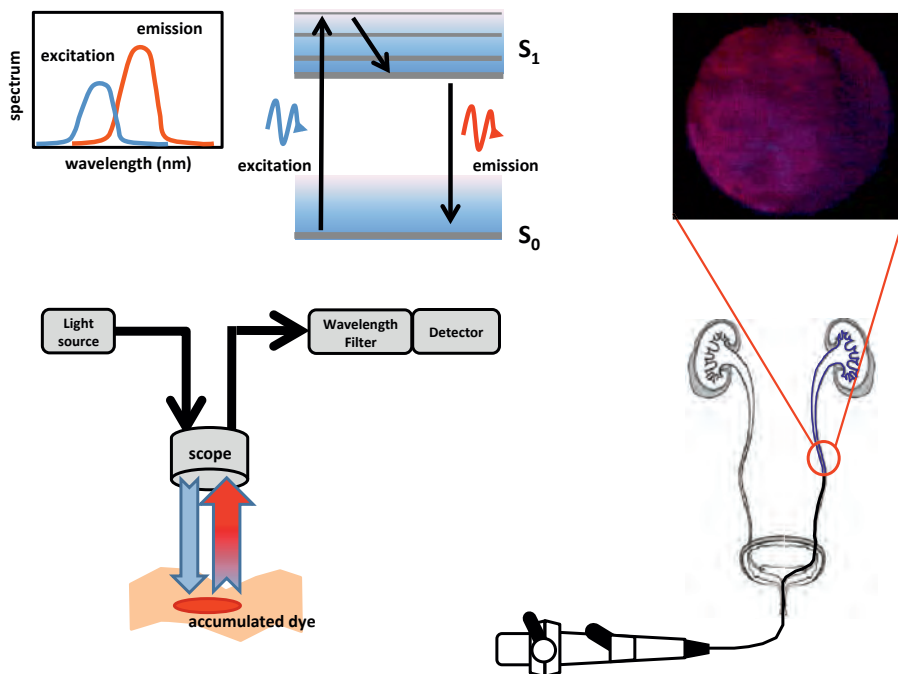


**Figure 4:** Storz Professional Image Enhancement System (SPIES) filters acquired white light images digitally in order to produce enhanced contrast images. Several modes can be used in order to increase viewing comfort for the endoscopist, enhancing sharpness of the displayed images and providing specific colour renderings. Spectral separation within the camera is amplified by adapted colour processing algorithms of the whole spectral light information. Inserts demonstrating upper urinary tumour seen with white light and SPIES Spectra A and Spectra B.

## Techniques based on fluorescence

### *Photodynamic Diagnosis*

Photodynamic diagnosis (PDD) employs fluorescence as a contrast mechanism to localize abnormal tissue (table 1). PDD is based on the selective accumulation of a fluorochrome in malignant tissue. Absorption of high-energy light of the appropriate wavelength (i.e. ~400 nm) excites the electro-vibrational state of the fluorochrome. When the molecule relaxes to the ground state a photon is emitted (i.e. 590-700 nm) to account for the energy difference. The fluorescent photon has less energy than the excitation photon; since the energy of light is inversely proportional to its wavelength, the emitted light has a longer wavelength than the illuminating light. Therefore, discrimination between the two types of light is possible (Figure 5). Several exogenous fluorochrome agents have been investigated to induce exogenous fluorescence. Most research in the upper urinary tract has been conducted using the approved porphyrin-related fluorochrome 5-Aminolaevulinic acid (5-ALA). Endoscopes with special light sources and filters are used to illuminate tissue with blue light (380-470 nm) that corrects for heterogeneous illumination and distance variations. It also



**Figure 5:** Photodynamic Diagnosis is based on fluorescence of externally applied dyes that accumulate in tumours. When a dye absorbs light, it is excited from the ground state ( $S_0$ ) to a higher energy level of the first excited state ( $S_1$ ), before relaxing to the lowest vibrational energy level of  $S_1$ . Subsequently, the dye returns to the ground state while emitting a photon of lower energy (higher wavelength) than used for excitation. Appropriate filtering separates the emitted light from the excitation. Insert shows a PDD image of urothelial carcinoma in the ureter. Since a tangential light beam is almost inevitable in the ureter, result interpretation is hampered and causes more false positives.

largely compensates for varying blood absorption and accumulated 5-ALA in malignant tissue appears pink/red on a blue background.

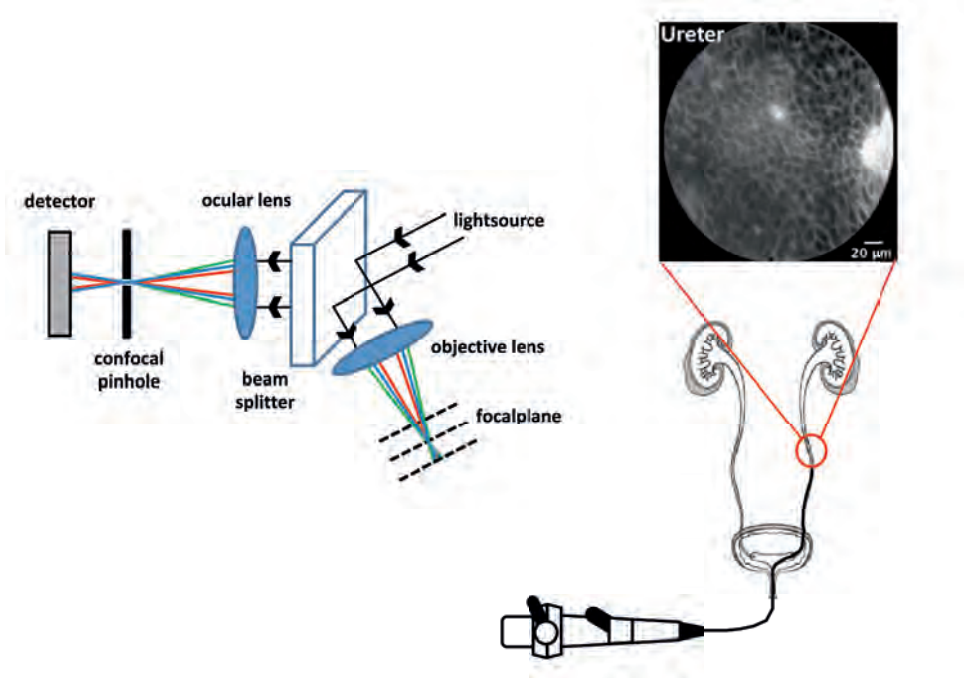
In the upper urinary tract several impediments exist for application of this technique. Concern is optimal delivery of fluorochromes and visualization in the setting of anatomic obstacles. Delivery of fluorochromes seems technically possible by nephrostomy or urinary stent, but equal administration of fluorochromes and optimal duration of urothelial exposure to fluorochromes are more difficult to establish because of the small cavity sizes.<sup>(16, 18)</sup> Furthermore, visualizing fluorescent thin, normal urothelium of the ureter requires a perpendicular viewing angle. The ureteroscope's longitudinal axis creates a tangential viewing angle in which the urothelial layer appears as a thicker layer with a corresponding increase in fluorescence, potentially resulting in false positives.

An alternative for 5-ALA instillation is oral administration of the same fluorophore, which has been described in three studies. The first in-human study demonstrated the feasibility on oral 5-ALA in patients with suspicion on UTUC.<sup>(19)</sup>

In two larger studies, more lesions were found in the upper urinary tract compared to standard white light imaging.<sup>(20, 21)</sup> Although a study on sensitivity and specificity of UUT-PDD revealed an increased sensitivity compared to standard white light endoscopy, this difference was not statistically significant. In summary, PDD enables improved visualization of upper urinary tract tumours. However, major limitations are the administration of 5-ALA and the higher false positive rate due to the tangential viewing angle of the ureteroscopes.

### *Confocal Laser Endomicroscopy*

Confocal Laser Endomicroscopy (CLE) is an ultra-high resolution microscopy technique that allows imaging of tissue up to a depth of 400 $\mu$ m (Table 1). This imaging depth and



**Figure 6:** Confocal endomicroscopy is based on the suppression of out-of-focus light by the insertion of a pin-hole before the detector. This results in the detection of backscattered light that originates from the focal plane only (red and blue in the overview) while light that is backscattered outside the focal plane (green in the overview) is stopped by the pin-hole. Miniaturization of a confocal microscope affects the numerical aperture (NA) of the system, which will directly influence the resolution of the system. Insert shows ex-vivo CLE of normal proximal ureter from a radical nephrectomy specimen. Normal urothelium showing uniform, monomorphic cells consistent with intermediate cells. (Insert image courtesy of Aristeo Lopez and Joseph Liao, Stanford University)

resolution is achieved using lasers and optics, which are combined with a very small hole (pin-hole) that acts as a diaphragm in the microscope objective. This pinhole ensures that only light from the focus in the tissue is collected. The light that is out of focus is rejected by the pin-hole (Figure 6). CLE uses fluorescence from fluorescein to stain tissue micro architecture and small vessels, which rapidly diffuses through the body after intravenous injection. Recent advantages in instrument miniaturization have led to the development of flexible, fiberoptic confocal microscopes that can be used with standard endoscopy to provide real-time information on tumour grade. In an ex-vivo study urothelial cells and lamina propria were clearly recognized.<sup>(22)</sup> Drawback of CLE is sensitivity to tissue movement leading to motion artefacts that could result in blurred images. Although commercially available CLE devices are now available with decreased probe size with a wider field of view and an improved imaging of the microarchitecture of tissue, it also results in a lower cellular resolution, which is needed for grading.<sup>(23)</sup>

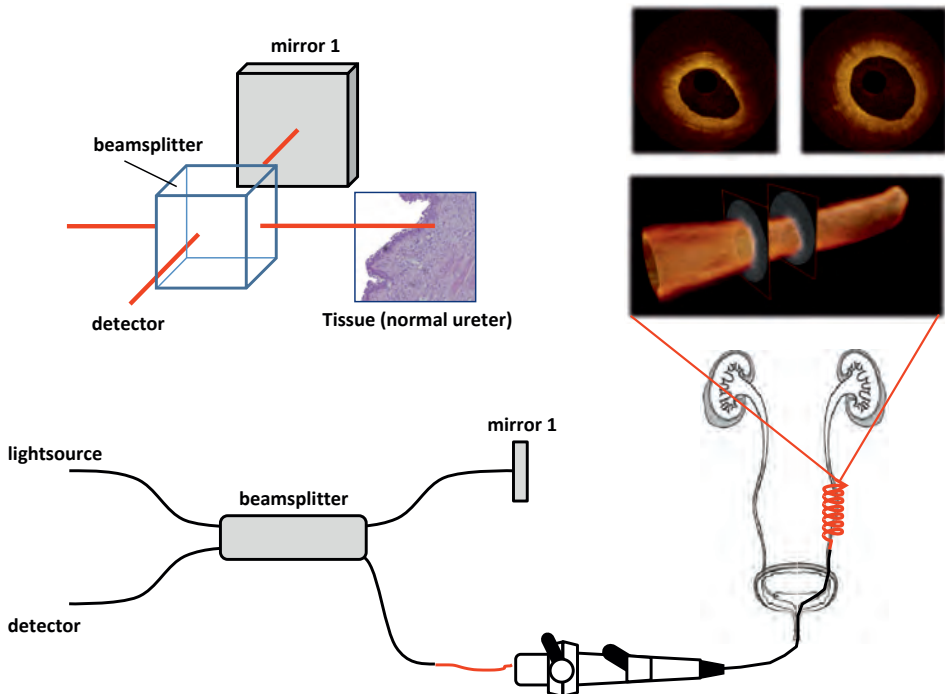
## Techniques based on light scattering

### *Optical Coherence Tomography*

Optical Coherence Tomography (OCT) is analogous to ultrasonography, using back-scattered light instead of back-reflected sound waves to produce micrometre-scale resolution, cross-sectional images (Table 1).<sup>(24)</sup> Recent OCT research investigates this technology in the diagnostic workup of several epithelial cancers.<sup>(25-27)</sup> In OCT, layered tissue anatomy can be distinguished. Interruption or absence of layered tissue under a visible lesion is indicative for tumour stage. However, light scattering causes a decrease of OCT signal magnitude over depth, and limits the imaging range to approximately 2mm depth. The rate of OCT signal decrease with depth is quantified by the attenuation coefficient ( $\mu_{\text{oct}}$ ) that allows in-vivo differentiation between different tissue types (Figure 7).<sup>(26-29)</sup> This distinction results from differences in intra- and extracellular organization of the tissue, which is reflected in the light scattering properties. Measurement of  $\mu_{\text{oct}}$  is therefore sensitive to the differences in organization associated with different grades of the lesion. The combination of real-time, high-resolution images and extraction of the optical attenuation coefficient gives OCT the ability to provide real-time information on tumour stage and grade in the upper urinary tract. The potential of OCT for staging/diagnosis of UTUC has been investigated ex-vivo in the porcine and human ureter where it clearly distinguished the ureteral wall layers, particularly the urothelium and lamina propria.<sup>(30-32)</sup> When compared to endoluminal ultrasonography, OCT can significantly better distinguish the wall layers of ex-vivo porcine ureter.<sup>(33)</sup> An in-vivo human pilot study in the ureter showed that normal appearing urothelium, the layered tissue anatomy including basement membrane, CIS and visible protrusions can be visualized on OCT images. Towards grading, UUT-OCT was able to visually differentiate between

non-invasive and invasive tumours and to differentiate between low- and high-grade lesions by quantifying  $\mu_{\text{oct}}$ <sup>(34)</sup>

Current commercial available OCT systems are limited to image lumina with a maximal diameter of 10 mm, compromising visualization of the pyelum as a whole. Furthermore, if tumour thickness transcends scattering-limited imaging depth in tissue (~2mm), invasiveness cannot be assessed.



**Figure 7:** Optical Coherence Tomography, the optical equivalent of ultrasound imaging, measures light reflectivity vs. depth. It is based on white-light (large wavelength bandwidth) interferometry, where interference signals are only detected if the light in the sample and reference arm has travelled equal distances. Thus, by varying the length of the reference arm, the imaging location in the tissue can be controlled. Modern embodiments of OCT do not use moving reference mirrors; instead technical complexity is shifted toward either the light source (that sequentially provides each wavelength within the source bandwidth at high speed) or the detector (which detects each wavelength within the source bandwidth in parallel).

## Discussion

We performed a systematic review of the current literature on optical diagnostics in the upper urinary tract. Only 11 articles were available, most of them were conducted ex-vivo in human or animal. Four articles were available for quality assessment, demonstrating the lack of evidence. All studies are in an initial phase of human research according to IDEAL stages for surgical innovations. All in vivo human studies showed high quality of diagnostic tests and low bias risk.

From a clinical point of view, the ideal adjunct modality for endoscopic procedures in the upper urinary tract should 1) detect malignant and premalignant lesions with a high sensitivity and specificity, 2) provide real-time reliable information on grade and stage, 3) reliably identify the extension and deep margins in order to achieve complete resection and consequently identifies residual tumour within resection margins, 4) be physician friendly; easy to apply with a short learning curve for image interpretation, 5) avoid the use of exogenic contrast agents, 6) preferably be low in costs.<sup>(8, 23)</sup> URS with conventional biopsy does not meet all of these conditions. Tumour detection and knowledge about grading and staging should be the ultimate diagnostic objective. Therefore, the potential combination of endoscopy with optical diagnostic techniques could increase diagnostic accuracy and improve treatment selection and may reduce costs.

NBI, SPIES and PDD aim at improving visualisation of upper urinary tract tumours during ureterorenoscopy. OCT and CLE aim at providing minimal invasive, real-time, objective prediction of histopathological diagnosis.

However, endoscopy in the upper urinary tract is challenging due to its small diameter and vulnerability of tissues. This environment creates many limitations that have to be overcome before optical diagnostics can be reliably applied in the upper urinary tract. In our opinion, the most optimal optical device should be able to detect urothelial tumours, to provide depth resolved tissue information which allows staging and specific information on biochemical or intracellular changes in tissue which allows grading, all in real-time. A combination of NBI, SPIES or PDD with OCT or CLE could be such a real-time optical adjunct modality.

Further research needs to be conducted in order to evaluate the true value, before they can be implemented in the management of UTUC. Current available data are too preliminary to evaluate these new technologies and implement them into the diagnostic work-up of patients with UTUC. Therefore, we would plea for more and better conducted studies for the evaluation of diagnostic technologies in the upper urinary tract. Studies on optical technologies in the upper urinary tract involve translation from a biomedical engineering technology, sometimes already applied in routine care for other specialties e.g. gastroenterology,

cardiology and ophthalmology. As it involves the use of a medical device instead of a pharmacological product, the optimal way to proceed is following the IDEAL evaluation criteria, described by the Balliol collaboration.<sup>(9, 10)</sup> This evaluation equals surgical innovation to the different phases of the pharmacological research. CLE has been described for the IDEAL stage 1 (Innovation phase). PDD, OCT and NBI are framed as IDEAL stage 2A or developmental phase. To develop these technologies into a diagnostic test, results should be compared with the standard test at use. In the case of PDD and NBI, the standard test is WL-URS (including biopsies), where OCT uses histology as gold standard. It is recommended to combine the IDEAL methodology with the QUADAS for assessing accuracy of a diagnostic test. These clinical studies should provide a full diagnostic accuracy analysis according to the QUADAS recommendations, including sensitivity, specificity, positive predictive value and negative predictive value. However, upper urinary tract tumours are rare, resulting in a limited study population and therefore require a multicentre approach when entering IDEAL phase 2b (exploration phase) or 3 (assessment phase). So far, only two studies on optical diagnostics in the upper urinary tract are registered at clinicaltrials.gov, using similar search terms as described in the method section. Both studies comprise optical coherence tomography and only one study is recruiting patients at this moment.

## Conclusions

NBI, SPIES and PDD aim at improved detection of upper urinary tract tumours. OCT and CLE aim at providing real-time, minimally invasive and objective prediction of histopathological diagnosis. Optical diagnostics might overcome the limitations of the current diagnostic standard of upper urinary tract tumours to determine which tumours can be treated endoscopically. Although these optical techniques show promising results, more, better conducted prospective studies should be done before they can be implemented in the diagnostic work up of upper urinary tract tumours.

## Acknowledgements

The authors like to thank Aristeo Lopez and Joseph Liao, Stanford University for generously providing the CLE figure used in this paper.



## Reference list

1. Sudakoff GS, Dunn DP, Guralnick ML, Hellman RS, Eastwood D, See WA. Multidetector computerized tomography urography as the primary imaging modality for detecting urinary tract neoplasms in patients with asymptomatic hematuria. *JUrol.* 2008;179(3):862-7.
2. Messer J, Shariat SF, Brien JC, Herman MP, Ng CK, Scherr DS, et al. Urinary cytology has a poor performance for predicting invasive or high-grade upper-tract urothelial carcinoma. *BJUInt.* 2011;108(5):701-5.
3. Xu AD, Ng CS, Kamat A, Grossman HB, Dinney C, Sandler CM. Significance of upper urinary tract urothelial thickening and filling defect seen on MDCT urography in patients with a history of urothelial neoplasms. *AJR AmJRoentgenol.* 2010;195(4):959-65.
4. Tavora F, Fajardo DA, Lee TK, Lotan T, Miller JS, Miyamoto H, et al. Small endoscopic biopsies of the ureter and renal pelvis: pathologic pitfalls. *AmJSurgPathol.* 2009;33(10):1540-6.
5. Wang JK, Tollefson MK, Krambeck AE, Trost LW, Thompson RH. High rate of pathologic upgrading at nephroureterectomy for upper tract urothelial carcinoma. *Urology.* 2012;79(3):615-9.
6. Roupert M, Babjuk M Fau - Comperat E, Comperat E Fau - Zigeuner R, Zigeuner R Fau - Sylvester R, Sylvester R Fau - Burger M, Burger M Fau - Cowan N, et al. European guidelines on upper tract urothelial carcinomas: 2013 update. (1873-7560 (Electronic)).
7. Cauberg EC, de Bruin DM, Faber DJ, van Leeuwen TG, de la Rosette JJ, de Reijke TM. A new generation of optical diagnostics for bladder cancer: technology, diagnostic accuracy, and future applications. *EurUrol.* 2009;56(2):287-96.
8. Liu JJ, Droller MJ, Liao JC. New optical imaging technologies for bladder cancer: considerations and perspectives. *JUrol.* 2012;188(2):361-8.
9. McCulloch P, Altman DG, Campbell WB, Flum DR, Glasziou P, Marshall JC, et al. No surgical innovation without evaluation: the IDEAL recommendations. *Lancet.* 2009;374(9695):1105-12.
10. McCulloch P. The IDEAL recommendations and urological innovation. *World J Urol.* 2011;29(3):331-6.
11. Whiting PF, Weswood ME, Rutjes AW, Reitsma JB, Bossuyt PN, Kleijnen J. Evaluation of QUADAS, a tool for the quality assessment of diagnostic accuracy studies. *BMC Med Res Methodol.* 2006;6:9.
12. Howick J, Chalmers I, Glasziou, Greenhalgh T, Heneghan C, Liberati A, et al. Explanation of the 2011 Oxford Centre for Evidence-Based Medicine (OCEBM) Levels of Evidence (Background Document) 2014 [updated 2014. Available from: <http://www.cebm.net/index.aspx?o=5653>.
13. Cauberg EC, Mamoulakis C, de la Rosette JJ, de Reijke TM. Narrow band imaging-assisted transurethral resection for non-muscle invasive bladder cancer significantly reduces residual tumour rate. *World J Urol.* 2011;29(4):503-9.

14. Inoue T, Murano M, Murano N, Kuramoto T, Kawakami K, Abe Y, et al. Comparative study of conventional colonoscopy and pan-colonic narrow-band imaging system in the detection of neoplastic colonic polyps: a randomized, controlled trial. *J Gastroenterol.* 2008;43(1):45-50.
15. Sharma P, Bansal A, Mathur S, Wani S, Cherian R, McGregor D, et al. The utility of a novel narrow band imaging endoscopy system in patients with Barrett's esophagus. *Gastrointest Endosc.* 2006;64(2):167-75.
16. Audenet F, Traxer O, Yates DR, Cussenot O, Roupret M. Potential role of photodynamic techniques combined with new generation flexible ureterorenoscopes and molecular markers for the management of urothelial carcinoma of the upper urinary tract. *BJU Int.* 2012;109(4):608-13.
17. Traxer O, Geavlete B, de Medina SG, Sibony M, Al-Qahtani SM. Narrow-band imaging digital flexible ureteroscopy in detection of upper urinary tract transitional-cell carcinoma: initial experience. *J Endourol.* 2011;25(1):19-23.
18. Irie A, Iwamura M, Kadowaki K, Ohkawa A, Uchida T, Baba S. Intravesical instillation of bacille Calmette-Guerin for carcinoma in situ of the urothelium involving the upper urinary tract using vesicoureteral reflux created by a double-pigtail catheter. *Urology.* 2002;59(1):53-7.
19. Somani BK, Moseley H, Eljamel MS, Nabi G, Kata SG. Photodynamic diagnosis (PDD) for upper urinary tract transitional cell carcinoma (UT-TCC): evolution of a new technique. *Photodiagnosis Photodyn Ther.* 2010;7(1):39-43.
20. Ahmad S, Aboumarzouk O, Somani B, Nabi G, Kata SG. Oral 5-aminolevulinic acid in simultaneous photodynamic diagnosis of upper and lower urinary tract transitional cell carcinoma - a prospective audit. *BJU Int.* 2012;110(11 Pt B):E596-600.
21. Aboumarzouk Om Fau - Mains E, Mains E Fau - Moseley H, Moseley H Fau - Kata SG, Kata SG. Diagnosis of upper urinary tract tumours: Is photodynamic diagnosis assisted ureterorenoscopy required as an addition to modern imaging and ureterorenoscopy? (1873-1597 (Electronic)).
22. Wu K, Liu JJ, Adams W, Sonn GA, Mach KE, Pan Y, et al. Dynamic real-time microscopy of the urinary tract using confocal laser endomicroscopy. *Urology.* 2011;78(1):225-31.
23. Adams W, Wu K, Liu JJ, Hsiao ST, Jensen KC, Liao JC. Comparison of 2.6- and 1.4-mm imaging probes for confocal laser endomicroscopy of the urinary tract. *J Endourol.* 2011;25(6):917-21.
24. Huang D, Swanson EA, Lin CP, Schuman JS, Stinson WG, Chang W, et al. Optical coherence tomography. *Science.* 1991;254(5035):1178-81.
25. Vakoc BJ, Lanning RM, Tyrrell JA, Padera TP, Bartlett LA, Stylianopoulos T, et al. Three-dimensional microscopy of the tumor microenvironment in vivo using optical frequency domain imaging. *NatMed.* 2009;15(10):1219-23.

26. Wessels R, de Bruin DM, Faber DJ, van Boven HH, Vincent AD, van Leeuwen TG, et al. Optical coherence tomography in vulvar intraepithelial neoplasia. *JBiomedOpt.* 2012;17(11):116022.
27. Barwari K, de Bruin DM, Faber DJ, van Leeuwen TG, de la Rosette JJ, Laguna MP. Differentiation between normal renal tissue and renal tumours using functional optical coherence tomography: a phase I in vivo human study. *BJUInt.* 2012;110(8 Pt B):E415-E20.
28. Barwari K, de Bruin DM, Cauberg EC, Faber DJ, van Leeuwen TG, Wijkstra H, et al. Advanced diagnostics in renal mass using optical coherence tomography: a preliminary report. *JEndourol.* 2011;25(2):311-5.
29. McLaughlin RA, Scolaro L, Robbins P, Saunders C, Jacques SL, Sampson DD. Mapping tissue optical attenuation to identify cancer using optical coherence tomography. *MedImage ComputComputAssistInterv.* 2009;12(Pt 2):657-64.
30. Mueller-Lisse UL, Meissner OA, Babaryka G, Bauer M, Eibel R, Stief CG, et al. Catheter-based intraluminal optical coherence tomography (OCT) of the ureter: ex-vivo correlation with histology in porcine specimens. *EurRadiol.* 2006;16(10):2259-64.
31. Wang H, Kang W, Zhu H, MacLennan G, Rollins AM. Three-dimensional imaging of ureter with endoscopic optical coherence tomography. *Urology.* 2011;77(5):1254-8.
32. Ikeda M, Matsumoto K, Choi D, Nishi M, Fujita T, Ohbayashi K, et al. The impact of real-time 3d imaging by ultra-high speed optical coherence tomography in urothelial carcinoma. *BMCUrol.* 2013;13:65.
33. Mueller-Lisse UL, Meissner OA, Bauer M, Weber C, Babaryka G, Stief CG, et al. Catheter-based intraluminal optical coherence tomography versus endoluminal ultrasonography of porcine ureter ex vivo. *Urology.* 2009;73(6):1388-91.
34. Bus MT, Muller BG, de Bruin DM, Faber DJ, Kamphuis GM, van Leeuwen TG, et al. Volumetric in vivo visualization of upper urinary tract tumors using optical coherence tomography: a pilot study. *J Urol.* 2013;190(6):2236-42.





# VOLUMETRIC IN-VIVO VISUALIZATION OF UPPER URINARY TRACT TUMORS USING OPTICAL COHERENCE TOMOGRAPHY: A PILOT STUDY

MT Bus<sup>1</sup>, BG Muller<sup>1</sup>, DM de Bruin<sup>1,2</sup>, DF Faber<sup>2</sup>,  
GM Kamphuis<sup>1</sup>, TG van Leeuwen<sup>2</sup>, TM de Reijke<sup>1</sup>,  
JJ de la Rosette<sup>1</sup>

<sup>1</sup>*Department of Urology*

<sup>2</sup>*Department of Biomedical Engineering & Physics*

*Journal of Urology 2013 Dec;190(6):2236-42*

---



## Abstract

### Introduction

Knowledge on tumor stage and grade is paramount for treatment decision in Upper Urinary Tract Urothelial Carcinoma (UTUC), but cannot be accurately assessed by current techniques. Optical Coherence Tomography (OCT) is a technique, which can hypothetically provide the urologist with real-time intra-operative information on tumor grade and stage. In this pilot study the first results of OCT in grading and staging of UTUC are presented.

### Material & Methods

Eight consecutive patients underwent URS for UTUC suspicion or follow-up. OCT datasets were intra-operatively obtained from the ureter and pyelum. All patients eventually underwent nephroureterectomy. OCT staging was performed by visual inspection of lesions found on OCT images and OCT grading by quantification of the OCT signal attenuation ( $\mu_{\text{oct}}$  [ $\text{mm}^{-1}$ ]) on lesions and compared with histopathological diagnosis. A Wilcoxon rank sum test was used for statistical analysis.

### Results

Seven in-vivo OCT diagnoses on staging were in accordance with histology. In the eighth patient tumor thickness transcended OCT imaging depth range and was therefore inconclusive on invasiveness. For grading, median (interquartile range)  $\mu_{\text{oct}}$  for grade 2 lesions was  $1.97 \text{ mm}^{-1}$  (1.57-2.30) and  $3.53 \text{ mm}^{-1}$  (2.74-3.94) for grade 3 (p-value <0.001). Healthy urothelium was too thin to reliably determine  $\mu_{\text{oct}}$ .

### Conclusions

OCT is a promising minimally invasive tool for real time intra-operative optical diagnostics for tumors in the upper urinary tract. Our study results warrant future research to determine in a larger sample size grading and staging accuracy of OCT and the possible implementation of OCT in the diagnostic algorithm of UTUC.

## Introduction

Optical Coherence Tomography (OCT) is a high resolution imaging technology originally applied in ophthalmology.<sup>(1)</sup> OCT is analogous to ultrasonography, using back-scattered light instead of back-reflected sound waves to produce micrometer-scale resolution, cross-sectional images in which layered tissue anatomy can be distinguished, e.g. the basement membrane, which status is indicative of stage in case of visible lesion.<sup>(2)</sup> Light scattering decreases the OCT signal magnitude with depth, and limits the imaging range to approximately 2mm. This signal decrease is quantified by the attenuation coefficient  $\mu_{\text{oct}}$  that allows in-vivo differentiation between different tissue types.<sup>(3, 4)</sup> During carcinogenesis, changes occur in cellular architecture resulting in an increased nuclear-cytoplasm ratio and increased amount of mitochondria. Physically, this sub-cellular organization of tissue determines light scattering properties.<sup>(5)</sup> Therefore, we hypothesized that lesion stage is obtained from image-based assessment of presence of a visible basement membrane; and that lesion grade correlates with  $\mu_{\text{oct}}$ .

Most research of OCT on urothelium is in the field of bladder cancer. After initial animal studies, several authors demonstrated the feasibility of OCT imaging in humans: Tearney *et al* first described the ability of OCT to distinguish anatomical layers (urothelium, lamina propria and muscularis propria) of non-diseased bladder wall tissue in an ex-vivo setting.<sup>(6)</sup> The potential of OCT for staging-diagnosis of UTUC has not yet been investigated in-vivo, although ex-vivo studies of the porcine ureter demonstrated that OCT could clearly distinguish the ureteral wall layers, particularly the urothelium and lamina propria.<sup>(7, 8)</sup> Compared to endoluminal ultrasonography, OCT distinguishes significantly better the wall layers of ex-vivo porcine ureter.<sup>(9)</sup>

An animal study by Xie *et al* showed differences in scattering properties between normal and cancerous urothelium.<sup>(5)</sup> Similar studies on lesions in the kidney, vulva, oral tissue and lymph node metastasis confirmed ability of OCT to distinguish tissue types based on  $\mu_{\text{oct}}$ .<sup>(3, 4, 10-12)</sup> However, our initial study on ex-vivo human bladder urothelial biopsies showed that factors typical for ex-vivo settings (e.g. cauterization of bladder tissue specimens) on  $\mu_{\text{oct}}$ -based grading of human bladder cancer were inconclusive but indicative of the need for in-vivo evaluation.<sup>(13)</sup>

Radical nephroureterectomy is the standard of care for UTUC.<sup>(14)</sup> Conservative treatment preserves the renal unit, and is preferred because of the increased chance of recurrence in the contralateral renal unit, and is clearly advantageous in imperative situations. However, conservative treatment is only offered to a select group of UTUC patients with low-grade and low-stage disease.

Nowadays, diagnosis of UTUC is based on imaging, ureterorenoscopy (URS) and cytology/histology. Although considered to be the reference standards, these techniques have limitations: 1) No real-time intra-operative histological information is obtained on stage and grade



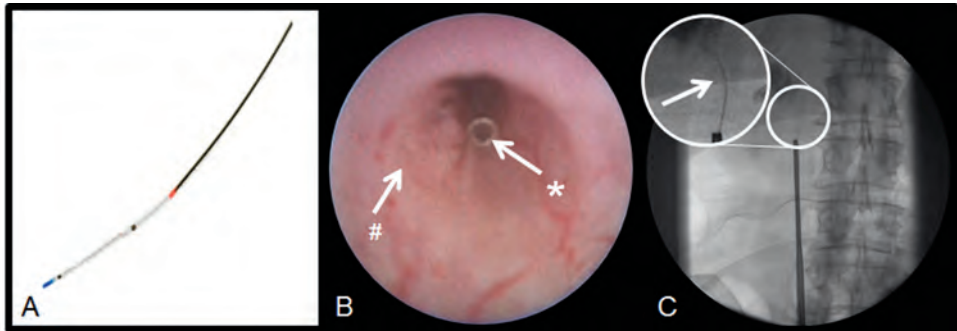
during diagnostic URS. 2) Carcinoma in situ (CIS) is easily missed on URS. 3) Histopathological diagnosis is often inconclusive due to small sampling.<sup>(15)</sup> Ultimately, these limitations lead to a high rate of tumor upgrading/upstaging after nephroureterectomy.<sup>(16)</sup> If knowledge about tumor grade and stage is obtained during URS, a better selection of patients eligible for endoscopic treatment is possible. Additionally, intra-operative tumor grading and staging reduces the amount of procedures and costs. OCT has the potential to provide real time information on grade and stage.

We evaluated OCT in the Upper Urinary Tract in the context of the first 2 stages (stage 1 and 2a) of the IDEAL model designed for evaluating new surgical innovations (1 Innovation/Idea, 2a Development, 2b Exploration, 3 Assessment, 4 Long-term follow-up).<sup>(17, 18)</sup> Furthermore, we highlight three cases, representing three types of UTUC and compare OCT staging and grading to histopathological diagnosis.

## Methods

From December 2011 until October 2012, we performed a prospective study in patients with clinical suspicion or follow-up of UTUC. Eight consecutive patients candidate for diagnostic URS underwent URS and OCT imaging at the operating room of our institute. The institutional Medical Ethical Committee approved this study. Informed consent was obtained from all patients.

We used a commercially available C7-XR<sup>tm</sup> Intravascular Imaging System interfaced to a single-use C7 Dragonfly<sup>tm</sup> 2.7Fr (0.9 mm) Intravascular Imaging Probe (St. Jude Medical, St. Paul, Minnesota, USA) (Figure 1A). The automatic pullback system scans a longitudinal trajectory of 52 mm in approximately 5.2 seconds, producing a 520-frame dataset at 15 $\mu$ m axial resolution. Amira (Visage Imaging GmbH, Berlin, Germany) was used for visualization. The identified ureteral lesion was manually segmented and separately rendered while given a green hue.



**Figure 1:** A) A C7 Dragonflytm Intravascular Imaging Probe 2.7 Fr (St. Jude Medical, St. Paul, Minnesota, USA). B) OCT Probe position during URS (left). # is papillary lesion, \* is OCT probe. C) X-ray taken during OCT probe positioning. Inset shows a thin dark line, indicated by the arrow, to show the OCT probe.

The OCT probe was introduced through the working channel of an ureterorenoscope (Karl Storz semi-rigid 9.5Fr, Karl Storz Flex XC, Olympus URF-V), resulting in simultaneous co-registered URS and OCT. Probe position was ensured by X-ray images. OCT imaging was performed at locations with macroscopic presence of tumor growth or suspected lesions during URS (Figures 1B, 1C).

Standard pathological report of nephroureterectomy specimen was considered reference standard for comparison with OCT grading and OCT staging. Nephroureterectomy specimens were dissected and examined at the pathology department according to standard protocol. The OCT investigator was blinded for pathology results and pre-operative imaging. OCT datasets were subjected to in-house developed staging and grading protocols and compared with histological diagnosis.

For staging, each OCT measurement was visually inspected and classified as normal (without visible lesion) or abnormal (with visible lesion). Visible lesions were divided in invasive and non-invasive by identifying the basement membrane that appears as a dark line between the urothelium and lamina propria. Interruption of this dark line was considered invasive.

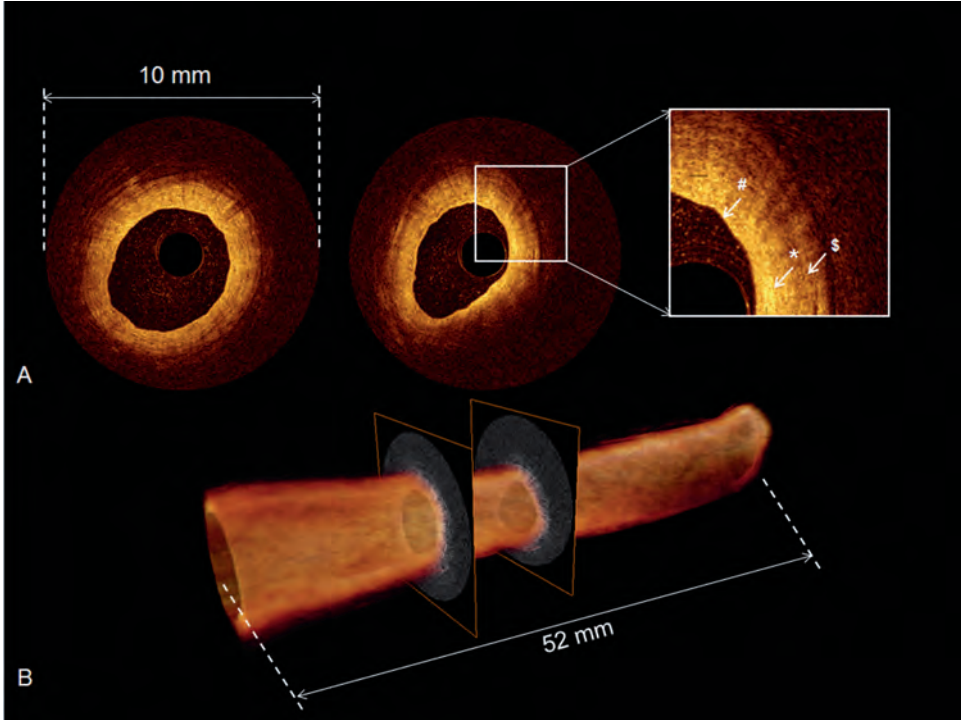
For grading,  $\mu_{\text{oct}}$  was determined in suspected lesions as described before.<sup>(3, 5, 19)</sup> The decrease of light intensity [ $\text{mm}^{-1}$ ] is quantified by fitting OCT data in a manually selected region of interest within a urothelial lesion to a single exponential decay model, after imperatively accounting for system specific calibrations.<sup>(20, 21)</sup> All suspected lesions were clearly identified through structural differences from normal appearing OCT images.

Statistical analysis was performed using SPSS version 19.0 for Windows (Chicago, IL, USA). Because of unequal sample size, the Wilcoxon rank sum test was used to describe differences in  $\mu_{\text{oct}}$  between grade 2 and grade 3 lesions.

No reporting standards for IDEAL 1 and 2a studies are yet described. We therefore followed standard scientific reporting.

## Results

Figure 2 shows OCT images of a healthy ureter obtained during URS of a normal looking ureter. Urothelium, basement membrane, lamina propria and muscularis are clearly visible.



**Figure 2:** OCT scan of a healthy ureter, measured during URS of patient number 2 in the contra lateral ureter. A) Individual OCT scans extracted from the volumetric OCT dataset as shown in B. Inset shows a magnification indicating the three different layers, urothelium (#), lamina propria (\*) and muscularis (\$) of a normal ureter. B) The automatic pullback system scans across a trajectory of 52 mm along the probe in approximately 5.2 seconds, producing a 520-frame dataset. This results in a total scanned cylindrical volume of 52 (length) by 10 mm (diameter). Reconstruction software from Amira (Visage Imaging GmbH, Berlin, Germany) was used to visualize a complete dataset of the ureter.

Eight consecutive patients (Table 1) underwent ureterorenoscopy (URS) plus biopsies for UTUC combined with OCT, followed by nephroureterectomy.

**Table 1:** Patient characteristics.

N	Gender	Age (Yr)	Location	Treatment
1	M	56	renal pelvis	nephroureterectomy
2*	M	63	proximal, mid, and distal ureter	nephroureterectomy
3	M	53	renal pelvis	nephroureterectomy
4*	M	60	renal pelvis, proximal, mid, and distal ureter	nephroureterectomy
5	M	67	proximal ureter	nephroureterectomy
6*	F	76	renal pelvis and proximal ureter	nephroureterectomy
7	F	48	distal ureter	nephroureterectomy
8	F	78	renal pelvis	nephroureterectomy

In-vivo measurements were performed during URS. \*Cases are highlighted in the text.

Seven of eight patients had visible papillary tumors on URS, in the eight patient random biopsies confirmed CIS. For seven of eight patients OCT staging of the visible tumors was in accordance with histology. In the eighth patient, assessment of tumor invasiveness was hampered by thickness of exophytic tumor bulk exceeding OCT imaging depth (Table 2).

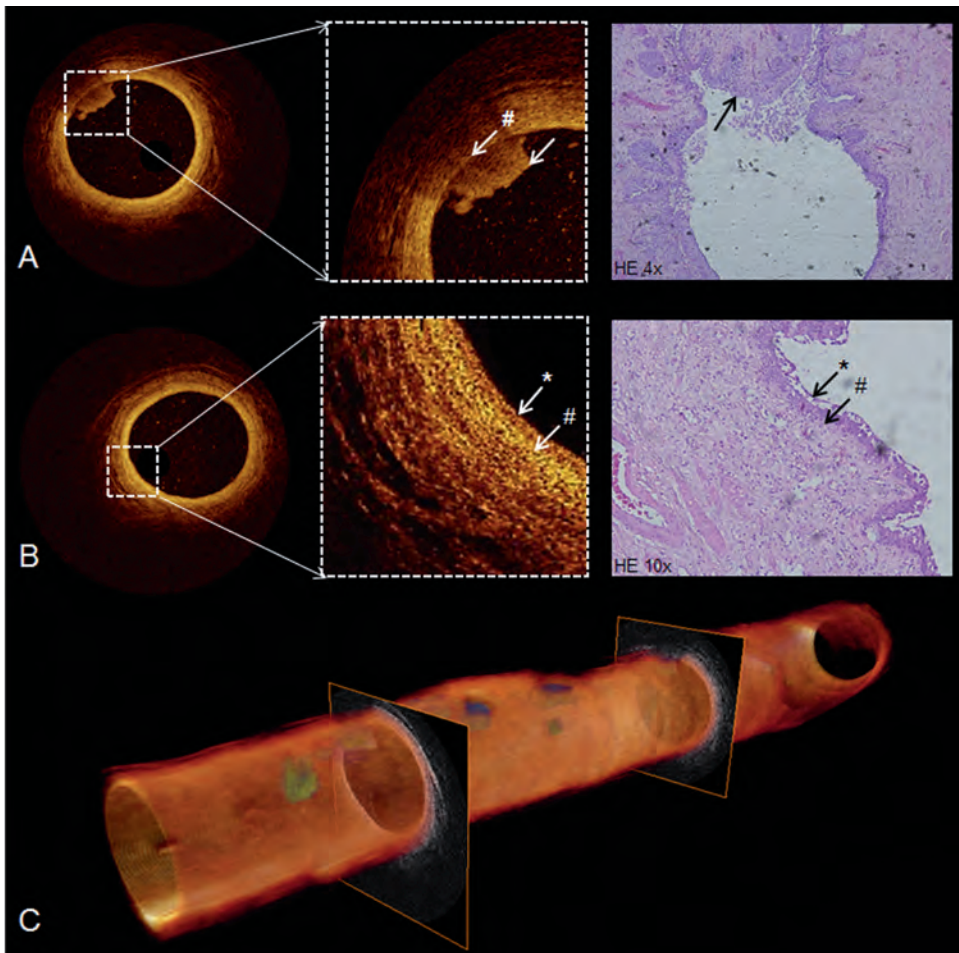
**Table 2:** Histopathological tumor characteristics (stage and grade), corresponding OCT staging, and OCT attenuation coefficients.

N	Tumor stage	OCT stage	Tumor Grade	$\mu_{\text{oct}}$
1	pT3	invasive	3	$2.9 \pm 0.4 \text{ mm}^{-1}$
2*	pTa	non invasive	2	$2.3 \pm 0.3 \text{ mm}^{-1}$
3	pTa	non invasive	2	$1.9 \pm 0.3 \text{ mm}^{-1}$
4*	pTIS	non invasive	3	NA
5	pT3	invasive	3	$3.7 \pm 0.3 \text{ mm}^{-1}$
6*	pT3	invasive	3	$3.8 \pm 0.8 \text{ mm}^{-1}$
7	pT1	invasive	2	$2.4 \pm 0.6 \text{ mm}^{-1}$
8	pTa	inconclusive	2	$2.3 \pm 0.5 \text{ mm}^{-1}$

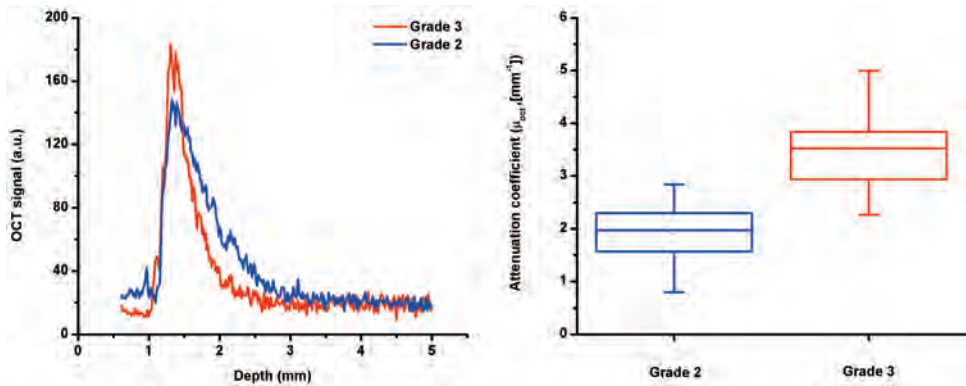
pT1 is considered invasive. \*Cases are highlighted in the text.

In patients with invasive tumors, clear interruption of the basement membrane was seen. In the two patients with non-invasive tumors, the basement membrane was seen as a thin dark line below the tumor growth. In one patient, a flat broadened urothelial layer with low reflectivity was seen without interruption of the basement membrane; histology showed multifocal CIS.

Figure 3 demonstrates exemplary individual depth profiles of grade 2 (blue) and grade 3 (red) lesions. For all individual OCT measurements, the median (interquartile range)  $\mu_{\text{oct}}$  was  $1.97 \text{ mm}^{-1}$  (1.57-2.30) in grade 2 lesions and  $3.53 \text{ mm}^{-1}$  (2.74-3.94) ( $p$ -value <0.001) in grade 3 lesions.



**Figure 4:** A) Intra-operative in-vivo cross-sectional OCT images of the ureter with a protrusion into the lumen (left, #arrow). Individual tissue layers can be identified with protrusion (arrow). The basal membrane is visible as a thin dark line under the protrusion (#), suggesting a non-invasive tumor. Corresponding histology (right) showed a TaG1-2 urothelial cancer. B) In normal ureter wall (left), individual tissue layers can be identified as urothelial layer (\*) and basement membrane (#). Corresponding histology is shown right. C) 3D pullback of the OCT, built from 520 individual cross-sectional images over a length of 5.2 cm. Suspected tumor regions are segmented given a green hue.



**Figure 3:** Attenuation data of grade 2 & 3 lesions. A) Example of individual depth profiles of a grade 2 (blue) and a grade 3 (red) lesion showing the difference in OCT signal attenuation over depth expressed by the differences in slope. Boxplot for individual  $\mu_{oc}$  values in grade 2 (n=29) and grade 3 (n=13) lesions. For all individual OCT measurements on grading, the median (interquartile range)  $\mu_{oc}$  is 1.97 mm<sup>-1</sup> (1.57-2.30) in grade 2 lesions and 3.52 mm<sup>-1</sup> (2.74-3.94) (p-value <0.001) in grade 3 lesions.

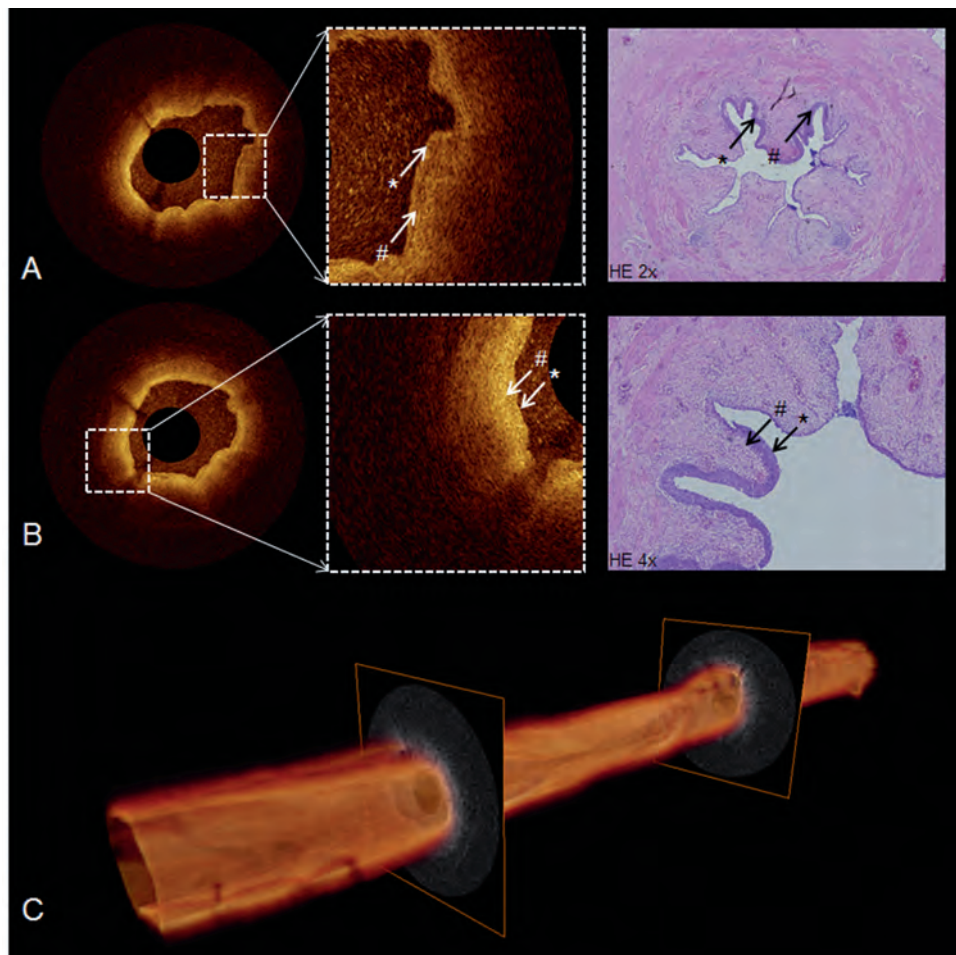
For all patients, no reliable  $\mu_{oc}$  could be obtained from normal appearing urothelium or CIS due to the small thickness of the urothelium (around 50  $\mu$ m).

Three exemplary cases, illustrative for OCT of the ureter and the three types of UTUC commonly seen in urological practice, are described in detail below (Figure 4-6).

*Case 1* – The patient was diagnosed since 2006 with recurrent multifocal TaG1-2 urothelial carcinoma of the bladder and right ureter. Follow-up URS showed multiple papillary lesions in the right, proximal, mid and distal ureter. Intra-operative OCT images showed the basement membrane as a thin dark line and protrusions into the lumen of multiple lesions. The protrusion is presented with a shadowing effect due to attenuation of light in the papillary tissue.

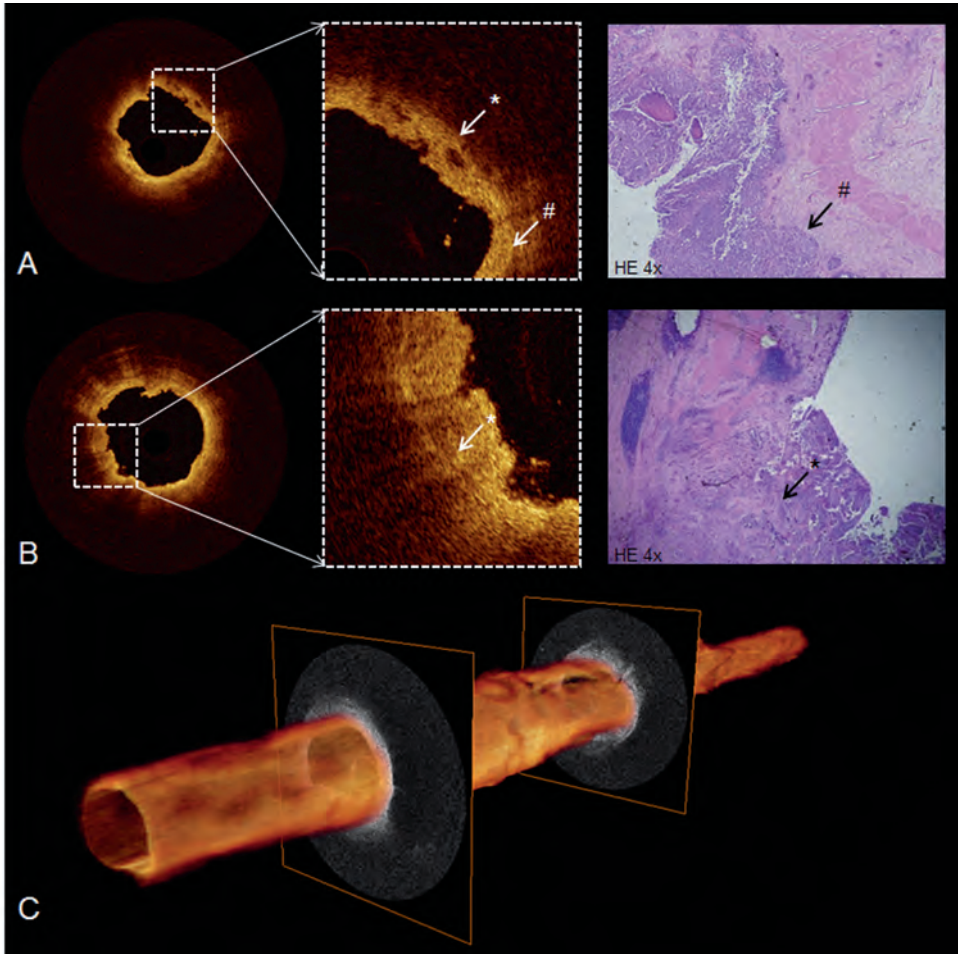
Since the basement membrane is still present as a thin dark line below these lesions, the OCT diagnosis suggests a non-invasive tumor (Figure 4A). In normal appearing OCT images, the anatomical layers of the ureter could be identified (Figure 4B). Average  $\mu_{oc}$  for lesions seen in the OCT images was  $2.3 \pm 0.3$  mm<sup>-1</sup>. Because of a high recurrence rate in the upper tract on the right side, and since the left ureter showed no defects, a right-sided nephroureterectomy was performed. Pathology showed multiple TaG1-2 tumors in the proximal, mid and distal ureter. In 3D OCT rendering, suspected tumor regions were manually segmented based on the visibility of the basement membrane below the tumors (Figure 4C).

*Case 2* – The patient was referred with persistent abnormal selective cytology from the right ureter, suspicious for high-grade urothelial carcinoma. Intra-operative OCT was performed during diagnostic URS on the right side and showed the basement membrane as a thin dark



**Figure 5:** A & B) In-vivo cross-sectional OCT images of the ureter with a flat, broadened urothelial layer (\*). Anatomical layers could be identified with lamina propria and muscularis propria presenting. The basal membrane presents as a thin dark line (#), suggesting a non-invasive tumor. Corresponding histology of the nephroureterectomy specimen showing CIS (\*, right) and basement membrane (#). C) 3D pullback of the OCT build from 520 individual cross-sectional images over a length of 5.2cm.

line. All anatomical layers could be identified. In suspected areas, a flat broadened urothelial layer with low reflectivity was seen (Figure 5A and Figure 5B). No  $\mu_{\text{occ}}$  could be obtained from the suspected areas. As 4 out of 8 biopsies showed carcinoma in situ, a right-sided nephroureterectomy was performed. Histopathological examination of the nephroureterectomy specimen confirmed CIS in the pyelum, proximal ureter, mid and distal ureter. In 3D OCT reconstruction suspected areas were seen (Figure 5C).



**Figure 6:** A & B) Cross-sectional OCT images (left) of the proximal ureter showing an interruption (\*) of the thin dark line (#) suggesting an invasive tumor (left). Distinction between the anatomical layers is not possible. Corresponding histology (right) showed a T3G3 urothelial carcinoma (\* & #). C) 3D pullback of the OCT, built from 520 individual cross-sectional images over a length of 5.2 cm.

*Case 3* – The patient was referred with new-onset hydronephrosis of the right kidney and suspicion of a renal pelvic tumor. Diagnostic URS combined with OCT measurements showed a mass at the ureteropelvic junction (UPJ). The basement membrane was not detectable below the tumor growth, suggesting an invasive tumor (Figure 6A-B). Average  $\mu_{\text{oct}}$  in the lesion was  $3.8 \pm 0.8 \text{ mm}^{-1}$ . As biopsies showed high-grade urothelial carcinoma, right-sided nephroureterectomy was performed. Pathology showed a T3G3 urothelial carcinoma



located at the pyelum and UPJ. Cross-sectional images corresponded with pathology (Figure 6). In 3D OCT reconstruction areas with visible protrusions were seen (Figure 6C).

## Discussion and Conclusion

We showed the first intraluminal OCT identification of the anatomical layers of healthy human ureter in vivo. Moreover, UUT-OCT 1) visually distinguished healthy tissue from tumor tissue, 2) visually differentiated between invasive and non-invasive tumors, 3) differentiates between grade 2 and 3 lesions by quantifying  $\mu_{\text{oct}}$  and 4) thus showed potential to provide intra-operative real-time histological information on stage and grade during minimal invasive procedures.

This study does not provide information on sensitivity and specificity of OCT in the UUT. Additionally, since we included patients consecutively, our study population is limited in pathology. We have not included patients with G1 tumors and patients with T2 tumors. However, our study warrants the importance of future research to determine the accuracy of OCT in grading and staging of UTUC in a larger sample size.

The combination of OCT and endo-urological approaches promises to improve diagnosis and therapy of UUT tumors. Several features of OCT make it well suited for intraluminal diagnostics. State-of-the-art flexible OCT probes are compatible with conventional endoscopes and easy to apply in the ureter, pyelum and calyces, enabling OCT imaging at all sites within the urinary tract that can be reached with an ureterorenoscope and do not interfere with rinsing during URS. OCT measurement duration per patient adds only maximal five minutes during URS, as the probe is easy to use and a single measurement takes 5.2 seconds. OCT images appear direct after measurement and can be analyzed intra-operatively. OCT does not require a conducting medium or direct contact, which makes it easily applicable in the ureter. Finally, the OCT system is compact and portable, which results in an easy to use system in the operation theatre.

The OCT system used in this study is limited to imaging lumen with a maximal diameter of 10 mm, compromising visualization of the pyelum as a whole. Moreover, if tumor thickness transcends scattering-limited imaging depth (~2mm) invasiveness cannot be assessed (case 10, table 2) as a result of this limited imaging depth. This is an important limitation of the technique, since tumors in the pyelum present often as large papillary exophytic masses. Secondly, although normal appearing urothelium and CIS can be visualized on OCT images, the current OCT analyses cannot obtain a reliable  $\mu_{\text{oct}}$  from normal appearing urothelium or CIS due to the limited thickness of these layers. Improvement by increasing resolution of OCT could solve this limitation.

Several clinical applications are conceivable for ureteroscopic OCT, e.g. improving the quality of endoscopic treatment of UUT tumors. OCT-assessment of tumor margins may verify complete vaporization at the time of the operation. In low-grade recurrence in patients with

low-grade, low-stage prior diagnosis, endoscopic laser fulguration can be applied. A drawback of laser treatment is absence of specimens for pathology for definite diagnosis with associated risk of progression having occurred without being noticed. OCT measurements of these tumors may provide this diagnosis, so laser fulguration becomes a safer treatment modality. Random biopsies are taken to exclude or confirm CIS in case of negative URS findings and cytology pointing to high-grade malignancy. OCT may be of value guiding these biopsies.

OCT is less suitable for screening of the complete ureter, since it has to be directed visually to points of interest detected at ureteroscopy. Thus in the absence of visually suspect lesions, a combination of OCT with established optical diagnostics (i.e. photodynamic diagnosis (PDD), narrow band imaging (NBI) or emerging techniques such as Raman spectroscopy and Low-coherence Spectroscopy to direct to the region of interest may further increase the diagnostic potential.<sup>(22-25)</sup> OCT combined with PDD reduces false-positive biopsies and increases specificity compared to PDD alone in the bladder.<sup>(26)</sup> Due to similarities between urothelial cancers of bladder and UUT, this combination may be applicable in the latter as well.

This study is carried out according to the step 1 and 2a of the IDEAL model. This model has high potential for study design in surgical innovations. However, only recommendations regarding study design are described but reporting standards still need to be formulated.

Several study designs could be considered to confirm the feasibility of OCT in UTUC. First of all, an extended in vivo study will have to confirm if OCT is able to differentiate between low-, high-grade and CIS lesions. Secondly, sensitivity and specificity should be determined. Finally by comparing OCT with established pre-operative and intra-operative methods like CT-scan, (selective) cytology and biopsies, the added value of OCT can be determined. As UTUC is not a common disease, studies as proposed above should preferably start as multi-centre studies in order to obtain a large study population.

In conclusion, OCT is a promising new tool for optical diagnostics in upper urinary tract abnormalities. An extended in vivo human study which is about to commence in our centre, second step (2b) in the IDEAL protocol, will confirm if OCT is able to differentiate between low-grade, high-grade and CIS lesions. Secondly, sensitivity and specificity testing of OCT will be determined in nephroureterectomy specimens.

## Project support

This study is funded with a grant provided by the Cure for Cancer foundation and Stichting Urologie 1973, which is gratefully acknowledged.

## Reference list

1. van Velthoven ME, Faber DJ, Verbraak FD, van Leeuwen TG, de Smet MD. Recent developments in optical coherence tomography for imaging the retina. *ProgRetinEye Res.* 2007;26(1):57-77.
2. Hermes B, Spoler F, Naami A, Bornemann J, Forst M, Grosse J, et al. Visualization of the basement membrane zone of the bladder by optical coherence tomography: feasibility of noninvasive evaluation of tumor invasion. *Urology.* 2008;72(3):677-81.
3. Wessels R, de Bruin DM, Faber DJ, van Boven HH, Vincent AD, van Leeuwen TG, et al. Optical coherence tomography in vulvar intraepithelial neoplasia. *JBiomedOpt.* 2012;17(11):116022.
4. Barwari K, de Bruin DM, Faber DJ, van Leeuwen TG, de la Rosette JJ, Laguna MP. Differentiation between normal renal tissue and renal tumours using functional optical coherence tomography: a phase I in vivo human study. *BJUInt.* 2012;110(8 Pt B):E415-E20.
5. Xie T, Zeidel M, Pan Y. Detection of tumorigenesis in urinary bladder with optical coherence tomography: optical characterization of morphological changes. *OptExpress.* 2002;10(24):1431-43.
6. Tearney GJ, Brezinski ME, Southern JF, Bouma BE, Boppart SA, Fujimoto JG. Optical biopsy in human urologic tissue using optical coherence tomography. *JUrol.* 1997;157(5):1915-9.
7. Mueller-Lisse UL, Meissner OA, Babaryka G, Bauer M, Eibel R, Stief CG, et al. Catheter-based intraluminal optical coherence tomography (OCT) of the ureter: ex-vivo correlation with histology in porcine specimens. *EurRadiol.* 2006;16(10):2259-64.
8. Wang H, Kang W, Zhu H, MacLennan G, Rollins AM. Three-dimensional imaging of ureter with endoscopic optical coherence tomography. *Urology.* 2011;77(5):1254-8.
9. Mueller-Lisse UL, Meissner OA, Bauer M, Weber C, Babaryka G, Stief CG, et al. Catheter-based intraluminal optical coherence tomography versus endoluminal ultrasonography of porcine ureter ex vivo. *Urology.* 2009;73(6):1388-91.
10. Barwari K, de Bruin DM, Cauberg EC, Faber DJ, van Leeuwen TG, Wijkstra H, et al. Advanced diagnostics in renal mass using optical coherence tomography: a preliminary report. *JEndourol.* 2011;25(2):311-5.
11. Tomlins PH, Adegun O, Hagi-Pavli E, Piper K, Bader D, Fortune F. Scattering attenuation microscopy of oral epithelial dysplasia. *JBiomedOpt.* 2010;15(6):066003.
12. McLaughlin RA, Scolaro L, Robbins P, Saunders C, Jacques SL, Sampson DD. Mapping tissue optical attenuation to identify cancer using optical coherence tomography. *MedImage ComputComputAssistInterv.* 2009;12(Pt 2):657-64.
13. Cauberg EC, de Bruin DM, Faber DJ, de Reijke TM, Visser M, de la Rosette JJ, et al. Quantitative measurement of attenuation coefficients of bladder biopsies using optical coherence tomography for grading urothelial carcinoma of the bladder. *JBiomedOpt.* 2010;15(6):066013.

14. Roupret M, Zigeuner R, Palou J, Boehle A, Kaasinen E, Sylvester R, et al. European guidelines for the diagnosis and management of upper urinary tract urothelial cell carcinomas: 2011 update. *EurUrol*. 2011;59(4):584-94.
15. Tavora F, Fajardo DA, Lee TK, Lotan T, Miller JS, Miyamoto H, et al. Small endoscopic biopsies of the ureter and renal pelvis: pathologic pitfalls. *AmJSurgPathol*. 2009;33(10):1540-6.
16. Wang JK, Tollefson MK, Krambeck AE, Trost LW, Thompson RH. High rate of pathologic upgrading at nephroureterectomy for upper tract urothelial carcinoma. *Urology*. 2012;79(3):615-9.
17. McCulloch P, Altman DG, Campbell WB, Flum DR, Glasziou P, Marshall JC, et al. No surgical innovation without evaluation: the IDEAL recommendations. *Lancet*. 2009;374(9695):1105-12.
18. McCulloch P. The IDEAL recommendations and urological innovation. *World J Urol*. 2011;29(3):331-6.
19. Faber D, van der Meer F, Aalders M, van Leeuwen T. Quantitative measurement of attenuation coefficients of weakly scattering media using optical coherence tomography. *Opt Express*. 2004;12(19):4353-65.
20. van Leeuwen TG FD, Aalders MC. Measurement of the axial point spread function in scattering media using single-mode fiber-based optical coherence tomography. *IEEE Journal*. 2003;9:227-33.
21. de Bruin DM, Bremmer RH, Kodach VM, de Kinkelder R, van Marle J, van Leeuwen TG, et al. Optical phantoms of varying geometry based on thin building blocks with controlled optical properties. *J Biomed Opt*. 2010;15(2):025001.
22. Patil CA, Bosschaart N, Keller MD, van Leeuwen TG, Mahadevan-Jansen A. Combined Raman spectroscopy and optical coherence tomography device for tissue characterization. *OptLett*. 2008;33(10):1135-7.
23. Patil CA, Kalkman J, Faber DJ, Nyman JS, van Leeuwen TG, Mahadevan-Jansen A. Integrated system for combined Raman spectroscopy-spectral domain optical coherence tomography. *JBiomedOpt*. 2011;16(1):011007.
24. Bosschaart N, Faber DJ, van Leeuwen TG, Aalders MC. Measurements of wavelength dependent scattering and backscattering coefficients by low-coherence spectroscopy. *JBiomedOpt*. 2011;16(3):030503.
25. Bosschaart N, Faber DJ, van Leeuwen TG, Aalders MC. In vivo low-coherence spectroscopic measurements of local hemoglobin absorption spectra in human skin. *JBiomedOpt*. 2011;16(10):100504.
26. Schmidbauer J, Remzi M, Klatte T, Waldert M, Mauermann J, Susani M, et al. Fluorescence cystoscopy with high-resolution optical coherence tomography imaging as an adjunct reduces false-positive findings in the diagnosis of urothelial carcinoma of the bladder. *EurUrol*. 2009;56(6):914-9.



# OPTICAL COHERENCE TOMOGRAPHY AS A TOOL FOR IN-VIVO STAGING AND GRADING OF UPPER URINARY TRACT UROTHELIAL CARCINOMA: A STUDY FOR DIAGNOSTIC ACCURACY

MT Bus<sup>1</sup>, DM de Bruin<sup>1,2</sup>, DF Faber<sup>2</sup>,  
GM Kamphuis<sup>1</sup>, PJ Zondervan<sup>1</sup>,  
MP Laguna Pes<sup>1</sup>, TG van Leeuwen<sup>2</sup>,  
TM de Reijke<sup>1</sup>, JJ de la Rosette<sup>1</sup>

*Academic Medical Center*

*<sup>1</sup>Department of Urology*

*<sup>2</sup>Department of Biomedical Engineering & Physics*

*Journal of Urology 2016 196(6), 1749-1755*

---



## Abstract

### Introduction

Biopsies and cytology are cornerstones in the diagnosis of upper urinary tract urothelial carcinoma (UTUC). However, a high rate of non-diagnostic biopsies, tumor upgrading and -staging after nephroureterectomy is observed. In this prospective in vivo study we aimed to evaluate the diagnostic accuracy of OCT for grading and staging of UTUC

### Material & Methods

Twenty-six patients underwent diagnostic URS including biopsies and OCT imaging, followed by nephroureterectomy or segmental ureter resection. Sensitivity, specificity, negative predictive value and positive predictive value of UTUC grading and staging by OCT were evaluated according to the STARD initiative and second stage (2a and 2b) of the IDEAL model. For tumor staging 2x2 table for sensitivity and specificity was calculated. For tumor grading, the Wilcoxon-rank-sum-test was used to test  $\mu_{\text{oct}}$  in low- and high-grade lesions followed by ROC analysis for sensitivity and specificity.

### Results

In 83% staging of lesions was in accordance with final histopathology. Sensitivity and specificity analysis for tumor invasion was 100% and 92% respectively. Tumor size >2mm and inflammation were risk for false-positives. For low- and high-grade lesions, median  $\mu_{\text{oct}}$  was 2.1 mm<sup>-1</sup> and 3.0 mm<sup>-1</sup> (p-value <0.01) respectively. ROC-analysis showed sensitivity of 87% and specificity of 90% using a cut-off value  $\mu_{\text{oct}}$  of 2.4 mm<sup>-1</sup>.

### Conclusion

This report describes OCT as a real time, intra-operatively diagnostic modality in the diagnostic workup of UTUC. We confirmed the ability of OCT to visualize, grade and stage urothelial carcinoma in the upper urinary tract.

## Introduction

Though radical nephroureterectomy (RNU) is still treatment of choice of upper urinary tract urothelium carcinoma (UTUC), nephron sparing surgery emerges as a viable option in selected patients.<sup>(1)</sup> In this setting, tumor grading and staging are inevitable in order to prevent recurrence or progression and to maintain the opportunity of curative surgery.

Diagnosis of UTUC is based on imaging, ureterorenoscopy (URS) and cytology/histology.<sup>(1)</sup> Unfortunately these techniques have several limitations. No real-time intra-operative histological information is obtained on stage and grade using imaging. Histopathological diagnosis obtained during URS is often inconclusive due the difficulty of tissue sampling. The small biopsy samples result in absence of malignant cells, distorted architecture or absence of muscular layer leading to a high rate of tumor upgrading/upstaging when compared with nephroureterectomy specimens.<sup>(2, 3)</sup> If reliable grading and staging can be obtained during URS, better patient selection for endoscopic treatment will be made. Optical Coherence Tomography (OCT) is a high resolution imaging technology that can be applied during URS and is analogous to ultrasound. It uses backscattered light instead of back reflected sound waves to produce cross-sectional images and has the potential to provide real-time information on grade and stage in UTUC, as previously demonstrated in a pilot study.<sup>(4)</sup> Although this pilot study demonstrated the potential of OCT in the diagnosis of grade and stage in UTUC, no information on diagnostic accuracy of OCT was given.

The primary aim of this study was to assess the diagnostic accuracy of OCT and biopsy in determining grade and stage of UTUC. Second, we aimed to evaluate the sensitivity and specificity of OCT and biopsy in the diagnosis of UTUC. We carried out this study in the context of the second stage (2a and 2b) of the IDEAL model, designed for evaluating new surgical innovations (1 Innovation/Idea, 2a Development, 2b Exploration, 3 Assessment, 4 Long-term follow-up) and the STARD initiative.<sup>(5-7)</sup>

## Material & Methods

### *Power calculation*

One Way Anova sample size calculation was performed using nQuery advisor7.0 using as input the attenuation values from our first in-vivo pilot by Bus et al. (#treatment or groups = 4, CSS of Means = 3.3, SD = 2.1).<sup>(4)</sup> The calculated power of 95% resulted in a sample size of twenty-six patients.

### *Inclusion and protocol*

Consecutive patients with clinical suspicion or follow-up of UTUC were included in a prospective study assessing the diagnostic accuracy of OCT in the staging and grading of UTUC. The study was approved by the institutional Medical Ethical Committee of our hospital and informed consent was required and obtained from all patients



The protocol included a diagnostic URS including biopsies and OCT during the same operative procedure. OCT measurement was only performed in case of visible lesions or strong suspicion for CIS (e.g. positive cytology and negative bladder biopsies). Patients not suitable for conservative therapy were subsequently planned for radical nephroureterectomy or segmental ureterectomy. This latter group was selected to compare OCT staging and grading with histopathology of the resected specimen. OCT results were not taken into account for clinical decision making

#### *Diagnostic URS and biopsies*

Diagnostic URS was performed at our operating theatre by two experienced urologists, using semi-rigid and flexible ureterorenoscopes (Karl Storz semi-rigid 9.5Fr, Karl Storz Flex XC, Olympus URF-V). Biopsies were taken after OCT measurement from visible lesions or at random in case of CIS suspicion, using cup biopsy forceps (Piranha®, 3Fr Boston Scientific) or basket biopsy instrument (zero tip 1.9Fr nitinol basket, Boston Scientific). Biopsies were graded low- or high-grade according to the WHO classification of 2004.<sup>(8)</sup> In addition, tumor invasion was determined if the biopsy contained underlying tissue layers.

#### *OCT measurements*

A commercially available C7-XR™ Intravascular Imaging System interfaced to a single-use C7 Dragonfly™ 2.7Fr (0.9 mm) Intravascular Imaging Probe (St. Jude Medical, St. Paul, Minnesota, USA) was used. It scans a longitudinal trajectory of 54 mm in approximately 5.4 seconds, producing a 540-frame dataset at 20 µm axial resolution. Amira (Visage Imaging GmbH, Berlin, Germany) was used for 3D visualization. The OCT probe was introduced through the working channel of the ureterorenoscope resulting in simultaneous co-registered URS and OCT. Probe position was ensured by X-ray and endoscopic imaging. OCT imaging was performed at locations with macroscopic presence of tumor or suspected lesions. In case of CIS suspicion OCT imaging was performed at planned biopsy sites. OCT images were analysed after surgery and the urologist performing URS was not informed on the outcome of the OCT images.

#### *Histopathological diagnosis of resection specimens and biopsies*

Standard pathological report of nephroureterectomy specimen was considered reference standard. Nephroureterectomy specimens were examined at the pathology department according to standard protocol. The pathologist was blinded for OCT diagnosis and not blinded for biopsy diagnosis.

### *OCT analysis*

OCT datasets were subjected to in-house developed staging and grading protocols by two experienced OCT investigators (MTJB, DMdB) blinded for pathology results, pre-operative imaging or other clinical information assessed the OCT images. Each OCT image was visually inspected and classified as normal (without visible lesion) or abnormal (with visible lesion).

For staging, visible lesions were divided in invasive and non-invasive as described before.<sup>(4)</sup> In short, full 3D OCT datasets were visually analysed on the appearance of a layered structure underneath a lesion, loss of anatomical architecture, intensity of the first layer appearance and structural differences in the A-line. Lesions suspicious for CIS were classified as non-invasive.

For grading, the decrease of light intensity [ $\text{mm}^{-1}$ ] was quantified after imperatively accounting for system specific calibrations.<sup>(9, 10)</sup> The decrease of light intensity was determined by fitting OCT data in a manually selected region of interest in a lesion, to a single exponential decay model in order to determine  $\mu_{\text{oct}}$  as described before.<sup>(11-13)</sup> From each patient we selected five 2D cross-sectional OCT scans from the middle part of clearly visible lesions.

### *Statistics*

Statistical analysis was performed using MedCalc® Version 14.12.0 (MedCalc Software bvba). The statistical setup of the analysis was performed in collaboration with the Clinical Research Unit of our Hospital.

### *Grading*

Because of unequal sample size in all groups, Wilcoxon rank sum test was used to describe differences in  $\mu_{\text{oct}}$  between low grade (grade 1 and grade 2, low-grade) and high-grade (grade 2 high-grade and grade 3) lesions. Boxplots were used for visualization. Because of continuous data, ROC-analysis was performed to calculate sensitivity, specificity and the cut-off value for OCT grading.

2x2 table calculation was performed to determine sensitivity and specificity for tumor grading on biopsy. For analysis, non-diagnostic OCT scans and biopsies were excluded. For biopsy grading, non-diagnostic (benign/ND) was indicated when no tumor was present (e.g. due to limited sample size). For OCT grading, non-diagnostic was indicated when no attenuation coefficient could be extracted from an acquired dataset.

### *Staging*

2x2 table calculation was performed to determine sensitivity and specificity for tumour stage on OCT imaging and biopsy. Non-diagnostic OCT scans and biopsies were excluded.

For biopsy staging, non-diagnostic was indicated when no tumour was present (benign/ND) or invasion could not be determined (Tx/ND)

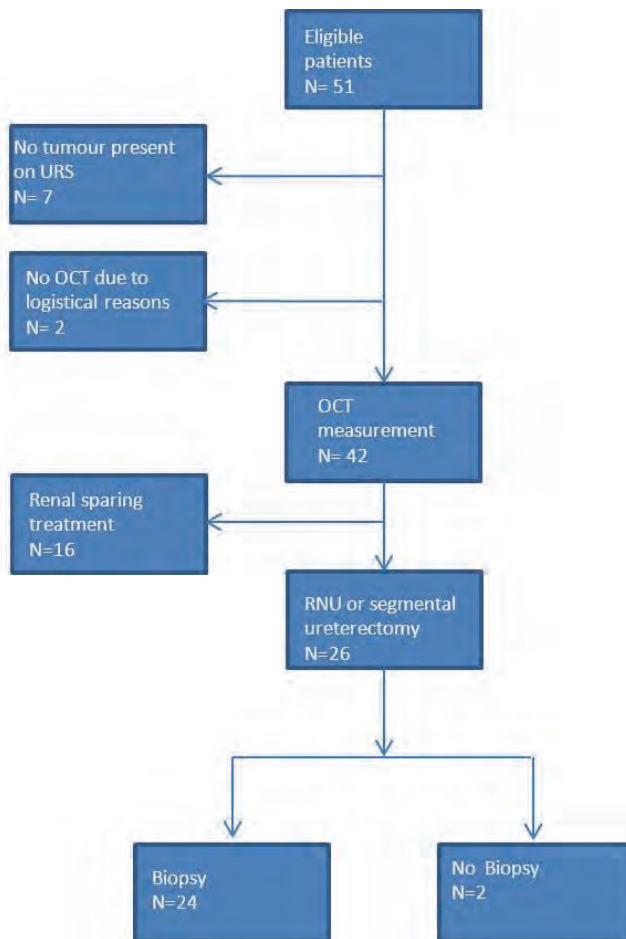
## Results

### *Inclusion*

From December 2011 until December 2014 fifty-one patients were included. In total twenty-six patients underwent URS for UTUC combined with OCT, followed by nephroureterectomy or segmental ureterectomy. Twenty-four patients had both OCT measurements and biopsies during diagnostic URS. In two patients OCT measurement was performed but no biopsies were taken because of poor visibility caused by bleeding during URS. No patients were excluded because of inadequate or failed OCT measurement (Figure 1). Radical surgery was performed  $7.5 \pm 5.5$  weeks after diagnostic URS with OCT measurement. Patient characteristics are listed in Table 1.


**Table 1:** Patient Characteristics

Patients (N)	26
Gender M:V	17:9
Age (yr)	65 ± 13
Solitary kidneys (N)	4
pre-surgery kreatinine (µmol/L)	110 ± 45
post-surgery kreatinine (µmol/L)	173 ± 199
CIS:concomitant CIS	2:5
RNU;partial ureterectomy	22:4
Tumour location	
	Pyelum 7
	Ureter 11
	Both 8



**Figure 1:** Flow chart describing patient inclusion in the OCT study. Patients who underwent a diagnostic URS including OCT measurement were finally included. RNU: radical nephroureterectomy.

Although maximal flexion of the ureterorenoscope is restricted when the OCT probe is inserted, none of the measurements were constrained by this (Figure 2). Fluid irrigation during the OCT procedure was possible due to the irrigating system in the OCT probe. There were no adverse events associated to the OCT procedure.



**Figure 2:** Maximal deflection of the ureterorenoscope is diminished when an OCT probe is inserted. The Karl Storz Flex-Xc ureterorenoscope is able to deflect 270 degrees. After insertion the OCT probe (right picture) the maximal deflection of the Karl Storz Flex-Xc is diminished to 250 degrees. However, this did not limit any of the OCT measurements.

*Histopathological resection specimen analysis*

Final pathologic examination after nephroureterectomy or segmental ureter resection showed in ten patients low-grade UTUC, in fourteen patients high-grade UTUC, in two patients isolated CIS whereas five patients had concomitant CIS. Fourteen patients had non-invasive UTUC and twelve patients had invasive UTUC (Table 2).

*Biopsy analysis*

In twenty-four patients biopsies were obtained during diagnostic URS (Table 2, Figure 3).

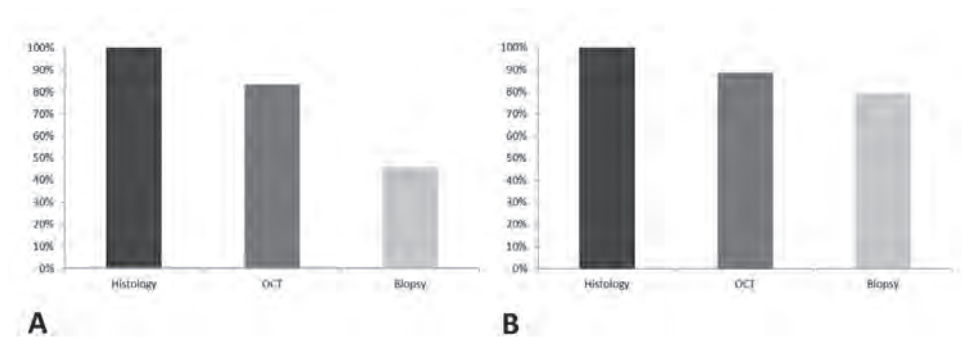
**Table 2:** Overview of the results of biopsy, nephroureterectomy, OCT grade and OCT stage of the included patients.

Patient	Biopt stage	Biopt grade	Surgical Treatment	Pa Nefroureterectomy	OCT grade ( $\mu\text{OCT} \pm \text{SD mm}^{-1}$ )	OCT stage
1	NA	NA	RNU	T3G3	2.93 $\pm$ 0.4	invasive
2	Ta	low grade	RNU	TaG2 (low grade)	2.25 $\pm$ 0.3	non invasive
3	benign/ND	benign/ND	RNU	TaG2 (low grade)	1.95 $\pm$ 0.5	non invasive
4	Ta	high grade	RNU	CIS	ND	non invasive
5	NA	NA	RNU	T3G3	3.66 $\pm$ 0.3	invasive
6	Tx/ND	high grade	RNU	T3G3	3.79 $\pm$ 0.8	invasive
7	Tx/ND	low grade	RNU	T1G2 (low grade)	2.38 $\pm$ 0.6	invasive
8	Ta	low grade	RNU	TaG2 (low grade)	2.31 $\pm$ 0.5	ND
9	Ta	low grade	RNU	TaG2 (low grade) + CIS	1.73 $\pm$ 0.4	non invasive
10	Ta	high grade	RNU	T1G2 (high grade) + CIS	2.56 $\pm$ 0.3	ND
11	Ta	low grade	partial ureterectomy	TaG2 (high grade)	3.17 $\pm$ 0.5	ND
12	Ta	low grade	RNU	T2G3 + CIS	2.98 $\pm$ 0.9	invasive
13	Ta	low grade	RNU	TaG2 (low grade)	1.97 $\pm$ 0.2	non invasive
14	Ta	high grade	RNU	TaG3	2.95 $\pm$ 0.5	non invasive
15	benign/ND	benign/ND	RNU	T1G3	4.58 $\pm$ 0.5	invasive
16	Tx/ND	benign/ND	partial ureterectomy	T2G3	3.04 $\pm$ 0.3	invasive
17	>T1	high grade	RNU	T2G3 + CIS	2.11 $\pm$ 0.4	invasive
18	Ta	low grade	RNU	TaG2 (low grade)	2.87 $\pm$ 0.6	non invasive
19	Tx/ND	low grade	RNU	TaG3	3.12 $\pm$ 1.2	non invasive
20	Ta	high grade	partial ureterectomy	T2G3 + CIS	3.52 $\pm$ 0.5	invasive
21	>T1	high grade	RNU	T4G3	2.12 $\pm$ 0.7	invasive
22	Ta	high grade	RNU	CIS	3.67 $\pm$ 0.5	invasive
23	Tx/ND	high grade	RNU	T2G3	2.83 $\pm$ 0.9	invasive
24	Ta	low grade	partial ureterectomy	TaG2 (low grade)	0.73 $\pm$ 0.3	non invasive
25	Tx/ND	low grade	RNU	TaG2 (low grade)	1.22 $\pm$ 0.4	non invasive
26	Tx/ND	benign/ND	RNU	TaG2 (low grade)	2.30 $\pm$ 0.5	non invasive

ND: non diagnostic NA: non available

### Biopsy Grading

For tumour grading, four (15%) had non-diagnostic biopsy results (benign/ND) and three (13%) had the tumour upgraded on the final pathologic examination after nephroureterectomy (figure 3B). Statistical testing resulted in a sensitivity of 75% with a confidence interval of 43-95%, specificity of 100% (63-100%), PPV of 100% (66-100%), and NPV of 73% (39-94%) (Table 3).



**Figure 3:** Biopsy and OCT results for grading and staging, compared to the histology of the resected specimen in 24 patients who had in-vivo OCT measurement and biopsy of the lesion during URS. In two patients no biopsies were taken during URS. Results are compared to final pathology after radical nephroureterectomy or partial ureter resection. A: Staging results in OCT matched in 83% with final histology and staging results in biopsies matched in 49% with histology. B: Grading results in OCT matched in 88% with histology. Grading results in biopsies matched in 79% with histology.

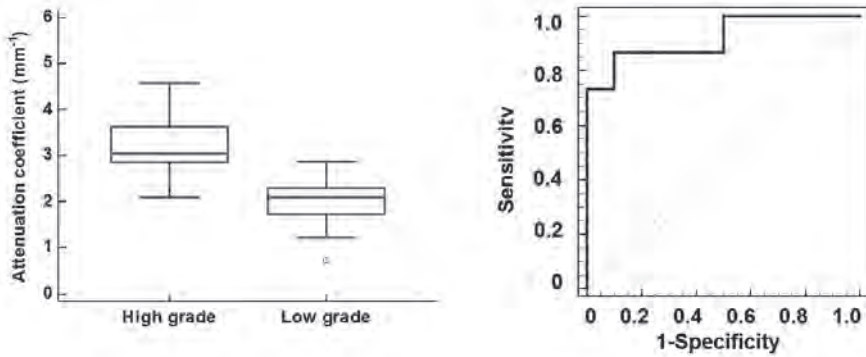
### *Biopsy Staging*

For tumour staging, nine patients (38%) had non-diagnostic biopsy results and in three patients (13%) biopsy showed non-invasive UTUC but had invasive UTUC on final pathologic examination on the nephroureterectomy specimen (Figure 3A). Statistical testing resulted in a sensitivity of 29% with a confidence interval of 4-71%, specificity of 100% (63-100%), PPV of 100% (16-100%) and NPV of 62% (32-86%) (Table 3).

### *OCT analysis*

#### *OCT Grading*

For all individual OCT measurements, median (IQR)  $\mu_{\text{oct}}$  is 2.1 (1.7-2.3  $\text{mm}^{-1}$ ) in low-grade lesions and 3.0 (2.9-3.7  $\text{mm}^{-1}$ ) in high-grade lesions (p-value <0.006) (figure 4A). No reliable  $\mu_{\text{oct}}$  could be obtained from normal appearing urothelium or CIS due to the small thickness of the urothelial layer resulting in one non-diagnostic scan for grading.



**Figure 4:** Boxplot of low grade (n=10) vs. high grade (n=15). No reliable attenuation coefficient could be calculated from CIS. Each used attenuation value is an average of 5 individual measurements. Median (interquartile range) attenuation coefficient is 2.1 (1.7-2.3 mm<sup>-1</sup>) in low grade tumors compared to 3.0 (2.9-3.7 mm<sup>-1</sup>) in high-grade tumors (p-value <0.006). The green line is indicating the cut-off value of 2.4mm<sup>-1</sup>. ROC curve of low grade (n=10) vs. high grade (n=15). Each used attenuation value is an average of 5 individual measurements. The area under curve is 0.92 (95% confidence interval 0.7-1.0%, p-value <0.0001). When using a  $\mu_{\text{cut}}$  cut-off value of 2.4 mm<sup>-1</sup> this results in a sensitivity of 87% (60-98%) and a specificity of 90% (56-100%).

ROC-analyses of low-grade compared to high-grade showed an area under the curve of 0.92 (CI 95% 0.8-1.0, p-value <0.01) (fig 4B). This results in a sensitivity of 87% with a confidence interval of 60-98%, specificity of 90% (56-100%), PPV of 93% (66-100%), and NPV of 82% (48-98%) when using  $\mu_{\text{cut}}$  cut-off value of 2.4 mm<sup>-1</sup> (table 3).

**Table 3:** Statistical results

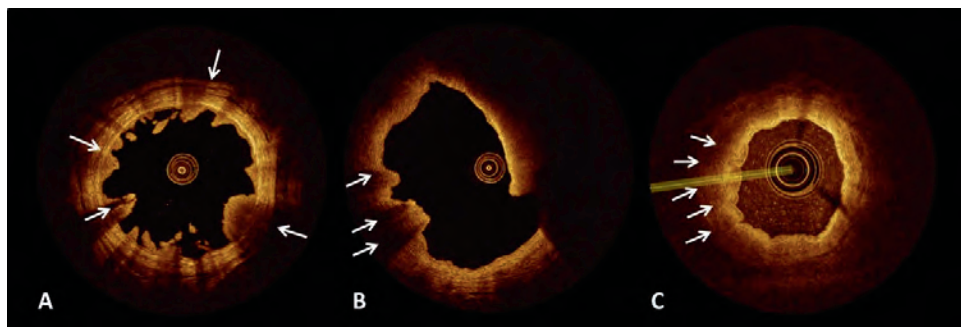
	OCT stage	Biopsy stage	OCT grade ( $\mu_{\text{cut}} \pm 2.4 \text{ mm}^{-1}$ )	biopsy grade
Sensitivity (95%CI)	100% (72-100%)	29% (4-71%)	87% (60-98%)	75% (43-95%)
Specificity (95% CI)	92% (62-100%)	100% (63-100%)	90% (56-100%)	100% (63-100%)
PPV (95% CI)	92% (62-100%)	100% (16-100%)	93% (66-100%)	100% (66-100%)
NPV (95% CI)	100% (72-100%)	62% (32-86%)	82% (48-98%)	73% (39-94%)
Prevalence (95% CI)	48% (27-70%)	47% (21-73%)	60% (39-79%)	60% (36-81%)
AUC (95%)	n.a.	n.a.	0.92(0.7-1)	n.a.
P	n.a.	n.a.	<0.0001	n.a.

CI: Confidence interval, PPV: positive predictive value, NPV: negative predictive value, AUC: Area under the curve, P: p-value, n.a.: not available.



### OCT Staging

In twenty-two patients (83%) staging of visible lesions was concordant with histopathology. In three patients, staging of the visible lesions was non-diagnostic due to large exophytic tumor growth exceeding OCT imaging depth (2 tumours located in ureter and 1 in ureter and pyelum). In one patient, inflammatory lesions were interpreted as invasive tumor lesions, resulting in a false positive diagnosis. In patients with non-invasive tumors, the anatomical layers could be identified underneath the lesions (Figure 5A). In patients with invasive tumors, clear interruption or complete loss of anatomical layers was seen (Figure 5B). In three out of six patients we were able to visually recognize CIS lesions. In patients in whom we were able to identify CIS, a flat broadened urothelial layer with low reflectivity was seen without interruption of the anatomical layers (Figure 5C). Statistical testing resulted in a sensitivity of 100% with a confidence interval of 72-100%, specificity of 92% (62-100%) PPV of 92% (62-100%) and NPV of 100% (72-100%) (Table 3).



**Figure 5 A:** OCT image of a TaG3 ureter carcinoma. Under visible lesions anatomical structure (arrows) is identified. **B:** OCT image of a T2G3 lesion. Anatomical structure could no longer be recognized (arrows). **C:** OCT image of a Carcinoma in Situ (CIS) lesion. Anatomical layers can be identified. A prominent, thickened urothelial layer is recognized (arrows), suggesting CIS.

### Discussion

We confirmed the ability of OCT to visualize, grade and stage low, high-grade and in a lesser extent CIS lesions in the upper urinary tract. OCT as a diagnostic method resulted in a high sensitivity and specificity for UTUC grading and staging. These outcomes confirm results from our previously published pilot study.<sup>(4)</sup> Although this study was conducted in a small study population, most of the criteria of the STARD initiative were followed, including a power calculation. For this reason, this study is methodologically powerful.<sup>(5-7)</sup>

A consequence of our study design was the exclusion of patients suitable for conservative treatment, resulting in inclusion of only advanced cases of UTUC. Final pathology was chosen as gold standard to compare to OCT results. This resulted in a selection bias.

In UTUC, a high rate (43 to 96%) of tumor upgrading and -staging is reported, particularly in low-grade tumorbiopsies.<sup>(3, 14)</sup> Anatomical limitations of the upper urinary tract are the most important cause of inaccurate biopsy. Instrumental maneuvers are hampered and the small caliber of biopsy graspers/ baskets leads to small sampling and crushed biopsies.<sup>(2)</sup> Despite this, biopsies are still an important cornerstone in the diagnostic workup of UTUC and in case of endoscopic treatment, the only available histopathology. Currently, conservative treatment of UTUC is increasingly offered to patients with a normal contralateral kidney and low-risk disease.<sup>(1)</sup> Therefore, knowledge on tumour grade and stage becomes of outmost importance to improve patient selection.

Before embracing OCT as a potential test to replace the classical work up, one needs to address the applicability, including time needed for analysis during diagnostic studies and possible limitations of OCT. Recent studies demonstrated high inter-observer agreement for  $\mu_{\text{oct}}$  determination.<sup>(15, 16)</sup> In addition it is shown that routine  $\mu_{\text{oct}}$  determination for tissue classification does not require extensive training and OCT naïve people only require three trainings to acquire the same results as experienced OCT investigators.<sup>(16)</sup>

### *Limitations*

Visual staging of OCT data using our developed protocols is possible during OCT imaging. Large tumors however, are difficult to stage since imaging of OCT is limited to approximately 2 mm in depth. These large lesions can fill up the lumen and do not necessarily show the layered anatomy needed for staging what led to false positives in this study. Inflammation led to a false positive in one patient with isolated CIS in this study. Histopathology showed extended chronic inflammation and fibrosis besides CIS. Previous studies on OCT in bladder carcinoma have shown that OCT findings in inflammatory state can lead to false positives. Interpretation of OCT findings should be cautious in these settings and the effect of pre-operatively double J-catheter and instillations has to be investigated.<sup>(17)</sup> For this reason, biopsies will remain necessary to confirm or exclude urothelial cancer in the upper urinary tract. OCT has to be seen as a valuable addition to the diagnostic workup in UTUC and not as a replacement for histology. For example OCT measurement of low-grade recurrence in patients with a prior diagnosis of low-grade, low-stage disease may provide this diagnosis so that laser fulguration becomes a safer treatment modality and less or no biopsies are necessary.

False negatives were seen in two of the six patients with concomitant CIS, in which CIS lesions were not recognized besides tumor lesions. An important limitation of our study protocol was to scan only endoscopic visible lesions, therefore concomitant CIS might have

been discovered if a measurement of the complete upper urinary tract would have been performed.

Current grading is obtained by offline analysis using in-house developed software. Incorporation of this software on the OCT console would allow immediate analysis of attenuation values. The fast acquisition time of the current available endoscopic OCT systems does allow imaging of a 54 mm long segment in 5.4 seconds and visualization of a full 3D dataset can be done immediately after acquisition and makes real time intra-operatively tumor grading and -staging possible. Grading of thin layers using  $\mu_{\text{oct}}$  has not been incorporated so far because current methods require at least 5-10 data points in depth which accounts for 50-100  $\mu\text{m}$  of layer thickness. Most normal urothelium however, does not have this required thickness. Recently published novel attenuation analysis methods for thin layers by Vermeer et al. could solve this limitation.<sup>(18)</sup>

We recommend a prospective observational study with a long-term follow-up to confirm the cut-off value for UTUC grading using OCT. This study should be conducted strictly according to the STARD initiative criteria and/or IDEAL stages. Since UTUC is rare, preferably this study design should be conducted in a multicenter approach.

## **Conclusion**

We confirmed the ability of OCT to visualize, grade and stage low, high-grade and CIS lesions in the upper urinary tract. OCT as a diagnostic tool resulted in a sensitivity of 86.7% and specificity of 78.6% for UTUC grading. For UTUC staging, OCT had a sensitivity of 91.7% and a specificity of 78.6%.

## **Project Support**

This study is funded with a grant provided by the Cure for Cancer foundation and Urology 1973 foundation, which are gratefully acknowledged.

## Reference list

1. Roupret M, Babjuk M, Comperat E, Zigeuner R, Sylvester R, Burger M, et al. European guidelines on upper tract urothelial carcinomas: 2013 update. *EurUrol*. 2013;63(6):1059-71.
2. Tavora F, Fajardo DA, Lee TK, Lotan T, Miller JS, Miyamoto H, et al. Small endoscopic biopsies of the ureter and renal pelvis: pathologic pitfalls. *AmJSurgPathol*. 2009;33(10):1540-6.
3. Wang JK, Tollefson MK, Krambeck AE, Trost LW, Thompson RH. High rate of pathologic upgrading at nephroureterectomy for upper tract urothelial carcinoma. *Urology*. 2012;79(3):615-9.
4. Bus MT, Muller BG, de Bruin DM, Faber DJ, Kamphuis GM, van Leeuwen TG, et al. Volumetric in vivo visualization of upper urinary tract tumors using optical coherence tomography: a pilot study. *J Urol*. 2013;190(6):2236-42.
5. Bossuyt PM, Reitsma JB, Bruns DE, Gatsonis CA, Glasziou PP, Irwig LM, et al. Towards complete and accurate reporting of studies of diagnostic accuracy: the STARD initiative. *BMJ*. 2003;326(7379):41-4.
6. McCulloch P. The IDEAL recommendations and urological innovation. *World J Urol*. 2011;29(3):331-6.
7. McCulloch P, Altman DG, Campbell WB, Flum DR, Glasziou P, Marshall JC, et al. No surgical innovation without evaluation: the IDEAL recommendations. *Lancet*. 2009;374(9695):1105-12.
8. B D, M.B. A, F. H, A. H, J.E. T. Pathology and Genetics of Tumours of the Urinary System and Male Genital Organs. In: J.N. E, G S, J.I E, I.A S, editors. World Health Organization Classification of Tumours. Lyon: IARC Press; 2004. p. 150-3.
9. van Leeuwen TG FD, Aalders MC. Measurement of the axial point spread function in scattering media using single-mode fiber-based optical coherence tomography. *IEEE Journal*. 2003;9:227-33.
10. de Bruin DM, Bremmer RH, Kodach VM, de Kinkelder R, van Marle J, van Leeuwen TG, et al. Optical phantoms of varying geometry based on thin building blocks with controlled optical properties. *J Biomed Opt*. 2010;15(2):025001.
11. Faber D, van der Meer F, Aalders M, van Leeuwen T. Quantitative measurement of attenuation coefficients of weakly scattering media using optical coherence tomography. *Opt Express*. 2004;12(19):4353-65.
12. Xie T, Zeidel M, Pan Y. Detection of tumorigenesis in urinary bladder with optical coherence tomography: optical characterization of morphological changes. *OptExpress*. 2002;10(24):1431-43.
13. Wessels R, de Bruin DM, Faber DJ, van Boven HH, Vincent AD, van Leeuwen TG, et al. Optical coherence tomography in vulvar intraepithelial neoplasia. *J Biomed Opt*. 2012;17(11):116022.

14. Smith AK, Stephenson AJ, Lane BR, Larson BT, Thomas AA, Gong MC, et al. Inadequacy of biopsy for diagnosis of upper tract urothelial carcinoma: implications for conservative management. *Urology*. 2011;78(1):82-6.
15. Cauberg EC, de Bruin DM, Faber DJ, de Reijke TM, Visser M, de la Rosette JJ, et al. Quantitative measurement of attenuation coefficients of bladder biopsies using optical coherence tomography for grading urothelial carcinoma of the bladder. *J Biomed Opt*. 2010;15(6):066013.
16. Wessels R, de Bruin DM, Faber DJ, Sanders J, Vincent AD, van Beurden M, et al. Inter-observer variance and learning curve in quantification of the optical coherence tomography attenuation coefficient. 2014.
17. Goh AC, Tresser NJ, Shen SS, Lerner SP. Optical coherence tomography as an adjunct to white light cystoscopy for intravesical real-time imaging and staging of bladder cancer. *Urology*. 2008;72(1):133-7.
18. Vermeer KA, Mo J, Weda JJ, Lemij HG, de Boer JF. Depth-resolved model-based reconstruction of attenuation coefficients in optical coherence tomography. *BiomedOptExpress*. 2013;5(1):322-37.





# EX-VIVO STUDY IN NEPHROURETERECTOMY SPECIMENS DEFINING THE ROLE OF 3D UPPER URINARY TRACT VISUALIZATION USING OPTICAL COHERENCE TOMOGRAPHY AND ENDOLUMINAL ULTRASOUND.

MT Bus<sup>1</sup>, P Cernohorsky<sup>2</sup>, DM de Bruin<sup>1,3</sup>,  
SL Meijer<sup>4</sup>, GJ Streekstra<sup>3,5</sup>, DJ Faber<sup>3</sup>,  
GM Kamphuis<sup>1</sup>, PJ Zondervan<sup>1</sup>, M van Herk<sup>3</sup>,  
MP Laguna Pes<sup>1</sup>, MJ Grundeken<sup>6</sup>, MJ Brandt<sup>3</sup>,  
TM de Reijke<sup>1</sup>, JJ de la Rosette<sup>1</sup>,  
TG van Leeuwen<sup>3</sup>

<sup>1</sup>*Department of Urology*

<sup>2</sup>*Department of Plastic, Reconstructive and  
Hand surgery*

<sup>3</sup>*Department of Biomedical Engineering & Physics*

<sup>4</sup>*Department of Pathology*

<sup>5</sup>*Department of Radiology*

<sup>6</sup>*Department of Cardiology*

*Journal of Medical Imaging 5(1), 017001*

---





## **Abstract**

### **Introduction**

Minimal invasive endoscopic treatment for upper urinary tract urothelial carcinoma (UUT-UC) is advocated in patients with low risk disease and limited tumor volume. Diagnostic ureterorenoscopy combined with biopsy is the diagnostic standard. This study aims to evaluate two alternative diagnostic techniques for UUT-UC: Optical Coherence Tomography (OCT) and Endoluminal Ultrasound (ELUS).

### **Material & Methods**

Following nephroureterectomy, OCT, ELUS and CT were performed of the complete nephroureterectomy specimen. Visualization software (AMIRA®) was used for reconstruction and co-registration of CT, OCT and ELUS. Finally, CT was used to obtain exact probe localization. Co-registered OCT and ELUS datasets were compared with histology.

### **Results**

Co-registration with 3D CT makes exact data matching possible in this ex-vivo setting in order to compare histology with OCT and ELUS. In OCT images of normal appearing renal pelvis and ureter, urothelium, lamina propria and muscularis were visible. With ELUS all anatomical layers of the ureter could be distinguished, besides the urothelial layer. ELUS identified suspect lesions although exact staging and differentiation between non-invasive and invasive lesions was not possible.

### **Conclusion**

OCT provides high-resolution imaging of normal ureter and ureter lesions. ELUS however is of limited value as it cannot differentiate between non-invasive and invasive tumors.

## Introduction

At present, nephroureterectomy is the reference standard for treatment of upper urinary tract urothelial carcinoma (UUT-UC). During the past decade, minimal invasive endoscopic treatments are recognized as a viable treatment option in selected cases with low-grade, non-invasive, UUT-UC and limited tumor volume.<sup>(1)</sup> The advantage of endoscopic treatment is preservation of kidney function. The choice of treatment depends on accurate visualization and pre-treatment information on grade and stage of suspected lesions. The contemporary mainstay in the diagnosis of UUT-UC is based on imaging (CT urography (CT-U)), Ureterorenoscopy (URS), biopsy and urine cytology. CT-U has the highest diagnostic accuracy for the upper urinary tract with a sensitivity of 0.67-1.0 and specificity of 0.93-0.99. However, its accuracy decreases in case of small lesions whereas flat lesions are not detectable unless they cause a filling defect or ureter thickening.<sup>(2)</sup> Unfortunately, histology obtained during URS is often inconclusive due to small biopsy samples and crush artefacts and usually no frozen section on biopsy specimen is done because of the limited and small biopsy specimens.<sup>(3)</sup> If histological diagnosis, grading and staging of UUT-UC is obtained intra-operatively, optimal patient selection and immediate decision on endoscopic conservative management might be possible. In addition, Patients who receive a conservative treatment need to undergo a thorough follow up consisting of URS, cytology and imaging regularly according to the guidelines. A minimal invasive endoluminal imaging technique could possibly provide an more optimal, less invasive follow up for patients and diminish the amounts of biopsies taken. A technology that provides simultaneous imaging of the ureter with high resolution and depth penetration could give this information. However, all imaging techniques suffer from a trade-off between imaging depth and resolution. Several technologies are studied for the upper urinary tract, including optical coherence tomography (OCT) and endoluminal ultrasound (ELUS). Each of these technologies harbours limitations. OCT produces high-resolution cross-section images of the ureter but has a maximal imaging depth of 1-2mm. If tumor thickness transcends this limited imaging depth, tumor invasiveness cannot be assessed.<sup>(4)</sup> ELUS has an increased imaging depth compared to OCT (table 1), but produces images of a low resolution.

**Table 1:** Imaging properties of ELUS and OCT

	ELUS	OCT
<b>Contrast mechanism</b>	Sound scattering	Light scattering
<b>Aim</b>	Real time imaging of luminal structures	Real time information on pathological diagnosis
<b>Imaging depth</b>	20-40mm	2-3mm
<b>Resolution</b>	Axial 200 $\mu\text{m}$ Lateral 200-250 $\mu\text{m}$	Axial 15 $\mu\text{m}$ Lateral 20-40 $\mu\text{m}$
<b>Advantage</b>	High imaging penetration depth	Fast data acquisition High resolution imaging Information on tumor grade and stage
<b>Limitations</b>	Slow data acquisition speed Low resolution imaging	Diminished imaging depth range

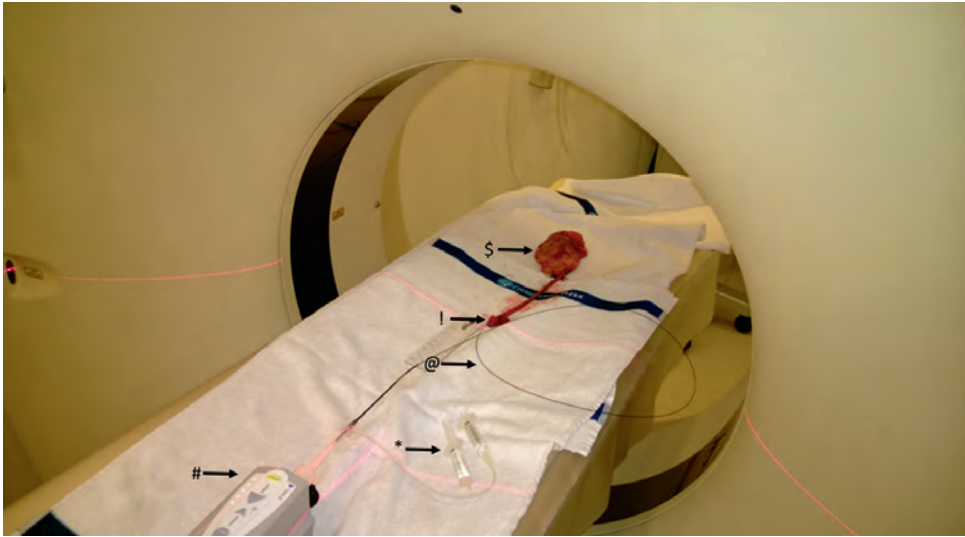
Finally, the challenge in comparing serially acquired OCT with ELUS data is that no absolute co-localisation can be attained without a second, common imaging modality for co-registration. Rapid co-registration can be achieved by automated pixel intensity based image correlation software.<sup>(5)</sup> However, due to serial introduction of the OCT and ELUS probe, the imaged ureter tissue can be shifted and altered and subsequently visualized differently. CT based co-registration has the benefit of absolute spatial co-localisation of two independently acquired datasets.<sup>(6)</sup>

We hypothesize that the high resolution of OCT increases the visibility of small structures and thin layers in the ureter itself, including urothelial layer, while the increased depth imaging of ELUS contributes to the visibility of tissue structures beyond 2mm in depth. The first aim of this feasibility study is to investigate the use of CT for optimal co-registration of OCT and ELUS. The second aim of this study is to determine whether co-registered OCT and ELUS could improve visualisation of large (>2mm) upper urinary tract tumors and discriminates between non-invasive and invasive tumors, by performing co-registered OCT and ELUS measurements in five nephroureterectomy specimens of patients with proven UUT-UC. We compared individual OCT and ELUS datasets on their ability to visualize individual tissue layers of the ureter (urothelium, lamina propria, muscularis propria and periureteral fat).

This study will be performed in the context of the first stage of the IDEAL model designed for evaluation new surgical techniques (1 Innovation/Idea, 2a Development, 2b Exploration, 3 Assessment, 4 Long-term follow-up).<sup>(7,8)</sup>

## Material & Methods

Five complete resected nephroureterectomy specimens including bladder cuff of patients with biopsy confirmed UUT-UC were examined using serial OCT and ELUS measurements combined with co-registered CT (figure 1).



**Figure 1:** Study set up: OCT measurement and ELUS measurements were performed during CT imaging. CT imaging allowed co-registration. This figure demonstrates our study set up while performing OCT measurements which was followed directly by ELUS measurements. \$: nephroureterectomy specimen. ! Insertion of OCT probe in the ostium of the resected bladder cuff. @ OCT probe. \* During each measurement saline was manually injected in by the probe into the ureter to ensure dilated lumen for optimal measurements. # OCT device. In total five complete resected nephroureterectomy specimens including bladder cuff of patients with biopsy confirmed UUT-UC were examined using serial OCT and ELUS measurements combined with co-registered CT.

Immediately after surgery, the specimens were transported to the radiology department to perform OCT, ELUS and CT imaging. Following CT, OCT and ELUS imaging, the specimens were transported to the pathology department for histopathological processing. This study was approved by the Institutional Review Board in 2013, Academic Medical Center, Amsterdam. The Institutional Review Board waived the need for written informed consent of the participants.

#### *Optical Coherence Tomography (OCT) Imaging*

OCT images were obtained as described previously by our group.<sup>(4)</sup> The OCT system used was the Illumien Intravascular Imaging System, interfaced to a C7 Dragonfly™ 2.7Fr (0.9mm) Imaging Probe (St. Jude Medical, St. Paul Minnesota, USA) with an axial resolution of 15µm and an lateral resolution of 20-40µm.<sup>(9)</sup> First, an OCT imaging probe was introduced through the ureteral orifice up to the renal pelvis. Subsequently, OCT images were acquired by retracting the imaging probe using an automatic pullback system at a pullback speed of 10mm/s, while rotating acquiring 100 frames/s, across a trajectory of 54mm. This resulted in a 540-frame dataset in 5.4 seconds. After pullback, the imaging probe was manually

re-positioned 50mm distally in the ureter and a new pullback was performed until the complete renal pelvis and ureter were visualized. After each pullback, the probe position was recorded using co-registered 3D CT.

#### *Endoluminal Ultrasound (ELUS) Imaging*

ELUS images were recorded using the Volcano intravascular ultrasound Imaging system interfaced to the Revolution® 45MHz 3.5Fr (1.7mm) IVUS probe (Volcano Corporation, San Diego, California, USA) with an axial resolution of 200µm and an lateral resolution of 200-250µm.<sup>(10)</sup> Following introduction through the ureteral orifice, the imaging probe was advanced into the renal pelvis. Subsequently, ELUS images were acquired by retracting the imaging probe using the Spinvision® automatic pullback system (Volcano Corporation, San Diego, California, USA) at a pullback speed of 0.5mm/s, while rotationally acquiring 30 frames/s, across a trajectory of 90mm. This resulted in 5400-frame datasets obtained in 180 seconds. After each pullback, the imaging probe was manually re-positioned 80mm distally in the ureter and a new pullback was performed until the complete renal pelvis and ureter were visualized. After each pullback, the probe position was recorded using co-registered 3D CT.

#### *Computed Tomography Imaging (CT)*

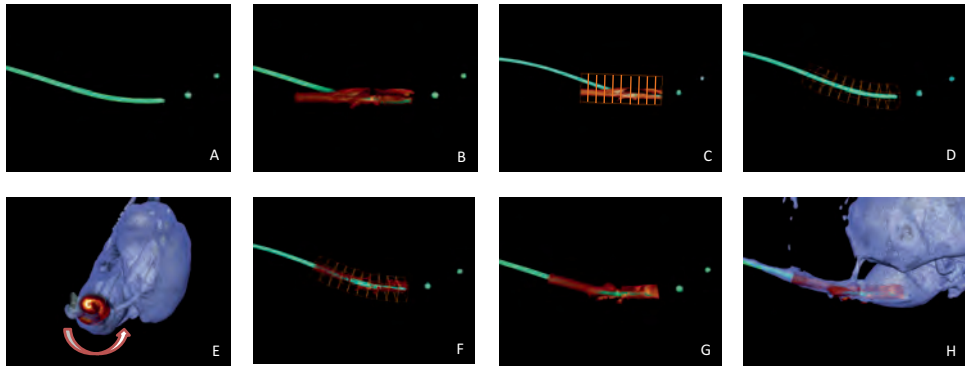
A Brilliance 64-slice CT scanner (Philips Medical System; Best; The Netherlands) was used to make CT-scans of each of the nephroureterectomy specimens. The scans were made at a tube voltage of 120 kV and tube charge of 22 mAs. The total detector collimation was 64x0.625 mm. The filter used in the CT-reconstruction was a medium smooth filter (filter B) and the final voxel spacing was 0.4x0.4x0.7 mm.

#### *Image Reconstruction, 3D rendering and deformable manual CT based co-registration*

CT datasets (DICOM) each depicting a different OCT or ELUS probe position were loaded into the 3D visualization software. An AMIRA embedded, automatic, rigid co-registration algorithm was used to accurately align the datasets in three dimensions. For separate depiction of 1) the probe, 2) kidney and ureter and 3) peri-renal fat, Hounsfield value (HU) based automatic segmentations were performed on the CT data.

Subsequently, corresponding OCT and ELUS datasets (TIFF stacks) were loaded, displayed as 3D-volume reconstruction, and visually aligned to the probe position as seen on CT, using the probe tip as the dataset's starting point. Rotational orientation of the OCT/ELUS datasets was determined based on mutual visible image features in both imaging modalities, such as lumen contour and air bubbles. To correct for the curvature of the probe (and ureter) and to facilitate registration with pathologic slides, manual 3D deformation of the OCT/ELUS datasets was performed. For this reason, the individual OCT/ELUS datasets were separated

into 50-frame segments and manually aligned perpendicular to the CT based probe segmentation in three dimensions. After alignment of the individual segments, recombination of the segments into a new, 3D deformed dataset was conducted. This process was repeated for all datasets to aim for a virtually complete 3D reconstruction of the ureter based on OCT and ELUS data only.



**Figure 2:** Co-registration steps as executed in AMIRA. A: Create and visualize segmented centerline of OCT probe in CT data, B: Read in OCT volume, C: Split total bounding box volume into 10 bounding boxes, D: Manually place individual OCT bounding boxes perpendicular to centerline probe in Y,Z plane, E: Manually rotate each individual OCT bounding box in X,Y plane to fit inner ureter shape, F & G: Merge individual OCT bounding boxes, H: Visualize fused OCT – CT dataset

### *Pathology preparation*

The standard pathological report of nephroureterectomy specimens was considered the reference standard for comparison with OCT/ELUS imaging. Nephroureterectomy specimens dissected and examined at the pathology department according to a standardized protocol.

### *Image analysis and matching with pathology.*

OCT and ELUS datasets were reviewed slice by slice for identification of ureter wall architecture, focusing on identification of ureter wall layers consisting of urothelium, lamina propria, muscularis propria and periureteral fat. Ureteral abnormalities seen as visible lesions were divided in either non-invasive tumors if underlying ureteral wall layer architecture was still visible, or invasive tumors when the wall architecture was interrupted or no visible underlying architecture was present. Images were scored inconclusive when imaged lesion transcended the field of view. Matching of histopathology with the corresponding regions of OCT/ELUS was achieved based on available histopathology slides with sufficient ureter tumor architecture and information provided by the uro-pathologist.

## Results

Specimen characteristics are listed in table 2. All the patients underwent a diagnostic URS including biopsies before radical nephroureterectomy. None of the patients received neo-adjuvant therapy.

**Table 2:** Patient Characteristics

N	Gender	Age (yr)	Tumor Stage	Tumor Grade	Tumor Location
1	F	84	T1	2 (high grade)	renal pelvis
2	F	48	Ta	2 (low grade)	distal ureter
3	F	65	T1	3	renal pelvis
4	M	74	T2	3	renal pelvis
5	M	76	T1	3	distal and proximal ureter, renal pelvis

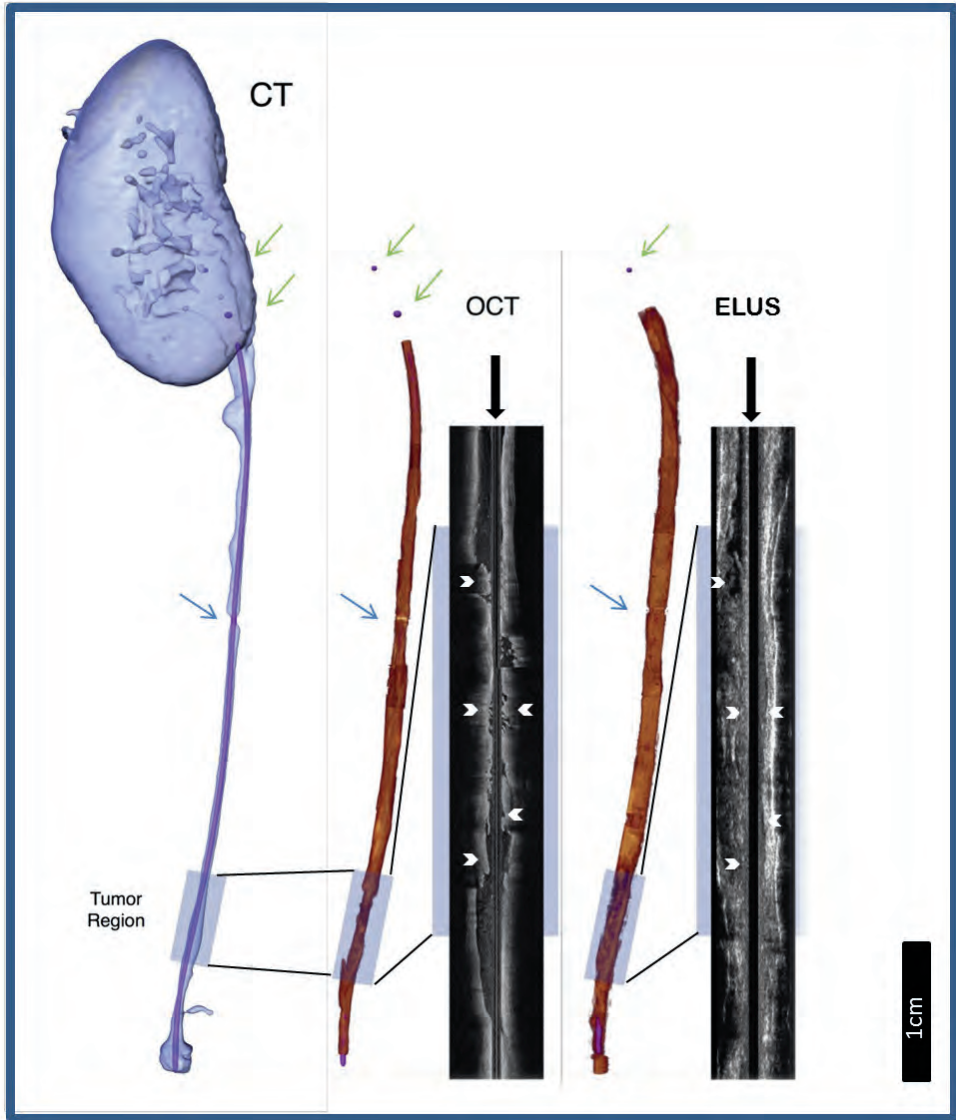
### *CT based co-registration*

CT based co-registration of ELUS and OCT data was achieved for 5 patients. Figure 2 depicts an exemplary semitransparent 3D rendering of the CT dataset which was used for co-localization of the OCT and CT datasets.

Within the CT rendering, a non-transparent purple probe has been made visible. The purple probe was automatically segmented based on Hounsfield units. The curvature of the probe was used to manually deform the OCT and ELUS datasets as shown in Figure 3. A longitudinal cross-section of both the OCT and ELUS dataset shows a clear difference in imaging depth. Additional visible markers, such as the indentation caused by surgical clip that was placed intra operatively and was removed before introducing the imaging probes show the accurateness of dataset matching.

### *OCT and ELUS imaging of the upper urinary tract*

In OCT images of normal appearing renal pelvis and ureter, the urothelium, lamina propria and muscularis propria were clearly visible. In ELUS images of normal appearing ureter, anatomical layers could be distinguished, although the resolution was lower compared to OCT images and because of this low-resolution imaging, the urothelial layer could not be identified (table 3). In OCT images with visible lesions, the anatomical layers could not be identified in all OCT datasets, resulting in a total identification of the urothelium in 79.4%, lamina propria in 79.4%, muscularis propria in 82.4% and periureteral fat in 50% of the total OCT datasets (table 3). In ELUS images the inner mucosal layer is seen as a hyperechoic layer and recognized in 80.9% of the ELUS datasets. The muscularis layer is hypoechoic and seen in 80.9% of the ELUS datasets and the periureteric fat hyperechoic and recognized in 80.9% of the ELUS datasets.



**Figure 3:** CT allowed co-registration and manual 3D deformation of OCT and ELUS datasets to produce an integrated ureter volume reconstruction. Green arrows: radio markers in OCT probe and ELUS imaging probe. Blue arrow: Notch caused by surgical clip that was placed intra operatively and was removed before introducing the imaging probes. White arrowheads: papillary tumour seen in sagittal OCT and ELUS images



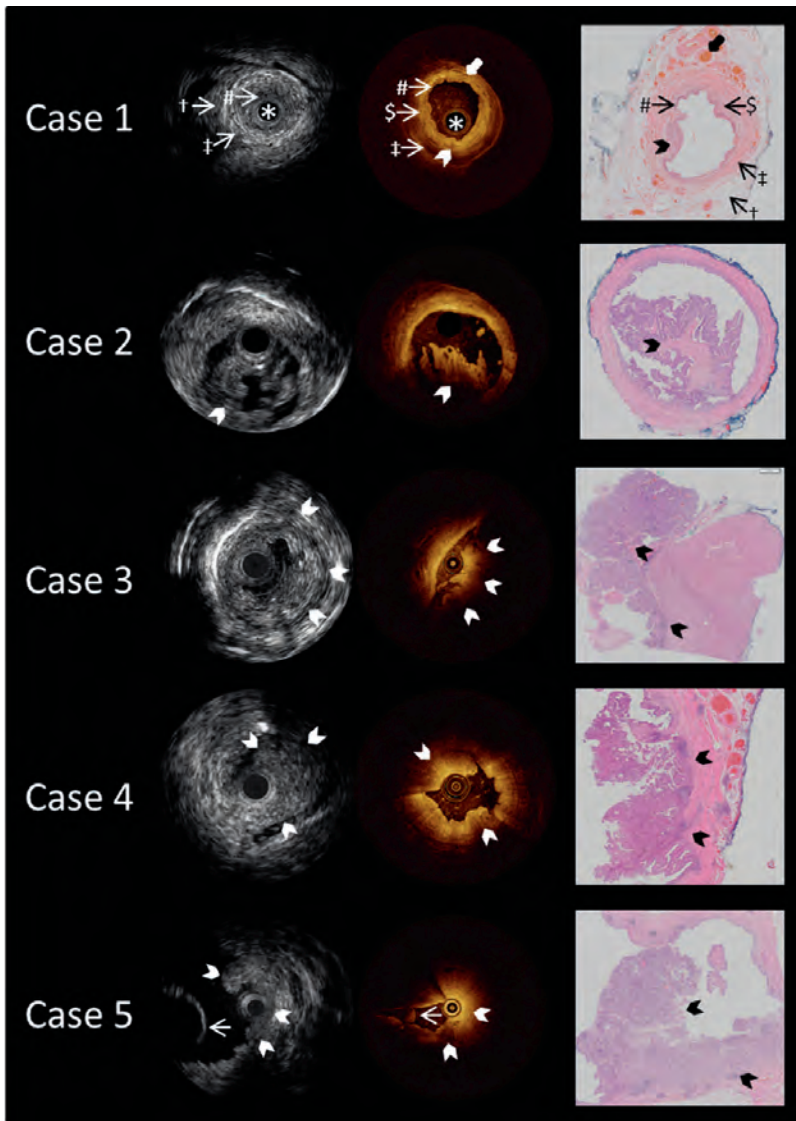
**Table 3:** Results OCT vs ELUS Results of OCT vs ELUS in the datasets.

	OCT	ELUS
<b>Urothelium</b>	80% (27/34)	0% (0/21)
<b>Lamina propria</b>	80% (27/34)	81% (17/21)
<b>Muscularis propria</b>	82% (28/34)	81% (17/21)
<b>Peri ureteral fat</b>	50% (17/34)	81% (17/21)
<b>Maximal imaging depth in lesions</b>	2.0mm	3.5mm*

\*Maximal imaging depth in lesions of ELUS is approximately 3.5mm due to field-of-view settings. The maximal imaging depth of the ELUS imaging probe used in this study is 20mm.

In the OCT imaging datasets the urothelial layer is seen as a low scattering layer and can be differentiated from the lamina propria, which is seen as a high scattering layer. The muscularis layer is seen as a low scattering layer. In the first case (figure 4) von Brunn's nest could be seen in the lamina propria as a low scattering spots within the high scattering lamina propria layer. In ELUS images the muscularis layer was identified as an hypoechoic layer surrounded by the hyperechoic periureteric fat as demonstrated in the first case (figure 4).

In both OCT images and ELUS images of suspected areas, lesions could be identified. The OCT imaging depth range is 2mm where the ELUS maximum imaging depth in lesions is 3.5 mm. This maximum imaging depth of ELUS images was limited by the field of view standard and not by loss of imaging signal in the lesions. In specimens 2 and 3 tumor growth exceeded the OCT 2mm imaging depth range and assessment of tumor invasiveness was hampered (figure 4). In the OCT image of case 2 a papillary structure is recognized. However, the lesion transcends the OCT imaging depth making accurate staging unreliable. Histology diagnosed a TaG2 urothelial carcinoma. In the OCT images of case 3, the tumor is seen as a high scattering lesion that transcends the imaging depth. For this reason, no reliable staging can be assessed, although the image is suspicious for invasion. In the fourth case, high resolution OCT images depicted clearly an invasive tumor. Invasion can be recognized as loss of architecture of the underlying layers. In the fifth case, invasive carcinoma was seen as a lesion with loss of architecture of the underlying layers. In this case, invasive carcinoma with a circular growth pattern was found in almost the complete resected specimen. For this reason, only in two of the eight OCT datasets anatomical layers were recognized. In ELUS imaging in case 2, 3, 4, and 5 tumors are recognized as papillary (case 2) or solid lesions (case 3, 4 and 5). Architecture loss is seen in invasive tumors (case 3, 4 and 5) but exact staging and differentiation between non-invasive (Ta) and invasive ( $\geq T1$ ) lesions was not possible due to low-resolution images (figure 4). In the OCT dataset of the pyelum, a nephrostomy tube was recognized.



**Figure 4:** Cross sectional images of the ureter and pyelum using endoluminal ultrasound (ELUS), optical coherence tomography (OCT) and matching histological images (10x Heamatoxyline and Eosine staining). Case 1 demonstrates a normal appearing part of the ureter. In the ELUS image, the hyperechoic inner mucosal layer (#), hypoechoic muscularis layer (†) and hyperechoic periureteric fat is shown (‡). The probe is marked (\*). The matching OCT image, thin urothelial layer (#), lamina propria (\$) and muscularis propria (‡) can be identified. In addition, von Brunn's nest are recognized (arrowhead) and vessels (thick arrow). In case 2, 3, 4 and 5, tumors are recognized as papillary (case 2) or solid lesions (case 3, 4 and 5) (arrowheads). Architecture loss is seen in invasive tumors (case 3, 4 and 5). In case 5 a nephrostomy tube was recognized on both images (thin arrow).

In the OCT imaging datasets tumor invasion could not be assessed in two of the five patients because tumor thickness hampered OCT interpretation. Tumor thickness up to ~2 mm could be reliably assessed with OCT (table 3). In our ELUS imaging datasets exact staging was not possible, due to the increased imaging depth. However ELUS provided a better overview of the lesions compared to OCT.

## Discussion

This paper demonstrates the first results of one to one comparison of ELUS and OCT data of the human ureter. It shows that OCT permits high-resolution imaging of the upper urinary tract and UUT-UC whereas ELUS provides more depth information. These results warrant hardware integration of both technologies in order to optimize the diagnosis of UUT-UC. The combination of OCT and ELUS allows for high-resolution imaging and greater imaging depth at the same time. This study demonstrates the potential of co-registered OCT and ELUS to visualize anatomical layers of the human upper urinary tract and the potential to discriminate between normal and suspected areas in an ex-vivo setting. However, the greater imaging depth obtained using ELUS did not result in improved staging of UUT-UC, since the imaging resolution of ELUS is too low to render reliable staging.

### *Optical Coherence Tomography of the upper urinary tract.*

This study has shown that visualization of the urothelium, lamina propria and muscularis propria is feasible with OCT in normal appearing tissue. The imaging depth of ~2mm even allows imaging into the peri-ureteral fat layer. However, the imaging depth is a clear limitation when assessing a papillary lesion, impeding visualization of the lesion base and underlying layers, which is needed for an accurate estimation of tumor invasiveness. The ability of OCT to distinguish the different anatomical layers of porcine and human ureter has been demonstrated and the potential to qualitatively differentiate between non-invasive and invasive UUT-UC has also been shown.<sup>(4, 11, 12)</sup> This gives OCT the potential to stage UUT-UC. In addition, OCT has the potential to grade UUT-UC by quantification of the optical attenuation coefficient ( $\mu_{\text{oct}}$ ).<sup>(4, 12-16)</sup> Malignant tissue manifests as an increased amount of mitochondria and an increased nuclear/cytoplasm ratio. As a result, malignant tissue has different scattering properties compared to benign tissue, allowing visible lesions to be graded in OCT images by analyzing the decay of light in tissue expressed as  $\mu_{\text{oct}}$ . Although OCT could be used for staging of small lesions, large lesions exceeded OCT imaging depth range, making staging not possible for lesions larger than ~2mm in-depth. Merging OCT with an imaging modality with a larger imaging depth range overcomes this important limitation of OCT, while the ability of OCT to grade lesions remains.

### *Endoluminal Ultrasound in the upper urinary tract*

Visualizing the mucosal layer, consisting of sub-layers of urothelium and lamina propria, is possible with ELUS. However, differentiation of these sub-layers is impossible due to a lack of contrast and low resolution. The 20mm imaging depth allows estimation of tumor size, although clear differentiation between non-invasive and invasive tumors cannot be achieved as a result of the limited resolution of  $\sim 100\mu\text{m}$ . Nonetheless, it is the deeper penetration depth of ELUS that makes this technique interesting for endourological applications. For example, an advantage of larger imaging depth is the ability to determine the relation of specific pathology with its direct surroundings, like lymphadenopathy in malignancy.<sup>(17)</sup> Advances of ELUS have led to small catheter-based ultrasound probes allowing visualization of a variety of luminal structures.<sup>(18)</sup> In the ureter, ELUS is mainly used in the diagnostic work-up of stenosis of the ureteropelvic junction (UPJ) and its relation with intersecting vessels. However a wide pathologic variety can be seen in the ureter, like upper urinary tract tumors and endometriosis.<sup>(17, 19, 20)</sup>

ELUS is based on the detection of the time delay in high frequency sound waves, which are backscattered by tissue structures. The difference in resolution between OCT and ELUS is explained by the different wavelengths at which they operate. Unlike light waves in OCT, the transmission of sound waves needs a conduction medium, which is provided by the fluid present in the upper urinary tract lumen. A disadvantage of ELUS is the time needed for data acquisition, which is a factor 20 times longer compared to data acquisition using OCT. This increased acquisition time makes ELUS more sensitive to movements, resulting in blurred images. In an in-vivo setting, motion artefacts will occur due to ureteric peristalsis, breathing and movement at the point where the ureter intersects with the great vessels. A second limitation of ELUS is its sensitivity for air bubbles.

This study shows data of OCT and ELUS acquired from the renal pelvis and ureter. Maneuvering the probe towards a suspected lesion in the renal pelvis compared to the ureter is more challenging but achievable after training of handling the imaging probe. Application of OCT and ELUS in the renal pelvis has been shown in previous studies as well.

(4, 12, 20)

### *CT as a guide for probe localization*

The main challenge in co-registration of endoluminal imaging techniques, is comparative localization with respect to histopathology. Co-registered ELUS and OCT combines greater depth imaging with superficial high-resolution images. To proof this, accurate correlation with histopathology is needed. To ensure that histopathology was obtained from the same location as OCT and ELUS measurements, accurate knowledge of probe position is needed. Therefore, we used CT to obtain reliable information on the intra-ureteral probe position, correlated to overall anatomy.

### *Fusion of OCT and ELUS*

To obtain reliable co-registration of OCT and ELUS, both diagnostic tools should have the same voxel size. Having the same voxel size will result in accurate fusion of image features and measurement of layer thickness. However, optimal merging of OCT with ELUS needs parallel imaging instead of serial imaging. Several research groups have worked on integration of both imaging modalities resulting in a single hybrid catheter. Using this hybrid catheter, one-to-one acquisition of integrated OCT and ELUS images was obtained of coronary vessels.<sup>(21-23)</sup> But standard OCT and ELUS acquisition does not take into account the curvature of the catheter in relation to the imaged lumen. A normal 3D OCT or ELUS dataset is therefore usually depicted as a rigid tube. Several research groups have shown the possibility to fuse 3D ELUS with CT. Center-line registration of the lumen found in CT data was employed to deform the rigid ELUS data in three dimensions, resulting in a more anatomically correct representation.<sup>(22, 24, 25)</sup> Sharp curvatures however, resulted in imperfect 2D image spacing within a 3D volume and should be taken into consideration during deformed 3D reconstruction and co-registration. This limitation is especially important when this technology will be applied in-vivo. For example, to examine the lower pole calyces during a URS, the ureterorenoscope has to make a curve of almost 180 degrees. Therefore, OCT and ELUS data acquisition should take this into account to provide the urologist with a reliable and realistic 3D representation of the ureter, pyelum and calyces.

## **Conclusion**

In this pilot study, it appears that co-registration with CT enables exact spatial OCT and ELUS data matching in this ex-vivo setting. OCT permits high-resolution imaging whereas ELUS provides more depth information of the upper urinary tract. These results warrant hardware integration of both technologies in order to combine larger depth sensitivity with superficial high-resolution images. However, differentiation between non-invasive and invasive tumors is not possible using the 45 MHz ELUS system employed in this study due to low-resolution images.

## Reference list

1. Roupret M, Babjuk M, Comperat E, Comperat E, Zigeuner R, Zigeuner R, Sylvester R, Sylvester R, Burger M, Burger M, Cowan N, et al. European guidelines on upper tract urothelial carcinomas: 2013 update. (1873-7560 (Electronic)).
2. Xu AD, Ng CS, Kamat A, Grossman HB, Dinney C, Sandler CM. Significance of upper urinary tract urothelial thickening and filling defect seen on MDCT urography in patients with a history of urothelial neoplasms. *AJR AmJRoentgenol.* 2010;195(4):959-65.
3. Wang JK, Tollefson MK, Krambeck AE, Trost LW, Thompson RH. High rate of pathologic upgrading at nephroureterectomy for upper tract urothelial carcinoma. *Urology.* 2012;79(3):615-9.
4. Bus MT, Muller BG, de Bruin DM, Faber DJ, Kamphuis GM, van Leeuwen TG, et al. Volumetric in vivo visualization of upper urinary tract tumors using optical coherence tomography: a pilot study. *J Urol.* 2013;190(6):2236-42.
5. G. C. Quantification of paper mass distributions within local picking areas. *Nord Pulp Paper Res J.* 2007;22(04):441-6.
6. Hutton BF, Braun M. Software for image registration: algorithms, accuracy, efficacy. *SeminNuclMed.* 2003;33(3):180-92.
7. McCulloch P, Altman DG, Campbell WB, Flum DR, Glasziou P, Marshall JC, et al. No surgical innovation without evaluation: the IDEAL recommendations. *Lancet.* 2009;374(9695):1105-12.
8. McCulloch P. The IDEAL recommendations and urological innovation. *World J Urol.* 2011;29(3):331-6.
9. Muller BG, de Bruin DM, van den Bos W, Brandt MJ, Velu JF, Bus MT, et al. Prostate cancer diagnosis: the feasibility of needle-based optical coherence tomography. *J Med Imaging (Bellingham).* 2015;2(3):037501.
10. Mintz GS, Nissen SE, Anderson WD, Bailey SR, Erbel R, Fitzgerald PJ, et al. American College of Cardiology Clinical Expert Consensus Document on Standards for Acquisition, Measurement and Reporting of Intravascular Ultrasound Studies (IVUS). A report of the American College of Cardiology Task Force on Clinical Expert Consensus Documents. *Journal of the American College of Cardiology.* 2001;37(5):1478-92.
11. Mueller-Lisse UL, Meissner OA, Babaryka G, Bauer M, Eibel R, Stief CG, et al. Catheter-based intraluminal optical coherence tomography (OCT) of the ureter: ex-vivo correlation with histology in porcine specimens. *EurRadiol.* 2006;16(10):2259-64.
12. Bus MT, de Bruin DM, Faber DJ, Kamphuis GM, Zondervan PJ, Laguna-Pes MP, et al. Optical Coherence Tomography as a Tool for In Vivo Staging and Grading of Upper Urinary Tract Urothelial Carcinoma: A Study of Diagnostic Accuracy. *J Urol.* 2016;196(6):1749-55.

13. Wessels R, de Bruin DM, Faber DJ, van Boven HH, Vincent AD, van Leeuwen TG, et al. Optical coherence tomography in vulvar intraepithelial neoplasia. *J Biomed Opt.* 2012;17(11):116022.
14. Tomlins PH, Adegun O, Hagi-Pavli E, Piper K, Bader D, Fortune F. Scattering attenuation microscopy of oral epithelial dysplasia. *JBiomedOpt.* 2010;15(6):066003.
15. Barwari K, de Bruin DM, Faber DJ, van Leeuwen TG, de la Rosette JJ, Laguna MP. Differentiation between normal renal tissue and renal tumours using functional optical coherence tomography: a phase I in vivo human study. *BJUInt.* 2012;110(8 Pt B):E415-E20.
16. McLaughlin RA, Scolaro L, Robbins P, Saunders C, Jacques SL, Sampson DD. Mapping tissue optical attenuation to identify cancer using optical coherence tomography. *MedImage ComputComputAssistInterv.* 2009;12(Pt 2):657-64.
17. Ingram MD, Sooriakumaran P, Palfrey E, Montgomery B, Massouh H. Evaluation of the upper urinary tract using transureteric ultrasound--a review of the technique and typical imaging appearances. *ClinRadiol.* 2008;63(9):1026-34.
18. Goldberg BB, Liu JB, Merton DA, Kurtz AB. Endoluminal US: experiments with nonvascular uses in animals. *Radiology.* 1990;175(1):39-43.
19. Goldberg BB, Bagley D, Liu JB, Merton DA, Alexander A, Kurtz AB. Endoluminal sonography of the urinary tract: preliminary observations. *AJR AmJRoentgenol.* 1991;156(1):99-103.
20. Liu JB, Bagley DH, Conlin MJ, Merton DA, Alexander AA, Goldberg BB. Endoluminal sonographic evaluation of ureteral and renal pelvic neoplasms. *JUltrasound Med.* 1997;16(8):515-21.
21. Yin J, Yang HC, Li X, Zhang J, Zhou Q, Hu C, et al. Integrated intravascular optical coherence tomography ultrasound imaging system. *J BiomedOpt.* 2010;15(1):010512.
22. van der Giessen AG, Schaap M, Gijzen FJ, Groen HC, van WT, Mollet NR, et al. 3D fusion of intravascular ultrasound and coronary computed tomography for in-vivo wall shear stress analysis: a feasibility study. *IntJ CardiovasclImaging.* 2010;26(7):781-96.
23. Hao-Chung Y, Jiechen Y, Changhong H, Cannata J, Qifa Z, Jun Z, et al. A dual-modality probe utilizing intravascular ultrasound and optical coherence tomography for intravascular imaging applications.
24. Cothren RM, Shekhar R, Tuzcu EM, Nissen SE, Cornhill JF, Vince DG. Three-dimensional reconstruction of the coronary artery wall by image fusion of intravascular ultrasound and bi-plane angiography. *IntJ Card Imaging.* 2000;16(2):69-85.
25. Marquering HA, Dijkstra J, Besnehard QJA, Duthé JPM, Schuijf JD, Bax JJ, et al., editors. *Coronary CT angiography: IVUS image fusion for quantitative plaque and stenosis analyses2008: International Society for Optics and Photonics.*







# DISCUSSION AND FUTURE PERSPECTIVES

*Based on:*

*Beyond Endoscopy-Ultrasound, Optical Coherence Tomography and Confocal Laser Endomicroscopy  
Bus MT, de Bruin DM, Kamphuis GM, Zondervan PJ,  
Laguna Pes MP, de Reijke ThM, de la Rosette JJ.  
Chapter 12 of Textbook of Upper Urinary Tract  
Urothelial Carcinoma*

*Editors: Grasso M, Bagley D. Published 2015 by  
Springer Science + Business Media  
ISBN 978-3-319-13869-5*

*And*

*Optical Coherence Tomography in Bladder Carcinoma  
Bus MT, de Bruin DM, de Reijke ThM, de la Rosette JJ  
Chapter 3 of Advances in Image-Guided Urologic Surgery  
Editors: Liao JC, Su L-M. Published 2015 by  
Springer Science+Business Media  
ISBN 978-1-4939-1449-4*

*And*

*Freund JE, Faber DJ, Bus MT, van Leeuwen TG,  
de Bruin DM. Grading upper tract urothelial carcinoma  
with the attenuation coefficient of in-vivo optical  
coherence tomography. Lasers in Surgery and Medicine 2019.*

---



## Discussion and future perspectives

The work presented in this thesis demonstrated that optical diagnostics have the potential to improve the diagnosis of upper urinary tract urothelial carcinoma (UTUC). Technical improvements have been introduced in the design of ureterorenoscopy armamentarium over the past years. Modern (flexible) ureterorenoscopy resulted in improved visualization of UTUC. These developments in ureterorenoscopy have paved the way to allow endoscopic treatment of UTUC, starting in imperative indications and now expanding to elective indications in patients with low-volume, low-grade, low-stage disease and a healthy contralateral kidney.<sup>(1,2)</sup> To overcome the problem of under detecting, under grading and under staging of UTUC, new optical diagnostics are being evaluated in the upper urinary tract.

## Optimising Diagnosis of Upper Urinary Tract Urothelial Carcinoma

One of the main challenges in endoscopic diagnosis of upper urinary tract urothelial carcinoma is the complicated anatomy and the small size of the upper urinary tract, resulting in high demands on the armamentarium and expertise of the urologist. Difficulties to reach the complete collecting system can result in an incomplete visual inspection. Complete armamentarium including flexible ureterorenoscopes and pliers for biopsies should be available for the urologist diagnosing and treating UTUC.

To reach the renal pelvis, the instruments have to pass the urethra (and prostate) and are then inserted through the ureteral orifice into the ureter. The ureter is a tubular structure that is generally 22-30 cm in length and 2-4 mm in width. Anatomical angulation of the ureter may restrict the insertion of endoscopes, but also anatomical tapering of the ureter may provide difficulties. While inserting a ureterorenoscope in the ureter, one will come across three anatomical restrictions of the ureter; the ureterovesical junction, the crossing of the ureter with the iliac vessels and the ureteropelvic junction.

By using a flexible ureterorenoscope the renal pelvis and the major calyces can usually easily be reached. To reach the lower pole calyx, the tip of the endoscope has to be capable to make a curve up to 180°. There is a huge anatomical variation in the number and location of the calyces and sometimes the necks of the calyces can be narrow, not allowing the endoscope to enter. Therefore, visual inspection should always be combined with fluoroscopic imaging.

The anatomy of the upper urinary tract demands great flexibility of endoscopes and instruments to inspect the complete collecting system. The limited diameter of the ureter, however, considerably limits the size of ureterorenoscopes that can be used in the upper urinary tract. To visualize the complete upper urinary tract including pyelum, calyces and papillae, flexible ureterorenoscopy should be performed in combination with semi-rigid endoscopy. Modern flexible ureterorenoscopes have a tip diameter of 4.9 to 8.7 Fr, a shaft diameter of 7.1 to 10.9 Fr and a proximal diameter of 7.2 to 10.9 Fr and can reach a deflection of up to

275°. <sup>(3)</sup> Besides diameter of the scope, the diameter of the working channel is of importance, as it is used for irrigation with water as well as for placement of instruments like graspers, baskets and laser fibers. Maximal deflection of the ureterorenoscope is diminished when instruments are placed in the working channel. This can hamper optimal utilization of the ureterorenoscope.

In case of a suspect lesion, histopathological examination is mandatory. Biopsy specimens retrieved during ureterorenoscopy are frequently minute because of the application of small caliber instruments, and may therefore, be difficult to examine by the pathologist. <sup>(4)</sup> Consequently, a high rate of tumour upgrading (37-96%) and upstaging (38%) is reported following nephroureterectomy. <sup>(5, 6)</sup>

To decide which patients are eligible for endoscopic treatment, information on tumour stage and grade has become imminent for clinical decision-making. Optimizing endoscopic visualization and accurate diagnosis of UTUC is therefore, a prerequisite. Novel optical diagnostic techniques, based on the interaction of light with tissue, have the potential to improve the detection and diagnosis of UTUC. <sup>(7)</sup> These interactions include scattering, absorption and fluorescence, all of which are characteristic for certain tissue types. Some of these techniques aim to provide real time intra-operative information on tumour grade and stage. If knowledge about tumour grade and stage is obtained during URS, a better selection of patients eligible for endoscopic treatment is possible and safe and simultaneous treatment can be applied. It is because of this promise that optical diagnostics might reduce the limitations of the current biopsies.

Most research on the application of optical diagnostics on urothelium has been done in the field of bladder cancer. <sup>(8, 9)</sup> Results on bladder urothelium resemble ureteral urothelium. However, the limited space in the ureter and the difficulty of reaching the upper urinary tract creates a whole new spectrum of challenges for the applied optical techniques. Given the speed of current technical developments and miniaturization of instruments, optical diagnostics have become available for the diagnostic work up of upper urinary tract investigation.

Novel optical diagnostic techniques, based on the interaction between light and tissue, have the potential to improve UTUC visualization. These interactions include scattering, absorption and fluorescence, all of which are characteristic for certain tissue types. Some of these techniques aim at improved visualisation of urothelial tumours (NBI, IMAGE1 S™, PDD), while other techniques aim at providing real time intra-operative information on tumour grade and stage (OCT, CLE).

However, research has to be done before endoluminal diagnostics can be reliably applied in the upper urinary tract. Although promising, the diagnostic value of optical diagnostics has not been determined yet. In addition, cost effectiveness has not been determined for these new diagnostic techniques. However, it can be hypothesized that improved tumour

detection and histological diagnosis of UTUC will diminish the total amount of procedures and total costs, but studies about the costs in UTUC management should confirm this hypothesis.

From a clinical point of view, the ideal adjunct modality for endoscopic procedures in the upper urinary tract should: 1) increase the sensitivity and specificity of detecting malignant and premalignant lesions, 2) provide real-time reliable information on grade and stage, 3) reliably identify the lateral and deep margins in order to achieve complete resection and consequently identify residual tumour within resection margins, 4) easily integrate in modern ureterorenoscopes, 5) be easy to apply with a short learning curve for image interpretation, 6) not require the use of toxic or inconvenient chemicals or pharmaceuticals, 7) allow simultaneous display of a conventional white light image such that endoscopic surgery could be guided by such modality in real time, 8) be compact and easy to handle in the operation room and 9) preferably be low in additional costs.<sup>(9, 10)</sup>

Although the combination of endoscopy and the novel optical diagnostic techniques show potential to improve diagnosis of UTUC, none of the described techniques in this overview meets all these conditions. In the future, a combination of optical diagnostics and improved ureterorenoscopy techniques should meet these conditions and provide an optimal grading and staging of UTUC.

## **Future Perspectives on Optical Coherence Tomography in the Upper Urinary Tract**

The combination of a high resolution imaging technique and modern endo-urolological approaches seems promising to improve the diagnosis and therapy of upper urinary tract tumours.<sup>(11)</sup> Several features of OCT make it well suited for intraluminal diagnostics. OCT can be constructed with common optical fiber components and integrated within conventional endoscopes. Additionally, the OCT system is compact and portable. All of these features make OCT an ideal tool for these purposes in the upper urinary tract. However, the OCT imaging probe currently used in the upper urinary tract is designed for intravascular imaging and is not optimally suitable for use in the upper urinary tract. The intravascular OCT imaging probe has a distal tip, containing radiopaque markers and a guidewire exit port for optimal intravascular placement. This long distal tip makes OCT imaging of lesions in calyces difficult. An OCT imaging probe especially designed for the upper urinary tract is for this reason highly desirable.

During the finalization of this thesis, we continued to study the diagnostic properties of OCT in UTUC. The primary aim of this subsequent study was to assess the diagnostic accuracy of OCT in determining grade and stage of UTUC in a larger study cohort. Second, we aimed to evaluate the sensitivity and specificity of OCT and biopsy in the diagnosis of UTUC.

During the development of the subsequent study by Freund et al, several methods were adapted compared to the study described above.<sup>(12)</sup> As discussed in chapter 4 and chapter 5, it is hypothesized that lesion grade correlates with  $\mu_{\text{OCT}}$ . In chapter 4 and chapter 5,  $\mu_{\text{OCT}}$  was assessed based on circular OCT grey-scale images and used  $\mu_{\text{OCT}}$  as a cut-off for UTUC grading.

As further development revealed, this method of calculating  $\mu_{\text{OCT}}$  did not accurately account for the a) confocal point spread function of the OCT probe and b) the sensitivity roll-off of the OCT system, since both were treated as a single offset ( $\mu_{\text{CAL}}$ ) to the attenuation coefficient. Originally, the  $\mu_{\text{OCT}}$  value was determined by adding  $\mu_{\text{CAL}}$  to the fitted decay constant. This approach assumes a fixed value of the system induced attenuation and can be calibrated on samples with known  $\mu_{\text{OCT}}$  as described by Almasian et al.<sup>(13)</sup>

Critically, it is assumed that the focus is located at the position where the probe is in contact with the tissue boundary. For Dragonfly probes applied in the upper urinary tract however, this assumption is invalid. The apparent Rayleigh length  $Z_R$ , focus position  $z_f$  and roll-off parameters were, therefore, calibrated independently and used as fixed parameters in the  $\mu_{\text{OCT}}$  analysis of the present study.

Furthermore, analysis was done on the circular TIF images as provided by the used OCT system. These circular TIF images are presented in a 10 LOG greyscale format and an additional adjustment for the log-transformation should have been applied to these images for correct  $\mu_{\text{OCT}}$  analysis.

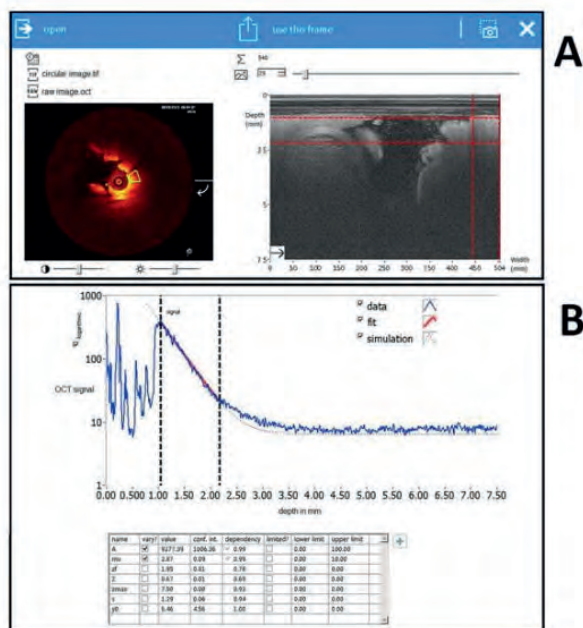
As a result, the  $\mu_{\text{OCT}}$  was potentially underestimated. To correct for this possible underestimation, additional software was developed in which the circular OCT images were directly coupled to the raw amplitude OCT data used, which was used for analysis. Secondly, the fitting algorithm was adapted to correct for the sensitivity roll-off and confocal point spread function.

A new  $\mu_{\text{OCT}}$  analysis with the new additional in-house software (LabVIEW 17.0) was performed. In the developed software, both circular scans and linear raw data were matched on a frame-to-frame basis (e.g. a single index of both multi-frame formats yields the same scan in circular and linear representation).

Using these improved definitions for sensitivity roll-off and confocal point spread, the  $\mu_{\text{OCT}}$  values are more accurate compared to the method described in chapters 4 and 5 and resulted in substantially higher  $\mu_{\text{OCT}}$  values for low-grade (median  $\mu_{\text{OCT}}$  3.3  $\text{mm}^{-1}$  (IQR 2.7 – 3.7  $\text{mm}^{-1}$ )) and high-grade UTUC (4.9  $\text{mm}^{-1}$  (IQR 4.3 – 6.1  $\text{mm}^{-1}$ )) ( $p=0.004$ ). Performing ROC

analysis for the  $\mu_{\text{OCT}}$  of low-grade versus high-grade UTUC yielded an AUC of 0.85 (95% CI 0.69 – 0.95,  $p < 0.001$ ), and a  $\mu_{\text{OCT}}$  value of  $>4.0 \text{ mm}^{-1}$  was identified as the optimal cut-off to discriminate high-grade from low-grade UTUC. This cut-off resulted in a sensitivity of 83% and a specificity of 94%.

Although this adjusted method to calculate  $\mu_{\text{OCT}}$  resulted in a new cut-off value of  $>4.0 \text{ mm}^{-1}$ , sensitivity and specificity remained compatible to the method used in chapters 4 and 5 of this thesis. Our adjusted method confirmed the ability of OCT to grade and stage low-, high-grade and CIS lesions in the upper urinary tract with a more accurate sensitivity and specificity.



**Figure 1:** screenshot of the in-house developed software for  $\mu\text{OCT}$  analysis; A) manual selection of the region of interest from the circular OCT scan (left panel) with coupled selection in the raw amplitude data of the linear scan (right panel); B) determining the  $\mu\text{OCT}$  by fitting a single-backscattering OCT model to the averaged A-scans of the selected region of interest (in between black stippled lines).(12)

OCT still needs comprehensive investigation before implementation in clinical practice. In order to know the real value of OCT, dedicated *in vivo* studies as described above should provide further insight in the ability of OCT to differentiate between low-, high-grade and CIS lesions. In addition, specific studies should confirm the diagnostic accuracy including sensitivity, specificity, positive predictive value and negative predictive value.<sup>(8)</sup> Finally, by comparing OCT with established pre-operative and intra-operative methods like CT-scan,

(selective) cytology and biopsies, the added value of OCT in clinical practice can be determined. Despite this lack of knowledge, there are several clinical applications conceivable, which are outlined below.

First of all, OCT might be of value in improving the quality of resection of urothelial tumours in the ureter. By evaluating the resection margins with OCT, one might be able to know if the resection is complete at time of the operation. Besides evaluating the lateral borders of the resection area, these techniques could also be of benefit in determining the depth of the resection. If OCT measurements of the base of a resection plane confirm urothelial carcinoma, one can complete the resection in depth, if technically possible. However, an initial study performed on ex-vivo human bladder urothelial biopsies showed that factors typical for ex-vivo settings (e.g. cauterization of bladder tissue specimens) on  $\mu_{\text{oct}}$ -based grading of human bladder cancer were inconclusive but indicative of the need for in-vivo evaluation.<sup>(14)</sup> More knowledge on the appearance of cauterized urothelium in OCT images is necessary and should be obtained in an in-vivo setting, as cauterization at resection margins might lead to problematic artefacts.<sup>(15)</sup>

Another possible implementation of OCT in a clinical setting could be OCT guided partial ureterectomy. Using OCT can help to precisely determine the tumour margin. This gives the urologist information of the tumour margin, making precise partial ureterectomy possible. In patients with low-grade, low-stage disease and a recurrence shown by OCT to be again low-grade, endoscopic laser fulguration and/or coagulation may be applied. One of the drawbacks of laser treatment is the fact that no specimen for pathology is obtained for definite diagnosis. The risk exists that progression has occurred without being noticed; therefore pathological confirmation of stage and grade is desirable. OCT can provide this confirmation and make laser fulguration a more safely and reliable mode of treatment. Additionally, it is a less invasive determination of disease grade and stage than biopsies.<sup>(15)</sup>

Another interesting future perspective is the merging of OCT with other optical diagnostics techniques like Narrow Band Imaging (NBI). NBI is an optical image enhancement technique designed for endoscopic applications, with demonstrated value in gastroenterology and urology.<sup>(16, 17)</sup> NBI takes advantage of altered blood vessel morphology of mucosa to enhance contrast between mucosa and microvascular structures. This technique is based on the principle that the depth of light penetration into the mucosa increases with increasing wavelength. By illuminating the tissue surface with specific wavelengths (blue 415 nm and green 540 nm), both increasingly absorbed by haemoglobin, the vascular structures appear dark brown/green against a pink/white mucosal background. This contrast enhancement can therefore result in improved tumour detection rates compared to white light endoscopy.<sup>(18)</sup> NBI could be combined with OCT, where NBI could be used first to visualize or target a suspected lesion and OCT could assist in epithelial lesion differentiation by addressing grade and stage as shown by several studies.<sup>(19-21)</sup>



Emerging techniques that enhance tumour visualisation with OCT can, therefore, potentially reduce unnecessary biopsies, without extra morbidity. This scenario is especially interesting for the case of cytology suspicious of high-grade malignancy and negative ureterorenoscopy findings, when so-called at-random biopsies are taken to exclude or confirm carcinoma in situ (CIS). OCT measurements via the working channel of the ureterorenoscope could be of value in the diagnosis of CIS, i.e. guiding the biopsy procedure by visualizing CIS lesions. Nowadays, CIS detection knows several challenges and OCT confirmation is limited by reliance on white light URS to identify the suspicious lesions. Combining NBI-URS with OCT can potentially overcome this limitation. As we demonstrated in this thesis, CIS can be recognized on OCT images as a thickened urothelial layer. However, there are more scenarios that can cause a thickened urothelial layer. To dilate the ureter, some patients receive a double J-catheter pre-operatively. This catheter can be irritating for the urothelial layer, causing oedema. This urothelial oedema might be seen as a thickened layer on OCT imaging and it is difficult to distinguish double J-catheter effect from CIS on OCT images. In addition, OCT is known for false-positives in inflammatory states as inflammation can cause a thickened urothelial layer, resembling UTUC lesions on OCT images.<sup>(22)</sup> For this reason, biopsies will remain, for now, necessary to confirm or exclude urothelial cancer in the upper urinary tract. At this moment, OCT has to be seen as a valuable addition to the diagnostic work-up in UTUC and not as a replacement for histology.

Finally, what is perhaps the most exciting possible feature of OCT is a combination of endoscopy, artificial intelligence (AI) with OCT. AI can be explained as a machine intelligence similar to natural intelligence displayed by humans, including cognitive functions as learning and problem solving. Deep learning (DL) is a method that autonomously learns features and tasks from a training dataset, for example medical images. Medical image-based diagnoses such as pathology radiology and endoscopy are expected in the very near future to be the first in the medical field using AI.<sup>(23)</sup> In gastroenterology this technique is already able to automatically detect cancer or other pathological endoscopic findings during endoscopy and is expected to be mainstream technology in the next few decades by helping endoscopists by providing a more accurate diagnosis by automatically detecting and classifying endoscopic lesions.<sup>(23, 24)</sup> This technique can be of great use in cystoscopy and ureterorenoscopy as well for detecting and classifying pathological findings. One of the most important factors for the development of DL is the availability of large amounts of high-quality endoscopic images for DL training dataset. In OCT imaging large volumes of clinical images are obtained, making it an excellent target for AI modalities.<sup>(25)</sup> AI using DL, based on endoscopic images combined with OCT datasets gives the urologist of the future optimal quantitative information of pathology in the urinary tract.

## Determining Diagnostic Accuracy

Further research needs to be conducted in order to evaluate the true value of the techniques in UTUC described in this thesis. Current available data are too preliminary to evaluate these new technologies and implement them into the diagnostic work-up of patients with UTUC. As UTUC is a rare disease, data are sparse and should be used wisely. In the future, well-conducted studies should start for the evaluation of diagnostic technologies in the upper urinary tract. Several groups have published guidelines on how to perform and report a study in order to assess diagnostic accuracy. As it involves the use of a medical device instead of a pharmacological product, the optimal way to proceed is following the IDEAL evaluation criteria, described by the Balliol collaboration.<sup>(26, 27)</sup> This evaluation equals surgical innovation to the different phases of the pharmacological research and consists of independent phases (1: Idea/Innovation, 2a: Development, 2b: Exploration, 3: Assessment, 4: Long-term Studies). To develop these technologies into a diagnostic test, results should be compared with the standard test at use. In the case of enhanced tumour visualization systems, the standard test is WL-URS (including biopsies), where techniques aiming for optical biopsy use histology as gold standard. The IDEAL methodology can be combined with the STARD statement. The STARD statement has been developed to improve the accuracy and completeness of reporting studies of diagnostic accuracy.<sup>(28)</sup> Before implementing a diagnostic technique in the diagnostic work-up of UTUC, clinical studies should provide a full diagnostic accuracy analysis according to the STARD recommendations, including sensitivity, specificity, positive predictive value and negative predictive value.

## Reference List

1. Roupret M, Babjuk M, Comperat E, Zigeuner R, Sylvester R, Burger M, et al. European guidelines on upper tract urothelial carcinomas: 2013 update. *EurUrol*. 2013;63(6):1059-71.
2. Ristau BT, Tomaszewski JJ, Ost MC. Upper tract urothelial carcinoma: current treatment and outcomes. *Urology*. 2012;79(4):749-56.
3. Al-Qahtani SM, Letendre J, Thomas A, Natalin R, Saussez T, Traxer O. Which ureteral access sheath is compatible with your flexible ureteroscope? *JEndourol*. 2014;28(3):286-90.
4. Tavora F, Fajardo DA, Lee TK, Lotan T, Miller JS, Miyamoto H, et al. Small endoscopic biopsies of the ureter and renal pelvis: pathologic pitfalls. *AmJSurgPathol*. 2009;33(10):1540-6.
5. Smith AK, Stephenson AJ, Lane BR, Larson BT, Thomas AA, Gong MC, et al. Inadequacy of biopsy for diagnosis of upper tract urothelial carcinoma: implications for conservative management. *Urology*. 2011;78(1):82-6.
6. Wang JK, Tollefson MK, Krambeck AE, Trost LW, Thompson RH. High rate of pathologic upgrading at nephroureterectomy for upper tract urothelial carcinoma. *Urology*. 2012;79(3):615-9.
7. Bus MT, de Bruin DM, Faber DJ, Kamphuis G, Zondervan P, Laguna P, et al. Optical diagnostics for Upper Urinary Tract Urothelial cancer: technology, thresholds and clinical applications. *JEndourol*. 2014.
8. Cauberg EC, de Bruin DM, Faber DJ, van Leeuwen TG, de la Rosette JJ, de Reijke TM. A new generation of optical diagnostics for bladder cancer: technology, diagnostic accuracy, and future applications. *EurUrol*. 2009;56(2):287-96.
9. Liu JJ, Droller MJ, Liao JC. New optical imaging technologies for bladder cancer: considerations and perspectives. *JUrol*. 2012;188(2):361-8.
10. Adams W, Wu K, Liu JJ, Hsiao ST, Jensen KC, Liao JC. Comparison of 2.6- and 1.4-mm imaging probes for confocal laser endomicroscopy of the urinary tract. *J Endourol*. 2011;25(6):917-21.
11. Ku JH, Lerner SP. Strategies to prevent progression of high-risk bladder cancer at initial diagnosis. *CurrOpinUrol*. 2012;22(5):405-14.
12. Freund JE, Faber DJ, Bus MT, van Leeuwen TG, de Bruin DM. Grading upper tract urothelial carcinoma with the attenuation coefficient of in-vivo optical coherence tomography. *Lasers Surg Med*. 2019.
13. Almasian M, Bosschaart N, van Leeuwen TG, Faber DJ. Validation of quantitative attenuation and backscattering coefficient measurements by optical coherence tomography in the concentration-dependent and multiple scattering regime. *J Biomed Opt*. 2015;20(12):121314.
14. Cauberg EC, de Bruin DM, Faber DJ, de Reijke TM, Visser M, de la Rosette JJ, et al. Quantitative measurement of attenuation coefficients of bladder biopsies using optical coherence tomography for grading urothelial carcinoma of the bladder. *J Biomed Opt*. 2010;15(6):066013.

15. Cauberg EC, de la Rosette JJ, de Reijke TM. How to improve the effectiveness of transurethral resection in nonmuscle invasive bladder cancer? *Curr Opin Urol*. 2009;19(5):504-10.
16. Inoue T, Murano M, Murano N, Kuramoto T, Kawakami K, Abe Y, et al. Comparative study of conventional colonoscopy and pan-colonic narrow-band imaging system in the detection of neoplastic colonic polyps: a randomized, controlled trial. *J Gastroenterol*. 2008;43(1):45-50.
17. Sharma P, Bansal A, Mathur S, Wani S, Cherian R, McGregor D, et al. The utility of a novel narrow band imaging endoscopy system in patients with Barrett's esophagus. *Gastrointest Endosc*. 2006;64(2):167-75.
18. Traxer O, Geavlete B, de Medina SG, Sibony M, Al-Qahtani SM. Narrow-band imaging digital flexible ureteroscopy in detection of upper urinary tract transitional-cell carcinoma: initial experience. *J Endourol*. 2011;25(1):19-23.
19. Bus MT, Muller BG, de Bruin DM, Faber DJ, Kamphuis GM, van Leeuwen TG, et al. Volumetric in vivo visualization of upper urinary tract tumors using optical coherence tomography: a pilot study. *J Urol*. 2013;190(6):2236-42.
20. Wessels R, de Bruin DM, Faber DJ, van Boven HH, Vincent AD, van Leeuwen TG, et al. Optical coherence tomography in vulvar intraepithelial neoplasia. *J Biomed Opt*. 2012;17(11):116022.
21. Barwari K, de Bruin DM, Faber DJ, van Leeuwen TG, de la Rosette JJ, Laguna MP. Differentiation between normal renal tissue and renal tumours using functional optical coherence tomography: a phase I in vivo human study. *BJU Int*. 2012;110(8 Pt B):E415-E20.
22. Goh AC, Tresser NJ, Shen SS, Lerner SP. Optical coherence tomography as an adjunct to white light cystoscopy for intravesical real-time imaging and staging of bladder cancer. *Urology*. 2008;72(1):133-7.
23. Min JK, Kwak MS, Cha JM. Overview of Deep Learning in Gastrointestinal Endoscopy. *Gut Liver*. 2019.
24. Yang YJ, Bang CS. Application of artificial intelligence in gastroenterology. *World J Gastroenterol*. 2019;25(14):1666-83.
25. Kapoor R, Whigham BT, Al-Aswad LA. Artificial Intelligence and Optical Coherence Tomography Imaging. *Asia Pac J Ophthalmol (Phila)*. 2019;8(2):187-94.
26. McCulloch P, Altman DG, Campbell WB, Flum DR, Glasziou P, Marshall JC, et al. No surgical innovation without evaluation: the IDEAL recommendations. *Lancet*. 2009;374(9695):1105-12.
27. McCulloch P. The IDEAL recommendations and urological innovation. *World J Urol*. 2011;29(3):331-6.
28. Bossuyt PM, Reitsma JB, Bruns DE, Gatsonis CA, Glasziou PP, Irwig LM, et al. Towards complete and accurate reporting of studies of diagnostic accuracy: the STARD initiative. *BMJ*. 2003;326(7379):41-4.



SUMMARY  
SAMENVATTING



## Summary

Technical improvements in the design of (flexible) ureterorenoscopes over the past years have resulted in improved visualization of upper urinary tract urothelial carcinoma (UTUC). For this reason, the attitude is radically changed towards treatment of patients with low risk UTUC and a healthy contralateral kidney by the acceptance of conservative treatment. Since conservative treatment is only considered safe in patients with low-volume, low-grade and non-invasive UTUC, treatment should be customized for each individual patient, based on tumour characteristics. Unfortunately, one of the main challenges is to obtain a reliable histopathological diagnosis assessing tumour grade and stage. Recent developments in optical diagnostics showed potential to improve the diagnostic work-up of UTUC. The applicability of urinary biomarkers and optical diagnostics in UTUC are increasingly debated. To receive insight in the opinion of the urological community involved in this field, a survey was sent to identify the most promising techniques and understand the need of new diagnostics in **Chapter 2**. Primary objectives of the survey were to provide an overview of current diagnostics in upper urinary tract urothelial carcinoma and to assess the need for additional diagnostic techniques in the current diagnostic work-up for UTUC and knowledge of novel techniques.

For this reason, an electronic survey was generated and distributed to all participants of the upper urinary tract tumour registration study by the Clinical Research Office of the Endourological Society and to experts in the field. Analysis was performed based on survey results. In total 81 of the 112 invited individuals responded resulting in a response rate of 72.3%. Of all responders, 61.4% consider current available diagnostics insufficient to select patients for conservative treatment of UTUC. Six optical techniques were evaluated. Four techniques aim to improve visualization of UTUC through contrast enhancement (Narrow Band Imaging (NBI), Photodynamic Diagnosis (PDD), IMAGE1 S™, and digital Retrograde Intrarenal Surgery (digital RIRS)). The other two techniques aim to provide real time information on tumour grade and stage (Optical Coherence Tomography (OCT) and Confocal Laser Endomicroscopy (CLE)). Of all evaluated diagnostic tools available today, techniques aiming to improve visualization of UTUC through contrast enhancement were best known among urologists, with in particular digital RIRS and NBI. Digital RIRS including NBI are likely to be beneficial according to the responders. Techniques aiming for real time information on tumour grade and stage were considerably less known among the participants.

To outline the potential for future applications of optical diagnostics, we systematically reviewed the literature in **Chapter 3** on five optical techniques: NBI, PDD, IMAGE1 S™, OCT and CLE. Literature was reviewed according to QUADAS and IDEAL standards. Only four articles were available for quality assessment. These articles demonstrated high level of evidence but low level of IDEAL stage.

NBI and IMAGE1 S™, enhance contrast of the mucosal surface and vascular structures, improving tumour detection rate. A first in-vivo study on NBI showed promising results. No studies on IMAGE1 S™, had been published so far. PDD uses fluorescence to improve tumour visualization. However, due to the acute angle of the ureterorenoscopes there is an increased risk of false-positives. OCT produces cross-sectional high-resolution images, providing information on tumour grade and stage. A pilot study showed promising diagnostic accuracy. CLE allows ultra-high resolution microscopy of tissue resulting in images of the cellular structure. CLE could not be applied in-vivo in the upper urinary tract yet, due to technical limitations. Before implementation of these techniques in the routine management of UTUC, more research has to be conducted.

In the second part of this thesis, we focused on the use of OCT in the upper urinary tract. OCT is the optical equivalent of ultrasonography, using back-scattered light instead of back-reflected sound waves to produce high-resolution, cross-sectional images in which layered tissue anatomy can be distinguished. Light scattering decreases the OCT signal magnitude with depth, and limits the imaging range to approximately 2 mm. This signal decrease is quantified by the attenuation coefficient ( $\mu_{\text{oct}}$  [ $\text{mm}^{-1}$ ]) that allows in-vivo differentiation between tissue types. During carcinogenesis, changes occur in cellular architecture resulting in an increased nuclear-cytoplasm ratio and increased amount of mitochondria. Physically, this sub-cellular organization of tissue determines light scattering properties. Therefore, we hypothesized that lesion stage is obtained from image-based assessment of lesions; and that lesion grade correlates with  $\mu_{\text{oct}}$ . In **Chapter 4** we did an in-vivo pilot study to assess the feasibility of OCT in UTUC. Eight consecutive patients underwent URS for UTUC suspicion or follow-up. OCT datasets were intra-operatively obtained from the ureter and pyelum. All patients eventually underwent nephroureterectomy. OCT staging was performed by visual inspection of lesions found on OCT images and OCT grading by quantification of the OCT signal attenuation on lesions and compared with histopathological diagnosis. Seven in-vivo OCT diagnoses on staging were in accordance with histology. In the eighth patient tumour thickness transcended OCT imaging depth range and was, therefore, inconclusive on tumour stage. For grading, median  $\mu_{\text{oct}}$  for grade 2 lesions was  $1.97 \text{ mm}^{-1}$  and  $3.52 \text{ mm}^{-1}$  for grade 3 ( $p$ -value  $<0.001$ ). Healthy urothelium was too thin to reliably determine  $\mu_{\text{oct}}$ . These study results warranted further research, to confirm in a larger sample size grading and staging accuracy of OCT. We, therefore, investigated OCT in UTUC in a larger patient population in **Chapter 5**. In total 26 patients underwent diagnostic URS including biopsies and OCT imaging, followed by nephroureterectomy. The ability of OCT to differentiate low-, and high-grade UTUC was assessed. Secondly, sensitivity, specificity, negative predictive value and positive predictive value of UTUC grading and staging by OCT were assessed.



In 83% staging of lesions was in accordance with histopathology. Sensitivity and specificity analysis for non-invasive and invasive tumours were 100% and 92%, respectively. Tumour size >2 mm and inflammation were risks for false-positives. For grading of low-, and high-grade lesions, median  $\mu_{\text{oct}}$  was 2.1 mm<sup>-1</sup> and 3.0 mm<sup>-1</sup> (p-value <0.01), respectively. ROC-analysis showed sensitivity of 87% and specificity of 90% using a cut-off value  $\mu_{\text{oct}}$  of 2.4 mm<sup>-1</sup>.

This study confirmed the ability of OCT to visualize, grade and stage lesions in the upper urinary tract. Although the studies described above showed high resolution cross-sectional images of the ureter using OCT, its imaging depth is limited to 1-2 mm. Tumour sizes that transcended the OCT imaging depth range resulted in false positives for tumour invasion. To overcome this important limitation, combining OCT with an imaging technique with an increased imaging depth range could be a solution. Therefore, we combined OCT with Endoluminal Ultrasound (ELUS) in **Chapter 6**. Endoluminal Ultrasound (ELUS) produces lower resolution images compared to OCT, but has increased imaging penetration depth. To enable co-registration of OCT and ELUS in human nephroureterectomy specimens, CT was used to obtain overall anatomy and exact probe localization. OCT and ELUS imaging catheters were introduced via the ureteral orifice up to the renal pelvis in five nephroureterectomy specimens and pulled back following each measurement. The OCT and ELUS systems scan a cylindrical trajectory of 54 mm by 10 mm and 890 mm by 10 mm, respectively. Visualization software (AMIRA®) was used for reconstruction and co-registration of CT, OCT and ELUS data from the complete renal pelvis and ureter. Co-registered OCT and ELUS datasets were compared with histology. 3D-CT enabled exact dataset fusion to compare histology with OCT and ELUS findings in this ex-vivo setting. In the high resolution OCT images of normal appearing renal pelvis and ureter, the urothelium, lamina propria and muscularis were clearly visible. OCT permits high-resolution imaging of normal ureter and ureter lesions whereas ELUS provides more depth information. However, in ELUS images of normal appearing ureter and anatomical layers could be distinguished, but the urothelial layer could not be identified. Using ELUS, images of suspected lesions were visible, although exact staging and differentiation between non-invasive and invasive lesions was not possible with ELUS due to low-resolution images. For this reason, ELUS was no beneficial addition to OCT in this ex-vivo setting.

In **chapter 7** a reflection is given on the work presented in this thesis. This thesis demonstrated that optical diagnostics have the potential to improve the diagnosis of upper urinary tract urothelial carcinoma (UTUC). However, optical diagnostics still need comprehensive investigation before implemented in clinical practice. In this chapter a plea is given to start well-conducted studies the further evaluation of diagnostic technologies in the upper urinary tract. In addition several potential clinical applications of optical diagnostics in the upper urinary tract are discussed.

## Samenvatting

Waar voorheen endoscopie alleen diende voor diagnostiek, hebben verbeteringen in beeldkwaliteit van (flexibele) ureterorenoscopen over de afgelopen jaren geresulteerd in verbeterde visualisatie van urotheelcarcinoom in de hoge urinewegen. Deze hoge beeldkwaliteit maakt het tegenwoordig mogelijk om patiënten met een laag-risico urotheelcarcinoom in de hoge urinewegen en een gezonde contralaterale nier, een niersparende behandeling aan te bieden. Omdat een niersparende behandeling alleen veilig kan worden uitgevoerd bij patiënten met een klein tumorvolume, laaggradig urotheelcarcinoom en niet-invasief urotheelcarcinoom, is adequate diagnostiek onontbeerlijk voor een juiste patiënten selectie. Deze selectie zal moeten plaats vinden op basis van deze tumorkarakteristieken. Tumorvolume kan bepaald worden met een ureterorenoscopie. Helaas is het lastig om tumorgraad en tumorstadium te bepalen en een betrouwbare histopathologische diagnose te stellen. Recente studies beogen ureterorenoscopie te verbeteren door middel van optische diagnostiek teneinde de diagnostiek van urotheelcarcinoom in de hoge urinewegen te verbeteren. Het toepassen van optische diagnostiek wordt in toenemende mate onderzocht. Om meer inzicht te krijgen in de behoefte aan nieuwe diagnostische middelen en de meest belovende techniek hielden we een enquête onder (endo)urologen in **Hoofdstuk 2**. Hoofddoel van deze enquête was om te bepalen of er behoefte was aan extra diagnostische technieken binnen de huidige diagnostische middelen voor patiënten met urotheelcarcinoom in de hoge urinewegen. Tevens wilden we de kennis van urologen over de huidige ontwikkelingen binnen diagnostische middelen bepalen en weten welke vorm van optische diagnostiek zij het meest belovend vonden.

Daarom hielden we een digitale enquête onder deelnemers van de hoge urineweg tumorregistratie studie van de Clinical Research Office of the Endourological Society en experts. Vervolgens werden de enquête resultaten geanalyseerd. In totaal reageerden 81 van de 112 genodigden wat resulteerde in een responspercentage van 72,3%. Van alle respondenten beschouwden 61,4% de huidige beschikbare diagnostische middelen als onvoldoende om een veilige patiëntselectie te maken voor niersparende behandeling van urotheelcarcinoom in de hoge urinewegen. Zes optische technieken werden geëvalueerd. Vier technieken claimen visualisatie van urotheelcarcinoom in de hoge urinewegen te verbeteren door contrast enhancement: "Narrow Band Imaging" (NBI), "Photodynamic Diagnosis" (PDD), "IMAGE1 S™" en "digital Retrograde Intrarenal Surgery" (digitale RIRS). De twee overige technieken stellen als doel real time informatie over de tumorgraad en het tumorstadium te geven; "Optical Coherence Tomography" (OCT) en "Confocal Laser Endomicroscopy" (CLE). Van de zes technieken die geëvalueerd werden, waren de technieken die verbetering van tumorvisualisatie geven door contrast enhancement het best bekend onder urologen. Met name digitale RIRS en NBI waren bekend onder de respondenten. Digitale RIRS in combinatie met NBI werden het meest geschikt geacht om bij te dragen aan een verbeterde

diagnostiek volgens de respondenten. De twee technieken die zich richtten op real time informatie over tumor karakteristieken waren een stuk minder bekend onder urologen.

Om de potentie van toekomstige applicatie van optische diagnostische methoden te bepalen voerden we een systematische review van de literatuur uit in **Hoofdstuk 3**. We bestudeerden de beschikbare literatuur van vijf optische technieken: NBI, PDD, IMAGE1 S™, OCT en CLE. De literatuur werd beoordeeld volgens de QUADAS en IDEAL standaard. Slechts vier artikelen waren beschikbaar voor kwaliteitsbeoordeling. Deze artikelen toonden alle een hoog niveau van bewijs maar een laag niveau volgens de IDEAL standaard.

NBI en IMAGE1 S™, verbeteren contrast van de mucosa en vaatstructuren om zo tumordetectie te optimaliseren. Een eerste in-vivo studie waarbij NBI onderzocht werd liet veelbelovende resultaten zien. Er waren op het moment van de literatuurstudie nog geen studies over IMAGE1 S™, gepubliceerd. PDD gebruikt fluorescentie om tumor visualisatie te optimaliseren. Doordat het licht uit de ureterorenoscoop tangentieel op het weefsel valt, is er een verhoogd risico op een vals positieve uitslag. OCT maakt hoog resolutie dwarsdoorsnede beelden en geeft hiermee informatie over tumor graad en tumor stadium. Een pilotstudie gaf eerste hoopvolle resultaten over de diagnostische accuratesse van OCT. CLE maakt ultrahoge resolutie microscopie van weefsel mogelijk wat resulteert in beelden van de cellulaire structuren. Door beperkingen van de huidige techniek wordt CLE nog niet in-vivo toegepast in de hoge urinewegen. Hoewel de besproken technieken hoopvol zijn moet er meer onderzoek verricht worden, voordat ze succesvol toegepast kunnen worden in de hoge urinewegen.

In het tweede deel van dit proefschrift richtten wij ons op het gebruik van OCT in de hoge urinewegen. OCT is het optische broertje van echografie, waarbij er in plaats van terugkaatsing van ultrageluid gebruik wordt gemaakt van lichtweerkaatsing. Door verschillen te detecteren tussen het uitgestraalde licht en het teruggekaatste licht, kunnen hoog resolutie beelden gemaakt worden, waarin verschillende onderliggende weefsellagen te onderscheiden zijn. Lichtverstrooiing geeft afname van het OCT signaal in de diepte en limiteert de afbeeldingsdiepte tot ongeveer 2mm. De verzwakking van het OCT signaal kan gekwantificeerd worden door de attenuatie coëfficiënt ( $\mu_{\text{oct}}$  [ $\text{mm}^{-1}$ ]).

Door gebruik te maken van deze attenuatie coëfficiënt kan er in-vivo onderscheid gemaakt worden tussen weefseltypen. Tijdens carcinogenese vinden er verschillende veranderingen plaats in de cellulaire architectuur. Dit resulteert onder andere in een toegenomen nucleus-cytoplasma ratio en toegenomen hoeveelheid mitochondriën. Deze samenstelling van de cellulaire organisatie bepaalt de lichtverstrooiingseigenschappen van het weefsel. Daarom stelden wij de hypothese op dat het tumorstadium bepaald kan worden op basis van beeldbeoordeling van tumoren en dat de tumorgradering correleert met  $\mu_{\text{oct}}$ .

In **Hoofdstuk 4** voerden wij een in-vivo pilotstudie uit om de haalbaarheid van OCT als diagnosticum voor urotheelcarcinoom in de hoge urinewegen vast te stellen. Acht opeenvolgende patiënten ondergingen een URS, omdat er bij hen een sterke verdenking op urotheelcarcinoom in de hoge urinewegen was of omdat zij onder controle waren na een eerder niersparend behandeld urotheelcarcinoom van de hoge urinewegen. OCT metingen werden peroperatief verricht van het pyelum en ureter. Alle patiënten ondergingen uiteindelijk een radicale nefroureterectomie. OCT stadiering werd gedaan door alle OCT beelden waarop een tumor zichtbaar was te inspecteren. OCT gradering werd gedaan door de OCT signaalverzwakking te kwantificeren. Bij zeven patiënten kwam tumorstadiering middels OCT overeen met de histologie. Bij de achtste patiënt was de tumor dikker dan 2mm waardoor deze de OCT afbeeldingsdiepte oversteeg. Daardoor werd deze patiënt als inconclusief beoordeeld voor wat betreft tumorstadiering.

Voor gradering was de mediane  $\mu_{\text{oct}}$  voor graad 2 tumoren  $1.97 \text{ mm}^{-1}$  en  $3.52 \text{ mm}^{-1}$  in graad 3 tumoren (p-waarde  $<0.001$ ). Gezond urotheel was te dun om betrouwbaar de  $\mu_{\text{oct}}$  te bepalen.

Aan de hand van deze studieresultaten werd een grotere studie opgezet om de accuratesse van tumorstadiering en tumorgradering van OCT te bevestigen. In **Hoofdstuk 5** onderzochten wij OCT in urotheelcarcinoom van de hoge urinewegen in een grotere studiepopulatie.

In deze studie ondergingen in totaal 26 patiënten URS inclusief biopten en OCT. Alle patiënten ondergingen vervolgens een radicale nefroureterectomy. De capaciteit van OCT om onderscheid te maken tussen laag- en hooggradig urotheelcarcinoom in de hoge urinewegen werd bepaald. Tevens berekenden we de sensitiviteit, specificiteit, negatieve voorspellende waarde en positief voorspellende waarden van het stageren en graderen van urotheelcarcinoom middels OCT.

In 83% kwam tumorstadiering overeen met histopathologie. Sensitiviteit en specificiteit analyse voor niet-invasieve tumoren en invasieve tumoren was respectievelijk 100% en 92%. Tumor grootte  $>2\text{mm}$  en ontsteking waren risico factoren voor vals positieven. Voor gradering van laag- en hooggradige tumoren was de mediane  $\mu_{\text{oct}}$  respectievelijk  $2.1 \text{ mm}^{-1}$  en  $3.0 \text{ mm}^{-1}$  (p-waarde  $<0.01$ ). ROC-analyse toonde een sensitiviteit van 87% en specificiteit van 90% bij een afkapwaarde van  $\mu_{\text{oct}} 2.4 \text{ mm}^{-1}$ . Deze studie bevestigde het vermogen van OCT om tumoren in de hoge urinewegen te visualiseren, te graderen en te stageren.

Hoewel de twee bovenstaande tumoren hoog resolutie dwarsdoorsnede OCT beelden van de ureter laten zien, is de afbeeldingsdiepte gelimiteerd tot 1-2mm. Tumordikte die deze afbeeldingsdiepte overstijgt resulteerde bij de bovenstaande studies in een vals positieve tumorinvasie. Om deze belangrijke beperking van OCT te overwinnen zou het combineren van OCT met een beeldvormende techniek met een hogere afbeeldingsdiepte een oplossing kunnen bieden. Daarom combineerden we OCT met Endoluminal Ultrasound (ELUS) in

**Hoofdstuk 6.** Endoluminal Ultrasound (ELUS) geeft lagere resolutie beelden vergeleken met OCT, maar heeft een toegenomen afbeeldingsdiepte. Om exacte co-registratie van OCT en ELUS in humane ex-vivo nefroureterectomie preparaten te kunnen verkrijgen, gebruikten we CT. Door middel van CT kon de gehele anatomie van de preparaten afgebeeld worden en de exacte locatie van de OCT en ELUS katheters bepaald worden. De OCT en ELUS katheters werden via het ureter ostium van het preparaat tot in het pyelum gebracht en na iedere meting terug getrokken. Zowel OCT als ELUS scant een cilindrisch traject van respectievelijk 54mm bij 10mm en 890mm bij 10mm. Visualisatie software (AMIRA®) werd gebruikt om de OCT, ELUS en CT data te reconstrueren en te co-registreren van het complete pyelum en ureter. Co-registratie van OCT en ELUS datasets werden vervolgens vergeleken met de histologie. 3D-CT maakte exacte OCT en ELUS data fusie mogelijk om deze vervolgens te vergelijken met de histologie van de preparaten. In de hoog resolutie OCT beelden van normaal ogend pyelum en ureter waren het urotheel, de lamina propria en muscularis propria duidelijk zichtbaar. Waar OCT hoog resolutie beelden gaf, gaf ELUS juist meer diepte informatie. In ELUS beelden van normaal ogend pyelum en ureter konden wel de anatomische lagen worden onderscheiden, maar kon het urotheel niet onderscheiden worden. In de ELUS beelden waren tumoren wel zichtbaar, maar door de lage resolutie beelden kon er geen onderscheid gemaakt worden tussen invasieve tumoren en niet-invasieve tumoren. Daarom concludeerden wij dat ELUS geen toegevoegde waarde geeft aan OCT in een ex-vivo studie opzet.

In **hoofdstuk 7** wordt het werk gepresenteerd in dit proefschrift besproken. Dit proefschrift laat zien dat optische diagnostiek potentie heeft om de diagnose te verbeteren van urothelcarcinoom in de hoge urinewegen. Desondanks moet er nog wel uitvoerig onderzoek gedaan worden naar deze technieken voordat zij geïmplementeerd kunnen worden in de kliniek. In dit hoofdstuk pleiten wij dan ook voor het starten van goed opgezette studies om optische diagnostiek verder te evalueren, zodat optische diagnostiek in de toekomst succesvol toegepast kan worden. Tenslotte worden verschillende potentiële klinische toepassingen van optische diagnostiek in de hoge urinewegen besproken.





LIST OF PUBLICATIONS  
PORTFOLIO  
DANKWOORD  
CURRICULUM VITAE







## List of Publications

Grading upper tract urothelial carcinoma with the attenuation coefficient of in-vivo optical coherence tomography

Freund JE, Faber DJ, **Bus MT**, van Leeuwen TG, de Bruin DM

*Lasers Surg Med.* 2019 Mar 28. [Epub ahead of print]

Ex-vivo study in nephroureterectomy specimens defining the role of 3-D upper urinary tract visualization using optical coherence tomography and endoluminal ultrasound

**Bus MT**, Cernohorsky P, de Bruin DM, Meijer SL, Streekstra GJ, Faber DJ, Kamphuis GM, Zondervan PJ, van Herk M, Laguna Pes MP, Grundeken MJ, Brandt MJ, de Reijke TM, de la Rosette JJ, van Leeuwen TG.

*J Med Imaging (Bellingham).* 2018 Jan;5(1):017001.

Fluorescence in situ hybridization as prognostic predictor of tumor recurrence during treatment with Bacillus Calmette-Guérin therapy for intermediate- and high risk non-muscle invasive bladder cancer

Liem EIML, Baard J, Cauberg ECC, **Bus MT**, de Bruin DM, Laguna Pes MP, de la Rosette JJMCH, de Reijke TM

*Med Oncol (2017)*34:172

Current position of diagnostics and surgical treatment for upper urinary tract urothelial carcinoma

**Bus MT**, de Bruin DM, Kamphuis GM, Zondervan PJ, Laguna Pes MP, de Reijke TM, van Leeuwen TG, de la Rosette JJ

*Minerva Urol Nefrol.* 2017 Apr;69(2):159-165.

Optical coherence tomography as a tool for in vivo staging and grading of upper urinary tract urothelial carcinoma: a study of diagnostic accuracy

**Bus MT**, de Bruin DM, Faber DJ, Kamphuis GM, Zondervan PJ, Laguna Pes MP, de Reijke ThM, Traxer O, van Leeuwen TG, de la Rosette JJ

*J Urol* 196(6), 1749-1755

Prostate Cancer Diagnosis: the Feasibility of Needle-Based Optical Coherence Tomography

Muller BG, de Bruin DM, van den Bos W, Brandt M, Velu J, **Bus MT**, Faber DJ, Savci CD, Zondervan PJ, de Reijke ThM, Laguna Pes MP, de la Rosette JJ, van Leeuwen TG

*J.Med.Imag.* 2(3),037501 (jul 09,2015).

Beyond Endoscopy-Ultrasound, Optical Coherence Tomography and Confocal Laser Endomicroscopy

**Bus MT**, de Bruin DM, Kamphuis GM, Zondervan PJ, Laguna Pes MP, de Reijke ThM, de la Rosette JJ.

*Chapter 12 of Textbook of Upper Urinary Tract Urothelial Carcinoma*

*Editors: Grasso M, Bagley D. Published by Springer Science + Business Media*

*ISBN 978-3-319-13869-5*

Ontwikkelingen bij de diagnose, behandeling en follow-up van urotheelcelcarcinoom in de hoge urinewegen

**Bus MT**, Kamphuis GM, Zondervan PJ, Laguna Pes MP, de la Rosette JJ, de Reijke TM

*Ned Tijdschr Geneeskd. 2014;158(0):A7347*

Optical diagnostics for Upper Urinary Tract Urothelial Cancer: technology, thresholds and clinical applications.

**Bus MT**, de Bruin DM, Faber DJ, Kamphuis GM, Zondervan PJ, Laguna-Pes MP, de Reijke TM, Traxer O, van Leeuwen TG, de la Rosette JJMCH.

*Journal of endourology 29 (2), 113-123*

Optical Coherence Tomography in Bladder Carcinoma

**Bus MT**, de Bruin DM, de Reijke TM, de la Rosette JJ

*Chapter 3 of Advances in Image-Guided Urologic Surgery*

*Editors: Liao JC, Su L-M. Published 2015 by Springer Science+Business Media*

*ISBN 978-1-4939-1449-4*

Very-low-calorie diet increases myocardial triglyceride content and decreases diastolic left ventricular function in type 2 diabetes with cardiac complications

Jonker JT, Djaberi R, van Schinkel LD, Hammer S, **Bus MT**, Kerpershoek G, Kharagjitsing AV, Romijn JA, Bax JJ, Jukema JW, de Roos A, Smit JW, Lamb HJ

*Diabetes Care. 2014 Jan;37(1):e1-2*

Volumetric in vivo visualization of upper urinary tract tumors using optical coherence tomography: a pilot study

**Bus MT**, Muller BG, de Bruin DM, Faber DJ, Kamphuis GM, van Leeuwen TG, de Reijke TM, de la Rosette JJ

*J Urol. 2013 Dec;190(6):2236-42*

Is photodynamic diagnosis ready for introduction in urological clinical practice?

Cordeiro ER, Anastasiadis A, **Bus MT**, Alivizatos G, de la Rosette JJ, de Reijke TM

*Expert Rev Anticancer Ther.* 2013 Jun;13(6):669-80

Urothelial carcinoma in both adnexa following perforation during transurethral resection of a non-muscle-invasive bladder tumor: a case report and literature review

**Bus MT**, Cordeiro ER, Anastasiadis A, Klioueva NM, de la Rosette JJ, de Reijke TM

*Expert Rev Anticancer Ther.* 2012 Dec;12(12):1529-36

Follow-up procedures for non-muscle-invasive bladder cancer: an update

Anastasiadis A, Cordeiro E, **Bus MT**, Alivizatos G, de la Rosette JJ, de Reijke TM

*Expert Rev Anticancer Ther.* 2012 Sep;12(9):1229-41

Myocardial metabolic flexibility in complicated type 2 diabetes

Jonker JT, Tjeerdema N, **Bus MT**, Lamb HJ, Kharagjitsingh AV, de Roos A, Romijn JA, Smit JW.

*Diabetes* 2011 Jul;(60)A142-A143

Cardiac autonomic neuropathy in patients with diabetes and no symptoms of coronary artery disease: comparison of <sup>123</sup>I-metaiodobenzylguanidine myocardial scintigraphy and heart rate variability

Scholte AJ, Schuijf JD, Delgado V, Kok JA, **Bus MT**, Maan AC, Stokkel MP, Kharagjitsingh AV, Dibbets-Schneider P, van der Wall EE, Bax JJ

*Eur J Nucl Med Mol Imaging.* 2010 Aug;37(9):1698-705



## PhD Portfolio

<i>Name</i>	Mieke TJ Bus
<i>PhD period</i>	January 2012-2019
<i>PhD Supervisors</i>	Prof. A.G.J.M. van Leeuwen, PhD Dr. Th.M. de Reijke, MD PhD Dr. D.M. de Bruin, PhD

## PhD Training

### *Courses*

2012	BROK (basiscursus regelgeving klinisch onderzoek)
2012	Clinical Epidemiology
2012	Systematic Reviews
2013	Scientific Writing in English for publication

### *Conferences & Presentations*

2012	SEOHS, Amsterdam Poster presentation "3D OCT van ureter en pyelum – humane ex vivo studie"
2013	EAU Congress, Milaan Poster presentation "In vivo optical coherence tomography for the evaluation of upper urinary tract urothelial carcinoma: initial results from a pilot study"
2013	6 <sup>th</sup> International symposium on focal therapy and imaging on prostate and kidney cancer, Noordwijk Poster presentation "In vivo optical coherence tomography for the evaluation of upper urinary tract urothelial carcinoma: initial results from a pilot study"
2013	Voorjaarsvergadering NvU, Zwolle Oral presentation "In Vivo optische coherentie tomografie voor evaluatie van urotheelcarcinoom in de hoge urinewegen"
2013	World congress of Endourology, New Orleans Poster presentation "Volumetric In-Vivo Visualization of Upper Urinary Tract Tumors using Optical Coherence Tomography: A Pilot Study"
2013	Najaarsvergadering NvU, Nieuwegein Oral presentation "3D optische coherentie tomografie en endoluminale echo van ureter en pyelum – een humane ex vivo studie"

2014	EAU congress, Stockholm Poster presentation “ Optical coherence tomography as a tool for in vivo staging and grading of upper urinary tract urothelial carcinoma” Poster presentation “ From Gleason score to changes in scattering: Optical Coherence Tomography in Prostate Cancer – a prospective human ex-vivo study.
2014	World congress of Endourology, Taipei Poster presentation “Optical Coherence Tomography as a tool for in vivo staging and grading of upper urinary tract urothelial cell carcinoma: comparison with biopsies and histopathology of the resected specimen”
2014	ESUI, Lissabon Oral presentation “Optical Coherence Tomography in Upper Urinary Tract Urothelial Carcinoma”.
2016	ESUI, Milaan Oral presentation “OCT and CLE in the upper urinary tract – Final real time histology?”

*Other activities*

2012	APROVE Board membership
2013	APROVE Board chair
2014	APROVE board membership
2014	Faculty Member ESUI 2014
2016	Faculty Member ESUI 2016

**Teaching**

<i>Lecturing</i>	Klinische les poli Chirurgie/Urologie
<i>Tutoring, Mentoring</i>	E. Kotelnikova L.M. Wierstra

**Parameters of Esteem**

Grants	Stichting Urologie 1973
Awards	Best Paper Award WCE congress 2014

## Dankwoord

Dit proefschrift is het resultaat van samenwerking. Graag wil ik iedereen die heeft bijgedragen bedanken.

Allereerst de patiënten die hebben deelgenomen aan onze studies. Zonder jullie belangeloze medewerking was dit proefschrift niet tot stand gekomen. Ik ben jullie zeer dankbaar voor het in mij gestelde vertrouwen.

Martijn. Ik ben trots en dankbaar dat onze samenwerking dit resultaat tot stand heeft gebracht en ik hoop dat er nog vele mooie studies zullen volgen. Dankjewel voor al je vertrouwen, steun en vriendschap. Eva ik wil ook jou bedanken, ik weet hoe vaak je Martijn hebt moet missen thuis omdat we weer tegen een deadline aanzaten.

Beste professor van Leeuwen. Dank dat ik in roerige tijden alle ruimte op uw afdeling kreeg en u het onbegrijpelijke begrijpelijk weet te maken voor mij, altijd met aanstekelijk enthousiasme.

Dr. de Reijke. Het was niet altijd even makkelijk om kliniek met onderzoek te combineren, maar u opende de deur naar de urologie voor mij en dankzij u kan ik mijn toekomst binnen de urologie vervolgen.

Geachte leden van de promotiecommissie. Ik ben jullie dankbaar voor de tijd en moeite die jullie in het beoordelen van mijn proefschrift steken en het voor het plaatsnemen in mijn promotiecommissie.

Alle mede-auteurs dank voor jullie bijdragen aan onze studies. Ik ben jullie zeer erkentelijk voor al jullie behulpzaamheid, zelfs op de gekste uren als het echt niet uitkwam stonden jullie mij bij bij de CT scanner of het doormeten van een preparaat. Dank voor alle kritische noten die ik op mijn stukken heb mogen ontvangen. Ik had dit niet zonder jullie kunnen doen.

Onderzoekers van G4 voor, tijdens en na mijn onderzoeksperiode. Dank voor de samenwerking met jullie. Berrend jij in het bijzonder. Ik denk dat promoveren een zelfde prestatie is als drie jaar in een kleine kamer met mij doorbrengen. Chapeau.

OCT onderzoekers dank voor al het sparren tijdens onze meetings.

Carla, ik kan je niet genoeg bedanken voor alle hulp bij de afronding van dit proefschrift.



Urologen en arts-assistenten urologie van het AMC, dank voor alle belangstelling en fijne samenwerking tijdens mijn onderzoeksperiode. Ik kijk er naar uit jullie weer tegen te komen binnen de urologie. In het bijzonder wil ik Lara bedanken voor alle ondersteuning tijdens de hematurie poli.

Sonja, Laura, Martine, Alice en Annemarie. Bedankt voor de eeuwig durende koffiepauzes en de interesse in mijn werk en mijn leven buiten het ziekenhuis. Jullie hebben drie jaar AMC tot een feestje gemaakt.

Annelies, zonder jou was de vrijdag niet compleet. Dankjewel voor drie jaar fantastisch samenwerken. Ik mis het nog steeds.

Geert en Ashana, dank voor jullie hulp aan mij op OK. Martin, dank voor al je hulp en interesse als ik weer eens het OCT apparaat van de cardiologie kwam lenen.

APROVE zonder jullie had ik mijn horizon in het AMC niet zo kunnen verbreden. Ik heb genoten van al onze acties, maar bovenal heb ik genoten van jullie.

Chirurgen en assistenten chirurgie van het Flevoziekenhuis. Dank jullie dat ik mijn opleiding bij jullie mocht beginnen. Ik ben jullie zeer erkentelijk voor de fijne start die ik bij jullie heb gemaakt.

Urologen en arts-assistenten urologie van het OLVG. Ik ging iedere dag dat ik werkte in het OLVG met zin naar mijn werk omdat ik wist dat jullie er waren. Dank voor alle interesse en plezier.

Urologen en arts-assistenten urologie van Amsterdam UMC, locatie VUMC. Dank dat ik mijn opleiding bij jullie voort kan zetten en de ruimte die ik bij jullie krijg om mijn promotie tot een goed einde te brengen.

Jose, seventeen years ago we met in Germany and I could not foresee that we would be in touch after all those years. You, Laura and Abril have a place in my heart. I am very honored that you designed the cover for me. Muchas gracias amigo.

Lieve vriendjes en vriendinnetjes. Dank jullie wel voor alle belangstelling die jullie hadden in mijn onderzoek maar bovenal voor alle afleiding als het weer eens tegen zat. Ik ben blij jullie in mijn leven te hebben.

Paranimfen. Lieve Olivia en Rutger. Dank dat jullie er voor mij zijn. Ik ga met vertrouwen mijn verdediging tegemoet met jullie aan mijn zijde, omdat ik weet dat jullie dit boek van A tot Z kennen.

Annette, Francis, Catherine, Mariette, Guillaume, Simon, Nina en Camille, wat zijn jullie een fijne en lieve schoonfamilie. Dank voor al jullie belangstelling.

Marnix wat heerlijk om met jou de liefde voor de gezondheidszorg te kunnen delen. Marloes, mijn excuses daar voor. Robbert dank dat je al jaren zo lief voor mijn zusje bent. Myriam jij maakt de M brigade compleet, wat fijn dat je er bij bent. Het is altijd genieten met jullie allemaal aan tafel.

Lieve Papa en Mama. Dank voor jullie oneindige belangstelling en vertrouwen in dit proefschrift. Jullie motiveerden me wanneer het nodig was en lieten het onderwerp rusten als ik daar om vroeg. Ik draag met liefde dit proefschrift aan jullie op.

Max. Ineens was je daar weer en daar ben ik oneindig dankbaar voor. Ik kijk uit naar de toekomst samen met jou en Mathilde. Jullie zijn mijn thuis.



## Curriculum Vitae

Mieke Theodora Jenneke Bus was born at the 18<sup>th</sup> of april 1985 in Brummen. In 2003 she graduated from secondary school at the Baudartius College in Zutphen. That same year she went on to study Biomedical Sciences at the University of Leiden. After receiving her Bachelor Degree, Mieke started her medical training in 2008. During her medical training she was involved in several research projects.

Mieke received her medical degree Cum Laude in 2011 after elective internships in the intensive care unit and urology. In 2012 she started her PhD training at the Department of Urology and the Department of Biomedical Engineering & Physics under the supervision of professor A.G.J.M. van Leeuwen, dr. Th. M. de Reijke and dr. D.M. de Bruin. She studied the application of optical diagnostics, within particular optical coherence tomography, in the upper urinary tract resulting in this thesis. For the study presented in chapter 5 of this thesis, she was granted with the Best Paper award of the World Congress of Endourology 2014.

During her PhD she was member and chair of the board of APROVE, the PhD association of the AMC and she participated in the hematuria clinic and cystoscopy clinic. In 2014 and 2016 Mieke was an invited faculty member of the 3<sup>rd</sup> and 5<sup>th</sup> Annual Meeting of the EAU Section of Urological Imaging (ESUI).

In January 2015 she started her residency in urology by a two year training in general surgery in the Flevoziekenhuis in Almere, under the supervision of dr. P.C.M. Verbeek. She continues her urology residency in the region of Amsterdam. She is especially interested in stone treatment and treatment of upper urinary tract urothelial carcinoma and continues reseach in order to optimise care for patients with upper urinary tract tumours.











