



UvA-DARE (Digital Academic Repository)

Surgery and medical therapy in Crohn's disease

Improving treatment strategies

de Groof, E.J.

Publication date

2017

Document Version

Other version

License

Other

[Link to publication](#)

Citation for published version (APA):

de Groof, E. J. (2017). *Surgery and medical therapy in Crohn's disease: Improving treatment strategies*. [Thesis, fully internal, Universiteit van Amsterdam].

General rights

It is not permitted to download or to forward/distribute the text or part of it without the consent of the author(s) and/or copyright holder(s), other than for strictly personal, individual use, unless the work is under an open content license (like Creative Commons).

Disclaimer/Complaints regulations

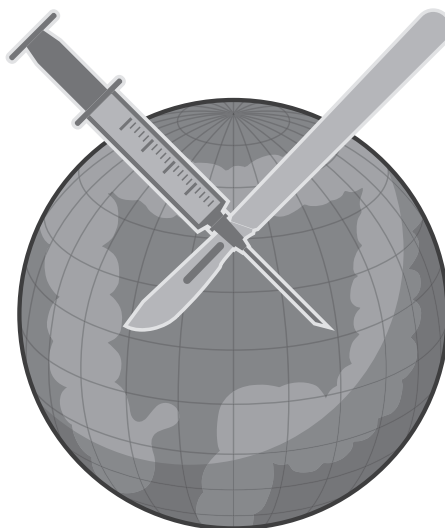
If you believe that digital publication of certain material infringes any of your rights or (privacy) interests, please let the Library know, stating your reasons. In case of a legitimate complaint, the Library will make the material inaccessible and/or remove it from the website. Please Ask the Library: <https://uba.uva.nl/en/contact>, or a letter to: Library of the University of Amsterdam, Secretariat, Singel 425, 1012 WP Amsterdam, The Netherlands. You will be contacted as soon as possible.

10

Systematic review of evidence and consensus on perianal fistulas; an analysis of national and international guidelines

E.J. de Groof, V.N. Cabral, C.J. Buskens, D.G. Morton, D. Hahnloser, W.A. Bemelman

Colorectal disease. April 2016.



Abstract

Aim

Treatment of perianal fistula has evolved with the introduction of new techniques and biologicals in Crohn's disease (CD). Several guidelines are available worldwide, but many recommendations are controversial or lack high-quality evidence. The aim of this work was to provide an overview of the current available national and international guidelines for perianal fistula and to analyse areas of consensus and areas of conflicting recommendations, thereby identifying topics and questions for future research.

Method

MEDLINE, EMBASE and PubMed were systematically searched for guidelines on perianal fistula. Inclusion was limited to papers in English less than 10 years old. The included topics were classified as having consensus (unanimous recommendations in at least two-thirds of the guidelines) or controversy (fewer than three guidelines commenting on the topic or no consensus) between guidelines. The highest level of evidence was scored as sufficient (level 3a or higher of the Oxford Centre for Evidence-based Medicine Levels of Evidence 2009), or insufficient.

Results

Twelve guidelines were included and topics with recommendations were compared. Overall, consensus was present in 15 topics, whereas six topics were rated as controversial. Evidence levels varied from strong to lack of evidence.

Conclusion

Evidence on the diagnosis and treatment of perianal fistulae (cryptoglandular or related to CD) ranged from nonexistent to strong, regardless of consensus. The most relevant research questions were identified and proposed as topics for future research.

Introduction

Perianal fistula is common. It can originate from infection of a cryptoglandular gland.¹ Other aetiologies include Crohn's disease (CD), malignancy, radiation, trauma or foreign body. Management requires the availability of specialist imaging and a detailed understanding of perianal anatomy and pathology, especially for complex fistulae. Treatment of fistula associated with CD has changed since the introduction of biologicals, with a reduced tendency towards surgery. New surgical techniques have been introduced, such as the ligation of the intersphincteric fistula track (LIFT) procedure.²

Many guidelines have been published with recommendations on diagnosis and surgical and medical management of cryptoglandular and Crohn's perianal fistula, but many of these are controversial or lack high-quality evidence. Some of the controversies can be explained by the persistence of guidelines that have become outdated because new medical and surgical therapies have since been introduced.

The aim of this study was systematically to review all the available international guidelines on perianal fistula and to provide an overview of the consensus and strength of the evidence for their recommendations for diagnosis and treatment. In addition, topics and questions for future research were sought.

Methods

A systematic search of the literature on national and international guidelines for perianal fistula was performed by two independent researchers (E.J.de G. and V.N.C.). The final search was performed on 22 August 2014 and updated on 30 September 2015. The following databases were searched: MEDLINE, EMBASE and PubMed.

Search terms

The MeSH terms and free text used in various forms and combinations were assembled with a medical librarian. The terms used were 'rectal fistula' or 'perianal fistula' or 'anal fistula' or 'Crohn's disease' and 'guideline' or 'consensus'. Details are provided in the Appendix.

Selection and data extraction

The reviewers separately screened the retrieved hits on titles and abstracts, and then discussed them together. In the event of disagreement, a third reviewer (C.J.B.) was involved. Guidelines on perianal fistula were considered for inclusion. Papers for inclusion were limited to those in English and less than 10 years old. Furthermore, guidelines alone based on evidence or grades of recommendation were considered for inclusion. The two reviewers independently extracted data from the included studies.

Consensus and levels of evidence

All topics discussed in the guidelines and followed by recommendations were included. They varied from diagnosis to surgical and medical therapy and the guideline recommendations were compared and classified as consensus or controversy. Consensus was defined as a topic discussed by at least two-thirds of the guidelines that achieved similar recommendations. Controversy was defined as a topic discussed by fewer than three guidelines or if there was no consensus. For each topic, the highest level of evidence available in the guidelines was determined and classified as sufficient if defined by a level of evidence 3a or higher according to the Oxford Centre for Evidence-based Medicine Levels of Evidence 2009 (<http://www.cebm.net/oxford-centre-evidence-based-medicine-levels-evidence-march-2009/>), or insufficient if defined by any lower level (Tables 1 and 2). If the recommendations were not reported in the format of the Oxford Centre for Evidence-based Medicine Levels of Evidence 2009 we manually re-assigned the level of evidence according to this system as shown in Tables 1 and 2. The topics of interest for future research were discussed in a plenary session during the 9th European Society of Coloproctology (ESCP) meeting held in Barcelona in 2014.

Table 1: Levels of evidence for studies on aetiology, prevention and therapy. From: Oxford Centre of Evidence-Based Medicine levels of Evidence 2009.

Levels of evidence	Description for studies on aetiology, prevention and therapy
1a	Systematic Review (with homogeneity) of Randomised Controlled Trials
1b	Individual Randomised Controlled Trial (with narrow confidence interval)
2a	Systematic Review (with homogeneity) of cohort studies
2b	Individual cohort study (including low-quality Randomised Controlled Trials)
3a	Systematic review (with homogeneity) of case-control studies
3b	Individual case-control studies
4	Case series (and poor quality cohort and case-control studies)
5	Expert opinion without explicit critical appraisal or based on physiology, bench research or "first" principles

Table 2: Levels of evidence for studies on diagnostics. From: Oxford Centre of Evidence-Based Medicine levels of Evidence 2009.

Levels of evidence	Description for studies on diagnostics
1a	Systematic Review (with homogeneity) of Level 1 diagnostic studies; or a clinical decision rule with 1b studies from different clinical centres.
1b	Validating cohort study with good reference standards; or clinical decision rule tested within one clinical centre
2a	Systematic Review (with homogeneity) of level > 2 diagnostic studies
2b	Exploratory cohort study with good reference standards; clinical decision rule after derivation
3a	Systematic review (with homogeneity) of case-control studies
3b	Non-consecutive study; or without consistently applied reference standards
4	Case-control study, poor or non-independent reference standard
5	Expert opinion without explicit critical appraisal or based on physiology, bench research or “first” principles

Results

Search

After the removal of duplicates the initial search identified 384 studies (Fig. 1). Titles and abstracts were then screened, after which 79 potentially eligible publications remained. After assessment of these full text publications, 12 studies were included in the review.³⁻¹⁴ One guideline was excluded because it was published over 10 years previously and 9 were excluded as they were not in English. None of the other excluded guidelines contained any recommendations or levels of evidence.

Included guidelines

Of the twelve guidelines included, nine were specifically on Crohn’s anal fistula, one on cryptoglandular fistula and two on both forms of fistula. The guidelines included were those published by the British Society of Gastroenterology (BSG), the Association of Coloproctology of Great Britain and Ireland (ACPGBI), the Canadian Association of Gastroenterology (CAG), the Brazilian Study Group of Inflammatory Bowel Diseases (BSGIBD), the Danish Society of Gastroenterology (DSG), the European Crohn’s and Colitis Organisation – Special Situations (ECCO), the Italian Society of Gastroenterology (SIGE), the German S3 guideline: cryptoglandular anal fistulas (CAF), the American College of Gastroenterology (ACG), the American Society of Colon and Rectal Surgeons (ASCRS), the Japanese Society of Gastroenterology (JSG) and the Shanghai Working Group (SWG) (Table 3).³⁻¹⁴

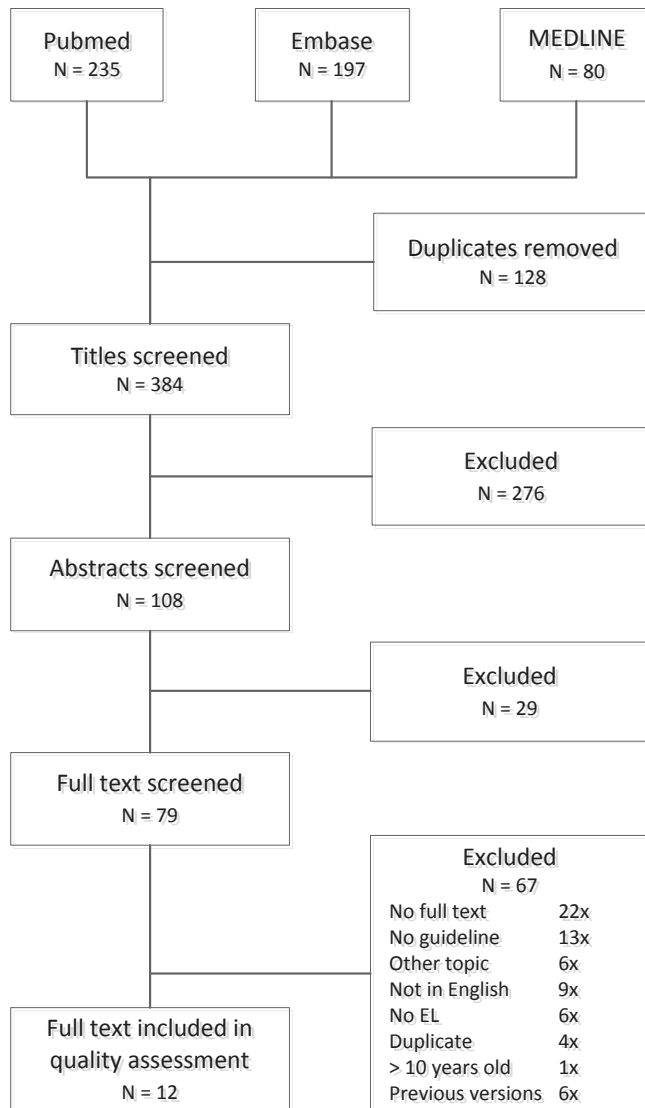


Figure 1: Flowchart of the systematic search and inclusion of guidelines.

Overall, consensus was reached in 15 topics. The comparative findings from the included guidelines are summarized in Table 4.

Table 3: overview of included guidelines.

Guideline	Year	Previous versions	Crohn's fistulas	Cryptoglandular fistulas
BSG [3] <i>British Society of Gastroenterology</i>	2004	-	Yes	No
ACPGBI [4] <i>Association of Coloproctology of Great Britain and Ireland</i>	2007	-	Yes	Yes
CAG [5] <i>Canadian Association of Gastroenterology</i>	2009	2001, 2004	Yes	No
BSGIBD [6] <i>Brazilian Study Group of Inflammatory Bowel Diseases</i>	2010	-	Yes	No
DSG [7] <i>Danish Society of Gastroenterology</i>	2010	-	Yes	No
ECCO [8] <i>Crohn's and Colitis Organisation – Special Situations</i>	2010	2006	Yes	No
SIGE [9] <i>Italian Society of Gastroenterology</i>	2010	-	Yes	No
CAF [10] <i>German S3 guideline: Cryptoglandular anal fistula</i>	2011	-	No	Yes
ACG [11] <i>American College of Gastroenterology - London Position Statement on Biological Therapy</i>	2011	-	Yes	No
ASCRS [12] <i>American Society of Colon and Rectal Surgeons</i>	2011	1996, 1997, 2005	Yes	Yes
JSG [14] <i>Japanese Society of Gastroenterology</i>	2012	2010	Yes	No
SWG [13] <i>Shanghai Working group: World Gastroenterology Organization, International Organisation for Inflammatory Bowel Diseases IOIBD, European Society of Coloproctology and Robarts Clinical Trials</i>	2014	-	Yes	No

Statements

Diagnostics

Magnetic resonance imaging

Of the included guidelines, seven advocated MRI for the assessment of perianal Crohn's and cryptoglandular fistula. The ASCRS guideline strongly recommended the use of MRI. The ACPGIBI and the ECCO guidelines were more specific, stating that MRI should be considered in all complex (including recurrent) fistulae. For a simple fistula MRI was not considered to be routinely necessary. Similar recommendations were given in the SIGE and BSGIBD guidelines. The SWG considered MRI to be the gold standard of imaging for perianal fistula in CD. Four guidelines stated that endoscopy, MRI, anorectal ultrasound and examination under anaesthesia (EUA) should be combined to increase the diagnostic accuracy to determine the best treatment strategy.

Conclusion: The use of MRI for diagnosing and mapping of perianal fistula is recommended. Consensus, highest level of evidence 1a.¹⁵⁻¹⁷

Anorectal ultrasound

The use of anorectal ultrasound was discussed in seven guidelines. The ACPGIBI stated that this technique may be the first-line investigation for patients with a recurrent fistula or one suspected to be complex. The accuracy of anorectal ultrasound was highly dependent on the expertise of the examiner, according to the ECCO, SIGE and CAF guidelines.

Conclusion: Anorectal ultrasound requires expertise of the examiner, but can be an accurate procedure to determine the anatomical pathology of perianal fistula. Consensus, highest level of evidence 1a.¹⁸⁻²¹

Examination under anaesthesia

EUA was mentioned and recommended in seven guidelines. Some (ECCO and SIGE) considered it to be the gold standard when performed by an experienced colorectal surgeon. The ECCO and SWG guidelines stated that in patients with an anorectal abscess drainage was the priority. Accordingly EUA should precede imaging by MRI or anorectal ultrasound unless these can be performed without delay. The ACPGIBI, CAF and ASCRS guidelines considered digital examination to be a useful tool, but none mentioned that this should be conducted under anaesthesia.

Conclusion: Examination under anaesthesia has an important role in the diagnosis and classification of perianal fistula. Consensus, highest level of evidence 1b.^{17, 19}

Endoscopy

Only three (ECCO, SIGE and SWG) guidelines on Crohn's perianal fistula included endoscopy. All stated that rectoscopy should be performed at the initial evaluation since proctitis is of crucial importance for the choice of therapy. In some case endoscopy may demonstrate the internal opening of a fistula.

Conclusion: Endoscopic assessment of the rectosigmoid should be performed in patients with Crohn's perianal fistula to determine the presence or absence of proctitis which will influence management. Consensus, highest level of evidence 2b.²²⁻²⁵

Computed tomography

Three guidelines (ACPGBI, ASCRS and SWG) included a statement on CT. The ACPGBI guideline recommended its use where MRI is not available or contraindicated. The ASCRS guideline recommended CT in patients with complex anorectal suppuration or in CD, but the SWG guideline stated that the visualization of perianal anatomy was poor. CT required administration of oral and/or rectal contrast and patients are exposed to radiation. CT for perianal fistula now appears to be regarded as obsolete.

Conclusion: CT for diagnosing perianal fistula is inferior to MRI and anorectal ultrasound. No consensus, highest level of 2b.^{26, 27}

Fistulography

None of the five guidelines (ACPGBI, ECCO, SIGE, ASCRS, SWG) that commented on fistulography recommended its use. Some of the guidelines specifically stated that fistulography should not be recommended, whereas others only mentioned that it has a very limited role in the assessment of perianal fistula.

Conclusion: Fistulography has a no role in the standard assessment of perianal fistula. Consensus, highest level of evidence 2b.²⁶⁻²⁸

Classification

The classification of perianal fistula was described in four of the twelve guidelines. Despite some variation, most mentioned two classification systems, including those described by Parks and the American Gastroenterology Association (AGA). Parks' classification defines four types of perianal fistula according to the relationship of the

primary fistula track to the anal sphincter complex.²⁹ A classification distinguishing between simple and complex fistula was proposed by the AGA, although there was no clear definition of these. The ECCO guideline stated that Parks' classification is superior for surgical decision taking.

Conclusion: There is no consensus which classification system should be used. No consensus, highest level of evidence 3b.^{25, 29}

Conclusion: There is no clear definition of simple and complex fistula. No consensus, highest level of evidence 3b.^{25, 29}

Surgery

Simple drainage of an abscess with no evidence of simultaneous fistula formation may result in healing in about half of cases. In those with a concurrent fistula track, the aim of drainage in patients with acute abscess is drainage and prevention of recurrent abscess formation by the insertion of a seton.

In patients with a persisting perianal fistula after resolution of the acute phase, the management of cryptoglandular and CD-related fistula is different. In each case cure of the fistula has to be balanced with the preservation of faecal continence. In CD the ultimate goal is to improve quality of life and to avoid a stoma and proctectomy. Several surgical techniques are available for the treatment of perianal fistula, depending on its characteristics.

Fistulotomy

Fistulotomy was mentioned by eight guidelines and all stated it to be effective. In cryptoglandular fistula, fistulotomy is the most common surgical technique (CAF guideline), but there were some discrepancies regarding its indications. According to the DSG, ECCO, SIGE and ASCRS guidelines, only symptomatic simple perianal fistulae should be treated by fistulotomy. Furthermore, the ACPGBI and SWG guidelines only recommended fistulotomy for superficial or low fistulae (without proctitis in patients with CD). In contrast, the ASCRS guideline stated that complex fistulae may be treated by staged fistulotomy provided that this is carefully considered, since there is an increased risk of incontinence, especially in female patients with an anterior fistula. The ACPGBI guideline also mentions a high incontinence rate after fistulotomy of more complex perianal fistulae with a high internal opening. Fistulectomy was addressed in some guidelines. The BSG recommended the use of fistulectomy for persistent or complex fistulae in CD

combined with medical therapy. The SIGE guideline stated that fistulectomy should not be performed because of the risk of incontinence.

Conclusion: There is an important role for fistulotomy in the treatment of perianal fistula. Consensus, highest level of evidence 1b.³⁰

Conclusion: Fistulotomy should in general not be used in high perianal fistulae. Consensus, highest level of evidence 3a.³⁰⁻³²

Cutting seton

There were four guidelines commenting on the cutting seton. Only the ACPGBI guideline recommended its use for transsphincteric fistulae. Because this technique is associated with a high risk of incontinence it was strongly advised against by the CAF guideline.³³

Conclusion: The use of the cutting seton is not advised because of the risk of incontinence. No consensus, highest level of evidence 2a.^{34, 35}

Loose seton

In cryptoglandular disease setons are mostly reported as a temporary measure, whereas in CD they may be a first step in any form of treatment, medically or surgically. In CD the seton can also be used as a chronic therapy. The use of a loose seton for some cryptoglandular or CD fistulae was advised in all but the CAG guideline. For CD, it was recommended as a first step before medical or definitive surgery. In patients with a more complex fistula it is often necessary to leave the seton in place as maintenance therapy (ECCO and ASCRS guideline). The optimal timing of removal of the seton is, however, unknown. For a simple fistula in CD, the ECCO recommended seton insertion only for a symptomatic fistula, whereas the SIGE guideline stated that all simple fistulae should be treated with placement of a loose seton or fistulotomy.

Conclusion: Loose seton placement is an effective treatment reducing the chance of recurrent abscess formation. Consensus, highest level of evidence 2a.³⁵⁻³⁹

Conclusion: Chronic loose seton drainage is an important alternative treatment for complex perianal fistula. Consensus, highest level of evidence 2a.^{36, 39}

Some surgeons advise a loose seton before surgery aiming at cure. No consensus, highest level of evidence 2a.³⁸

Conclusion: The combination of a loose seton with medical therapy is helpful in CD. Consensus, highest level of evidence 3b.³⁸

Rectal advancement flap

Six guidelines included a statement on treatment by a rectal advancement flap and all stated that this technique may be used for the treatment of more complex Crohn's or cryptoglandular fistulae. In Crohn's perianal fistula, concomitant medical therapy with an immunosuppressant was advised (BSG and ECCO guideline).

Conclusion: Advancement flap repair of cryptoglandular and Crohn's fistula is a technique that is often used for closure of the fistula. Consensus, highest level of evidence 1b.⁴⁰⁻⁴⁴

Fibrin glue

Six guidelines stated that the injection of fibrin glue down the primary track can be used in Crohn's and cryptoglandular perianal fistula. Several guidelines mentioned that this technique should still be evaluated by controlled studies. There were some discrepancies regarding the specific indication for fibrin glue treatment. The ACPGBI and the ASCRS guidelines stated that both simple and complex fistulae can be treated with fibrin glue injection, while the DSG and CAF stated that it should be utilised only for complex fistulae.

Conclusion: There is a place for fibrin glue in the treatment of complex perianal fistulae, although the efficiency remains unclear. Consensus, highest level of evidence 1b.^{37, 45, 46}

Conclusion: It is unclear which patients should receive this treatment. Consensus, highest level of evidence 1b.^{37, 45, 46}

Fistula plug

Five guidelines included a fistula plug. Although they stated that further research is required, a fistula plug may be used for definite fistula repair for Crohn's and cryptoglandular fistula. The ECCO guideline stated that a fistula plug can be used in CD. The healing rate in the long term might be improved if used in combination with infliximab.

Conclusion: Fistula plugs are a valid option for treating perianal fistula. Consensus, highest level of evidence 1b.⁴⁷⁻⁴⁹

Ligation of the intersphincteric fistula track

LIFT is a new technique and was mentioned in only three (CAF, ASCRS and SWG) guidelines, two of which included a level of evidence. All three stated that it may be an option for complex fistula, but that the data were too preliminary to draw conclusions.

Conclusion: The LIFT procedure is an option for the treatment of perianal fistula in selected patients. No consensus, highest level of evidence 4.^{50, 51}

Stoma

Creation of a defunctioning stoma was mentioned in eight guidelines, and all agreed that, depending on the severity and complexity of anorectal CD, a stoma may be required since this can rapidly restore quality of life and sometimes lead to remission on its own. A stoma should be reserved for exceptional cases. Unfortunately, intestinal continuity is often not restored, and eventually many patients with a stoma will require a proctectomy during the course of their disease.

Conclusion: The creation of a defunctioning stoma is an option for patients with severe perianal fistulising disease and may often be followed by a proctectomy. Consensus, highest level of evidence 2b.^{25, 52-54}

Proctectomy

Despite optimal medical and surgical treatment for anorectal CD some patients may eventually require a proctectomy. All five guidelines that commented on proctectomy stated that this may be necessary in patients with severe perianal fistulising disease, but this should be considered as a last resort.

Conclusion: A proctectomy is a last resort in patients with severe fistulising anorectal CD that is refractive to therapy. Consensus, highest level of evidence 2b.^{25, 55}

Medical therapy

The administration of medical therapy for a Crohn's perianal fistula aims at the reduction of symptoms and eventually closure, with improvement in quality of life. Prevention of recurrent abscess formation is of crucial importance for the patient. There are several medical treatment options. Symptom alleviation may be achieved with medical therapy, but definitive closure of perianal fistulae is rare, and unfortunately overall recurrence rates are high.

Antibacterial agents

Antibacterial agents such as nitroimidazoles (metronidazole and tinidazole) and antibiotics including ciprofloxacin are widely used in perianal fistula. All seven guidelines

commenting on antibacterial agents recommended their use, but there were some discrepancies in their indications. Some guidelines stated that antibacterial drugs are more suited as first-line treatment for simple fistulae, whereas others recommended them as a second-line treatment or for more complex fistulae. The combination of antibacterial agents with immunomodulators and/or biologicals for Crohn's perianal fistula was also recommended by several guidelines.

Conclusion: Antibacterial agents are effective in the treatment of perianal fistulae in CD. Consensus, highest level of evidence 1b.⁵⁶⁻⁵⁹

Conclusion: It is unclear whether antibacterial agents should be used as first-line or second-line treatment in both simple and complex fistulae. No consensus, highest level of evidence 1b.⁵⁶⁻⁵⁹

Immunomodulators

Seven guidelines mentioned the use of immunomodulators such as azathioprine and 6-mercaptopurine and were unanimous in recommending their use for Crohn's perianal fistula. The guidelines showed discrepancies in their indications. Some stated that immunomodulators were potentially effective in simple perianal fistula, whereas others indicated that they should be used in complex fistula as a second-line treatment. The ECCO and DSG guidelines indicated that immunomodulators should be used in combination with surgery, since when given alone they are rarely able to control the fistula.

Conclusion: Immunomodulators are recommended in the medical management of perianal Crohn's fistula, but recent evidence is conflicting with respect to efficacy. Consensus, highest level of evidence 1a.^{58, 60-62}

Conclusion: The specific indications for immunomodulators are unclear. No consensus, highest level of evidence 1a.^{58, 60-62}

Biologicals

Ten guidelines provided a statement regarding anti-tumour necrosis factor (TNF) therapy, mainly for infliximab (n = 10) and adalimumab (n = 8). All were in favour of biologicals as induction or maintenance therapy for a complex Crohn's perianal fistula. Combination therapy with biologicals and immunomodulators seemed to be more effective than monotherapy.

Conclusion: Infliximab is recommended for patients with fistulating CD. Consensus, highest level of evidence 1a.^{63, 64}

Conclusion: In patients with fistulating CD who respond to induction therapy with infliximab, maintenance therapy is effective in maintaining fistula closure or other response. Consensus, highest level of evidence 1a.^{64, 65}

Conclusion: Administration of adalimumab is recommended for patients with fistulising CD. Consensus, highest level of evidence 1a.^{64, 66}

Conclusion: In patients with fistulating CD who responded to induction therapy with adalimumab, maintenance therapy is effective. Consensus, highest level of evidence 1a.^{64, 66}

Cyclosporine

Cyclosporine for perianal fistula in CD was only mentioned by two guidelines, and both stated that the evidence for this treatment option was limited.

Conclusion: The role of cyclosporine for treating Crohn's perianal fistula is limited. No consensus, highest level of evidence 1b.⁶⁷⁻⁶⁹

Tacrolimus

Tacrolimus has been used extensively in patients undergoing organ transplantation. It has subsequently been demonstrated to improve the outcome of inflammatory bowel disease (IBD) in patients having a liver transplant for primary sclerosing cholangitis (PSC). Of three guidelines which mentioned tacrolimus for Crohn's perianal fistula, two stated that it can be effective in treating active Crohn's fistula.

Conclusion: Tacrolimus may be effective for Crohn's perianal fistula. No consensus, highest level of evidence 1b.⁷⁰

Table 4. Overview of the evidence levels as reported in the guidelines per topic.

		Included guidelines											
BSG	ACPGBI	CAG	BSGIBD	DSG	ECCO	SIGE	CAF	ACG	ASCRS	JSG	SWG		
2004	2007	2009	2010	2010	2010	2010	2011	2011	2011	2012	2014		
<i>Imaging</i>													
MRI	1b [17,75,76]	-	-	2b [17,19]	2b [17,23]	2b [18,77]	1a [15]	-	1b [15-17,75]	-	3a [23,76]		
Anorectal ultrasound	3 [16-18]	-	-	2b [17,19]	2b [17,78]	2b [71,78,79]	1a [18,20]	-	2b [15-17,75]	-	1b [19,21]		
Examination under anaesthesia	2a [17,76]	-	-	2b [17,19]	5 [17,23]	5 [23,77]	-	-	1b [17]	-	1b [19]		
Endoscopy	-	-	-	-	2b [23,24]	2b [NR]	-	-	-	-	2b [22,25]		
CT-scanning	3 [76,80]	-	-	-	-	-	-	-	3b [80,81]	-	2b [26,27]		
Fistulography	3 [26,27]	-	-	-	3 [23,24]	3 [NR]	-	-	2b [26-28]	-	2b [26,27]		
<i>Classification</i>													
Classification system	3 [29]	-	-	-	-	5 [25,29]	4 [29,82]	-	-	-	3b [29]		
<i>Surgical therapy</i>													
Fistulotomy	4 [62,63,65,83]	1b [30-32]	-	3b [83,84]	3b [85]	3 [NR]	2b [34,86,87]	-	2b [88,89]	-	4 [31]		
Cutting seton	3 [34,35]	-	-	-	-	-	2a [34,35]	-	-	-	-		
Loose seton	4 [83]	3 [36,39,90]	-	4 [36,91]	3 [38,92]	3 [19,36,38,92]	2a [34,36]	4 [38,92]	2b [35,37]	4 [62]	2b [38,39]		
Advancement flap	4 [83]	4 [93]	-	-	-	4 [NR]	1b [40-42,44]	-	2b [41,42,45,94]	-	2a [43]		

Table 4. Overview of the evidence levels as reported in the guidelines per topic. (continued)

Included guidelines												
	BSG	ACPGBI	CAG	BSGIBD	DSG	ECCO	SIGE	CAF	ACG	ASCRS	JSG	SWG
	2004	2007	2009	2010	2010	2010	2010	2011	2011	2011	2012	2014
Fibrin glue	-	3 [95]	-	-	2b [37]	5 [NR]	-	1b [37,45,96]	-	2b [46,97,98]	-	2b [37,98-100]
Fistula plug	-	-	-	-	2b [47,101,102]	5 [NR]	-	1b [47-49]	-	2b [47-49]	-	2b [48,101]
LIFT procedure	-	-	-	-	-	-	-	5 [NR]	-	-	-	4 [50,51]
Ostomy creation	-	4 [52]	-	-	-	5 [NR]	5 [NR]	5 [NR]	-	2b [25,52]	5 [NR]	2b [25,52-54]
Proctectomy	-	-	-	-	-	5 [NR]	5 [NR]	-	-	2b [25,55]	-	2b [25]
<i>Medical therapy</i>												
Antibiotics	2a [62,63,65]	-	-	-	3b [59,103-105]	4 [59,103,104]	3 [59,103]	-	1b [59,106]	-	1 [NR]	1b [56,57,59,106]
Immunomodulators for Crohn's fistulas	1a [62,63,65]	-	-	-	3b [58]	4 [58,107]	4 [61]	-	-	-	1 [58,61]	1b [58,60,61]
Biologicals for Crohn's fistulas	1b [62,63,65]	1b [63,65,78]	1b [63]	1b [106,108]	1a [63,64]	1b [63,65,66,109]	1b [63]	-	1b [65,109]	-	2 [65,109,110]	1 [63,65,66,111]
Cyclosporine for Crohn's perianal fistulas	-	-	-	-	-	-	-	-	-	-	-	4 [67-69]
Tacrolimus for Crohn's perianal fistulas	-	-	-	-	-	-	1b [70]	-	-	-	-	2b [70,74]

Topics with consensus and high-quality evidence

Diagnosis

For imaging the guidelines strongly advised the use of MRI, with accuracy rates of more than 90%. Anorectal ultrasound may also be used, with accuracy rates similar to MRI (56–100%), especially when hydrogen peroxide was injected into the external opening, but the quality of imaging depended on the expertise of the examiner.^{17, 71} EUA played an important role in diagnosis and assessment, which influenced the nature of surgery. Combining imaging modalities increased diagnostic accuracy. Colonoscopy was advised in the initial evaluation of CD patients. Fistulography was traditionally the imaging technique of choice, but with an accuracy of less than 20% this technique was not favoured.²⁶

Surgery

Fistulotomy was advised for low perianal fistula, but should be avoided in complex (high) perianal fistula due to the risk of incontinence. The use of a cutting seton was strongly advised against, since it was associated with a high risk (57%) of incontinence.³³ In contrast, insertion of a loose seton was recommended by all the guidelines, in combination with medical therapy in CD or as maintenance treatment in case of a complex cryptoglandular fistula. Most of the guidelines stated that an advancement flap may be used for the treatment of a complex fistula, with reported closure rates of approximately 80% and 60% in patients with cryptoglandular fistula and CD, respectively.⁴³ Fibrin glue and a fistula plug were also considered to be useful for a complex perianal fistula, although the guidelines stated that further research was required.

Medical treatment

Antibiotics are considered to be effective in the treatment of perianal fistula and septic complications in CD. Combining antibiotics with immunomodulators and/or biologicals for Crohn's perianal fistula was also recommended by most guidelines. A recent randomised placebo-controlled trial evaluated the effect of adding ciprofloxacin to adalimumab treatment for Crohn's perianal fistula. Combination therapy proved to be more effective in achieving closure ($P = 0.047$).⁵⁶ The effect disappeared with the discontinuation of antibiotic therapy at week 24. A recent published meta-analysis combining the three above-mentioned studies revealed that ciprofloxacin was effective in achieving remission in patients with Crohn's perianal fistula (pooled relative risk = 1.66; 95% CI 1.16–2.39; $P = 0.006$).⁷² Immunomodulators are recommended in the medical management of perianal

CD, but there are no comparative studies and indirect evidence is derived from secondary endpoints in clinical trials. Most of the guidelines considered the administration of biologicals to be helpful in patients with (complex) CD. Although several randomised controlled trials (RCTs) showed that induction and maintenance therapy with biologicals is effective in patients with Crohn’s perianal fistula, efficacy is limited. Unfortunately, there was no statement on when anti-TNF medication can be stopped. The literature shows that 50% of fistulae reopened after cessation of medication after a median period of 3 months.⁷³ An overview of the topics with consensus is presented in Fig. 2.

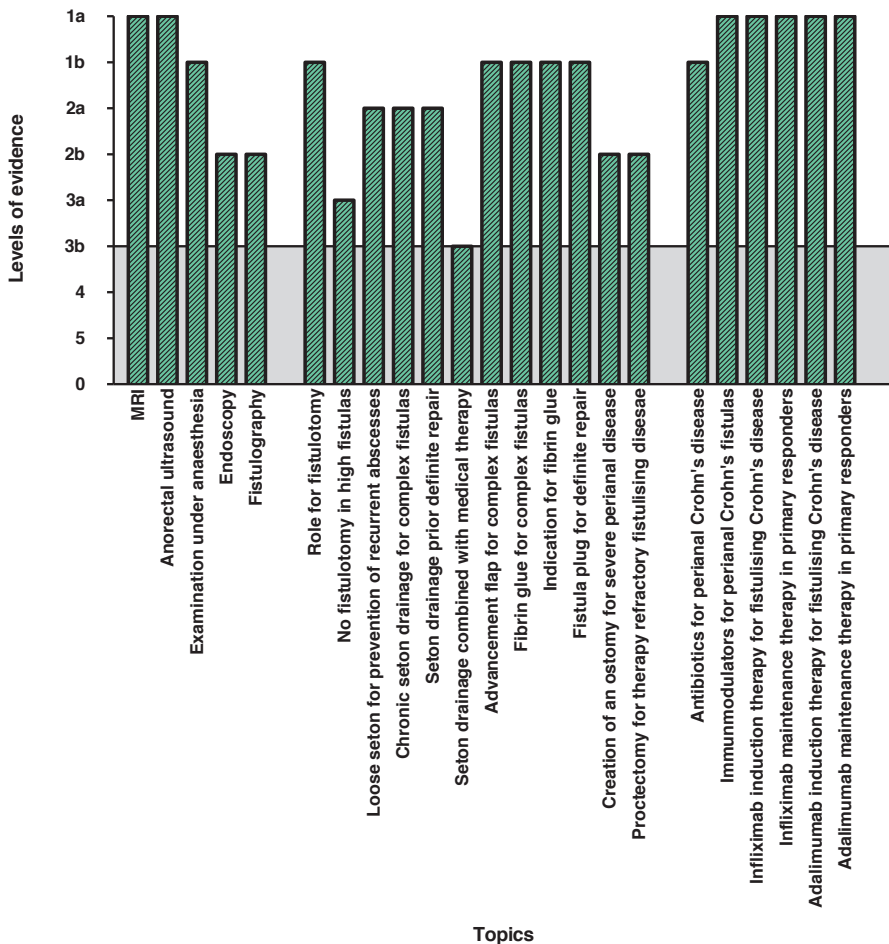


Figure 2: Topics on diagnostics, surgical and medical treatment for perianal fistulas with consensus. Consensus was defined as unanimous recommendations in two third of the guidelines commenting on included topics. An evidence level of 3a or higher according to the Oxford level of evidence 2009 was considered sufficient.

Topics with consensus without high-quality evidence

Stoma

Creation of a defunctioning stoma is an option in patients with severe perianal fistulising disease, but it should be reserved for exceptional cases. Unfortunately, intestinal continuity is often not subsequently restored.

Proctectomy

Some patients with a stoma will require a proctectomy during the course of their disease, but this procedure should be considered as a last resort. An overview of the topics with consensus is presented in Fig. 2.

Topics without consensus

Computed tomography

The use of CT is considered helpful in some situations, for example when MRI is not available or when it is contraindicated. There are, however, some disadvantages of CT since it requires administration of oral and/or rectal contrast and patients are exposed to radiation. In addition, visualization of perianal anatomy is poor, and for these reasons CT is regarded as obsolete for the visualization of perianal fistula.

Classification

Most of the guidelines mentioned two classification systems including that of Parks and the American Gastroenterological Association (AGA). But there was no consensus on which system should be used. There was no clear definition of simple and complex fistula mentioned in the AGA guidelines.

Loose seton placement prior to definite repair

Insertion of a loose seton prior to definite surgical repair was not frequently mentioned, but in CD draining of all fistula tracks including the branches was regarded as an important first step.

Ligation of intersphincteric fistula track

The LIFT procedure is a new technique for the surgical management of transsphincteric fistula, and for this reason only two of the guidelines included a statement on this technique. LIFT can be an effective treatment for perianal fistulising disease in selected patients.

Specific Indication for antibiotics

It is unclear whether antibiotics should be used as a first- or second-line treatment in both simple and complex fistulae, but in the absence of scientific evidence metronidazole and ciprofloxacin are widely used in the treatment of patients with perianal fistula.

Specific Indications for immunomodulators

It is unclear in which specific cases immunomodulators should be used. Some guidelines stated that immunomodulators are potentially effective in simple Crohn's fistula, whereas others indicated that it should be used in complex fistula as a second-line medical treatment.

Cyclosporine

The role of cyclosporine in Crohn's fistula is limited. Only a few uncontrolled case studies reported a rapid response to cyclosporine, but in these any response was rapidly lost after cessation of medication.⁶⁷⁻⁶⁹

Tacrolimus

Tacrolimus may be effective for Crohn's perianal fistula, but only two guidelines mentioned this medication. A RCT was performed comparing tacrolimus with placebo and revealed a favourable effect on the improvement of symptoms, but there was no significant difference in remission at 4 weeks.⁷⁰ Another study assessing topical tacrolimus revealed no significant benefit.⁷⁴ An overview of the topics without consensus is presented in Fig. 3.

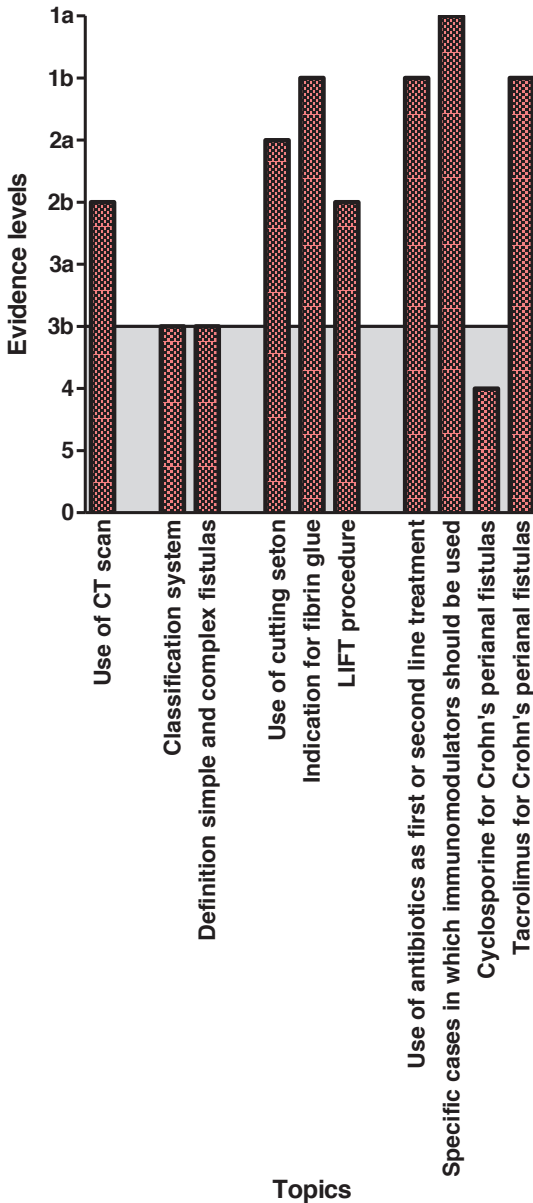


Figure 3: Topics on diagnostics, surgical and medical treatment for perianal fistulas without consensus (controversy). Controversy was defined as less than 3 guidelines commenting on a topic or no consensus between the guidelines on included topics. An evidence level of 3a or higher according to the Oxford level of Evidence 2009 was considered sufficient.

Discussion

In this review an overview of the current available national and international guidelines for perianal fistulae is provided to analyse areas of consensual and conflicting recommendations.

Overall, consensus was found in most topics. When there was failure to achieve consensus this was due to the fact that fewer than three guidelines commented on the specific topic. Some guidelines may have mentioned a topic but did not include any statement on level of evidence or recommendation.

All 12 of the included guidelines either used levels of evidence or grades of recommendation. Most topics had sufficient (level 3a or above) supporting evidence, but in the review process there were some difficulties regarding the actual level. Although there are several classifications of the quality of assessment of the literature, the assignment of a level of evidence is subjective, leading to variation in interpretation. First, the two reviewers did not always agree on the assigned level of evidence, and in this situation we simply reported the level of evidence stated in the guidelines. For example, the reported level of evidence on the use of tacrolimus was 1b, but this was based on one randomised controlled trial of only 48 patients. Secondly, when a level of evidence was assigned to a statement in the guidelines the relevant literature was often lacking. Some guidelines referred to other guidelines to find the evidence, which raised the question of what the evidence level of the guideline was. Other inconsistencies between guidelines and evidence levels were the result of when the guideline was published. Science is evolving, and newly published evidence and the development of surgical techniques and medical treatment need to be regularly updated. Multidisciplinary management of patients with Crohn's perianal fistula is of crucial importance to improve the outcome, but most guidelines deal with surgery and medical treatment separately. The SWG guideline was the most extensive in reviewing diagnosis as well as surgery and medical therapy.

Currently there are several ongoing trials mainly addressing the treatment options for perianal fistula. Several RCTs are being conducted for the treatment of cryptoglandular fistula. These include a study of the effect of adding stem cells to fibrin glue (NCT01803347) and of injection of platelet-rich plasma (PRP) into the fistula track combined with advancement flap for recurrent cryptoglandular fistula (NCT01615302). There are, furthermore, two ongoing trials comparing advancement flap with collagen plug insertion (NCT01021774) or LIFT (NCT01997645) for complex cryptoglandular

fistula. For complex Crohn's perianal fistula, there is a trial comparing adipose tissue-derived stem cells with a placebo (NCT01541579). Another trial comparing chronic seton drainage, anti-TNF therapy or an advancement flap for Crohn's fistula has recently been initiated (NTR4137) with the primary endpoint of the proportion of fistula-related interventions over time.

Topics for further research

Suggested topics for future research were discussed in a plenary session at the 9th ESCP annual meeting after presentation of the results of the present review (Table 5). It was agreed that a classification should be generally adopted, with no present consensus on whether Parks' classification or the more clinical subdivision of simple and complex fistula should be used, although there is no agreed definition of the terms 'simple' and 'complex'. There should be a surgical algorithm of the treatment options for the various types of fistula. The surgical and medical options used alone or in combination should be compared in patients with a Crohn's fistula. In the case of Crohn's fistula there is no guideline on when a seton should be removed after anti-TNF treatment and there is no recommendation on when anti-TNF treatment should be stopped. Evidence on the diagnosis and treatment of perianal fistula varies from strong to nonexistent. There was consensus among the guidelines on most topics, but there were several important areas with contradicting recommendations.

Table 5: Topics for further research.

Topic	Question
<i>Classification</i>	Definition of a simple or complex fistula (both in cryptoglandular and Crohn's)
	Classification system to be used in cryptoglandular fistulas
<i>Surgical treatment</i>	Surgical treatment algorithm with respect to the available options
	Timing of seton removal
<i>Medical therapy</i>	When to stop anti-TNF therapy in patients with Crohn's perianal fistulas
<i>Surgical versus medical treatment</i>	Surgical versus medical versus combination options in the treatment of Crohn's fistulas

References

1. Parks AG. Pathogenesis and treatment of fistula-in-ano. *Br Med J* 1961; 1: 463–9.
2. Bleier JI, Moloo H, Goldberg SM. Ligation of the intersphincteric fistula tract: an effective new technique for complex fistulas. *Dis Colon Rectum* 2010; 53: 43–6.
3. Carter MJ, Lobo AJ, Travis SP. Guidelines for the management of inflammatory bowel disease in adults. *Gut* 2004; 53(Suppl 5): V1–16.
4. Williams JG, Farrands PA, Williams AB et al. The treatment of anal fistula: ACPGBI position statement. *Colorectal Dis* 2007; 9(Suppl 4): 18–50.
5. Sadowski DC, Bernstein CN, Bitton A et al. Canadian Association of Gastroenterology clinical practice guidelines: the use of tumour necrosis factor-alpha antagonist therapy in Crohn's disease. *Can J Gastroenterol* 2009; 23: 185–202.
6. Brazilian Study Group of Inflammatory Bowel Diseases. Consensus guidelines for the management of inflammatory bowel disease. *Arq Gastroenterol* 2010; 47: 313–25.
7. Hvas CL, Dahlerup JF, Jacobsen BA et al. Diagnosis and treatment of fistulising Crohn's disease. *Dan Med Bull* 2011; 58: C4338.
8. Van AG, Dignass A, Reinisch W et al. The second European evidence-based Consensus on the diagnosis and management of Crohn's disease: special situations. *J Crohn's Colitis* 2010; 4: 63–101.
9. Orlando A, Armuzzi A, Papi C et al. The Italian Society of Gastroenterology (SIGE) and the Italian Group for the study of Inflammatory Bowel Disease (IG-IBD) Clinical Practice Guidelines: the use of tumor necrosis factor-alpha antagonist therapy in inflammatory bowel disease. *Dig Liver Dis* 2011; 43: 1–20.
10. Ommer A, Herold A, Berg E et al. Cryptoglandular anal fistulas. *Dtsch Arztebl Int* 2011; 108: 707–13.
11. D'Haens GR, Panaccione R, Higgins PD et al. The London Position Statement of the World Congress of Gastroenterology on Biological Therapy for IBD with the European Crohn's and Colitis Organization: when to start, when to stop, which drug to choose, and how to predict response? *Am J Gastroenterol* 2011; 106:199–212.
12. Steele SR, Kumar R, Feingold DL, Rafferty JL, Buie WD. Practice parameters for the management of perianal abscess and fistula-in-ano. *Dis Colon Rectum* 2011; 54: 1465–74.
13. Gecse KB, Bemelman W, Kamm MA et al. A global consensus on the classification, diagnosis and multidisciplinary treatment of perianal fistulising Crohn's disease. *Gut* 2014; 63: 1381–92.
14. Ueno F, Matsui T, Matsumoto T et al. Evidence-based clinical practice guidelines for Crohn's disease, integrated with formal consensus of experts in Japan. *J Gastroenterol* 2013; 48: 31–72.
15. Sahni VA, Ahmad R, Burling D. Which method is best for imaging of perianal fistula? *Abdom Imaging* 2008; 33:26–30.
16. West RL, Zimmerman DD, Dwarkasing S et al. Prospective comparison of hydrogen peroxide-enhanced three-dimensional endoanal ultrasonography and endoanal magnetic resonance imaging of perianal fistulas. *Dis Colon Rectum* 2003; 46: 1407–15.
17. Buchanan GN, Halligan S, Bartram CI et al. Clinical examination, endosonography, and MR imaging in preoperative assessment of fistula in ano: comparison with outcome-based reference standard. *Radiology* 2004; 233: 674–81.
18. Ratto C, Grillo E, Parello A, Costamagna G, Doglietto GB. Endoanal ultrasound-guided surgery for anal fistula. *Endoscopy* 2005; 37: 722–8.
19. Schwartz DA, Wiersema MJ, Dudiak KM et al. A comparison of endoscopic ultrasound, magnetic resonance imaging, and exam under anesthesia for evaluation of Crohn's perianal fistulas. *Gastroenterology* 2001; 121:1064–72.

20. McKee RF, Keenan RA. Perianal Crohn's disease—is it all bad news? *Dis Colon Rectum* 1996; 39: 136–42.
21. West RL, Dworkasing S, Felt-Bersma RJ et al. Hydrogen peroxide-enhanced three-dimensional endoanal ultrasonography and endoanal magnetic resonance imaging in evaluating perianal fistulas: agreement and patient preference. *Eur J Gastroenterol Hepatol* 2004; 16: 1319–24.
22. Regueiro M. The role of endoscopy in the evaluation of fistulizing Crohn's disease. *Gastrointest Endosc Clin N Am* 2002; 12: 621–33.
23. Haggett PJ, Moore NR, Shearman JD et al. Pelvic and perineal complications of Crohn's disease: assessment using magnetic resonance imaging. *Gut* 1995; 36: 407–10.
24. Schwartz DA, Loftus EV Jr, Tremaine WJ et al. The natural history of fistulizing Crohn's disease in Olmsted County, Minnesota. *Gastroenterology* 2002; 122: 875–80.
25. Bell SJ, Williams AB, Wiesel P et al. The clinical course of fistulating Crohn's disease. *Aliment Pharmacol Ther* 2003; 17: 1145–51.
26. Kuijpers HC, Schulpen T. Fistulography for fistula-in-ano. Is it useful? *Dis Colon Rectum* 1985; 28: 103–4.
27. Weisman RI, Orsay CP, Pearl RK, Abcarian H. The role of fistulography in fistula-in-ano. Report of five cases. *Dis Colon Rectum* 1991; 34: 181–4.
28. Schaefer O, Lohrmann C, Langer M. Assessment of anal fistulas with high-resolution subtraction MR-fistulography: comparison with surgical findings. *J Magn Reson Imaging* 2004; 19: 91–8.
29. Parks AG, Gordon PH, Hardcastle JD. A classification of fistula-in-ano. *Br J Surg* 1976; 63: 1–12.
30. Quah HM, Tang CL, Eu KW, Chan SY, Samuel M. Meta-analysis of randomized clinical trials comparing drainage alone vs primary sphincter-cutting procedures for anorectal abscess-fistula. *Int J Colorectal Dis* 2006; 21: 602–9.
31. Williams JG, Rothenberger DA, Nemer FD, Goldberg SM. Fistula-in-ano in Crohn's disease. Results of aggressive surgical treatment. *Dis Colon Rectum* 1991; 34: 378–84.
32. Levien DH, Surrell J, Mazier WP. Surgical treatment of anorectal fistula in patients with Crohn's disease. *Surg Gynecol Obstet* 1989; 169: 133–6.
33. Hamalainen KP, Sainio AP. Cutting seton for anal fistulas: high risk of minor control defects. *Dis Colon Rectum* 1997; 40: 1443–6.
34. Garcia-Aguilar J, Belmonte C, Wong DW, Goldberg SM, Madoff RD. Cutting seton versus two-stage seton fistulotomy in the surgical management of high anal fistula. *Br J Surg* 1998; 85: 243–5.
35. Zbar AP, Ramesh J, Beer-Gabel M, Salazar R, Pescatori M. Conventional cutting vs. internal anal sphincter-preserving seton for high trans-sphincteric fistula: a prospective randomized manometric and clinical trial. *Tech Coloproctol* 2003; 7: 89–94.
36. Williams JG, MacLeod CA, Rothenberger DA, Goldberg SM. Seton treatment of high anal fistulae. *Br J Surg* 1991; 78: 1159–61.
37. Lindsey I, Smilgin-Humphreys MM, Cunningham C, Mortensen NJ, George BD. A randomized, controlled trial of fibrin glue vs. conventional treatment for anal fistula. *Dis Colon Rectum* 2002; 45: 1608–15.
38. Hyder SA, Travis SP, Jewell DP, McC Mortensen NJ, George BD. Fistulating anal Crohn's disease: results of combined surgical and infliximab treatment. *Dis Colon Rectum* 2006; 49: 1837–41.
39. Buchanan GN, Owen HA, Torkington J et al. Long-term outcome following loose-seton technique for external sphincter preservation in complex anal fistula. *Br J Surg* 2004; 91: 476–80.

40. Ortiz H, Marzo J, Ciga MA et al. Randomized clinical trial of anal fistula plug versus endorectal advancement flap for the treatment of high cryptoglandular fistula in ano. *Br J Surg* 2009; 96: 608–12.
41. Mitalas LE, Gosselink MP, Zimmerman DD, Schouten WR. Repeat transanal advancement flap repair: impact on the overall healing rate of high transsphincteric fistulas and on fecal continence. *Dis Colon Rectum* 2007;50: 1508–11.
42. Perez F, Arroyo A, Serrano P et al. Randomized clinical and manometric study of advancement flap versus fistulotomy with sphincter reconstruction in the management of complex fistula-in-ano. *Am J Surg* 2006; 192:34–40.
43. Soltani A, Kaiser AM. Endorectal advancement flap for cryptoglandular or Crohn's fistula-in-ano. *Dis Colon Rectum* 2010; 53: 486–95.
44. Schouten WR, Zimmerman DD, Briel JW. Transanal advancement flap repair of transsphincteric fistulas. *Dis Colon Rectum* 1999; 42: 1419–22.
45. Ellis CN, Clark S. Fibrin glue as an adjunct to flap repair of anal fistulas: a randomized, controlled study. *Dis Colon Rectum* 2006; 49: 1736–40.
46. Swinscoe MT, Ventakasubramaniam AK, Jayne DG. Fibrin glue for fistula-in-ano: the evidence reviewed. *Tech Coloproctol* 2005; 9: 89–94.
47. Schwandner O, Stadler F, Dietl O, Wirsching RP, Fuerst A. Initial experience on efficacy in closure of cryptoglandular and Crohn's transsphincteric fistulas by the use of the anal fistula plug. *Int J Colorectal Dis* 2008; 23: 319–24.
48. Ellis CN, Rostas JW, Greiner FG. Long-term outcomes with the use of bioprosthetic plugs for the management of complex anal fistulas. *Dis Colon Rectum* 2010; 53: 798–802.
49. Song WL, Wang ZJ, Zheng Y, Yang XQ, Peng YP. An anorectal fistula treatment with acellular extracellular matrix: a new technique. *World J Gastroenterol* 2008; 14: 4791–4.
50. Rojanasakul A, Pattanaarun J, Sahakitrungruang C, Tantiphlachiva K. Total anal sphincter saving technique for fistula-in-ano; the ligation of intersphincteric fistula tract. *J Med Assoc Thai* 2007; 90: 581–6.
51. Abcarian AM, Estrada JJ, Park J et al. Ligation of intersphincteric fistula tract: early results of a pilot study. *Dis Colon Rectum* 2012; 55: 778–82.
52. Yamamoto T, Allan RN, Keighley MR. Effect of fecal diversion alone on perianal Crohn's disease. *World J Surg* 2000; 24: 1258–62.
53. Guillem JG, Roberts PL, Murray JJ et al. Factors predictive of persistent or recurrent Crohn's disease in excluded rectal segments. *Dis Colon Rectum* 1992; 35: 768–72.
54. Rehg KL, Sanchez JE, Krieger BR, Marcet JE. Fecal diversion in perirectal fistulizing Crohn's disease is an underutilized and potentially temporary means of successful treatment. *Am Surg* 2009; 75: 715–8.
55. Galandiuk S, Kimberling J, Al-Mishlab TG, Stromberg AJ. Perianal Crohn disease: predictors of need for permanent diversion. *Ann Surg* 2005; 241: 796–801.
56. Dewint P, Hansen BE, Verhey E et al. Adalimumab combined with ciprofloxacin is superior to adalimumab monotherapy in perianal fistula closure in Crohn's disease: a randomised, double-blind, placebo controlled trial (ADAFI). *Gut* 2014; 63: 292–9.
57. Maeda Y, Ng SC, Durdey P et al. Randomized clinical trial of metronidazole ointment versus placebo in perianal Crohn's disease. *Br J Surg* 2010; 97: 1340–7.
58. Pearson DC, May GR, Fick GH, Sutherland LR. Azathioprine and 6-mercaptopurine in Crohn disease. A meta-analysis. *Ann Intern Med* 1995; 123: 132–42.
59. Thia KT, Mahadevan U, Feagan BG et al. Ciprofloxacin or metronidazole for the treatment of perianal fistulas in patients with Crohn's disease: a randomized, double-blind, placebo-controlled pilot study. *Inflamm Bowel Dis* 2009; 15: 17–24.

60. Prefontaine E, Macdonald JK, Sutherland LR. Azathioprine or 6-mercaptopurine for induction of remission in Crohn's disease. *Cochrane Database Syst Rev* 2010; 6: CD000545.
61. Present DH, Korelitz BI, Wisch N et al. Treatment of Crohn's disease with 6-mercaptopurine. A long-term, randomized, double-blind study. *N Engl J Med* 1980; 302: 981–7.
62. Sandborn WJ, Fazio VW, Feagan BG, Hanauer SB. AGA technical review on perianal Crohn's disease. *Gastroenterology* 2003; 125: 1508–30.
63. Present DH, Rutgeerts P, Targan S et al. Infliximab for the treatment of fistulas in patients with Crohn's disease. *N Engl J Med* 1999; 340: 1398–405.
64. Behm BW, Bickston SJ. Tumor necrosis factor-alpha antibody for maintenance of remission in Crohn's disease. *Cochrane Database Syst Rev* 2008; 1: CD006893.
65. Sands BE, Anderson FH, Bernstein CN et al. Infliximab maintenance therapy for fistulizing Crohn's disease. *N Engl J Med* 2004; 350: 876–85.
66. Colombel JF, Schwartz DA, Sandborn WJ et al. Adalimumab for the treatment of fistulas in patients with Crohn's disease. *Gut* 2009; 58: 940–8.
67. Hanauer SB, Smith MB. Rapid closure of Crohn's disease fistulas with continuous intravenous cyclosporin A. *Am J Gastroenterol* 1993; 88: 646–9.
68. Present DH, Lichtiger S. Efficacy of cyclosporine in treatment of fistula of Crohn's disease. *Dig Dis Sci* 1994; 39: 374–80.
69. Egan LJ, Sandborn WJ, Tremaine WJ. Clinical outcome following treatment of refractory inflammatory and fistulizing Crohn's disease with intravenous cyclosporine. *Am J Gastroenterol* 1998; 93: 442–8.
70. Sandborn WJ, Present DH, Isaacs KL et al. Tacrolimus for the treatment of fistulas in patients with Crohn's disease: a randomized, placebo-controlled trial. *Gastroenterology* 2003; 125: 380–8.
71. Orsoni P, Barthet M, Portier F et al. Prospective comparison of endosonography, magnetic resonance imaging and surgical findings in anorectal fistula and abscess complicating Crohn's disease. *Br J Surg* 1999; 86: 360–4.
72. Wu XW, Ji HZ, Wang FY. Meta-analysis of ciprofloxacin in treatment of Crohn's disease. *Biomed Rep* 2015; 3: 70–4.
73. Lichtenstein GR, Yan S, Bala M, Blank M, Sands BE. Infliximab maintenance treatment reduces hospitalizations, surgeries, and procedures in fistulizing Crohn's disease. *Gastroenterology* 2005; 128: 862–9.
74. Hart AL, Plamondon S, Kamm MA. Topical tacrolimus in the treatment of perianal Crohn's disease: exploratory randomized controlled trial. *Inflamm Bowel Dis* 2007; 13: 245–53.
75. Maier AG, Funovics MA, Kreuzer SH et al. Evaluation of perianal sepsis: comparison of anal endosonography and magnetic resonance imaging. *J Magn Reson Imaging* 2001; 14: 254–60.
76. Halligan S. Imaging fistula-in-ano. *Clin Radiol* 1998; 53: 85–95.
77. Skalej M, Makowiec F, Weinlich M et al. [Magnetic resonance imaging in perianal Crohn's disease]. *Dtsch Med Wochenschr* 1993; 118: 1791–6.
78. van Bodegraven AA, Sloots CE, Felt-Bersma RJ, Meuwissen SG. Endosonographic evidence of persistence of Crohn's disease-associated fistulas after infliximab treatment, irrespective of clinical response. *Dis Colon Rectum* 2002; 45: 39–45.
79. Sloots CE, Felt-Bersma RJ, Poen AC, Cuesta MA, Meuwissen SG. Assessment and classification of fistula-in-ano in patients with Crohn's disease by hydrogen peroxide enhanced transanal ultrasound. *Int J Colorectal Dis* 2001; 16: 292–7.
80. Guillaumin E, Jeffrey RB Jr, Shea WJ, Asling CW, Goldberg HI. Perirectal inflammatory disease: CT findings. *Radiology* 1986; 161: 153–7.

81. Yousem DM, Fishman EK, Jones B. Crohn disease: perirectal and perianal findings at CT. *Radiology* 1988;167: 331–4.
82. Roig JV, Garcia-Armengol J, Jordan JC et al. Fistulectomy and sphincteric reconstruction for complex cryptoglandular fistulas. *Colorectal Dis* 2010; 12: e145–52.
83. Scott HJ, Northover JM. Evaluation of surgery for perianal Crohn's fistulas. *Dis Colon Rectum* 1996; 39:1039–43.
84. Morrison JG, Gathright JB Jr, Ray JE et al. Surgical management of anorectal fistulas in Crohn's disease. *Dis Colon Rectum* 1989; 32: 492–6.
85. van der Hagen SJ, Baeten CG, Soeters PB et al. Anti-TNF-alpha (infliximab) used as induction treatment in case of active proctitis in a multistep strategy followed by definitive surgery of complex anal fistulas in Crohn's disease: a preliminary report. *Dis Colon Rectum* 2005; 48: 758–67.
86. van Koperen PJ, Wind J, Bemelman WA et al. Long-term functional outcome and risk factors for recurrence after surgical treatment for low and high perianal fistulas of cryptoglandular origin. *Dis Colon Rectum* 2008; 51:1475–81.
87. van Tets WF, Kuijpers HC. Continence disorders after anal fistulotomy. *Dis Colon Rectum* 1994; 37: 1194–7.
88. Garcia-Aguilar J, Belmonte C, Wong WD, Goldberg SM, Madoff RD. Anal fistula surgery. Factors associated with recurrence and incontinence. *Dis Colon Rectum* 1996; 39: 723–9.
89. Davies M, Harris D, Lohana P et al. The surgical management of fistula-in-ano in a specialist colorectal unit. *Int J Colorectal Dis* 2008; 23: 833–8.
90. Parks AG, Stitz RW. The treatment of high fistula-in-ano. *Dis Colon Rectum* 1976; 19: 487–99.
91. Faucheron JL, Saint-Marc O, Guibert L, Parc R. Long-term seton drainage for high anal fistulas in Crohn's disease—a sphincter-saving operation? *Dis Colon Rectum* 1996; 39: 208–11.
92. Topstad DR, Panaccione R, Heine JA et al. Combined seton placement, infliximab infusion, and maintenance immunosuppressives improve healing rate in fistulizing anorectal Crohn's disease: a single center experience. *Dis Colon Rectum* 2003; 46: 577–83.
93. Ozuner G, Hull TL, Cartmill J, Fazio VW. Long-term analysis of the use of transanal rectal advancement flaps for complicated anorectal/vaginal fistulas. *Dis Colon Rectum* 1996; 39: 10–4.
94. van Koperen PJ, Wind J, Bemelman WA, Slors JF. Fibrin glue and transanal rectal advancement flap for high transsphincteric perianal fistulas; is there any advantage? *Int J Colorectal Dis* 2008; 23: 697–701.
95. Hjortrup A, Moesgaard F, Kjaergard J. Fibrin adhesive in the treatment of perineal fistulas. *Dis Colon Rectum* 1991; 34: 752–4.
96. Adams T, Yang J, Kondylis LA, Kondylis PD. Long-term outlook after successful fibrin glue ablation of cryptoglandular transsphincteric fistula-in-ano. *Dis Colon Rectum* 2008; 51: 1488–90.
97. Sentovich SM. Fibrin glue for anal fistulas: long-term results. *Dis Colon Rectum* 2003; 46: 498–502.
98. Vitton V, Gasmi M, Barthet M et al. Long-term healing of Crohn's anal fistulas with fibrin glue injection. *Aliment Pharmacol Ther* 2005; 21: 1453–7.
99. Grimaud JC, Munoz-Bongrand N, Siproudhis L et al. Fibrin glue is effective healing perianal fistulas in patients with Crohn's disease. *Gastroenterology* 2010; 138: 2275–81.
100. O'Connor L, Champagne BJ, Ferguson MA et al. Efficacy of anal fistula plug in closure of Crohn's anorectal fistulas. *Dis Colon Rectum* 2006; 49: 1569–73.

101. Ky AJ, Sylla P, Steinhagen R et al. Collagen fistula plug for the treatment of anal fistulas. *Dis Colon Rectum* 2008; 51: 838–43.
102. Bernstein LH, Frank MS, Brandt LJ, Boley SJ. Healing of perineal Crohn's disease with metronidazole. *Gastroenterology* 1980; 79: 357–65.
103. Brandt LJ, Bernstein LH, Boley SJ, Frank MS. Metronidazole therapy for perineal Crohn's disease: a follow-up study. *Gastroenterology* 1982; 83: 383–7.
104. Dejaco C, Harrer M, Waldhoer T et al. Antibiotics and azathioprine for the treatment of perianal fistulas in Crohn's disease. *Aliment Pharmacol Ther* 2003; 18: 1113–20.
105. West RL, van der Woude CJ, Hansen BE et al. Clinical and endosonographic effect of ciprofloxacin on the treatment of perianal fistulae in Crohn's disease with infliximab: a double-blind placebo-controlled study. *Aliment Pharmacol Ther* 2004; 20: 1329–36.
106. Korelitz BI, Adler DJ, Mendelsohn RA, Sacknoff AL. Long-term experience with 6-mercaptopurine in the treatment of Crohn's disease. *Am J Gastroenterol* 1993; 88: 1198–205.
107. Felley C, Mottet C, Juillerat P et al. Fistulizing Crohn's disease. *Digestion* 2007; 76: 109–12.
108. Colombel JF, Sandborn WJ, Rutgeerts P et al. Adalimumab for maintenance of clinical response and remission in patients with Crohn's disease: the CHARM trial. *Gastroenterology* 2007; 132: 52–65.
109. Hanauer SB, Sandborn WJ, Rutgeerts P et al. Human anti-tumor necrosis factor monoclonal antibody (adalimumab) in Crohn's disease: the CLASSIC-I trial. *Gastroenterology* 2006; 130: 323–33.
110. Ford AC, Sandborn WJ, Khan KJ et al. Efficacy of biological therapies in inflammatory bowel disease: systematic review and meta-analysis. *Am J Gastroenterol* 2011; 106: 644–59, quiz.

Appendix

PubMed on 30 September 2015 – 235 hits

1. ('Rectal fistula'[Mesh] OR perianal fistul*[tiab] OR peri-anal fistul*[tiab] OR rectal fistul*[tiab] OR anorectal fistul*[tiab] OR anus fistul*[tiab] OR anal fistul*[tiab] OR rectum fistul*[tiab] OR rectal fistul*[tiab]) OR ('Crohn Disease'[MeSH] AND guideline*[ti]) OR ('Crohn Disease'[MeSH] AND consensus*[ti]) OR (fistulising crohn*[ti])
2. ('Guideline' [Publication Type] OR 'Guidelines as Topic'[Mesh] OR 'Guideline Adherence'[Mesh] OR 'Practice Guideline' [Publication Type] OR 'Consensus'[Mesh] OR 'Consensus Development Conferences as Topic'[Mesh] OR practice parameter*[tiab] OR consensus*[tiab] OR guideline*[tiab] OR 'Consensus Development Conference, NIH' [Publication Type] OR 'Consensus Development Conference' [Publication Type] OR 'Consensus Development Conferences, NIH as Topic'[Mesh] OR (fistulising crohn*[ti] AND 'Review'[pt]))
3. ('Case Reports' [Publication Type] OR 'Letter' [Publication Type] OR 'Newspaper Article' [Publication Type])
4. 1 and 2
5. 4 not 3

EMBASE on 30 September 2015 – 197 hits

1. anus fistula/
2. perianal fistul* or peri-anal fistul* or rectal fistul* or anorectal fistul* or anus fistul* or anal fistul* or fistula ani or rectum fistul* or fistula recti or rectal fistul*.ti,ab,kw.
3. Crohn disease/and guideline*.ti.
4. 1 or 2 or 3
5. exp practice guideline/
6. consensus development/
7. consensus/
8. practice parameter* or consensus* or guideline*.mp.
9. fistulising crohn*.ti and 'review'/
10. 5 or 6 or 7 or 8 or 9
11. 4 and 10
12. case report/or letter/or publication
13. 11 not 12

MEDLINE on 30 September 2015 – 80 hits

1. exp Rectal Fistula/
2. perianal fistul* or peri-anal fistul* or rectal fistul* or anorectal fistul* or rectovaginal fistul* or anus fistul* or anal fistul* or fistula ani or rectum fistul* or fistula recti or rectal fistul*).ti,ab,kw.
3. Crohn disease/and (guideline* or consensus*).ti.
4. 1 or 2 or 3
5. exp Practice Guideline/or exp Guideline Adherence/or exp Guideline/or consensus/ or exp Guidelines as Topic/
6. practice parameter* or consensus* or guideline*).mp.
7. fistulising crohn*.ti. and 'review'/
8. 5 or 6 or 7
9. 4 and 8
10. case reports/or letter/or newspaper article/
- 11.9 not 10