



UvA-DARE (Digital Academic Repository)

Selecting regions of interest on intraoral radiographs for the prediction of bone mineral density

Geraets, W.G.M.; Verheij, H.G.C.; van der Stelt, P.F.; Horner, K.; Lindh, C.; Nicopoulou-Karayianni, K.; Jacobs, R.; Marjanovic, E.J.; Adams, J.E.; Devlin, H.

DOI

[10.1259/dmfr/29966973](https://doi.org/10.1259/dmfr/29966973)

Publication date

2008

Document Version

Author accepted manuscript

Published in

Dentomaxillofacial Radiology

[Link to publication](#)

Citation for published version (APA):

Geraets, W. G. M., Verheij, H. G. C., van der Stelt, P. F., Horner, K., Lindh, C., Nicopoulou-Karayianni, K., Jacobs, R., Marjanovic, E. J., Adams, J. E., & Devlin, H. (2008). Selecting regions of interest on intraoral radiographs for the prediction of bone mineral density. *Dentomaxillofacial Radiology*, 37(7), 375-379. <https://doi.org/10.1259/dmfr/29966973>

General rights

It is not permitted to download or to forward/distribute the text or part of it without the consent of the author(s) and/or copyright holder(s), other than for strictly personal, individual use, unless the work is under an open content license (like Creative Commons).

Disclaimer/Complaints regulations

If you believe that digital publication of certain material infringes any of your rights or (privacy) interests, please let the Library know, stating your reasons. In case of a legitimate complaint, the Library will make the material inaccessible and/or remove it from the website. Please Ask the Library: <https://uba.uva.nl/en/contact>, or a letter to: Library of the University of Amsterdam, Secretariat, Singel 425, 1012 WP Amsterdam, The Netherlands. You will be contacted as soon as possible.

UvA-DARE is a service provided by the library of the University of Amsterdam (<https://dare.uva.nl>)

Selecting regions of interest on intra oral radiographs for the prediction of bone mineral density

W.G.M. Geraets^a, J.G.C. Verheij^a, P.F. van der Stelt^a,
K. Horner^b, C. Lindh^c, K. Nicopoulou-Karayianni^d, R. Jacobs^e, H. Devlin^b

^a Department of Oral and Maxillofacial Radiology,

Academic Centre for Dentistry Amsterdam (ACTA), The Netherlands

^b Department of Radiology, School of Dentistry University of Manchester, UK

^c Faculty of Odontology, Malmö University, Sweden

^d Department of Oral Diagnosis and Radiology, University of Athens, Greece

^e Oral Imaging Center, University of Leuven, Belgium

Corresponding author:

Dr. Wil G.M. Geraets, MSc, PhD
Department of Oral and Maxillofacial Radiology
Academic Centre for Dentistry Amsterdam
Louwesweg 1
1066 EA Amsterdam The Netherlands
E-mail: W.Geraets@acta.nl

Abstract

Objectives: A previous study showed that the trabecular pattern on dental radiographs correlates with femoral and spinal Bone Mineral Density (BMD). The objective of this study was to determine if the correlation is affected by size and location of the region of interest (ROI).

Methods: In a European research project on osteoporosis BMD was measured at the left hip and the lumbar spine of 525 women. From all subjects intraoral radiographs were made of the premolar region in the upper and lower jaws. Two ROIs were indicated manually on each image and scanned. The smallest ROI involved trabecular bone only and the largest included parts of the neighbouring teeth as well. The ROIs were subjected to automatic image analysis yielding 26 measurements per ROI. Stepwise linear regression was used to predict femoral and spinal BMD.

Results: Inner and outer regions predicted BMD equally well. Also the radiographs of lower and upper jaw predicted BMD equally well. Combining inner and outer regions did not improve the prediction of femoral and spinal BMD but combining lower and upper jaws did.

Conclusions: This study shows that it is allowed to include parts of neighbouring teeth in the region of interest used to assess the trabecular pattern and predict BMD. This simplifies the process of selecting the ROI because no efforts have to be made to exclude neighbouring teeth. Combining ROIs of lower and upper jaws improves the prediction of BMD significantly.

Keywords: dental radiographs, region of interest, image processing, bone mineral density

Introduction

According to the WHO osteoporosis is defined as reduced Bone Mineral Density (BMD) preferably measured by Dual X-ray Absorptiometry. Osteoporosis being a systemic skeletal disease affects density and structure of all skeletal parts including the jaws. Intraoral radiographs are common diagnostic tools in dentistry today. Although intraoral radiographs are primarily made for dental diagnosis, they provide other useful information as well. Because the radiographs are relatively inexpensive and made regularly of a large fraction of the adult population in many societies, they represent an enormous potential as a screening tool for osteoporosis. By recognizing the possibility of osteoporosis in its early phase and referring the patient to a specialist, the dentist can help the patient greatly to increase the chances for a cure and a normal life, and help society to control the financial burden that is associated with osteoporosis. Previous studies have shown that dental radiographs of mandibular and maxillary bone can also be used for the diagnosis of osteoporosis.¹⁻³ Reduced bone mass of the jaws of osteoporotic subjects has been reported.⁴⁻⁸ With respect to the structure of the trabecular pattern on dental radiographs some studies have explored the use of fractal dimension as a predictive parameter for osteoporosis.⁹⁻¹¹ Extensive morphologic analysis of the trabecular pattern on dental radiographs in relation to osteoporosis has also been described.¹¹⁻¹³

The correlations between osteoporosis and radiological measurements in dental radiographs are comparable to those reported for commonly used clinical screening instruments for osteoporosis such as the Osteoporosis Self-assessment Tool (OST) or the Simple Calculated Osteoporosis Risk Estimation (SCORE) with area under ROC curves of about 0.8. However, most researchers conclude that these correlations are still too low for clinical use of dental radiographs in screening of osteoporosis.^{1-3,6,12,13}

In 2003 the European Union granted a research project of five European Universities at Manchester, Amsterdam, Athens, Leuven, and Malmö. This project, named OSTEODENT, investigated the diagnostic validity of dental radiography techniques for identifying osteoporotic patients. The overall aim of the research project was to find methods which the dentist can use to assess the osteoporotic status of patients by means of dental radiographs, possibly combined with other clinical information. More specifically, the goals of the project were to investigate up to what extent the BMD of the spine and femur could be predicted by characteristics of dental radiographs. One of the techniques used was a quantitative analysis of the radiographic trabecular pattern as shown on dental intraoral and panoramic radiographs. This technique has been described in detail before.^{14,15} It was shown that the trabecular pattern on dental radiographs can be used to predict the BMD of hip and lumbar spine.¹¹ In the latter study the region of interest (ROI) on intraoral radiographs was located between the teeth but included also parts of the neighbouring teeth and in particular the roots. Because the texture of roots is different from that of the trabecular pattern, it is conceivable that inclusion of root sections in the ROI may adversely affect the prediction of the BMD. But if it does not then the trouble of indicating a ROI that is located entirely in the interdental region can be saved. Considering that the interdental region can be very narrow this would imply a simplification of the observer task. When it is considered to use intraoral dental radiographs it is relevant to know whether the upper or lower jaw or both jaws should be used. The present study investigates the effect of size and location of the ROI on the correlation of the radiographic trabecular pattern with BMD of hip and spine.

Material and methods

Subjects

In the Osteodent project subjects from Manchester, Athens, Leuven, and Malmö were invited to participate in the study by means of articles in the local press, flyers, and by oral communication. 671 Women in the age range of 39 to 71 years (average 54.6 years) were recruited. Women with possible secondary osteoporosis caused by primary hyperparathyroidism, poorly controlled

thyrotoxicosis, malabsorption, liver disease and alcoholism were excluded. Informed consent was obtained from all participating subjects. BMD was measured at the lumbar spine and left hip. The dental status was assessed by means of a dental panoramic radiograph and intraoral radiographs of the upper and lower premolar regions of the right side. A complete set of data including BMD values and dental radiographs could be obtained from 525 women.

BMD values and gold standard

BMD values were measured by means of DXA scans of the left hip and of the lumbar spine (L1 to L4). The scans were made with the Hologic QDR 4500, the Hologic Discovery (Hologic Inc., Bedford, Massachusetts, USA), and the GE Lunar Prodigy (GE Lunar Corporation, Madison, Wisconsin) at the centres in Athens, Leuven, Malmö, and Manchester. Shewarts rules were used to monitor quality assurance throughout the study period.¹⁶ The measurements by different machines were standardised using the European spine phantom and the method described by Pearson and colleagues.¹⁷ Next, the BMD values were converted into T-scores by comparison with the mean and standard deviation of the BMD values in a reference population of young healthy women. For example, a T-score of -1 indicates that the BMD of the subject is 1 standard deviation below the mean. For the hip the NHANES data were used as reference and for the lumbar spine the Hologic reference data were used.¹⁸ Subjects were diagnosed as osteoporotic in accordance with the criteria of the World Health Organization if the T-score of hip, or lumbar spine was -2.5 or less. This diagnosis was considered as the gold standard.

Intraoral radiographs and ROIs

From each subject two intraoral radiographs were made with three Planmeca Prostyle Intra devices (60 - 63 kV) (Planmeca Oy, Helsinki, Finland), and one Siemens Heliodent MD (60 kV) (Sirona, Bensheim, Germany). They depicted the upper right and lower right premolar regions on conventional films which were scanned at a resolution of 118 pixels/cm (300 pixels/inch) with a flatbed scanner (Agfa Duoscan T1200, fixed sensitivity settings).

For each subject 4 ROIs were selected, 2 in the upper jaw and 2 in the lower jaw, yielding 2100 regions in all. Most radiographs displayed three interdental regions of which the widest was chosen to select a region containing trabecular pattern only; this was the inner region. A larger region was selected enclosing the inner region and parts of the neighbouring teeth as well (Figs. 1, 2). On average the size of the ROIs on the intraoral radiographs of the upper jaw were 40 x 90 for the inner region and 70 x 100 pixels for the outer region. For the lower jaw the inner region was 50 x 100 pixels on average and the outer region 80 x 120 pixels. The narrowest ROI selected was 1.5 mm wide.

Measurements

The ROIs were subjected to automatic measurement procedures. First, the mean and standard deviation of the gray values were determined on the raw unfiltered ROI. High- and low frequency noise were filtered out and the region was segmented into black and white segments.^{14,19,20-22} The segments were used to measure the fractal dimension according to the caliper method, the total area of the black segments, the total area of the white segments, the perimeter of white segments, the number of black segments, and the number of white segments.²³ The measurements of area and perimeter, and of the numbers of black and white segments were normalized by dividing them by the total area of the ROI. Next the white segments were eroded to a wire frame that was used to measure the total length of the frame, the number of endpoints, and the number of furcations.^{14,19-21,24} Similarly, the black regions were eroded to a wire frame that was used to measure the total length of the frame, the number of endpoints, and the number of furcations. The measurements that were made on the wire frames also were normalized by dividing them by the total area of the ROI. Finally, the segmented region was used to measure the Line Fraction Deviation (LFD) index of orientation along 12 directions starting with 0°, and then in steps of 15° up to 165° (LFD 0 to LFD 165).^{15,24-26} Of these image features 99% had values of Cronbach's α of 0.8 or more indicating that they have high reliability or precision.²⁷

Statistics

BMD values of total hip and spine were predicted with stepwise multiple linear regression yielding the multiple correlation between the BMD value and the predictors. The first predictor was the single variable correlating most with the BMD. The second predictor was the variable that increased the correlation most when combined with the first predictor. This process was repeated until the prediction of the BMD did not improve statistically significant. Computations of correlations were done using the SPSS package (version 12.0, SPSS inc., Chicago, USA). Additional tests for the level of significance were done according to the method of Steiger.²⁸

Age is an important determinant of BMD that can be obtained easily in most cases and without radiation.^{29,30} Hence it was decided that age should be used first to predict the BMD of total hip and spine. Subsequently the measurements on the intraoral radiograph were included in the analysis.

Results

Table 1 shows the BMD of hip and spine for 6 age groups. It clearly shows that BMD decreases as age increases. Tables 2 and 3 show the correlations of femoral and spinal BMD with the radiographic trabecular pattern measured on the smallest (inner) region and the enclosing (outer) region. The differences between the two regions were not significant with respect to predicting femoral BMD nor with respect to predicting spinal BMD.

Combining the two regions hardly improved the predictive power; only predicting femoral BMD using the data of the radiographs of the lower jaw showed a just significant improvement.

When comparing the radiographs of the lower and the upper jaw it was found that they predicted BMD equally well. Combining radiographs of lower and upper jaw significantly increased the

power to predict femoral and spinal BMD for the inner region, the outer region as well as for the combination of the two regions.

Conclusions and discussion

As a consequence of the anatomical dimensions many of the intra oral dental radiographs in this study contained only small areas with interdental bone structure. On average the inner ROIs were only 0.14 cm² for the lower jaw and 0.10 cm² for the upper jaw. It is remarkable that such small areas still enable prediction of femoral and spinal BMD. In the present study a coefficient of variation for BMD of nearly 2% was found which is comparable to the precision errors that are reported for measuring BMD by means of QCT and DXA techniques.^{31,32}

In previous studies it was shown that the characteristics of the radiographic trabecular pattern can be used to predict BMD values.^{11,20} Tables 2 and 3 show that prediction of femoral and spinal BMD can be done equally well by the outer region as by the inner region. From the fact that using both regions did not improve the prediction it can be concluded that the inner and outer regions contain the same information regarding BMD and that the inclusion of parts of the neighbouring teeth has a negligible effect on the outcome of the BMD prediction which might be explained by projection of trabecular bone on the roots. It implies that when the trabecular pattern is used for the prediction of bone mineral density the procedure for manual selection of the ROI can be simplified. No efforts need to be made to select the rather narrow region between the teeth avoiding inclusion of parts of neighbouring teeth.

Radiographs of the lower and upper jaw predicted femoral and spinal BMD equally well, but the combination of the two radiographs increased the predictive power. Obviously the radiographs of lower and upper jaw contain complementary information regarding BMD. Averaging over spine and hip it is seen that the combination of age and radiographs triples the variance accounted for

compared with the variance accounted for by age only. Thus it can be concluded that the radiographs contain twice as much valuable information on BMD not contained in age.

In conclusion it can be stated that areas of 0.10 cm² of interdental bone on intraoral dental radiographs are large enough to enable prediction of femoral and spinal BMD. Both lower and upper jaw facilitate prediction of BMD equally well but using ROIs from both jaws improves the prediction. Selecting the ROI is not very critical and does not require extensive training thus making the use of this method on a routine base more plausible in the future.

Acknowledgements

This work was supported by a research and technological development project grant from the European Commission Fifth Framework Programme "Quality of Life and Management of Living Resources" (QLK6-2002-02243; "OSTEODENT").

References

1. Hildebolt CF. Osteoporosis and oral bone loss. *Dentomaxillofac Radiology* 1997; 26: 3-15.
2. Ledgerton D, Horner K, Devlin H. Osteoporosis research: a dental perspective. *Radiography* 1997; 3: 265-277.
3. White SC. Oral radiographic predictors of osteoporosis. *Dentomaxillofac Radiology* 2002; 31: 84-92.
4. Devlin H, Horner K. Measurement of mandibular bone mineral content using the dental panoramic tomogram. *J Dent* 1991; 19: 116-120.
5. Horner K, Devlin H. Clinical bone densitometric study of mandibular atrophy using dental panoramic tomography. *J Dent Res* 1992; 20: 33-37.
6. Horner K, Devlin H, Harvey L. Detecting patients with low skeletal bone mass. *J Dent* 2002; 30: 171-175.
7. Mohajery M, Brooks SL. Oral radiographs in the detection of early signs of osteoporosis. *Oral Surg Oral Med Oral Pathol Oral Radiol Endod* 1992; 73: 112-117.
8. Taguchi A, Tanimoto K, Suei Y, Ohama K, Wada T. Relationships between the mandibular and lumbar vertebral bone mineral density at different postmenopausal stages. *Dentomaxillofac Radiology* 1996; 25: 130-135.
9. Law AN, Bollen AM, Chen SK. Detecting osteoporosis using dental radiographs: a comparison of four methods. *J Am Dent Assoc* 1996; 127: 1734-1742.

10. Bollen AM, Taguchi A, Huijoe PP, Hollender LG. Fractal dimension on dental radiographs. *Dentomaxillofac Radiology* 2001; 30: 270-275.
11. Geraets WGM, Verheij JGC, Van der Stelt PF, Horner K, Lindh C, Nicopoulou-Karayianni K, et al. Prediction of bone mineral density with dental radiographs. *Bone* 2007; 40: 1217-1221.
12. White SC, Rudolph DJ. Alterations of the trabecular pattern of the jaws in patients with osteoporosis. *Oral Surg Oral Med Oral Pathol Oral Radiol Endod* 1999; 88: 628-635.
13. White SC, Atchison KA, Gornbein JA, Nattiv A, Paganini-Hill A, Service SK, et al. Change in mandibular trabecular pattern and hip fracture rate in elderly women. *Dentomaxillofac Radiology* 2005; 34: 168-174.
14. Geraets WGM, Van der Stelt PF, Netelenbos CJ, Elders PJM. A new method for automatic recognition of the radiographic trabecular pattern. *J Bone Miner Res* 1990; 5: 227-233.
15. Geraets WGM, Van der Stelt PF, Lips P, Elders PJM, Van Ginkel FC, Burger EH. Orientation of the trabecular pattern of the distal radius around the menopause. *J Biomech* 1997; 30: 363-370.
16. Orwoll ES, Oviatt SK. Longitudinal precision of dual-energy x-ray absorptiometry in a multicenter study. The Nafarelin/Bone Study Group. *J Bone Miner Res* 1991; 6: 191-97.
17. Pearson J, Dequeker J, Henley M, Bright J, Reeve J, Kalender W, et al. European semi-anthropomorphic spine phantom for the calibration of bone densitometers: assessment of precision, stability and accuracy. The European quantitation of osteoporosis study group. *Osteoporos Int* 1995; 5: 174-184.

18. Looker A, Wahner H, Dunn W, Calvo M, Harris T, Heyse S, et al. Updated data on proximal femur bone mineral levels of US adults. *Osteoporos Int* 1998; 8: 468-89.
19. Geraets WGM, Van der Stelt PF. Analysis of the radiographic trabecular pattern. *Pattern Recognition Letters* 1991; 12: 575-581.
20. Geraets WGM, Van der Stelt PF, Elders PJM. The radiographic trabecular bone pattern during menopause. *Bone* 1993; 14: 859-864.
21. Korstjens CM, Geraets WGM, Van Ginkel FC, PrahI-Andersen B, Van der Stelt PF, Burger EH. Longitudinal analysis of radiographic trabecular pattern by image processing. *Bone* 1995; 17: 527-532.
22. Korstjens CM, Mosekilde L, Spruijt RJ, Geraets WGM, Van der Stelt PF. Relations between radiographic trabecular pattern and biomechanical characteristics of human vertebrae. *Acta Radiol* 1996; 37: 618-624.
23. Geraets WGM, Van der Stelt PF. Fractal properties of bone. *Dentomaxillofac Radiol* 2000; 29: 144-153.
24. Geraets WGM, Van der Stelt PF, Lips P, Van Ginkel FC. The radiographic trabecular pattern of hips in patients with hip fractures and in elderly control subjects. *Bone* 1998; 22: 165-173.
25. Korstjens CM, Geraets WGM, Van Ginkel FC, PrahI-Andersen B, Van der Stelt PF, Burger EH. An analysis of the orientation of the radiographic trabecular pattern in the distal radius of children. *Growth Dev Aging* 1994; 58: 211-221.

26. Geraets WGM. Comparison of two methods for measuring orientation. *Bone* 1998; 23: 383-388.
27. Geraets WGM, Verheij JGC, Van der Stelt PF, Horner K, Lindh C, Nicopoulou-Karayianni K, et al. Osteoporosis and the general dental practitioner: reliability of some digital dental radiological measures. *Community Dentistry and Oral Epidemiology* 2007; 35: 465-471.
28. Steiger JH. Tests for comparing elements of a correlation matrix. *Psychological bulletin* 1980; 87:245-251.
29. Riggs BL, Wahner HW, Dunn WL, Mazess RB, Offord KP, Melton LJ III. Differential changes in bone mineral density of the appendicular and axial skeleton with aging. *J Clin Invest* 1981;67:328-35
30. Riggs BL, Wahner HW, Seeman E, Offord KP, Dunn WL, Mazess RB, et al. Changes in bone mineral density of the proximal femur and spine with aging. *J Clin Invest* 1982;70:716-23
31. Taguchi A, Tanimoto K, Ogawa M, Sunayashiki T, Wada T. Effect of size of region of interest on precision of bone mineral measurements of the mandible by quantitative computed tomography. *Dentomaxillofac Radiology* 1991; 20: 25-29.
32. Baran DT, Faulkner KG, Genant HK, Miller PD, Pacifici R. Diagnosis and management of osteoporosis: guidelines for the utilization of bone densitometry. *Calcif Tissue Int*, 1997; 61: 433-440.

Figure legends

Fig. 1 Intraoral radiograph of the lower jaw with inner and outer region of interest.

Fig. 2 Intraoral radiograph of the upper jaw with inner and outer region of interest.

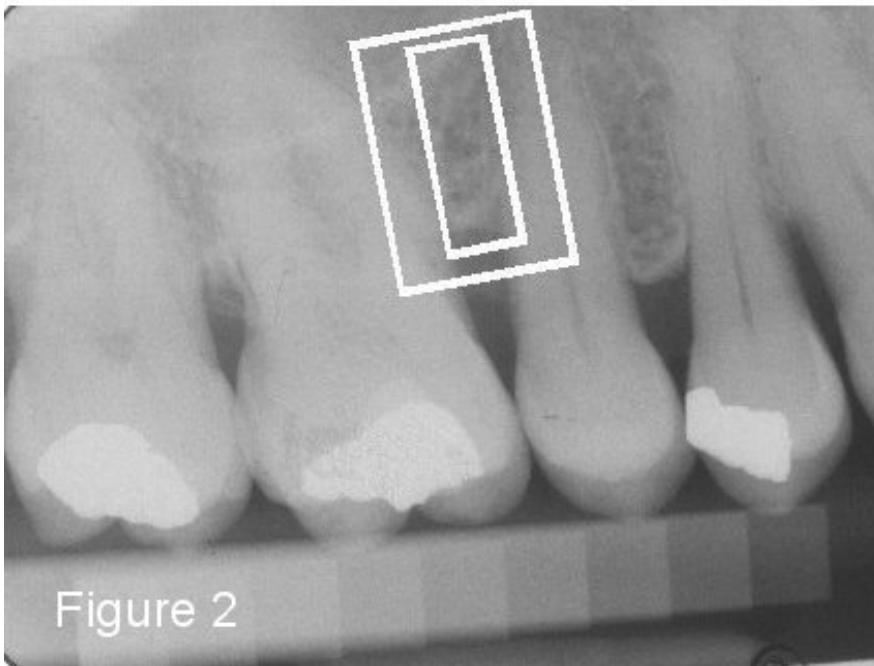
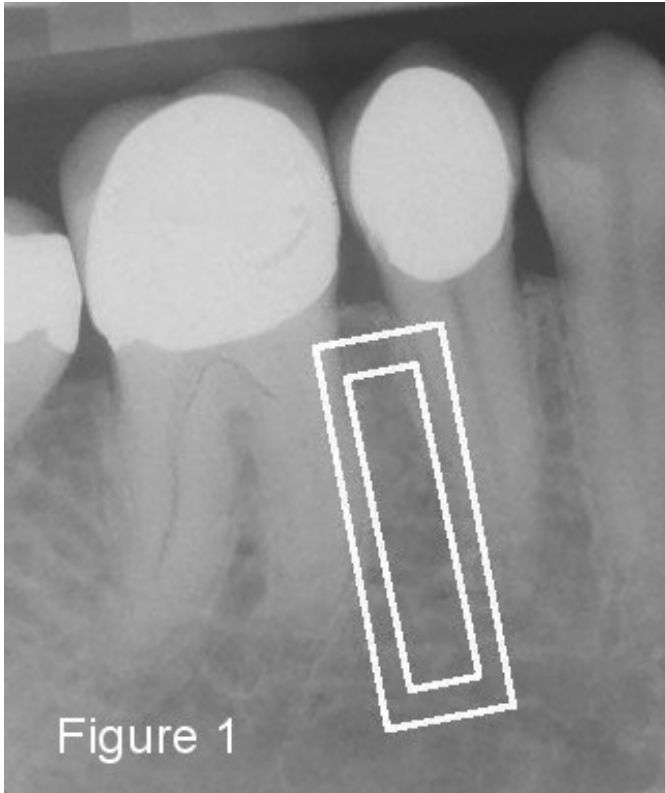


Table 1: Standardised BMD of Femoral neck and Lumbar spine for 6 age groups.

Age	N	Femoral neck	Lumbar spine
45 - 49	119	0.80 ± 0.13	1.03 ± 0.15
50 - 54	177	0.77 ± 0.12	1.00 ± 0.17
55 - 59	132	0.72 ± 0.14	0.92 ± 0.18
60 - 64	79	0.70 ± 0.12	0.90 ± 0.18
65 - 69	33	0.64 ± 0.15	0.82 ± 0.19
70 - 74	9	0.66 ± 0.11	0.85 ± 0.21
Total	549	0.75 ± 0.14	0.96 ± 0.18

Table 2: Squared multiple correlation coefficient (proportion of variance) for femoral bone mineral density.

	Inner region	Outer region	Inner + Outer region
Age	10%	10%	10%
Age + radiograph upper jaw	18%	18%	24%
Age + radiograph lower jaw	17%	18%	23%
Age + radiograph upper jaw + radiograph lower jaw	23%	26%	34%

Table 3: Squared multiple correlation coefficient (proportion of variance) for spinal bone mineral density.

	Inner region	Outer region	Inner + Outer region
Age	14%	14%	14%
Age + radiograph upper jaw	22%	22%	27%
Age + radiograph lower jaw	20%	21%	25%
Age + radiograph upper jaw + radiograph lower jaw	27%	28%	36%