



## UvA-DARE (Digital Academic Repository)

### X linked adrenoleukodystrophy: clinical presentation, diagnosis, and therapy

van Geel, B.M.; Assies, J.; Wanders, R.J.A.; Barth, P.G.

**DOI**

[10.1136/jnnp.63.1.4](https://doi.org/10.1136/jnnp.63.1.4)

**Publication date**

1997

**Published in**

Journal of Neurology, Neurosurgery and Psychiatry

[Link to publication](#)

**Citation for published version (APA):**

van Geel, B. M., Assies, J., Wanders, R. J. A., & Barth, P. G. (1997). X linked adrenoleukodystrophy: clinical presentation, diagnosis, and therapy. *Journal of Neurology, Neurosurgery and Psychiatry*, 63, 4-14. <https://doi.org/10.1136/jnnp.63.1.4>

**General rights**

It is not permitted to download or to forward/distribute the text or part of it without the consent of the author(s) and/or copyright holder(s), other than for strictly personal, individual use, unless the work is under an open content license (like Creative Commons).

**Disclaimer/Complaints regulations**

If you believe that digital publication of certain material infringes any of your rights or (privacy) interests, please let the Library know, stating your reasons. In case of a legitimate complaint, the Library will make the material inaccessible and/or remove it from the website. Please Ask the Library: <https://uba.uva.nl/en/contact>, or a letter to: Library of the University of Amsterdam, Secretariat, Singel 425, 1012 WP Amsterdam, The Netherlands. You will be contacted as soon as possible.



## X linked adrenoleukodystrophy: clinical presentation, diagnosis, and therapy

Björn M van Geel, Johanna Assies, Ronald J A Wanders and Peter G Barth

*J. Neurol. Neurosurg. Psychiatry* 1997;63;4-14

---

Updated information and services can be found at:  
<http://jnp.bmj.com/cgi/content/full/63/1/4>

---

*These include:*

- |                               |   |
|-------------------------------|---|
| <b>References</b>             | This article cites 122 articles, 41 of which can be accessed free at:<br><a href="http://jnp.bmj.com/cgi/content/full/63/1/4#BIBL">http://jnp.bmj.com/cgi/content/full/63/1/4#BIBL</a><br><br>8 online articles that cite this article can be accessed at:<br><a href="http://jnp.bmj.com/cgi/content/full/63/1/4#otherarticles">http://jnp.bmj.com/cgi/content/full/63/1/4#otherarticles</a> |
| <b>Rapid responses</b>        | You can respond to this article at:<br><a href="http://jnp.bmj.com/cgi/eletter-submit/63/1/4">http://jnp.bmj.com/cgi/eletter-submit/63/1/4</a>  |
| <b>Email alerting service</b> | Receive free email alerts when new articles cite this article - sign up in the box at the top right corner of the article   |
- 

### Notes

---

To order reprints of this article go to:  
<http://www.bmjournals.com/cgi/reprintform>

To subscribe to *Journal of Neurology, Neurosurgery, and Psychiatry* go to:  
<http://www.bmjournals.com/subscriptions/>

## REVIEW

## X linked adrenoleukodystrophy: clinical presentation, diagnosis, and therapy

Björn M van Geel, Johanna Assies, Ronald J A Wanders, Peter G Barth

### Abstract

**X linked adrenoleukodystrophy (X-ALD) is an inherited disorder of peroxisomal metabolism, biochemically characterised by accumulation of saturated very long chain fatty acids. Accumulation of these fatty acids is associated with cerebral demyelination, peripheral nerve abnormalities, and adrenocortical and testicular insufficiency. The lowest estimated birth incidence is one per 100 000. At least six phenotypes can be distinguished, of which the two most frequent are childhood cerebral ALD and adrenomyeloneuropathy. The X-ALD gene has been identified, but thus far no relation between genotype and phenotype has been found. Diagnosis is relatively easy and can be confirmed reliably, and prenatal testing is possible in affected families. Several therapeutic options, some with promising perspectives, are available. Neurologists and other physicians seem not to be familiar with the many facets of X-ALD. In this review, the clinical presentation, the relative frequencies of the different phenotypes, and the diagnostic and therapeutic options are presented.**

(*J Neurol Neurosurg Psychiatry* 1997;63:4-14)

Keywords: adrenoleukodystrophy; adrenomyeloneuropathy; very long chain fatty acids; peroxisome

More than seven decades have passed since Siemerling and Creutzfeldt reported a seven year old previously healthy boy with a bronzed skin, behavioural abnormalities, dysphagia, and spasticity of the lower limbs.<sup>1</sup> Within months he became tetraplegic, developed dysarthria and seizures, and died six months after presentation. Postmortem examination disclosed atrophy of the adrenal cortex and diffuse cerebral sclerosis. In 1963 an X linked mode of inheritance was suggested,<sup>2</sup> and in the mid-1970s the term adrenoleukodystrophy was coined for this mysterious disorder.<sup>3</sup> Apparently only boys were affected by the disease, now known as X linked adrenoleukodystrophy (X-ALD). Adrenomyeloneuropathy (AMN), a more indolent phenotypic variant

that has its onset in adulthood, was first reported in 1976.<sup>4</sup> Now, at least six different phenotypes are recognised.<sup>5</sup> Not only men are affected: in the early 1980s it was shown that female carriers are at risk for developing neurological deficits as well.<sup>6</sup>

In 1976 the accumulation of saturated very long chain fatty acids (VLCFAs) in brain lipids and adrenal cortex of patients with X-ALD was reported.<sup>7,8</sup> In 1980 raised concentrations of VLCFAs were shown in cultured skin fibroblasts<sup>9</sup> and in 1981 in plasma,<sup>10</sup> thus providing a reliable biochemical diagnostic test. In 1984 a defect in peroxisomal metabolism was suggested,<sup>11</sup> and shortly thereafter the defective enzyme activity in peroxisomal  $\beta$ -oxidation of VLCFAs was discovered.<sup>12,13</sup> In 1981 the X-ALD locus was mapped to Xq28,<sup>14</sup> and in 1993 the gene predisposing for X-ALD was identified.<sup>15</sup>

Nevertheless, many physicians are still unfamiliar with X-ALD and its many facets. Although the disease is rare, the estimated birth incidence is at least one per 100 000.<sup>5,16,17</sup> Early identification is mandatory, as untreated patients with adrenocortical insufficiency need steroid hormone substitution therapy. Genetic counselling should be performed, and prenatal diagnosis is possible and desired in affected families.<sup>18</sup> Dietary treatment with "Lorenzo's oil"<sup>19</sup> can be considered, particularly in male patients without neurological symptoms, and cerebral demyelination in boys may be halted or reversed by bone marrow transplantation.<sup>20</sup> Furthermore, gene therapy may become a serious therapeutic option in the near future.<sup>21,22</sup> The aim of this review is to familiarise neurologists and other physicians with the clinical presentation of X-ALD and the diagnostic and therapeutic options.

### Clinical manifestations

#### HEMIZYGOTES

The classification of the different phenotypes of X-ALD is somewhat arbitrary, and based on the age of onset and the organs principally affected. At present, at least six variants can be distinguished (table).<sup>5</sup> The two most frequent phenotypes, that account for about 80% of all cases, are childhood cerebral ALD and adrenomyeloneuropathy.<sup>5,16,23,24</sup> The delay

Department of Neurology, Academic Medical Center, University of Amsterdam, PO Box 22700, 1100 DE Amsterdam, the Netherlands  
B M van Geel

Departments of Psychiatry and Internal Medicine  
J Assies

Department of Clinical Biochemistry, Academic Medical Center, University of Amsterdam, PO Box 22700, 1100 DE Amsterdam, the Netherlands  
R J A Wanders

Departments of Neurology and Pediatrics, Academic Medical Center, University of Amsterdam, PO Box 22700, 1100 DE Amsterdam, the Netherlands  
P G Barth

Correspondence to:  
Dr B M van Geel,  
Department of Neurology,  
Academic Medical Center,  
University of Amsterdam,  
PO Box 22700, 1100 DE  
Amsterdam, the Netherlands.

Received 9 December 1996  
and in revised form  
11 February 1997  
Accepted 14 February 1997

## Clinical characteristics of the different phenotypes of X-ALD in hemizygotes

	Pre- or asymptomatic ALD	CCALD	AdolCALD	ACALD	AMN	Addison only
Relative frequencies (%)	4-10		31-57	1-3	25-46	8-14
Age at onset of neurological symptoms	-	< 10	10-21	> 21	> 18; frequent 3rd-4th decade	> 2
Behavioural disturbances	-	+	+	+	-	-
Impaired cognition	-	+	+	Frequent	-	-
Pyramidal tract involvement	-	Eventually, not initially	Eventually, not initially	Frequent	Present by definition	-
Cerebral MRI abnormalities	Absent or mild*	Extensive in occipital or frontal myelin	Extensive in occipital or frontal myelin	Extensive in occipital or frontal myelin	Internal capsule basal ganglia, mesencephalon, pons	Absent or mild*
Polyneuropathy	-	-	Rare	Possible	Sensorimotor, mostly axonal	-
Abnormal evoked potentials	-	VEP, BAEP (not initially) sometimes SEP	VEP, BAEP (not initially)	VEP (not initially), BAEP sometimes SEP	BAEP, SEP	Sometimes BAEP
Impaired endocrine function	-	AD in most	AD in most	AD in most	AD and hypogonadism in most	AD by definition
Abnormal neuropsychological examination	-	+	+	Frequent	-	-
Progression	-	Rapidly, rarely slowly	Rapidly, rarely slowly	Rapidly, sometimes slowly	Slowly, sometimes rapidly	-

- = Absent; + = present; \* = depending on definition; CCALD = childhood cerebral ALD; AdolCALD = adolescent cerebral ALD; ACALD = adult cerebral ALD; AMN = adrenomyeloneuropathy; VEP = visual evoked potential; BAEP = brainstem auditory evoked potential; SEP = somatosensory evoked potential; AD = adrenocortical insufficiency (Addison's disease).

between onset and diagnosis may be long, particularly in probands.<sup>25</sup>

About two thirds of the male patients with neurological dysfunction also have overt or subclinical adrenocortical insufficiency (Addison's disease).<sup>26</sup> This may precede, accompany, or follow the onset of neurological symptoms. Virtually all affected men have manifest or subclinical testicular insufficiency (Assies *et al*, unpublished data), and many have typical, scanty scalp hair (fig 1).

#### Childhood cerebral ALD

Childhood cerebral ALD (CCALD) is characterised by rapidly progressive cerebral demyelination.<sup>27 28</sup> The onset is between 3 and 10 years of age. Frequent early neurological symptoms are behavioural disturbances, poor school performance, deterioration of vision,

and impaired auditory discrimination. The course is relentlessly progressive, and seizures, spastic tetraplegia, and dementia become manifest within months. Figure 2 shows a typical patient with CCALD. Most patients die within two to three years after the onset of neurological symptoms.<sup>5</sup> However, some patients survive longer, albeit in a persistent vegetative state. In 80% of patients with CCALD, cerebral MRI typically shows extensive demyelination in the occipital periventricular white matter (fig 3).<sup>29</sup> The early symptoms of CCALD are often attributed to an attention deficit disorder or hyperactivity. Before the advent of reliable diagnostic tests and MRI, metachromatic leukodystrophy, ceroid lipofuscinosis, globoid cell leukodystrophy (Krabbe's disease), and subacute sclerosing panencephalitis were sometimes diagnosed instead of CCALD.<sup>5</sup>

#### Adolescent cerebral ALD

Adolescent cerebral ALD (AdolCALD) occurs much less often. The symptoms and progression are similar to those of CCALD, but the onset is between 10 and 21 years of age (fig 4).

#### Adult cerebral ALD (ACALD)

Very rarely, cerebral demyelination occurs in adult hemizygotes and causes symptoms as seen in CCALD.<sup>30-35</sup> These patients may be misdiagnosed as having paranoid psychosis, schizophrenia, or other psychiatric disorders. The illness may progress rapidly.

#### Adrenomyeloneuropathy (AMN)

At least in The Netherlands, AMN (fig 5) is the most common phenotype of X-ALD.<sup>16</sup> The onset of neurological symptoms in this phenotype usually occurs in the third and fourth

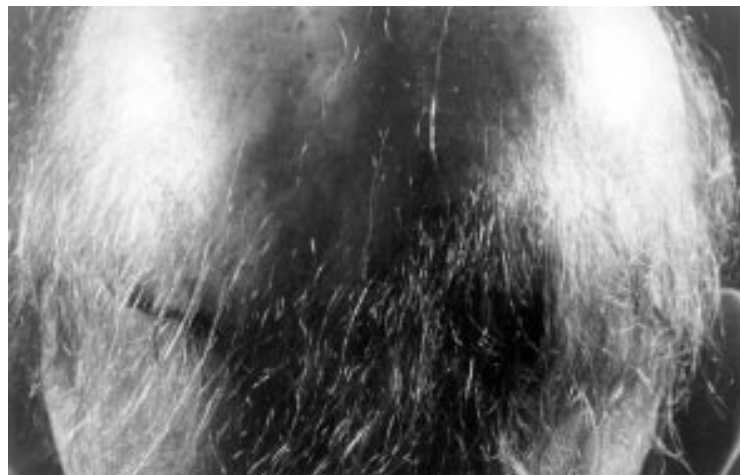
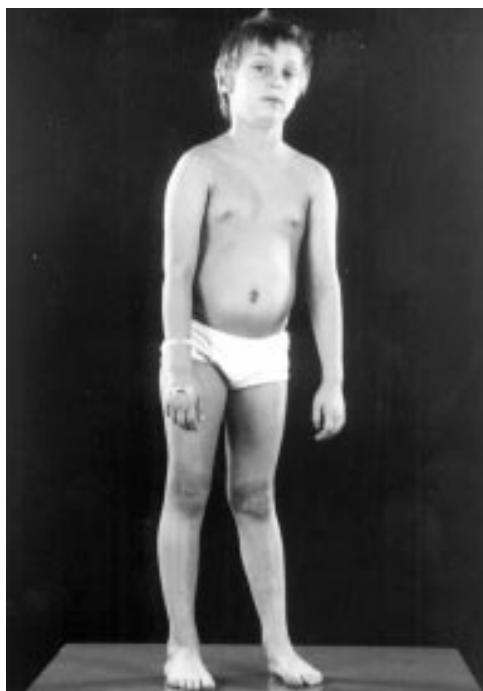
Figure 1 The typical scanty scalp hair that can be seen in all phenotypes. This patient with AMN developed the hair pattern during adolescence.

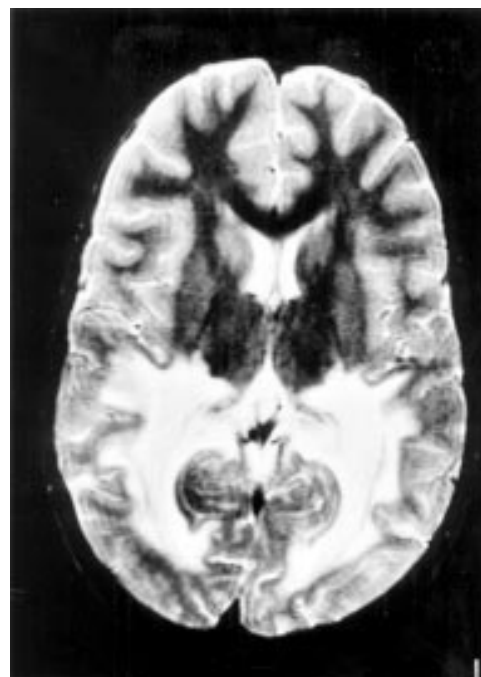


*Figure 2* A 7 year old boy with CCALD. Until the age of 6 years psychomotor development was normal. At the age of 6 impaired auditory discrimination was noted. Shortly thereafter his vision became impaired and he developed seizures and a spastic tetraparesis as shown in this photograph. He died two years after the onset of neurological symptoms.

decade.<sup>16 36</sup> Neurological deficits are primarily due to myelopathy, and to a lesser extent to neuropathy.<sup>4 28 37</sup> Patients gradually develop a spastic paraparesis, often in combination with disturbed vibration sense in the legs and voiding disturbances. About 50% of men with AMN show mild to moderate cerebral involvement on MRI, and in some the abnormalities in white matter may resemble the demyelination seen in CCALD; the spinal cord is often atrophic.<sup>38 39</sup> Nerve conduction studies and EMG are compatible with a predominantly axonal, sensorimotor polyneuropathy.<sup>40 41</sup> Life expectancy is probably normal, unless patients additionally develop cerebral demyelination, or when adrenocortical insufficiency is not recognised and remains untreated. In many patients with AMN neurological diseases such as chronic progressive multiple sclerosis and hereditary spastic paraparesis were initially diagnosed.<sup>5 25 42</sup>

#### *The "Addison only" phenotype*

Some patients have isolated adrenocortical dysfunction (Addison's disease), manifested by fatigue, hypotension, and diffuse or focal bronzing of the skin. Laboratory studies in these patients show raised plasma concentrations of adrenocorticotrophin (ACTH), often in combination with lowered cortisol concentrations in plasma, or inadequate cortisol increases after ACTH stimulation. Several studies have disclosed that a variable, though possibly substantial percentage (4% to 63%) of patients with Addison's disease in fact may have the "Addison only" phenotype of X-ALD.<sup>24 43-47</sup> The risk for developing neurological involvement is very high



*Figure 3* Cerebral T2 weighted MRI of an 8 year old boy with impaired visual acuity and seizures due to CCALD. The extensive damage inflicted on the occipital periventricular white matter is evident. Three of his maternal uncles died before the age of 10, but his mother had normal VLCFAs in plasma and skin fibroblasts and somehow had understood that she could not be a heterozygote. Retrospectively, his first neurological symptoms consisted of divergent strabismus for which he was operated on twice. He died at the age of 10 years (MRI courtesy of Dr EL Mooyaart, University Hospital, Groningen, the Netherlands.)

indeed. However, we examined a 78 year old biochemically affected man with adrenocortical insufficiency who, considering his age, had a normal neurological examination and a normal cerebral MRI.

#### *Asymptomatic or presymptomatic patients*

Some patients, in particular those identified by family screening, may neither have neurological nor endocrinological abnormalities, even in the presence of mild cerebral involvement as evidenced by MRI<sup>48</sup> or MR spectroscopy.<sup>49</sup> Although there is no consensus, we regard these patients as presymptomatic or asymptomatic, and consider a patient symptomatic once the neurological examination or neuropsychological tests disclose abnormalities. The risk for asymptomatic patients to develop neurological symptoms is high. However, some patients may remain asymptomatic into their 60s.<sup>50</sup>

#### *Atypical presentations*

Very rarely, patients with X-ALD display symptoms resembling olivoponto-cerebellar atrophy<sup>51-53</sup> or spinocerebellar degeneration.<sup>54</sup> Unilateral neurological deficits do not exclude X-ALD.<sup>55</sup> It has been suggested that head injury can precipitate or accelerate cerebral demyelination.<sup>55 56</sup>

Powers and Schaumburg reported that the first symptoms of X-ALD may be caused by gonadal insufficiency.<sup>57</sup> In a series of 26 adult

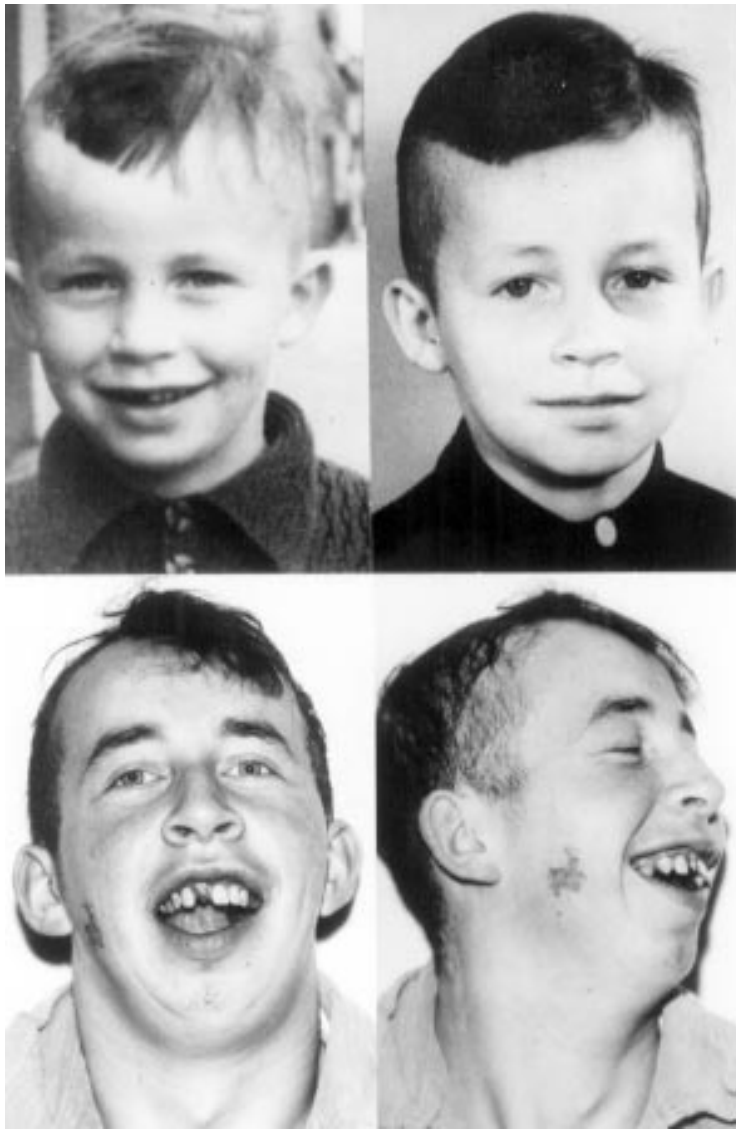

Figure 4 Dramatic metamorphosis of a healthy 6 year old boy into a demented and spastic 17 year old adolescent. The initial diagnosis was myoclonus epilepsy, but retrospectively AdoCALD was diagnosed after one of his cousins had died from CCALD.

patients with X-ALD, we found four men with only signs of hypogonadism (Assies *et al*, unpublished data).

#### PHENOTYPIC VARIABILITY AMONG AFFECTED KINDREDS

In 178 kindreds Moser *et al* found only cerebral variants in 30%, only AMN in 20%, and both CCALD and AMN in 50%.<sup>5</sup> In 15 Dutch kindreds, we found only CCALD in 20%, only AMN in 40%, and both cerebral variants and AMN in 40%.<sup>16</sup> So it is possible that in a family with AMN, someone will develop CCALD, and vice versa. Even siblings may have different phenotypes.<sup>58 59</sup>

#### HETEROZYGOTES

As many as 20% to 50% of all heterozygotes may show neurological symptoms resembling those of AMN.<sup>16 50</sup> The onset usually is in the fourth decade, symptoms are milder, and the progression is slower than in the patients with AMN. On cerebral MRI abnormalities in white



Figure 5 This 44 year old man with AMN shows a posture resulting from a slowly progressive spastic paraparesis with an onset 15 years earlier. He also shows the typical scanty scalp hair.

matter are found in about 20% of the heterozygotes.<sup>39</sup>

Often, chronic progressive multiple sclerosis is suspected initially in symptomatic carriers.<sup>25 50 60 61</sup> In The Netherlands, at least one female carrier underwent a cervical laminectomy because of suspected stenosis of the cervical spinal canal, whereas X-ALD remained unnoticed.

Exceptionally, heterozygotes may develop rapidly progressive cerebral demyelination.<sup>62-64</sup> In an interview with members of an affected family, we learned that a Dutch girl developed bronzing of her skin and neurological symptoms attributable to cerebral demyelination and died at the age of 14 years.

Overt adrenocortical dysfunction in female carriers has been reported,<sup>62 65</sup> but in general adrenocortical function is normal.<sup>26</sup> The scanty scalp hair in most male patients can also be found in heterozygotes.<sup>66</sup>

#### Epidemiology

X-ALD is considered by many to be very rare, although neither prevalence nor incidence are exactly known. The disease is found among all races and on all continents. For The Netherlands we estimated a frequency of at least one in 100 000 male births, and a prevalence of at least one in 200 000.<sup>16</sup> Surveys in France<sup>17</sup> and in the United States<sup>5</sup> showed a similar frequency.

Aubourg *et al*<sup>24</sup> and Moser *et al*<sup>26</sup> reported in the early 1990s that the variants dominated by cerebral demyelination prevailed (more than 50% of all cases) in France and the United

States. We reported that AMN is the predominant phenotype (46% of all cases), at least in The Netherlands.<sup>16</sup> Moser *et al* assumed that ascertainment bias might have influenced the results in previous reports, and that the Dutch phenotypic distribution may be more precise.<sup>67</sup> Indeed, the rapidly progressive variants of X-ALD prompt extensive investigations such as cerebral MRI and analysis of VLCFAs, whereas the more indolent variants such as AMN or the "Addison only" phenotype are often overlooked or misdiagnosed. The thorough screening of affected Dutch kindreds has been facilitated by the small area of The Netherlands, the high density of population, the insurance level of nearly 100%, and the decentralisation and accessibility of healthcare facilities. Indeed, over the past years the relative frequencies of CCALD and AMN in France and the United States are shifting towards the Dutch percentages (P Aubourg, HW Moser, personal communications).

### Biochemical abnormalities

In 1976, the first report appeared on the characteristic accumulation of saturated unbranched very long chain fatty acids (VLCFAs), in particular hexacosanoic acid (C26:0).<sup>7</sup> This accumulation is due to an impaired capacity to  $\beta$ -oxidise these fatty acids. As very long chain fatty acyl-CoA esters were metabolised in peroxisomes, it was reasoned that the defect was at the level of the very long chain acyl-CoA synthetase (or ligase). The  $\beta$ -oxidation of VLCFAs occurs exclusively in peroxisomes.<sup>11-13 68 69</sup>

Peroxisomes are intracellular organelles that are present in virtually every cell, except for the mature erythrocyte.<sup>70 71</sup> Their abundance and size vary from tissue to tissue: they are prominent in liver and kidney, but relatively rare in the nervous system. The biochemical reactions that occur in peroxisomes are many, the most important being the aforementioned  $\beta$ -oxidation of VLCFAs, biosynthesis of plasmalogens and bile acids, and glyoxylate detoxification.<sup>72</sup> Peroxisomal disorders are tentatively subdivided into three distinct groups.<sup>73</sup> In group I, peroxisomal biogenesis is impaired and peroxisomes are virtually absent (for example, Zellweger syndrome and neonatal adrenoleukodystrophy). In group II, peroxisomes are present, but multiple peroxisomal functions are lost (for example, rhizomelic chondrodysplasia punctata). The most frequent peroxisomal disorder, X-ALD, belongs to group III in which only one peroxisomal function is deficient.

### Genetics

In 1981 X-ALD was linked to the long arm of the X chromosome (Xq28).<sup>14</sup> It took 12 years to identify the X-ALD gene.<sup>15</sup> It spans 21 kb, contains 10 exons, and encodes a protein of 745 amino acids with significant homology to the peroxisomal membrane protein PMP-70, belonging to the "ATP binding cassette" superfamily of transporters. Monoclonal antibodies were raised against this X-ALD protein (ALDP), and it was shown that the ALDP is

incorporated in the peroxisomal membrane.<sup>74</sup> Its precise function remains to be determined, but it is somehow involved in the activation of VLCFAs or the import of these fatty acids into peroxisomes.<sup>75</sup>

Worldwide, patients with X-ALD have mutations in the X-ALD gene,<sup>76-79</sup> by contrast with healthy controls.<sup>77</sup> Often, a 2 bp deletion in exon 5 is found.<sup>77 79 80</sup> So far, no correlation was found between genotype and phenotype.<sup>76-79</sup> An autosomal modifier gene has been suggested,<sup>36 81</sup> but so far has not been identified. Surprisingly, a variation in phenotypic expression has even been found in monozygotic twins,<sup>82 83</sup> suggesting that non-genetic factors may also be involved in the varying phenotypic expression.

### Pathological findings

Abnormalities are particularly found in the central and peripheral nervous system, testis, and adrenal cortex.<sup>4 27 28 37 84 85</sup> Characteristic are the lamellar cytoplasmic inclusions in brain macrophages, Schwann cells, Leydig cells, and adrenocortical cells. These lamellar inclusions consist of cholesterol esterified with VLCFAs.<sup>8</sup>

Postmortem examination in the cerebral variants of X-ALD shows widespread periventricular demyelination and cavitation, most severe in the occipital region, with sparing of the U fibres and cerebral cortex, and perivascular lymphocytic infiltrates.<sup>28 86</sup> Peripheral nerve abnormalities are uncommon and minimal in comparison with the cerebral lesions.

In AMN, mainly the spinal cord and, to a lesser extent, peripheral nerves are affected. Perivascular lymphocytic infiltrates may be found, but they are much less prominent than in CCALD. It is suggested that, by contrast with the cerebral variants with their characteristic severe demyelination, AMN in fact is a distal axonopathy with secondary degeneration of myelin in the most distant part of the axons.<sup>28</sup>

### Pathogenesis

The accumulation of VLCFAs has long been held responsible for damage inflicted to the nervous system, testis, and adrenal cortex. An excess of VLCFAs may be toxic to adrenocortical cells.<sup>28</sup> The incorporation of abnormal amounts of VLCFA laden lipids in the membranes of cultured human adrenocortical cells influenced the response to ACTH stimulation.<sup>87</sup>

However, the exact mechanisms by which the nervous system is damaged remain to be unravelled. It is hypothesised that immune mechanisms are involved in the cerebral variants of X-ALD: perivascular mononuclear accumulations compatible with a cellular immune response are found in active brain lesions in CCALD and AdolCALD,<sup>86</sup> and CSF examination showed a raised IgG index in about 30% of patients with CCALD and AdolCALD.<sup>27 86 88</sup> A two stage scheme has been suggested: at first there is degradation of myelin due to its instability by an excess of VLCFAs, followed by an inflammatory reaction that

destroys the myelin.<sup>28 89</sup> By contrast with the cerebral variants of X-ALD, inflammatory infiltrates are scarce in AMN.<sup>37</sup>

Thus far there is no evidence that the severity of the biochemical defect, as measured by the plasma concentration of VLCFAs, accounts for the phenotypic variability.<sup>5</sup> However, a correlation between impairment of nerve conduction and VLCFAs was recently found.<sup>41</sup>

### Diagnosis

The discovery that VLCFAs, particularly hexacosanoic acid, are raised in cultured skin fibroblasts,<sup>9 90</sup> plasma,<sup>10</sup> erythrocytes,<sup>91</sup> and leucocytes,<sup>92</sup> led to reliable and relatively simple biochemical diagnostic tests becoming available. Most laboratories measure the absolute concentration of C26:0 as well as the C24:0/C22:0 and C26:0/C22:0 ratios.<sup>73</sup> DNA linkage analysis has also been used for postnatal and prenatal diagnosis,<sup>93-95</sup> and after the identification of the X-ALD gene, mutational analysis became available. Monoclonal antibodies have been raised against ALDP, and may facilitate the diagnosis in people at risk.<sup>79 96 97</sup>

#### POSTNATAL DIAGNOSIS

##### *Biochemical assays*

In virtually all male patients with X-ALD the plasma concentrations of C26:0 and the C24:0/C22:0 and C26:0/C22:0 ratios are clearly increased: in 0.1% of affected males the plasma C26:0 is borderline normal or mildly increased, but the ratios are abnormal.<sup>5</sup> In generalised peroxisomal disorders (for example, the Zellweger syndrome and neonatal adrenoleukodystrophy) the concentrations of VLCFAs are raised as well, but both the pattern of the VLCFAs and the clinical presentation differ widely from X-ALD. Analysis of VLCFAs in cultured skin fibroblasts is also possible.<sup>9 90</sup> In addition, the oxidation rate of VLCFAs in skin fibroblasts can be measured.<sup>13</sup>

Nevertheless, plasma concentrations of C26:0 at the upper limit of normal, but certainly not abnormally increased, have recently been reported in two male patients.<sup>98 99</sup> In these patients diagnosis was finally established by elevated concentrations of VLCFAs in cultured skin fibroblasts, and abnormal plasma VLCFA concentrations in one of the mothers.

In a study conducted in 96 obligate female carriers, the combined results of VLCFA concentrations in plasma and skin fibroblasts were abnormal in 93%.<sup>100</sup> Consequently, about 5% to 10% of female carriers have false negative test results. This is probably due to the compensatory function of their non-affected X chromosomes.

##### *Other tests*

DNA linkage analysis with the DXS52 marker can be used, in particular for the identification of heterozygotes, when the necessary relatives are available, and when it is informative at the X-ALD locus.<sup>93 94</sup>

Immunofluorescence studies in cultured skin fibroblasts or leucocytes may aid in the identification heterozygous females, in particular when VLCFA concentrations in plasma and fibroblasts are normal. In 70% to 80% of the affected kindreds affected boys and men lack ALDP immunoreactivity in cultured skin fibroblasts or leucocytes; female carriers in these kindreds show a mixture of positive and negative immunoreactivity.<sup>79 96 97</sup>

Mutational analysis is another option once a certain mutation has been shown in an affected family.<sup>76</sup> However, this technique is very laborious, and, to our knowledge, not yet carried out routinely.

#### PRENATAL DIAGNOSIS

Prenatal diagnosis has been performed by VLCFA analysis in cultured amniotic fluid cells<sup>101</sup> and cultured chorionic villus cells.<sup>102</sup> So far, there have been two reports of false negative test results of a VLCFA assay in cultured chorionic villus cells.<sup>103 104</sup> DNA linkage analysis with the DXS52 DNA probe is also possible.<sup>94 95</sup> Recently, prenatal diagnosis by means of mutational analysis was reported.<sup>105</sup>

False negative and false positive results both have far reaching consequences. In the first a boy may develop CCALD, and in the second a pregnancy might be needlessly terminated. Therefore, the most reliable diagnostic procedures should be used. Unfortunately, mutational analysis is not yet routinely available.

#### DIAGNOSTIC STRATEGY

When X-ALD is suspected, the first diagnostic step consists of analysis of VLCFAs in plasma. An abnormal test result should always be followed by a repeat assay in another sample to exclude problems such as sample mix up. If the test results are abnormal and peroxisomal disorders with neonatal onset are excluded (for example, Zellweger syndrome or neonatal adrenoleukodystrophy),<sup>106</sup> the patient has a biochemical defect consistent with X-ALD. We perform VLCFA assays in cultured skin fibroblasts in all probands and in females at risk for heterozygosity.

If the patient is the proband, or if a mutation has not yet been shown in a kindred, mutational analysis is desirable. The presence of ALDP in skin fibroblasts or leucocytes should be investigated, as abnormal ALDP expression on immunofluorescence staining may eventually aid in the identification of heterozygotes.

### Therapy

After the discovery of increased concentrations of VLCFAs in blood and other tissues of patients with X-ALD, several dietary treatments were developed. Bone marrow transplantation and immunosuppressive therapies are currently investigated.

Before reviewing these, we emphasise that the adrenocortical insufficiency, found in most patients with X-ALD, if left untreated, may be lethal. Therefore, the adrenocortical function, either measured by plasma ACTH and cortisol



concentrations, or by the rise in cortisol after ACTH stimulation,<sup>107</sup> should be tested in all affected male patients at regular intervals, unless they are already on steroid hormone substitution therapy.

#### DIETARY THERAPY

After the finding that orally administered C26:0 reached the brain of a terminally ill patient with CCALD,<sup>108</sup> it was reasoned that the VLCFA accumulation was at least in part of dietary origin. However, a diet reducing the intake of products rich in VLCFAs failed to lower plasma concentrations.<sup>109</sup> Later, an excess of VLCFA biosynthesis was shown in skin fibroblasts obtained from patients with X-ALD.<sup>110 111</sup> Oleic acid (C18:1), a monounsaturated fatty acid, was shown to competitively inhibit the fatty acid elongation system, thus interfering with the biosynthesis of VLCFAs.<sup>111</sup> With the combination of fat restriction and oral supplementation with glyceroltrioleate (oleic acid in triglyceride form, or GTO) it was possible to reduce plasma VLCFA concentrations by about 50%.<sup>112 113</sup> After glycerol trierucate (erucic acid (C22:1) in triglyceride form, GTE) was added, a dramatic lowering of the plasma concentration of C26:0 was noted: in most patients C26:0 concentrations normalised within a month.<sup>114</sup> The 4:1 combination of the GTO and GTE oils became known as "Lorenzo's oil", as a tribute to Lorenzo Odone, a boy with CCALD, whose parents helped to develop the dietary treatment.<sup>19</sup> Trials with "Lorenzo's oil" were started worldwide, and hundreds of patients were—and still are—treated.

Because of the dramatic progression of the cerebral variants of X-ALD, the impressive biochemical effect, the relatively few patients, and the considerable phenotypic variability, open studies were preferred to randomised, placebo controlled, and double blinded studies. This has complicated the evaluation of the efficacy of the treatment tremendously. Results of the dietary treatment thus far have been disappointing. "Lorenzo's oil" did not halt the neurological progression in the cerebral forms of X-ALD.<sup>23 36 115 116</sup> This may be explained by the failure of the dietary oil to reach the brain.<sup>117 118</sup> Nevertheless, a retrospective analysis of the efficacy of Lorenzo's oil in patients with CCALD indicated that there was slight but significant slowing of progression of symptoms and delay of death.<sup>119</sup> In 14 men with AMN and five symptomatic female carriers, "Lorenzo's oil" failed to induce a neurological benefit.<sup>120</sup> Furthermore, endocrine function did not improve in five patients with AMN.<sup>121</sup> On the other hand, side effects such as thrombocytopenia were often found,<sup>122-125</sup> fortunately not resulting in a haemorrhagic diathesis. In several Dutch patients, we have found platelet counts below  $40 \times 10^9/l$ , which increased again after the intake of the GTO and GTE products was reduced or discontinued.

Although no beneficial effect of "Lorenzo's oil" was noted in patients with neurological symptoms thus far, we cannot conclude that "Lorenzo's oil" does not postpone the onset of

neurological symptoms in asymptomatic males. The side effects encountered have been relatively mild, and lacking other therapeutic options for asymptomatic or presymptomatic males, we continue to prescribe the GTO and GTE products to neurologically asymptomatic patients, and those symptomatic patients already treated who prefer to adhere to the diet. We no longer recommend the use of "Lorenzo's oil" to the parents of patients with CCALD, and newly diagnosed patients with AMN, and symptomatic female carriers.

#### BONE MARROW TRANSPLANTS

Postmortem examinations of the brain of patients with the cerebral variants of X-ALD have shown perivascular mononuclear infiltrates compatible with an immune reaction.<sup>28 86</sup> This inflammatory reaction has been linked to excess of VLCFAs in myelin lipids in the region of the brain where demyelination takes place.<sup>86 89 126</sup> On the assumption that brain macrophages of patients with X-ALD are unable to remove and degrade the VLCFAs, and that the inflammatory reaction is thus continued, brain macrophages derived from the bone marrow from a donor with normal peroxisomal function might halt the cerebral demyelination.

In 1984 the results of the first bone marrow transplant (BMT) in X-ALD were reported.<sup>127</sup> A 12½ year old boy with cerebral abnormalities showed no improvement of his clinical status, and died of an adenovirus infection 141 days after transplantation. In 1990 the first reversal of neurological and neuroradiological manifestations was reported in an 8 year old boy with CCALD.<sup>128</sup> Six years after BMT he is still alive and well: his cerebral MRI, cognitive function, and neurological examination are normal, despite mildly raised plasma VLCFAs (P Aubourg, personal communication).

Worldwide, some 200 bone marrow transplants have been performed in patients with the intention to treat storage diseases, including CCALD and AdoCALD and other leukodystrophies.<sup>20</sup> Apart from the boy presented by Aubourg in 1990,<sup>128</sup> bone marrow transplantation was shown to reverse or stabilise abnormalities on cerebral MRI<sup>129</sup> and may result in stability of mental ability.<sup>130</sup> Correction of increased plasma VLCFAs before transplantation has been advocated, as this seems to improve the survival of the procedure.<sup>20</sup> Analysis by Moser of data supplied by Krivit, Aubourg and others, showed that up to January 1996 52 patients underwent a bone marrow transplant (HW Moser, personal communication). Nineteen patients, mostly those with severe neurological symptoms, died because of the transplant procedure or neurological progression. The 33 patients who survived in general had mild to moderate neurological involvement, and two thirds of them showed stabilisation or improvement after the procedure. According to Krivit *et al* the donor may even be a heterozygous sister, and because of new techniques to purify donor cells, a bone marrow transplant

should be considered in all instances, even if there is no related match.<sup>20</sup>

Because a bone marrow transplant may be indicated in X-ALD, we perform HLA-typing in a family once a patient at risk for developing cerebral demyelination has been identified. In The Netherlands, a bone marrow transplant is only performed when a suitable donor, preferably an HLA identical sibling, is available and when cerebral involvement is mild, as may be evidenced by abnormalities on neurological and neuropsychological examination. So far, bone marrow transplants have been given to two Dutch boys, one with progressive demyelination of the corpus callosum, and one with impending cerebral demyelination. There were no serious complications, and at one and two years after engraftment, their plasma C26:0 concentrations are mildly raised, and both the neurological and neuropsychological examination are normal.

#### OTHER THERAPEUTIC INTERVENTIONS

Plasmapheresis lowered VLCFA concentrations, but did not alter the progressive course.<sup>131</sup> Clofibrate and L-carnitine were not effective.<sup>109</sup>

Because of the severe inflammatory reaction in the brain of patients with CCALD,<sup>86 89 126</sup> there have been several attempts to suppress this reaction. Immunosuppression with cyclophosphamide, alone or in combination with prednisone, failed to prevent neurological progression in CCALD.<sup>132 133</sup>

There are conflicting reports on the efficacy of treatment with intravenous immunoglobulins (IVIGs). An arrest of neurological dysfunction lasting 18 months was seen in a patient with AdolCALD.<sup>134</sup> On the other hand, in a recent report no differences were shown between the progression of cerebral demyelination in six patients with CCALD or AdolCALD treated with IVIG, and six who did not receive IVIG.<sup>135</sup>

Similarities between the inflammation found in the cerebral forms of CCALD and multiple sclerosis and the effect of  $\beta$ -interferon on the MRI abnormalities in multiple sclerosis<sup>136</sup> led to an increasing interest in the possible treatment of CCALD with  $\beta$ -interferon. A placebo controlled trial with  $\beta$ -interferon in patients with CCALD is now underway in the United States.<sup>137</sup> Recently German investigators found neurological deterioration and progression of cerebral lesions in three boys with CCALD despite treatment with  $\beta$ -interferon.<sup>138</sup>

#### Concluding remarks

X-ALD is probably underdiagnosed as not everyone is aware of the relatively high incidence and the clinical presentations of the different phenotypes of X-ALD, in particular those variants with only mild or no neuroinvolvement. It is important to recognise X-ALD and its many facets, as it is an inherited disease and may result in severe disability or death. Although the pathogenesis of X-ALD is still not completely understood, much progress has been made in its diagnosis, and our better

understanding of the disease has led to several therapeutic options.

In addition to the biochemical diagnostic tests, mutational analysis is possible, and abnormal ALDP immunoreactivity in skin fibroblasts or leucocytes may aid in the identification of patients with X-ALD, in particular female carriers.

The results of dietary treatment with "Lorenzo's oil" so far have been disappointing; however, neurologically asymptomatic patients may still benefit. Bone marrow transplants have a therapeutic potential, but should only be performed in patients with mild cerebral involvement who have a suitable donor. It must not be forgotten that adrenocortical insufficiency may be the only manifestation of X-ALD, and that it has to be treated with steroid hormone substitution.

Retroviral mediated gene transfer corrected VLCFA metabolism for several months in cultured skin fibroblasts obtained from patients with X-ALD.<sup>139</sup> Therefore, it is hoped—and feasible—that in the near future gene therapy may become available for those affected by this severely disabling and potentially lethal disease.<sup>21 22</sup>

This report was financially supported by grant 28-1942 from the Praeventiefonds, the Hague, The Netherlands. We thank the patients and their relatives who permitted us to use their photographs for scientific publications and presentations. We are very grateful to M Vermeulen and J Stam for their critical reading and helpful suggestions.

- Siemerling E, Creutzfeldt HG. Bronzekrankheit und sclerosierende Encephalomyelitis (Diffuse Sklerose). *Archiv für Psychiatrie* 1923;68:217–44.
- Fanconi A, Prader A, Isler W, Luthy F, Siebenmann R. Morbus Addison mit X-chromosomaler Vererbung. *Helvetica Paediatrica Acta* 1963;18:480–501.
- Blaw ME. Melanodermic type leukodystrophy (adrenoleukodystrophy). In: Vinken PJ, et al. *Handbook of clinical neurology*. Vol 10. New York: American Elsevier, 1970:128–33.
- Budka H, Sluga E, Heiss WD. Spastic paraplegia associated with Addison's disease: adult variant of adrenoleukodystrophy. *J Neurol* 1976;213:237–50.
- Moser HW, Smith KD, Moser AB. X-linked adrenoleukodystrophy. In: Scriver CR, et al. *The metabolic and molecular bases of inherited disease*. New York: McGraw-Hill, 1995: 2325–49.
- O'Neill BP, Marmion LC, Feringa ER. The adrenoleukomyeloneuropathy complex: expression in four generations. *Neurology* 1981;31:151–6.
- Igarashi M, Schaumburg HH, Powers J, Kishimoto Y, Kolodny E, Suzuki K. Fatty acid abnormality in adrenoleukodystrophy. *J Neurochem* 1976;26:851–60.
- Johnson AB, Schaumburg HH, Powers JM. Histochemical characteristics of the striated inclusions of adrenoleukodystrophy. *J Histochem Cytochem* 1976;24:725–30.
- Moser HW, Moser AB, Kawamura N, et al. Adrenoleukodystrophy: elevated C26 fatty acid in cultured skin fibroblasts. *Ann Neurol* 1980;7:542–9.
- Moser HW, Moser AB, Frayer KK, et al. Adrenoleukodystrophy: increased plasma content of saturated very long chain fatty acids. *Neurology* 1981;31:1241–6.
- Singh I, Moser AE, Goldfischer S, Moser HW. Lignoceric acid is oxidized in the peroxisome: implications for the Zellweger cerebro-hepato-renal syndrome and adrenoleukodystrophy. *Proc Natl Acad Sci USA* 1984;81:4203–7.
- Lazo O, Contreras M, Hashmi M, Stanley W, Irazu C, Singh I. Peroxisomal lignoceryl-CoA ligase deficiency in childhood adrenoleukodystrophy and adrenomyeloneuropathy. *Proc Natl Acad Sci USA* 1988;85:7647–51.
- Wanders RJA, van Roermund CWT, van Wijland MJA, et al. X-linked adrenoleukodystrophy: defective peroxisomal oxidation of very long chain fatty acids but not of very long chain fatty acyl-CoA esters. *Clin Chim Acta* 1987;165:321–9.
- Migeon BR, Moser HW, Moser AB, Axelman J, Silience D, Norum RA. Adrenoleukodystrophy: evidence for X-linkage, inactivation and selection favouring the mutant allele in heterozygous cells. *Proc Natl Acad Sci USA* 1981;78:5066–70.

- 15 Mosser J, Douar AM, Sarde CO, *et al.* Putative X-linked adrenoleukodystrophy gene shares unexpected homology with ABC transporters. *Nature* 1993;361:726-30.
- 16 van Geel BM, Assies J, Weverling GJ, Barth PG. Predominance of the adrenomyeloneuropathy phenotype of X-linked adrenoleukodystrophy in the Netherlands: a survey of 30 kindreds. *Neurology* 1994;44:2343-6.
- 17 Sereni C, Paturneau-Jouas M, Aubourg P, Baumann N, Feingold J. Adrenoleukodystrophy in France: an epidemiological study. *Neuroepidemiology* 1993;12:229-33.
- 18 Costakos D, Abramson R, Edwards JG, Rizzo WB, Best RG. Attitudes toward presymptomatic testing and prenatal diagnosis for adrenoleukodystrophy among affected families. *Am J Med Genet* 1991;41:295-300.
- 19 Odone A, Odone M. Lorenzo's oil: a new treatment for adrenoleukodystrophy. *J Pediatr Neurosci* 1989;5:55-61.
- 20 Krivit W, Lockman LA, Watkins PA, Hirsch J, Shapiro EG. The future for treatment by bone marrow transplantation for adrenoleukodystrophy, metachromatic leukodystrophy, globoid cell leukodystrophy and Hurler syndrome. *J Inher Metab Dis* 1995;18:398-412.
- 21 Moser HW. Gene therapy in neurology. *Eur Neurol* 1994;34:241-2.
- 22 Leiden JM. Gene therapy - promise, pitfalls and prognosis. *N Engl J Med* 1995;333:871-3.
- 23 Uziel G, Bertini E, Bardelli P, Rimoldi M, Gambetti M. Experience on therapy of adrenoleukodystrophy and adrenomyeloneuropathy. *Dev Neurosci* 1991;13:274-9.
- 24 Aubourg P, Chaussain JL. Adrenoleukodystrophy presenting as Addison's disease in children and adults. *Trends Endocrinol Metab* 1991;2:49-52.
- 25 van Geel BM, Assies J, Haverkort EB, *et al.* Delay in diagnosis of X-linked adrenoleukodystrophy. *Clin Neurol Neurosurg* 1993;95:115-20.
- 26 Moser HW, Bergin A, Naidu S, Ladenson PW. Adrenoleukodystrophy. *Endocrinol Metab Clin North Am* 1991;20:297-317.
- 27 Schaumburg HH, Powers JM, Raine CS, Suzuki K, Richardson EP. Adrenoleukodystrophy: a clinical and pathological study of 17 cases. *Arch Neurol* 1975;32:577-91.
- 28 Powers JM. Adreno-leukodystrophy (adreno-testiculo-leuko-myelo-neuropathic-complex). *Clin Neuropathol* 1985;4:181-99.
- 29 Loes DJ, Hite S, Moser H, *et al.* Adrenoleukodystrophy: a scoring method for brain MR observations. *Am J Neuroradiol* 1994;15:1761-6.
- 30 Powers JM, Schaumburg HH, Gaffney CL. Kluver-Bucy syndrome caused by adreno-leukodystrophy. *Neurology* 1980;30:1131-2.
- 31 James ACD, Kaplan P, Lees A, Bradley JJ. Schizophreniform psychosis and adrenomyeloneuropathy. *J R Soc Med* 1984;77:882-4.
- 32 Esiri MM, Hyman NM, Horton WL, Lindenbaum RH. Adrenoleukodystrophy: clinical, pathological and biochemical findings in two brothers with the onset of cerebral disease in adult life. *Neuropathol Appl Neurobiol* 1984;10:429-45.
- 33 Sereni C, Ruel M, Iba-Zizen T, Baumann N, Marteau R, Paturneau-Jouas M. Adult adrenoleukodystrophy: a sporadic case? *J Neurol Sci* 1987;80:121-8.
- 34 Angus B, de Silva R, Davidson R, Bone I. A family with adult-onset cerebral adrenoleukodystrophy. *J Neurol* 1994;241:497-9.
- 35 Farrell DF, Hamilton SR, Knauss TA, Sanocki E, Deeb SS. X-linked adrenoleukodystrophy: adult cerebral variant. *Neurology* 1993;43:1518-22.
- 36 Moser HW, Moser AB, Smith KD, *et al.* Adrenoleukodystrophy: phenotypic variability and implications for therapy. *J Inher Metab Dis* 1992;15:645-4.
- 37 Schaumburg HH, Powers JM, Raine CS, *et al.* Adrenomyeloneuropathy: a probable variant of adrenoleukodystrophy. *Neurology* 1977;27:1114-9.
- 38 Aubourg P, Adamsbaum C, Lavallard-Rousseau MC, *et al.* Brain MRI and electrophysiologic abnormalities in pre-clinical and clinical adrenomyeloneuropathy. *Neurology* 1992;42:85-91.
- 39 Kumar AJ, Kohler W, Kruse B, *et al.* MR findings in adult-onset adrenoleukodystrophy. *Am J Neuroradiol* 1995;16:1227-37.
- 40 van Geel BM, Koelman JHTM, Barth PG, Ongerboer de Visser BW. Peripheral nerve abnormalities in adrenomyeloneuropathy: a clinical and electrodiagnostic study. *Neurology* 1996;46:112-8.
- 41 Chaudhry V, Moser HW, Cornblath DR. Nerve conduction studies in adrenomyeloneuropathy. *J Neurol Neurosurg Psychiatry* 1996;61:181-5.
- 42 Maris T, Androulidakis EJ, Tzagournissakis M, Papavassiliou S, Moser H, Platikis A. X-linked adrenoleukodystrophy presenting as neurologically pure familial spastic paraparesis. *Neurology* 1994;45:1101-4.
- 43 Sadeghi-Nejad A, Senior B. Adrenomyeloneuropathy presenting as Addison's disease in childhood. *N Engl J Med* 1990;322:13-6.
- 44 Jorge P, Quelhas D, Oliveira P, Pinto R, Nogueira A. X-linked adrenoleukodystrophy in patients with idiopathic Addison disease. *Eur J Pediatr* 1994;153:594-7.
- 45 Schäfer JR, Ehlenz K, Steinmetz A, *et al.* Adrenomyeloneuropatie: eine häufige Ursache des Morbus Addison. *Dtsch Med Wochenschr* 1994;119:327-31.
- 46 Kong M, Jeffcoats J. Eighty-six cases of Addison's disease. *Clin Endocrinol* 1994;41:757-61.
- 47 Laureti S, Casucci G, Santese F, Angeletti G, Aubourg P, Brunetti P. X-linked adrenoleukodystrophy is a frequent cause of idiopathic Addison's disease in young adult male patients. *J Clin Endocrinol Metab* 1996;81:470-4.
- 48 Aubourg P, Sellier N, Chaussain JL, Kalifa G. MRI detects cerebral involvement in neurologically asymptomatic patients with adrenoleukodystrophy. *Neurology* 1989;39:1619-21.
- 49 Kruse B, Barker PB, van Zijl PCM, Duyn JH, Moonen CTW, Moser HW. Multislice proton magnetic resonance spectroscopy imaging in X-linked adrenoleukodystrophy. *Ann Neurol* 1994;36:595-608.
- 50 Moser HW, Moser AB, Naidu S, Bergin A. Clinical aspects on adrenoleukodystrophy and adrenomyeloneuropathy. *Dev Neurosci* 1991;13:254-61.
- 51 Kuroda S, Hirano R, Yuasa S. Adrenoleukodystrophy-cerebello-brainstem dominant case. *Acta Neuropathol* 1983;60:149-52.
- 52 Ohno T, Tsuchiya H, Fukuhara N, Yuasa T, Tsuji T, Miyatake T. Adrenoleukodystrophy: new clinical variant presenting as olivopontocerebellar atrophy. *Ann Neurol* 1983;14:147-8.
- 53 Kobayashi T, Noda S, Umezaki H, *et al.* Familial spinocerebellar degeneration as an expression of adrenoleukodystrophy. *J Neurol Neurosurg Psychiatry* 1986;49:1438-40.
- 54 Marsden CD, Obeso JA, Lang AE. Adrenomyeloneuropathy presenting as spinocerebellar degeneration. *Neurology* 1982;32:1031-2.
- 55 Weller M, Liedtke W, Petersen D, Opitz H, Poremba M. Very-late-onset adrenoleukodystrophy: possible precipitation of demyelination by cerebral contusion. *Neurology* 1992;42:367-70.
- 56 Wilkinson IA, Hopkins AC. Can head injury influence the site of demyelination in adrenoleukodystrophy? *Dev Med Child Neurol* 1987;29:797-800.
- 57 Powers JM, Schaumburg HH. A fatal cause of sexual inadequacy in men: adrenoleukodystrophy. *J Urol* 1980;124:583-5.
- 58 Martin JJ, Dompas B, Ceuterick C, Jakobs K. Adrenomyeloneuropathy and adrenoleukodystrophy in two brothers. *Eur Neurol* 1980;19:281-7.
- 59 Elrington GM, Bateman DE, Jeffrey MJ, Lawton NF. Adrenoleukodystrophy: heterogeneity in two brothers. *J Neurol Neurosurg Psychiatry* 1989;52:310-3.
- 60 Dooley JM, Wright BA. Adrenoleukodystrophy mimicking multiple sclerosis. *Can J Neurol Sci* 1985;12:73-4.
- 61 Stöckler S, Millner M, Molzer B, Ebner F, Korner E, Moser HW. Multiple sclerosis-like syndrome in a woman heterozygous for adrenoleukodystrophy. *Eur Neurol* 1993;33:390-2.
- 62 Pilz P, Schiener P. Kombination von morbus Addison und Morbus schilder bei einer 43 jährigen Frau. *Arch Neuropathol* 1973;26:357-60.
- 63 Schlote W, Molzer B, Peiffer J, *et al.* Adrenoleukodystrophy in an adult female. *J Neurol* 1987;235:1-9.
- 64 Simpson RHW, Rodda J, Reinecke CJ. Adrenoleukodystrophy in a mother and son. *J Neurol Neurosurg Psychiatry* 1987;50:1165-72.
- 65 Heffungs W, Hameister H, Ropers HH. Addison disease and cerebral sclerosis in an apparently heterozygous girl: evidence of inactivation of the adrenoleukodystrophy locus. *Clin Genet* 1980;18:184-8.
- 66 Dumic M, Gubarev N, Sikic N, Roscher A, Plavsic V, Filipovic-Grcic B. Sparse hair and multiple endocrine disorders in two women heterozygous for adrenoleukodystrophy. *Am J Med Genet* 1992;43:829-32.
- 67 Moser HW, Kok F, Neumann S, *et al.* Adrenoleukodystrophy update: genetics and effect of Lorenzo's oil therapy in asymptomatic patients. *Int Pediatr* 1994;9:196-204.
- 68 Hashmi M, Stanley W, Singh I. Lignoceryl-CoASH ligase: enzyme defect in fatty acid  $\beta$ -oxidation system in X-linked childhood adrenoleukodystrophy. *FEBS Lett* 1986;196:247-50.
- 69 Jakobs BS, Wanders RJA. Conclusive evidence that that very long chain fatty acids are oxidized exclusively in peroxisomes in human skin fibroblasts. *Biochem Biophys Res Commun* 1991;178:842-7.
- 70 de Duve C, Baudhuin P. Peroxisomes (microbodies and related particles). *Physiol Rev* 1966;46:323-57.
- 71 Hruban Z, Vigil EL, Slesars A, Hopkins E. Microbodies: constituent organelles of animal cells. *Lab Invest* 1972;27:184-91.
- 72 Schutgens RBH, Barth PG, van Geel BM, Wanders RJA. Peroxisomal disorders: classification, diagnosis and treatment. In: Di Donato S, *et al.* *Metabolic encephalopathies*. London: John Libbey, 1995:129-40.
- 73 Wanders RJA, Heymans HSA, Schutgens RBH, Barth PG, van den Bosch H, Tager JM. Peroxisomal disorders in neurology. *J Neurol Sci* 1988;88:1-39.
- 74 Mosser J, Lutz Y, Stoeckel ME, *et al.* The gene responsible for adrenoleukodystrophy encodes a peroxisomal membrane protein. *Hum Molec Genet* 1994;3:265-71.
- 75 Valle D, Gärtner J. Penetrating the peroxisome. *Nature* 1993;361:682-3.
- 76 Ligtenberg MJL, Kemp S, Sarde CO, *et al.* Spectrum of mutations in the gene encoding the adrenoleukodystrophy protein. *Am J Hum Genet* 1995;56:44-50.
- 77 Kok F, Neumann S, Sarde C, *et al.* Mutational analysis of patients with X-linked adrenoleukodystrophy. *Hum Mutat* 1995;6:104-15.
- 78 Krasemann EW, Meier V, Korenke GC, Hunneman D, Hanefeld F. Identification of mutations in the ALD-gene of 20 families with adrenoleukodystrophy/adrenomyeloneuropathy. *Hum Genet* 1996;97:194-7.
- 79 Feigenbaum V, Lombard-Platet G, Guidoux S, Sarde C, Mandel J, Aubourg P. Mutational and protein analysis of

- patients and heterozygous women with X-linked adrenoleukodystrophy. *Am J Hum Genet* 1996;58:1135-44.
- 80 Kemp S, Ligtenberg MJL, van Geel BM, *et al.* Identification of a two base pair deletion in five unrelated families with adrenoleukodystrophy: a possible hot spot for mutations. *Biochem Biophys Res Commun* 1994;202:647-53.
- 81 Maestri NE, Beaty TH. Predictions of a 2-locus model for disease heterogeneity: applications to adrenoleukodystrophy. *Am J Med Genet* 1992;44:576-82.
- 82 Sobue G, Ueno-Natsukari I, Okamoto H, *et al.* Phenotypic heterogeneity of an adult form of adrenoleukodystrophy in monozygotic twins. *Ann Neurol* 1994;36:912-5.
- 83 Korenke GC, Fuchs S, Krasemann E, *et al.* Cerebral adrenoleukodystrophy (ALD) in only one of monozygotic twins with an identical ALD genotype. *Ann Neurol* 1996;40:254-7.
- 84 Powers JM, Schaumburg HH. Adreno-leukodystrophy (sex-linked Schilder disease): a pathogenetic hypothesis based on ultrastructural lesions in adrenal cortex, peripheral nerve and testis. *Am J Pathol* 1974;76:481-500.
- 85 Powers JM, Schaumburg HH. The testis in adrenoleukodystrophy. *Am J Pathol* 1981;102:90-8.
- 86 Griffin DE, Moser HW, Mendoza Q, Moench TR, O'Toole S, Moser AB. Identification of the inflammatory cells in the central nervous system of patients with adrenoleukodystrophy. *Ann Neurol* 1985;18:660-4.
- 87 Whitcomb RW, Linehan WM, Knazek RA. Effect of long-chain, saturated fatty acids on membrane microviscosity and adrenocorticotropin responsiveness of human adrenocortical cells in vivo. *J Clin Invest* 1988;81:185-8.
- 88 Phillips JP, Lockman LA, Shapiro EG, *et al.* CSF findings in adrenoleukodystrophy: correlation between measures of cytokines, IgG production, and disease severity. *Pediatr Res* 1994;10:289-94.
- 89 Powers JM, Liu Y, Moser AB, Moser HW. The inflammatory myelinopathy of adreno-leukodystrophy: cells, effector molecules, and pathogenetic implications. *J Neuropathol Exp Neurol* 1992;51:630-43.
- 90 Tonshoff B, Lehnert W, Ropers HH. Adrenoleukodystrophy: diagnosis and carrier detection by determination of long-chain fatty acids in cultured fibroblasts. *Clin Genet* 1982;22:25-9.
- 91 Tsuji S, Suzuki M, Ariga T, Sekine M, Kuriyama M, Miyatake T. Abnormality of long-chain fatty acids in erythrocyte membrane sphingomyelin from patients with adrenoleukodystrophy. *J Neurochem* 1981;36:1046-9.
- 92 Molzer B, Bernheimer H, Toifi K. Fatty acid patterns in brain, fibroblast, leukocyte and body fluid lipids in adrenoleukodystrophy. *Acta Neuropathol* 1981;(suppl VII):211-4.
- 93 Notarangelo LD, Parolini O, Baiguini G, *et al.* Carrier detection in X-linked adrenoleukodystrophy by determination of very long chain fatty acids and by linkage analysis. *Eur J Pediatr* 1992;151:761-3.
- 94 van Oost BA, van Zandvoort PM, Tunte W, *et al.* Linkage analysis in X-linked adrenoleukodystrophy and application in post- and prenatal diagnosis. *Hum Genet* 1991;86:404-7.
- 95 Boué J, Oberle I, Heilig R, *et al.* First trimester prenatal diagnosis of adrenoleukodystrophy by determination of very long chain fatty acids and by linkage analysis to a DNA probe. *Hum Genet* 1985;69:272-4.
- 96 Watkins PA, Gould SJ, Smith MA, *et al.* Altered expression of ALDP in X-linked adrenoleukodystrophy. *Am J Hum Genet* 1995;57:292-301.
- 97 Kemp S, Mooyer PAW, Bolhuis PA, *et al.* ALDP expression in fibroblasts of patients with X-linked adrenoleukodystrophy. *J Inher Metab Dis* 1996;19:667-74.
- 98 Wanders RJA, van Roermund CWT, Lageweg W, *et al.* X-linked adrenoleukodystrophy: biochemical diagnosis and enzyme defect. *J Inher Metab Dis* 1992;15:634-44.
- 99 Kennedy CR, Allen JT, Fensom AH, Steinberg SJ, Wilson R. X-linked adrenoleukodystrophy with non-diagnostic plasma very long chain fatty acids. *J Neurol Neurosurg Psychiatry* 1994;57:759-61.
- 100 Moser HW, Moser AE, Trojak JE, Supplee SW. Identification of female carriers of adrenoleukodystrophy. *J Pediatr* 1983;103:54-9.
- 101 Moser HW, Moser AB, Powers JM, *et al.* The prenatal diagnosis of adrenoleukodystrophy: demonstration of increased hexacosanoic acid concentrations in cultured amniocytes and fetal adrenal gland. *Pediatr Res* 1982;16:172-5.
- 102 Wanders RJA, Schutgens RBH, van den Bosch H, Tager JM, Kleijer WJ. Prenatal diagnosis of inborn errors in peroxisomal  $\beta$ -oxidation. *Prenat Diagn* 1991;11:253-61.
- 103 Carey WF, Poulos A, Sharp P, *et al.* Pitfalls in the prenatal diagnosis of peroxisomal  $\beta$ -oxidation defects by chorionic villus sampling. *Prenat Diagn* 1994;14:813-819.
- 104 Gray RGF, Green A, Cole T, *et al.* A misdiagnosis of X-linked adrenoleukodystrophy in cultured chorionic villus cells by the measurement of very long chain fatty acids. *Prenat Diagn* 1995;15:486-90.
- 105 Imamura A, Suzuki Y, Song X, *et al.* Prenatal diagnosis of adrenoleukodystrophy by means of mutation analysis. *Prenat Diagn* 1996;16:259-61.
- 106 Wanders RJA, Schutgens RBH, Barth PG, Tager JM, van den Bosch H. Postnatal diagnosis of peroxisomal disorders: a biochemical approach. *Biochimie* 1993;75:269-79.
- 107 Blevins LS, Shankroff J, Moser HW, Ladenson PW. Elevated plasma adrenocorticotropin concentration as evidence of limited adrenocortical reserve in patients with adrenomyeloneuropathy. *J Clin Endocrinol Metab* 1994;78:261-5.
- 108 Kishimoto Y, Moser HW, Kawamura N, Platt M, Pallante B, Fenselau C. Evidence that abnormal very long chain fatty acids of brain cholesterol esters are of exogenous origin. *Biochem Biophys Res Commun* 1980;96:69-76.
- 109 Brown III FR, van Duyn MA, Moser AB, *et al.* Adrenoleukodystrophy: effects of dietary restriction and of administration of carnitine and clofibrate on clinical status and plasma fatty acids. *Johns Hopkins Med J* 1982;151:164-72.
- 110 Tsuji S, Sano T, Ariga T, Miyatake T. Increased synthesis of hexacosanoic acid (C26:0) by cultured skin fibroblasts from patients with adrenoleukodystrophy (ALD) and adrenomyeloneuropathy (AMN). *J Biochem* 1981;90:1233-6.
- 111 Rizzo WB, Watkins PA, Phillips MW, Cranin D, Campbell B, Avigan J. Adrenoleukodystrophy: oleic acid lowers fibroblast saturated C22-26 fatty acids. *Neurology* 1986;36:357-61.
- 112 Rizzo WB, Phillips MW, Dammann AL, *et al.* Adrenoleukodystrophy: dietary oleic acid lowers hexacosanoate levels. *Ann Neurol* 1987;21:232-9.
- 113 Moser AB, Borel J, Odone A, *et al.* A new dietary therapy for adrenoleukodystrophy: biochemical and preliminary clinical results in 36 patients. *Ann Neurol* 1987;21:240-9.
- 114 Rizzo WB, Leshner RT, Odone A, *et al.* Dietary erucic acid therapy for X-linked adrenoleukodystrophy. *Neurology* 1989;39:1415-22.
- 115 Asano J, Suzuki Y, Yajima S, *et al.* Effects of erucic acid therapy on Japanese patients with X-linked adrenoleukodystrophy. *Brain Dev* 1994;16:454-8.
- 116 Korenke GC, Hunneman DH, Kohler J, Stöckler S, Landmark K, Hanefeld F. Glyceroltrioleate/glyceroltrierucate therapy in 16 patients with X-chromosomal adrenoleukodystrophy/adrenomyeloneuropathy: effect on clinical, biochemical and neurophysiological parameters. *Eur J Pediatr* 1995;154:64-70.
- 117 Poulos A, Gibson R, Sharp P, Beckman K, Grattan-Smith P. Very long chain fatty acids in X-linked adrenoleukodystrophy brain after treatment with Lorenzo's oil. *Ann Neurol* 1994;36:741-6.
- 118 Rasmussen M, Moser AB, Borel J, Khangoor S, Moser HW. Brain, liver, and adipose tissue erucic and very long chain fatty acid levels in adrenoleukodystrophy patients treated with glyceryl trierucate and trioleate oils (Lorenzo's oil). *Neurochem Res* 1994;8:1073-82.
- 119 Moser HW. Adrenoleukodystrophy: natural history, treatment and outcome. *J Inher Metab Dis* 1995;18:435-47.
- 120 Aubourg P, Adamsbaum C, Lavallard-Rousseau MC, *et al.* A two-year trial of oleic and erucic acids (Lorenzo's oil) as treatment for adrenomyeloneuropathy. *N Engl J Med* 1993;329:745-52.
- 121 Assies J, van Geel BM, Weverling GJ, Haverkort EB, Barth PG. Endocrine evaluation during dietary therapy for adrenomyeloneuropathy. In: Bhatt HR, *et al.* *Advances in Thomas Addison's diseases, vol 1.* Bristol: Journal of Endocrinology, 1994:191-8.
- 122 Zierz S, Schröder R, Unkrig CJ. Thrombocytopenia induced by erucic acid therapy in patients with X-linked adrenoleukodystrophy. *Clin Invest* 1993;71:802-5.
- 123 Stöckler S, Molzer B, Plecko B, *et al.* Giant platelets in erucic acid therapy for adrenoleukodystrophy. *N Engl J Med* 1993;341:1414-5.
- 124 Toplak H, Wascher TC, Pleschko B, *et al.* Reduced stimulatory of platelet surface adhesion molecules under treatment with Lorenzo's oil. *J Inher Metab Dis* 1994;17:628-9.
- 125 Zinkham WH, Kicker T, Borel J, Moser HW. Lorenzo's oil and thrombocytopenia in patients with adrenoleukodystrophy. *N Engl J Med* 1993;328:1126-7.
- 126 Bernheimer H, Budka H, Muller P. Brain tissue immunoglobulins in adrenoleukodystrophy: a comparison with multiple sclerosis and systemic lupus erythematosus. *Acta Neuropathol* 1983;59:95-102.
- 127 Moser HW, Tutschka PJ, Brown III FR, *et al.* Bone marrow transplant in adrenoleukodystrophy. *Neurology* 1984;34:1410-7.
- 128 Aubourg P, Blanche S, Jambaqué I, *et al.* Reversal of early neurologic and neuroradiologic manifestations of X-linked adrenoleukodystrophy by bone marrow transplantation. *N Engl J Med* 1990;322:1860-6.
- 129 Loes DJ, Stillman AE, Hite S, *et al.* Childhood cerebral form of adrenoleukodystrophy: short-term effect of bone marrow transplantation on brain MR observations. *Am J Neuroradiol* 1994;15:1767-71.
- 130 Shapiro EG, Lockman LA, Balthazor M, Krivit W. Neuropsychological outcomes of several storage diseases with and without bone marrow transplantation. *J Inher Metab Dis* 1995;18:413-29.
- 131 Murphy JV, Marquardt KM, Moser HW, van Duijn MA. Treatment of adrenoleukodystrophy by diet and plasmapheresis. *Ann Neurol* 1982;12:220.
- 132 Stumpf DA, Hayward A, Haas R, Frost M, Schaumburg HH. Adrenoleukodystrophy: failure of immunosuppression to prevent neurological progression. *Arch Neurol* 1981;38:48-9.
- 133 Naidu S, Bresnan MJ, Griffin D, O'Toole S, Moser HW. Childhood adrenoleukodystrophy: failure of intensive immunosuppression to arrest neurological progression. *Arch Neurol* 1988;45:846-8.
- 134 Miike T, Taku K, Tamura T, *et al.* Clinical improvement of adrenoleukodystrophy following intravenous gammaglobulin therapy. *Brain Dev* 1989;11:134-7.
- 135 Cappa M, Bertini E, del Balzo P, Cambiaso P, Di Biase A, Salvati S. High dose immunoglobulin IV treatment in adrenoleukodystrophy. *J Neurol Neurosurg Psychiatry* 1994;57(suppl):69-70.

- 136 Paty DW, Li DKB, the UBS MS/MRI Study Group, the IFNB Multiple Sclerosis Study Group. Interferon beta-1b is effective in relapsing-remitting multiple sclerosis: II. MRI analysis results of a multicenter, randomized, double-blind, placebo-controlled trial. *Neurology* 1993;43:662-7.
- 137 Moser HW. Clinical and therapeutic aspects of adrenoleukodystrophy and adrenomyeloneuropathy. *J Neuropathol Exp Neurol* 1995;54:740-5.
- 138 Korenke GC, Christen H, Hunneman DH, Hanefeld F. Failure of beta interferon therapy in X-linked adrenoleukodystrophy. *Eur J Pediatr* 1996;155:833.
- 139 Cartier N, Lopez J, Moullier P, et al. Retroviral-mediated gene transfer corrects very-long-chain fatty acid metabolism in adrenoleukodystrophy fibroblasts. *Proc Natl Acad Sci USA* 1995;92:1674-8.

---

## NEUROLOGICAL STAMP

---

### Georg Agricola (1490-1555)

Georg Agricola, a younger contemporary of Paracelsus whose real name was Georg Bauer, and who was born in Saxony, Germany, is often regarded as the father of modern mineralogy. He studied philology and then went to Italy where he graduated in medicine in 1525. On returning to Germany he was appointed physician in Joachimsthal, the centre of a rich mining area. Later in 1530 he was appointed historiographer of Prince Maurice of Saxony and in 1533 city physician to Chemnitz, another well known mining town. Here he occupied himself with medical, mathematical, theological, and historical studies, but particularly with mineralogy. His greatest work *De re metallica* was published in 1556 the year after his death. The book has a unique distinction of having been translated and edited in 1912 by Herbert Hoover, President of the United States and his wife, Lou Henry Hoover.

Agricola acknowledged a very old belief that an emerald worn on an amulet or ring averted epilepsy. He stated that the emerald fights with epilepsy as with a deadly enemy. If the stone was stronger than the disease, it remained whole; if, however, it was conquered by the disease it broke into several parts.

Philatelically he was honoured in 1955 on the 400th anniversary of his death by East Germany as a mineralogist and scholar (Stanley Gibbons No E240, Scott No 271).



L F HAAS