



## UvA-DARE (Digital Academic Repository)

### Prospective comparative study of spiral computer tomography and magnetic resonance imaging or detection of hepatocellular carcinoma

Stoker, J.; Romijn, M.G.; de Man, R.A.; Brouwer, J.T.; Weverling, G.J.; van Muiswinkel, J.M.; Zondervan, P.E.; Laméris, J.S.; IJzermans, J.N.

**DOI**

[10.1136/gut.51.1.105](https://doi.org/10.1136/gut.51.1.105)

**Publication date**

2002

**Published in**

Gut

[Link to publication](#)

**Citation for published version (APA):**

Stoker, J., Romijn, M. G., de Man, R. A., Brouwer, J. T., Weverling, G. J., van Muiswinkel, J. M., Zondervan, P. E., Laméris, J. S., & IJzermans, J. N. (2002). Prospective comparative study of spiral computer tomography and magnetic resonance imaging or detection of hepatocellular carcinoma. *Gut*, 51, 105-107. <https://doi.org/10.1136/gut.51.1.105>

**General rights**

It is not permitted to download or to forward/distribute the text or part of it without the consent of the author(s) and/or copyright holder(s), other than for strictly personal, individual use, unless the work is under an open content license (like Creative Commons).

**Disclaimer/Complaints regulations**

If you believe that digital publication of certain material infringes any of your rights or (privacy) interests, please let the Library know, stating your reasons. In case of a legitimate complaint, the Library will make the material inaccessible and/or remove it from the website. Please Ask the Library: <https://uba.uva.nl/en/contact>, or a letter to: Library of the University of Amsterdam, Secretariat, Singel 425, 1012 WP Amsterdam, The Netherlands. You will be contacted as soon as possible.

*UvA-DARE is a service provided by the library of the University of Amsterdam (<https://dare.uva.nl>)*



## Prospective comparative study of spiral computer tomography and magnetic resonance imaging for detection of hepatocellular carcinoma

J Stoker, M G Romijn, R A de Man, J T Brouwer, G J Weverling, J M van Muiswinkel, P E Zondervan, J S Laméris and J N M Ijzermans

*Gut* 2002;51;105-107  
doi:10.1136/gut.51.1.105

---

Updated information and services can be found at:  
<http://gut.bmj.com/cgi/content/full/51/1/105>

---

*These include:*

**Data supplement**

"Web-only Longer Version"  
<http://gut.bmj.com/cgi/content/full/51/1/105/DC1>

**References**

1 online articles that cite this article can be accessed at:  
<http://gut.bmj.com/cgi/content/full/51/1/105#otherarticles>

**Email alerting service**

Receive free email alerts when new articles cite this article - sign up in the box at the top right corner of the article

---

**Topic collections**

Articles on similar topics can be found in the following collections

[Other imaging techniques](#) (1499 articles)  
[Cancer: gastroenterological](#) (1220 articles)  
[Liver, including hepatitis](#) (954 articles)

---

**Notes**

---

To order reprints of this article go to:  
<http://www.bmjournals.com/cgi/reprintform>

To subscribe to *Gut* go to:  
<http://www.bmjournals.com/subscriptions/>

## LIVER AND BILIARY DISEASE

## Prospective comparative study of spiral computer tomography and magnetic resonance imaging for detection of hepatocellular carcinoma

J Stoker, M G Romijn, R A de Man, J T Brouwer, G J Weverling, J M van Muiswinkel, P E Zondervan, J S Laméris, J N M Ijzermans

Gut 2002;51:105-107

See end of article for authors' affiliations

Correspondence to: Dr J Stoker, Department of Radiology, Academic Medical Centre, University of Amsterdam, PO Box 22700, 1100 DE Amsterdam, the Netherlands; [j.stoker@amc.uva.nl](mailto:j.stoker@amc.uva.nl)

Accepted for publication 11 September 2001

**Background:** Hepatocellular carcinoma (HCC) is often detected at a relatively late stage when tumour size prohibits curative surgery. Screening to detect HCC at an early stage is performed for patients at risk.

**Aim:** The aim of this study was to compare prospectively the diagnostic accuracy and classification for management of the two state of the art secondline imaging techniques: triphasic spiral computer tomography (CT) and super paramagnetic iron oxide (SPIO) enhanced magnetic resonance imaging (MRI).

**Patients:** Sixty one patients were evaluated between January 1996 and January 1998. Patients underwent CT and MRI within a mean interval of 6.75 days.

**Methods:** CT and MRI were evaluated blindly for the presence and number of lesions, characterisation of these lesions, and classification for management. For comparison of the data on characterisation, the CT and MRI findings were compared with histopathological studies of the surgical specimens and/or follow up imaging. Data of patients not lost to follow up were available to January 2001.

**Results:** SPIO enhanced MRI detected more lesions and overall smaller lesions than triphasic spiral CT (number of lesions 189 v 124; median diameter 1.0 v 1.8 cm; Spearman rank's correlation coefficient 0.63,  $p < 0.001$ ). There was no significant difference in accuracy between CT and MRI for lesion characterisation. The agreement in classification for management was very good (weighted kappa 0.91, 95% CI 0.83-0.99).

**Conclusion:** SPIO enhanced MRI detects more and smaller lesions, but both techniques are comparable in terms of classification for management. SPIO enhanced MRI may be preferred as there is no exposure to ionising radiation.

Secondline imaging is performed in patients positive in screening programmes for hepatocellular carcinoma (HCC) to detect and characterise intrahepatic lesions. Recent developments in computer tomography (CT) and magnetic resonance imaging (MRI) techniques have led to several new strategies for advanced imaging but the optimum strategy has not yet been established.

The aim of this prospective study was to compare triphasic spiral CT and super paramagnetic iron oxide (SPIO) enhanced MRI in establishing the number of hepatic lesions and their nature and to compare both techniques in terms of classification for management (surgery) in patients suspected of having HCC at screening.

## MATERIAL AND METHODS

## Patient inclusion

From January 1996 to January 1998, we studied 61 consecutive patients (41 males, 20 females; mean age 54.4 years, range 30-77). Patients were included in the present study when at screening a new non-cystic focal lesion was detected at ultrasound and/or  $\alpha$  fetoprotein (AFP) level was elevated to twice the previous value or twice the upper limit of normal (20  $\mu$ g/l). Patients were excluded when there were contraindications for intravenous low osmolar iodised contrast medium, SPIO, or MRI. For 36 patients, findings at imaging were compared with histopathological findings on the resected specimen or follow up imaging.

## Imaging and image analysis

Spiral CT comprised plain, arterial phase, and portal phase imaging using a single detector row machine. For analysis of the MRI, the most sensitive sequence was used: axial T2w turbo spin echo (TSE) with fat saturation after administration of SPIO. CT and MRI were evaluated blindly and separately by two consultants. Triphasic spiral CT and MRI with SPIO were evaluated for the presence of hepatic lesions, number of hepatic lesions, size of the lesions (<2 cm, 2-5 cm,  $\geq 5$  cm), diagnosis of the lesions (for a maximum of three lesions), and for establishing the correct classification for management.

CT and MRI were compared for establishing the correct classification for management: no suspect lesion and no surgical treatment; suspect lesion(s) and eligible for curative surgery; and extensive disease without the possibility of curative surgical treatment. Patients with a suspect lesion(s) for HCC were considered candidates for hepatic surgery when only one lesion was present ( $\leq 5$  cm) or there were two lesions of  $\leq 2$  cm.

## Histopathology and follow up imaging

Histopathological studies were evaluated with knowledge of the findings at spiral CT and MRI with SPIO. Follow up imaging comprised repeat triphasic CT and MRI with SPIO. Growth

**Abbreviations:** AFP,  $\alpha$  fetoprotein; CT, computer tomography; HCC, hepatocellular carcinoma; MRI, magnetic resonance imaging; SPIO, super paramagnetic iron oxide; TSE, turbo spin echo.

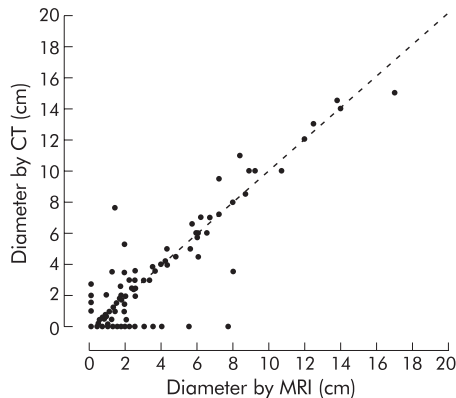
**Table 1** Number of suspected lesions at triphasic spiral computer tomography (CT) and super paramagnetic iron oxide enhanced magnetic resonance imaging (MRI) in 61 patients

	MRI			All
	<2 cm	2–<5 cm	≥5 cm	
CT				
<2 cm	128	10	2	140
2–<5 cm	9	19	2	30
≥5 cm	2	1	24	27
All	139	30	28	197

**Table 2** Agreement in terms of classification for management by computer tomography (CT) or magnetic resonance imaging (MRI) in 61 patients.

	MRI		
	No surgery necessary	Eligible for surgery	Extensive disease, no surgery
CT			
No surgery necessary	15	2	0
Eligible for surgery	1	7	2
Extensive disease, no surgery	0	0	34

Weighted kappa 0.91 (95% confidence interval 0.83–0.99).

**Figure 1** Diameter of the lesions measured by spiral computer tomography (CT) scan or magnetic resonance imaging (MRI) in 61 patients. The broken line represents the x=y line.

of lesions by at least 20% of the initial diameter or 5 mm or more and/or the presence of new lesions was defined as evidence of malignancy.

### Statistical analysis

Statistical analysis was performed with SAS version 6.12 (SAS Institute Inc., Cary, North Carolina, USA). The number of lesions per patient at CT and MRI were compared using the Wilcoxon rank's sum test. Correlation of CT and MRI for lesion size was determined using Spearman rank's correlation test.  $p < 0.05$  was considered significant. Weighted kappa values were calculated for agreement between CT and MRI in terms of classification for management.

### RESULTS

Two patients experienced uneventful back pain during the SPIO infusion for MRI. One patient suffered transient hypotension after the SPIO infusion for follow up MRI but did not require further treatment.

For the 61 patients studied, SPIO enhanced MRI detected more HCC suspect lesions than triphasic spiral CT (124 v 189). The total number of suspect lesions identified with CT or MRI was 197 (table 1). Median number of lesions was 1 (interquartile range 1–3.5) at CT and 2 (interquartile range 1–7) at MRI. In 39 patients equal numbers of lesions were found, in five patients more lesions were found with CT, and in 18 patients more lesions were found by MRI, indicating that MRI detected more lesions compared with CT scan ( $p < 0.01$ ). In 14 of 15 patients diagnosed with cirrhosis at histopathology, MRI and CT scan showed equal numbers of lesions.

Median diameter of the lesions at MRI was smaller (1.0 cm; interquartile range 1.0–2.5 cm) than at CT (1.8 cm; interquartile range 1.0–4.0 cm) (Spearman rank's correlation coefficient

0.63,  $p < 0.001$ ) (fig 1). When only the largest lesion was considered per patient, median diameter was 5.4 cm (interquartile range 2.7–9.8) for CT and 5.6 cm (interquartile range 2.4–8.4) for MRI.

CT and MRI had very good agreement (weighted kappa 0.91; 95% confidence intervals 0.83–0.99) in classifying patients for management (table 2). In five patients there were differences in classification for management; in all, MRI was correct.

For the 36 patients with positive histopathological findings for the partial or completely resected liver and follow up imaging, findings of CT and MRI in characterizing the lesions were comparable (table 3).

For the 10 patients who underwent liver transplantation, CT yielded the correct number of lesions and correct characterisation of the lesions in six cases (MRI in nine cases). For the six patients with a resected liver, CT findings were correct in five cases and MRI findings were correct in all cases. With CT, a 3 cm HCC was missed.

### DISCUSSION

The present prospective study demonstrated that SPIO enhanced MRI was superior to spiral CT for detection of lesions in patients at risk of HCC. A major problem is differentiation between benign nodules (regenerative nodules and dysplastic nodules) and HCC in cirrhotic livers. MRI has been advocated as the optimum imaging technique for differentiation between these benign nodules and HCC, with further improvement with the use of SPIO.<sup>1–3</sup> The limiting factor is the gradual progression of dysplastic nodules to HCC, which is only partly reflected in changes in the imaging characteristics. Normal liver parenchyma, regenerative nodules, and dysplastic nodules demonstrate uptake of SPIO by Kupffer cells but this may also be found in highly differentiated HCC. Therefore, some highly differentiated lesions may be considered benign lesions.

Importantly, the detection of more lesions at MRI compared with CT in this study did not lead to improved classification for treatment (for example, curative surgery). The major reason is that the difference in detection of lesions is predominantly in patients with extensive disease (more than two lesions). These patients are not candidates for curative surgery and therefore differences in the number of lesions higher than two do not influence management.

Both spiral CT and MRI are rapidly developing techniques with new improvements yet to come. For MRI the widespread use of phased array coils, new imaging sequences, and protocols (for example, multiphase breath hold three dimensional gadolinium enhanced MR) and further developments in liver specific contrast media will enhance the efficacy of the technique. A recent innovation is the introduction of the next generation of CT scanners with the possibility of very thin slices (1–3 mm), which might improve lesion detection with

**Table 3** Characterisation of liver lesions (maximum three per patient) detected with triphasic spiral computer tomography (CT) and super paramagnetic iron oxide (SPIO) enhanced magnetic resonance imaging (MRI) in 36 patients compared with histopathology and/or follow up imaging

	Triphasic spiral CT	SPIO enhanced MRI	Histopathology/ follow up imaging
HCC	20 (16)	25 (18)	25
Regeneration nodule*	1 (1)	4 (4)	5
Benign lesion (cyst, haemangioma)	14 (13)	15 (14)	18
Metastasis	0	0	3

\*Lesions characterised as suspect lesion at screening ultrasound.  
Numbers in parentheses are correctly characterised lesions.  
HCC, hepatocellular carcinoma.

spiral CT. A drawback is the further increase in radiation dose, especially for patients who need multiple secondline imaging procedures during the screening period. The CT technique used in the present study produces an effective dose of approximately 12 mSv, leading to an estimated risk of a fatal radiation induced cancer of 1:1700 per examination for the general population.<sup>4,5</sup> This risk, which is age dependent, decreases with increasing age.

Triphasic spiral CT and SPIO enhanced MRI are both valuable advanced imaging techniques but the absence of ionising radiation exposure makes SPIO enhanced MRI preferable for the workup and follow up of patients suspected of having HCC. As a result, future studies on HCC may become more accurate in the identification and monitoring of this malignancy.



Please visit the *Gut* website ([www.gutjnl.com](http://www.gutjnl.com)) for a fuller version of this article.

#### Authors' affiliations

**J Stoker**, Department of Radiology, Erasmus Medical Centre Rotterdam, and Department of Radiology, Academic Medical Centre, University of Amsterdam, the Netherlands

**M G Romijn**, Department of Radiology, and Department of Surgery, Erasmus Medical Centre Rotterdam, and Department of Radiology, Academic Medical Centre, University of Amsterdam, the Netherlands

**R A de Man, J T Brouwer**, Department of Gastroenterology, Erasmus Medical Centre Rotterdam, the Netherlands

**G J Weverling**, Department of Clinical Epidemiology and Biostatistics, Academic Medical Centre, University of Amsterdam, the Netherlands

**J M van Muiswinkel**, Department of Radiology, Erasmus Medical Centre Rotterdam, the Netherlands

**P E Zondervan**, Department of Pathology, Erasmus Medical Centre Rotterdam, the Netherlands

**J S Laméris**, Department of Radiology, Academic Medical Centre, University of Amsterdam, the Netherlands

**J N M Ijzermans**, Department of Surgery, Erasmus Medical Centre Rotterdam, the Netherlands

#### REFERENCES

- Murakami T**, Kurado C, Marukawa T, *et al*. Regenerating nodules in hepatic cirrhosis: MR findings with pathologic correlation. *AJR Am J Roentgenol* 1990;**155**:1227-31.
- Choi BI**, Takayasu K, Han MC. Small hepatocellular carcinomas and associated nodular lesions of the liver: pathology, pathogenesis and imaging findings. *AJR Am J Roentgenol* 1993;**160**:1177-87.
- Matsui O**, Kadoya M, Kameyama T, *et al*. Adenomatous hyperplastic nodules in the cirrhotic liver: differentiation from hepatocellular carcinoma with MR imaging. *Radiology* 1989;**173**:123-6.
- Ware DE**, Huda W, Mergo PJ, *et al*. Radiation effective doses to patients undergoing abdominal CT examinations. *Radiology* 1999;**210**:645-50.
- 1990 Recommendations of the International Commission on Radiological Protection**. *Radiation protection*. ICRP publication 60. Oxford: Pergamon Press, 1990.