



UvA-DARE (Digital Academic Repository)

Development of oxygen insensitivity of the quantitative histochemical assay of G6PDH activity during colorectal carcinogenesis

van Driel, B.E.M.; de Goeij, A.F.P.M.; Song, J.; de Bruïne, A.P.; van Noorden, C.J.F.

Publication date

1997

Document Version

Final published version

Published in

Journal of Pathology

[Link to publication](#)

Citation for published version (APA):

van Driel, B. E. M., de Goeij, A. F. P. M., Song, J., de Bruïne, A. P., & van Noorden, C. J. F. (1997). Development of oxygen insensitivity of the quantitative histochemical assay of G6PDH activity during colorectal carcinogenesis. *Journal of Pathology*, *182*, 398-403.

General rights

It is not permitted to download or to forward/distribute the text or part of it without the consent of the author(s) and/or copyright holder(s), other than for strictly personal, individual use, unless the work is under an open content license (like Creative Commons).

Disclaimer/Complaints regulations

If you believe that digital publication of certain material infringes any of your rights or (privacy) interests, please let the Library know, stating your reasons. In case of a legitimate complaint, the Library will make the material inaccessible and/or remove it from the website. Please Ask the Library: <https://uba.uva.nl/en/contact>, or a letter to: Library of the University of Amsterdam, Secretariat, Singel 425, 1012 WP Amsterdam, The Netherlands. You will be contacted as soon as possible.

DEVELOPMENT OF OXYGEN INSENSITIVITY OF THE QUANTITATIVE HISTOCHEMICAL ASSAY OF G6PDH ACTIVITY DURING COLORECTAL CARCINOGENESIS

BERNARD E. M. VAN DRIEL¹, ANTON F. P. M. DE GOEIJ², JI-YING SONG¹, ADRIAAN P. DE BRUÏNE² AND CORNELIS J. F. VAN NOORDEN^{1*}

¹Academic Medical Centre, University of Amsterdam, Laboratory of Cell Biology and Histology, P.O. Box 22700, 1100 DE Amsterdam, The Netherlands

²Department of Pathology, University of Limburg, Maastricht, The Netherlands

SUMMARY

The effects of oxygen on the quantitative histochemical assay to detect glucose-6-phosphate dehydrogenase (G6PDH) activity based on neotetrazolium reduction were studied in the different stages of carcinogenesis in the colon. Normal and hyperplastic epithelium, mucosae of patients with active Crohn's disease, and adenomas and adenocarcinomas of the colon were used. Epithelium of normal and inflamed mucosa, and hyperplastic epithelium, showed a residual G6PDH activity (RA) in oxygen that was always less than 20 per cent of the activity in the absence of oxygen. In adenomas and in dysplastic epithelia adjacent to carcinomas, the RA was significantly higher than that in normal epithelium, but significantly lower than that in adenocarcinomas. The RA of adenomas never exceeded 35 per cent. The RA of adenocarcinomas was on average 53 per cent and always higher than 20 per cent. When 35 per cent was used as a cut-off level, the sensitivity of RA to diagnose malignancy was 96.5 per cent. In a parallel study, a mouse model was used in which colon carcinomas and their precursors were induced chemically. Development of oxygen insensitivity during chemically induced carcinogenesis showed a pattern similar to that observed in the human. In conclusion, the test to determine RA is a useful tool for the detection of malignant mucosa in the colon. The test is particularly helpful in addition to histopathology for the detection of small lesions and the early stages of cancer. © 1997 by John Wiley & Sons, Ltd.

J. Pathol. 182: 398–403, 1997.

No. of Figures: 5. No. of Tables: 0. No. of References: 28.

KEY WORDS—colon; carcinoma; adenoma; hyperplastic polyp; glucose-6-phosphate dehydrogenase; histochemistry; diagnosis

INTRODUCTION

Most if not all colorectal carcinomas develop from adenomas.^{1,2} Since patients who undergo polypectomy for adenomas are at high risk of developing new adenomas and carcinomas,^{3,4} repeated endoscopy is warranted. Because endoscopic surveillance is expensive⁵ and only a small percentage of gastrointestinal lesions develop into malignant tumours,¹ the identification of patients at higher risk of recurrence of adenomas or development of carcinomas could decrease the burden of repeated colonoscopy. However, reliable parameters are still not available to predict which lesions will become malignant and when.⁶

The activity of enzymes may change in early stages of malignancy, before morphological changes become apparent.⁷ Glucose-6-phosphate dehydrogenase (G6PDH; EC 1.1.1.49), the regulatory enzyme of the pentose shunt pathway, is such an enzyme.⁸ Its activity can be demonstrated histochemically in tissue sections by using a tetrazolium salt as final electron acceptor.⁹

Because G6PDH activity is usually high in any proliferating cell, and thus in normal proliferating cells as well as in cancer cells,¹⁰ histochemical detection of its activity *per se* cannot be applied to make this distinction. When a particular tetrazolium salt, neotetrazolium (NT), is used in an atmosphere of oxygen, formazan production in normal tissue is almost completely prevented by oxygen, but not in the cells of cancer of the bronchus,¹¹ stomach,¹⁰ colon,^{10,12,13} or breast.¹⁴ Whether this oxygen insensitivity of the G6PDH assay in neoplasms develops during the transition from premalignancy to malignancy is unclear.

In the present study, we analysed the development of oxygen insensitivity in the process of colorectal carcinogenesis. The histochemical assay was applied to normal colonic mucosa, hyperplastic mucosa, dysplastic mucosa, and colorectal carcinomas, in both humans and mice. The (pre-)neoplastic lesions in the mice were chemically induced. Furthermore, we determined whether oxygen insensitivity in adenomas in humans could predict the development of metachronous colonic adenomas or carcinomas. The oxygen insensitivity of adenomas was also correlated with well-established histopathological parameters of neoplastic potential, such as growth pattern, degree of dysplasia, and adenoma size.^{15,16}

*Correspondence to: Cornelis J. F. Van Noorden, Academic Medical Centre, Laboratory of Cell Biology and Histology, Meibergdreef 15, 1105 AZ Amsterdam, The Netherlands. E-mail: C.J.VANNOORDEN@AMC.UVA.NL

MATERIALS AND METHODS

Human tissue specimens

Samples of normal mucosa ($n=17$), hyperplastic mucosa [$n=17$; small hyperplastic polyps (<5 mm): $n=10$; transitional mucosa adjacent to carcinomas: $n=7$], mucosa of patients with active Crohn's colitis ($n=6$), adenomatous mucosa ($n=35$; adenomas: $n=21$; dysplasia adjacent to carcinomas: $n=14$), and adenocarcinomas ($n=28$) of the colon were supplied by the Department of Pathology, University Hospital, Maastricht and by the Division of Gastroenterology, Academic Medical Centre, Amsterdam, The Netherlands.

A selection of adenoma patients who underwent total colonoscopy (index colonoscopy) and endoscopic polypectomy for colonic adenomas were included in the present study. None of the patients with adenomas or hyperplastic polyps had been previously diagnosed as having colonic neoplasms. Every half year up to 4 years after the initial procedure, surveillance colonoscopies were performed.

Mouse model

Primary colon carcinomas and (pre-)neoplastic lesions were induced in 20 female Swiss mice by weekly subcutaneous injections of 1,2-dimethylhydrazine dihydrochloride (Fluka, Buchs, Switzerland, 20 mg/kg body weight) dissolved in a physiological salt solution (pH 6.5) containing 1 mM EDTA for 18 weeks. Eight control mice received weekly subcutaneous injections of physiological salt solution (pH 6.5) containing 1 mM EDTA only, for the same period of time. After 4, 6, 8, 10, 12, 14, 16, and 18 weeks of treatment, treated and control mice were killed, followed by resection of the entire colon. The colon was opened longitudinally and faeces were removed. Afterwards, the colon was cut across in two parts and both parts were coiled up.¹⁷

Tissue processing

After resection, the tissue samples were immediately frozen in liquid nitrogen and stored at -80°C . Serial cryostat sections ($8\ \mu\text{m}$ thick) were cut at a cabinet temperature of -25°C on a motor-driven cryostat (Bright, Huntington, U.K.) at a low but constant speed to minimize variation in section thickness.¹⁸ The sections were mounted on clean glass slides and stored at -80°C until used. Pathological examination of the human specimens and mouse specimens was performed on haematoxylin and eosin-stained sections.

Quantitative histochemical assay of G6PDH activity

Incubation media for the histochemical assay of G6PDH activity consisted of 100 mM phosphate buffer (pH 7.45) containing 18 per cent (w/v) polyvinyl alcohol (PVA; weight average M_w 70 000–100 000; Sigma Chemical Co., St. Louis, MO, U.S.A.), 10 mM glucose-

6-phosphate (Boehringer, Mannheim, Germany), 0.8 mM NADP (Boehringer), 4.5 mM NT (Polysciences, Northampton, U.K.), and 0.45 mM 1-methoxyphenazine methosulphate (1-methoxyPMS; Serva, Heidelberg, Germany).¹⁸

Incubation media (6 ml) were poured into glass vials and equilibrated in an atmosphere of either 100 per cent oxygen or 100 per cent nitrogen (500–800 ml/min, 10 min, 37°C) using a tonometer, in order to avoid the formation of gas bubbles in the viscous media.¹⁹ Sections were air-dried for at least 5 min at room temperature before incubation. After placing plastic rings around the sections, media were poured onto the sections and coverslips were placed on top of the rings to avoid loss of gas from the incubation media. After exactly 10 min of incubation at 37°C , the viscous PVA-containing medium was rinsed from the sections with the use of 100 mM phosphate buffer (pH 5.3, 60°C). Afterwards, sections were mounted in glycerol jelly. The reproducibility was validated by the inclusion of at least two samples which were oxygen-insensitive in a previous run.

Formazan production was measured at 585 nm, the isobestic wavelength for the formazans of NT,²⁰ with a Vickers M85a scanning and integrating cytophotometer (Vickers Instruments, York, U.K.). The area scanned in each measurement was $3119\ \mu\text{m}^2$.¹² Five representative areas with the highest activity after incubation in the presence of oxygen were measured in each of three serial sections. Corresponding areas in three adjacent sections after incubation in the absence of oxygen were also measured. Control reactions were performed by omitting substrate and coenzyme from the incubation media,²¹ and resulting control values were subtracted from the test values. Arbitrary cytophotometric machine units were converted into amounts of substrate converted per gram wet weight of tissue per min.^{18,20} Residual G6PDH activity (RA) was calculated as the percentage of formazan produced in the presence of oxygen, compared with that produced in the absence of oxygen, after 10 min of incubation. We considered cells to be oxygen-sensitive when the RA was less than 20 per cent and oxygen-insensitive when the RA was more than 20 per cent.¹³

Statistical analysis

Kruskal–Wallis non-parametric ANOVA tests were applied to determine whether the groups of normal colonic mucosa, hyperplastic polyps, transitional and dysplastic mucosa adjacent to carcinomas, adenomas, and adenocarcinomas differed significantly in RA. In the case of significant differences, a Dunn's post test was applied to specify which stages exactly were different from the others.

Two-tailed Mann–Whitney tests were applied to establish differences in RA between different stages of the carcinogenesis process and between subgroups of adenomas on the basis of the degree of dysplasia [mild/moderate ($n=17$) vs. severe ($n=5$)], growth pattern [tubular ($n=16$) vs. tubulo-villous ($n=6$)], and adenoma

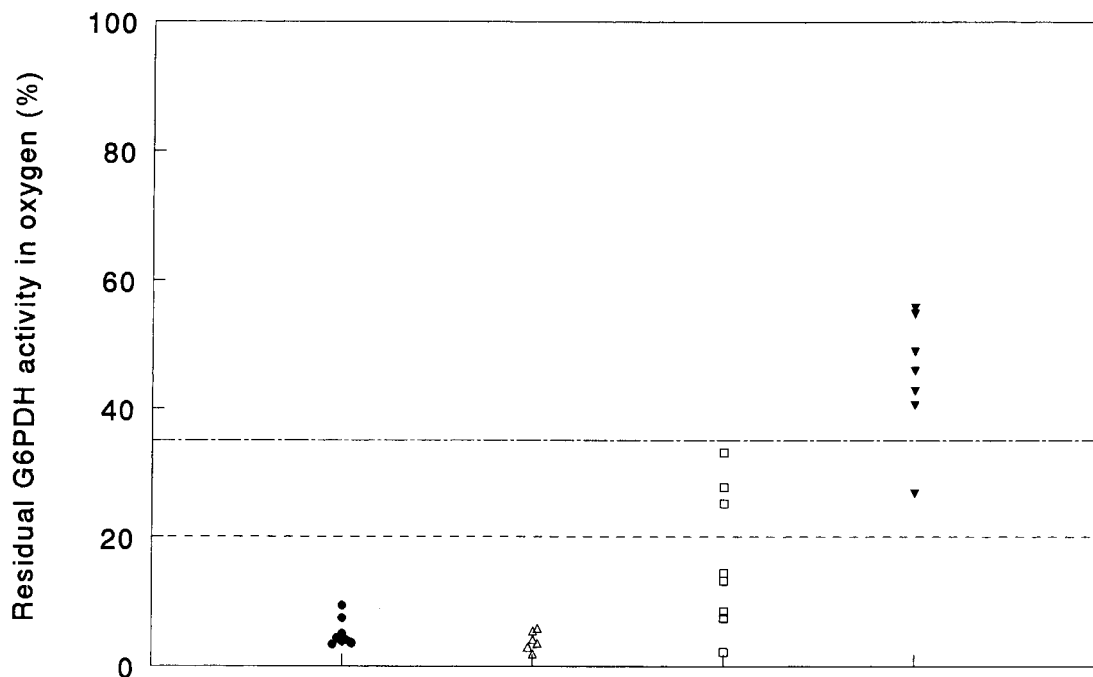


Fig. 1—Residual glucose-6-phosphate dehydrogenase activity (RA) in mouse colonic epithelial cells of (●) normal mucosa ($n=8$), (△) hyperplastic polyps ($n=6$), (□) adenomas ($n=8$), and (▼) carcinomas ($n=7$). The discrimination level between oxygen sensitivity and insensitivity is at a RA of 20 per cent (---), whereas indication of malignancy is at RA >35 per cent (—)

size [diameter ≤ 10 mm ($n=9$) vs. >10 mm ($n=13$)]. The level of significance was taken as 0.05.

RESULTS

The histochemical detection of G6PDH activity was specific, since omission of both substrate and coenzyme from the incubation media reduced the production of formazan below detection limits.

Carcinogenesis in mouse colon

Development of oxygen insensitivity in mouse colonic mucosa was clearly related to the stages of carcinogenesis, all of which were found. No dysplastic or hyperplastic mucosa was observed in the vicinity of the carcinomas. In total, six hyperplastic polyps, eight adenomas, and seven adenocarcinomas were present (Fig. 1). Colonic mucosa of control mice, but also the histologically normal mucosa of mice which developed (pre-)neoplasms, proved to be oxygen-sensitive (mean \pm SD: 5.7 ± 2.1 per cent). All hyperplastic polyps showed RA comparable to that of normal mucosa (mean \pm SD: 4.0 ± 1.5 per cent). Oxygen insensitivity (RA >20 per cent) appeared for the first time in the adenoma stage, in three of eight adenomas. The RA of adenomas (mean \pm SD: 16.4 ± 10.9 per cent) was significantly higher than that of normal mucosa and hyperplastic polyps. Significantly higher RA was present in carcinomas (mean \pm SD: 45.0 ± 9.9 per cent) when

compared with normal mucosa, hyperplastic polyps, and adenomas.

Oxygen insensitivity of the G6PDH assay in human colonic neoplasms

Similar RA patterns were observed in normal and (pre-)neoplastic epithelial cells of the mouse and human colon. G6PDH activity in normal human mucosa proved to be sensitive to oxygen without exception, independent of the activity in the absence of oxygen (Figs 2a and 2b). RA was always less than 20 per cent (mean \pm SD: 8.3 ± 2.4 per cent; Fig. 3). Mucosa of biopsies with Crohn's colitis contained patchy areas of inflammation predominantly consisting of lymphocytes. Epithelial cells in active Crohn's colitis also showed oxygen sensitivity (mean \pm SD: 6.2 ± 2.9 per cent; Fig. 3). Small hyperplastic polyps (<5 mm) and transitional mucosa adjacent to colorectal carcinomas were both oxygen-sensitive (mean \pm SD: 4.5 ± 2.4 per cent and 11.9 ± 4.0 per cent, respectively; Fig. 3).

In accordance with the findings in the mouse model, oxygen insensitivity in human colon carcinogenesis occurred first in the adenoma stage (Figs 3, 4a, and 4b). In 11 of 22 adenomas, oxygen insensitivity (RA >20 per cent) was demonstrated in dysplastic mucosa. RA was significantly higher in adenomas (mean \pm SD: 20.3 ± 9.9 per cent) than in normal mucosa and hyperplastic polyps. The mean RA of adenomas did not differ significantly from that of residual adenomas adjacent to carcinomas (mean \pm SD: 28.5 ± 14.7 per cent), but 5 of

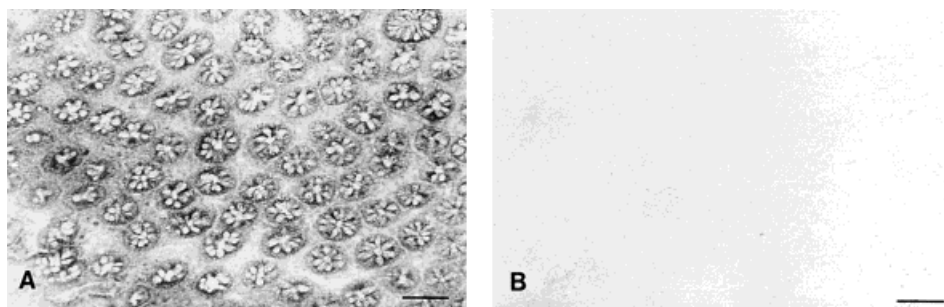


Fig. 2—Micrographs of serial cryostat sections of normal colonic mucosa after incubation to demonstrate G6PDH activity in an atmosphere of nitrogen (A) or oxygen (B). The residual G6PDH activity in oxygen was 8.7 per cent. Bar = 100 μ m

14 residual adenomas next to carcinomas showed RA similar to that of carcinomas (RA >35 per cent).

All samples of colorectal carcinomas were oxygen-insensitive (RA >20 per cent; Figs 3, 5a, and 5b). Furthermore, the RA in colorectal adenocarcinomas (mean \pm SD: 52.7 \pm 16.1 per cent) was significantly higher than in adjacent dysplastic mucosa, adenomas, transitional mucosa in the vicinity of carcinomas, hyperplastic polyps, and samples of normal mucosa. Of the carcinomas, 96, 86, and 50 per cent showed a RA \geq 35, 40, and 60 per cent, respectively.

Prognostic value of the oxygen insensitivity assay for adenomas

We investigated whether the oxygen insensitivity of adenomas indicated the development of metachronous

colonic adenomas or carcinomas. Of the 21 patients who underwent resection of adenomas, ten showed recurrence of one or more metachronous adenomatous polyps within 4 years of follow-up. Colorectal carcinomas were diagnosed in four other adenoma patients within 4 years after resection. Adenomas of patients without recurrence or those of patients who developed new adenomas or carcinomas did not differ significantly in RA. We also investigated whether there was a correlation between RA and histopathological prognostic parameters for adenomas, such as grade of dysplasia, growth pattern, and adenoma size. Of these parameters, only growth pattern appeared to be related to RA. A significantly higher RA was demonstrated in tubulo-villous adenomas (mean \pm SD: 25.8 \pm 8.8), when compared with tubular adenomas (mean \pm SD: 17.6 \pm 9.2). In these tubulo-villous adenomas, we determined the

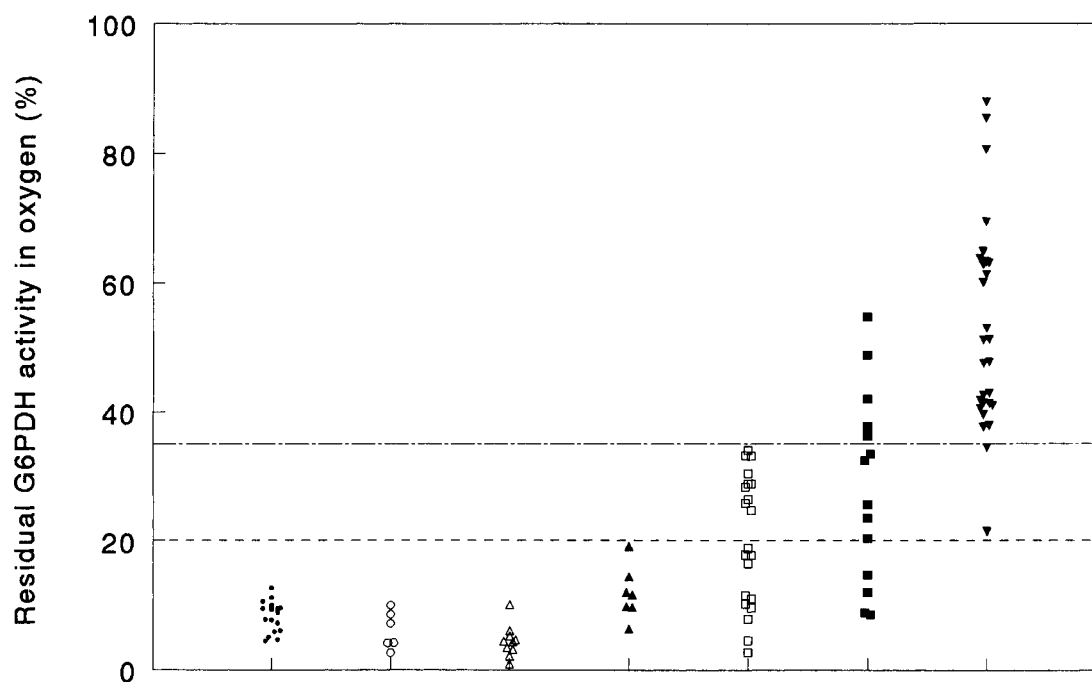


Fig. 3—Residual glucose-6-phosphate dehydrogenase activity (RA) in human colonic epithelial cells of (●) normal mucosa ($n=17$), (○) mucosa of acute Crohn's colitis ($n=6$), (△) hyperplastic polyps ($n=10$), (▲) transitional mucosa nearby a carcinoma ($n=7$), (□) adenomas ($n=21$), (■) dysplasia nearby a carcinoma ($n=14$), and (▼) carcinomas ($n=28$). The discrimination level between oxygen sensitivity and insensitivity is at a RA of 20 per cent (---), whereas indication of malignancy is at RA >35 per cent (—)

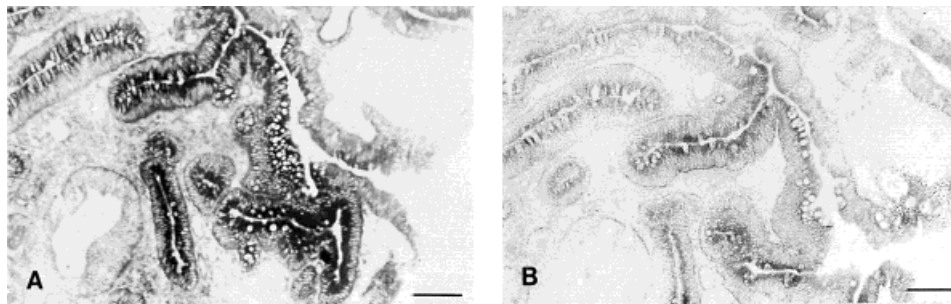


Fig. 4—Micrographs of serial cryostat sections of a moderately dysplastic adenoma after incubation to demonstrate G6PDH activity in an atmosphere of nitrogen (A) or oxygen (B). The residual G6PDH activity in oxygen was 37.5 per cent. Bar=100 μ m

RA in crypts with a villous growth pattern, since here a markedly higher RA was observed than in the areas with a tubular architecture. Five of six tubulo-villous adenomas showed oxygen insensitivity, whereas only six of 16 tubular adenomas were insensitive to oxygen.

DISCUSSION

Colorectal cancer appears to develop through a multi-step process in which adenomas are precursor lesions.²² In the present study, the effects of oxygen on the quantitative histochemical assay to detect G6PDH activity based on NT reduction were studied in different stages of carcinogenesis in the colon, in order to establish transition of oxygen sensitivity to oxygen insensitivity in the carcinogenetic process, and thereby its potential diagnostic value. Oxygen sensitivity (RA <20 per cent) was found in normal mucosa in both humans and mice. Since precancerous dysplasia is rarely observed in patients with Crohn's colitis,²³ we included biopsies of inflamed mucosa in the present study as an additional control. Epithelial cells in these biopsies were all sensitive to oxygen. Although there are some exceptions to the rule, hyperplastic polyps are generally considered non-neoplastic and are in this respect comparable to normal colorectal mucosa.²⁴ In this regard, it is of note that hyperplastic polyps all show oxygen sensitivity.

Although large hyperplastic polyps may contain a focus of cancer and may be coincident with adenomas and synchronous carcinomas,²⁵ there is no evidence that hyperplastic mucosa is more prone to neoplastic change than normal mucosa. This is endorsed by our finding

that hyperplastic epithelium in mucosa adjacent to carcinomas was sensitive to oxygen, like normal epithelium and hyperplastic polyps (Fig. 3).

In the carcinogenetic process, oxygen insensitivity was observed first in adenomas, both in humans and in mice (Figs 1 and 3). A limited rise in oxygen insensitivity occurred in 37–50 per cent of the adenomas, but RA never exceeded 35 per cent. Because of this finding and the fact that 96 per cent of the carcinomas showed RA greater than 35 per cent, this percentage appears to be the level to establish malignancy. Only one human and one mouse adenocarcinoma formed exceptions (RA of 22 and 26 per cent, respectively; Figs 1 and 3). The finding that RA is more than 35 per cent in one-third of residual adenomas adjacent to carcinomas (Fig. 3) is an indication of either malignant transformation or a direct effect of the neighbouring cancer on the metabolism in these adenomas.²⁶

The prognostic value of the assay for premalignant colonic mucosa seems to be limited. Significantly higher RA was observed in tubulo-villous adenomas than in tubular adenomas. In terms of their morphology, size, and malignant potential, tubulo-villous adenomas may be regarded as intermediate between tubular and villous adenomas, of which the propensity for malignant change is high.¹ A correlation could not be demonstrated between the RA of adenomas and other prognostic indicators, such as degree of dysplasia and adenoma size. However, smaller (<10 mm) adenomas, which are often regarded as early adenomas, have a much higher malignant potential than previously suspected.^{27,28}

The metabolic background of the oxygen insensitivity of neoplastic epithelium is not yet completely clear, but

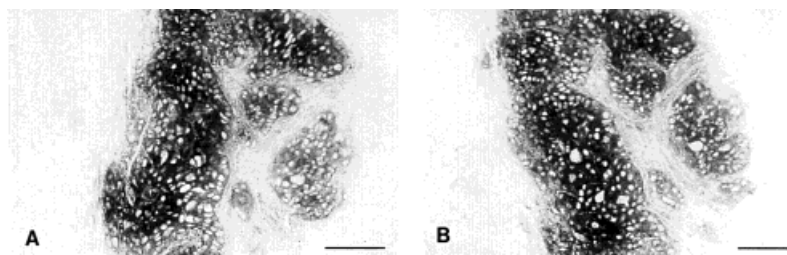


Fig. 5—Micrographs of serial cryostat sections of a poorly differentiated adenocarcinoma after incubation to demonstrate G6PDH activity in an atmosphere of nitrogen (A) or oxygen (B). The residual G6PDH activity in oxygen was 88.7 per cent. Bar=100 μ m

there is evidence that the formation of oxygen radicals is involved, as discussed by Best *et al.*¹² and Griffini *et al.*¹³ The oxygen insensitivity of the G6PDH assay can be considered to be a reliable tool to be used in addition to histopathology in difficult cases, for the identification of (potentially) malignant cells. Since the assay can be performed in 15 min, it can be applied during surgical resection of carcinomas for verification of macroscopically tumour-free margins, or the presence or absence of occult (potentially) malignant cells or foci.

ACKNOWLEDGEMENTS

We are grateful to Dr A. H. N. Hopman, Department of Pathology, University Hospital, Maastricht, and Dr J. F. W. Bartelsman, Division of Gastroenterology, Academic Medical Centre, Amsterdam, for supply of colon specimens. The helpful suggestions of Professor Dr G. J. A. Offerhaus, Department of Pathology, Academic Medical Centre, and Professor Dr F. T. Bosman, Department of Pathology, University of Lausanne, Switzerland, are gratefully acknowledged. The preparation of the figures by Mr J. Peeterse and of the manuscript by Ms T. M. S. Pierik is highly appreciated.

REFERENCES

- Muto T, Bussey HJR, Morson BC. The evolution of cancer of the colon and the rectum. *Cancer* 1975; **36**: 2251–2270.
- Jass JR. Do all colorectal carcinomas arise in preexisting adenomas? *World J Surg* 1989; **13**: 45–51.
- Winawer SJ, Zauber AG, O'Brien MJ, *et al.* Randomized comparison of surveillance intervals after colonoscopic removal of newly diagnosed adenomatous polyps. *N Engl J Med* 1993; **328**: 901–906.
- Hixson LJ, Fennerty MB, Sampliner RE, McGee DL, Garewal H. Two-year incidence of colon adenomas developing after tandem colonoscopy. *Am J Gastroenterol* 1994; **89**: 687–691.
- Ransohoff DF, Lang CA, Kuo HS. Colonoscopic surveillance after polypectomy: considerations of cost effectiveness. *Ann Intern Med* 1991; **114**: 177–182.
- Maté J, Durán R, Lara S, Pajares JM, Moreno-Otero R. A study of the lactate dehydrogenase isoenzyme patterns in the adenoma–carcinoma sequence of the colon. *Hepato-Gastroenterology* 1993; **40**: 471–474.
- Bannasch P, Moore MA, Klimek F, Zerban H. Biological markers of preneoplastic foci and neoplastic nodules in rodent liver. *Toxicol Pathol* 1982; **10**: 19–34.
- Weber G. Enzymology of cancer cells. Parts I and II. *N Engl J Med* 1977; **296**: 486–493, 541–551.
- Van Noorden CJF. Histochemistry and cytochemistry of glucose-6-phosphate dehydrogenase. *Prog Histochem Cytochem* 1984; **15/1**: 1–84.
- Ibrahim KS, Husain O, Bitensky L, Chayen J. A modified tetrazolium reaction for identifying malignant cells from gastric and colonic cancer. *J Clin Pathol* 1983; **36**: 133–136.
- Butcher RG. The oxygen insensitivity phenomenon as a diagnostic aid in carcinoma of the bronchus. In: Pattison JR, Bitensky L, Chayen J, eds. *Quantitative Cytochemistry and its Applications*. New York: Academic Press, 1979; 241–251.
- Best AJ, Das PK, Patel HRA, Van Noorden CJF. Quantitative cytochemical detection of malignant and potentially malignant cells in the colon. *Cancer Res* 1990; **50**: 5112–5118.
- Griffini P, Vigorelli E, Jonges GN, Van Noorden CJF. The histochemical G6PDH reaction but not the LDH reaction with neotetrazolium is suitable for the oxygen sensitivity test to detect cancer cells. *J Histochem Cytochem* 1994; **42**: 1355–1363.
- Petersen OW, Hoyer PE, Hilgers J, Briand P, Van Deurs B. Characterization of epithelial cell islets in primary monolayer cultures of human breast carcinomas by the tetrazolium reaction for glucose-6-phosphate dehydrogenase. *Virchows Arch B* 1985; **50**: 27–42.
- Grossman S, Milos ML, Tewaka IS, Jewell NP. Colonoscopic screening of persons with suspected risk factors for colon cancer. II. Past history of colorectal neoplasms. *Gastroenterology* 1989; **96**: 299–306.
- Jørgensen OD, Kronborg O, Fenger C. The Funen adenoma follow-up study. *Scand J Gastroenterol* 1993; **28**: 869–874.
- Butcher RG, Evans AW. Diffusion during dehydrogenase reactions: the effects of intermediate electron acceptors. *Histochem J* 1984; **16**: 885–895.
- Van Noorden CJF, Frederiks WM. *Enzyme Histochemistry: A Laboratory Manual of Current Methods*. Oxford: Oxford University Press, 1992.
- Butcher RG. Oxygen and the production of formazan from neotetrazolium chloride. *Histochemistry* 1978; **56**: 329–340.
- Butcher RG. Precise cytochemical measurement of neotetrazolium formazan by scanning and integrating microdensitometry. *Histochemistry* 1972; **32**: 171–190.
- Butcher RG, Van Noorden CJF. Reaction rate studies of glucose-6-phosphate dehydrogenase activity in sections of rat liver using four tetrazolium salts. *Histochem J* 1985; **17**: 993–1008.
- Fearon ER, Vogelstein B. A genetic model for colorectal tumorigenesis. *Cell* 1990; **61**: 759–767.
- Warren R, Barwick W. Crohn's colitis with carcinoma and dysplasia. Report of a case and review of 100 small and large bowel resections for Crohn's disease to detect incidence of dysplasia. *Am J Surg Pathol* 1983; **7**: 151–159.
- Jass JR. Relationship between metaplastic polyp and carcinoma of the colorectum. *Lancet* 1983; **i**: 28–30.
- Warner AS, Glick ME, Fogt F. Multiple large hyperplastic polyps of the colon coincident with adenocarcinoma. *Am J Gastroenterol* 1994; **89**: 123–125.
- Jonges GN, Vogels IMC, Bosch KS, Dingemans KP, Van Noorden CJF. Experimentally induced colon cancer metastases in rat liver increase the proliferation rate and capacity for purine metabolism in liver cells. *Histochemistry* 1993; **100**: 41–51.
- Muto T, Kamiya J, Sawada T, *et al.* Colonoscopic polypectomy in diagnosis and treatment of early carcinoma of the large intestine. *Dis Colon Rectum* 1980; **23**: 68–75.
- Watanabe T, Sawada T, Kubota Y, *et al.* Malignant potential in flat elevations. *Dis Colon Rectum* 1993; **36**: 548–553.