



## UvA-DARE (Digital Academic Repository)

### Advances in MRI of the colon and pelvic floor

Zijta, F.M.

**Publication date**

2012

**Document Version**

Final published version

[Link to publication](#)

**Citation for published version (APA):**

Zijta, F. M. (2012). *Advances in MRI of the colon and pelvic floor*. [Thesis, fully internal, Universiteit van Amsterdam].

**General rights**

It is not permitted to download or to forward/distribute the text or part of it without the consent of the author(s) and/or copyright holder(s), other than for strictly personal, individual use, unless the work is under an open content license (like Creative Commons).

**Disclaimer/Complaints regulations**

If you believe that digital publication of certain material infringes any of your rights or (privacy) interests, please let the Library know, stating your reasons. In case of a legitimate complaint, the Library will make the material inaccessible and/or remove it from the website. Please Ask the Library: <https://uba.uva.nl/en/contact>, or a letter to: Library of the University of Amsterdam, Secretariat, Singel 425, 1012 WP Amsterdam, The Netherlands. You will be contacted as soon as possible.

# Advances in MRI of the colon and pelvic floor

Advances in MRI of the colon and pelvic floor

F.M. Zijta

Frank M. Zijta



# **Advances in MRI of the colon and pelvic floor**

Thesis: Advances in MRI of the colon and pelvic floor

This thesis was prepared at the Department of Radiology, Academic Medical Center, University of Amsterdam, The Netherlands.

Copyright © 2012, Frank Zijta, Amsterdam, The Netherlands.

No parts of this thesis may be reproduced, stored, or transmitted in any form or by any means, without prior permission of the author.

Printing of this thesis was financially supported by:

- Department of Radiology, Academic Medical Center, Amsterdam, the Netherlands
- the University of Amsterdam, the Netherlands
- Teaching Hospital, Onze Lieve Vrouwe Gasthuis, Amsterdam, the Netherlands

Layout: Frank Zijta  
Shandra Bipat  
Jaap Groen

Cover: Fibre trajectories representing the anal sphincter complex.

Printed by: Ipskamp Drukkers B.V., Enschede

ISBN: 978-94-6191-211-4



# **Advances in MRI of the colon and pelvic floor**

## **ACADEMISCH PROEFSCHRIFT**

ter verkrijging van de graad van doctor  
aan de Universiteit van Amsterdam  
op gezag van de Rector Magnificus  
Prof. dr. D.C. van den Boom

ten overstaan van een door het college voor promoties ingestelde  
commissie, in het openbaar te verdedigen in de Agnietenkapel  
op donderdag 12 april 2012, te 10.00 uur

door

Frank Marinus Zijta

geboren te Alkmaar

# Promotiecommissie

Promotor: Prof. dr. J. Stoker

Co-promotores: Dr. A.D. Montauban van Swijndregt  
Dr. ir. A.J. Nederveen

Overige leden: Prof. dr. J.S. Laméris  
Prof. dr. M.P.M. Burger  
Prof. dr. P. Fockens  
Prof. dr. R.G.H. Beets-Tan  
Dr. C.H. van der Vaart  
Dr. J.J. Fütterer

Faculteit der Geneeskunde

# Contents

<b>Chapter 1</b>	General introduction and outline of the thesis	7
	<i>Part I : MR colonography</i>	
<b>Chapter 2</b>	Colonography by magnetic resonance imaging. <i>MRI of the Colon (Colonography): Results. Medical Radiology Diagn. Imaging. MRI of the Gastrointestinal Tract – J. Stoker (Ed). 185-204. MRI of the colon. Imaging in Medicine 2010; 2:195-209.</i>	25
<b>Chapter 3</b>	Magnetic resonance (MR) colonography in the detection of colorectal lesions: a systematic review of prospective studies. <i>Eur Radiol. 2010;20:1031-46.</i>	47
<b>Chapter 4</b>	Diagnostic performance of radiographers as compared to radiologists in magnetic resonance colonography. <i>Eur J Radiol. 2010;75:e12-7.</i>	77
<b>Chapter 5</b>	Feasibility of using automated insufflated carbon dioxide (CO <sub>2</sub> ) for luminal distension in 3.0T MR colonography. <i>Eur J Radiol. 2011. Epub ahead of print.</i>	93
	<i>Part II : MRI of the pelvic floor</i>	
<b>Chapter 6</b>	Dynamic magnetic resonance imaging to quantify pelvic organ prolapse; reliability of assessment and correlation with clinical findings and pelvic floor symptoms. <i>Submitted.</i>	111
<b>Chapter 7</b>	Feasibility of diffusion tensor imaging (DTI) with fibre tractography of the normal female pelvic floor. <i>Eur Radiol. 2011;21:1243-9.</i>	127
<b>Chapter 8</b>	Evaluation of the female pelvic floor in pelvic organ prolapse using 3.0T diffusion tensor imaging and fibre tractography. <i>Submitted</i>	141

<b>Chapter 9</b>	ENG: Summary, conclusions and implications	<b>159</b>
<b>Chapter 10</b>	NL: Samenvatting, conclusies en implicaties	<b>167</b>
<b>Chapter 11</b>	<b>Appendix</b> List of Publications Dankwoord Curriculum Vitae	<b>177</b>



# Chapter **1**

## **General Introduction and Outline of the Thesis**

### **Part I: MRI of the colon**

First part of this thesis focuses on magnetic resonance (MR) colonography as a method for the detection of colorectal lesions in patients suspected for colorectal cancer. An overview of the results of MR colonography in the present literature is presented and diagnostic accuracy in colorectal polyp detection is estimated. Furthermore, performance characteristics of observers with a different educational background in polyp detection were assessed. Finally, we focused on the gaseous distension of the colon using 3.0T MR colonography. Below, a concise description of colorectal cancer screening, computed tomographic (CT) colonography and MR colonography is provided.

#### **Colorectal cancer**

Colorectal cancer (CRC) is one of the most prevalent causes of cancer related death in the Western world. Each year, approximately one million people are diagnosed with CRC worldwide and this cancer accounts for around 500.000 deaths [1]. The adenoma-carcinoma sequence is considered to be crucial for development of CRC, in which an adenomatous polyp advances to a carcinoma in an estimated time-scale of approximately ten years [2].

There is strong evidence that strategies aiming to detect and remove these benign precursors of CRC result in reduced cancer-related mortality and incidence [3,4]. Furthermore the detection of CRC in a confined stage, consequently preventing advanced disease, reduces both cancer-related mortality and morbidity [5]. Thus, early detection of CRC and its precursor is the main objective in population screening programs for CRC [6].

Screening test for CRC either concerns faecal tests or luminal tests. The principal advantage of faecal tests over luminal screening tests, include low-costs and the lack of a pre-procedural bowel preparation. These stool-based tests concern guaiac faecal occult blood test (gFOBT), faecal immunochemical test (FIT) and faecal DNA tests. For gFOBT has been demonstrated that it significantly decreases colon cancer mortality [7], although the test characteristics are rather mediocre. FIT has superior yield (exclusively detects human haemoglobin) and participation rate as compared to gFOBT and is for several countries (including the Netherlands) the preferred screening test [8]. Finally, faecal DNA testing encompasses a fairly novel stool-based test which requires further research [9].

Luminal screening tests seek to detect (precursors of) CRC directly, and include conventional colonoscopy, sigmoidoscopy, barium double contrast examination (barium enema) and computed tomographic (CT) colonography. To

date, conventional colonoscopy is the most accurate technique for adenoma and CRC screening. It combines both the detection of lesions with subsequent polypectomy and histopathology, and is generally recommended in subjects at increased risk for CRC and symptomatic patients [10]. Even though sigmoidoscopy as screening tool has been demonstrated to lead to a reduction in CRC incidence and mortality larger than in gFOBT screening [11], the tendency to develop proximal colon neoplasia with advancing age and therefore polyp-undetectability during distal colon screening, is a recognized limitation [12]. Further, the use of a barium enema is obsolete if other luminal screening tests are available, whereas it's accuracies in polyp-detecting are fairly poor [9]. The use of CT colonography in polyp detection is briefly summarized in the next paragraph.

### **Computed tomographic (CT) colonography**

Although endoscopy is frequently applied, it entails a rather invasive procedure. Conventional colonoscopy is characterized by a high procedural discomfort, which eventually result in confined participation rates in CRC screening programs [13].

Therefore less invasive luminal techniques have emerged, of which computed tomographic (CT) colonography has gained most interest in the literature in the last decade [14,15]. Overall, based on recent research CT colonography demonstrates an excellent accuracy for detecting clinically significant colorectal lesions.

In CT colonography the patient is scanned in the supine and prone position using a multislice CT scanner, enabling a cross-sectional assessment of the colon and extra colonic structures. For optimal evaluation of the colon, it is either cleansed, using cathartic bowel preparation, or prepared with a faecal tagging agent for mimicking stool rests [15]. High-osmolar iodine contrast tagging is a frequently applied tagging regimen in CT colonography, demonstrating high-image quality already at low tagging doses consequently resulting in lesser patient burden [16]. During CT colonography, the colorectum is distended by the insufflation of carbon dioxide (CO<sub>2</sub>) which is mostly achieved by the use of an automated insufflator. CO<sub>2</sub> is quickly absorbed through the colon wall and excreted, therefore resulting in lesser patient discomfort. Furthermore, bowel relaxing agents are used to improve colonic distension and diminishing per procedural discomfort.

Following acquisition, image interpretation includes an two-dimensional (2D) axial read with three-dimensional (3D) comparison for problem solving or primary 3D read with 2D comparison for problem solving. Yet, the accuracy of CT

colonography in polyp detecting is significantly determined by reader performance which is inherently correlated with reader experience [17]. Proposed double interpretation strategies to improve CT colonography accuracies include the use of computer-aided diagnosis (CAD) and the use of non-radiologists as second readers.

### **Magnetic resonance (MR) colonography**

An important issue of CT colonography as a mass screening tool applied in average-risk population, is the benefit-risk ratio of the examination related to the cancer risk associated with the radiation exposure [18]. Therefore efforts have been made to obtain a per-examination radiation exposure which is as low as reasonable achievable with maintenance of adequate image quality [19]. Still, the risk is not negligible and consequently a comparable imaging technique with similar accuracy estimates but without radiation exposure would be preferable. Magnetic resonance imaging (MRI) could fulfil this role. The clinical role of MRI in colorectal imaging is increasing and this technique is currently commonly applied in the areas of inflammatory bowel disease (IBD) [20] and rectal cancer staging [21]. Similar to CT colonography for the detection of (precursors of) CRC, in magnetic resonance (MR) colonography the colon is cross sectional evaluated following colonic distension with the use of a luminal contrast medium [22].

Major impetus for the use of MR colonography in the detection and screening for precursors of CRC, would be the lack of ionizing radiation exposure and the high soft tissue contrast. However the limited availability, relatively high costs and rather complexity of MR colonography as compared to CT colonography has limited the use of MRI in this area [23]. Nonetheless, several research groups have studied MR colonography [24-26], with however a substantial diversity in proposed bowel preparation methods, luminal distending agents and technical parameters, which makes it rather difficult to interpret and compare the available study data.

Procedural discomfort is dependent of applied study elements, which among others includes the type of bowel preparation and type of luminal distending agent. Traditionally, in MR colonography the administration of a water-based enema has been preferred over gaseous distension due to technical issues related to the presence of artefacts on the air / soft-tissue interfaces, which has negatively influenced patient acceptance of MR colonography [27]. Utilizing gaseous agents as luminal distending agent, as applied in CT-colonography, will



most likely positively influence procedural discomfort but attained only limited interest in MR colonography literature.

### **Part II: MRI of the pelvic floor**

Second part of this thesis concerns the evaluation of the female pelvic floor using both conventional static and dynamic MRI techniques which enables to describe the functional pelvic floor support on a macro structural level. Also a more extended MRI technique is introduced to describe micro structural characteristics of the pelvic floor support.

The pelvic floor is multifunctional unit of muscles, fasciae and ligaments that have numerous interconnections and connections to bony structures, organs and the fibro elastic network within fat-containing spaces. Below, a brief description is presented of the basic female pelvic floor anatomy, pelvic floor disorders and the available imaging techniques.

#### **Anatomy of the female pelvic floor**

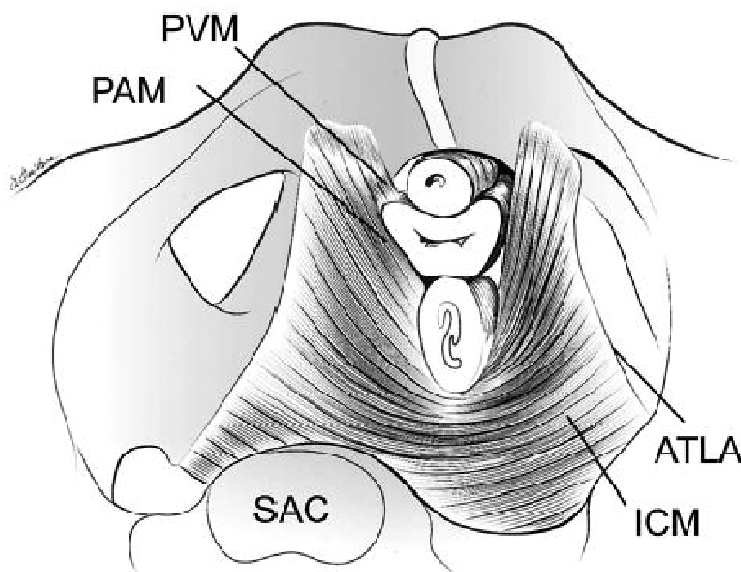
##### *Pelvic diaphragm*

The endopelvic fascia comprises the most superior supporting layer of the pelvic floor. It consists of connective tissue surrounding and supporting the pelvic viscera [28]. The pelvic floor is principally formed by the *pelvic diaphragm* which is generally considered to consist of paired striated muscles, combined recognized as the levator ani muscle and coccygeus muscle, and associated fascia. The levator ani muscle consists of several subdivisions that are defined by their origin and point of insertion (*Figure 1*). The pubovisceral muscle, originating from the dorsal aspect of the pubic bone, supports and elevates the abdominopelvic viscera and is composed of the pubovaginal -, the puboperineal - and the puboanal muscle, respectively (*Figure 2*) [29].

The interior margin of the pubovisceral muscle forms the urogenital hiatus' border, through which passes the urethra, vagina and anal sphincter. Whereas the key function of these muscles is to support the pelvic viscera, damage of this muscular support will ultimately result in a loss of support and compromised function of pelvic organs [30]. The second subdivision of the levator ani musculature is located at the inferior border of the pelvic diaphragm, this is the puborectal muscle which forms a sling just below the anorectal junction which subsequently forms the anorectal angle (*Figure 2*). During defecation, the puborectal muscle relaxes and the anorectal angle becomes obtuse, facilitating

## Chapter 1

defecation. The most posterior subdivision of the levator ani muscle is the iliococcygeus muscle, originating laterally from the *tendinous arch of the levator ani*, (which is formed by the internal obturator fascia) and inserting medially to the anococcygeal ligament and inferior part of the coccygeal bone. The iliococcygeus muscle is frequently poorly developed [31]. Separately from the levator ani muscle, the coccygeus muscle is the posterior constituent of the pelvic diaphragm, arising from the ischial spine and inserting at the lateral side of the coccyx and the lowest part of the sacrum [28].



**Figure 1.** The levator ani muscle seen from above looking over the sacral promontory (SAC) showing the pubovaginal muscle (PVM). The urethra, vagina, and rectum have been transected just above the pelvic floor. PAM = puboanal muscle; ATLA = arcus tendineus levator ani; and ICM = iliococcygeus muscle. (The internal obturator muscles have been removed to clarify levator muscle origins.) (Copyright © DeLancey 2003. Kearney R, Sawhney R, DeLancey JO. Levator ani muscle anatomy evaluated by origin-insertion pairs. *Obstet Gynecol.* 2004;104(1):168-73. With permission.)

### *Perineum*

The area inferior to the pelvic diaphragm is the perineum which is anatomically demarcated from anterior to posterior by the pubic symphysis, inferior pubic ramus, ischial tuberosity, sacrotuberous ligament and the coccyx. The *urogenital*

*diaphragm* comprises a small layer of striated muscle, which covers the anterior aspect of the perineum and encloses the urethra and vagina and is considered as the most inferior layer of the pelvic floor. Although its precise composition is still under debate, among others it comprises both fibromuscular components of the compressor urethra and the external urethral sphincter muscle [28]. Centrally at the posterior border of the urogenital diaphragm, directly anterior of the anal sphincter, the central perineal tendon is located which is organized of several fibromuscular structures converging at this location (*Figure 2*). In women this structure is more distinct if compared to men, and often is defined as the *perineal body*. Anatomical structures interweaving in this complex area include the superficial transverse perineal muscle, the puboperineal muscle, the bulbospongiosus muscle and fibers of the external anal sphincter [28]. The most superficial layer of the perineum is formed by the bulbospongiosus - , ischiocavernosus - and superficial transverse perineal muscle.

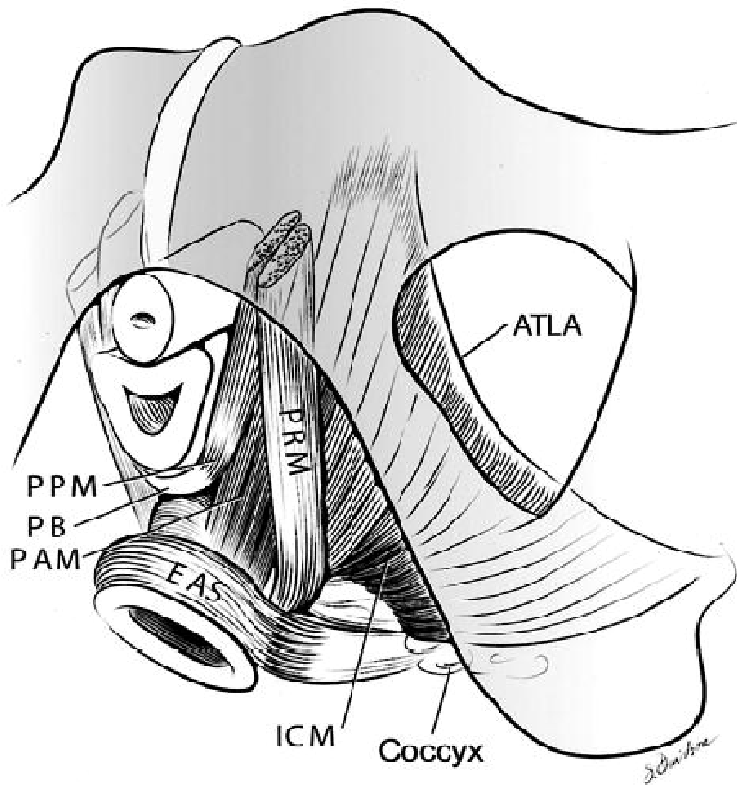
### *The anal and urethral sphincter complex*

The anal canal is surrounded by two muscular cylindrical layers which include both the inner layer of the internal sphincter and outer layer comprising the striated external anal sphincter and puborectal muscle. The internal anal sphincter is composed of smooth muscle cells and its function is exclusively involuntary. The lower half of the outer layer is the external anal sphincter. The external sphincter has a voluntary function and is bounded superiorly by the puborectal muscle, which forms the upper outer part of the anal sphincter complex and is also characterized by a voluntary muscle contraction and -relaxation.

Similar to the anal canal, the female urethra is enclosed by two predominantly circular orientated muscular layers. The inner layer consists of a smooth muscle sphincter (lissosphincter), the outer layer is formed by a striated muscle sphincter, the rhabdosphincter.

### **Pelvic floor disorders**

The pelvic floor provides support to the abdominopelvic viscera, i.e. bladder, vagina, uterus and lower part of the gastrointestinal tract. Also it plays a prominent role in the maintenance of urinary and faecal continence. Therefore, weakening or damage to the pelvic floor support will result in a decrease of support and ultimately in functional pelvic floor disorders such as pelvic organ prolapse and urinary / faecal incontinence. These functional disorders result in a



**Figure 2.** Schematic view of the levator ani muscles from below after the vulvar structures and perineal membrane have been removed showing the arcus tendineus levator ani (ATLA); external anal sphincter (EAS); puboanalis muscle (PAM); perineal body (PB) uniting the 2 ends of the puboperineal muscle (PPM); iliococcygeal muscle (ICM); puborectal muscle (PRM). Note that the urethra and vagina have been transected just above the hymenal ring. (Copyright © DeLancey 2003. Kearney R, Sawhney R, DeLancey JO. Levator ani muscle anatomy evaluated by origin-insertion pairs. *Obstet Gynecol.* 2004;104(1):168-73. With permission.)

wide range of symptoms (e.g. incontinence, prolaps) and have a considerable effect on the quality of life [32,33].

Pelvic organ prolapse entails the descent of one or more of the anterior vaginal wall, posterior vaginal wall, the uterus (cervix), or the apex of the vagina in correlation with associated symptoms (e.g. vaginal bulging, increased pelvic pressure) [34]. These associated symptoms are believed to occur if the prolapse reaches the hymen level [34, 35]. It represents an important health care concern, affecting women in particular at higher age. The aetiology of pelvic organ



prolapse is complex and multifactorial and is currently only partly understood. It is believed to result from a combination of different causal factors which among others include advancing age, obesity, connective tissue abnormalities, complicated vaginal delivery, denervation and/or weakness of the pelvic floor [36].

An increased weakening and misbalance of the passive and active components of the pelvic support can consequently result in prolapse of unsupported pelvic viscera of at least one of the three anatomical pelvic floor compartments (i.e. anterior, middle and posterior compartment). It can thus involve a pathologic protrusion of the urethra (urethrocele) or bladder (cystocele); vaginal apex or uterus descent (vaginal vault or uterine prolapse); small bowel (enterocele), peritoneum (peritoneocele), sigmoid or rectum (sigmoidocele or rectocele, respectively). The severity of both symptoms and the maximum grade of protrusion will ultimately determine treatment of the organ prolapse [37]. If surgical prolapse repair is considered, an adequate preoperative triage is essential to prevent surgical failure. Pelvic floor imaging, to complement frequently used clinical assessment systems [38], currently plays a limited role in the assessment of pelvic floor disorders. However, given the high recurrence rates after initial surgical treatment [39], there is an increasing interest in using additional pelvic floor imaging [40-42].

### **Imaging of the female pelvic floor**

Initially, defecography was the principal diagnostic imaging tool to assess pelvic floor dysfunction and still is frequently applied. Especially in case of a suspected posterior wall prolapse, defecography has been demonstrated to be valuable in the standard diagnostic work-up [43].

In anal incontinence, endoanal ultrasound and to a limited extent MRI are used for the evaluation of anal sphincter anatomy and injury. Translabial or transperineal two -, three - or four dimensional (2D / 3D/ 4D) ultrasound is a clinical easy accessible real-time diagnostic imaging tool in the investigation of pelvic floor disorders which has been increasingly recommended in pelvic floor disorders [44]. The levator ani muscle integrity and the degree of hiatal distension can be easily determined using this dynamic technique, which has also shown high accuracies in the identification of anal sphincter defects [45]. Principal limitations of pelvic floor ultrasound include the operator dependency and the restricted visualization of the complete pelvic floor.

In the past two decades, both static and dynamic magnetic resonance imaging (MRI) have substantially developed [40,46,47]. The lack of ionizing radiation and the high-contrast evaluation of the complete pelvic floor muscles and pelvic viscera, advantages MRI over conventional X-ray defecography. Limitation is that the MRI examination is performed in the supine position. Dynamic MR imaging permits the evaluation of all three anatomical pelvic floor compartments at rest and during straining, with or without the use of vaginal and/ or rectal contrast opacification. By the use of standardized pelvic anatomical landmarks and reference lines, pelvic floor prolapse can be graded [40,48]. Still, the exact correlation of MRI findings with respect to subjective pelvic floor symptoms and prolapse stage is largely unknown and therefore the additional value of dynamic MRI in pelvic floor disorders remains unclear.

Continuing MRI developments currently allow static data acquisition of the pelvic floor with high spatial resolution, enabling the identification of structural levator ani muscle defects [49] and reliable categorization of these structural supportive muscle defects [50]. Towards an advanced understanding of the supportive defects associated with pelvic floor dysfunction, three-dimensional (3D) rendering techniques of high resolution two-dimensional (2D) static pelvic floor MRI images have recently been reported [51]. Evidently, MRI might have the potential to give new insights in the precise pathophysiology which contributes to pelvic organ prolapse, yet current conventional MRI techniques seem to have reached their technical optimisation limits.

## Outline of the thesis

This thesis focuses on magnetic resonance imaging (MRI) of the colon and female pelvic floor. *Part I* of this thesis studies MR colonography as a possible imaging technique for the evaluation of the colon.

**Chapter 2** presents an overview of the results of MR colonography in detecting (precursors of) colorectal cancer (CRC) as presented in the literature. Both diagnostic values and patient acceptance of different acquisition methods are discussed. In **chapter 3** the literature on the accuracy of MR-colonography is summarized in a systematic review.

Observer performance plays an important role in measures of accuracy of MR-colonography for detection of (precursors) of CRC. Double read strategies have been effective in limiting inter-observer variability, and the use of trained non-radiologists as potential second readers in MR colonography might be feasible. The aim of **chapter 4** was to assess and compare performance of trained radiographers to the performance of trained radiologists in the detection of colorectal polyps using bright lumen MR colonography examinations.

Prerequisite for an adequate assessment of the colonic wall using MR colonography is an optimal distended colon. The feasibility of automated insufflated carbon dioxide (CO<sub>2</sub>) as distending agent in MR colonography, particularly regarding the presence of susceptibility artefacts is evaluated in **chapter 5**. We studied CO<sub>2</sub> insufflation with different applied bowel preparation regimes in terms of image quality and burden.

*Part II* of this thesis focuses on the ability of MRI to study the normal female pelvic floor and to evaluate potential clinical applications, using both frequently used and advanced MRI examination methods.

Static and dynamic MRI is increasingly proposed to supplement clinical data and physical examination in diagnosing and grading pelvic organ prolapse. In **chapter 6** we investigated the reliability of prolapse staging using dynamic MRI, as assessed in women with - and without pelvic organ prolapse. In addition, we compared prolapse stages as assessed on dynamic MRI with a standardized method of clinical prolapse staging.

In **chapter 7** we assessed the feasibility of visualizing the normal pelvic floor support in nulliparous women using diffusion tensor imaging (DTI) at 3.0T MRI. In addition we established a range of anisotropic measures for clinically relevant anatomical structures in the pelvic floor. In the study described in **chapter 8**, we prospectively investigated the potential clinical application of DTI

## Chapter 1

---

and fiber tractography by comparing microstructure tissue parameters of the pelvic floor support of women with pelvic organ prolapse to women without pelvic organ prolapse and to asymptomatic nulliparous women. Also the inter-rater agreement was assessed.

**Chapter 9** contains the summary, conclusions and implications of this thesis. **Chapter 10** includes the Dutch translation of the summary, conclusions and implications.

## References

1. Weitz, J. et al. (2005) Colorectal cancer. *Lancet* 365, 153–165.
2. Bond JH. (2000) Clinical evidence for the adenoma-carcinoma sequence, and the management of patients with colorectal adenomas. *Semin Gastrointest Dis.*11(4):176-84.
3. Winawer SJ, Zauber AG, Ho MN et al. (1993) Prevention of colorectal cancer by colonoscopic polypectomy. The National Polyp Study Workgroup. *N Engl J Med.* 1993 Dec 30;329(27):1977-81.
4. Selby JV, Friedman GD, Quesenberry CP Jr, Weiss NS. (1992) A case-control study of screening sigmoidoscopy and mortality from colorectal cancer. *N Engl J Med.* 326(10):653-7.
5. Edwards BK, Ward E, Kohler BA et al. (2010) Annual report to the nation on the status of cancer, 1975-2006, featuring colorectal cancer trends and impact of interventions (risk factors, screening, and treatment) to reduce future rates. *Cancer.* 116(3):544-73.
6. Levin B, Lieberman DA, McFarland B et al. (2008) Screening and surveillance for the early detection of colorectal cancer and adenomatous polyps, 2008: a joint guideline from the American Cancer Society, the US Multi-Society Task Force on Colorectal Cancer, and the American College of Radiology. *CA Cancer J Clin.* 58(3):130-60
7. Mandel JS, Church TR, Bond JH et al. (2000) The effect of fecal occult-blood screening on the incidence of colorectal cancer. *N Engl J Med.* 343(22):1603-7.
8. Haug U, Hundt S, Brenner H. (2010) Quantitative immunochemical fecal occult blood testing for colorectal adenoma detection: evaluation in the target population of screening and comparison with qualitative tests. *Am J Gastroenterol.* 105(3):682-90.
9. Lieberman D (2009) Colon cancer screening and surveillance controversies. *Curr Opin Gastroenterol.* 25(5):422-7
10. Winawer SJ, Zauber AG, Fletcher RH et al. (2006) Guidelines for colonoscopy surveillance after polypectomy: a consensus update by the US Multi-Society Task Force on Colorectal Cancer and the American Cancer Society. *CA Cancer J Clin.* 56(3):143-59; quiz 184-5.
11. Atkin WS, Edwards R, Kralj-Hans I et al. (2010) Once-only flexible sigmoidoscopy screening in prevention of colorectal cancer: a multicentre randomised controlled trial. *Lancet.* 375(9726):1624-33.
12. Imperiale TF, Wagner DR, Lin CY, Larkin GN, Rogge JD, Ransohoff DF. (2000) Risk of advanced proximal neoplasms in asymptomatic adults according to the distal colorectal findings. *N Engl J Med.* 20;343(3):169-74..
13. Stoop EM, de Haan MC, de Wijkerslooth TR et al. (2011) Participation and yield of colonoscopy versus non-cathartic CT colonography in population-based screening for colorectal cancer: a randomised controlled trial. *The Lancet Oncology, Early Online Publication.*
14. de Haan MC, van Gelder RE, Graser A, Bipat S, Stoker J. (2011) Diagnostic value of CT-colonography as compared to colonoscopy in an asymptomatic screening population: a meta-analysis. *Eur Radiol.* 21(8):1747-63.

15. Halligan S, Altman DG, Taylor SA et al. (2005) CT colonography in the detection of colorectal polyps and cancer: systematic review, meta-analysis, and proposed minimum data set for study level reporting. *Radiology* 237:893-904.
16. Liedenbaum MH, Denters MJ, Zijta FM et al. (2011) Reducing the oral contrast dose in CT colonography: evaluation of faecal tagging quality and patient acceptance. *Clin Radiol.* 66(1):30-7.
17. Liedenbaum MH, Bipat S, Bossuyt PM et al. (2011) Evaluation of a standardized CT colonography training program for novice readers. *Radiology.* 258(2):477-87.
18. Liedenbaum MH, Venema HW, Stoker J. (2008) Radiation dose in CT colonography--trends in time and differences between daily practice and screening protocols. *Eur Radiol.* 18(10):2222-30.
19. Graser A, Wintersperger BJ, Suess C, Reiser MF, Becker CR. (2006) Dose reduction and image quality in MDCT colonography using tube current modulation. *AJR Am J Roentgenol.* 187(3):695-701.
20. Horsthuis K, Bipat S, Stokkers PC, Stoker J. (2009) Magnetic resonance imaging for evaluation of disease activity in Crohn's disease: a systematic review. *Eur Radiol.* 19(6):1450-60.
21. Beets-Tan RG, Beets GL. (2011) Local staging of rectal cancer: a review of imaging. *J Magn Reson Imaging.* 33(5):1012-9.
22. Lauenstein TC. (2006) MR colonography: current status. *Eur Radiol.* 16(7):1519-26.
23. Pickhardt PJ. (2010) Noninvasive radiologic imaging of the large intestine: a valuable complement to optical colonoscopy. *Curr Opin Gastroenterol.* 26(1):61-8.
24. Florie J, Jensch S, Nievelstein RA et al. (2007) MR colonography with limited bowel preparation compared with optical colonoscopy in patients at increased risk for colorectal cancer. *Radiology* 243(1):122-31.
25. Kinner S, Kuehle CA, Langhorst J et al. (2007) MR colonography vs. optical colonoscopy: comparison of patients' acceptance in a screening population. *Eur Radiol.* 17(9):2286-93.
26. Ajaj W, Lauenstein TC, Pelster G et al. (2004) MR colonography: how does air compare to water for colonic distention? *J Magn Reson Imaging.* 19(2):216-21.
27. Florie J, Birnie E, van Gelder RE et al. (2007) MR colonography with limited bowel preparation: patient acceptance compared with that of full-preparation colonoscopy. *Radiology* 245(1):150-9.
28. Stoker J, Wallner C. (2008) The anatomy of the pelvic floor and sphincters. In: Stoker J, Taylor S, De Lancey JOL (eds). *Imaging pelvic floor disorders.* Springer Verlag, New York. 1-29.
29. Umek WH, DeLancey JO. (2008) MRI of the levator ani muscle. In: Stoker J, Taylor S, DeLancey JO (eds). *Imaging pelvic floor disorders.* Springer Verlag, New York. 89-111.
30. DeLancey JO, Morgan DM, Fenner DE et al. (2007) Comparison of levator ani muscle defects and function in women with and without pelvic organ prolapse. *Obstet Gynecol.* 109:295-302.
31. Moore KL, Agur AMR. (2002) Pelvis and perineum. In: Moore KL, Agur AMR, eds. *Essential Clinical Anatomy.* 2nd ed. Philadelphia: Lippincott Williams & Wilkins. 209-73.

32. van der Vaart CH, de Leeuw JR, Roovers JP, Heintz AP. (2003) Measuring health-related quality of life in women with urogenital dysfunction: the urogenital distress inventory and incontinence impact questionnaire revisited. *Neurourol Urodyn.*22(2):97-104.
33. Jelovsek JE, Barber MD. (2006) Women seeking treatment for advanced pelvic organ prolapse have decreased body image and quality of life. *Am J Obstet Gynecol.* 194(5):1455-61.
34. Haylen BT, de Ridder D, Freeman RM et al. (2010) An International Urogynecological Association (IUGA)/International Continence Society (ICS) joint report on the terminology for female pelvic floor dysfunction. *Neurourol Urodyn.* 29(1):4-20.
35. Gutman RE, Ford DE, Quiroz LH, Shippey SH, Handa VL. (2008) Is there a pelvic organ prolapse threshold that predicts pelvic floor symptoms? *Am J Obstet Gynecol.*199(6):683.e1-7.
36. Delancey JO, Kane Low L, Miller JM, Patel DA, Tumbarello JA. (2008) Graphic integration of causal factors of pelvic floor disorders: an integrated life span model. *Am J Obstet Gynecol.*199(6):610.e1-5.
37. DeLancey JO. (2005) The hidden epidemic of pelvic floor dysfunction: achievable goals for improved prevention and treatment. *Am J Obstet Gynecol.*192(5):1488-95.
38. Bump RC, Mattiasson A, Bø K, et al. (1996) The standardization of terminology of female pelvic organ prolapse and pelvic floor dysfunction. *Am J Obstet Gynecol.* 175(1):10-7
39. Maher C, Baessler K, Glazener CM, Adams EJ, Hagen S. (2007) Surgical management of pelvic organ prolapse in women. *Cochrane Database Syst Rev.* Jul 18;(3):CD004014.
40. Boyadzhyan L, Raman SS, Raz S. (2008) Role of static and dynamic MR imaging in surgical pelvic floor dysfunction. *Radiographics* 28(4):949-967.
41. Macura KJ. (2006) Magnetic resonance imaging of pelvic floor defects in women. *Top Magn Reson Imaging.* 17(6):417-26.
42. El Sayed RF, El Mashed S, Farag A, Morsy MM, Abdel Azim MS. (2008) Pelvic floor dysfunction: assessment with combined analysis of static and dynamic MR imaging findings. *Radiology.*248(2):518-30.
43. Groenendijk AG, van der Hulst VP, Birnie E, Bonsel GJ. (2008) Correlation between posterior vaginal wall defects assessed by clinical examination and by defecography. *Int Urogynecol J Pelvic Floor Dysfunct.* 19(9):1291-7.
44. Dietz HP. (2011) Pelvic floor ultrasound in prolapse: what's in it for the surgeon? *Int Urogynecol J.* 22(10):1221-32.
45. Dobben AC, Terra MP, Slors JF, et al. (2007) External anal sphincter defects in patients with fecal incontinence: comparison of endoanal MR imaging and endoanal US. *Radiology* 242(2):463-471
46. DeLancey JO, Kearney R, Chou Q, Speights S, Binno S. (2003) The appearance of levator ani muscle abnormalities in magnetic resonance images after vaginal delivery. *Obstet Gynecol.* 101(1):46-53.
47. Fielding JR. (2002) Practical MR imaging of female pelvic floor weakness. *Radiographics.* 22(2):295-304.



## Chapter 1

---

48. Broekhuis SR, Fütterer JJ, Barentsz JO, Vierhout ME, Kluivers KB. (2009) A systematic review of clinical studies on dynamic magnetic resonance imaging of pelvic organ prolapse: the use of reference lines and anatomical landmarks. *Int Urogynecol J Pelvic Floor Dysfunct.* 20(6):721-9.
49. Miller JM, Brandon C, Jacobson JA et al. (2010) MRI findings in patients considered high risk for pelvic floor injury studied serially after vaginal childbirth. *AJR Am J Roentgenol.* 195(3):786-91.
50. Morgan DM, Umek W, Stein T, Hsu Y, Guire K, DeLancey JO. (2007) Interrater reliability of assessing levator ani muscle defects with magnetic resonance images. *Int Urogynecol J Pelvic Floor Dysfunct.* 18(7):773-8.
51. Hoyte L, Ye W, Brubaker L et al. (2011) Segmentations of MRI images of the female pelvic floor: a study of inter- and intra-reader reliability. *J Magn Reson Imaging.* 33(3):684-91.

# Part I

## MR colonography



# Chapter 2

## Colonography by Magnetic Resonance Imaging (MRI).

*Adapted from:*

MRI of the Colon (Colonography): Results.  
*Medical Radiology Diagn. Imaging. MRI of the Gastrointestinal Tract – J. Stoker (Ed). 185-204.*

*F.M. Zijta  
J. Stoker*

MRI of the colon.  
*Imaging in Medicine 2010;2,195-209.*

*M.P. van der Paardt  
F.M. Zijta  
J. Stoker*

### **MR colonography**

The second chapter of this thesis focuses on the evaluation of the colon using Magnetic Resonance (MR) imaging, which has been increasingly applied over the last decade. Recent advances in MR technology, particularly the advent of faster T1 pulse sequences, resulted in reduced physiological artefacts and consequently facilitated bowel imaging and assessment.

When applying colonic distension (i.e. MR colonography), MRI offers a method for colon imaging comparable to computed tomography (CT) colonography. MR colonography can be regarded as a minimally invasive tool for evaluating the entire colon, permitting multiplanar imaging and potentially enables three-dimensional (3D) rendering during post-processing. Additionally, it provides information of the extra colonic organs which are not perceptible during colonoscopy. Advantages of MR colonography over CT colonography is the lack of the use of ionizing radiation and the high inherent soft tissue contrast, which allows the use of a wide range of 'faecal tagging' regimes for bowel preparation. Whereas colonic distension in CT colonography typically entails the rectal administration of carbon dioxide or air, in MR colonography colonic distension is often acquired with the administration of a water-based enema and only few studies have reported on the usage of gaseous agents for colonic distension.

Since the introduction of MR colonography [1], research in this field is mainly focused to outline its role in the detection of colorectal masses and subsequently describe the future potentials of this modality in screening for colorectal carcinoma (CRC) as it has proved to be accurate in detecting clinical relevant precursors of CRC [2]. However, the clinical indications for performing MR colonography reach beyond and cover indications which are applied for both colonoscopy and CT colonography.

A variety of acquisition methods are described to perform MR colonography, but to date none of the different approaches have been shown to be superior. Regardless of the applied technique, prerequisite is a well distended colon which is either cleansed or homogeneously tagged, in order to permit an adequate assessment in a MR colonography setting.

### **When to perform MRI of the large bowel**

The indications for performing MRI of the colon merely cover the indications which are applied for colonoscopy and / or CT colonography and has been proposed in the diagnostic assessment of the colorectum of symptomatic patients for colorectal carcinoma (CRC), the colorectal assessment of asymptomatic

individuals who are at average or increased risk for CRC, clinical staging evaluation in patients with CRC, assessment of colorectal involvement in patients with recognized or suspected inflammatory bowel disease (IBD), the evaluation of patients with incomplete or failed colonoscopy and the evaluation of patients with suspected diverticular disease (DD).

### **Detection of precursors of colorectal cancer**

In many western countries, colorectal cancer (CRC) is currently one of the leading causes of cancer-related death in both men and women. If the disease is diagnosed at a low stage, the five-year survival is high. However the five-year survival rate drops to less than 10% if distant metastases are present [3]. Primary goals of colorectal cancer screening programs are to reduce both morbidity and mortality through reducing the incidence of the advanced staged disease and prevention of colorectal cancer by removal of benign precursors (adenomas) [4,5]. Histologically, colorectal polyps primarily can be divided into adenomatous and hyperplastic, in which adenomatous polyps comprise nearly two-third of all colorectal polyps. According to the adenoma-carcinoma sequence hypothesis, adenomatous polyps have the potential to progress to CRC.

The potential risk for developing CRC from colorectal adenomas is related to both size and histology. Colonography enables the detection and size estimation of colorectal polyps and can therefore trigger future polypectomy at colonoscopy. Importantly, no histological distinction can be applied using colonography and size remains the most important criterion to estimate the potential to evolve into malignancy. Therefore it is essential to define the potential CRC risk associated with each polyp size category before data on MR colonography polyp detection rates can be interpreted in their context.

Irrespective of histology, colorectal polyps can be stratified into three generally accepted size thresholds, reflecting the potential risk to contain or progress into cancer. Large polyps are defined as polyps with a size of 10 mm or larger ( $\geq 10\text{mm}$ ) and a recent study demonstrated advanced histology in 30.6% of all polyps  $\geq 10\text{mm}$ . Of the 13,992 asymptomatic patients who underwent colonoscopy malignancy was demonstrated in 2.6% of the large polyps ( $\geq 10\text{mm}$ ), 0.2% of the intermediate polyps (6-9mm), and the likelihood that polyps smaller than 5 mm ('diminutive' lesions) harboured malignancy was less than 0.1% [6].

A recently published simulation, which has inherent limitations, estimated the associated risk for a large colorectal adenomatous polyp ( $\geq 10\text{mm}$ ) to evolve

into CRC, as approximately 16% in ten years. The estimated risk potential for intermediate (6-9 mm) and diminutive lesions is substantially smaller (0.7 % and 0.08%, respectively) [7]. Histological features which have been associated with a higher risk for CRC include high-grade of dysplasia (HGD) and villous element [8]. Neoplasia can therefore be classified into 'advanced' (i.e. adenocarcinoma and advanced adenomas, the latter being all adenomas  $\geq 10$ mm, adenomas with HGD or containing villous element ( $>25\%$ )) and therefore clinically significant, or 'non advanced'.

General guidelines regarding relevance of lesion size for colonography are presented by the recently published consensus proposal for CT colonography. These recommendations propose that patients with polyps  $\geq 10$ mm as found with colonography, should be referred for polypectomy at colonoscopy. In addition, patients with intermediate polyps (6-9 mm) should either be referred for colonoscopy or undergo CT colonography on a custom basis [9]. Though, in daily practice frequently a more stringent approach is applied, resulting in the colonoscopy for any CT colonography with one of more polyps  $> 6$ mm. Small polyps ( $\leq 5$  mm) are considered clinically not important, because of their very low risk for development of CRC. Recommendations have been proposed concerning data reporting in colonography, which encompasses the presentation of outcomes regarding different polyp size categories and additional data for histological subset analyses [10].

### **Image interpretation**

Accurate colonic distension is the key element for adequate visualization of colorectal polyps and cancers. Inferior distension or segmental collapse will ultimately lead to false-positive and false-negative findings. This as the observer is not optimal able to detect lesions that may protrude into the colonic lumen, and otherwise a segment which is collapsed may simulate pathological bowel wall thickening. Similar to CT colonography, in MR colonography the post-procedural display techniques for detecting colorectal lesions distinguishes two reading techniques and is performed on a post processing workstation with dedicated software.

Firstly, two-dimensional data sets will be evaluated using a two-dimensional method, which facilitates the evaluation of both the colon and extra-colonic organs. Three-dimensional (3D) data sets can be evaluated two-dimensionally in each orthogonal anatomical plane (i.e. transverse, sagittal and coronal), using multiplanar reformation (MPR). If detected, colorectal lesions can



be described by the location and morphological features, also it can be measured and consequently be classified into one of the three predefined polyp categories [9]. Again, solitary colorectal polyps smaller than 6 mm can be ignored in this setting, as the likelihood for the presence of advanced neoplasia is extremely low [7].

Most MR colonography studies report the solitary use of MPR data set interpretation. An additional principle of data evaluation entails the application of virtual colonoscopy, in which the MR colonography dataset is used to construct a 3D rendering. However, current technical limitations hamper the application of this method in MR colonography, which is widely applied in CT colonography. Whereas in CT colonography this endoluminal view is typically based on data thresholding, high variation in signal value precludes such a straightforward approach for MRI data. These fluctuations in MRI signal might originate both from global (e.g. distance to the antenna) as well as from local effects (inhomogeneities in bowel content), and are difficult to overcome. Nonetheless, several authors report on the use of a local 3D surface rendering during review and might be used for problem solving [11, 12].

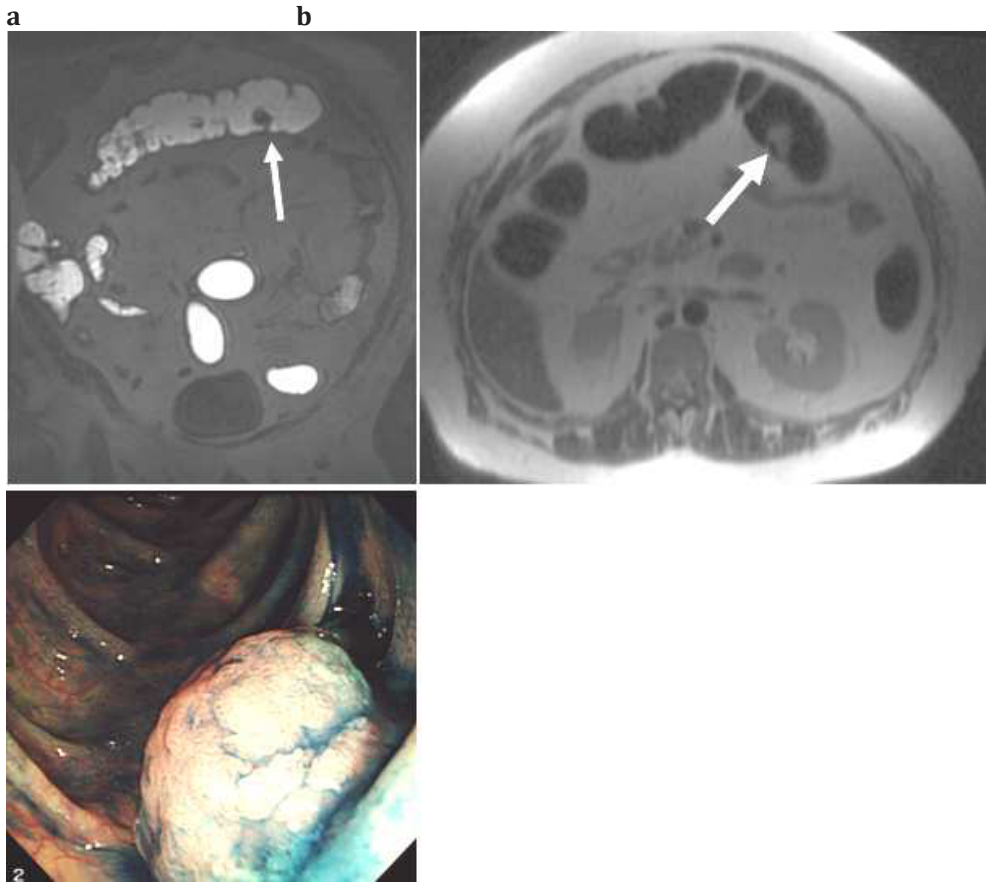
### **MR-colonography techniques in relation to prevalence**

As in CT-colonography, different groups with a different prevalence of disease can be identified: (1) asymptomatic subjects at increased risk for CRC (e.g. family history of familial adenomatous polyposis (FAP), first degree relative with CRC, personal and/or family history of colorectal cancer or polyps, inflammatory bowel disease (IBD)) and (2) asymptomatic subject at average risk for CRC (age >50yrs). The first group is considered as individuals with a high prevalence of disease and the latter is considered a screening population with a relatively low prevalence of disease. The results of MR-colonography will be described taking these different groups with different disease prevalence and disease spectrum into account.

### **High prevalence population**

#### *Bright lumen strategy*

In de late 1990's and early 2000's several investigators identified MR colonography as a potential diagnostic method for the detection of colorectal polyps and cancer in symptomatic patients and patients at increased risk for CRC [13, 14]. Initial research was performed with the use of bright lumen MR colonography in which the colonic lumen appears hyper intense on T1w sequences by the rectal administration of a gadolinium based enema (*Figure 1*).



**Figure 1.** (a) T1 w three-dimensional (3D) coronal Fast Field Echo (FFE) image of a 56 year old patient with suspicion of a hyperplastic polyposis syndrome. MR colonography visualized a hypo-intense lesion which protrudes into the ‘bright’ colonic lumen (arrow), in the distal part of the transverse colon. Suspicious of a pedunculated polyp. (b) The presence of a lesion is also confirmed at an axial T2 w two-dimensional (2D) Fast Spin Echo (FSE) image, with relative high signal intensity on this sequence (arrow). (c) The presence of a 15 mm pedunculated polyp was confirmed at colonoscopy. Histology analysis confirmed the diagnosis of a hyperplastic polyp. (Adapted from Zijta FM, Stoker J. *MRI of the Colon (Colonography): Results. Medical Radiology Diagn. Imaging. MRI of the Gastrointestinal Tract – J. Stoker (Ed). 185-204. With kind permission of Springer Science + Business Media*)

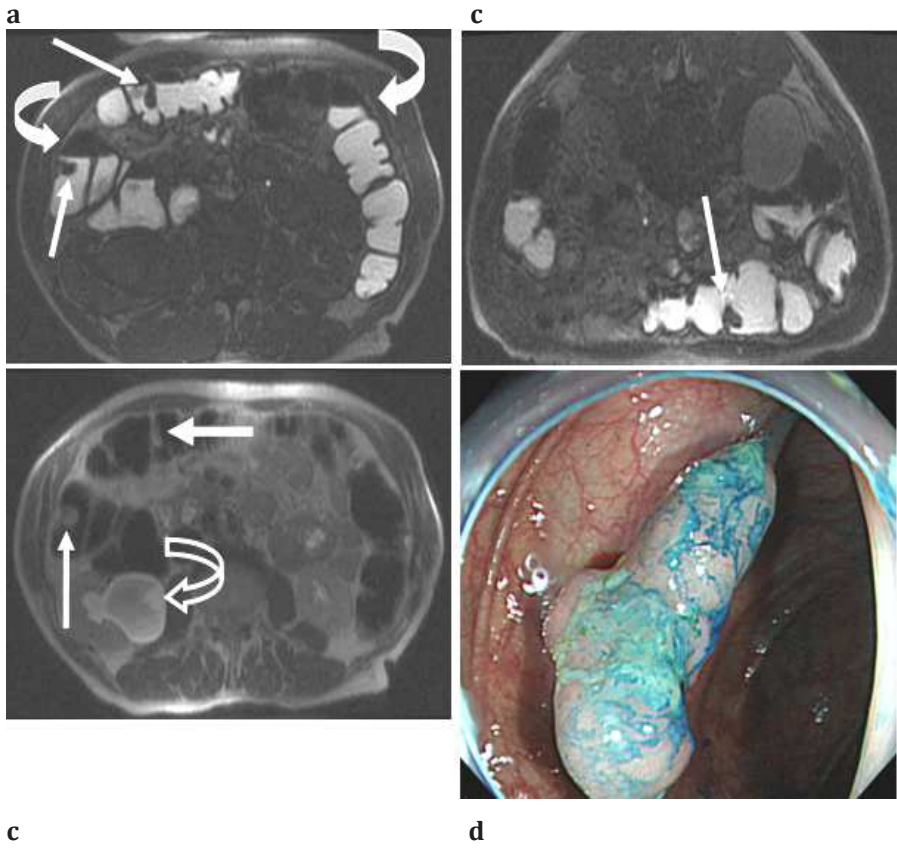
Among the first prospective studies using bright lumen MR colonography was a paper by Luboldt et al., who reported a high sensitivity (93%) and a high specificity (99%) for detecting patients with large colorectal lesions. 1.5T MR

colonography was compared with colonoscopy in 117 symptomatic patients referred for colonoscopy, using a rectal enema which contained 3L of water and 60mL of 0.5 mol/L Magnevist (gadopentetate dimeglumine). However a moderate sensitivity was demonstrated (75%) when a cut-off value of 7 mm was applied [13]. Pappalardo and colleagues studied 70 patients at increased risk for CRC, who underwent 1.0T MR colonography using a comparable bright lumen approach. High diagnostic outcomes were found (sensitivity 96% and specificity 93%) for detecting patients with polyps of all sizes [15]. In this study 125 endoluminal lesions were found in 54 patients of which 94 lesions were larger than 10 mm in size.

These results demonstrated the ability of MR colonography to detect colorectal lesions exceeding the size of 10 mm with acceptable diagnostic accuracy. This encouraged study groups to investigate MR colonography as alternative diagnostic tool in this field, particularly the value of this modality in detecting intermediate polyps (6-9 mm).

While earlier studies typically used the bright lumen variant with promising outcomes, currently the dark lumen method is mostly applied. This change in acquisition method however was more based on practical reasons (costs of contrast agent) than on extensive series. Some research was performed on different type of MR colonography regimes by Florie et al., who studied diagnostic yield for the bright lumen strategy [16]. In this study, three different MR colonography strategies, which consisted of two dark lumen (*water-based and air-based colonic distension*) and one bright lumen strategy with faecal tagging strategy as bowel preparation, were compared. Forty-five subjects at increased risk for CRC were subjected to both MR colonography and colonoscopy. While the diagnostic confidence of both the bright lumen and dark lumen strategy using air for colonic distension was rated best by two independent observers, patient acceptance in the bright lumen method proved less burdensome as compared to the other two dark lumen strategies. The latter was mainly due to the better tolerance of the bowel preparation method.

In a further prospective study in 200 patients at increased risk for CRC bright lumen MR colonography using gadolinium/water mixture for colonic distension was compared to findings with colonoscopy [17]. Results in this study showed only moderate sensitivity in detecting patients with polyps  $\geq 10$  mm (75%). Specificity for these clinical significant polyps was 93%, however a high number of false positive findings reduced specificity for polyps  $\geq 6$  mm to 67%. The latter was mostly related to both air pockets and motion artefacts. This study



**Figure 2 . (a)** Supine T1w 3D axial FFE image of an 84-year old male with multiple polyps in the right colon. ‘Bright lumen’ MR colonography visualizes a lesion in the transverse colon (arrow) and a lesion in the proximal aspect of the ascending colon (arrow). Several air collections are visible, potentially leading to false negative findings in this position (curved arrows). **(b)** The presence of the polyps is also visualized on the corresponding axial T2w 2D FSE image in supine position, which shows relative high signal on this sequence (arrows). Hydronephrosis of the right kidney (curved open arrow). **(c)** Corresponding prone T1w 3D axial FFE image shows the somewhat elongated polyp on the anterior aspect of the transverse colon **(d)** Colonoscopy confirmed the presence of a pedunculated 10 mm polyp in the proximal aspect of the transverse colon. The presence of a polyp in the ascending colon was confirmed at colonoscopy (not shown). ( Adapted from Zijta FM, Stoker J. *MRI of the Colon (Colonography): Results. Medical Radiology Diagn. Imaging. MRI of the Gastrointestinal Tract – J. Stoker (Ed). 185-204. With kind permission of Springer Science + Business Media*)

was performed in primarily high-risk patients for CRC who took part in a surveillance program. Interestingly the prevalence of patients with polyps larger

than 10 mm in this cohort who underwent colonoscopy surveillance was only 6%, which might have influenced test outcome.

Another prospective study, conducted in 120 symptomatic patients and patients at increased risk, using the 'bright lumen' approach with standard bowel preparation, showed adequate detection rates for patients with present polyps or lesions with any size. Forty-seven of 56 patients with colonoscopically confirmed colorectal lesions, were correctly identified to have lesions using bright lumen MR colonography, and 94% of lesions  $\geq 10$  mm were depicted [18]. Additionally, MR colonography was able to detect all seven colorectal carcinomas.

Limitations in these studies concern the technical ability of the used technique to correctly identify flat polyps / adenomas and small polyps which is also frequently reported in CT colonography in surveillance populations [19, 20]. But more importantly, small air pockets and non-tagged faecal residue are reported as a constant source of false positive findings in recent bright lumen MR colonography studies (*Figure 2*).

### *Dark lumen strategy*

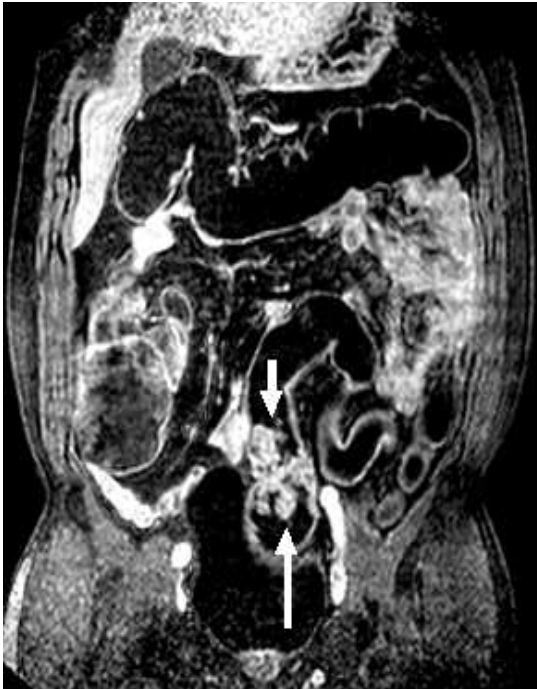The first published article on the use of dark lumen MR colonography appeared in 2001 and suggested promising results regarding diagnostic accuracy, acquisition time and review time. Initially following a standard preparation for bowel cleansing, a water enema was used which consisted of the rectal administration of 3000mL of warm tap water followed by a pre- and post-(IV) contrast T1w three-dimensional gradient echo data acquisition [21]. The use of water results in a homogeneously low signal throughout the colonic lumen at T1w sequences and allows depiction of enhancing abnormalities originating from the colonic wall after the intravenous administration of contrast agent (*Figure 3 - 5*).

As the increase in signal-to-noise ratio (SNR) is significant between pre- and post contrast series, this technique will in theory lead to better diagnostic accuracy. Interestingly, three of twelve patients included in this study underwent additional bright lumen MR colonography in a further session, which in turn resulted in two false-positive findings in one patient. In contrast, in dark lumen MR imaging no false-negative findings were reported.

Studies specifically evaluating the value of dark lumen MR colonography, using standardized bowel cleansing and water-based enema for colonic bowel distension, have been conducted. In one study, 122 subjects underwent MR colonography prior to colonoscopy. Adequate colonic distension and the absence of significant disturbing artefacts resulted in a high diagnostic confidence in

practically all acquired examinations. All nine carcinomas, and 89% (16/18) of all intermediate polyps (5-10 mm) and 100% (2/2) of polyps  $\geq 10$  mm at colonoscopy were detected with MR colonography performed in prone position [22].

A more recent prospective study by Hartmann et al. found comparable results for the detection of intermediate, large adenomatous polyps and colorectal carcinomas (84%, 100% and 100%, respectively). Ninety-two patients underwent both dark lumen colonography and colonoscopy, using standard bowel preparation and colonic distension method [23]. Yet, these studies have reported on populations which are characterized with a relatively high prevalence of colorectal polyps and malignancy and the results therefore apply to these populations only. Clinical application of this technique is far from established and prospective studies with predefined end points are necessary to validate its use.



**Figure 3.** Dark lumen MR colonography using 3DT1 turbo field echo (TFE) sequence with additional fat saturation.

Sequential parameters: TR/TE=4.6/2.2 ms; FOV=420mm; FA = 10; slice thickness = 3mm. **(a)** 60 year old male patient who presented with weight loss and rectal bleeding. MR colonography visualized the presence of a 5-6 cm large intraluminal, enhancing tumor just above the recto-sigmoid junction (arrows). (Adapted from Zijta FM, Stoker J. *MRI of the Colon (Colonography): Results. Medical Radiology Diagn. Imaging. MRI of the Gastrointestinal Tract* – J. Stoker (Ed). 185-204. With kind permission of Springer Science + Business Media)

So far only few studies focused on the use of gaseous agents for colonic distension, which subsequently results in a dark appearing colonic lumen at both T1w and T2w sequences. For this purpose both room air and carbon dioxide (CO<sub>2</sub>) are applicable agents (Figure 6). If comparing these two entities, diffusion through



the bowel wall favours the application of CO<sub>2</sub> as this ultimately leads to better patient acceptance [24]. Overall, the use gas insufflation is considered less burdensome , if compared to a water-enema. Also, gas distension is thought to allow better colonic distension, but this assumption has not been established in MR colonography [25, 26].

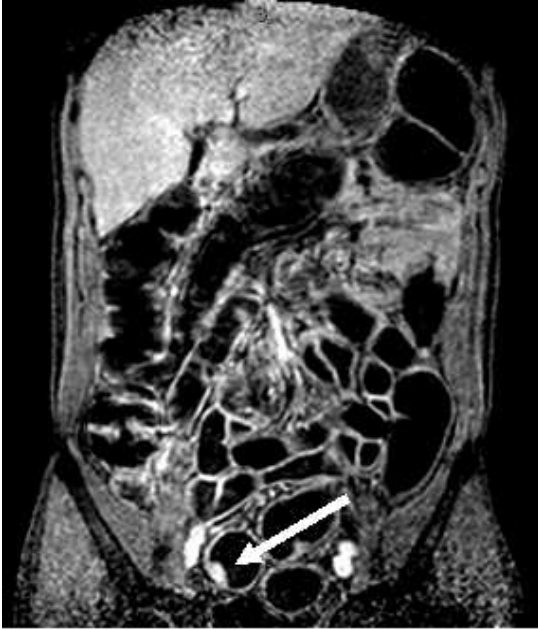In a study of 156 patients at average and increased risk of CRC, MR colonography correctly depicted only four out of 31 colorectal polyps of any size which resulted in poor overall diagnostic outcomes. In this study room air was manually inflated for luminal distension and was compared with colonoscopy findings. Factors which negatively affected MR colonography performance included physiological artefacts, moderate colonic distension and the presence of faecal residue [27]. Whereas carbon dioxide (CO<sub>2</sub>) for colonic distension is now standard in CT colonography [28], in MR colonography it has been reported in a series of six patients with known colorectal cancer [29]. Although the included population in this study was small, the results are encouraging on applied T2w sequences.

### *Faecal tagging*

As previously outlined, one of the key elements for performing MR colonography is an optimal differentiation between bowel wall and lumen. In order to correctly identify colonic wall-related pathology, adequate cleansing or homogenous tagging of residual faeces of the bowel is essential. In most earlier studies a standardized polyethylene glycol electrolyte lavage solution was orally administered for proper cleansing, which goes together with abdominal discomfort and nausea and eventually leads to limited patient acceptance and compliance.

Faecal tagging refers to the labelling of the faecal residue and is similar to the method as applied in CT colonography. The administration of an oral tagging agent results in either low or high signal intensity of the bowel in MR colonography allowing an improved differentiation between bowel wall and bowel content and ultimately results in less false-positive findings. Importantly, this enables the use of a limited bowel preparation regime and thus obviates cathartic preparation [11, 30]. Faecal tagging can be applied in bright-lumen and dark-lumen techniques and has been evaluated both on diagnostic outcomes and patient acceptance, in MR colonography literature.





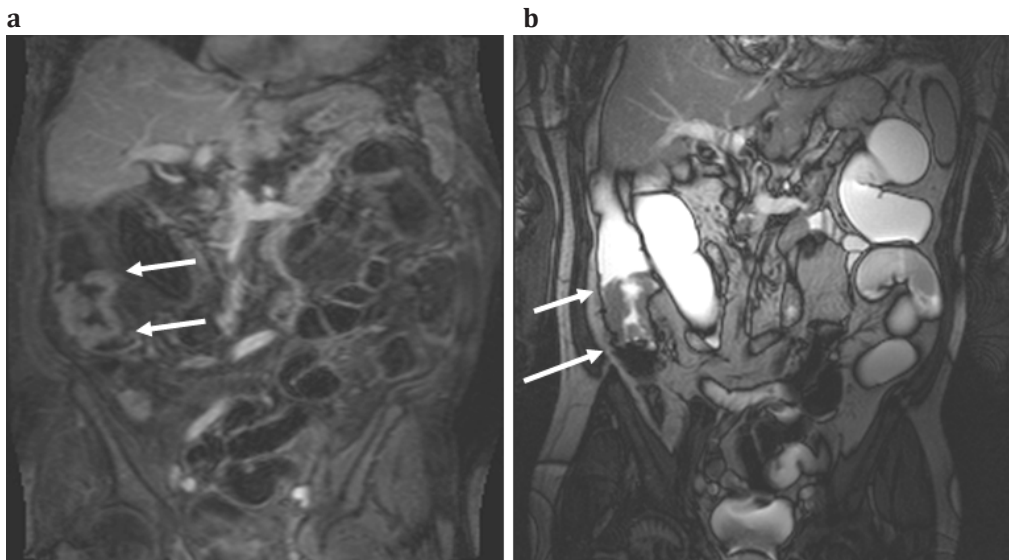
**Figure 4.** 58 Year old male who presented with fatigue and changed bowel habits. Dark lumen MR colonography visualized an enhancing lesion in the sigmoid colon (arrow). The presence of a 12 mm polyp was confirmed at colonoscopy. *Adapted from Zijta FM, Stoker J. MRI of the Colon (Colonography): Results. Medical Radiology (Colonography): Results. Medical Radiology Diagn. Imaging. MRI of the Gastrointestinal Tract – J. Stoker (Ed). 185-204. With kind permission of Springer Science + Business Media)*

Lauenstein et al. proposed a concentrated barium sulphate contrast agent for faecal tagging, which resulted in a homogeneously low signal intensity of the colonic lumen, and additionally high contrast-to-noise ratios were measured following to the intravenous administration of T1-shortening paramagnetic contrast agent. Twenty-four symptomatic patients were included in this prospective study, presenting with only mild symptoms. MR colonography demonstrated a high sensitivity (91%) for detecting patients with any sized colorectal lesions and the absence of false-positive findings resulted in an excellent specificity. Though these study results were substantially biased by the high prevalence of large abnormalities as >90% of the colorectal lesions consisted of polyps >8 mm and carcinomas [11].

Initial optimism regarding the barium-based faecal tagging approach was tempered by a study reported by Goehde et al.. In this study, inclusion of patients was stopped owing to inferior MR performance. The diagnostic performance was mainly affected by the high signal intensity of faecal residue throughout the colon on the T1w sequences, which hampered reliable polyp detection in 1 out of every 5 included patients. This is reflected in the low sensitivity of lesions >10mm (50%) [31].

Adjusting the barium-based faecal tagging protocol thereby reducing the amount of barium sulphate and add ferumoxsil (GastroMark®, Lumirem®), has been

reported to improve patient acceptance. This preparation technique was compared with colonoscopy in 56 patients. For intermediate and large polyps MR colonography had a sensitivity of 86% and 81%, respectively. The results improved if these were calculated on a per-patient bases, resulting in a high sensitivity (100%) and specificity (91.4%) for depicting patients with polyps  $\geq 10$  mm [32]. In summary, diagnostic outcomes in studies using barium sulphate-based faecal tagging method vary considerably and are therefore difficult to interpret. This emphasizes the necessity to further investigate and optimize this approach.



**Figure 5.** MR colonography in a patient with incomplete endoscopy due to an elongated colon. **(a)** Coronal 3DT1 w sequence with additional fat saturation after administration of intravenous contrast agent. A circumferential enhancing tumor was found in the proximal part of the ascending colon (arrows). **(b)** True FISP sequence of the same patient, showing a bright lumen appearance with evident filling defect on the level of the tumor.

(Adapted from Zijta FM, Stoker J. *MRI of the Colon (Colonography): Results. Medical Radiology Diagn. Imaging. MRI of the Gastrointestinal Tract – J. Stoker (Ed). 185-204. With kind permission of Springer Science + Business Media*)

## Low prevalence population

### Screening MR colonography

Whereas most investigators evaluated MR colonography in relatively high prevalence populations, to date one study solely has evaluated MR colonography

in a screening population. In this single centre prospective study, dark lumen MR colonography without bowel cleansing was compared to colonoscopy in an asymptomatic average risk population of 315 subjects [12]. The overall prevalence of patients with polyps  $\geq 10$  mm within this population was 6.3 percent (20 / 315). In this study faecal tagging was applied using a modified barium-based solution (5% Gastrografin / 1% barium / 0.2% locust bean gum). Sensitivity for the detection of patients with polyps  $\geq 10$  mm and patients with intermediate polyps (5-10 mm) was 70% and 60%, respectively. The sensitivity of MR colonography for the detection of patients with adenomatous polyps at least 10 mm in diameter was 87% and 81% for patients with intermediate polyps. Specificity for polyps  $\geq 10$  mm and polyps 5-10 mm was 100% and 98%, respectively. Recently published data of a multicenter CT colonography screening study [33], reported a comparable sensitivity in identifying asymptomatic patients with adenomas with a size of 10 mm or more, and 6 mm in size or more (90% and 78%, respectively).

Evidence on MR colonography in screening is very limited, and only concerns the aforementioned single centre study. Current limited evidence, the lack of an established technique, the costs and rather limited access make MR colonography at the moment of writing less suited for screening. Still the use of non-ionizing radiation and the wide range of possible limited bowel preparation schemes make MR colonography a potential diagnostic alternative to CT colonography.

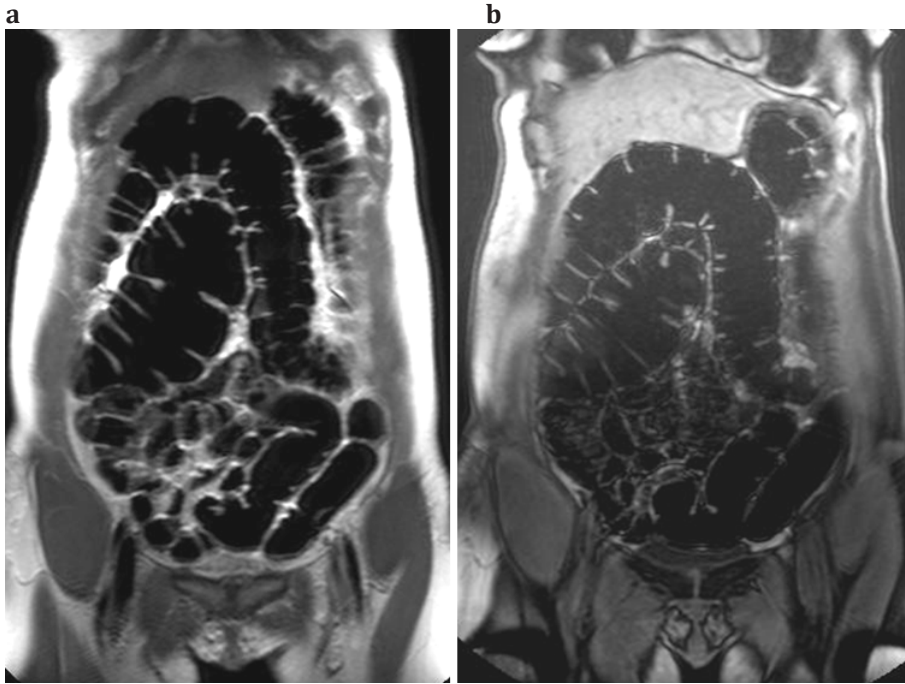
### **Patient acceptance in MR colonography**

Several investigators have focused on the degree of comfort, acceptance and future preferences of MR colonography, if compared to conventional colonoscopy. Here we focus on two aspects of the examination, namely patient acceptance regarding bowel preparation and colonic distension.

#### *Bowel Preparation*

As previously outlined, prerequisite for a high quality MR colonography is a clean or homogeneously tagged colon. This as residual faeces can both conceal and simulate bowel wall pathology, which potentially leads to false-negative and false-positive findings. In the earlier studies patient preparation for MR colonography was similar to the bowel preparation as applied for conventional colonoscopy. This ultimately could influence future preferences for this modality, since bowel purgation is rated as one of the most unpleasant parts during conventional

colonoscopy. With the introduction of faecal tagging in MR colonography a method was described which obviated the application of a complete bowel cleansing approach.



**Figure 6.** MR colonography after the automatic insufflation of carbon-dioxide ( $\text{CO}_2$ ) in a normal volunteer, results in an optimal distension in all colonic segments. The lumen shows a low signal on both T2w (**a**) and T1w (**b**) images, without the presence of disturbing artefacts. This method allows adequate differentiation between the colonic lumen and colonic wall, even without the administration of an intravenous paramagnetic contrast agent (**b**). (*Adapted from Zijta FM, Stoker J. MRI of the Colon (Colonography): Results. Medical Radiology Diagn. Imaging. MRI of the Gastrointestinal Tract – J. Stoker (Ed). 185-204. With kind permission of Springer Science + Business Media*)

Since 1999 several faecal tagging strategies have been evaluated, for both bright lumen and dark lumen approach [14, 30]. Initial approach in dark lumen MR colonography, as reported by Lauenstein et al, was the oral administration of 200mL barium-based contrast agent with each meal, starting 36 hrs for the examination and proved feasible. In this study patient acceptance was thought to improve, however this was not thoroughly investigated [14]. From the same research group, Goehde et al. used a comparable bowel preparation strategy,

which consisted of the administration of 150mL barium-sulphate in six consecutive oral intakes. Opposite conclusions were drawn from this study as this technical approach resulted in only moderate diagnostic accuracy, poor image quality in approximately 20% of the MR examinations, and moreover the total MR colonography examination was graded more uncomfortable than conventional colonoscopy. The barium intake was graded as most disturbing factor [31]. The taste of barium sulphate is generally considered unpleasant, and especially the viscous texture might lead to some degree of discomfort. Adjustments in this barium-sulphate regime have been reported. Adding ferumoxsil (GastroMark®, Lumirem®) and reducing the amount of barium sulphate results in improved patient acceptance of the bowel preparation [34].

A modified barium based faecal-tagging protocol - consisting of 5% Gastrografine, 1% barium and 0.2% locust bean gum - has been described by a research group in two different studies. In 29 patients with IBD, this faecal tagging preparation was rated significantly less bothersome than bowel purgation [35]. However, overall patient acceptance based on preparation protocol and examination procedures was in favour of colonoscopy. Patient acceptance of MR colonography in a screening population was reported for a series of 248 patients using the modified barium faecal tagging regime with colonoscopy as the reference standard [36]. Important conclusions in this study entailed the comparable patient acceptance of MR colonography and colonoscopy and the comparable future patient preferences for MR colonography and colonoscopy. A better patient acceptance than colonoscopy would be a major factor favouring MR colonography for screening. Given the wide range of possible limited bowel strategies for MR colonography, efforts should be made to study regimes with a lower burden to be applied for screening.

A prospective study was performed comparing three different faecal tagging strategies with respect to image quality and patient acceptance in a series of 45 patients at increased risk (surveillance)[16]. The study was executed using two dark lumen approaches with barium-based (3 x 200mL) faecal tagging strategy and one bright lumen approach with gadolinium (3 x 10mL) as oral tagging agent, in combination with a low-fibre diet. The bright lumen strategy resulted in better outcomes regarding the diagnostic confidence and acceptance of bowel preparation and therefore this protocol was used in the following study in which MR colonography was preferred above conventional colonoscopy [37]. Experience from 209 patients regarding bowel preparation and the overall

procedure were rated better directly after finishing the examinations, and five weeks after both examinations.

### **Colonic Distension**

Another important aspect which influence patient acceptance is the colonic distension method. A frequently used method for colonic distension is the administration of a water-based enema, which mostly consists of warm tap-water (*dark lumen*) or gadolinium/water mixture (*bright lumen*). However, enemas are relative uncomfortable. Insufflation of gas for colonic distension most likely leads to less patient burden, as is common practice in CT colonography. Initial studies did not use gaseous distending agents because of substantial susceptibility artefacts at gas soft tissue interfaces and motion artefacts. Improved techniques with data acquisition with short echo times has enabled the performance of MR colonography without important susceptibility artefacts and/ or motion artefacts. Considering these factors, gaseous based distension methods are evaluated in order to improve image quality and patient acceptance in MR colonography.

In a single prospective experience in 165 individuals at both high risk and average risk for CRC, no significant differences in discomfort was found between MR colonography using air for colonic distension and colonoscopy with identical bowel preparation [38]. Yet a significant proportion of the individuals preferred colonoscopy to MR colonography. The authors suggest that this finding might be related to the fact that all individuals received sedation during colonoscopy and the examination time was shorter for colonoscopy.

Other authors used air-based MR colonography to compare feasibility and patients acceptance with both water-based colonic distension and colonoscopy in a randomized study, studying 50 patients at high risk for CRC with similar bowel preparation technique [25]. Water-based and air-based colonic distension were rated comparable, regarding the degree of discomfort. This is rather in contrast with studies evaluating patient acceptance in CT colonography and double-contrast barium enema [39], as resulted a better tolerance of air based colonic distension.

Another feasible way to improve patient acceptance might be a combined faecal tagging strategy and air-based colonic distension. However comparable patient acceptance with the water-based alternative and significant better examination tolerance compared to colonoscopy, was combined with inferior image quality of air-based MR colonography [26].



Considering patient acceptance, the potential better tolerance of using gas for colonic distension instead of a water based enema has not been evidently demonstrated in MR colonography literature. Moreover so far there is no available evidence on the patient acceptance of carbon-dioxide in MR colonography, the colonic distension method frequently applied in CT colonography.

### **3.0T MR colonography**

During the last decade, high-field imaging has become increasingly studied and the application is widely implemented [40]. In 3.0T MR imaging, the high-field strength permits an increase in spatial resolution and/or a decrease in acquisition time [41, 42] and this might improve image quality considerably. However straight adoption of sequences used at 1.5T is not feasible. At high-field strength tissue T1 and T2 relaxation parameters are different than at 1.5T, as well as specific absorption rate (SAR) and changes in chemical shift - and susceptibility effects [41, 43] which are especially perceptible at soft tissue-air interfaces (e.g. residual gas in the colonic lumen [42]). Magnetic susceptibility artefacts are more prominent at 3.0T if compared to low-field strength MRI and might therefore potentially disadvantage the use of air-based distension in 3.0T MR colonography.

Although high-field imaging is promising, there is limited evidence concerning the role of 3.0T MRI in MR colonography [41]. Saar and colleagues, proved feasibility of 3.0T MR colonography in 34 symptomatic patients, demonstrating good diagnostic quality and high overall diagnostic accuracy ( per-patient sensitivity and specificity was 83% and 100%, respectively) [44]. A study in 40 patients demonstrated no significant difference in image quality at 3.0T compared to 1.5T in two sequences (T1w fat-suppressed GRE and T2w single-shot fast spin-echo) [45] and in a phantom study no significant difference in detection of polyps larger than 6 mm at 1.5T and 3.0T were demonstrated [46].

### **Extracolonic findings**

In contrast to colonoscopy, MRI also provides information of the extra colonic organs. Reported data on extracolonic findings in MR colonography are limited [47, 48]. Recently, Yusuf et al. [47] reported on the prevalence of extra-colonic findings in 210 patients at increased risk for CRC who underwent bright lumen MR colonography. The study demonstrated a wide range of extra-colonic findings in 125 (59.5%) patients (e.g. lymphadenopathy, aortic aneurysm, gallbladder stones, hepatic and renal cysts ). Ten (4.8%) findings were clinically significant (as



scored according to the CRADS Reporting System [9]) of which two revealed to be malignant (1.0%) [47]. It was concluded that in MR colonography extra-colonic findings are common, but the majority are of low clinical significance. Ajaj et al. [48] demonstrated extracolonic findings in 69% of 375 subjects who underwent dark lumen MR colonography for suspected colonic disease of which 27 subjects were subjected to an additional examination which confirmed the MRI findings. They concluded that dark lumen MR colonography has a high accuracy for the assessment of extracolonic findings [48].

### **MR colonography perspectives**

MR imaging of the colon can be applied for a wide spectrum of indications. The current available evidence however is rather limited, and therefore its role for detecting different types of colonic disorders is far from established. Whereas additional administration of a rectal enema seems legitimated for improving detection of colorectal polyps, the beneficial effect for other indications, in particular inflammatory bowel disease, remains unclear.

To date most of the MR colonography research is aimed at the detection of (precursors of) CRC. Although no consensus has been reached regarding important elements of the exam, current evidence suggests sufficient accuracy in detecting significant large polyps. Yet at this point we are far from the implementation of an established diagnostic tool, such as presently observed in CT colonography for screening.

### References

1. Luboldt W, Bauerfeind P, Steiner P et al. (1997) Preliminary assessment of three-dimensional magnetic resonance imaging for various colonic disorders. *Lancet* 349(9061):1288-91
2. Zijta FM, Bipat S, Stoker J. (2010) Magnetic Resonance (MR) Colonography in the Detection of Colorectal Lesions: a Systematic Review of Prospective Studies. *Eur Radiol.* 20:1031-46.
3. O'Connell JB, Maggard MA, Ko CY et al. (2004) Colon cancer survival rates with the new American Joint Committee on Cancer sixth edition staging. *J Natl Cancer Inst.* 96(19):1420-5
4. Levin B, Lieberman DA, McFarland B et al. (2008) Screening and surveillance for the early detection of colorectal cancer and adenomatous polyps, 2008: a joint guideline from the American Cancer Society, the US Multi-Society Task Force on Colorectal Cancer, and the American College of Radiology. *CA Cancer J Clin.* 58(3):130-60
5. Atkin WS, Edwards R, Kralj-Hans I et al. (2010) Once-only flexible sigmoidoscopy screening in prevention of colorectal cancer: a multicentre randomised controlled trial. *Lancet.* 375(9726):1624-33.
6. Lieberman D, Moravec M, Holub J et al. (2008) Polyp size and advanced histology in patients undergoing colonoscopy screening: implications for CT colonography. *Gastroenterology* 135(4):1100-5
7. Pickhardt PJ, Hassan C, Laghi A, et al. (2008) Small and diminutive polyps detected at screening CT colonography: a decision analysis for referral to colonoscopy. *AJR Am J Roentgenol* 190:136-144
8. Winawer SJ, Zauber AG (2002) The advanced adenoma as the primary target of screening. *Gastrointest Endosc Clin N Am.* 12(1):1-9
9. Zalis ME, Barish MA, Choi JR et al. (2005) CT colonography reporting and data system: a consensus proposal. *Radiology* 236(1):3-9
10. Halligan S, Altman DG, Taylor SA, et al. (2005) CT colonography in the detection of colorectal polyps and cancer: systematic review, meta-analysis, and proposed minimum data set for study level reporting. *Radiology* 237(3):893-904.
11. Lauenstein TC, Goehde SC, Ruehm SG et al. (2002) MR colonography with barium-based fecal tagging: initial clinical experience. *Radiology* 223(1):248-54
12. Kuehle CA, Langhorst J, Ladd SC, et al. (2007) Magnetic resonance colonography without bowel cleansing: a prospective cross sectional study in a screening population. *Gut* 56(8):1079- 85
13. Luboldt W, Bauerfeind P, Wildermuth S et al. (2000) Colonic masses: detection with MR colonography. *Radiology* 216(2):383-8
14. Lauenstein TC, Holtmann G, Schoenfelder D et al. (2001) MR colonography without colonic cleansing: a new strategy to improve patient acceptance. *AJR Ame. Journal Roentgenol.* 177:823-827
15. Pappalardo G, Poletti E, Frattaroli FM et al. (2000) Magnetic resonance colonography versus conventional colonoscopy for the detection of colonic endoluminal lesions. *Gastroenterology* 119(2):300-4
16. Florie J, van Gelder RE, Haberkorn B et al. (2007) Magnetic resonance colonography with limited bowel preparation: a comparison of three strategies. *J Magn Reson Imaging* 25(4): 766-74

17. Florie J, Jensch S, Nievelstein RA et al. (2007) MR colonography with limited bowel preparation compared with optical colonoscopy in patients at increased risk for colorectal cancer. *Radiology* 243(1):122-31
18. Saar B, Meining A, Beer A, et al. (2007) Prospective study on bright lumen magnetic resonance colonography in comparison with conventional colonoscopy. *Br J Radiol.* 80(952):235-41
19. Van Gelder RE, Nio CY, Florie J et al. (2004) Computed tomographic colonography compared with colonoscopy in patients at increased risk for colorectal cancer. *Gastroenterology.* 2004 Jul;127(1):41-8
20. Jensch S, de Vries AH, Peringa J et al. (2008) CT colonography with limited bowel preparation: performance characteristics in an increased-risk population. *Radiology.* 2008 Apr;247(1):122-32
21. Lauenstein TC, Herborn CU, Vogt FM et al. (2001) Dark lumen MR colonography: initial experience. *Rofo* 173(9):785-9
22. Ajaj W, Pelster G, Treichel U et al. (2003) Dark lumen magnetic resonance colonography: comparison with conventional colonoscopy for the detection of colorectal pathology. *Gut* 52(12):1738-43
23. Hartmann D, Bassler B, Schilling D et al. (2006) Colorectal polyps: detection with dark-lumen MR colonography versus conventional colonoscopy. *Radiology* 238(1):143-149
24. Sumanac K, Zealley I, Fox BM et al. (2002) Minimizing postcolonoscopy abdominal pain by using CO<sub>2</sub> insufflation: a prospective, randomized, double blind, controlled trial evaluating a new commercially available CO<sub>2</sub> delivery system. *Gastrointest Endosc.* 56(2):190-4
25. Ajaj W, Lauenstein TC, Pelster G et al. (2004) MR colonography: how does air compare to water for colonic distention? *J Magn Reson Imaging.* 19(2):216-21
26. Rodriguez Gomez S, Pagés Llinas M, Castells Garangou A et al. (2008) Air-lumen MR colonography with fecal tagging: a comparison of water enema and air methods of colonic distension for detecting colonic neoplasms. *Eur Radiol.* 18(7):1396-405
27. Lam WW, Leung WK, Wu JK et al. (2004) Screening of colonic tumors by air-inflated magnetic resonance (MR) colonography. *J Magn Reson Imaging.* 19(4):447-52
28. Taylor SA, Laghi A, Lefere P, et al. (2007) European Society of Gastrointestinal and Abdominal Radiology (ESGAR): consensus statement on CT colonography. *Eur Radiol.* 17(2):575-9.
29. Lomas DJ, Sood RR, Graves MJ et al. (2001) Colon carcinoma: MR imaging with CO<sub>2</sub> enema--pilot study. *Radiology* 219(2):558-62.
30. Weishaupt D, Patak MA, Froehlich J et al. (1999) Faecal tagging to avoid colonic cleansing before MRI colonography. *Lancet* 354(9181):835-6
31. Goehde SC, Descher E, Boekstegers A et al. (2005) Dark lumen MR colonography based on fecal tagging for detection of colorectal masses: accuracy and patient acceptance. *Abdom Imaging* 30(5):576-83
32. Achiam MP, Løgager VB, Chabanova E et al. (2008) Diagnostic accuracy of MR colonography with fecal tagging. *Abdom Imaging* PMID: 18452023
33. Johnson CD, Chen MH, Toledano AY et al. (2008) Accuracy of CT colonography for detection of large adenomas and cancers. *N Engl J Med.* 359(12):1207-17.

34. Achiam MP, Løggager V, Chabanova E et al. (2008) Patient acceptance of MR colonography with improved fecal tagging versus conventional colonoscopy. *Eur J Radiol.* PMID: 19041207
35. Langhorst J, Kühle CA, Ajaj W et al. (2007) MR colonography without bowel purgation for the assessment of inflammatory bowel diseases: diagnostic accuracy and patient acceptance. *Inflamm Bowel Dis.* 13(8):1001-8
36. Kinner S, Kuehle CA, Langhorst J et al. (2007) MR colonography vs. optical colonoscopy: comparison of patients' acceptance in a screening population. *Eur Radiol.* 17(9):2286-93
37. Florie J, Birnie E, van Gelder RE et al. (2007) MR colonography with limited bowel preparation: patient acceptance compared with that of full-preparation colonoscopy. *Radiology* 245(1):150-9
38. Leung WK, Lam WW, Wu JC, et al. (2003). Magnetic resonance colonography in the detection of colonic neoplasm in high-risk and average-risk individuals. *Am J Gastroenterol.* 99(1):102-8.
39. Gluecker TM, Johnson CD, Harmsen WS et al. (2003) Colorectal cancer screening with CT colonography, colonoscopy, and double-contrast barium enema examination: prospective assessment of patient perceptions and preferences. *Radiology.* 227(2):378-84
40. Barth MM, Smith MP, Pedrosa I, Lenkinski RE, Rofsky NM (2007). Body MR Imaging at 3.0 T: Understanding the opportunities and challenges. *Radiographics* 27: 1445–1464.
41. Lauenstein TC, Saar B, Martin DR (2007) MR colonography: 1.5T versus 3T. *Magn Reson Imaging Clin N Am.* 15(3), 395-402, vii.
42. Rimola J, Rodriguez S, Garcia-Bosch O et al. (2009) Role of 3.0-T MR colonography in the evaluation of inflammatory bowel disease. *Radiographics* 29(3), 701-719.
43. Nederveen AJ, Gonçalves SI (2010): Imaging of the gastrointestinal tract at high-field strength. In: *Magnetic resonance imaging of the gastrointestinal tract.* Stoker J (Ed.), Springer Verlag, Berlin, Heidelberg, Germany, 21-32.
44. Saar B, Gschossmann JM, Bonel HM, Kickuth R, Vock P, Netzer P (2008) Evaluation of magnetic resonance colonography at 3.0 Tesla regarding diagnostic accuracy and image quality. *Invest Radiol.* 43(8):580-6.
45. Rottgen R, Herzog H, Bogen P, Freund T, Felix R, Bruhn H (2006) MR colonoscopy at 3.0 T: comparison with 1.5 T in vivo and a colon model. *Clin.Imaging* 30(4), 248-253.
46. Wessling J, Fischbach R, Borchert A et al: Detection of colorectal polyps (2006) comparison of multi-detector row CT and MR colonography in a colon phantom. *Radiology* 241(1), 125-131.
47. Yusuf E, Florie J, Nio CY et al (2009) Incidental extracolonic findings on bright lumen MR colonography in a population at increased risk for colorectal carcinoma. *Eur.J.Radiol.*
48. Ajaj WM, Ruehm SG, Ladd SC, Gerken G, Goyen M (2007) Utility of dark-lumen MR colonography for the assessment of extra-colonic organs. *Eur Radiol.* 17, 1574–1583.

# Chapter 3

## **Magnetic Resonance (MR) Colonography in the Detection of Colorectal Lesions: a Systematic Review of Prospective Studies.**

*Eur Radiol. 2010;20(5):1031-46*

*F.M. Zijta*

*S. Bipat*

*J. Stoker*

### Abstract

**Objective:** To determine the diagnostic accuracy of MR colonography for the detection of colorectal lesions.

**Material and methods:** A comprehensive literature-search was performed for comparative MR colonography studies, published between May 1997 and February 2009, using the MEDLINE, EMBASE and Cochrane databases. We included studies if MR colonography findings were prospectively compared with conventional colonoscopy in (a)symptomatic patients. Two reviewers independently extracted study design characteristics and data for summarising sensitivity and specificity. Heterogeneity in findings between studies was tested using  $I^2$ -test statistics. Sensitivity and specificity estimates with 95% confidence intervals were calculated on per-patient basis and summary sensitivity on per-polyp basis, using bivariate and univariate statistical models.

**Results:** 37 were found to be potentially relevant and 13 fulfilled the inclusion criteria. The study population comprises 1285 patients with a mean disease prevalence of 44% (range:22%-63%). Sensitivity for the detection of CRC was 100%. Significant heterogeneity was found for overall per-patient sensitivity and specificity. For polyps  $\geq 10$ mm, per-patient sensitivity and specificity estimates were 88% (95%CI:63%-97%;  $I^2=37\%$ ) and 99% (95%CI:95%-100%;  $I^2=60\%$ ). On a per-polyp basis, polyps  $\geq 10$ mm were detected with a sensitivity of 84% (95%CI:66%-94%;  $I^2=51\%$ ). The data were too heterogeneous for polyps  $< 6$ mm and 6-9mm.

**Conclusion:** MR colonography can accurately detect colorectal polyps more than 10mm in size.

## Introduction

Colonography comprises a complete colon examination that can be performed with the use of either computed tomography (CT) [1] or magnetic resonance imaging (MRI) [2]. CT colonography has been reported to be a feasible, safe, well tolerated examination with good diagnostic accuracy for the detection of colorectal polyps and cancer (CRC) [3]. Unfortunately, CT colonography requires ionising radiation, which poses a substantial drawback to large-scale use in patients at both average and increased risk of CRC [4]. Although some studies have shown that substantial dose reduction in CT colonography is feasible [5,6], an alternative imaging method that does not require ionising radiation would be preferable, especially for screening purposes.

Since 1997, several research groups have investigated the use of MR colonography. These studies show a large variation in terms of bowel preparation used, luminal contrast agents and imaging features. However in general, two main strategies can be identified for the visualisation of the colonic lumen and wall, i.e. the bright lumen and the dark lumen strategy [2, 7].

To determine the diagnostic accuracy of MR colonography, to date only one meta-analysis concerning an overall estimation of the diagnostic accuracy of MR colonography for the diagnosis of colorectal masses, has been carried out [8]. However, in this meta-analysis limited evaluation was performed regarding the detection of different polyp size thresholds. Additionally, this previous meta-analysis was performed in 2004 and mainly concerned the earlier studies, which were conducted in relatively small population cohorts. Considering the quantity of studies that have been performed since 2004 and the rapid developments and associated progress in the MRI field, an update seems to be warranted.

Therefore the primary aim of this study was to perform a systematic review and meta-analysis of the diagnostic accuracy of MR colonography compared with the reference standard (colonoscopy) for the detection of colorectal lesions, with a special interest in different polyp size thresholds. Our secondary aim was to assess the methodological quality and accuracy of reporting of the available primary studies using the QUADAS tool for proposing future reporting recommendations.

## Materials and Methods

### *Literature search*

A computer-assisted literature search was performed of the MEDLINE, EMBASE and Cochrane databases for relevant publications on the accuracy of MR

colonography in detecting colorectal lesions (see Appendix). We searched the databases from May 1997, when MR colonography was first described [2], to February 2009. There were no language restrictions. One observer (FZ) assessed the title and/or abstract of all retrieved papers to identify relevant articles for inclusion. Papers were considered ineligible if from reading the title or abstract it appeared that the paper was irrelevant, did not meet all the inclusion criteria or met any of the exclusion criteria. Reference lists of review articles and papers selected for inclusion were checked by hand to identify other relevant papers. The eligible articles were retrieved as full-text articles and independently checked by two reviewers (FZ,SB) for inclusion and exclusion criteria.

### *Inclusion and exclusion criteria*

Full prospective reports, in which subjects at average or increased risk of CRC underwent 1.5 Tesla or 3.0 Tesla MR colonography and completed colonoscopy for verification, were considered for inclusion. Furthermore eligible studies needed to focus on the detection of colorectal polyps and CRC, irrespective of histological findings. Inclusion criteria also required the construction of 2 x 2 tables, either by extracting true-positive (TP), false-negative (FN), false-positive (FP) and true-negative (TN) values or by reconstructing from sensitivity and specificity values.

Studies that reported any diagnosis other than colorectal polyps and/or CRC or in which the accuracy of detecting colorectal polyps could not be extrapolated from the paper, were excluded from our study. In addition studies with less than 10 patients were excluded. If there was any suspicion of a duplicate study, with a noticeable overlap of the study population, the most recent study with the largest population cohort was considered for inclusion. Disagreement between the two reviewers regarding inclusion and exclusion criteria was resolved by consensus. If a primary study was considered for inclusion, however additional information was required because of the incompleteness of the data sets, the corresponding author was contacted.

### *Study characteristics*

Methodological quality assessment and relevant data extraction were independently performed by the same two reviewers using a standardised form. In the event of disagreement, a decision was made by consensus. No blinding to the authors' information, publication year or journal title was applied.



*Study quality assessment*

To assess the methodological quality of the included studies and detect potential bias, ten relevant items of the Quality Assessment of Diagnostic Accuracy Studies in Systematic Reviews (QUADAS) tool were used [9]. We focused on the qualitative assessment of the included study population, index test and reference test. Therefore we assessed study population characteristics, such as number of included subjects; definition of potential CRC risk factors; whether subjects were consecutively recruited, mean or median age with age range and sex distribution (a). We determined whether a clear description of selection criteria was reported (b) and whether an accurate reference test (i.e. colonoscopy) was used (c). In addition, we determined the possibility of a disease progression bias. Therefore we documented the time interval between MR colonography and colonoscopy, assuming that the index test always preceded the reference test (maximum time-interval 4 weeks) (d).

To exclude the possibility of a partial verification bias, we assessed whether the whole sample or a random selection of the sample, did receive verification by means of colonoscopy. We accepted a sample of at least 90% receiving the reference test as complete verification (e). Furthermore we recorded if a clear description was given for the execution of the index test (f), if the index test findings were interpreted without knowledge of the reference standard (g), and if the reference standard was potentially adjusted by the index test findings (e.g. segmental unblinding, reassessment) (h). Additionally we investigated whether intermediate test results were reported in the included studies (i) and if withdrawals were reported (j).

*Imaging features*

If available, the following characteristics were documented regarding bowel preparation methods: type of bowel preparation (a); in the case of limited bowel preparation methods specification of contrast-material used (b); type of dietary restrictions (c); type of colonic luminal contrast method applied (d); amount of enema and pressure used if recorded (e); amount and type of spasmolytic drugs, if administered (f). In addition we recorded the following MR imaging characteristics: magnetic field strength (g); intravenous paramagnetic contrast material used (h); imaging parameters (e.g. acquisition time and imaging plane) (i); imaging procedure positions (j); and total examination time (k).

### *Imaging analysis*

The following data regarding image analysis, data handling and the reference standard were extracted from the selected studies, if available: image quality assessment (evaluation regarding: bowel distension, motion artefacts, lumen homogeneity)(a); type of data interpretation (two-dimensional reading (2D), three-dimensional reading (3D) or both)(b); number of observers (c); definition of observer experience (d); definition of consensus reading in the case of multiple observers (e); review time (f); and histological findings (g).

### *Data extraction*

For each report, we attempted to construct a 2x2 contingency table, consisting of TP, FN, FP, and TN values for per-patient analysis purposes. For the per-patient analysis, 2 x 2 tables were constructed for patients with any polyp (irrespective of size) and patients with large polyps ( $\geq 10$  mm).

For per-polyp analyses TP and FN values were extracted or reconstructed from each of the included studies. We attempted to stratify the extracted data into three different polyp size thresholds that are generally applied in colonography literature, based on the associated potential CRC risk [10]. Small polyps are generally defined as polyps  $< 6$ mm, medium polyps measure between 6 and 9mm and large polyps, which are polyps with a size of 10 mm or larger ( $\geq 10$  mm). Additionally we attempted to extract subset analysis of adenomas and CRC, if data were available.

### *Data analysis*

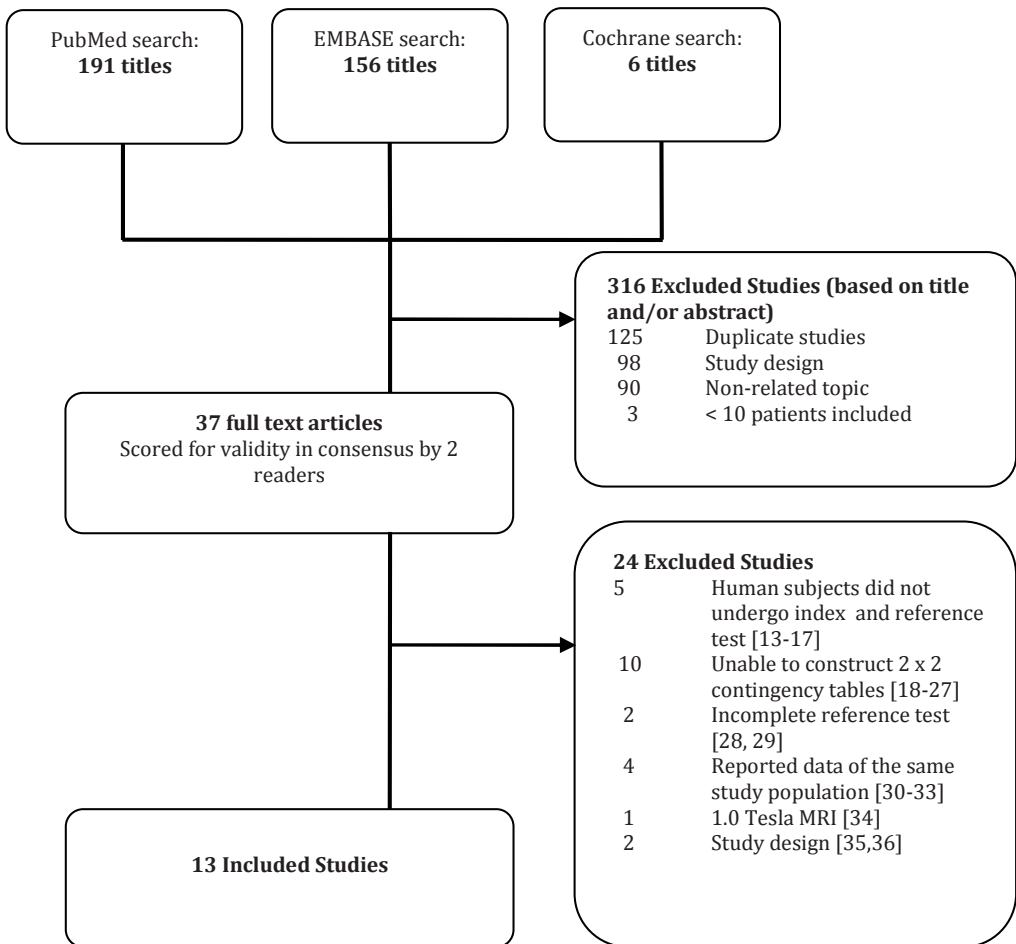
Per-patient analysis: per study we constructed 2x2 contingency tables for MR colonography compared with the reference standard and calculated sensitivity as  $TP/(FN+TP)$  and specificity as  $TN/(FP+TN)$ . For the assessment of heterogeneity the  $I^2$ -test statistic was used. The  $I^2$ -test is a measure of inconsistency describing the percentage of total variation between studies that is due to heterogeneity, with larger percentages indicating increasing heterogeneity [11]. In the case of  $I^2$ -value  $> 75\%$ , we assumed that data were significantly heterogeneous; consequently no data pooling was performed.

In all other cases,  $I^2$ -values  $< 75\%$ , we used the following bivariate statistical models – the random-effects model (random for both sensitivity as well as specificity, both  $I^2$ -values between 25% and 75%), the fixed-effects model (homogeneous for both sensitivity and specificity, both  $I^2$ -values  $< 25\%$ ) or the mixed effects model (e.g. random for sensitivity and fixed for specificity, one  $I^2$ -

value < 25% and the other I<sup>2</sup>-value between 25% and 50%) – to summarise results for meta-analysis.

The bivariate effects model [12] was used to summarise estimates of sensitivity and specificity with 95% confidence intervals. In this bivariate effects model, the logit-transformed sensitivities and logit-transformed specificities are assumed to follow a bivariate normal distribution across studies around a mean logit-sensitivity and mean logit-specificity, and therefore mean logit-sensitivity and mean logit-specificity with corresponding standard errors were obtained. After antilogit-transformation, summary estimates of sensitivity and specificity with their 95% confidence intervals (CIs) were obtained.

**Figure 1.** Flow chart of articles included for analysis.



Per-polyp analysis: for each threshold per study we calculated sensitivity as  $TP/(FN+TP)$ . The  $I^2$ -test statistics was used to quantify heterogeneity for sensitivity in percentages. In the case of  $I^2$ -value  $> 75\%$  no data pooling was performed. In all other cases, we used either univariate random-effects ( $I^2$ -values between 25% and 75%) or univariate fixed-effects models ( $I^2$ -values  $< 25\%$ ) to obtain summary estimates of sensitivity for meta-analysis. All analyses were executed using SAS software (SAS 9.2 procNlmixed, SAS Institute, Cary, NC, USA).

## Results

### *Search characteristics*

We retrieved 353 articles on the initial search. After screening on title and abstract, 316 papers were excluded from our study. Main considerations for rejection were duplicate studies (identical studies in MEDLINE, EMBASE and Cochrane databases), study design (e.g. review, letters and comments) and non-related topic (e.g. IBD, CT colonography) (*Figure 1*). Thirty-seven papers were considered for inclusion and the full-text papers were retrieved.

### *Study design characteristics*

Thirteen studies met all predefined criteria and were included in this study (*Figure 1*). Study design characteristics of all included studies are outlined in *Table 1*. Ten selected studies [38-45, 48,49] provided a clear description of the study population included, and in three studies [37,46,47] no indications of referral to colonoscopy were provided. In one study insufficient information was provided [37] regarding the time period between index test and the reference standard. In the remaining studies, colonoscopy was performed after MR colonography within a time interval ranging from same day performance [40, 41, 44-49] to a maximum of four weeks [42]. MR colonography findings were presented by segmental unblinding in four studies [37, 42, 45, 49]. Of the remaining studies one reported on a potential colonoscopic reassessment in the case of inconsistencies between MR colonography and colonoscopy findings [38], two studies did not describe any details of colonoscopy (un)blinding methods [46, 48] and in six studies the gastroenterologist was unaware of the MR findings during the complete colonoscopy procedure. Uninterpretable results of MR colonography were reported in eight studies [37, 39, 41, 42, 45-47]. In general, 11 studies fulfilled at least eight methodological criteria.

Table 1. Quality assessment of included studies using relevant items of the QUADAS tool

Study	Representative Patient population	Selection Criteria Specified	Accurate Verification	Time-interval specified*	Complete sample size verification†	Reproducible description index-test	Blinded interpretation index test	Blinded interpretation reference test	Intermediate index test results reported	Description of withdrawals
<b>Achiam [37]</b>	Yes	No	Yes	Unclear	No	Yes	Yes	No§	Yes	Yes
<b>Florie [38]</b>	Yes	Yes	Yes	Yes	Yes	Yes	Yes	Yes‡	Yes	Yes
<b>Goehde [39]</b>	Yes	Yes	Yes	Yes	Yes	Yes	Yes	Yes	Yes	Yes
<b>Hartmann [40]</b>	Yes	Yes	Yes	Yes	Yes	Yes	Yes	Yes	No	Yes
<b>Kerker [41]</b>	Yes	Yes	Yes	Yes	No	Yes	Unclear	Yes	Unclear	Yes
<b>Kuehle [42]</b>	Yes	Yes	Yes	Yes	No	Yes	Yes	No§	Yes	Yes
<b>Lauenstein [43]</b>	Yes	Yes	Yes	Yes	Yes	Yes	Yes	Yes	Unclear	Unclear
<b>Lauenstein [44]</b>	Yes	Yes	Yes	Yes	Yes	Yes	Yes	Yes	Yes	Yes
<b>Leung [45]</b>	Yes	Yes	Yes	Yes	Yes	Yes	Yes	No§	Yes	Yes
<b>Luboldt [46]</b>	Yes	No	Yes	Yes	Yes	Yes	Yes	Unclear	Yes	Yes
<b>Luboldt [47]</b>	Yes	Unclear	Yes	Yes	Yes	Yes	Yes	Yes	Yes	Yes
<b>Saar [48]</b>	Yes	Yes	Yes	Yes	Yes	Yes	Yes	Unclear	Unclear	Yes
<b>Saar [49]</b>	Yes	Yes	Yes	Yes	Yes	Yes	Yes	No§	Unclear	Yes

\* maximum time interval was defined as 4 weeks; † defined as at least 90% receiving the reference test; ‡ reassessment in new session if needed; § segmental unblinding

**Table 2.** Study characteristics of included studies.

<b>Study</b>	<b>Number of subjects for analysis</b>	<b>Consecutively recruited</b>	<b>Indications for Colonoscopy †</b>	<b>Patients with CRC or polyps &gt;10mm</b>	<b>Prevalence of patients with polyps &gt; 10 mm (%)</b>	<b>Mean age ±SD; range (yrs)</b>	<b>Sex ratio (male / female)</b>	<b>Study design</b>
<b>Achiam [37]</b>	47	Yes	NA	12/47	25	NA	NA	Prospective
<b>Florie [38]</b>	200	Yes	5 - 8	12/200	6	58±12	128/72	Prospective
<b>Goehde [39]</b>	42	Yes	1 - 6	NA	NA	NA	18/24	Prospective
<b>Hartmann [40]</b>	92	Yes	1,2,3,9,10	17/92	18	61.5±14.5	52/40	Prospective
<b>Kerker [41]</b>	80	Unclear	1,3,4,10	NA	NA	NA	NA	Prospective
<b>Kuehle [42]</b>	315	NA	1	20/315	6,3	NA	NA	Prospective
<b>Lauenstein [43]</b>	24	NA	2,4,9	13/24	25	57.4; 33-78	12/12	Prospective
<b>Lauenstein [44]</b>	37	NA	2,4,5,9	NA	NA	NA	NA	Prospective
<b>Leung [45]</b>	156	NA	1,2,4,7,10	11/156	4,5	55.2±9.1	74/82	Prospective
<b>Luboldt [46]</b>	21	NA	NA	4/21	19	NA	NA	Prospective
<b>Luboldt [47]</b>	117	NA	NA	14/117	12	NA	NA	Prospective
<b>Saar [48]</b>	120	Yes	6,9	NA	NA	69;22-87	56/64	Prospective
<b>Saar [49]</b>	34	NA	2,4,6,7,9	NA	NA	60 *;21-88	21/13	Prospective

NA = not available; \* median age; † indications: 1) Screening; 2) Faecal blood; 3) abdominal complaints; 4) change in bowel habits; 5) personal history of CRC; 6) personal history of polyps; 7) family history of CRC; 8) family history of polyps; 9) faecal occult blood testing positive (FOBT+); 10) anaemia.

*Patient characteristics*

Patient characteristics are outlined in Table 2. In this meta-analysis we included 13 studies with in total 1285 patients. Five studies reported a study population of >100 patients [38, 42, 45, 47, 48] and these studies comprised 908(71%) patients of the total study population. The largest study population included 315 asymptomatic individuals with a normal risk profile for CRC [42]. In 9 studies [38-41, 43-45, 48, 49] symptomatic and/or asymptomatic patients at increased risk of CRC were included, and in three studies [37, 46, 47] indications for colonoscopy were unclear.

*Imaging features and image analysis*

MR imaging features are outlined in *Tables 3 and 4*. Most of the studies reported all relevant data. However, there was a variation in the preparation as well as the applied technical parameters. Dark-lumen MR colonography was reported in nine studies [37, 39-45, 49] in which a water-based enema and intravenous paramagnetic contrast administration was used in eight of these studies (89%). Individual reader experience was defined in four studies ranging from 40 cases [38] to over 50 cases [48, 49]. In two other studies [39, 40], reader experience was defined as >4 years [39] or 5-15 years' [40] clinical experience with abdominal MRI, however no proven competence was shown for reading MR colonography in these studies (*Table 5*).

*Data extraction*

For each included study we were able to construct 2x2 contingency tables of the extracted determinates. However no standard format of data presentation was found, as per-patient data were not reported for each threshold. In 11 studies [39-49] per-patient reporting concerned at least overall results, which included polyps of all sizes. In six of these studies overall results were presented with at least one additional threshold of per-patient polyp data. In two studies per-patient data were presented as sensitivity and specificity stratified to medium and large sized polyps combined ( $\geq 6\text{mm}$ ) and polyps  $\geq 10\text{mm}$ , however the overall polyp data were missing [37, 38]. Corresponding authors were contacted in order to obtain overall polyp data (including  $< 6\text{mm}$ ), and all supplied us with the required data. Per-polyp data for each of the different polyp size categories could be obtained in 5 of the 13 studies (38%).

**Table 3.** MR imaging characteristics of included studies.

<b>Study</b>	<i>Type of Bowel preparation / faecal tagging</i>	<i>Diet</i>	<i>Technical method</i>	<i>Type of enema used</i>	<i>Volume (L)</i>	<i>Enema pressure</i>	<i>Spasmolytic drugs (mg)</i>	<i>Intravenous contrast agent (mmol/kg)</i>
<b>Achiam [37]</b>	4 x 200cc ferumoxsil/Barium sulphate	Low †	dark-lumen	water-based	2-2.5	1.5m H2O	buscopan® (40)	Dotarem® (0.2)
<b>Florie [38]</b>	6 x 10cc Magnevist® + lactulose	Low †	bright-lumen	mixture water/gadolinium-based	1.9	0.8m H2O	buscopan® (20)	None
<b>Goehde [39]</b>	6 x 150cc Barium sulphate	Low †	dark-lumen	water-based	2-2.5	NA	buscopan® (40)	Multihance® (0.2)
<b>Hartmann [40]</b>	Bowel cleansing (4L polyeth. glycol-electr)	no	dark-lumen	water-based	2-2.5	NA	buscopan® (40)	Multihance®
<b>Kerker [41]</b>	Bowel cleansing (4L polyeth. glycol solution)	no	dark-lumen	water-based	2	NA	buscopan® (40)	Magnevist®
<b>Kuehle [42]</b>	6 x 150cc solution (5% gastrografin/ 1% barium/ 0.2% bean gum)	no	dark-lumen	water-based	2	1-1.5	buscopan® (40)	Dotarem® (0.2)
<b>Lauenstein [43]</b>	4/5 x 200cc Barium sulphate	Low †	dark-lumen	water-based	1.5-2.5	1.0-1.5m H2O	buscopan® (20)	Multihance® (0.2)
<b>Lauenstein [44]</b>	Bowel cleansing (3L electrolyte solution)	no	dark-lumen	water-based	2.5	1.0m H2O	buscopan® (20)	Multihance® (0.2)
<b>Leung [45]</b>	Bowel cleansing (phospho-soda)	no	dark-lumen	air-based	30-40 puffs*	NA	hyoscine (20)	None
<b>Luboldt [46]</b>	Bowel cleansing (3L polyeth. glycol solution)	no	bright-lumen	mixture water/gadolinium-based	1.5-2.0	1-2m H2O	buscopan® (20)	Magnevist® (0.1)
<b>Luboldt [47]</b>	Bowel cleansing (3L bowel preparation solution)	no	bright-lumen	mixture water/gadolinium-based	1.8-3.0	1.0m H2O	buscopan® (20)	None
<b>Saar [48]</b>	Bowel cleansing (4-6L polyeth. glycol-electr)	no	bright-lumen	mixture water/gadolinium-based	1.5-2.5	NA	buscopan® (20)	None
<b>Saar [49]</b>	Bowel cleansing (3-4L electrolytic solution)	no	dark-lumen	water-based	2.5	±1m H2O	buscopan® (40)	Multihance® (0.2)

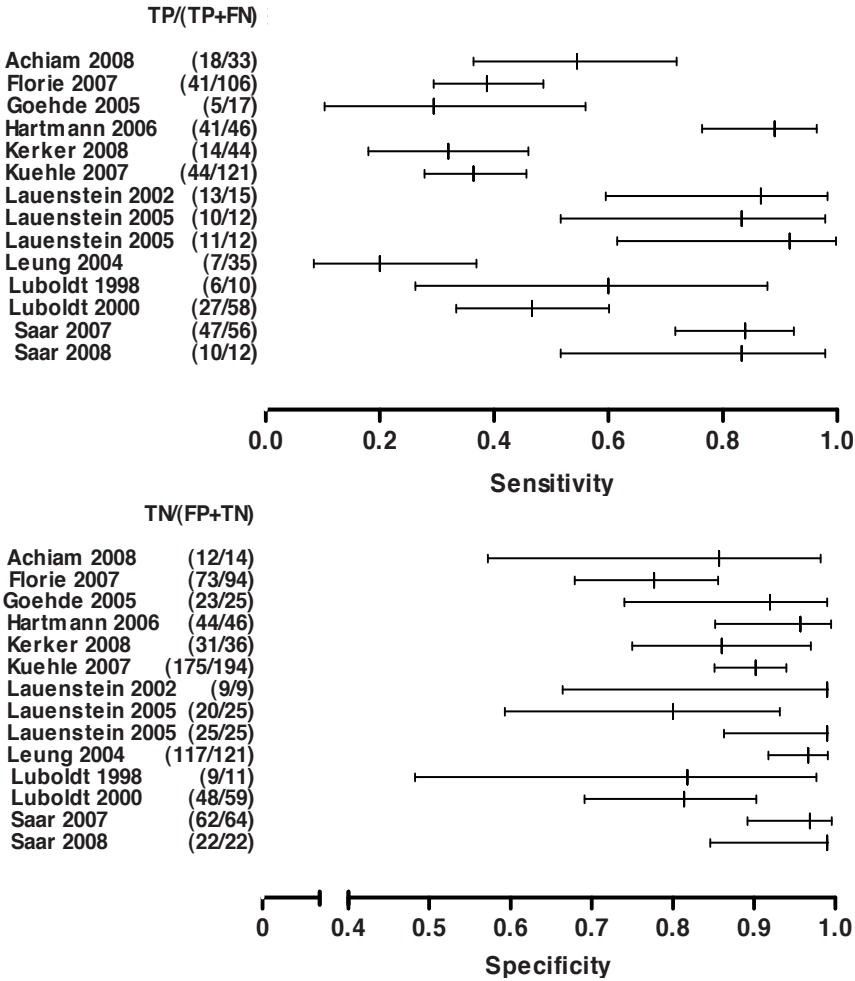
\* manual air-inflation; † low fibre diet



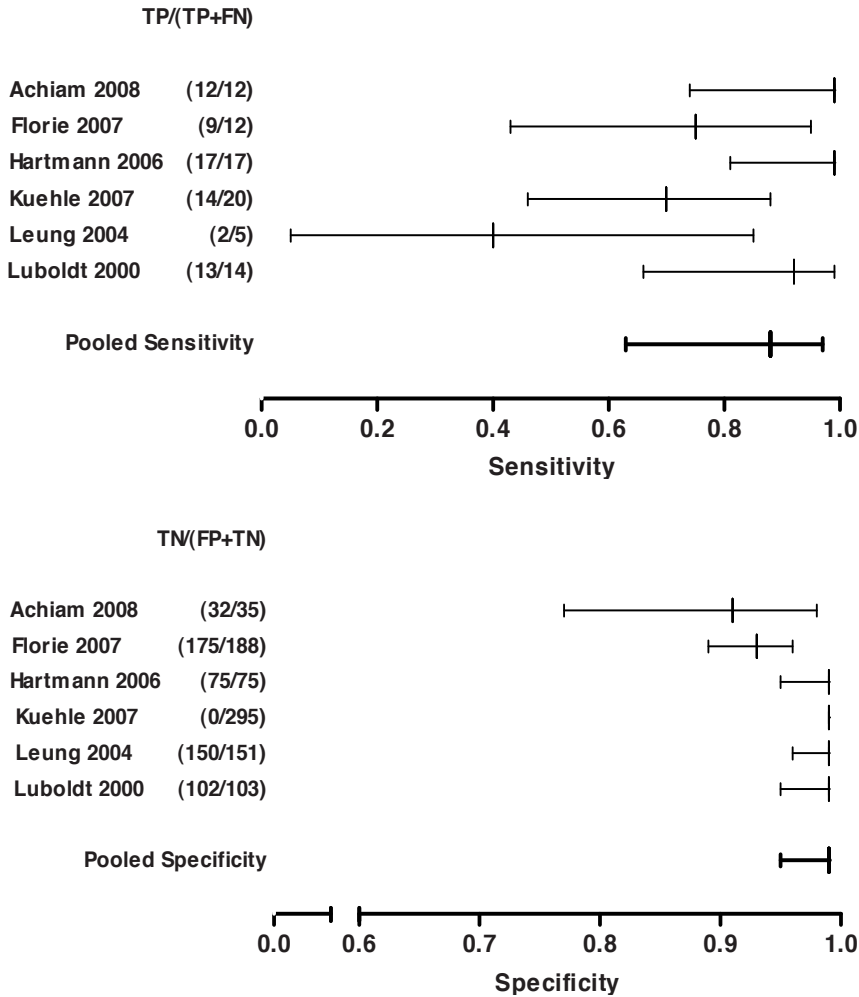
*Data analysis*

Per-patient analysis: Inter-study heterogeneity ( $I^2$ ) for the detection of patients with polyps, irrespective of size, was significant for sensitivity (86% (95%CI: 79%-91%)) and proved moderate for specificity (58%(95%CI: 28%-76%). Therefore, calculating summary estimates of sensitivity and specificity for the detection of all polyps was not sensible in this context (Figure 2a). Outcomes for the detection of patients with large polyps ( $\geq 10\text{mm}$ ) were available in six studies comprising 927 patients (72%). The  $I^2$  percentage for the sensitivities was 37% (95%CI:10%-63%) and for the specificities 60% (95%CI:17%-80%). The per-patient summary estimates of sensitivity and specificity values for this polyp size threshold were 88% (95%CI:63%-97%) and 99% (95%CI:95%-100%), respectively (Figure 2b). Because of this low to moderate heterogeneity, per-patient data for polyps  $\geq 10\text{mm}$  were analysed with the use of a random-effects approach.

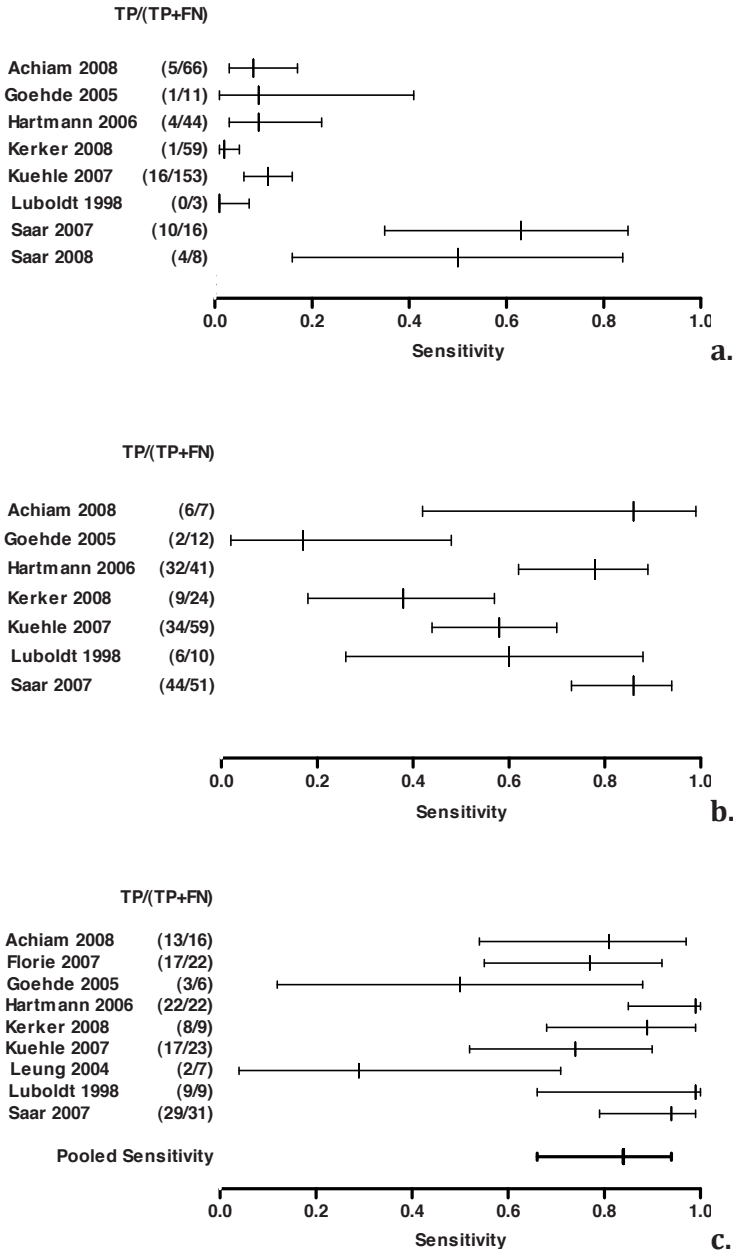
Per-polyp analysis: for per-polyp data, using the  $I^2$ -test statistics we found significant heterogeneity for polyps  $< 6\text{mm}$  (81% (95%CI:65%-90%) and polyps 6-9mm (80% (95%CI: 62%-89%)), which impedes reasonable meta-analysis for these two thresholds. Individual sensitivities for polyps  $< 6\text{mm}$  are presented in Figure 3a. Individual per-polyp sensitivities for polyps 6-9mm were based on the data of six studies comprising 204 polyps (Figure 3b). The  $I^2$  for the sensitivity of polyps  $\geq 10\text{mm}$  was 51% (95%CI:8%-74%). For polyps  $\geq 10\text{mm}$  the mean sensitivity estimate was 84% (95%CI: 66%-94%) (Figure 3c) and was based on the results of 145 polyps  $\geq 10\text{mm}$  and obtained by the random-effects approach. Reported individual detection rates of MR colonography for CRC were 100% comprising 32 carcinomas in 5 studies (Figure 4). In two studies an additional subanalysis for adenomas was performed [40, 42]. Per-patient sensitivity for detecting adenomatous polyps  $\geq 10\text{mm}$  in these studies was 100% and 87%, respectively.



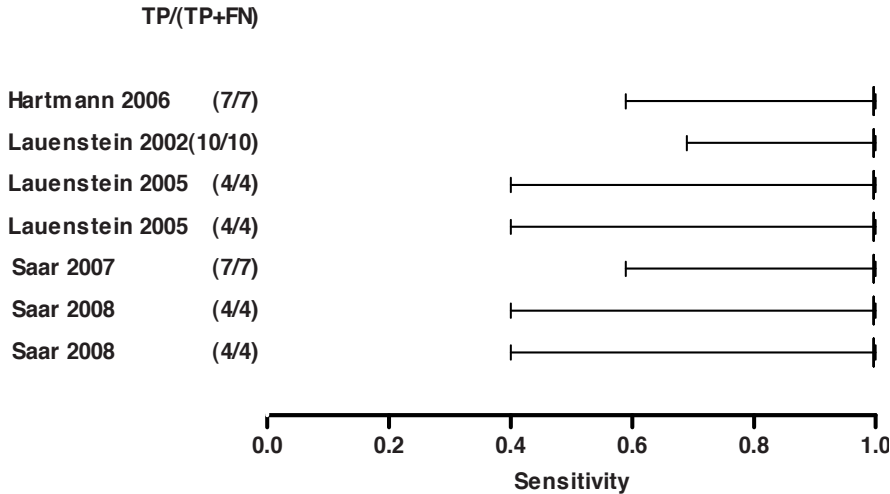
**Figure 2a.** Forest plot of per-patient sensitivity and specificity, including sensitivity and specificity estimates, for all polyps. FN = false-negative, FP = false-positive, TN = true-negative, TP = true-positive. Lauenstein et al. (2005) compared two different sequences in the same study population [44]; results of both sequences are used for calculating sensitivity and specificity estimates. Heterogeneity ( $I^2$ ) between study results for sensitivities was 86% (CI: 79-91%) and for specificities 58%(CI: 28-76%).



**Figure 2b.** Forest plot of per-patient sensitivity and specificity, including pooled sensitivity and specificity, for polyps  $\geq 10$  mm. FN = false-negative, FP = false-positive, TN = true-negative, TP = true-positive. Heterogeneity ( $I^2$ ) between study results for sensitivities was 37% (CI:10-63%) and for specificities 60% (CI:17-80%).



**Figure 3.** Forest plot of per-polyp sensitivity, including pooled per-polyp sensitivity, for polyps <6mm (a), polyps 6-9mm (b) and polyps ≥10 mm (c). FP = false-positive, TN = true-negative. Heterogeneity ( $I^2$ ) among study results for sensitivities for polyps <6mm 81%(CI:65-90%), polyps 6-9mm 80%(CI: 62-89%) and polyps ≥10 mm 51%(CI:8-74%).



**Figure 4.** Forest plot of sensitivity of MR colonography in the detection of CRC. Lauenstein et al. (2005) and Saar et al. (2008) compared two different sequences in the same study population [44,49]; results of both sequences are outlined in this forest plot.

## Discussion

Our systematic review demonstrates an average per-patient sensitivity of 88% (95%CI:63%-97%) and specificity of 99% (95%CI:95%-100%) for the detection of large polyps ( $\geq 10\text{mm}$ ) with the use of MR colonography. The sensitivity of MR colonography in detecting CRC was 100%. At per-polyp analysis, a summary sensitivity estimate of MR colonography in detecting polyps  $\geq 10\text{mm}$  was acceptable (84%;95%CI:66%-94%). Additionally, substantial variation is shown in data reporting between studies, as no standard format is used for presenting both per-patient and per-polyp results.

Important variability between study results was shown in sensitivity and specificity values, which is reflected by the significantly high  $I^2$ -values ( $>75\%$ ) for overall per-patient data and per-polyp data in the detection of polyps  $< 6\text{mm}$  and polyps 6-9mm, and impeded the complementary performance of a rational meta-analysis. This heterogeneity might be a consequence of a prominent diversity in technical aspects, as no consensus has been achieved regarding important study elements. This appears to be the opposite of CT colonography, where because of the rapid development of this technique, a consensus statement is currently established [50, 51]. Halligan et al. [52] proposed a minimum data set for study

level reporting for CT colonography in order to improve the quality of reporting in this field. The most obvious measure is to adopt similar reporting of study characteristics to those of CT colonography as far as possible. Still, compared with CT colonography, research on MR colonography is rather limited and more importantly to date no consensus has been achieved regarding imaging aspects. Therefore similar recommendations to those applied in CT colonography can only be achieved for certain aspects of MR colonography.

In a substantial number of included studies, important demographic characteristics could often not be derived from the available dataset after withdrawals were excluded from the initial included population. Regarding the description of the presence of risk factors for CRC in the study cohort, reports were detailed. Most primary studies included patients at increased risk of colorectal polyps, which leads to a higher prevalence of abnormalities and will ultimately result in better diagnostic outcomes [53]. One study exclusively reports on a screening population consisting of 315 individuals at no increased risk of CRC, and the overall prevalence of clinically relevant abnormalities in this cohort was 6.3 percent [42]. It should be stated that a detailed description regarding demographic characteristics and potential risk factors for CRC is required for study reporting. Moreover complete description of the data collection (prospective, retrospective) and participant sampling (consecutively) should be provided [54].

Similar to CT colonography, the prerequisite for MR colonography is a clean, well-distended colon with few residual faeces. Although the reported methods of achieving this baseline varied considerably, the technical specifications of the materials and methods used to perform MR colonography were sufficiently described in all studies. Because of the small groups and heterogeneous data, we were not able to perform a formal subgroup analysis and therefore we are unable to propose recommendations regarding the application of specific MR colonography techniques (i.e. dark lumen, bright lumen, bowel purgation, faecal tagging).

Six studies (46%) reported adequate determinates in order to calculate per-patient sensitivity and specificity values for separate size thresholds. In two of these studies calculation could be performed for each of three different size thresholds with additional split analyses for adenomas. Although per-patient analysis on overall polyp data were included in our statistical approach, we believe that similar to CT colonography a reasonable minimum size for reported polyps is >5mm [51]. Therefore we recommend that per-patient analysis must be

Table 4. MRI technical parameters of included studies

Study	Type of MRI scanner	Field strength (Tesla)	Sequence	TR (ms) / TE (ms)	Matrix	Slice Thickness (mm)	FOV (mm)	Prone (P)/ Supine (S)	Imaging plane	Breath hold(s)	Examination time(min)
<b>Achiam [37]</b>	Philips	1.5	3D T1	3.2/1.6	NA	1.7	420	NA	coronal	22	NA
<b>Florie [38]</b>	GE	1.5	3D T1	5.4/1.6	256x192	2	480x336	P/S	coronal	10-20	45
			2D T2	1354/64	320x224	4	460x322	P/S	axial		
			2D T2	1050/62	256x160	5	400x280	P/S	coronal		
	Philips	1.5	3D T1	5.6/1.9	512/304	2.5	480x432	P/S	coronal	10-20	45
			2D T2	676/165	256x256	5	400x320	P/S	axial		
			2D T2	687x195	256x256	5	480x432	P/S	coronal		
	Philips	3.0	3D T1	5.4x2.0	192x163	2.5	480x384	P/S	coronal	10-20	45
			2D T2	1002/60	455x455	5	455x455	P/S	axial		
<b>Goehde [39]</b>	Siemens	1.5	3D T1	1.64x0.6	512x460	1.5-2.0	450x450	P	coronal	22	NA
<b>Hartmann [40]</b>	Siemens	1.5	3D T1	3.1/1.17	NA	1.5-2.0	400x400	P	coronal	22	NA

NA = not available; \* using zero-filling interpolation; † voxel size; ‡ balanced GRE

**Table 4.** MRI technical parameters of included studies

Study	Type of MRI scanner	Field strength (Tesla)	Sequence	TR (ms) / TE (ms)	Matrix	Slice Thickness (mm)	FOV (mm)	Prone (P)/ Supine (S)	Imaging plane	Breath hold(s)	Examination time(min)
<b>Kerker [41]</b>	Siemens	1.5	3D T1	1.92/0.8	NA	NA	400	NA	coronal	20-25	NA
<b>Kuehle [42]</b>	Siemens	1.5	3D T1	3.08/1.1	168x256	1.8-2.4	500 (z)	P	coronal	<20	NA
				3	168x256	NA	500	P	axial		
<b>Lauenstein [43]</b>	Siemens	1.5	3D T1	1.64/0.6	460x512	1.57	450	P	coronal	22	<20
				0	460x512	NA	400	P	coronal		
<b>Lauenstein [44]</b>	Siemens	1.5	3D T1	3.1/1.1	180x256	1.8*	400	S	coronal	22	NA
				1.1	180x256	NA	400	S	coronal		
<b>Leung [45]</b>	Siemens	1.5	2D T2	∞/56	256x134	4	340-400	P/S	coronal/ axial	24	20.6±2.7
				56	256x134	4	340-400	P/S	coronal/ axial	24	20.6±2.7
<b>Luboldt [46]</b>	GE	1.5	3D T1	3.1/1.1	256x165	2.5	280-400	P/S	coronal	22	NA
				1.1	256x165	2.5	280-400	P/S	coronal	22	NA
			2D T1	4.7/2	256x160	2.2-3.6	380-460	p/S	NA	28	NA
				2	256x160	2.2-3.6	380-460	p/S	NA	28	NA
			2D T1	6/1.3	256x160	8-10	360-400	NA	NA	28	28

NA = not available, \* using zero-filling interpolation; † voxel size; ‡ balanced GRE



Table 4. MRI technical parameters of included studies

Study	Type of MRI scanner	Field strength (Tesla)	Sequence	TR (ms) / TE (ms)	Matrix	Slice Thickness (mm)	FOV (mm)	Prone (P)/ Supine (S)	Imaging plane	Breath hold(s)	Examination time(min)
Luboldt [47]	GE	1.5	3D T1	3.8/2.5	384x192	2-3	340-420	P/S	coronal	<30	NA
			2D T2	∞/65	256x160	6	340-420	P/S	coronal	<30	
Saar [48]	Philips	1.5	2D T1	4/1.7	128x128	4	450x450	P/S	coronal	20-23	21.5
			3D T1	3.3/1.3	256x256	1.5	450x450	P/S	coronal	20-23	
Saar [49]	Siemens	3.0	3D T1	2.53/1.0 3	384x384	1.6x1.0x1.5 ‡	400x400	S	coronal	NA	NA
			3D T1	3.14/1.5 1	256x256	2.4x1x1.5†	400x400	S	coronal		

NA = not available; \* using zero-filling interpolation; † voxel size; ‡ balanced GRE

reported both stratified into thresholds of medium and large polyps (6-9mm and  $\geq 10$ mm respectively) and combined. Additionally we propose per-polyp sensitivity results for polyps 6-9mm and polyps  $\geq 10$ mm, as this analysis enlightens the effective diagnostic performance of the test [55].

In CT colonography, diagnostic performance is known to be closely related to the level of observers' experience [56]. In our systematic review, most of the included studies insufficiently defined observer experience. Until now the required level of experience is not known for either MR colonography or CT colonography, but in CT colonography 50 verified training cases has been specified to be an absolute minimum [57]. MR colonography is most likely to be more difficult to interpret than CT colonography, therefore observer experience of just 40-50 validated MR colonography cases, which was reported in several studies, is always expected to be inadequate. As observer performance plays a substantial role in the measurement of accuracy, we recommend clearly describing the total number of per-study observers together with a clear definition of the observers' experience, quantified as the total number of verified cases interpreted.

To our knowledge, so far one meta-analysis has been carried out to evaluate the diagnostic performance of MR colonography [8]. In the previous meta-analysis sensitivity and specificity estimates for the detection of polyps of all sizes combined were 75% and 96%, but the presence of significant heterogeneity between the different studies minimised the statistical value of these outcomes. Individual study sensitivities in our analysis differed markedly as well and hampered quantification of all extracted data. However to be confronted with statistical heterogeneity is almost unavoidable when performing a meta-analysis of diagnostic studies.

Despite the statistical heterogeneity, the clinical relevance of summarising the sensitivity estimate for the detection of polyps of all sizes, as calculated in the previous meta-analysis, is limited, and reporting per relevant size category is far more informative. Importantly, in the present study we were able to perform additional analysis for the clinically most relevant polyp size threshold on both a per-patient and a per-polyp basis. This was based on a considerable albeit not large number of polyps  $\geq 10$ mm (145 polyps in total).

Furthermore, the previous meta-analysis included eight earlier comparative studies (1998-2004) with similar inclusion criteria to those we have set in our study. However in 3 of these 8 included studies [18, 21, 25], we were not able to extract important determinates (e.g. FP, TNs) and were consequently

**Table 5.** Image analysis characteristics.

<b>Study</b>	<i>Number of observers</i>	<i>Experience of observers Defined *</i>	<i>Data analysis method †</i>	<i>Consensus reading</i>	<i>Review Time (min)</i>	<i>Image Quality Assessment ‡</i>
<b>Achiam [37]</b>	2	50 cases	2D	No §	NA	Yes
<b>Florie [38]</b>	2	40 cases	2D	No §	NA	Yes
<b>Goehde [39]</b>	2	No	2D	Yes	NA	Yes
<b>Hartmann [40]</b>	5 II	No	2D/3D	Yes	NA	No
<b>Kerker [41]</b>	2	No	NA	NA	NA	No
<b>Kuehle [42]</b>	2	No	2D/3D	Yes	NA	Yes
<b>Lauenstein [43]</b>	2	No	2D/3D	Yes	NA	Yes
<b>Lauenstein [44]</b>	2	No	2D/3D	Yes	NA	Yes
<b>Leung [45]</b>	2	No	2D/3D	Yes	NA	No
<b>Luboldt [46]</b>	2	No	2D/3D	Yes	35-55	Yes
<b>Luboldt [47]</b>	2	No	2D/3D	Yes	NA	Yes
<b>Saar [48]</b>	2	>50 cases	2D/3D	Yes	23.5 (13.5-48)	Yes
<b>Saar [49]</b>	2	>50 cases	2D	Yes	NA	Yes

N.A. not available ; \* defined in exact number of validated MR colonography training cases; † 2D = multi planar reformation (MPR), 3D = virtual endoscopy; ‡ Quality assessment includes assessment of colonic distension, artefacts, lumen homogeneity or SNR/CNR; § interobserver agreement; II 2 radiologists and 3 gastroenterologists

excluded from our analysis. As no false-positive findings of any size were extracted for the primary studies concerned, the authors of the previous meta-analysis reported an excellent overall pooled specificity. In total we included three studies that were also evaluated in the previous meta-analysis [43, 45, 47], as we additionally excluded one study based on the use of 1.0Tesla field strength [34] and one study based on the inclusion of fewer than 10 patients [58].

A limitation of our study was the exclusion of seven studies due to the absence of per-patient polyp data and consequently not meeting our inclusion criteria. This could potentially result in a selection bias and ultimately in biased diagnostic estimates. Therefore we would like to emphasise the importance of completeness in data reporting in comparative MR colonography studies and subsequently facilitate future meta-analyses.

In our study publication bias is inevitable, regardless of attempts to use appropriate analytical approaches and execute a wide search without essential restrictions. However, we did not evaluate publication bias as much controversy remains about the applied statistical methods and outcomes in studies detecting publication bias [59].

In recent meta-analyses [52, 55, 60], high sensitivity estimates (ranging from 85% to 93%) were reported for detecting patients with large polyps using CT colonography. Our results seem comparable as the applied inclusion criteria do not differ considerably, and therefore MR colonography might be regarded as a future competitive diagnostic tool for this category of colorectal polyps. In this context the principal advantage of MR colonography is the use of non-ionising radiation. However one must bear in mind that currently MR colonography is hampered by its limited availability, unfavourable cost-effectiveness and longer examination time. Moreover, in order to compare the accuracy of these two techniques, ideally it would be preferable to execute a direct head-to-head comparison study. To date one study compared CT colonography with MR colonography in the detection of colorectal abnormalities in the same study population [19]. However CT colonography was not performed using state-of-the-art CT colonography, which makes it difficult to pose meaningful conclusions.

In conclusion, this systematic review shows that MR colonography can play a role in the detection of large colorectal polyps in patients at increased risk of CRC. Yet more research is needed to define its role in the detection of medium-sized polyps in this population, as this is far from established to date. Sizeable prospective screening studies using state of the art technique are warranted for this purpose. During our analysis we found little uniformity in the methods used with regard to MR colonography and data reporting. Ultimately, this leads to considerable heterogeneity, and therefore we propose reporting recommendations regarding crucial study design characteristics (i.e. definition of observer experience in MR colonography, standardised per-patient and per-polyp data presentation) for future studies. The methodology as used in CT colonography studies can serve as a framework for new MR colonography studies.

## References

1. Vining DJ, Gelfand DW, Bechtold RE, Scharling ES, Grishaw EK, Shifrin RY (1994) Technical feasibility of colon imaging with helical CT and virtual reality. *AJR Am J Roentgenol* 162 (suppl):104.
2. Luboldt W, Bauerfeind P, Steiner P, Fried M, Krestin GP, Debatin JF (1997) Preliminary assessment of three-dimensional magnetic resonance imaging for various colonic disorders. *Lancet* 349:1288-1291.
3. Johnson CD, Chen MH, Toledano AY, Heiken JP, Dachman A, Kuo MD, Menias CO, Siewert B, Cheema JI, Obregon RG, Fidler JL, Zimmerman P, Horton KM, Coakley K, Iyer RB, Hara AK, Halvorsen RA Jr, Casola G, Yee J, Herman BA, Burgart LJ, Limburg PJ (2008) Accuracy of CT colonography for detection of large adenomas and cancers. *N Engl J Med* 359:1207-1217.
4. Brenner DJ, Georgsson MA (2005) Mass screening with CT colonography: should the radiation exposure be of concern. *Gastroenterology* 129:328-337.
5. van Gelder RE, Venema HW, Serlie IW, Nio CY, Determann RM, Tipker CA, Vos FM, Glas AS, Bartelsman JF, Bossuyt PM, Laméris JS, Stoker J (2002) CT colonography at different radiation dose levels: feasibility of dose reduction. *Radiology* 224:25-33.
6. Florie J, van Gelder RE, Schutter MP, van Randen A, Venema HW, de Jager S, van der Hulst VP, Prent A, Bipat S, Bossuyt PM, Baak LC, Stoker J (2007) Feasibility study of computed tomography colonography using limited bowel preparation at normal and low-dose levels study. *Eur Radiol* 17:3112-3122.
7. Ajaj W, Debatin JF, Lauenstein T (2004) Dark-lumen MR colonography. *Abdom Imaging* 29:429-433.
8. Purkayastha S, Tekkis PP, Athanasiou T, Aziz O, Negus R, Gedroyc W, Darzi AW (2005) Magnetic resonance colonography versus colonoscopy as a diagnostic investigation for colorectal cancer: a meta-analysis. *Clin Radiol* 60: 980-989.
9. Whiting P, Rutjes AW, Reitsma JB, Bossuyt PM, Kleijnen J (2003) The development of QUADAS: a tool for the quality assessment of studies of diagnostic accuracy included in systematic reviews. *BMC Med Res Methodol* 3:25.
10. Iafrate F, Hassan C, Pickhardt PJ, Pichi A, Stagnitti A, Zullo A, Di Giulio E, Laghi A (2008) Portrait of a polyp: the CTC dilemma. *Abdom Imaging* DOI: 10.1007/s00261-008-9494-3
11. Higgins JP, Thompson SG, Deeks JJ, Altman DG (2003) Measuring inconsistency in meta-analyses. *BMJ* 327: 557-560.
12. Reitsma JB, Glas AS, Rutjes AW, Scholten RJ, Bossuyt PM, Zwinderman AH (2005). Bivariate analysis of sensitivity and specificity produces informative summary measures in diagnostic reviews. *J Clin Epidemiol* 58 :982-990.
13. Ajaj W, Lauenstein TC, Schneemann H, Kuehle C, Herborn CU, Goehde SC, Ruehm SG, Goyen M (2005) Magnetic resonance colonography without bowel cleansing using oral and rectal stool softeners (fecal cracking)--a feasibility study. *Eur Radiol* 15:2079-2087.
14. Bielen DJ, Bosmans HT, De Wever LL, Maes F, Tejpar S, Vanbeckevoort D, Marchal GJ (2005) Clinical validation of high-resolution fast spin-echo MR colonography after colon distention with air. *J Magn Reson Imaging* 22: 400-405.
15. Goehde SC, Hunold P, Vogt FM, Ajaj W, Goyen M, Herborn CU, Forsting M, Debatin JF, Ruehm SG (2005) Full-body cardiovascular and tumor MRI for early detection

- of disease: feasibility and initial experience in 298 subjects. *AJR Am J Roentgenol* 184: 598-611.
16. Wong TY, Lam WW, So NM, Lee JF, Leung KL (2007) Air-inflated magnetic resonance colonography in patients with incomplete conventional colonoscopy: Comparison with intraoperative findings, pathology specimens, and follow-up conventional colonoscopy. *Am J Gastroenterol* 102: 56-63.
  17. Goyen M, Goehde SC, Herborn CU, Hunold P, Vogt FM, Gizewski ER, Lauenstein TC, Ajaj W, Forsting M, Debatin JF, Ruehm SG (2004) MR-based full-body preventative cardiovascular and tumor imaging: technique and preliminary experience. *Eur Radiol* 14: 783-791.
  18. Luboldt W, Luz O, Vonthein R, Heuschmid M, Seemann M, Schaefer J, Stueker D, Claussen CD (2001) Three-dimensional double-contrast MR colonography: a display method simulating double-contrast barium enema. *AJR Am J Roentgenol* 176: 930-932.
  19. Haykir R, Karakose S, Karabacakoglu A, Sahin M, Kayacetin E (2006) Three-dimensional MR and axial CT colonography versus conventional colonoscopy for detection of colon pathologies. *World J Gastroenterol* 12: 2345-2350.
  20. Haykir R, Karaköse S, Karabacakoğlu A, Kayaçetin E, Sahin M (2006) Detection of colonic masses with MR colonography. *Turk J Gastroenterol* 17: 191-197.
  21. Ajaj W, Pelster G, Treichel U, Vogt FM, Debatin JF, Ruehm SG, Lauenstein TC (2003) Dark lumen magnetic resonance colonography: comparison with conventional colonoscopy for the detection of colorectal pathology. *Gut* 52: 1738-1743.
  22. Zhang S, Peng JW, Shi QY, Tang F, Zhong MG (2007) Colorectal neoplasm: magnetic resonance colonography with fat enema - initial clinical experience. *World J Gastroenterol* 13: 5371-5375.
  23. Achiam MP, Chabanova E, Løgager VB, Thomsen HS, Rosenberg J (2008) MR colonography with fecal tagging: barium vs. barium ferumoxsil. *Acad Radiol* 15: 576-583.
  24. Rodriguez Gomez S, Pagés Llinas M, Castells Garangou A, De Juan Garcia C, Bordas Alsina JM, Rimola Gibert J, Ayuso Colella JR, Ayuso Colella C (2008) Dark-lumen MR colonography with fecal tagging: a comparison of water enema and air methods of colonic distension for detecting colonic neoplasms. *Eur Radiol* 18: 1396-1405.
  25. Ajaj W, Lauenstein TC, Pelster G, Goehde SC, Debatin JF, Ruehm SG (2004) MR colonography: How does air compare to water for colonic distention? *J Magn Reson Imaging* 19: 216-221.
  26. Ajaj W, Veit P, Kuehle C, Joekel M, Lauenstein TC, Herborn CU (2005) Digital subtraction dark-lumen MR colonography: initial experience. *J Magn Reson Imaging* 21:841-844.
  27. Ajaj W, Ruehm SG, Gerken G, Goyen M (2006) Strengths and weaknesses of dark-lumen MR colonography: clinical relevance of polyps smaller than 5 mm in diameter at the moment of their detection. *J Magn Reson Imaging* 24:1088-1094.
  28. Ajaj W, Lauenstein TC, Pelster G, Holtmann G, Ruehm SG, Debatin JF, Goehde SC (2005) MR colonography in patients with incomplete conventional colonoscopy. *Radiology* 234: 452-459.

29. Hartmann D, Bassler B, Schilling D, Pfeiffer B, Jakobs R, Eickhoff A, Riemann JF, Layer G (2005) Incomplete conventional colonoscopy: magnetic resonance colonography in the evaluation of the proximal colon. *Endoscopy* 37:816-820.
30. Luboldt W, Debatin JF (1998) Virtual endoscopic colonography based on 3D MRI. *Abdom Imaging* 23 :568-572.
31. Lauenstein TC, Herborn CU, Vogt FM, Göhde SC, Debatin JF, Ruehm SG (2001) Dark lumen MR colonography: initial experience. *Rofo* 173: 785-789.
32. So NM, Lam WW, Mann D, Leung KL, Metreweli C (2003) Feasibility study of using air as a contrast medium in MR colonography. *Clin Radiol* 58 :555-559.
33. Lam WW, Leung WK, Wu JK, So NM, Sung JJ (2004) Screening of colonic tumors by air-inflated magnetic resonance (MR) colonography. *J Magn Reson Imaging* 19: 447-452.
34. Pappalardo G, Poletti E, Frattaroli FM, Casciani E, D'Orta C, D'Amato M, Gualdi GF (2000) Magnetic resonance colonography versus conventional colonoscopy for the detection of colonic endoluminal lesions. *Gastroenterology* 119 : 300-304.
35. Ajaj W, Rühm SG, Papanikolaou N, Lauenstein TC, Gerken G, Goyen M (2006) Dark lumen MR colonography: can high spatial resolution VIBE imaging improve the detection of colorectal masses? *Rofo* 178 :1073-1078.
36. Meier C, Wildermuth S (2002) Feasibility and potential of MR colonography for evaluating colorectal cancer. *Swiss Surg* 8:21-24.
37. Achiam MP, Løgager VB, Chabanova E, Eegholm B, Thomsen HS, Rosenberg J (2008). Diagnostic accuracy of MR colonography with fecal tagging. *Abdom Imaging* 34:483-490
38. Florie J, Jensch S, Nievelstein RA, Bartelsman JF, Baak LC, van Gelder RE, Haberkorn B, van Randen A, van der Ham MM, Snel P, van der Hulst VP, Bossuyt PM, Stoker J (2007) MR colonography with limited bowel preparation compared with optical colonoscopy in patients at increased risk for colorectal cancer. *Radiology* 243: 122-131.
39. Goehde SC, Descher E, Boekstegers A, Lauenstein T, Kühle C, Ruehm SG, Ajaj W (2005) Dark lumen MR colonography based on fecal tagging for detection of colorectal masses: accuracy and patient acceptance. *Abdom Imaging* 30: 576-583.
40. Hartmann D, Bassler B, Schilling D, Adamek HE, Jakobs R, Pfeifer B, Eickhoff A, Zindel C, Riemann JF, Layer G (2006) Colorectal polyps: detection with dark-lumen MR colonography versus conventional colonoscopy. *Radiology* 238 : 143-149.
41. Kerker J, Albes G, Roer N, Montag M, Budde T, Schaefer A (2008) MR colonography in hospitalized patients: feasibility and sensitivity. *Z Gastroenterol* 46: 339-343.
42. Kuehle CA, Langhorst J, Ladd SC, Zoepf T, Nuefer M, Grabellus F, Barkhausen J, Gerken G, Lauenstein TC (2007) Magnetic resonance colonography without bowel cleansing: a prospective cross sectional study in a screening population. *Gut* 56: 1079-1085.
43. Lauenstein TC, Goehde SC, Ruehm SG, Holtmann G, Debatin JF (2002) MR colonography with barium-based fecal tagging: initial clinical experience. *Radiology* 223: 248-254.
44. Lauenstein TC, Ajaj W, Kuehle CA, Goehde SC, Schlosser TW, Ruehm SG (2005) Magnetic resonance colonography: comparison of contrast-enhanced three-



- dimensional vibe with two-dimensional FISP sequences: preliminary experience. *Invest Radiol* 40 :89-96.
45. Leung WK, Lam WW, Wu JC, So NM, Fung SS, Chan FK, To KF, Yeung DT, Sung JJ (2004) Magnetic resonance colonography in the detection of colonic neoplasm in high-risk and average-risk individuals. *Am J Gastroenterol* 99: 102-108.
  46. Luboldt W, Steiner P, Bauerfeind P, Pelkonen P, Debatin JF (1998) Detection of mass lesions with MR colonography: preliminary report. *Radiology* 207:59-65.
  47. Luboldt W, Bauerfeind P, Wildermuth S, Marincek B, Fried M, Debatin JF (2000) Colonic masses: detection with MR colonography. *Radiology* 216 :383-388.
  48. Saar B, Meining A, Beer A, Settles M, Helmberger H, Frimberger E, Rummeny EJ, Rösch T (2007) Prospective study on bright lumen magnetic resonance colonography in comparison with conventional colonoscopy. *Br J Radiol* 80:235-241.
  49. Saar B, Gschossmann JM, Bonel HM, Kickuth R, Vock P, Netzer P (2008) Evaluation of magnetic resonance colonography at 3.0 Tesla regarding diagnostic accuracy and image quality. *Invest Radiol* 43:580-586.
  50. Taylor SA, Laghi A, Lefere P, Halligan S, Stoker J (2007) European Society of Gastrointestinal and Abdominal Radiology (ESGAR): consensus statement on CT colonography. *Eur Radiol* 17:575-579.
  51. Zalis ME, Barish MA, Choi JR, Dachman AH, Fenlon HM, Ferrucci JT, Glick SN, Laghi A, Macari M, McFarland EG, Morrin MM, Pickhardt PJ, Soto J, Yee J; Working Group on Virtual Colonoscopy (2005) CT colonography reporting and data system: a consensus proposal. *Radiology* 236: 3-9.
  52. Halligan S, Altman DG, Taylor SA, Mallett S, Deeks JJ, Bartram CI, Atkin W (2005) CT colonography in the detection of colorectal polyps and cancer: systematic review, meta-analysis, and proposed minimum data set for study level reporting. *Radiology* 237:893-904.
  53. Lalkhen G, McCluskey A (2008) Clinical tests: sensitivity and specificity. *Critical Care* 12:221-223.
  54. Bossuyt PM, Reitsma JB, Bruns DE, Gatsonis CA, Glasziou PP, Irwig LM, Lijmer JG, Moher D, Rennie D, de Vet HC; Standards for Reporting of Diagnostic Accuracy (2003) Towards complete and accurate reporting of studies of diagnostic accuracy: The STARD Initiative. *Radiology* 226:24-28.
  55. Sosna J, Morrin MM, Kruskal JB, Lavin PT, Rosen MP, Raptopoulos V (2003) CT colonography of colorectal polyps: a metaanalysis. *AJR Am J Roentgenol* 181:1593-1598.
  56. Soto JA, Barish MA, Yee J (2005) Reader training in CT colonography: how much is enough? *Radiology* 237:26-27.
  57. Burling D, Halligan S, Atchley J, Dhingsar R, Guest P, Hayward S, Higginson A, Jobling C, Kay C, Lilford R, Maskell G, McCafferty I, McGregor J, Morton D, Kumar Neelala M, Noakes M, Philips A, Riley P, Taylor A, Bassett P, Wardle J, Atkin W, Taylor SA (2007) CT colonography: interpretative performance in a non-academic environment. *Clin Radiol*;62:424-429.
  58. Lauenstein T, Holtmann G, Schoenfelder D, Bosk S, Ruehm SG, Debatin JF (2001) MR colonography without colonic cleansing: A new strategy to improve patient acceptance. *AJR Am J Roentgenol* 177:823-827.



59. Song F, Khan KS, Dinnes J, Sutton AJ (2002) Asymmetric funnel plots and publication bias in meta-analyses of diagnostic accuracy. *Int J Epidemiol* 31:88-95.
60. Mulhall BP, Veerappan GR, Jackson JL (2005) Meta-analysis: computed tomographic colonography. *Ann Intern Med* 142:635-650.

## Chapter 3

---

**Appendix.** Characteristics of the search strategy.

### PUBMED

	Search terms	Number of hits
#1	MR colonography [keyword]	122
#2	magnetic resonance colonography [keyword]	175
#3	virtual colonoscopy [keyword]	1230
#4	magnetic resonance imaging [MeSH]	225890
#5	#3 AND #4	115
#6	#1 OR #2 OR #5	209
	Limits: Human and publication date: from 1997 to 2009	191

### EMBASE

	Search terms	Number of hits
#1	MR colonography [keyword]	99
#2	magnetic resonance colonography [keyword]	78
#3	exp Nuclear Magnetic Resonance Imaging [MeSH]	232502
#4	virtual colonoscopy [keyword]	365
#5	#3 AND #4	51
#6	#1 OR #2 OR #5	175
	Limits: Human and publication date: from 1997 to 2009	156

### Cochrane

	Search terms	Number of hits
#1	MR colonography [Title, Abstract, Keyword]	3
#2	magnetic resonance colonography [Title, Abstract, Keyword]	6
#3	magnetic resonance imaging [Title, Abstract, Keyword]	4008
#4	virtual colonoscopy [Title, Abstract, Keyword]	32
#5	#3 AND #4	1
#6	#1 OR #2 OR #5	6

# Chapter 4

## **Diagnostic Performance of Radiographers as compared to Radiologists in Magnetic Resonance Colonography.**

*Eur J Radiol. 2010;75(2):e12-7*

*F.M. Zijta*

*J.Florie*

*S.Jensch*

*S.Bipat*

*R.A.J.Nievelstein*

*M.Poulus*

*M.A.Thomassen-de Graaf*

*A.D. Montauban van Swijndregt*

*J. Stoker*

### Abstract

**Purpose:** To evaluate the diagnostic performance of radiographers compared to radiologists in the detection of colorectal lesions in MR colonography.

**Material and methods:** 159 patients at increased risk of colorectal cancer were included. Four different experienced observers, one MR radiologist, one radiologist in training and two radiographers evaluated all MR colonography examinations. The protocol included T1-weighted and T2-weighted sequences in prone and supine position. Colonoscopy was used as reference standard. Mean sensitivity rates with 95% confidence intervals (CI's) were determined on a per-patient and per-polyp basis, segmented by size ( $\geq 6$  mm and  $\geq 10$  mm). Specificity was calculated on a per-patient basis. The McNemar and chi-square ( $\chi^2$ ) test was used to determine significant differences.

**Results:** At colonoscopy 74 patients (47%) had normal findings; 23 patients had 40 polyps with a size  $\geq 6$  mm. In ten patients at least one polyp  $\geq 10$  mm was found (20 polyps in total). Similar sensitivities for patients with lesions  $\geq 10$  mm were found for radiologists and radiographers (65% (95%CI: 44%-86%) vs. 50% (95%CI: 28%-72%)) (p=n.s.). For lesions  $\geq 10$ mm combined per-patient specificity for radiologists and radiographers was 96% (95%CI: 94%-98%) and 73% (95%CI: 68%-79%)(p<0.0001). Combined per-patient sensitivity for lesions  $\geq 6$ mm differed significantly between both groups of observers (57% (95%CI: 42%-71%) vs. 33% (95%CI: 19%-46%)) (p=0.03).

**Conclusion:** Radiographers have comparable sensitivity but lower specificity relative to radiologists in the detection of colorectal lesions  $\geq 10$ mm at MR colonography. Adequate training in evaluating MR colonography is necessary, especially for readers with no prior experience with colonography.

## Introduction

Magnetic Resonance (MR) colonography has increasingly been evaluated as a possible, non-invasive tool in the detection of colorectal neoplasia [1,2]. Equally to CT colonography, MR colonography permits a full examination of the entire colon. Major impetus for studying MR colonography is the lack of ionizing radiation, while high intrinsic contrast resolution might be considered as a further advantage. Recently high sensitivities (87-100 %) have been reported for MR colonography in the detection of colorectal adenomatous polyps  $\geq 10\text{mm}$ , in patients with both a normal risk profile and increased risk for colorectal cancer (CRC) [3,4]. As these results are comparable to results as found with CT colonography [5], MR colonography is considered as a competitive technique by some [6].

However, a meta-analysis of earlier studies comparing diagnostic performance of MR colonography to colonoscopic findings, demonstrated divergent results which were interpreted to be related to important differences in used MR colonography techniques [7].

In CT colonography research it is now widely accepted that besides the technical aspects of the examination, observer performance plays a substantial role in measures of accuracy [8]. To date this issue has not been addressed in the MR colonography literature. In order to improve diagnostic accuracy and decrease potential inter-observer variability, double reading has been applied in both mammography screening programs and CT colonography [9]. Yet, the role of non-radiologists as potential observers for double reading purposes, in MR colonography has not been studied. Prior to investigate this role, firstly the diagnostic performance of radiographers in MR colonography should be evaluated.

This study is aimed to compare the performance of two trained radiographers in comparison with the performance of two trained radiologists in the detection of colorectal polyps, using MR colonography examinations of 159 patients at increased risk of colorectal cancer. Sensitivity and specificity were compared using colonoscopy (CC) as reference standard.

## Methods

### *Study population*

159 consecutively enrolled patients were selected from a multicenter series of 200 surveillance patients who had participated in a comparative study of MR colonography and colonoscopy [10]. These 159 patients were selected for logistic

reasons, as all subjects consecutively underwent MR colonography in our centre. All patients were at increased risk of CRC and scheduled and were consequently included in prior study between February 20, 2003, and October 27, 2004. Patients were excluded if they were younger than 18 years, had a colostomy after colorectal surgery, had received oral or intravenous administration of another contrast medium within 48 hours prior to MR colonography, were unable to hold their breath for 25 s or presenting case of contraindications for MRI in general (including claustrophobia, metallic implants and/or pregnancy). Baseline study characteristics are outlined in *Table 1*. Previous multicenter study was performed in accordance with all guidelines set forth by the institutional ethics committee and all patients gave written informed consent. No additional informed consent was required for this study.

### *MRI preparation en imaging technique*

Bowel preparation consisted of a low-fibre diet, together with the ingestion of lactulose packets (Lactulose CF powder 6g/sachet, Centrafarm, Etten-Leur, the Netherlands) for stool softening starting 2 days before the examination. Additionally patients received 10 mL of gadolinium in a dose of 0.5 mmol/mL (gadopentetate dimeglumine, Magnevist; Schering, Berlin, Germany) at all six major meals prior to MR colonography (during this 2 day period).

Prior to scanning, 20 mg butylscopolamine bromide (Buscopan; Boehringer-Ingelheim, Ingelheim, Germany) or, if contraindicated, 1 mg glucagon hydrochloride (Glucagen; Novo-Nordisk, Bagsvaerd, Denmark) was administrated intravenously in order to reduce bowel movements. After placement of a flexible balloon-tipped rectal catheter, colonic distension was obtained by filling the colon with a mixture of water and gadolinium-based contrast-agent (10 mmol/L) by using 80 cm of hydrostatic pressure. By filling the colon with a mixture of water and paramagnetic contrast agent, the lumen appears hyperintense on the T1-weighted and hypointense on the T2-weighted sequences. Lesions originating from the colonic wall appeared as filling defects which protrude into the bright lumen.

Bright-lumen MR colonography was performed at 1.5T (Signa, GE Healthcare, Milwaukee, WI, USA) or 3T (Intera; Philips Medical Systems, Best, The Netherlands) using phased-array coils. The protocol included a coronal three-dimensional (3D) T1- weighted fast field echo (FFE) and a coronal and transverse two-dimensional (2D) T2- weighted fast spin echo (FSE). Technical parameters are shown in *Table 2*. All sequences were performed in both prone and supine

position during multiple breath holds, which took a maximum of 10 – 20 seconds each.

**Table 1.** Baseline characteristics at MR colonography.

Characteristics	Number
Men/women	103 / 56 ( 65 / 35% )
Mean age $\pm$ SD (range)	57 $\pm$ 12 ( 23 - 84 )
<b>Polyps status</b>	
No polyp detected	74 (47%)
At least one polyp $\geq$ 6 mm	23 (14%)
At least one polyp $\geq$ 10 mm	10 (6,2%)
<b>Reason for colonoscopy</b>	
Personal history of polyp(s)	88 (55%)
Personal history of CRC	37 (23%)
Family history of polyp(s)	4 (3%)
Familiiy history of CRC	30 (19%)
<b>Histopathological origin (<math>\geq</math>6 mm)</b>	
Adenomatous	16 (40%)
Hyperplastic	10 (25%)
Inflammatory/reactive tissue	3 (7%)
No histopathological classification	11 (28%)

**Table 2.** Parameters of three-dimensional (3D) T1-weighted fast field echo (FFE) and two-dimensional (2D) T2- weighted fast spin echo (FSE) sequences.

	TR (ms)	TE (ms)	Matrix	Slice thickness	FOV (mm)	Slices
<b>1.5T</b>						
T1-FFE cor	5.4	1.6	256x192	2.0	480x336	120
T2-FSE cor	1050	62	256x160	5	400x280	50
T2-FSE ax	1354	64	320x224	4	460x322	88
<b>3.0T</b>						
T1-FFE cor	5.4	2.0	192x163	2.5	480x384	72
T2-FSE cor	1002	60	304x274	5	485x485	40
T2-FSE ax	1002	60	304x274	5	455x455	72

### *Reader experience*

All 159 datasets were independently evaluated by four different observers, who were blinded for the results of colonoscopy and patient's history. Reading performance of the radiologists were extracted from the database which was reported earlier as part of a multicenter study evaluating the diagnostic performance of MR colonography [10]. Observer 1 (RN), an experienced abdominal radiologist with 11 years of clinical experience of (abdominal) MR imaging, had reviewed 20 CT colonography examinations. The second observer (SJ), a second-year resident in radiology, had read over 160 CT colonography examinations.

Observers three and four were radiographers with experience in performing CT (colonography) examinations. Furthermore observer 4 (MP) had read more than 165 CT colonography examinations by participating in an identical study evaluating the performance of radiographers in CT colonography [11]. Observer 3 (MT) had no experience in evaluating CT colonography or MR colonography images prior to this study.

### *Radiographers training*

All four observers had complementary training prior to start of the study by evaluating 40 MR colonography examinations. Radiographers were instructed to read a maximum of five MR colonography exams in 1 day, and all 40 exams were read within 3 weeks. After the completion of respectively 20 and 40 test cases each radiographer was being unblinded to the reference standard results. Supplementary feedback was provided and in addition common pitfalls in the interpretation of MR colonography were outlined by a research fellow (JF), whose experience consisted of reading images from CT colonography (>400 examinations with colonoscopy verification) and matching (>80 CT colonography and >50 MR colonographic evaluations with colonoscopy).

### *MR colonography reading*

2D data evaluation of axial (T2w) and coronal (T1w and T2w) images of the colon and comparison of the prone and supine datasets, was performed on a post-processing workstation (Extended Brilliance Workspace; Philips Medical Systems, Best, the Netherlands) or image archiving and communication system (IMPAX-SP4-SU4-DS3000; Agfa, Mortsel, Belgium).

The presence, size and location of detected colorectal lesions were documented. Lesion size was measured by using callipers. The location of the



detected polyp was scored (predefined segments: cecum, ascending colon, transverse colon, descending colon, sigmoid colon or rectum). A degree of interpretation confidence regarding the detected lesions was documented by all observers; 100 %, certainly polyp; 75%, probably polyp; 50%, possibly a polyp; 25% probably no polyp; 0%, no polyp. Only detected polyps with a confidence degree of 50% or higher were considered for analyses. During reading radiographers were blinded to clinical information, initial results of readings by radiologists and consequently disease prevalence in the datasets.

### *Colonoscopy and data handling*

Colonoscopy was performed after the MR colonography and was considered as the reference standard regarding the presence of colorectal polyps. Full bowel preparation, consisted of 4 – 6 L of polyethylene glycol electrolyte solution (KleanPrep, Helsinn Birex Pharmaceuticals, Dublin, Ireland). Colonoscopy was performed with a standard endoscope (CF-Q160AL or CF-Q160L; Olympus, Tokyo, Japan) and videotaped, observed abnormalities were registered by the examiner. Detected polyps were documented and scored based on location (segment location: cecum, ascending colon, transverse colon, descending colon, sigmoid colon, rectum), morphology (sessile, pedunculated and/or flat) and size. Before removal the polyp size was estimated based on comparison with an open biopsy forceps of known size (8mm).

A research fellow (JF) who was not involved in the reading, matched all large polyps in a face-to-face comparison of colonoscopy and MR colonography. Colorectal polyps were classified according to their size as follows:  $\geq 6$  mm and  $\geq 10$  mm. For a true-positive result three criteria had to be met; the lesion identified at MR colonography had to match CC findings with respect to location (the segmental location had to correspond with the same or adjacent segment as allocated with colonoscopy), size (estimation of size was performed during colonoscopy on comparison with the open forceps) and morphologic features (sessile, pedunculated and/or flat) of a lesion. A 50% margin was applied on the polyp size, as measured with MR colonography.

### *Statistical analysis*

Main outcome parameters of this study were per-patient sensitivity and per-patient specificity for polyps  $\geq 6$  mm (medium and large sized polyps) and  $\geq 10$  mm (large polyps) in size.

In the per-patient evaluation, a result was considered a true-positive

finding, if at least one polyp as detected with MR colonography was matched to a lesion as detected with colonoscopy in one patient. If a polyp was detected with MR colonography and no matching lesion was found with CC, a finding was defined as false-positive. A false-positive patient was defined when a patient had at least one finding detected with MR colonography with no matching finding with CC.

The secondary outcome of this study was per-polyp sensitivity for polyps  $\geq 6$  mm and  $\geq 10$  mm. The per-polyp sensitivity was defined as the number of colorectal polyps detected with MR colonography relative to the number as detected with colonoscopy. Per-patient sensitivity and specificity and the per-polyp sensitivity rates were combined for both observers 1 and 2 and observers 3 and 4, in order to obtain a mean sensitivity for both groups.

The McNemar statistic was used to test differences on significance in per-patient sensitivity and specificity rates between the four observers. The chi-square ( $\chi^2$ ) test was used to determine significant differences between groups of observers. Differences with  $p$ -values  $< 0.05$  were considered statistical significant. SPSS 15.0.1 for Windows (SPSS Inc, Chicago, IL, USA) was used for all statistical analyses except for the calculation of confidence intervals.

## Results

### *Results of colonoscopy*

Seventy-four (47%) of the 159 patients had normal findings with colonoscopy. In 23 of the 159 patients (14%) 1 or more polyps with a size exceeding 6 mm were detected (40 polyps in total), in 10 patients 1 or more polyps with a size  $\geq 10$  mm were detected (20 polyps in total). The histopathology classification of all found and removed polyps  $\geq 6$  mm are outlined in *Table 1*. No villous adenomas and/or carcinomas were detected during colonoscopy.

### *MR colonography*

Of 159 patients, 127 were scanned on a 1.5T GE MRI scanner (80%) and 32 were scanned on a 3.0T Philips scanner. Of the 20 polyps  $\geq 10$  mm, no reference polyp could be identified in three cases based on previous outlined matching criteria, concerning three flat polyps of respectively 10, 15 and 20 mm in size. *Table 3* shows the diagnostic performance for all four individual observers and for radiologists and radiographers combined, at MR colonography in the detection of polyps according to size for per-patient analysis.

**Table 3.** Per-patient sensitivity and specificity for individual observers and mean per group

Observer	Polyps $\geq 10$ mm		Polyps $\geq 6$ mm	
	Sensitivity [95%CI]	Specificity [95%CI]*	Sensitivity [95%CI]†	Specificity [95%CI]‡
	Number	Number	Number	Number
<b>1</b>	60% [30-90] 6/10	95% [92-99] 142/149	48% [27-68] 11/23	72% [65-80] 98/136
<b>2</b>	70% [42-98] 7/10	97% [95-100] 145/149	65% [46-85] 15/23	88% [83-94] 120/136
<b>1 + 2</b>	65% [44-86] 13/20	96% [94-98] 287/298	57% [42-71] 26/46	80% [75-85] 218/272
<b>3</b>	30% [02-58] 3/10	75% [68-82] 112/149	22% [05-39] 5/23	75% [68-82] 102/136
<b>4</b>	70% [42-98] 7/10	72% [65-79] 107/149	43% [23-64] 10/23	37% [29-45] 50/136
<b>3 + 4</b>	50% [28-72] 10/20	73% [68-79] 219/298	33% [19-46] 15/46	56% [50-62] 152/272

CI: confidence interval

\*= obs. 1 vs. obs. 3 :  $p < 0.001$ ; obs. 1 vs. obs. 4 :  $p < 0.001$ ; obs. 2 vs. obs. 3 :  $p < 0.001$ ; obs. 2 vs. obs. 4 :  $p < 0.001$ ; groups  $p < 0.0001$ .

†= obs. 2 vs. obs. 3 :  $p = 0.002$ ; groups  $p = 0.03$

‡= obs. 1 vs. obs. 4 :  $p < 0.001$ ; obs. 2 vs. obs. 3 :  $p = 0.014$ ; obs. 2 vs. obs. 4 :  $p < 0.001$ ; groups  $p < 0.0001$

### Per-patient

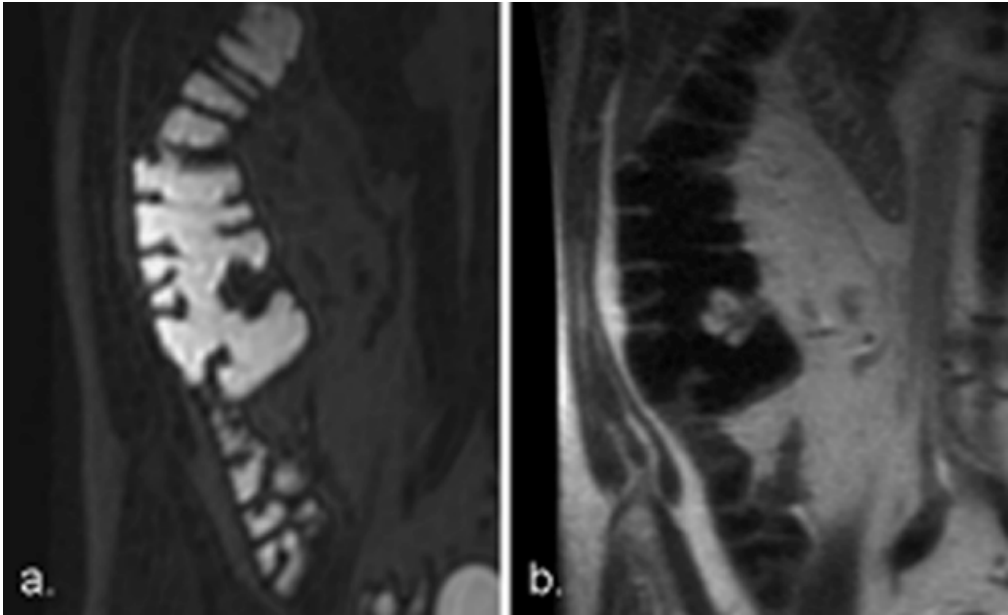
Radiographers identified true-positive polyps  $\geq 10$  mm in respectively 3 and 7 patients, resulting in a per-patient sensitivity of 30%, 70% and 50% for observers 3, 4 and observers 3 and 4 combined. The sensitivity for detection of polyps in this category was 65% for observers 1 and 2 combined. For this threshold no significant differences in detection rates were found between observers and combined groups of observers ( $p = 0.337$ ). Lower sensitivity values were found for patients with polyps  $\geq 6$  mm (33% for radiographers combined and 57% for radiologists combined), which showed a significant difference between both groups of observers ( $p = 0.03$ ).

Specificity values among patients with large polyps  $\geq 10$  mm were significantly different between radiologists and radiographers and both groups combined ( $p < 0.0001$ ). Radiographers showed high numbers of false-positive patients (37 for observer 3 and 42 for observer 4), resulting in a moderate

specificity rate for large polyps (75% and 72% for observers 3 and 4 respectively). Retrospective analyses of the false-positive patients in this group learned that in 86% (32/37) and in 57% (24/42), the false positive findings were related to the ileocecal valve, for observers 3 and 4 respectively (*Figure 1*). The remaining false-positive findings could be explained by faecal material or air bubbles. Significant differences in specificity rates were found for polyps  $\geq 6$  mm in size between observers 1 and 4 ( $p < 0.001$ ), between observers 2 and 3 ( $p = 0.014$ ) and between observers 2 and 4 ( $p < 0.001$ ).

*Per-polyp*

Observer 3 detected 4/20 (20%) and observer 4 detected 10/20 (50%) of the polyps  $\geq 10$  mm. Radiologists correctly identified 11/20 (55%) and 9/20 (45%) of the large polyps. High false-negative rates for polyps  $\geq 6$  mm resulted in low sensitivity in both observers 3 and 4. *Table 4* shows the polyp detection for all four individual observers and for radiologists and radiographers combined.



**Figure 1.** Coronal 3D T1-weighted (a) sequence in bright-lumen MR colonography. Example of a protruding ileocecal valve which was incorrectly identified as a colonic lesion by both radiographers. Both radiologists correctly identified the structure as a normal anatomic appearance of an ileocecal valve with correspondent signal intensities on the T2-weighted sequence (b).

**Table 4.** Per-polyp sensitivity and specificity for individual observers and mean per group.

Observer	Polyps $\geq 10$ mm		Polyps $\geq 6$ mm	
	Sensitivity [95%CI]	Number	Sensitivity [95%CI]	Number
1	55% [33-77]	11/20	50% [35-65]	20/40
2	45% [23-67]	9/20	58% [42-73]	23/40
1 + 2	50% [35-65]	20/40	54% [43-65]	43/80
3	20% [02-38]	4/20	15% [04-26]	6/40
4	50% [28-72]	10/20	35% [20-50]	14/40
3 + 4	35% [20-50]	14/40	25% [16-34]	20/80

## Discussion

This study evaluated the diagnostic performance of radiographers as compared to radiologists (one radiologist, one radiology resident), in the detection of colorectal lesions in an increased risk population using MR colonography. We found that there was no significant difference in sensitivity for polyps  $\geq 10$  mm between radiographers and radiologists. However, specificity values were significantly lower in radiographers (75%, 72%) than in radiologists (95%, 97%).

To our knowledge this is the first study in which the performance of non-radiologists in MR colonography is evaluated. In CT colonography, a number of studies already evaluated reader performance of radiographers. In one study with 150 patients at increased risk for colorectal cancer, trained radiologists and trained radiographers showed similar accuracy in detection rate of patients with polyps  $\geq 10$  mm (78%) [11]. Another study [12] reported a comparable diagnostic performance between radiologists and non-radiologists identifying patients with large lesions ( $\geq 10$  mm) in 81% and 78% respectively. As a consequence a future role was suggested for trained radiographers in double-interpretation screening in CT colonography.

In our study we found no statistical significant differences in sensitivity rates between radiologists and radiographers for the detection of large polyps ( $\geq 10$  mm), therefore our findings are comparable to previous mentioned CT colonography studies. However, the detection rates for clinical significant polyps in this study are only moderate for both radiographers and radiologists and proved inferior to the detection rates in CT colonography, as previously outlined. Yet this study was aimed to evaluate the reader performance of non-radiologists relative to that of radiologists rather than to evaluate the performance of MR colonography relative to CT colonography.

Substantial variability in polyp detection rates was observed between the two radiographers in the present study. Radiographers in our study were both highly motivated technologists who were experienced in performing CT (colonography) examinations at the department of Radiology in our centre. The first radiographer (observer 3) had no experience in evaluating CT colonography or MR colonography images prior to this study. The second radiographer (observer 4) had read more than 145 CT colonography examinations by participating in a study evaluating the performance of radiographers in CT colonography [11]. Interestingly observer 3 showed the lowest diagnostic performance during this study for both polyps  $\geq 6$  mm and  $\geq 10$  mm, underlining the important value of predefined training and experience.

Observers in this study had a variable level of expertise, however the required level of experience for MR colonography is not known. In CT colonography research there is increasing interest for the evaluation of interreader variability. Burling et al. [13] showed a high variability in individual reader performance and recommended that radiologists or radiographers are certified for CT colonography screening with predefined training and sufficient performance. Previously, training comprising a number of 40-50 cases validated by colonoscopy has been indicated to be sufficient to attain competence in CT colonography, though currently the actual number are not known and most likely are higher than 50 [13,14]. Taking into account the complexity of MRI interpretation and the moderate diagnostic outcomes in this study, one might suggest that the actual number of validated cases for training purposes must be substantially higher in MR colonography.

Besides variability in accuracy, a considerable overlap in individual performance was present between radiologists and radiographers regarding per-patient sensitivity. Radiographer 2 correctly identified seven out of the 10 patients with at least one polyp  $\geq 10$  mm, a comparable finding if compared to the combined sensitivity rate of the radiologist group at this polyp threshold. However, relatively high sensitivity was combined with a high number of false-positive patients which resulted in a moderate per-patient specificity. These high number of false-positive findings, as detected by the radiographers, were largely related to the ileocecal valve. Since ileocecal valves are a potential cause of false-positive findings on colonography [15], correct identification of the normal anatomical appearances rests on acquired experience, which was apparently insufficiently present in this group of observers.

In our study we used the 'bright-lumen' strategy, in which colonic

distension is obtained by the rectal administration of a gadolinium-based fluid mixture and results in a hyperintense colonic lumen on the T1-weighted images. This strategy selection was based on a prospective study in which three strategies of MR colonography were compared, which resulted in better outcomes regarding image quality and patient acceptance if compared to the dark lumen alternative [16]. However, in current literature 'dark lumen' MR colonography is frequently applied and an important strength of this approach is the intravenous administration of a paramagnetic contrast-agent which allows excellent differentiation between the hypo-intense colonic lumen and enhancing colonic wall. Moreover, evidence suggests that bright-lumen strategy is associated with relative more false-positive findings if compared to the dark lumen approach [17]. On the other hand, the faecal-tagging method which is often applied in the dark lumen variant is obtained by the oral administration of barium-based substances and results in a low patient acceptance [18].

The present study has recognized limitations. In this study only 20 polyps  $\geq 10$  mm were identified in a total of 10 patients during colonoscopy. As diagnostic accuracy is dependent on the population size being tested and influenced by the prevalence of the disease, one might suggest that our sensitivity rates are negatively affected by the relatively low-prevalence of clinical relevant polyps in our study (6.2%). However, in a recent MR colonography study a per-patient diagnostic value of 70% is reported for polyps  $\geq 10$  mm in a low-prevalence population (6.3%) [4]. These findings are comparable with the results of observers 2 and 4 in this study. Nevertheless, a more representative dataset for this first exploratory study would have been beneficial as, with only 10 patients with clinical significant polyps, the current statistical power is rather limited.

Furthermore, our reading protocol consisted of a two-dimensional (2D) assessment of the complete MR colonography datasets, as to date three-dimensional (3D) rendering (fly-through) of the data is hampered by technical limitations (e.g. field inhomogeneity). Previously mentioned CT colonography studies however implemented three-dimensional approaches for problem solving and for improving reader confidence [9,10]. Moreover, 3D endoluminal evaluation appears to have better outcomes than the initial 2D approach used in CT colonography, especially for novice observers [19]. The absence of a 3D endoluminal evaluation might therefore partly impede overall outcomes in this study.

Yet, MR colonography has not reached the stage of possible implementation as screening modality for CRC, and the precise diagnostic

application needs to be clarified. Amongst others no consensus has been reached regarding optimal type of bowel preparation with lowest patient burden, scan parameters and colonic distension method. In this study 88% (35/40) of the polyps  $\geq 6$  mm and 80% (17/20) of the polyps  $\geq 10$  mm, as found with colonoscopy, could be matched with a reference polyp on MR colonography. Therefore, diagnostic accuracy in this study is not substantially hampered by limitations regarding visualisation of colorectal lesions but primarily by errors in interpretation. Therefore, this study demonstrates that more research will have to be performed on the required level of expertise for reading MR colonography. For example, one might consider adopting a formal teaching program to novice readers and the application of a test to ensure baseline competency, similar as applied in the ESGAR consensus statement on CT colonography [20].

Our findings suggest comparable sensitivity in the detection of clinical relevant polyps between radiographers and radiologists using MR colonography in a low-prevalence population. However, significant differences in specificity values for both polyp size categories were observed between radiographers and radiologists. Prior experience with both colonography and MR imaging interpretation seems to favour diagnostic outcomes. In addition, training and experience beyond 40 MR colonography cases validated by colonoscopy seems mandatory for acceptable sensitivity and specificity rates, in particular for readers with no prior experience with colonography. Presently a potential beneficial effect, with regard to diagnostic accuracy, from the implementation of non-radiologists for double-interpretation purposes cannot be expected, but can only be adequately appreciated if conducted within a large prospective study.



## References

1. Ajaj W, Pelster G, Treichel U et al. (2003) Dark lumen magnetic resonance colonography: comparison with conventional colonoscopy for the detection of colorectal pathology. *Gut* 52:1738-43.
2. Florie J, Jensch S, Nievelstein RA et al. (2007) MR colonography with limited bowel preparation compared with optical colonoscopy in patients at increased risk for colorectal cancer. *Radiology* 243(1):122-31.
3. Hartmann D, Bassler B, Schilling D et al. (2006) Colorectal polyps: detection with dark-lumen MR colonography versus conventional colonoscopy. *Radiology* 238(1):143-149.
4. Kuehle CA, Langhorst J, Ladd SC et al. (2007) Magnetic resonance colonography without bowel cleansing: a prospective cross sectional study in a screening population. *Gut*. 56(8):1079-1085.
5. Johnson CD, Chen MH, Toledano AY et al. (2008) Accuracy of CT colonography for detection of large adenomas and cancers. *N Engl J Med*. 359(12):1207-17.
6. Kinner S, Lauenstein T. (2007) MR colonography. *Radiol Clin N Am* 45(2):377-387
7. Purkayastha S, Tekkis PP, Athanasiou T et al. (2005) Magnetic resonance colonography versus colonoscopy as a diagnostic investigation for colorectal cancer: a meta-analysis. *Clin Rad*. 60:980-989
8. Cotton PB, Durkalski VL, Pineau BC et al. (2004) Computed tomographic colonography (virtual colonoscopy): a multicenter comparison with standard colonoscopy for detection of colorectal neoplasia. *JAMA* 291(14):1713-1719.
9. Johnson CD, Harmsen WS, Wilson LA et al. (2003) Prospective blinded evaluation of computed tomographic colonography for screen detection of colorectal polyps. *Gastroenterology* 125:311-319.
10. Florie J, Jensch S, Nievelstein RA, et al. (2007) MR colonography with limited bowel preparation compared with optical colonoscopy in patients at increased risk for colorectal cancer. *Radiology* 243(1):122-31.
11. Jensch S, van Gelder RE, Florie J, et al. (2007) Performance of radiographers in the evaluation of CT colonographic images. *AJR Am J Roentgenol* 188(3):W249-55.
12. Bodily KD, Fletcher JG, Engelby T et al. (2005) Non radiologists as second readers for intraluminal findings at CT colonography. *Acad Rad* 12(1):67-73.
13. Burling D, Halligan S, Atchley J et al. (2007) CT colonography: interpretative performance in a non-academic environment. *Clin Rad* 62(5):424-429.
14. Soto JA, Barish MA, Yee J. (2005) Reader training in CT colonography: how much is enough? *Radiology*. 237(1):26-27.
15. Regge D, Gallo TM, Nieddu G et al. (2005) Ileocecal valve imaging on computed tomographic colonography. *Abdom Imaging* 30(1):20-25
16. Florie J, van Gelder RE, Haberkorn B et al. (2007) Magnetic resonance colonography with limited bowel preparation: a comparison of three strategies. *J Magn Reson Imaging*. 25(4):766-74
17. Lauenstein TC, Ajaj W, Kuehle CA, Goehde SC, Schlosser TW, Ruehm SG. (2005) Magnetic resonance colonography: comparison of contrast-enhanced three-dimensional vibe with two-dimensional FISP sequences: preliminary experience. *Invest Radiol*. 40(2):89-96.

## Chapter 4

---

18. Goehde SC, Descher E, Boekstegers A et al. (2005) Dark lumen MR colonography based on fecal tagging for detection of colorectal masses: accuracy and patient acceptance. *Abdom Imaging* 30(5):576-583.
19. de Vries AH, Liedenbaum MH, Bipat S, et al. (2009) Primary uncleaned 2D versus primary electronically cleansed 3D in limited bowel preparation CT-colonography Is there a difference for novices and experienced readers? *Eur Radiol* 19(8):1939-50.
20. Taylor SA, Laghi A, Lefere P, Halligan S, Stoker J. (2007) European Society of Gastrointestinal and Abdominal Radiology (ESGAR): consensus statement on CT colonography. *Eur Radiol.* 17(2):575-9.

# Chapter 5

## **Feasibility of Using Automated Insufflated Carbon Dioxide (CO<sub>2</sub>) for Luminal Distension in 3.0T MR colonography.**

*Eur J Radiol. 2011; accepted for publication*

*F.M.Zijta*

*A.J. Nederveen*

*S. Jensch*

*J. Florie*

*S. Bipat*

*M.P. van der Paardt*

*A.D. Montauban van Swijndregt*

*J. Stoker*

### Abstract

**Objective:** Primary aim of our study was to prospectively evaluate the feasibility of automated carbon dioxide (CO<sub>2</sub>) delivery as luminal distending agent in 3.0T MR colonography.

**Material and methods:** Rectally insufflated CO<sub>2</sub> was evaluated in four groups with different bowel preparation (A-D). Bowel preparation regimes were: gadolinium-based tagging (A), bowel purgation (B), barium-based tagging (C) and iodine-based tagging (D). Supine (3D)T1w-FFE and (2D)T2w-SSFSE series were acquired. Each colon was divided into six segments (cecum S1-rectum S6). Two observers independently assessed the presence of artefacts, diagnostic confidence and segmental colonic distension. Also characteristics of the residual stool (presence, composition and signal-intensity) were assessed per segment. Discomfort was assessed with questionnaires.

**Results:** Fourteen healthy subjects were included. Colonic distension by means of rectally insufflated CO<sub>2</sub> was not associated with susceptibility artefacts. Overall image quality was affected by the presence of bowel motion-related artefacts: none of the segments in 3DT1w-series and 10/84 (12%) colon segments in 2DT2w-series were rated artefact-free by both observers. Diagnostic confidence ratings were superior for the 2DT2w-SSFSE series. Overall bowel distension was rated adequate to optimal in 312/336 (93%) colon segments.

**Conclusion:** MR colonography at 3.0T using carbon dioxide (CO<sub>2</sub>) for colonic distension is technically feasible. The presence of intraluminal CO<sub>2</sub> did not result in susceptibility artefacts, although overall image quality was influenced by artefacts.

## Introduction

Magnetic resonance (MR) colonography has been increasingly studied as non-invasive diagnostic tool for the detection of colorectal neoplasia [1-3]. Important reason to study MR colonography is the lack of ionizing radiation exposure. Further, it has a wide spectrum of soft tissue contrast which allows for a diversity of bowel preparation methods. However, besides the limited availability and relatively higher costs, at present there is no established MR colonography method [4].

Colonic distension in MR colonography is predominantly achieved with the use of a water-based enema, although the rectal administration of water is reported as the most burdensome part of a MR colonography examination [5]. The use of carbon dioxide (CO<sub>2</sub>) or alternatively room air as luminal distending agent, as generally applied in CT-colonography, can be expected to decrease procedural discomfort. Furthermore, automated insufflation results in superior colonic distension, when compared with manual insufflation of a gaseous distending agent [6]. The potential presence of susceptibility artefacts at air /tissue interfaces is a potential disadvantage of the application of gaseous agents for luminal distension in MR colonography. However, recent developments allow data acquisition with short echo-times and therefore this limitation can be largely overcome. Still, current available studies using room-air for colonic distension in MR colonography demonstrate divergent outcomes regarding feasibility [7,8].

As high-field strength imaging is now widely available for clinical purpose, 3.0T MR imaging is used for MR colonography [9]. Several technical issues, including tissue T1 and T2 relaxation parameters, specific absorption rate (SAR), susceptibility and chemical shift effects differ distinctively from 1.5T [10] and this may affect the use of 3.0T for MR colonography. On the other hand, the gain in signal-to-noise ratio can be used to increase spatial resolution and decrease acquisition times [9].

In order to give direction towards a future more elaborate study, purpose of this study was to assess the feasibility of automated insufflated carbon dioxide as luminal distending agent in MR colonography at 3.0T, particularly regarding the presence of susceptibility artefacts. As dark-lumen MR colonography can be combined with several bowel preparation regimes, we additionally studied CO<sub>2</sub> insufflation in four different applied bowel preparation regimes in terms of image quality and burden.

### Materials and methods

#### *Subjects*

In this prospective feasibility study, volunteers without relevant medical history were consecutively recruited by public advertisement. Whereas this comprised a feasibility study, no power analysis was performed and for practical reasons sixteen volunteers were included. Exclusion criteria for this study were an age of less than 18 years or over 75 years, the inability to hold breath for 25 seconds, any suspicion of bowel perforation or obstruction in subjects' medical history and general contraindications to undergo MRI or bowel preparation. This study was approved by the institutional review board and all participants gave informed consent. No evaluation of colonic or extracolonic abnormalities was performed in these normal volunteers.

#### *Bowel preparation*

Each subject was randomly allocated to one of four different preparation groups: A, B, C and D (*Table 1*). All groups received a low-fibre diet starting three days before the MRI. In group A, subjects received 10mL Gadolinium (dimegluminegadopentetate 0.5 mml/ml (Magnevist; Schering, Berlin, Germany)) as oral contrast agent for faecal tagging with all major meals starting two days prior to the MR colonography, together with the ingestion of 12 grams lactulose (Lactulose CF powder 6g/sachet, Centrafarm, Etten-Leur, the Netherlands), once per day. Subjects in group B received 4 L polyethylene glycol electrolyte solution (KleanPrep; Helsinn Birex Pharmaceuticals, Dublin, Ireland), starting one day prior to the examination. In group C, subjects ingested 200mL 1 g/ml bariumsulfate (Micropaque, Guerbet, Aulnay-sous-Bois, France) three days prior to MR colonography with all major meals, together with a daily 12 g lactulose (Lactulose CF powder 6g/sachet). In addition subjects in group C were asked to avoid the consumption of high concentrations of manganese (e.g. chocolate), whereas this shortens T1 relaxation time and therefore potentially outweighing the darkening effect of bariumsulfate. In group D, subjects ingested a high-osmolar ionic monomer contrast agent (meglumine-ioxithalamate, 300 mg I/ml, Telebrix Gastro; Guerbert, Cedex, France); an analogous bowel preparation regime as recently proposed for CT-colonography [11]. One day prior to MR colonography examination, 50mL Telebrix was taken with all three major meals. A final 50mL was taken 1.5h before MR colonography.

*MR colonography*

MR colonography in supine position was performed at 3.0T (Intera, Philips Healthcare, Best, the Netherlands). A 16-channel phased-array surface coil (SENSE-XL-Torso) for signal reception was used and data was acquired with two data-stacks using software-controlled table movement (*Figure 1*). The automated table movement takes less than 30 seconds. Prior to data acquisition, the colon was automatically insufflated with CO<sub>2</sub> gas via a balloon-tipped flexible rectal catheter (20 French Gauge) with long tubing, using an automated insufflator outside the MRI suite (Bracco, PROTOCO2L insufflator, New York, USA). While currently used automated insufflators are not MRI compatible, we extended the tube to insufflate CO<sub>2</sub> to approximately 7m, in order to cover the distance between the automatic device and subject. The extended insufflation system was tested as a closed system, in order to test the maximum rectal pressure shutdown and to prevent for any pressure drop.

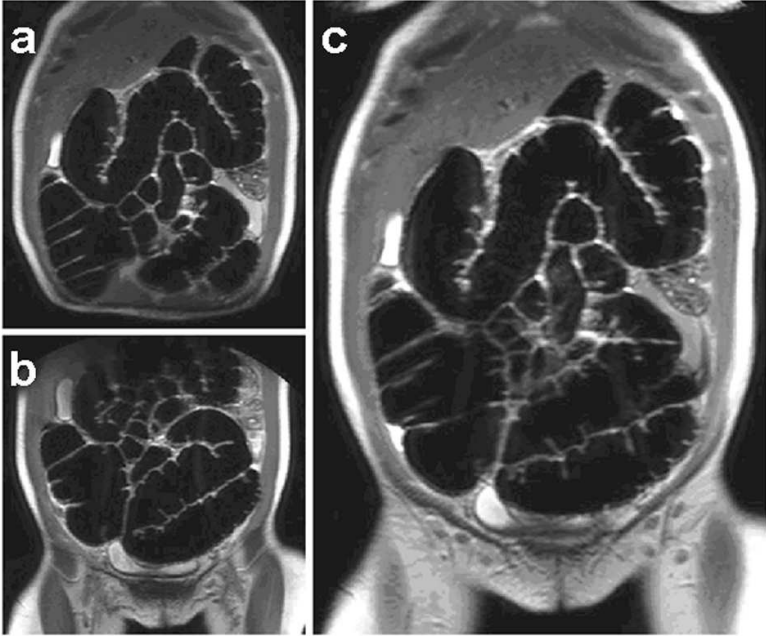
**Table 1.** Characteristics on bowel preparations for each of the four different MR colonography approaches. Rows describe type of bowel preparation for each approach.

groups	Bowel preparation			Bowel distension
	A (n=4)	Low-fibre diet	Lactulose	Gadolinium
B (n=4)	Low-fibre diet	Polyethylene glycol electrolyte solution		Carbon- dioxide (CO <sub>2</sub> )
C (n=3)	Low-fibre diet	Lactulose	Barium-sulphate	Carbon- dioxide (CO <sub>2</sub> )
D (n=3)	Low-fibre diet	Telebrix		Carbon- dioxide (CO <sub>2</sub> )

Controlled insufflation was started with the subject in a right lateral position, supine position, followed by a left lateral position and the subject then gradually turned to the supine position. The automated system was left active during the total examination. Data acquisition was started when approximately 3 l of CO<sub>2</sub> was insufflated into the colon. The maximum insufflation pressure was set at 20 mm Hg throughout the complete procedure which was reached by gradual increase of the insufflation pressure. The pressure was decreased if subjects reported pain or felt uncomfortable.

A smooth muscle relaxant (Buscopan; Boehringer-Ingelheim, Ingelheim, Germany or when contraindicated Glucagen; Novo-Nordisk, Bagsvaerd, Denmark) was administered intravenously before insufflation and prior to the 2D/3D data acquisition, 20 mg in total. No intravenous paramagnetic contrast agent was administered. Examinations were performed in supine position.

Three-dimensional (3D) fat suppressed fast T1-weighted spoiled gradient-echo (fast field echo (FFE)) and two-dimensional (2D) T2-weighted (single-shot fast spin echo (SSFSE)) series were acquired in the coronal plane. Scan parameters were: 3DT1w-FFE: TR/TE 2.12/1.01 ms; FA 10°; No. of slices 90; FOV 540mm x 400mm; voxel 2.00mm x 2.00mm x 2.00mm; 2DT2w-SSFSE: TR/TE 475/60 ms; FA 90°; No. of slices 45; FOV 540mm x 400mm, parallel imaging factor (SENSE) 2, voxel: 2.00mm x 2.00mm x 3.00mm; slice gap 0; interleaved scan order. Breath hold was at maximum 18 seconds per data-stack. The refocusing angle (RA) of the 2DT2w-SSFSE was adjusted to 120° in order to prevent exceeding the Specific Absorption Rate (SAR) limit at 3.0T. The examination was limited to these sequences in supine position only, as the primary aim was to evaluate the presence of susceptibility artefacts.



**Figure 1.** 2D-T2w Single-Shot Fast Spin Echo (SSFSE) of a 51-year old normal healthy female volunteer after the insufflation of CO<sub>2</sub> as negative luminal distending agent showing adequate overall colonic distension. Coverage of the entire colon included the acquisition of two linked image-stacks of the upper abdomen (a) and lower abdomen (b) using software-controlled table movement. For non-diagnostic purpose, the separate stacks can be fused into one image using the MR imaging system post-processing software (*MobiView, Philips Healthcare*) (c).



### *Data analysis*

All data-stacks were separately analyzed on a dedicated post-processing workstation (View Forum, Philips Healthcare) by two observers, who were instructed to critically analyze the data-stacks and were blinded for the type of applied bowel preparation. Observer 1 (SJ), an abdominal radiologist, with a prior experience of >250 CT-colonography examinations and >250 MR colonography examinations [1]. The second observer (JF), a fourth-year resident in radiology, had evaluated over >600 CT-colonography examinations with colonoscopy verification and matched >120 CT-colonography and >250 MR colonography examinations with colonoscopy in previous studies [1, 12]. For evaluation purposes the colon was divided in six colon segments: cecum (S1), ascending colon (S2), transverse colon (S3), descending colon (S4), sigmoid colon (S5) and rectum (S6).

Both observers scored image quality regarding presence of (*susceptibility artefacts* (3-point scale: 1 = absent; 2 = present; 3 = present and influencing evaluation) and *diagnostic confidence* (3-point scale: 1 = non-diagnostic, polyps  $\geq$  10 mm could be missed when it would concern a symptomatic patient or screening, 2 = diagnostic, only for polyps  $\geq$  10 mm, 3 = diagnostic, for polyps  $\geq$  6 mm) of both 3DT1w and 2DT2w series. *Bowel-distension* (3-point scale: 1 = optimal, 2 = adequate, 3 = poor) of both series was scored and outcomes were combined. An additional assessment was performed in order to discriminate between the presence of susceptibility artefacts and other artefacts.

Although the study was not primarily intended for evaluating bowel preparation schemes, the residual stool was evaluated for *presence* (4-point scale: 1 = 0-25%, 2 = 25-50%, 3 = 50-75%, 4 = 75-100%), *composition* (3-point scale: 1=liquid; 2=combined liquid/solid, 3=solid) and *signal intensity* (3-point scale: 1= low, 2= intermediate, 3= high signal intensity) in both sequences.

### *Questionnaires*

Participants were asked to complete two questionnaires (based on previous questionnaires for MR colonography [5]). Both questionnaires evaluated the discomfort (5-point Likert scale: not, mild, adequate, severe and extreme); one questionnaire prior to MR colonography evaluated the discomfort of the bowel preparation. The second questionnaire was completed after MR colonography. Additionally, subjects were asked what they considered the most burdensome aspect of the examination.

### *Statistical analysis*

We used descriptive statistical analysis to evaluate study group characteristics, image quality and subject acceptance. Continuous data were expressed as mean $\pm$ SD, and dichotomized data as number and percentage. Ordinal data were also expressed as mean $\pm$ SD. In addition, each observation (multiple ratings per observer and per sequence), was considered as independent, and therefore per-segment outcomes consist of ratings for both observers and sequences. The total included number of subjects was too small for statistical assessment of inter-group and inter-observer differences.

## **Results**

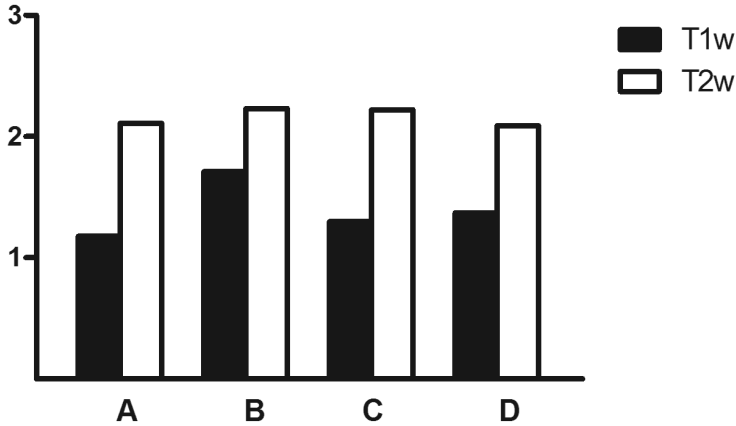
### *Subjects*

Between January 6, 2009, and June 6, 2009, sixteen subjects provided written informed consent. Two subjects were unable to complete the MR colonography examination, data from fourteen subjects were available for study analysis (mean age 40.1 years  $\pm$  15.5 (standard deviation), range 18.5 - 67.7 years; M:F 8:6). Total insufflated CO<sub>2</sub> volume was 5.2 (SD $\pm$ 1.1)L.

### *Artefacts and diagnostic confidence*

No susceptibility effects were identified on both sequences. 3DT1w series were substantially more prone to artefacts than the 2DT2w series and were attributed to the presence of bowel motion. Observer 1 detected artefacts which influenced evaluation in 62 / 84 (74%) of the available colon segments on 3DT1w series, and in 27 / 84 (32%) of the segments on 2DT2w series. Observer 1 rated 6 / 84 (7%) and 17 / 84 (20%) of the segments as completely artefacts-free on 3DT1w and 2DT2w series, respectively.

Similar ratings were obtained from observer 2, detecting artefacts influencing evaluation in 60/84(71%) of the available colon segments on 3DT1w-series, and in 32 / 84 (38%) of the segments on corresponding 2DT2w series. No segments on 3DT1w series were rated as artifact-free by the second observer compared with 22 / 84 (26%) segments on 2DT2w series. None of the colon segments were rated artifact free on 3DT1w series, 10 / 84 (12%) of the colon segments were rated artifact free on 2DT2w series by both observers. Diagnostic confidence ratings for each of the different MR colonography approaches showed most favorable results for 2DT2w series (*Figure 2*).



**Figure 2.** Diagnostic confidence was estimated on presence of artefacts, quality of bowel distension and subjective ability to differentiate bowel wall from the colonic lumen. Ratings on diagnostic confidence regarding 3DT1w and 2DT2w series combined for both observers and are stratified for each of the four different groups and combined for all colonic segments.

(3-point scale: 1= non-diagnostic; polyps  $\geq 10$  mm could be missed when it would concern a symptomatic patient or screening; 2= diagnostic, polyps 6 - 9mm could be missed; 3 = diagnostic, polyps  $\geq 6$  mm might be visible).

### *Bowel distension*

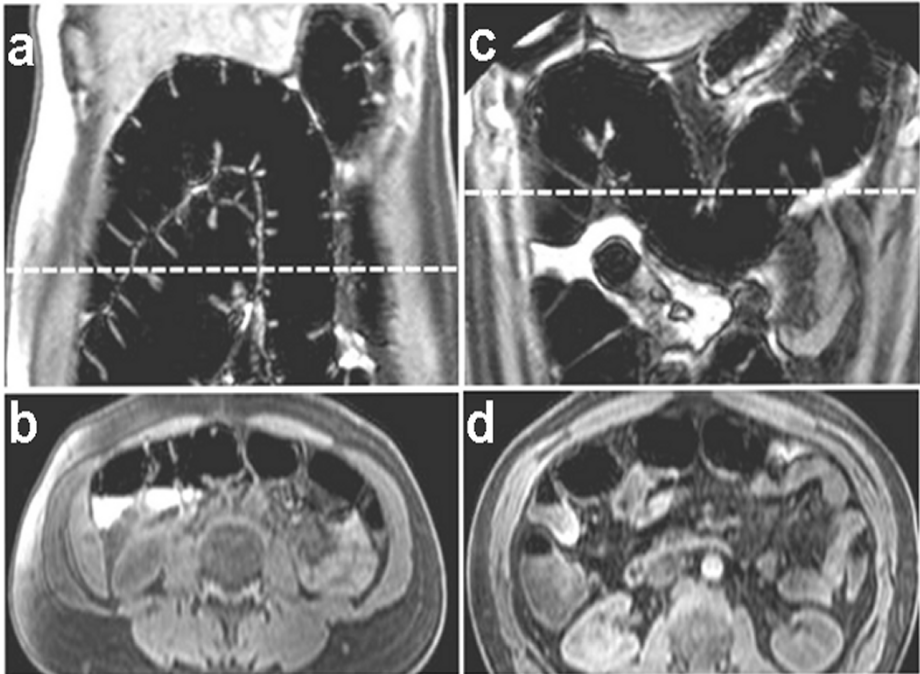
Overall distribution of distension showed adequate to optimal distension in 312/336 (93%) of the colon segments. In 12/336 (4%) segmental distension was poor. In three subjects the rectum was insufficiently visualized for proper analysis. Mean segmental bowel distension scores were distributed as follows: 1.2 (S1); 1.3 (S2); 1.3 (S3); 1.8 (S4); 1.9 (S5) and 1.3 (S6) with lower numbers indicating better distension (1.0 is optimal).

Evaluating the individual segments, the descending colon (S4) accounted for the highest number of poorly distended segments (n=6; 50%), followed by the sigmoid colon (S5) and rectum (S6) (both n = 3, 25%). No perceptible differences were observed in distension ratings between both sequences.

### *Presence, composition and signal intensity of residual stool*

The total amount of residual stool visible on 3DT1w series was lowest in groups B and D (1.3 and 1.2 respectively) (Table 2). Stool composition was rated as homogeneously liquid in all subjects of group D (mean value of 1.0) and relatively liquid in group B (mean value of 1.5) (Figure 3). In subjects receiving a barium-

based bowel preparation, the residual stool showed relatively high signal intensity on the 3DT1w series (mean 2.6).

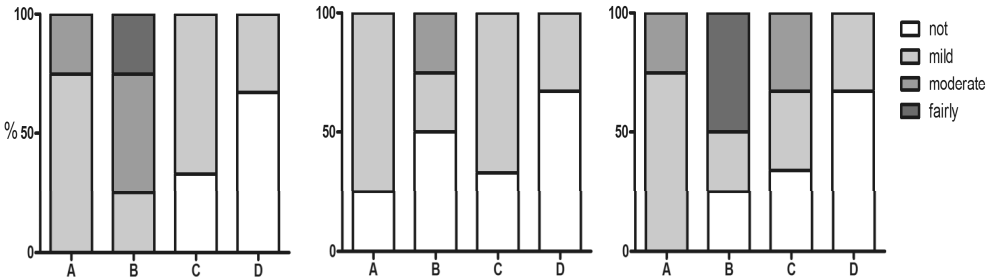


**Figure 3.** Coronal 3D fat suppressed T1w-FFE without susceptibility artefacts, in a subject receiving polyethylene glycol electrolyte solution for bowel preparation and CO<sub>2</sub> for colonic distension (group B) (a). Multiplanar reconstruction (MPR) allows the reconstruction of a transverse image showing a small amount of liquid stool with a relatively high signal intensity as compared to adjacent structures (b). Subject receiving iodine-based contrast agent for bowel preparation and CO<sub>2</sub> for colonic distension (group D) (c), showing liquid stool with intermediate signal intensity in the proximal colon on corresponding (dotted line) reconstructed transverse image (d).

*Discomfort score*

None of the participants rated the bowel preparation extremely burdensome regardless of preparation (Figure 4). Comparing the discomfort caused by the bowel preparation, MRI-examination including CO<sub>2</sub> insufflation and preparation plus MRI-examination combined, the type of bowel preparation mainly determined the overall experienced burden during the MR colonography examination in all four groups. The most burdensome aspect of the complete

examination for groups A - D combined was the execution of breath-holds (4/14 participants) during the MR examination.



**Figure 4.** Discomfort scores sorted for each of the four different groups (A - D) regarding the burden of bowel preparation (a), of the MRI examination (b) and of both bowel preparation and MR colonography combined (c).

## Discussion

In this feasibility study, evaluating the use of automated insufflation of carbon-dioxide (CO<sub>2</sub>) for luminal distension in 3.0T MR colonography, we found no susceptibility artefacts on either 3DT1w or 2DT2w series. Overall adequate to optimal colonic distension was found. The diagnostic confidence was inferior for 3DT1w series as compared to the 2DT2w series, which was most likely related to the presence of bowel motion related artefacts.

Until now, concerns regarding the presence of susceptibility artefacts using gaseous distending media in MR colonography favoured the use of water-based distending agents. Only a few studies on a small number of patients have studied the use of gaseous agents for luminal distension in MR colonography, either by manually inflated room air [7,8,12,13,14] or by manually inflated CO<sub>2</sub> [15]. In a comparative study, Ajaj et al. reported a higher CNR and better colonic distension using manually inflated air for colonic distension, if compared to the use of conventional water-based colonic distension in 50 patients at increased risk for CRC [7]. Importantly, the presence of air in the colonic lumen was not associated with susceptibility effects. In a comparable study-design, 83 patients at increased risk for CRC underwent MR colonography using either water or air for colonic distension [8]. Air distension evidently proved inferior to water-based distension in most quality aspects. The artefacts as observed in the air-based distension group were largely attributable to susceptibility effects. The discordant findings between these two studies can be explained by the substantial difference

**Table 2.** Ratings for amount, composition and signal intensity of residual stool for each different bowel preparation (A-D) per segment (S1-S6).

	3D-T1w FFE						2D-T2w SSFSE							
	S1	S2	S3	S4	S5	S6	Mean	S1	S2	S3	S4	S5	S6	Mean
<b>Amount</b>														
Group A	2.0	1.5	1.3	1.6	1.3	1.2	1.5	1.0	1.0	1.0	1.0	1.0	1.0	1.0
Group B	1.3	1.4	1.3	1.3	1.2	1.0	1.3	1.3	1.0	1.0	1.0	1.0	1.0	1.0
Group C	2.0	1.8	1.7	1.8	1.3	1.0	1.6	1.3	1.0	1.0	1.0	1.0	1.0	1.1
Group D	1.2	1.6	1.0	1.4	1.0	1.0	1.2	2.2	1.5	1.0	2.0	1.3	1.7	1.6
<b>Composition</b>														
Group A	2.0	2.0	2.1	2.3	2.4	2.8	2.3	0,0	0,0	0,0	0,0	0,0	0,0	0,0 <sup>a</sup>
Group B	1.5	1.5	1.5	1.5	1.5	1.5	1.5	1.0	1.0	1.0	1.0	1.5	1.0	1.8
Group C	2.3	2.3	2.3	2.7	2.7	2.6	2.5	2.4	2.8	2.8	2.8	2.8	2.8	2.7
Group D	1.0	1.0	1.0	1.0	1.0	1.0	1.0	1.0	1.0	1.3	1.3	1.5	1.0	1.2
<b>Signal Intensity</b>														
Group A	2.9	2.9	2.8	2.5	2.7	2.8	2.8	1.0	1.0	1.0	1.0	1.0	1.0	1.0
Group B	2.8	2.7	2.3	2.3	2.3	2.4	2.5	3.0	3.0	3.0	3.0	2.0	3.0	2.8
Group C	2.7	2.7	2.7	2.7	2.7	2.2	2.6	2.0	2.0	2.0	2.0	2.0	2.0	2.0
Group D	2.0	2.5	2.0	2.5	2.0	2.0	2.2	2.6	2.6	2.6	2.6	2.7	2.7	2.6

<sup>a</sup> Unable to characterize; Mean = mean value of available segments

in applied echo sequence parameters. In our study the use of 3.0T imaging allowed the use of fast imaging sequences with a short echo-time (TE), which is a similar TE as applied by Ajaj et al. [7]. The use of such short echo-times practically excludes the presence of artefacts at the interface between luminal gas and soft tissue colonic wall.

Insufflation of CO<sub>2</sub> is considered preferable to room air because of the better absorption and consequently less post-procedural discomfort. Its use has been propagated in a current consensus statement of CT colonography [16]. Yet, the rapid absorption of CO<sub>2</sub> by the bowel wall, might lead to varying colonic distension in a prolonged data-acquisition setting, like MR colonography [7]. By the use of continuous automated CO<sub>2</sub> insufflation, we were able to avoid a potential decrease in distension during data-acquisition. To our knowledge this is the first study which describes the use of automated insufflation of CO<sub>2</sub> for luminal distension in MR colonography.

A number of different bowel preparation methods have been proposed in MR colonography [4]. Dark lumen strategies generally use barium-based approaches as oral tagging agent, although its use in air-based distending methods is reported to result in inferior image quality [8,12]. We hypothesized that the oral ingestion of gadolinium together with the ingestion of a stool softener (group A), would result in fluid tagged stool with luminal contrast ratios similar to CT colonography. However, comparable to the barium-based approach (group C), the gadolinium-based approach resulted in relatively high-signal intense sticky residual faeces throughout the colon.

On 3DT1w series, residual stool was observed in all four bowel-preparation approaches with the smallest liquid volumes scored in groups B and D. In group D, the bowel content was liquid by the laxative effect of the iodine and rated as having slightly lower signal intensity when compared to other preparation methods. Moreover, the amount of total residual faecal material was relatively small, which is in concordance to the findings as recently reported for CT-colonography [11].

This feasibility study has recognized limitations. Firstly, the total number of included subjects was small and therefore the qualitative results are too small to study statistical significant differences between observations. Yet, the current study was primarily aimed to assess feasibility of using CO<sub>2</sub> for colonic distension in MR colonography, in order to give direction towards a future more elaborate clinical study. Thence only supine datasets were acquired as we primarily focused on technical feasibility. This will ultimately have influenced current study results since double position scanning, as routinely applied in colonography, is mandatory for sufficient distension [17]. Also, this may have ultimately influenced the burden of participants.

In dark lumen MR colonography, intravenous administration of paramagnetic contrast agent is used in order to improve the contrast between the low intense colonic lumen and colonic wall. Nonetheless, this study was performed in normal healthy volunteers and in order to prevent any gadolinium side effects, we did not use intravenous contrast agent. Consequently, the subjective image quality ratings including the diagnostic confidence, as scored by both observers, will ultimately differ when compared to a diagnostic setting with colonic wall enhancement. Among others this will differ due to post-processing automatic scaling. It also prevents a practical objective evaluation (contrast-to-noise ratio, CNR) of image quality on the T1-weighted series [7,18].

In our study, a spasmolytic agent for both optimizing bowel distension and minimizing bowel motion was administered intravenously in two aliquots, prior to the rectal filling process and 2D/3D data-acquisition. However, the second injection was not performed directly prior to the 3DT1w data-acquisition and in addition, 3D data-acquisition was rather lengthened with the use of software-controlled table movement. When taking into account the relatively short half-life of the administered spasmolytic agent, these issues might largely explain the presence of bowel motion artefacts as observed in the fast gradient echo series. In addition, data acquisition was performed with an active insufflation system and it is indefinable whether continuous pumping during data acquisition has been a source of the perceptible motion artefacts. Besides the injection timing, either increasing the total dosage of spasmolytic agent or the intramuscular administration of N-butylscopolamine for minimizing peristalsis can be considered [19].

In conclusion, this study demonstrates that MR colonography using automated insufflation of CO<sub>2</sub> for colonic distension, similar as currently applied in CT colonography, is technically feasible and is not associated with susceptibility artefacts. Nonetheless, in this study image quality was substantially impaired by motion artefacts, therefore refining the protocol regarding certain essential aspects (e.g. impact of spasmolytic agents) is necessary in order to make this technique applicable in a clinical setting. Future prospective clinical studies are warranted in order to determine the exact diagnostic performance and acceptance of this technique in MR colonography.



---

## References

1. Florie J, Jensch S, Nievelstein RA et al. (2007) MR colonography with limited bowel preparation compared with optical colonoscopy in patients at increased risk for colorectal cancer. *Radiology*.243(1):122-31.
2. Kuehle CA, Langhorst J, Ladd SC, et al. (2007) Magnetic resonance colonography without bowel cleansing: a prospective cross sectional study in a screening population. *Gut* 56(8):1079-1085.
3. Hartmann D, Bassler B, Schilling D, et al. (2006) Colorectal polyps: detection with dark-lumen MR-colonography versus conventional colonoscopy. *Radiology* 238(1):143-149.
4. Zijta FM, Bipat S, Stoker J. (2010) Magnetic resonance (MR) colonography in the detection of colorectal lesions: a systematic review of prospective studies. *Eur Radiol*. 20(5):1031-1046.
5. Florie J, Birnie E, van Gelder RE et al. (2007) MR colonography with limited bowel preparation: patient acceptance compared with that of full-preparation colonoscopy. *Radiology* 245(1):150-9.
6. Burling D, Taylor SA, Halligan S et al. (2006) Automated insufflation of carbon dioxide for MDCT colonography: distension and patient experience compared with manual insufflation. *AJR Am J Roentgenol*. 186(1):96-103.
7. Ajaj W, Lauenstein TC, Pelster G, Goehde SC, Debatin JF, Ruehm SG. (2004) MR-colonography: how does air compare to water for colonic distention? *J Magn Reson Imaging*. 19:216-221.
8. Rodriguez Gomez S, Pagés Llinas M, Castells Garangou A, et al. (2008) Dark-lumen MR-colonography with fecal tagging: a comparison of water enema and air methods of colonic distension for detecting colonic neoplasms. *Eur Radiol* 18(7):1396-1405.
9. Lauenstein TC, Saar B, Martin DR. (2007) MR colonography: 1.5T versus 3T. *Magn Reson Imaging Clin N Am*. 15[3]:395-402, vii.
10. Erturk SM, Alberich-Bayarri A, Herrmann KA, Marti-Bonmati L, Ros PR. (2009) Use of 3.0-T MR imaging for evaluation of the abdomen. *Radiographics* 29[6]:1547-1563.
11. Liedenbaum MH, de Vries AH, Gouw CI, et al. (2010) CT-colonography with minimal bowel preparation: evaluation of tagging quality, patient acceptance and diagnostic accuracy in two iodine-based preparation schemes. *Eur Radiol*. 20(2):367-376.
12. Florie J, van Gelder RE, Haberkorn B et al. (2007) Magnetic resonance colonography with limited bowel preparation: a comparison of three strategies. *J Magn Reson Imaging*. 25(4):766-74.
13. Lam WWM, Leung WK, Wu JKL, So NMC, Sung JY. (2004) Screening of colonic tumors by air – inflated magnetic resonance (MR) colonography. *J Magn Reson Imaging* 19:447 – 452.
14. Keeling AN, Morrin MM, McKenzie C et al. (2010) Intravenous, contrast-enhanced MR colonography using air as endoluminal contrast agent: Impact on colorectal polyp detection. *Eur J Radiol*. PMID: 21131152
15. Lomas DJ, Sood RR, Graves MJ, Miller R, Hall NR, Dixon AK. (2001) Colon carcinoma: MR imaging with CO<sub>2</sub> enema--pilot study. *Radiology*;219(2):558-562.

16. Taylor SA, Laghi A, Lefere P, Halligan S, Stoker J. (2007) European Society of Gastrointestinal and Abdominal Radiology (ESGAR): consensus statement on CT-colonography. *Eur Radiol.* 17(2):575-579.
17. Morrin MM, Farrell RJ, Keogan MT, Kruskal JB, Yam CS, Raptopoulos V. (2002) CT-colonography: colonic distention improved by dual positioning but not intravenous glucagon. *Eur Radiol.* 12:525-530
18. Achiam MP, Chabanova E, Løgager VB, Andersen LP, Thomsen HS, Rosenberg J. (2008) MR-colonography with fecal tagging: barium vs. barium ferumoxsil. *Acad Radiol.* 15(5):576-83
19. Wagner M, Klessen C, Rief M et al. (2008) High-resolution T2-weighted abdominal magnetic resonance imaging using respiratory triggering: impact of butylscopolamine on image quality. *Acta Radiol.* 49(4):376-82.

# Part II

## MRI of the pelvic floor





# Chapter 6

## **Dynamic Magnetic Resonance Imaging to Quantify Pelvic Organ Prolapse; Reliability of Assessment and Correlation with Clinical Findings and Pelvic Floor Symptoms.**

*Submitted*  
*M.M.E. Lakeman*  
*F.M. Zijta*  
*J. Peringa*  
*A.J. Nederveen*  
*J. Stoker*  
*J.P.W.R. Roovers*

### Abstract

**Objective:** The aim of this study is first, to assess the inter-observer agreement of staging pelvic organ prolapse (POP) using MRI. Second; to correlate MRI-based POP assessment with POP-Q. Third, to evaluate whether MRI staging or POP-Q staging of prolapse correlates well with pelvic floor symptoms.

**Material and methods:** In this cross-sectional study we included 10 patients with pelvic floor symptoms and stage 2 or more POP, 10 patients with pelvic floor symptoms but stage 1 or less POP and 10 nulliparous women without POP or pelvic floor symptoms. All women underwent dynamic MRI and completed validated disease specific questionnaires. Three different observers assessed POP on MRI using four different reference lines: pubo-coccygeal line (PCL), mid-pubic line (MPL), perineal line and the H-line.

**Results:** The intra-class correlation coefficient for all four reference lines was good to excellent when assessing prolapse of the anterior and middle compartment. Correlation of dynamic MRI with POP-Q in the prolapse group was good in the anterior and middle compartment using the perineal line and in the posterior compartment using the PCL and H-line. In the control group a good correlation was found only in the posterior compartment using the MPL line. The correlation of MRI-based staging and POP-Q with pelvic floor symptoms was poor to moderate.

**Conclusion:** The inter-observer agreement of MRI-based POP staging was excellent independent of the reference line used. The correlation between MRI-based staging and POP-Q staging is moderate and, like POP-Q assessment, MRI-based staging of POP has an unsatisfying correlation with pelvic floor symptoms.

## Introduction

Pelvic organ prolapse (POP) is a very common condition affecting about 30% of women over 40 years old [1,2]. Pelvic organ prolapse can be associated with micturition, defecation symptoms and also with sexual dysfunction. If symptoms are severe and conservative methods have failed, surgical correction of the prolapse is indicated. However, the main dilemma of surgical correction is the high recurrence rate, which for some procedures is stated to be as high as 50% [3,4]. Also after surgery both persisting and de-novo pelvic floor symptoms may still lead to impaired pelvic floor function [5]. Therefore, careful evaluation from the anatomic abnormalities involved in the prolapse is mandatory, to make the correct and complete diagnosis and hereby indicate the right treatment.

Currently the most commonly used method for prolapse staging is the Pelvic Organ Prolapse Quantification (POP-Q) as recommended by the International Continence Society (ICS) , which is scored during physical examination [6]. Imaging of the pelvic floor might provide important additional anatomical information since it not only assesses what can be seen on the outside but also the internal relationship of the pelvic organs. Several imaging techniques have been proposed in addition to the physical examination findings. Using dynamic Magnetic Resonance Imaging (MRI), the maximal descent of the three compartments and their mutual relationships can be viewed during rest and maximal straining [7].

In current available literature several reference lines have been proposed to assess pelvic organ prolapse during dynamic MRI, however appropriate validation of these reference lines is lacking [7]. Furthermore the inter-observer variability of the method and information whether the level of experience of observers affects the assessment are largely unknown.

Since the most commonly used method in staging POP is POP-Q staging (ICS), POP staging using dynamic MRI should be correlated with POP-Q staging [8].

Besides the high recurrence rate, also a high rate of persisting and de novo pelvic floor symptoms is seen after prolapse surgery. A problem in the treatment of these symptoms is that the correlation between anatomical findings on physical examination and pelvic floor symptoms has been reported to be weak [9,10]. By using dynamic MRI, all three compartments and their mutual relationships can be assessed. Consequently, one might expect improved correlation of pelvic floor symptoms to anatomical abnormalities.

The aim of our study was threefold. First to evaluate the reliability of the most commonly proposed reference lines in prolapse staging, as assessed in women with - and without POP by three different observers with different levels of experience. Second, to correlate POP as assessed on dynamic MRI with POP as assessed using POP-Q and third to evaluate whether MRI staging or POP-Q staging of prolapse correlates well with pelvic floor symptoms.

### **Materials and Methods**

This prospective study was performed in the AMC Amsterdam, from January 5<sup>th</sup> 2010 to December 8<sup>th</sup> 2010. After approval of the medical ethics committee, three groups of ten women were included in this study. The first group consisted of women with pelvic floor symptoms and at least stage 2 pelvic organ prolapse (POP) as assessed with POP-Q staging. The second group consisted of age matched controls with bothersome pelvic floor symptoms but maximum stage 1 pelvic organ prolapse. The third group consisted of nulliparous women without any known anatomical or functional pelvic floor abnormalities. All women gave written informed consent. All women underwent physical examination, dynamic MRI and filled out a questionnaire.

#### *Physical examination*

To assess pelvic organ prolapse, all women underwent a pelvic examination during which prolapse was staged using the Pelvic Organ Prolapse Quantification (POP-Q), according to the recommendations of the ICS [6]. Staging of the prolapse was performed at maximal straining in the 45° supine position. For the correlation between POP-Q findings and MRI findings used the most descending point in every compartment (i.e. anterior point Ba, middle compartment point C and posterior point Bp).

#### *Questionnaires*

To assess the presence and discomfort of prolapse symptoms, micturition or defecation symptoms, women were asked to complete a validated questionnaire. This questionnaire consisted of the following items: the Urogenital Distress Inventory (UDI), the Defecation Distress Inventory (DDI) and the Incontinence Impact Questionnaire (IIQ). The UDI consists of 19 items to assess the presence and the amount of bother of micturition or prolapse symptoms [11, 12]. The DDI consists of 15 items to assess the presence and amount of bother of defecation symptoms [13]. Every item consists of two parts: whether a symptom is present



or not, and the extent of both the woman experiences from that symptom. The latter is measured on a four-point Likert scale ranging from 'not at all' to 'greatly bothered'. The questionnaire also contained a few questions on BMI, parity, mode of delivery and previous gynaecological surgery.

### *Image acquisition*

Each woman underwent MRI in the supine position with the legs parallel, lightly flexed using a 3.0T MR-scanner (Intera, Philips Healthcare, Best, the Netherlands) with a 16-channel phased-array surface coil (SENSE-XL-Torso, Philips Healthcare) centred low on the pelvis, for signal reception. No intravenous contrast was administered, nor any contrast was administered in the bladder, urethra, vagina or rectum. Subjects were asked to empty the bladder 1 hour prior to the examination. Static MR imaging for anatomical reference was based on the acquisition of a multishot turbo spin echo (TSE) T2-weighted sequence in axial, coronal and sagittal planes (field-of-view (FOV): 300 x 300 mm<sup>2</sup>, slice thickness: 4 mm, no. of slices 31, slice gap: 0.4mm, TR/TE: 3021/80 ms, in plane resolution of 1.0 x 1.0 mm<sup>2</sup>). Dynamic MR imaging of the pelvis was performed using a (half Fourier acquisition single shot turbo spin echo) HASTE sequence in the mid sagittal plane (FOV: 300 x 300 mm<sup>2</sup>, slice thickness: 3 mm, TR/TE: 2000/75 ms, in-plane resolution of 1.6 x 1.6 mm<sup>2</sup>). Images were obtained at rest, and during both maximal contraction of the pelvic floor muscles and maximal straining (Valsalva manoeuvre). Instructions were given by the technologist prior to each separate series. This procedure was repeated to acquire most optimal patient compliance, regarding individual contraction and straining outcomes.

### *Data analysis*

The obtained images were evaluated offline by three observers; one radiologist (JP) with 8 years of experience in abdominal radiology, one fourth year radiology resident (FZ) and one researcher (ML) with no experience in radiology. The images were analyzed both qualitatively and quantitatively using the following reference lines which are also shown in *Figure 1*:

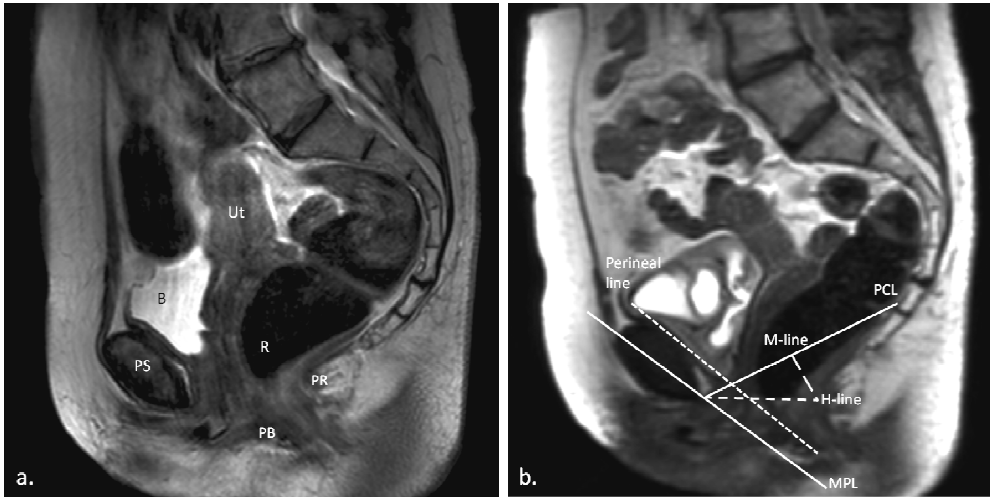
- The *pubo-coccygeal line* (PCL) is defined as a straight line between the inferior rim of the pubic bone and the anterior side of the last visible coccygeal joint [14-17].
- The *H-line* concerns a straight line between the inferior rim of the pubic and the posterior wall of the anal canal on the level of the impression of the puborectal sling [14, 15].

- The *perineal line* is a line from the internal surface of the symphysis pubis down to the caudal end of the external anal sphincter [18].
- The *mid-pubic line* (MPL) is a line drawn through the longitudinal axis of the pubic bone, passing through its mid-equatorial point [18, 19].

Three different pelvic compartments can be identified based on characteristic anatomical landmarks:

- the most postero-caudal point of the bladder base (anterior compartment),
- the most antero-caudal point of the cervix or the vaginal vault (middle compartment)
- the most anterior-caudal point of the anterior rectal wall (posterior compartment).

The perpendicular distance from the different reference lines to these three different points were assessed. If the anatomical landmark is located above a reference line, the distance had a negative value; below the reference line is a positive value.



**Figure 1.** Static T2-weighted turbo spin echo (TSE) for anatomical reference in midsagittal plane through the pelvis of a 66-year old woman with symptoms of pelvic organ prolapse, at rest. The uterus (Ut), Bladder (B), pubic symphysis (PS), rectum (R), puborectal muscle (PR) and perineal body (PB) are shown (a). Dynamic midsagittal half Fourier acquisition single shot turbo spin echo (HASTE) sequence during straining, in the same patient. The used reference lines, *pubo-coccygeal line* (PCL), *H-line*, *perineal line*, *mid-pubic line* (MPL) and *M-line* are shown (b).

*Statistical analysis*

Inter-observer reliability of the three observers was assessed by calculating the intra-class correlation coefficient (ICC) for all four different reference lines in the three different compartments. An ICC of more than 0.8 indicates excellent agreement, between 0.8 and 0.6 good agreement, between 0.6 and 0.4 moderate agreement, and below 0.4 indicates a poor agreement [20]. We used Spearman's rank correlation to correlate POP-Q measurements of the control group and the POP group with POP as assessed during dynamic MRI using the four different reference lines.

**Table 1.** Patient characteristics

	<i>Nulliparous women</i>	<i>Control group</i>	<i>Prolapse group</i>
Age (median; range)	27.7 (3.9)	52.7 (7.4)	58.0 (9.7)
BMI (median; range)	21.5 (20.5-26.3)	22.2 (19.9-31.4)	24.3 (22.2-35.1)
Parity (median; range)	0 (0-0)	2 (0-3)	2 (1-3)
<b>POP-Q stage (median; range)</b>			
<i>Cystocele</i>	0 (0-0)	0 (0-1)	2 (0-3)
<i>Uterine descent</i>	0 (0-0)	0 (0-1)	1 (0-2)
<i>Rectocele</i>	0 (0-0)	1 (0-1)	1 (0-2)
<b>UDI domain scores (mean; SD)</b>			
<i>Overactive bladder</i>	7 (10)	49 (26)	24 (20)
<i>Urinary incontinence</i>	2 (6)	25 (24)	39 (30)
<i>Pain</i>	24 (17)	33 (22)	22 (34)
<i>Genital prolapse</i>	11 (19)	26 (30)	46 (35)
<i>Obstructive micturition</i>	4 (11)	40 (31)	25 (20)
<b>DDI domain scores (mean; SD)</b>			
<i>Constipation</i>	7 (12)	24 (21)	13 (16)
<i>Obstructive defecation</i>	4 (6)	21.9 (21)	19 (16)
<i>Pain</i>	7 (17)	15 (19)	4 (7)
<i>Incontinence</i>	0 (0)	10 (15)	22 (34)
<i>Flatulence incontinence</i>	15 (18)	33 (36)	41 (36)

SD= Standard deviation; BMI= Body Mass Index

Domain scores of the UDI, DDI and IIQ, ranging from 0 (no symptoms present) to 100 (all symptoms present and causing maximal bother) were calculated. The spearman's rank correlation was used to correlate UDI and DDI domain scores with POP-Q measurements and with MRI-staged POP using the PCL line. The PCL was chosen for this comparison since this is the most commonly used reference line and is drawn between two good identifiable points. An exclusion criterion for the nulliparous women was the presence of pelvic floor symptoms therefore they were not included in this analysis. We decided not to adjust for multiple testing since we did not want to miss any important findings [21].

### Results

In *Table 1* the patient characteristics, findings on physical examination and questionnaire results of the three different groups are shown. The prolapse group and control group are comparable in age, BMI and parity.

*Table 2* shows the inter-observer correlation of the four different reference lines as assessed by the three different observers during maximal straining. In all three groups of women a good to excellent correlation was found for the assessment of the anterior and middle compartment using all four different reference lines. For the posterior compartment only in the prolapse group excellent correlations were found using the MPL, H line and perineal line. In the nulliparous and control group a moderate to good correlation was found in the posterior compartment for all four reference lines.

In *Table 3* the correlation between POP-Q findings and MRI findings is shown. In the prolapse group we found a good correlation between dynamic MRI and POP-Q findings in the anterior and middle compartment using the perineal line and in the posterior compartment using the PCL and H-line. In the control group we found a good correlation in the posterior compartment using the MPL line, in the anterior and middle compartment the correlation was poor for all four reference lines. None of the reference lines demonstrated a good correlation in both groups in all three compartments.

*Table 4* shows the correlation between pelvic floor symptoms as assessed using the UDI and DDI domain scores and prolapse as assessed using the PCL on dynamic MRI and as assessed during physical examination using POP-Q. No significant correlations were found in both groups between pelvic floor symptoms and POP-Q findings. Using dynamic MRI in the control group a significant correlation between the UDI urinary incontinence domain score and prolapse of the middle compartment was found. In the POP group a significant correlation

between DDI pain domain score and prolapse of the posterior compartment as assessed using dynamic MRI was found.

**Table 2.** Inter-observer correlation (ICC) (3 observers)

	Nulliparous		Control group		Prolaps group	
	ICC	95% CI	ICC	95% CI	ICC	95% CI
<b>PCL</b>						
Anterior	0.98	(0.93-0.99)	0.95	(0.83-0.99)	0.95	(0.84-0.99)
Middle	0.94	(0.82-0.98)	0.88	(0.64-0.97)	0.96	(0.89-0.99)
Posterior	0.74	(0.23-0.93)	0.48	(-0.64-0.87)	0.79	(0.34-0.95)
<b>MPL</b>						
Anterior	0.97	(0.92-0.99)	0.82	(0.44-0.96)	0.98	(0.95-0.99)
Middle	0.97	(0.92-0.99)	0.95	(0.84-0.99)	0.95	(0.86-0.99)
Posterior	0.67	(0.02-0.91)	0.91	(0.72-0.98)	0.88	(0.63-0.97)
<b>Perineal line</b>						
Anterior	0.73	(0.20-0.93)	0.57	(-0.47-0.91)	0.98	(0.94-1.0)
Middle	0.96	(0.89-0.99)	0.86	(0.55-0.97)	0.94	(0.82-0.98)
Posterior	0.61	(-0.21-0.91)	0.43	(-0.80-0.86)	0.87	(0.58-0.97)
<b>H-line</b>						
Anterior	0.98	(0.93-0.99)	0.87	(0.60-0.97)	0.98	(0.94-0.99)
Middle	0.85	(0.55-0.96)	0.82	(0.45-0.96)	0.95	(0.86-0.99)
Posterior	0.52	(-0.42-0.87)	0.63	(-0.16-0.91)	0.87	(0.60-0.97)

PCL= Pubococcygeal line; MPL= Mid-pubic line

## Discussion

We found a good to excellent inter-observer agreement for the evaluation of POP on dynamic MRI for all four different reference lines, despite the level of observer experience. In women with pelvic floor symptoms without stage 2 or more POP, correlation of dynamic MRI with findings during physical examination was overall poor while in women with at least stage 2 POP this correlation was moderate. The correlation of dynamic MRI and POP-Q with pelvic floor symptoms was poor for most symptoms in both groups.

Before further interpreting these data some strengths and weaknesses of our study need to be addressed. First of all the relative low number of women included in each group may be the reason that we did not observe statistical significant correlations between pelvic floor symptoms and POP-Q findings. The

**Chapter 6**

power to show statistical significant correlations might be too limited however since the correlation coefficients were very small we do not think that with more women these correlations would have become statistically significant and clinically relevant.

**Table 3.** Correlation of the most descending point in the three compartments using the POP-Q staging with the measurements in the same compartment using dynamic MRI.

	<i>Control group</i>	<i>Prolapse group</i>
<b>Anterior (Ba)</b>		
PCL	0.22	0.34
MPL	0.11	0.58
Perineal line	0.33	0.64*
H line	0.33	0.39
<b>Middle (C)</b>		
PCL	0.17	0.36
MPL	-0.48	0.54
Perineal line	-0.43	0.67*
H line	-0.61	0.39
<b>Posterior (Bp)</b>		
PCL	0.51	0.79*
MPL	0.70*	0.52
Perineal line	0.62	0.56
H line	0.51	0.84*

Values are correlation coefficients; \* P< 0.05; PCL= Pubococcygeal line; MPL= Mid-pubic line

The strength of this study is that we also included women without prolapse on physical examination but with pelvic floor symptoms. This is an interesting group because of the unexplained symptoms and especially in this group therefore MRI might show anatomical abnormalities which were not seen during physical examination. Furthermore, in contrast to previous studies, none of the women included underwent previous surgery because of prolapse complaints. This makes the relationship between anatomical abnormalities and pelvic floor symptoms more easy to interpret since previous surgery did not alter the anatomical relationship between the three pelvic compartments.

Our first aim was to assess if POP can be reliably assessed using different reference lines and observers with different levels of experience. In line with

previous studies reporting that none of the suggested reference lines is clearly superior, we found an excellent inter-class correlation in the anterior and middle compartment no matter what reference line used.[7, 15, 18] Since one of the observers only had a minimal level of experience in viewing MRI, the high intra-class correlation also shows that all four reference lines are easy to use also for observers with a minimal level of experience.

In the posterior compartment we only found a good intra-class correlation in the prolapse group. An explanation for this might be that in this group of women with obvious anatomical abnormalities, the most descending point is easy to assess, while in the group without anatomical abnormalities this is harder. Therefore assessment might vary more between the investigators in the nulliparous and control group.

To date, several studies have been published reporting on different reference lines and inter and intra-observer reliability, however only a few studies reported on correlations between MRI-staged POP and POP-Q staged POP [18, 19, 22, 23]. Most of these studies described a poor correlation between clinical and MRI findings and stated that POP can not be described using only one reference line [16, 18, 19]. Our findings are somewhat more optimistic. In the prolapse group we found a good correlation for at least one of the four reference lines in each of the three compartments. However, among the age-matched control group, only a good correlation was found in the posterior compartment, using the MPL line. This indicates that POP cannot be described by the usage of one reference line only, but also indicates that the absence of significant prolapse ultimately results in inferior agreement between clinical and MRI findings.

An explanation for the poor correlation between clinical examination and dynamic MRI findings might be a result of a lack of subjects' compliance. Unlike during physical examination, the subject is not being directly instructed and therefore coaching on the maximal Valsalva manoeuvre is not possible, ultimately this may lead to suboptimal straining results. Furthermore due to the straight position with the legs stretched and close together, it might be more difficult for the women to perform maximum Valsalva manoeuvre. By repeating the Valsalva manoeuvre sequences an attempt was made to reduce this effect and to retrieve a maximum Valsalva manoeuvre.

A few previous studies reported that pelvic defects were staged more reliable on MRI [23, 24]. It has therefore been suggested that this increased sensitivity of dynamic MRI in staging POP may make it useful in the evaluation of women with symptoms of pelvic floor relaxation who have negative findings on

**Table 4.** Correlation coefficients between UDI and DDI domain scores and POP as staged using the PCL reference line on dynamic MRI and POP-Q during physical examination in the control group

	Control group						Prolaps groups						
	MRI PCL staging			POP staging			MRI PCL staging			POP staging			
	Ant	Middle	Post	Ant	Middle	Post	Ant	Middle	Post	Ant	Middle	Post	
<b>UDI</b>													
Overactive bladder	0.56	0.41	-0.07	0.29	0.22	0.61	0.25	0.06	0.04	-0.07	-0.32	-0.05	
Incontinence	0.66	0.77*	0.18	0.06	0.29	0.23	-0.19	0.22	0.18	-0.35	-0.55	0.44	
Pain	0.06	-0.22	-0.51	0.39	0.16	0.20	-0.51	0.04	0.03	-0.43	-0.06	0.49	
Genital prolapse	0.73	0.28	0.34	-0.08	0.14	0.00	-0.01	0.15	-0.15	-0.03	0.24	0.13	
Obstructive micturition	0.03	0.23	-0.36	0.06	-0.05	0.13	0.36	0.28	0.13	0.15	0.15	-0.07	
<b>DDI</b>													
Constipation	0.35	0.44	0.51	-0.15	-0.19	0.69	-0.06	0.39	0.48	-0.39	0.23	0.49	
Obstruction defecation	0.39	0.39	0.53	-0.22	-0.23	0.50	0.15	0.49	0.78	-0.53	0.27	0.72	
Pain	-0.05	-0.14	-0.10	-0.29	-0.35	-0.23	0.52	0.10	0.76*	-0.05	0.16	0.27	
Incontinence	0.04	-0.08	-0.04	0.38	0.48	-0.14	-0.04	-0.22	-0.14	0.00	-0.35	0.00	
Flatus incontinence	0.43	0.30	0.05	0.46	0.59	0.24	0.46	-0.61	0.05	0.46	0.59	0.24	

\*Significant correlation; UDI= urogenital distress inventory; DDI= defecation distress inventory; POP= pelvic organ prolapsed; PCL= pubopoccygeal line; MRI= magnetic resonance imaging



clinical examination using POP-Q [24]. In our study a group of women with pelvic floor symptoms without prolapse stage 2 or more on physical examination using POP-Q, was included. Still, in this group the correlation of symptoms with POP as staged using dynamic MRI and POP-Q was moderate at most for all of the DDI domain scores and most of the UDI domain scores.

Only the UDI incontinence domain score seemed to correlate well with prolapse of the middle compartment as staged using dynamic MRI. It has been reported that some weakening of the pelvic support might increase urinary incontinence symptoms, however most studies reported that with increasing POP urinary incontinence symptoms decreased due to more obstruction [9, 10]. In our study we also failed to observe a strong correlation between POP and urinary incontinence among the prolapse group supporting the theory that with increasing POP the correlation between POP and urinary incontinence disappears. Therefore the clinical relevance of the correlation between the UDI incontinence domain score and POP of the middle compartment using MRI might be limited.

In conclusion, all four evaluated reference lines for assessing POP using dynamic MRI have an excellent inter-observer correlation even if used by less experienced viewers. In line with previous findings, no reference line could be identified which optimally correlated with findings on clinical examination in all three compartments among women with and without stage 2 or more POP. Also the correlation with clinical symptoms is not satisfying. In general we question the added value of dynamic MRI in assessing the anatomical abnormalities involved in POP.

### References

1. Bump RC, Norton PA. (1998) Epidemiology and natural history of pelvic floor dysfunction. *Obstet Gynecol Clin North Am* 25(4):723-46.
2. Fialkow MF, Newton KM, Weiss NS. (2008) Incidence of recurrent pelvic organ prolapse 10 years following primary surgical management: a retrospective cohort study. *Int Urogynecol J Pelvic Floor Dysfunct* 19(11):1483-7.
3. Whiteside JL, Weber AM, Meyn LA, Walters MD. (2004) Risk factors for prolapse recurrence after vaginal repair. *Am J Obstet Gynecol* 191(5):1533-8.
4. Miedel A, Tegerstedt G, Morlin B, Hammarstrom M. (2008) A 5-year prospective follow-up study of vaginal surgery for pelvic organ prolapse. *Int Urogynecol J Pelvic Floor Dysfunct* 19(12):1593-601.
5. Roovers JP, van der Vaart CH, van der Bom JG, van Leeuwen JH, Scholten PC, Heintz AP. (2004) A randomised controlled trial comparing abdominal and vaginal prolapse surgery: effects on urogenital function. *BJOG* 111(1):50-6.
6. Bump RC, Mattiasson A, Bo K, Brubaker LP, DeLancey JO, Klarskov P, et al. (1996) The standardization of terminology of female pelvic organ prolapse and pelvic floor dysfunction. *Am J Obstet Gynecol* 175(1):10-7.
7. Broekhuis SR, Futterer JJ, Barentsz JO, Vierhout ME, Kluivers KB. (2009) A systematic review of clinical studies on dynamic magnetic resonance imaging of pelvic organ prolapse: the use of reference lines and anatomical landmarks. *Int Urogynecol J Pelvic Floor Dysfunct* 20(6):721-9.
8. Broekhuis SR, Kluivers KB, Hendriks JC, Futterer JJ, Barentsz JO, Vierhout ME. (2009) POP-Q, dynamic MR imaging, and perineal ultrasonography: do they agree in the quantification of female pelvic organ prolapse? *Int Urogynecol J Pelvic Floor Dysfunct* 17.
9. Burrows LJ, Meyn LA, Walters MD, Weber AM. (2004) Pelvic symptoms in women with pelvic organ prolapse. *Obstet Gynecol* 104(5 Pt 1):982-8.
10. Ellerkmann RM, Cundiff GW, Melick CF, Nihira MA, Leffler K, Bent AE. (2001) Correlation of symptoms with location and severity of pelvic organ prolapse. *Am J Obstet Gynecol* 185(6):1332-7.
11. Uebersax JS, Wyman JF, Shumaker SA, McClish DK, Fantl JA. (1995) Short forms to assess life quality and symptom distress for urinary incontinence in women: the Incontinence Impact Questionnaire and the Urogenital Distress Inventory. Continence Program for Women Research Group. *Neurourol Urodyn* 14(2):131-9.
12. van dV, de L, Jr., Roovers JP, Heintz AP. (2000) [The influence of urinary incontinence on quality of life of community-dwelling, 45-70 year old Dutch women]. *Ned Tijdschr Geneesk* 144(19):894-7.
13. Van Brummen HJ, Bruinse HW, Van De PG, Heintz AP, van der Vaart CH. (2006) Defecatory symptoms during and after the first pregnancy: prevalences and associated factors. *Int Urogynecol J Pelvic Floor Dysfunct* 17(3):224-30.
14. Boyadzhyan L, Raman SS, Raz S. (2008) Role of static and dynamic MR imaging in surgical pelvic floor dysfunction. *Radiographics* 28(4):949-67.
15. Broekhuis SR, Kluivers KB, Hendriks JC, Vierhout ME, Barentsz JO, Futterer JJ. (2009) Dynamic magnetic resonance imaging: reliability of anatomical landmarks and reference lines used to assess pelvic organ prolapse. *Int Urogynecol J Pelvic Floor Dysfunct* 20(2):141-8.

16. Lienemann A, Sprenger D, Janssen U, Grosch E, Pellengahr C, Anthuber C. (2004) Assessment of pelvic organ descent by use of functional cine-MRI: which reference line should be used? *Neurourol Urodyn* 23(1):33-7.
17. Woodfield CA, Hampton BS, Sung V, Brody JM. (2009) Magnetic resonance imaging of pelvic organ prolapse: comparing pubococcygeal and midpubic lines with clinical staging. *Int Urogynecol J Pelvic Floor Dysfunct* 20(6):695-701.
18. Fauconnier A, Zareski E, Abichedid J, Bader G, Falissard B, Fritel X. (2008) Dynamic magnetic resonance imaging for grading pelvic organ prolapse according to the International Continence Society classification: which line should be used? *Neurourol Urodyn* 27(3):191-7.
19. Cortes E, Reid WM, Singh K, Berger L. (2004) Clinical examination and dynamic magnetic resonance imaging in vaginal vault prolapse. *Obstet Gynecol* 103(1):41-6.
20. Shrout PE. (1998) Measurement reliability and agreement in psychiatry. *Stat Methods Med Res* 7(3):301-17.
21. Rothman KJ. (1990) No adjustments are needed for multiple comparisons. *Epidemiology* 1(1):43-6.
22. Gousse AE, Barbaric ZL, Safir MH, Madjar S, Marumoto AK, Raz S. (2000) Dynamic half Fourier acquisition, single shot turbo spin-echo magnetic resonance imaging for evaluating the female pelvis. *J Urol* 164(5):1606-13.
23. Tunn R, Paris S, Taupitz M, Hamm B, Fischer W. (2000) MR imaging in posthysterectomy vaginal prolapse. *Int Urogynecol J Pelvic Floor Dysfunct* 11(2):87-92.
24. Goodrich MA, Webb MJ, King BF, Bampton AE, Campeau NG, Riederer SJ. (1993) Magnetic resonance imaging of pelvic floor relaxation: dynamic analysis and evaluation of patients before and after surgical repair. *Obstet Gynecol* 82(6):883-91.





Chapter 7

**Feasibility of Diffusion Tensor  
Imaging (DTI) with Fibre  
Tractography of the Normal  
Female Pelvic Floor**

*Eur Radiol. 2011 Jun;21(6):1243-9*

*F.M. Zijta*

*M. Froeling*

*M.P. van der Paardt*

*M.M.E. Lakeman*

*S. Bipat*

*A.D. Montauban van Swijndregt*

*G.J. Strijkers*

*A.J. Nederveen*

*J. Stoker*

### Abstract

**Objectives:** To prospectively determine the feasibility of diffusion tensor imaging (DTI) with fibre tractography as a tool for the three-dimensional (3D) visualisation of normal pelvic floor anatomy.

**Material and methods:** Five young female nulliparous subjects (mean age  $28 \pm 3$  years) underwent DTI at 3.0T. Two-dimensional diffusion-weighted axial spin-echo echo-planar (SP-EPI) pulse sequence of the pelvic floor was performed, with additional T2-TSE multiplanar sequences for anatomical reference. Fibre tractography for visualisation of predefined pelvic floor and pelvic wall muscles was performed offline by two observers, applying a consensus method. Three eigenvalues ( $\lambda_1, \lambda_2, \lambda_3$ ), fractional anisotropy (FA) and mean diffusivity (MD) were calculated from the fibre trajectories.

**Results:** In all subjects fibre tractography resulted in a satisfactory anatomical representation of the pubovisceral muscle, perineal body, anal - and urethral sphincter complex and internal obturator muscle. Mean FA values ranged from  $0.23 \pm 0.02$  to  $0.30 \pm 0.04$ , MD values from  $1.30 \pm 0.08$  to  $1.73 \pm 0.12 \times 10^{-3} \text{ mm}^2/\text{s}$ . Muscular structures in the superficial layer of the pelvic floor could not be satisfactorily identified.

**Conclusions:** This study demonstrates the feasibility of visualising the complex three-dimensional pelvic floor architecture using 3.0T DTI with fibre tractography. DTI of the deep female pelvic floor may provide new insights into pelvic floor disorders.

## Introduction

The female pelvic floor has a multilayered complex anatomy and includes several closely aligned muscles [1]. For imaging work-up of pelvic floor dysfunction, either evacuation proctography [2], transperineal ultrasound [3] or magnetic resonance imaging (MRI) can be used [4-6]. MRI has the advantage that no ionising radiation is employed and offers a high contrast resolution multiplanar examination with a detailed demonstration of the pelvic floor anatomy. To date, MRI has been demonstrated to be valuable in the characterisation of pelvic floor muscle defects [7,8]. However, the complexity of the pelvic floor anatomy does not make either the interpretation of these examinations or the communication of the results straightforward. This generally concerns the presence of muscular defects and altered signal intensity (e.g. scar tissue).

In vivo diffusion tensor imaging (DTI) has emerged as a unique non-invasive tool to describe the directionality of the internal microstructure within anisotropic tissues [9]. For anisotropic tissues, it is known that the diffusion of water is higher in the length of an internal microstructure and conversely, diffusion will be more restricted perpendicular to this direction. The directional dependence of water diffusion in tissue can be described by a three-dimensional (3D) diffusion tensor for each voxel. By combining the diffusion tensor data from multiple voxels, fibre tracts can be reconstructed that correlate with the principal diffusion direction of water molecules in a tissue microstructure [10]. This can provide important information about the tissue's architectural organisation that cannot be extrapolated from conventional MRI techniques.

Thus far, MR- or fibre tractography has been studied extensively in order to visualise and characterise the normal and diseased cerebral and spinal white matter tracts [11], and to a lesser extent the fibre orientation of striated skeletal muscle [12,13]. The latter is mostly limited to sizable muscles (muscle groups) of the upper and lower extremity, thereby avoiding motion-related artefacts and complex multidirectional anatomy. Demonstration of the normal pelvic floor muscular anatomy is more challenging and if this were feasible with DTI it might prove valuable in evaluating pelvic floor defects.

The aim of this work was to investigate the feasibility of visualising the normal pelvic floor musculature in healthy female nullipara subjects using DTI at 3.0 T. In addition, a quantitative description of the different muscles was performed by calculating the mean eigenvalues ( $\lambda_1$ ,  $\lambda_2$ ,  $\lambda_3$ ) and derived parameters (fractional anisotropy (FA) and mean diffusivity (MD)) for isolated muscles.

### **Material and methods**

#### *Study population*

In this prospective pilot study, five healthy nullipara women volunteered to participate in this study (mean age 28 SD  $\pm$  3 yrs). Exclusion criteria for participating were history of pregnancy, any (symptom of) pelvic floor disease and/or previous pelvic surgery. Other exclusion criteria were (relative) contraindications to undergoing MRI; pacemakers, claustrophobia and pregnancy.

In order to exclude pelvic floor dysfunction, subjects were subjected to composed standardised questionnaires, including Urogenital Distress Inventory (UDI), Defecation Distress Inventory (DDI) and Incontinence Impact Questionnaire (IIQ) [14,15]. This study was approved by the institutional review board. All subjects gave written informed consent.

#### *MRI data acquisition*

Magnetic resonance imaging was performed using 3.0T MRI (Intera, Philips Medical Systems, Best, the Netherlands). To allow coverage of the entire pelvic area a 6-channel surface coil was used, with subjects positioned in the supine position with the legs parallel, lightly flexed. Subjects were asked to empty the bladder before the examination. No contrast agent was administered in the bladder, urethra, vagina or rectum.

The MRI protocol comprised three sequences: static T1-weighted imaging (Turbo Spin Echo (TSE), field of view (FOV): 200 x 200 mm<sup>2</sup>, matrix: 400 x 400, slice thickness: 5 mm, no. of slices: 20, TR/TE: 600/10 ms), T2-weighted imaging (FOV: 200x200 mm<sup>2</sup>, matrix: 400x400, slice thickness: 5 mm, slices: 20, TR/TE: 1560/70 ms) and diffusion tensor imaging (DTI) (spin echo- echo- planar-imaging (SE-EPI), FOV: 200 x 200 mm<sup>2</sup>, matrix: 80 x 80 with 112 x 112 reconstructed matrix, slice thickness: 5 mm, slices: 20, 32 diffusion-weighted directions, TR/TE: 3250/48 ms, NSA: 2, b= 400 s/mm<sup>2</sup>, Spectral Adiabatic Inversion Recovery (SPAIR) for fat suppression, imaging time: 3min52s). The diffusion-weighted images were registered to their unweighted b=0 s/mm<sup>2</sup> images using Philips software. Non-angulated T1-weighted TSE and DTI were performed in the axial plane. Non-angulated T2-weighted sequences of the pelvis were obtained in axial, sagittal and coronal orientations for anatomical reference.

Image quality of the obtained T1w and T2w sequences of all subjects, was analysed by 2 physicists (AN, MF) who scored image quality regarding the presence of artefacts. DTI datasets were assessed regarding the presence of distortions due to field heterogeneity.



### *Data analyses*

Fibre tractography was performed offline using a dedicated software program (DTITool, Biomedical Image Analysis group, Department of Biomedical Engineering, Eindhoven University of Technology, Eindhoven, the Netherlands [16]). All data sets were independently analysed and measurements were performed by two observers (FZ, MP). After the initial independent analyses, the fibre tracking results were discussed by the two observers and modified if necessary, applying a consensus reading method. Both observer 1 (FZ, a third-year resident in radiology with an additional 3-year experience as a teaching assistant at the department of Anatomy and Embryology, Academic Medical Center, Amsterdam) and observer 2 (MP, a second-year PhD student), were taught in the anatomy of the pelvic floor before analysis by an abdominal radiologist (JS) with extensive experience in MRI of the pelvic floor (> 1500 examinations), including specific research into the MR anatomy of the pelvic floor. To determine whether fibre orientation and muscle shape were an adequate representation of the expected anatomical appearance, the findings were rated as satisfactory or non-satisfactory. These final findings were used for quantitative analysis.

The muscular structures of interest were: pubovisceral muscle; superficial transverse perinea, bulbospongiosus and ischiocavernosus muscle and the fibromuscular perineal body [1]. Also, special interest was focused on the muscular components of both the anal canal and urethral support, i.e. anal sphincter and the urethral sphincter complex. In addition, measurements were performed to track the major striated muscular component of the pelvic wall, i.e. the internal obturator muscle.

### *ROI selection*

To allow the 3D visualisation of the predefined muscles, a seed region of interest (ROI) in outline was manually drawn in the axial, coronal and/or sagittal planes on the resulting coloured FA map at the site where the course of the muscle could be expected. On the FA map, the per-voxel absolute vector values were colour-coded: red (medio-lateral direction), blue (cranio-caudal direction) and green (antero-posterior direction) (*Figure 1*). The corresponding T2w anatomical series was used for anatomical reference. Based on the initial fibre tracking results the seeding contour was manually adjusted. If the total extent of the muscle was insufficiently identified with a single seeding ROI, additional ROIs were appended. Overall, fibre tracking was automatically terminated if one of three conditions was met: 1) fibre length > 100 mm; 2) FA threshold < 0.1; 3) fibre angle > 10° / step.

In the case of small and/or circular (fibro) muscular structures (i.e. perineal body, anal sphincter and urethral sphincter), fibre tracking stop criteria were adjusted to fibre angle > 15° / step and fibre length > 40 mm, respectively.

### *DTI parameters*

For each muscle five DTI parameters were automatically calculated, the three eigenvalues ( $\lambda_1$ ,  $\lambda_2$  and  $\lambda_3$ ), the mean diffusivity (MD), and the fractional anisotropy (FA), according to (1) and (2) ( $D$  = diffusion tensor):

$$\text{MD} = \frac{1}{3} \text{Trace}(\mathbf{D}) = (\lambda_1 + \lambda_2 + \lambda_3) / 3 = \langle \lambda \rangle \quad [1]$$

$$\text{FA} = \sqrt{\frac{3}{2}} \frac{\sqrt{(\lambda_1 - \langle \lambda \rangle)^2 + (\lambda_2 - \langle \lambda \rangle)^2 + (\lambda_3 - \langle \lambda \rangle)^2}}{\sqrt{(\lambda_1^2 + \lambda_2^2 + \lambda_3^2)}} \quad [2]$$

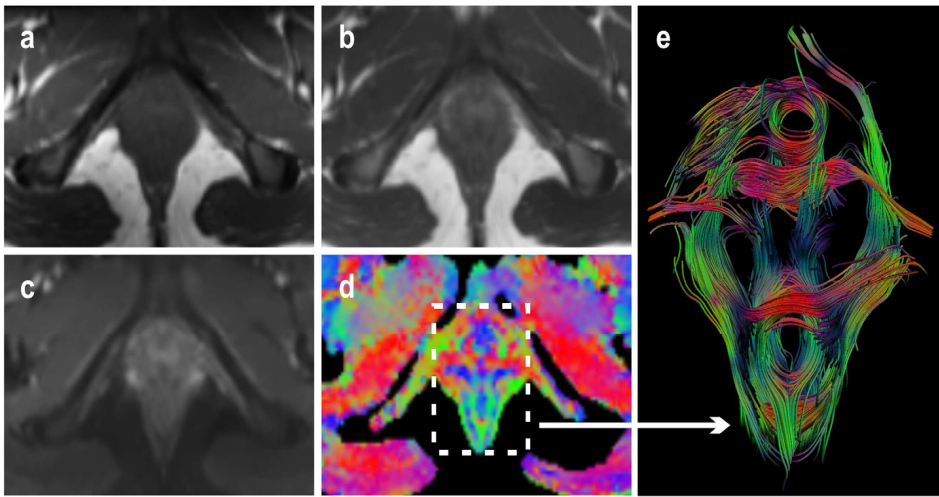
For each muscle or muscle group the DTI parameters were calculated at multiple points per fibre along the fibre tracts. The parameters were considered as normal distributed data. From these data points the mean value for each of the parameters was calculated. Per-muscle data for five subjects were combined and were expressed as mean value  $\pm$  standard deviation (SD).

## **Results**

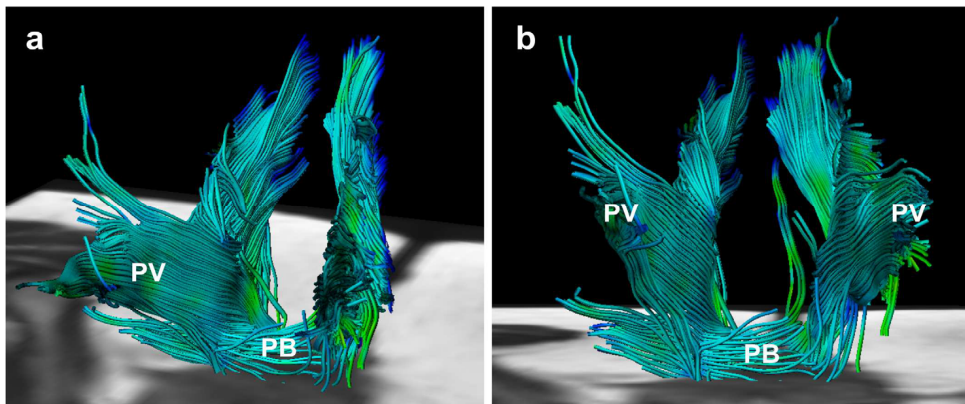
Based on the composed standardised questionnaires, none of the participating female subjects experienced any prolapse, micturition and/or defecation symptoms. Image quality of the obtained T1w, T2w and DTI datasets proved robust, and no influencing artefacts and/or distortions were detected.

Fibre-tracking resulted in a satisfactory representation of the global muscle morphology and fibre orientation for the following predefined pelvic muscular structures: pubovisceral muscle (*Figure 2*), perineal body, anal sphincter complex (*Figure 3*), urethral sphincter complex (*Figure 4*) and internal obturator muscle (*Figure 5*) in all five female volunteers.

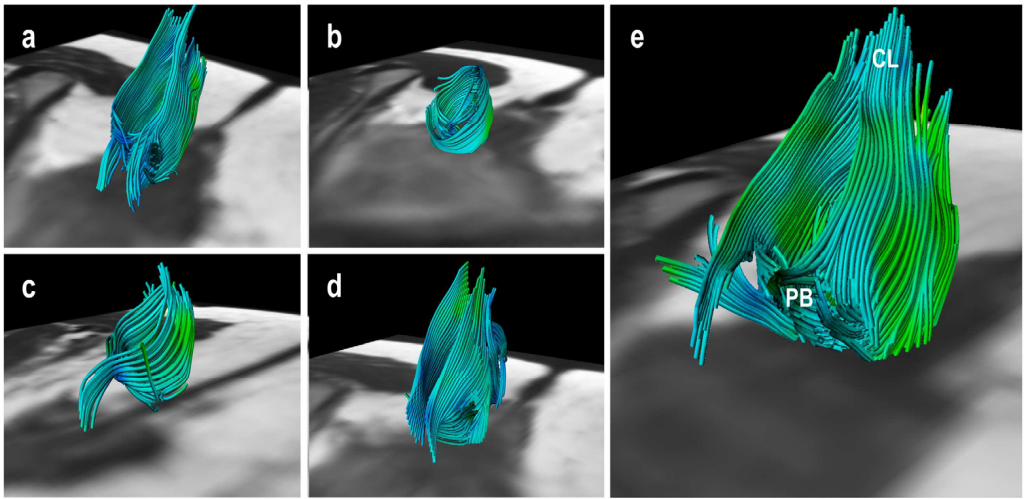
Although for each identified muscle the corresponding origin and insertion could not be clearly identified, all fibres were positioned within the expected muscle boundaries as perceptible on corresponding anatomical T2w series. At the level of both the anal canal and urethral sphincter complex, we were able to detect circularly orientated fibre trajectories (*Figures 1, 3 and 4*). No



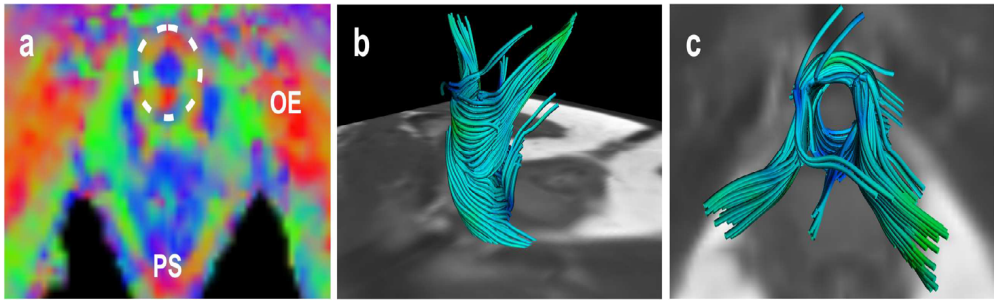
**Figure 1.** Axial T1-weighted image (a), T2-weighted image (b), b=0 image (c) and corresponding FA map (d) of the pelvic floor of a 24-year old healthy nulliparous female subject. FA and direction map with per-voxel colour-coded vector values: red (right-left direction), green (antero-posterior direction); blue (cranio-caudal direction). With the application of whole volume seeding, present three dimensional (3D) fibre trajectories provide a comprehensive overview of the complex pelvic floor anatomy (*caudal view*) (e).



**Figure 2.** Fibre tractography demonstrates the complex, multidirectional organisation of the different pubovisceral (PV) muscle components in a 28-year old female subject in both oblique-anterior (a) and anterior-posterior view (b). At the bottom of the pelvic floor transverse orientation of the fibre tracts are displayed matching the perineal body (PB).



**Figure 3.** Fibre trajectories representing the anal sphincter complex in all five female subjects; 28 years, 32 years, 24 years, 27 years and 31 years of age, respectively (a-e). Not all extrapolated fibre trajectories, matching the appearance of the anal sphincter complex, were perfectly circularly orientated. This might be attributed to both the predefined fibre angle cut-off point and the potential inaccurate fibre tractography based on signal originating from various muscles and ligamentous structures converging and interweaving in this area (e.g. perineal body (PB) and coccygeal ligament (CL)) (e).

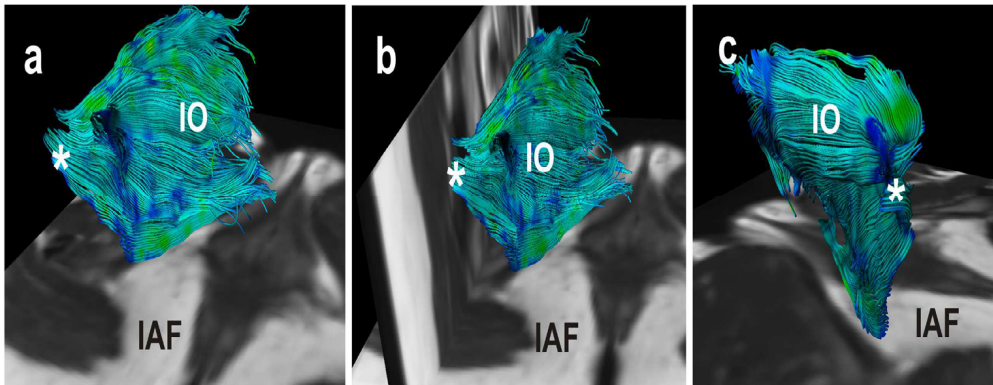


**Figure 4.** Transverse colour coded FA-map image of the inferior pelvic floor of a 31-year old nulliparous female subject (a). Several anatomical structures are depicted on this level based on the colour code: external obturator muscle (OE) and puborectal sling (PS). Similar to the anal sphincter complex, the vector orientation on the level of the urethral sphincter was medio-laterally (red ) orientated at the anterior and posterior borders, and antero-posteriorly (green ) orientated at the lateral border in all subjects, as an indication of the circular organisation of the structure (dotted circle) (a). Fibre trajectories reflecting the urethral sphincter complex with a cranial (b) and anterolateral view (c).

supplementary categorisation in muscular components (i.e. smooth muscle vs. striated muscle) could be stratified from the obtained fibre trajectories.

The bulbospongiosus muscle, ischiocavernosus muscle and superficial transverse perineal muscle could not or could only partially be tracked in the available datasets and were therefore rated as unsatisfactory representations in all 5 volunteers. Accordingly, no parameters were calculated for these muscular structures.

Per-group mean values of fractional anisotropy (FA) for the different muscles were comparable and ranged from  $0.23 \pm 0.02$  to  $0.30 \pm 0.04$ . Lowest FA values were found for the urethral sphincter and highest for the anal sphincter complex. Lowest in-group variability was found for the obturator muscle ( $SD = \pm 0.01$ ). Highest per-group variability in mean diffusivity (MD) and the three eigenvalues ( $\lambda_1, \lambda_2$  and  $\lambda_3$ ) was found for the pubovisceral muscle (*Table 1*).



**Figure 5.** Fibre trajectories as a representation of the internal obturator muscle (IO) from a postero-medial (a), posterior (b) and postero-lateral view (c) in a 27-year old female subject. The flat muscle shape is satisfactory represented; the muscle is medio-inferiorly bounded by the ischio-anal fossa (IAF). Fibre tracks converge posteriorly and bend laterally into the greater sciatic foramen (\*).

## Discussion

In this feasibility study we obtained three-dimensional (3D) fibre trajectories of the female pelvic floor and wall muscles, which match the global appearance of the pubovisceral muscle, perineal body, anal sphincter complex, urethral sphincter complex and internal obturator muscle based on fibre orientation, shape, size and location. Furthermore, the extrapolated objective microstructural

parameters fitted within the range of values previously reported studying striated muscle diffusion tensor imaging (DTI) [10,12,13].

To date, studies assessing striated muscles by means of DTI are narrowed to mostly normal, perfectly geometrically arranged muscles in the muscle compartments of the lower extremity [10,12,13]. By assessing the feasibility of DTI fibre-tracking of the muscular pelvic floor, we were confronted with a complex organisation of muscular structures, demonstrating a pennate architecture with indistinct boundaries regarding origin and insertion in close relation to adjacent pelvic viscera (e.g. bladder, vagina and rectum) [1]. Yet, we were able to collect data sets without notable distortions at SE-EPI and T2w-TSE sequences and no disturbing motion-related artefacts were observed in the five data sets.

**Table 1.** Mean DTI values  $\pm$  SD were calculated from five female subjects for each muscle

	<i>FA</i>	<i>MD</i> *	$\lambda_1$ *	$\lambda_2$ *	$\lambda_3$ *	<i># points</i> †	<i># fibers</i> ‡
<b>Anal Sphincter</b>	0.30 $\pm$ 0.04	1.30 $\pm$ 0.08	1.70 $\pm$ 0.08	1.24 $\pm$ 0.08	0.95 $\pm$ 0.11	22566	457
<b>Urethral Sphincter</b>	0.23 $\pm$ 0.02	1.73 $\pm$ 0.12	2.15 $\pm$ 0.17	1.69 $\pm$ 0.11	1.36 $\pm$ 0.10	9241	174
<b>Pubovisceral Muscle</b>	0.28 $\pm$ 0.04	1.49 $\pm$ 0.47	1.89 $\pm$ 0.51	1.45 $\pm$ 0.47	1.12 $\pm$ 0.43	60550	1035
<b>Perineal body</b>	0.27 $\pm$ 0.04	1.32 $\pm$ 0.19	1.67 $\pm$ 0.17	1.28 $\pm$ 0.21	0.99 $\pm$ 0.20	3896	97
<b>Internal Obturator Muscle</b>	0.27 $\pm$ 0.01	1.51 $\pm$ 0.11	1.93 $\pm$ 0.13	1.43 $\pm$ 0.09	1.16 $\pm$ 0.10	89330	888

FA = Fractional Anisotropy; MD = Mean Diffusivity

\* MD,  $\lambda_1$ ,  $\lambda_2$ ,  $\lambda_3$  are in units of [ $\times 10^{-3}$  mm<sup>2</sup>/s]

† Refers to the mean number of points of which DTI parameters are calculated.

‡ Refers to the mean number of fibers per isolated muscle.

Fibre tracts at the level of the anal- and urethral sphincter complex demonstrated a strong circular directionality in all five female subjects, which therefore was appreciated as a representation of both sphincter complexes. However, both urethral sphincter and anal sphincter constitute two important cylindrical muscular structures, i.e. smooth muscle inner layer (lissosphincter, internal sphincter, respectively) and striated muscle outer layer (rhabdosphincter,



external sphincter, respectively) [1], which we were unable to discriminate. In the current literature, little is known about fibre tracking applied in smooth muscle cell structures, and one can question whether its anisotropic characteristics in DTI applications are similar to those of striated muscle. Because of such uncertainties, we have considered the fibre tracts as a representation of the cylindrical sphincter complex, rather than as a representation of striated sphincter alone.

The highest variability in mean diffusivity (MD) values was found for the pubovisceral muscle ( $1.49 \pm 0.47 \times 10^{-3} \text{ mm}^2/\text{s}$ ) and might be attributed to the complex organisation of this muscle. The pubovisceral muscle encompasses several muscular components: the puboperineal/pubovaginal muscle, puboanal muscle and puborectal muscle [1]. Muscle fibres are orientated in different directions, are closely aligned and demarcations among the endopelvic fascia, intermuscular fat issue and neurovascular bundle are indistinct. The relatively wide ROIs used for data collection for this muscle might therefore be subjected to alterations in both fibre tracking and extrapolated parameters.

Muscular structures of the superficial layer of the pelvic floor (bulbospongiosus, ischiocavernosus and superficial transverse perineal muscle) could not be satisfactorily identified in the available datasets, although these muscles play a less important supportive role in pelvic floor dysfunction and are therefore are of less clinical importance [1]. Optimising the protocol and increasing resolution might solve present limitations for detecting these small superficial structures, but can also result in lower SNR which decreases the accuracy of fibre tractography and parameter estimation. Also, increasing the resolution would increase the echo train length of echo planar imaging (EPI) acquisition leading to more artefacts associated with EPI imaging, e.g. deformation due to field heterogeneities.

Owing to the relatively small dimensions of some of the pelvic muscles [1,17], relative to the voxel dimensions ( $5 \times 1.79 \times 1.79 \text{ mm}^3$ ), it was difficult to isolate individual small muscles. Voxels might contain signal originating from multiple muscles or both muscle and fat leading to partial volume effects, which could lead to inaccurate values for the DTI parameters and fibre tractography. As a fibre trajectory originating from a single muscle voxel connects to a subsequent voxel containing signal from a different muscle, the tract might continue its path in a different muscle to that in which it originated. Reduction of this partial volume effect can be accomplished by reducing the voxel size, which consequently decreases the signal-to-noise ratios (SNRs). Another option is to use high angular

resolution diffusion imaging (HARDI) which is a novel post-processing technique that is able to describe multiple fibre directions in a single voxel [18].

Although fibre tractography in the pelvic region was proven feasible for most predefined muscular structures, several issues need improvement. The seeding of fibres is a time-consuming iterative manual process and is reported to be strongly user-dependent, which ultimately affects the output results [19]. For fibre tractography as a clinical tool this is not desirable.

This feasibility study has recognised limitations. The number of subjects studied was limited, but the consistent feasibility of DTI of the important pelvic floor structures shows the robustness of the technique. As variation in observed diffusion parameters in relation to age and gender have been reported [20], larger and more heterogeneously composed cohorts need to be evaluated in order to derive objective reference values for pelvic floor diffusion parameters. We included only female subjects of relatively young age and without symptoms in this feasibility study as we wanted to demonstrate the normal anatomy before considering studying patients. As pelvic floor dysfunction primarily concerns women, we limited our study to female subjects.

The current available musculoskeletal DTI tractography literature shows a rather large heterogeneity in reported diffusion parameter values. This heterogeneity might be attributed to the recognised user-dependent analytical methods to some degree [19]. From this perspective, the assessment of reproducibility (i.e. intra-observer and inter-observer variability) is essential in order to evaluate DTI with tractography for diagnostic purposes. This study was primarily aimed at assessing the feasibility of visualising the muscular anatomy of the pelvic floor and therefore reproducibility was not assessed.

In conclusion, 3.0T diffusion tensor imaging (DTI) with fibre tractography is a technically feasible method for the 3D visualisation of the normal female muscular pelvic floor. The overall small SDs of the extrapolated fractional anisotropy (FA), the mean diffusivity (MD) values strongly suggest that we were able to reliably measure per-muscle DTI parameters in the pelvic area. In this pilot study we studied the normal anatomy in nulliparous women without previous pelvic trauma. Research is needed to define the potential role of DTI and fibre tractography in demonstrating alterations in pelvic organ support in pelvic floor dysfunction. This may not only concern anatomical defects but also differences in measured diffusion parameters between normal and injured muscle tissue [21,22], whereas it is assumed that tissue integrity is altered when injured and therefore results in a focal distortion of diffusion and derivative parameters [21].



---

**References**

1. Stoker J, Wallner C (2008) The anatomy of the pelvic floor and sphincters. In: Stoker J, Taylor S, De Lancey JOL (eds). *Imaging pelvic floor disorders*. Springer Verlag, New York, pp 1-29
2. Maglinte DD, Bartram C (2007) Dynamic imaging of posterior compartment pelvic floor dysfunction by evacuation proctography: techniques, indications, results and limitations. *Eur J Radiol.* 61(3):454-461
3. Majida M, Braekken IH, Umek W, Bø K, Saltyte Benth J, Ellstrøm Engh M (2009) Interobserver repeatability of three- and four-dimensional transperineal ultrasound assessment of pelvic floor muscle anatomy and function. *Ultrasound Obstet Gynecol.* 33(5):567-573
4. Boyadzhyan L, Raman SS, Raz S (2008) Role of static and dynamic MR imaging in surgical pelvic floor dysfunction. *Radiographics* 28(4):949-967
5. Colaiacomo MC, Masselli G, Poletti E, Lanciotti S, Casciani E, Bertini L, Gualdi G (2009) Dynamic MR imaging of the pelvic floor: a pictorial review. *Radiographics* 29(3):e35
6. Stoker J, Rociu E, Bosch JL, Messelink EJ, van der Hulst VP, Groenendijk AG, Eijkemans MJ, Laméris JS (2003) High-resolution endovaginal MR imaging in stress urinary incontinence. *Eur Radiol.* 13(8):2031-2037
7. Dobben AC, Terra MP, Slors JF, Deutekom M, Gerhards MF, Beets-Tan RG, Bossuyt PM, Stoker J (2007) External anal sphincter defects in patients with fecal incontinence: comparison of endoanal MR imaging and endoanal US. *Radiology* 242(2):463-471
8. Delancey JO (2002) Fascial and muscular abnormalities in women with urethral hypermobility and anterior vaginal wall prolapse. *Am J Obstet Gynecol.* 187(1):93-98
9. Lansdown DA, Ding Z, Wadington M, Hornberger JL, Damon BM (2007) Quantitative diffusion tensor MRI-based fiber tracking of human skeletal muscle. *J Appl Physiol.* 103(2):673-681
10. Sinha U, Yao L (2002) In vivo diffusion tensor imaging of human calf muscle. *J Magn Reson Imaging.* 2002;15(1):87-95
11. Choi SJ, Lim KO, Monteiro I, Reisberg B (2005) Diffusion tensor imaging of frontal white matter microstructure in early Alzheimer's disease: a preliminary study. *J Geriatr Psychiatry Neurol.* 18(1):12-19
12. Budzik JF, Le Thuc V, Demondion X, Morel M, Chechin D, Cotten A (2007) In vivo MR tractography of thigh muscles using diffusion imaging: initial results. *Eur Radiol.* 17(12):3079-3085
13. Froeling M, Oudeman J, van den Berg S, Nicolay K, Maas M, Strijkers GJ, Drost MR, Nederveen AJ (2010) Reproducibility of diffusion tensor imaging in human forearm muscles at 3.0 T in a clinical setting. *Magn Reson Med.* 64(4):1182-1190
14. Uebersax JS, Wyman JF, Shumaker SA, McClish DK, Fantl JA (1995) Short forms to assess life quality and symptom distress for urinary incontinence in women: The Incontinence Impact Questionnaire and the Urogenital Distress Inventory. *Neurourol Urodyn* 14:131-139
15. van Brummen HJ, Bruinse HW, van de Pol G, Heintz APM, van der Vaart CH (2006) Defecatory symptoms during and after the first pregnancy: prevalences and associated factors. *Int Urogynecol J Pelvic Floor Dysfunct* 17:224-230

16. Vilanova A, Berenshot G, van de Pul C (2004) DTI Visualization with Streamsurfaces and Evenly-Spaced Volume Seeding. Paper presented at: Proceedings of the VisSym Joint Eurographics/IEEE TCVG Symposium on Visualization; Konstanz, Germany.
17. Rociu E, Stoker J, Eijkemans MJ, Laméris JS (200) Normal anal sphincter anatomy and age- and sex-related variations at high-spatial-resolution endoanal MR imaging. *Radiology* 217(2):395-401
18. Tuch DS, Reese TG, Wiegell MR, Wiegell MR, Makris N, Belliveau JW, Wedeen VJ (2002) High angular resolution diffusion imaging reveals intravoxel white matter fiber heterogeneity. *Magn Reson Med.* 48(4):577-582
19. Brecheisen R, Vilanova A, Platel B, ter Haar, Romeny B (2009) Parameter Sensitivity Visualization for DTI Fiber Tracking. *IEEE Transactions on Visualization and Computer Graphics* 15(6):1441-1448
20. Khalil C, Budzik JF, Kermarrec E, Balbi V, Le Thuc V, Cotten A (2010) Tractography of peripheral nerves and skeletal muscles. *Eur J Radiol.* doi:10.1016/j.ejrad.2010.03.012
21. Zaraiskaya T, Kumbhare D, Noseworthy MD (2006) Diffusion tensor imaging in evaluation of human skeletal muscle injury. *J Magn Reson Imaging.* 24(2):402-408.
22. Kan JH, Heemskerk AM, Ding Z, Gregory A, Mencio G, Spindler K, Damon BM (2009) DTI-based muscle fibre tracking of the quadriceps mechanism in lateral patellar dislocation. *J Magn Reson Imaging.* 29(3):663-670



# Chapter 8

## **Evaluation of the Female Pelvic Floor in Pelvic Organ Prolapse using 3.0T Diffusion Tensor Imaging and Fibre Tractography.**

*Submitted*  
*F.M. Zijta*  
*M.M.E. Lakeman*  
*M. Froeling*  
*M.P. van der Paardt*  
*C.S.V. Borstlap*  
*S.Bipat*  
*A.D. Montauban van Swijndregt*  
*G.J. Strijkers*  
*J.P. Roovers*  
*A.J. Nederveen*  
*J. Stoker*

### Abstract

**Purpose:** To prospectively explore the clinical application of diffusion tensor imaging (DTI) and fibre-tractography in the evaluation of the female pelvic floor.

**Material and Methods:** Thirty women were consecutively included: 10 patients with pelvic organ prolapse, 10 patients with pelvic floor symptoms and 10 asymptomatic women. 2D SE-EPI sequence of the pelvic floor was performed. Offline fibre-tractography of principal pelvic structures was performed and two observers evaluated the tracking results. From agreed tracking results DTI parameters (eigen values ( $\lambda_1$ ,  $\lambda_2$  and  $\lambda_3$ ), mean diffusivity (MD), fractional anisotropy (FA)) were calculated. Inter-rater agreement for quality assessment was evaluated using weighted kappa statistics ( $\kappa$ ). Mean MD and FA values were compared among the three groups using variance analysis (ANOVA). Inter-rater reliability of DTI parameters was interpreted using intra-class correlation coefficient (ICC) statistics.

**Results:** For qualitative analyses, substantial inter-rater agreement was found ( $\kappa=0.71$ (95% CI 0.63-0.78)). Four anatomical structures (anal sphincter complex (AS), perineal body (PB), puboperineal muscle (PPM) and internal obturator muscle (IO)) could be reliably identified. Substantial inter-rater agreement was found for MD and FA values (ICC 0.60-0.91). No significant differences between groups of MD and FA were observed for AS, PB and PPM. Significant difference in mean FA was found in the IO-muscle between the prolapse group and nulliparous women ( $0.27\pm 0.05$ ) and ( $0.23\pm 0.03$ )( $p=0.013$ ).

**Conclusion:** Currently, DTI with fibre-tractography permits three dimensional visualization of in-vivo pelvic floor anatomy, with reliable identification of part but not all of the clinically relevant anatomical structures. Overall no significant differences in DTI parameters were found between groups.

## Introduction

Pelvic floor dysfunction entails a variety of conditions, including pelvic organ prolapse (POP), faecal and urinary incontinence. Certain basic risk factors have been considered, which among others include (complicated) vaginal delivery, normal aging and obesity [1,2]. Although its precise pathophysiology is currently only partly understood, defects in the levator ani muscle are known to be highly associated with the presence of pelvic floor prolapse [3]. Therefore, visualization of the pelvic floor musculature, identification of muscle injuries and in particular evaluation of muscle structure and function, would complement generally used clinical tools, and might reveal etiologic factors for pelvic organ prolapse.

Both static and dynamic Magnetic Resonance Imaging (MRI) enable a comprehensive interpretation of the complex pelvic floor anatomy and are increasingly proposed as a complementary diagnostic tool in pelvic floor dysfunction [4-7]. In the search for an improved three-dimensional (3D) understanding of anatomical relationships in the pelvic floor and changes in muscle integrity which might correlate with pelvic floor dysfunction, recently the use of diffusion tensor imaging (DTI) with fibre-tractography was proposed for the visualization of the normal female pelvic floor [8].

Recent studies have reported DTI as a useful method for detecting alterations in tissue organization of injured striated skeletal muscles as compared to normal muscles [9,10], which can be expressed in basic DTI parameters (i.e. eigen values, mean diffusivity (MD), and fractional anisotropy (FA)). The enhanced 3D visualization with DTI and fibre-tractography might have potential to visualize abnormal pelvic floor support in patients with pelvic floor prolapse, but has not been studied yet.

The purpose of this study was to examine the clinical application of diffusion tensor imaging (DTI) and fibre-tractography of the pelvic floor support, by prospectively evaluating and comparing the fibre-tract outcomes and basic DTI parameters of women with pelvic organ prolapse to women with pelvic floor symptoms, but without pelvic organ prolapse and to asymptomatic nulliparous women. In addition, the degree of inter-rater reliability was determined.

## Material and Methods

### *Subjects*

For this prospective cross-sectional study, institutional review board approval was obtained and all participants gave written informed consent. Three different groups of subjects were included, in total 30 female subjects were enrolled in this

study. Based on a published feasibility study [8], we anticipated the detection of (micro) structural differences between the symptomatic and asymptomatic pelvic support at already a small sample size.

The first group consisted of women with pelvic floor symptoms and had at least a stage 2 pelvic organ prolapse as staged with Pelvic Organ Prolapse Quantification (POPQ) staging criteria, according to the recommendations of the International Continence Society (ICS)[11]. The second group, which was age-matched with the prolapse group, consisted of women who had pelvic floor symptoms but without clinical relevant pelvic organ prolapse. The third group consisted of nulliparous women, without pelvic floor symptoms. All women were recruited in an outpatient clinic of a tertiary referral centre and underwent a pelvic examination during which the presence of a prolapse was assessed and staged [11]. Pelvic symptoms were measured in all subjects using a disease-specific symptom questionnaire, which was based on the Urogenital Distress Inventory (UDI), Incontinence Impact Questionnaires (IIQ) and Defecation Distress Inventory (DDI) items [12,13]. Exclusion criteria for all groups included previous pelvic floor surgery and general contraindications to undergo MRI (e.g. pacemakers, claustrophobia and pregnancy).

### *Image Acquisition*

Each woman underwent MRI in the supine position with the legs parallel, slightly flexed using a 3.0T MR-scanner (Intera, Philips Healthcare, Best, the Netherlands) with a 16-channel phased-array surface coil (SENSE-XL-Torso, Philips Healthcare) for signal reception. No intravenous contrast medium was administered. Subjects were asked to empty the bladder 1 hour prior to the examination. MR imaging comprised the acquisition of a multishot Turbo Spin Echo (TSE) T1-weighted sequence (TR/TE: 600/10 ms, field-of-view (FOV): 200x200 mm<sup>2</sup>, slice thickness: 5 mm, slices: 20, echo train length: 7), multishot TSE T2-weighted sequence (TR/TE: 3021/80 ms, FOV: 300x300 mm<sup>2</sup>, slice thickness: 4 mm, slices: 31, slice gap 0.4mm, echo train length: 16) in axial, coronal and sagittal planes for anatomical reference and dual-echo gradient echo imaging to derive a B0-field inhomogeneity map (TR/TE1/TE2=12/4.6/9.6 ms, FOV: 200x200 mm<sup>2</sup>, acquisition matrix: 80x80, pixel size: 2.5x2.5 mm<sup>2</sup>, slice thickness: 5 mm, number of signal averages (NSA)=2). Axial two-dimensional (2D) diffusion weighted images were acquired with a diffusion-weighted Spin-Echo Echo- Planar Imaging (SE-EPI) pulse sequence using the following MRI parameters; TR/TE: 3750/40 ms, FOV: 200x200 mm<sup>2</sup>, acquisition matrix: 80x80,

pixel size: 2.5x2.5 mm<sup>2</sup> , slice thickness: 5 mm, slices: 20, 32 diffusion weighted directions, NSA: 2, b= 400 s/mm<sup>2</sup>, Spectral Adiabatic Inversion Recovery (SPAIR for fat suppression). The total acquisition time for the DTI sequence was less than 4 minutes. The axial DTI sequence was non-angularly positioned and care was taken in order to place the anal sphincter complex and coccygeal bone within the FOV.

#### *Post processing and Visualization*

DTI data was processed using a custom build toolbox in Mathematica 8.0 [14]. Initially the data was filtered using a rician noise suppression algorithm [15], after which the diffusion-weighted data was registered to the non-weighted images using an affine transformation and corresponding b-matrix rotation [16]. Subsequently the diffusion tensor was calculated and corrected for field inhomogeneity induced deformations. The per-voxel absolute vector direction was colour coded according to standardized FA map colour coding: red indicating the left-right direction, blue the superior-inferior direction and green the antero-posterior direction. Offline fibre tracking was performed independently by two observers (FZ,MP), blinded to subject symptomatology and to prolapse status, using DTI software (DTITool, Biomedical Image Analysis group, Department of Biomedical Engineering, Eindhoven University of Technology, Eindhoven, the Netherlands (<http://bmia.bmt.tue.nl/software/dtitool> ) ). Observer 1 (FZ, a fourth-year resident in radiology with an additional 3-year experience as a teaching assistant at the department of Anatomy and Embryology, Academic Medical Centre, Amsterdam the Netherlands) and observer 2 (MP, medical doctor and third-year PhD student), were experienced with the complex pelvic floor anatomy and subsequent 3D DTI tractography [8].

In the acquired FA-maps and/or T1-weighted sequence, multiplanar, both manually drawn and positioned user-defined regions-of-interest (ROI's) were used to construct 3D fibre tracts of each of the predefined anatomical structures in the pelvic floor and wall (levator ani muscle (i.e. pubovisceral -, puborectal - and iliococcygeus muscle [17] ), anal - and urethral sphincter complex, perineal body and internal obturator muscle) and the pelvic floor superficial layer (superficial transverse perineal -, bulbospongiosus muscle (also called bulbocavernosus muscle) and ischiocavernosus muscles). As the pubovisceral muscle consists of different subdivisions (with insertions on the level of the vagina (pubovaginal muscle), perineal body (puboperineal muscle) and the anal sphincter complex (puboanal muscle), respectively [17]), observers

were instructed to check whether these subdivisions could be separately visualized. Applied tracking parameters were standardized: minimal/maximal fibre length 10-100 mm; minimum/maximum FA thresholds 0.10-0.50; angle threshold <10-15°; integration step length 0.1 voxel. In case of a paired anatomical structure, the left and right muscle were tracked separately. The two symmetrical parts of both the bulbospongiosus – and puboperineal muscle were considered as an unpaired structure for analyses purposes as these structures were difficult to isolate as a paired structure.

### *Qualitative data analysis*

The resultant 3D representation of each isolated anatomical structure was independently rated by both observers using a four-point scale (*good*=high-quality representation of the expected anatomical appearance within expected boundaries; *sufficient*=adequate representation of the expected anatomical appearance, based on fibre orientation, shape and location, but presence of focal tracking distortions and non-tracking; *insufficient*=non-satisfactory visualization with presence of only few fibre tracks and/or deviant fibre orientation, *not found*=not present). Subsequently, rates were categorized into satisfactory ( i.e. *good* and *sufficient*) and non-satisfactory ( *insufficient* and *not found*). By using a consensus based method, individual 3D fibre trajectories were qualitatively evaluated and ROI's were adjusted if necessary, resulting in a consensus based dataset.

Towards a better understanding of qualitative and quantitative fibre-tractography outcomes, the *pubovisceral muscle* was bilaterally evaluated on multiplanar 2D TSE T2w images using a grading system which was previously reported to assess (birth-associated) muscle abnormalities [18]. A four-point Likert scale was used to qualitatively assess the pubovisceral musculature (0=no visible defects; 1=less than half of muscle bulk lost; 2=more than half of muscle bulk lost; 3=complete muscle bulk lost) [18].

### *DTI parameters*

For quantitative analysis, mean values ( $\pm$ SD) of the three eigen-values ( $\lambda_1$ ,  $\lambda_2$  and  $\lambda_3$ ) were calculated for multiple points per fibre along the resultant fibre tracts. Mean diffusivity (MD) and fractional anisotropy (FA) were defined as ( $\mathbf{D}$ =Diffusion tensor):

$$\text{MD} = \frac{1}{3} \text{Trace}(\mathbf{D}) = (\lambda_1 + \lambda_2 + \lambda_3)/3 = \langle \lambda \rangle \quad [1]$$



$$FA = \frac{\sqrt{3}}{2} \frac{\sqrt{(\lambda_1 - \langle \lambda \rangle)^2 + (\lambda_2 - \langle \lambda \rangle)^2 + (\lambda_3 - \langle \lambda \rangle)^2}}{\sqrt{(\lambda_1^2 + \lambda_2^2 + \lambda_3^2)}} \quad [2]$$

### Statistical Analysis

Interobserver agreement analysis was performed for each isolated anatomical structure. For the overall qualitative data (i.e. four-point scale quality assessment of 3D representation), inter-observer agreement was determined using quadratic weighted kappa statistics. Kappa statistics with 95% confidence intervals were calculated. For qualitative sub analyses, prevalence- and bias-adjusted kappa( $\kappa$ ) statistics (PABAK) were used.

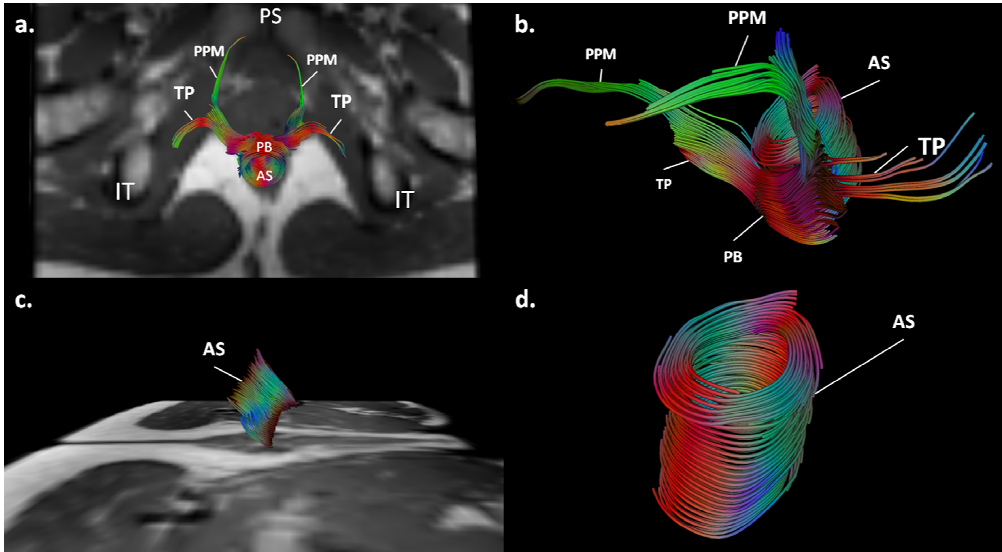
DTI parameters (i.e. mean MD and FA values) were recorded and compared amongst the three groups if an isolated muscle was rated satisfactory (i.e. *good* or *sufficient*) in at least seven subjects per group. This cut-off was chosen to avoid statistical significant differences between groups based on substantial differences in group size. Per-muscle means for MD and FA values were compared among the three groups using a one-way analysis of variance (ANOVA). In case of significant difference ( $P < 0.05$ ) a post-hoc student's T-test with Bonferoni correction ( $P < 0.016$ ) was performed to study the significance among sets of two groups. Inter-rater agreement for the per-muscle quantitative data amongst the two independent observers was assessed using intra-class correlation analysis (ICC).

## Results

From January 2010 to December 2010, thirty women were included in this study. One subject was not willing to complete the MRI examination after a technical interruption of the acquisition procedure. In one subject image quality was poor and therefore fibre-tractography was impossible, leaving 28 subjects for analyses. Baseline characteristics of the cohorts are shown in *Table 1*.

### Qualitative analysis and inter-rater agreement

DTI with fibre-tractography was feasible in the 28 datasets, consequently resulting in 28 unpaired - and 56 paired anatomical structures. Fibre-tractography resulted in a satisfactory anatomical representation of the pubovisceral muscle in 34% (19/56); puborectal muscle in 13% (7/56); superficial transverse perineal muscle in 27% (15/56); ischiocavernosus muscle in 54% (30/56); bulbospongiosus muscle in 43% (12/28) and urethral sphincter



**Figure 1.** (a) Axial T2-weighted image of the pelvic area (ischial tuberosity (*IT*), pubic symphysis (*PS*)) of a 31-year old nulliparous woman, with projected three dimensional (3D) fiber tractography. Fiber tracts representing the anal sphincter complex (*AS*), perineal body (*PB*), transverse perineal muscle (*TP*) and puboperineal muscle (*PPM*). Vector directions are color coded: red indicating the left-right axis, blue the superior-inferior axis and green the antero-posterior axis. (b) An area of compact horizontally orientated fiber-tracts (*red*) is demonstrated on the level of the perineal body (*PB*), when fiber tracts are viewed from left anterolaterally. (c) In the same patient, the vector direction on the level of the anal sphincter complex (*AS*) reflects a predominating left-right (*red*) orientation at the anterior and posterior border and combined antero-posterior and superior-inferior (*blue*) orientation at the lateral border, indicating circular orientation from right lateral (c) and left anterolateral view (d).

complex in 29% (8/28) of the datasets, respectively. No perceptible differences in tractability or non-tractability were found in per-group distributions. The iliococcygeus muscle was rated non-satisfactory in all datasets (56/56). The following anatomical structures were identified in most of the DTI datasets: perineal body 100% (28/28), anal sphincter complex 93% (26/28) and internal obturator muscle 100% (56/56) (Figure 1). Despite the overall non-satisfactory visualization of the global appearance of the pubovisceral muscle in the data sets (37/56), analyses of its subdivisions resulted in a satisfactory visualization of the puboperineal muscle in 23 of the 28 subjects (Figure 2). Both the pubovaginal and puboanal subdivision could not or only insufficiently be tracked.

Substantial overall inter-rater agreement was found for the independent qualitative scores. The overall weighted kappa for all muscle assessments was 0.71(95% CI 0.63–0.78). Qualitative inter-observer agreement for the anatomical structures which met the criteria for quantification was also substantial (PABAK=0.76).

**Table 1.** Baseline characteristics of the study groups

	<i>Nullipara</i>	<i>Age matched controls</i>	<i>Prolapse Group</i>
Subjects per study group	9	9	10
Age	27.7 (3.9)	52.7 (7.4)	58.0 (9.7)
BMI	21.5 (20.5-26.3)	22.2 (19.9-31.4)	24.3 (22.2-35.1)
Parity	0 (0-0)	2 (0-3)	2 (1-3)
<b>POP-Q stage</b>			
<i>Anterior compartment</i>	0 (0-0)	0.5 (0-1)	2 (0-3)
<i>Middle compartment</i>	0 (0-0)	0 (0-1)	0.5 (0-2)
<i>Posterior compartment</i>	0 (0-0)	1 (0-2)	1 (0-2)
<b>PVM injury</b>			
<i>Right</i>	0 (0-0)	0 (0-2)	0 (0-2)
<i>Left</i>	0 (0-0)	0 (0-1)	1 (0-2)

Characteristics are expressed as median (range); *BMI*, body mass index; *POP-Q*, pelvic organ prolapse quantification; *PVM*, pubovisceral muscle

#### *DTI parameters and inter-rater agreement*

No statistical difference was detected in the mean values of MD between asymptomatic nulliparous women, age-matched controls and the prolaps group for the perineal body, anal sphincter complex, internal obturator muscle and the puboperineal muscle (*Table 2*). Mean MD values between groups, ranged from  $1.35 \pm 0.09 \times 10^{-3} \text{mm}^2/\text{s}$  to  $1.52 \pm 0.11 \times 10^{-3} \text{mm}^2/\text{s}$  and FA values between  $0.22 \pm 0.03$  to  $0.27 \pm 0.04$ . Analysis of variance demonstrated no significant differences in mean diffusivity between the three groups for the perineal body, anal sphincter complex and the puboperineal muscle (*Table 2*). Mean FA value for the left obturator muscle was significantly lower in asymptomatic nulliparous women when compared to the prolaps group (mean FA  $0.22 \pm 0.03$  and  $0.27 \pm 0.05$  ( $p < 0.05$ ), respectively) which consequently resulted in a significant difference between these groups for the combined obturator DTI measures (*Table 2*).

**Table 2.** Mean DTI values ± SD were compared between nulliparous -, control - and prolapse group. DTI measures for the internal obturator muscle were combined.

	$\lambda 1$ *	$\lambda 2$ *	$\lambda 3$ *	FA	<i>p</i> -value <sup>a</sup>	MD *	<i>p</i> -value <sup>a</sup>
<b>Perineal body</b>							
<i>Nullipara</i>	1.79±0.18	1.35±0.16	1.00±0.14	0.25±0.06	.203	1.39±0.11	.877
<i>Controls</i>	1.67±0.18	1.29±0.16	1.03±0.16	0.24±0.05		1.36±0.14	
<i>Prolapse</i>	1.90±0.44	1.50±0.38	1.18±0.26	0.24±0.06		1.51±0.36	
<b>Anal sphincter</b>							
<i>Nullipara</i>	1.76±0.13	1.37±0.11	1.08±0.13	0.25±0.04	.881	1.38±0.10	.340
<i>Controls</i>	1.76±0.30	1.40±0.30	1.09±0.22	0.25±0.04		1.42±0.28	
<i>Prolapse</i>	1.70±0.18	1.36±0.11	1.09±0.12	0.22±0.03		1.39±0.12	
<b>Internal obturator muscle†</b>							
<i>Nullipara</i>	1.80±0.16	1.38±0.13	1.12±0.10	0.23±0.03	.013	1.43±0.13	.870
<i>Controls</i>	1.84±0.18	1.39±0.17	1.09±0.16	0.25±0.04		1.44±0.18	
<i>Prolapse</i>	1.91±0.27	1.42±0.17	1.08±0.15	0.27±0.05		1.46±0.15	
<b>Puboperineal muscle</b>							
<i>Nullipara</i>	1.71±0.10	1.31±0.10	1.00±0.09	0.26±0.04	.127	1.35±0.09	.319
<i>Controls</i>	1.74±0.11	1.37±0.15	1.07±0.17	0.27±0.04		1.39±0.14	
<i>Prolapse</i>	1.81±0.27	1.41±0.22	1.14±0.19	0.23±0.05		1.47±0.21	

FA = Fractional Anisotropy; MD = Mean Diffusivity ; \* MD,  $\lambda 1$ ,  $\lambda 2$ ,  $\lambda 3$  are in units of [ x 10<sup>-3</sup> mm<sup>2</sup>/s ] ; <sup>a</sup> statistical differences between-groups using one way-ANOVA test; † DTI measures of left - and right side were combined.

For the perineal body, anal sphincter complex, internal obturator muscle and the puboperineal muscle, the inter-rater agreement and 95% confidence interval (CI) for mean diffusivity and FA are summarized in Table 3. The intra-class correlation coefficient ranged between 0.60 and 0.91, which was interpreted as a substantial inter-rater agreement. Highest correlation between the two observers was found for the perineal body. The pubovisceral muscle status was normal for asymptomatic nulliparous women. Minor muscle injury (accumulated bilateral score 1-3, [18]) was observed for the age-matched control group. Both minor and major muscle injuries (accumulated bilateral score 4-6, [18]) were observed in the prolapse group. Median unilateral scores are expressed in Table 1.

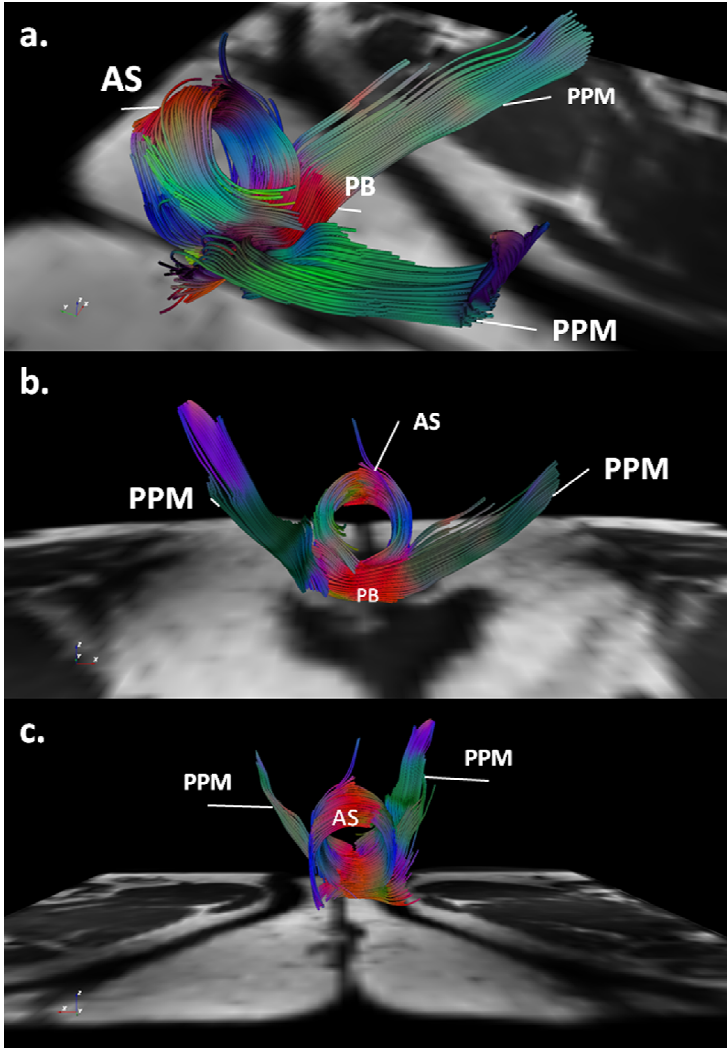
**Table 3.** Inter-rater agreement for Mean Diffusivity (MD) and Fractional Anisotropy (FA). Intra-class correlation coefficient (ICC) and 95% confidence interval (CI) are shown.

	<i>ICC</i>	<i>95% CI</i>
<b>Perineal body</b>		
FA	0.82	0.65 - 0.91
MD	0.91	0.81 - 0.96
<b>Anal sphincter</b>		
FA	0.76	0.55 - 0.88
MD	0.60	0.30 - 0.79
<b>Internal obturator muscle (R)</b>		
FA	0.76	0.55 - 0.88
MD	0.69	0.43 - 0.84
<b>Internal obturator muscle (L)</b>		
FA	0.70	0.44 - 0.85
MD	0.74	0.52 - 0.87
<b>Puboperineal muscle</b>		
FA	0.71	0.44 - 0.86
MD	0.66	0.37 - 0.84

## Discussion

Diffusion tensor imaging (DTI) permits a three-dimensional visualization and quantification of the pelvic floor anatomy, with reliable high-quality tractability of the anal sphincter complex, perineal body, the puboperineal muscle - a subdivision of the pubovisceral muscle - and the internal obturator muscle. However, not all pelvic support structures as initially defined could be reliably tracked. Basic DTI parameters could be determined with substantial inter-observer agreement. No apparent statistical significant differences in mean diffusivity (MD) and fractional anisotropy (FA) were demonstrated in the pelvic floor support between women with symptoms and stage 2 pelvic organ prolapse, women with symptoms and no prolapse and asymptomatic nulliparous controls. DTI characterizes and is able to visualize the local (micro) structural organization within anisotropic tissues, such as brain white matter [19] and striated skeletal muscle [20]. Technical feasibility of 3.0 Tesla DTI with fibre-tractography as a method to visualize the normal female pelvic anatomy was recently reported [8]. In that study, early estimates of the range of mean MD and FA values ( $1.30 \pm 0.08 \times 10^{-3} \text{mm}^2/\text{s}$  to  $1.73 \pm 0.12 \times 10^{-3} \text{mm}^2/\text{s}$  and  $0.23 \pm 0.02$  to  $0.30 \pm 0.04$ ,

respectively) of pelvic floor structures in five healthy nulliparous women were provided. Current derived DTI parameters are concordant with these results.



**Figure 2.** (a) Tractography of the pelvic floor in a 70-year-old women with pelvic organ prolapse, representing the anal sphincter complex (AS), perineal body (PB) and puboperineal muscle (PPM) with an right anterolateral view, (b) anterior –and (c) posterior view. Vector directions are color coded: red= left-right axis; blue=superior-inferior axis; green=antero-posterior axis. Fiber tracts originating from the pubic bone with postero-inferior orientation of the vector as representation of the puboperineal muscle (PPM), reflected as an overall blue and green color coded fiber tract. Both fiber tracts bend medially to insert the perineal body (PB).

The association between levator ani muscle impairment and the presence of pelvic floor prolapse has been recognized [3]. Since DTI has been reported to be valuable in the assessment of muscle fatigue and defects [9], there was particular interest for the tractability of the pubovisceral muscle and its subdivisions (i.e. pubovaginal- , puboperineal- and puboanal muscle [17]), puborectal - and iliococcygeus muscle in the present three study groups. It is known that the iliococcygeus muscle, the most posterior part of the levator ani muscle, is often poorly developed and consequently difficulties in fibre tracking were expected and were confirmed during analyses.

Based on the initial hypothesis, potential alterations of water diffusivity as measured in the levator ani musculature were expected to be found in the prolapse group and to lesser extent in the age-matched group for the pubovisceral muscle. The pubovisceral muscle could be reliably tracked in a third of the women and the non-tractability of the pubovisceral musculature was proportionally distributed over the three study groups. In an earlier published pilot study in normal volunteers the pubovisceral muscle anatomy was globally demonstrated, although the highest variability in mean MD values was found for this muscle ( $1.49 \pm 0.47 \times 10^{-3} \text{mm}^2/\text{s}$ ) and was attributed to its multifaceted organization [8]. The relatively complex architecture of the pubovisceral muscle together with the relative large voxel size and subsequent partial volume effects with potentially bending of effective diffusion vectors, made fibre tracking of the overall pubovisceral muscle in this study rather challenging with current applied MRI techniques. Despite these restrictions, assessment of the pubovisceral muscle resulted in a reliable 3D representation matching the global appearance of the puboperineal muscle anatomy, which appeared as robust fibre trajectories originating from the pubic bone and inserting to the perineal body. Yet, no significant differences were found in DTI measures among groups.

The perineal body, located between the vagina and anal sphincter complex, serves as an anchor point for the pelvic floor. Recently, the anatomy of perineal body has been studied extensively by the Pelvic Floor Research Group with the use of thin-slice 3.0T MRI, in an attempt to enhance our understanding of this centrally located anatomical structure [6]. In that study, 3D models were created based on conventional MRI acquisition methods in women without pelvic floor dysfunction, which allowed organizing the complex anatomy in a superficial, mid and deep part [6]. With the usage of a 5 mm slice thickness we were able to observe the large number of fibre tracts transversing and bending in this complex area. The perineal body anatomy or central perineal tendon [21] could be tracked

in all subjects, demonstrating an area of compact horizontally orientated fibre trajectories located caudally in the midline between the urogenital area and anal sphincter complex. Given the increasing interest in the perineal body, detailed demonstration of this anchor point at DTI could be a potential advantage of this technique.

Due to the uniform left-right orientation of the mean diffusion tensor in this area, the perineal body could easily be identified on colored FA-maps in all subjects and therefore fibre-tracts were obtained with high inter-rater agreement (ICC > 0.80 for mean FA and MD values). This in contrast to the overall pubovisceral muscle, where muscle detection was much less apparent owing to its complex anatomy with closely aligned muscles each with their own distinctive fibre direction. By assessing the different pubovisceral components during the analysis, we were able to overcome multidirectional tracking difficulties to a certain extent.

Significantly higher mean FA values in the left internal obturator muscle were found for women in the prolapse group, if compared to nulliparous women. The principal function of the internal obturator muscle is to abduct the flexed thigh and although it forms the most important element of the pelvic wall, it is not regarded as a pelvic support constituent. Yet, whereas the levator ani musculature anatomically originates partially from the tendinous ridge of the internal obturator muscle fascia, one might hypothesise a possible relation between levator ani muscular defects and subsequent changes in the internal obturator muscle on a microstructural level. In our study most levator ani muscle defects [18] in the prolapse group were observed unilaterally at the left side. Nonetheless, these results are still difficult to interpret.

The DTI fibre tracking process is reported to be highly user-dependent whereas the placement of the seeding ROI and the tracking criteria are determined by the individual observer [22]. By the use of predefined tracking parameters which were applied by both observers, the fibre tract stopping criteria were standardized. Also, by the application of consensus-based reading, an attempt was made to reduce the user dependence of this method. For the anal sphincter complex, perineal body, puboperineal muscle and the internal obturator muscle, high intra-class coefficients were found which can be interpreted as a substantial inter-observer reliability of DTI measures.

This study has recognized limitations. At present, we were not able to compare DTI measures of all clinical relevant anatomical structures of the pelvic floor support among the three groups, owing to the limited fibre tractability of



some anatomical structures. Among others this might be contributed to applied technical parameters and technical improvements may overcome these limitations. The current study was performed using a 3.0 Tesla system, 16 channel surface coil and optimized scanning parameters, but still relatively large voxel dimensions were acquired ( $5 \times 2 \times 2 = 20 \text{ mm}^3$ ) when compared to the commonly small diameter pelvic muscles. By increasing the number of acquisitions for the different encoding directions, an improvement of signal-to-noise ratio (SNR) and fiber-tracking precision can be obtained [23]. However, this will result in prolonged SE-EPI acquisition time ( $>10$  minutes) which is associated with a higher likelihood of motion artifacts. Yet, spatial resolution can be optimized using dedicated coils, permitting the visualization of smaller anatomical structures and to minimize spatial volume effects. The use of an endoanal coil will ultimately result in an improved visualization of the perineal body anatomy and anal sphincter complex, but it will distort the local anatomy while the small effective volume will preclude evaluation of the complete pelvic floor. The latter can be overcome by using a combined pelvic and endoanal coil. Endosonography is widely used in clinical practice and shown to be as accurate as MRI for evaluating anal sphincter lesions [4]. However, this does not allow simultaneous evaluation of the complete pelvic floor support as in MRI.

Based on the published feasibility study [8], we anticipated the detection of (micro) structural differences between the symptomatic and asymptomatic pelvic support at already a small sample size. Yet, our current findings might result from substantial per-subject variation in tissue characteristics.

In conclusion, DTI with fibre-tractography allows for in-vivo 3D visualization of part of the pelvic floor support, with reliable visualization of the anal sphincter complex, perineal body, puboperineal muscle and the internal obturator muscle in women with pelvic organ prolapse (POP) as well as symptomatic age matched controls and asymptomatic nulliparous women. No significant differences were found in extrapolated per-muscle DTI parameters of the pelvic support, amongst the groups. Mean MD and FA values were assessed with substantial consistency by the different observers and overall SDs for the parameters were small. These initial results of DTI and tractography of the pelvic floor support in pelvic organ prolapse are encouraging and could be helpful to provide new insights in pelvic floor abnormalities and expand our three-dimensional understanding of this complex area. Further technical developments can be expected to lead to increased visualization of those muscular structures not or only partly visualized in this series.

### References

1. DeLancey JO, Kane Low L, Miller JM, Patel DA, Tumbarello JA. (2008) Graphic integration of causal factors of pelvic floor disorders: an integrated life span model. *Am J Obstet Gynecol.* 199(6):610.e1-5.
2. Lukacz ES, Lawrence JM, Contreras R, Nager CW, Lubner KM. (2006) Parity, mode of delivery, and pelvic floor disorders. *Obstet Gynecol.* 107(6):1253-60.
3. DeLancey JO, Morgan DM, Fenner DE, et al. (2007) Comparison of levator ani muscle defects and function in women with and without pelvic organ prolapse. *Obstet Gynecol.* 109:295-302.
4. Dobben AC, Terra MP, Slors JF, et al. (2007) External anal sphincter defects in patients with fecal incontinence: comparison of endoanal MR imaging and endoanal US. *Radiology* 242(2):463-471
5. Miller JM, Brandon C, Jacobson JA, et al. (2010) MRI findings in patients considered high risk for pelvic floor injury studied serially after vaginal childbirth. *AJR Am J Roentgenol.* 195(3):786-91.
6. Larson KA, Yousuf A, Lewicky-Gaupp C, Fenner DE, DeLancey JO. (2010) Perineal body anatomy in living women: 3-dimensional analysis using thin-slice magnetic resonance imaging. *Am J Obstet Gynecol.* 203(5):494.e15-21.
7. Boyadzhyan L, Raman SS, Raz S. (2008) Role of static and dynamic MR imaging in surgical pelvic floor dysfunction. *Radiographics* 28(4):949-967.
8. Zijta FM, Froeling M, van der Paardt MP et al. (2011) Feasibility of diffusion tensor imaging (DTI) with fibre tractography of the normal female pelvic floor. *Eur Radiol.* 21(6):1243-9
9. Zaraiskaya T, Kumbhare D, Noseworthy MD. (2006) Diffusion tensor imaging in evaluation of human skeletal muscle injury. *J Magn Reson Imaging.* 24(2):402-408.
10. Kan JH, Heemskerk AM, Ding Z, et al. (2009) DTI-based muscle fiber tracking of the quadriceps mechanism in lateral patellar dislocation. *J Magn Reson Imaging.* 29(3):663-70.
11. Bump RC, Mattiasson A, Bø K, et al. (1996) The standardization of terminology of female pelvic organ prolapse and pelvic floor dysfunction. *Am J Obstet Gynecol.* 175(1):10-7.
12. Uebersax JS, Wyman JF, Shumaker SA, McClish DK, Fantl JA. (1995) Short forms to assess life quality and symptom distress for urinary incontinence in women: The Incontinence Impact Questionnaire and the Urogenital Distress Inventory. *Neurourol Urodyn* 14:131-9.
13. van Brummen HJ, Bruinse HW, van de Pol G, Heintz AP, van der Vaart CH. (2006) Defecatory symptoms during and after the first pregnancy: prevalences and associated factors. *Int Urogynecol J Pelvic Floor Dysfunct* 17(3):224-30.
14. Froeling M et al. Towards a general approach for skeletal muscle DTI acquisition and post-processing. Presented at the 19th Scientific Meeting, International Society for Magnetic Resonance in Medicine. Montreal, May 2011.
15. Aja-Fernandez S, Niethammer M, Kubicki M, Shenton ME, Westin CF. (2008) Restoration of DWI data using a Rician LMMSE estimator. *IEEE Trans Med Imaging.* 27(10):1389-403.
16. Leemans A, Jones DK. (2009) The B-matrix must be rotated when correcting for subject motion in DTI data. *Magn Reson Med.* 61(6):1336-49.

17. Umek WH, DeLancey JO. (2008) MRI of the levator ani muscle. In: Stoker J, Taylor S, DeLancey JO (eds). *Imaging pelvic floor disorders*. Springer Verlag, New York; pp 1-29
18. DeLancey JO, Kearney R, Chou Q, Speights S, Binno S. (2003) The appearance of levator ani muscle abnormalities in magnetic resonance images after vaginal delivery. *Obstet Gynecol.* 101(1):46-53
19. Nucifora PG, Verma R, Lee SK, Melhem ER. (2007) Diffusion-tensor MR imaging and tractography: exploring brain microstructure and connectivity. *Radiology.* 245(2):367-84
20. Froeling M, Oudeman J, van den Berg S, et al. Reproducibility of diffusion tensor imaging in human forearm muscles at 3.0 T in a clinical setting. *Magnetic Resonance in Medicine* PMID: 20725932
21. Stoker J, Wallner C. (2008) The anatomy of the pelvic floor and sphincters. In: Stoker J, Taylor S, De Lancey JOL (eds). *Imaging pelvic floor disorders*. Springer Verlag, New York. pp 1-29
22. Brecheisen R, Platel B, Vilanova A, ter Haar Romeny B. (2009) Parameter sensitivity visualization for DTI fiber tracking. *IEEE Trans Vis Comput Graph.* 15(6):1441-8.
23. Khalil C, Budzik JF, Kermarrec E, Balbi V, Le Thuc V, Cotten A. (2010) Tractography of peripheral nerves and skeletal muscles. *Eur J Radiol.* 76(3):391-7.



# Chapter 9

## Summary, conclusions and implications

### Summary

#### *Part I: MRI of the colon*

In the first part of this thesis we addressed certain aspects of magnetic resonance (MR) colonography, which comprises a method permitting the evaluation of the colon for disorders. **Chapter 2** comprises an overview of the current status of MR colonography in the literature regarding examination indications, image interpretation, applied bowel preparation methods and results of diagnostic accuracy.

In **chapter 3** our objective was to determine accuracy estimates of MR colonography for the detection of colorectal lesions. Also, methodological quality and accuracy of reporting was assessed for proposing future reporting recommendations in this field. Therefore, the available literature of prospective primary studies which have compared the diagnostic accuracy of 1.5T or 3.0T MR colonography to completed colonoscopy in detecting colorectal lesions was systematically reviewed and a meta-analysis was performed. Thirteen studies were included, evaluating 1285 patients with a mean disease prevalence of 44%. The included studies were difficult to compare due to little uniformity in essential study design characteristics, which precluded a meta-analysis of polyp detection for all different size thresholds. We were only able to perform a meta analysis for polyps 10 mm and larger for which the per-patient summary sensitivity and specificity estimates were 88% and 99%, respectively. Therefore, it seems reasonable to assume that MR colonography can play a role in the detection of large colorectal polyps in patients at increased risk of CRC. Based on the considerable heterogeneity in data reporting we encountered during this systematic review, a more standardized reporting is needed in future diagnostic studies on MR colonography.

CT colonography research has documented a wide inter-observer variability in polyp detection between radiologists. Accordingly, diagnostic accuracy is considered to be largely determined by observer performance and double-read strategies might improve sensitivity in CT colonography. Current MR colonography protocols result in a relatively large number of series to be interpreted when compared to CT colonography, potentially leading to reader fatigue and ultimately influences reader performance. In order to explore the role of non-radiologists as potential observers for double-read purposes, we sought to determine if non-radiologists were able to interpret intraluminal findings in MR colonography. In **chapter 4**, MR colonography of 159 patients at increased risk of colorectal cancer were independently assessed by two trained radiographers and

the performance characteristics were compared to those of two trained radiologists in the detection of colorectal polyps. Our data showed no significant differences in detection rates for polyps 10 mm and larger. However combined specificity differed significantly between radiologists and radiographers (96% and 73%, respectively). Although the combined sensitivity rates suggest a comparable diagnostic performance of both the radiologists and radiographers, prior colonography and MRI experience favoured diagnostic outcomes with regard to specificity. Currently no added diagnostic value is to be expected of non-radiologists as potential observers for double-read purposes. More research will have to be performed on the required level of expertise for reading MR colonography since diagnostic accuracy was principally impeded by an inaccuracy in interpretation rather than a technical limitation in visualizing colorectal polyps.

Conventionally, colonic distension in MR colonography literature is mostly achieved by the use of a water enema. In **chapter 5** we evaluated the feasibility of using automated insufflation of carbon-dioxide (CO<sub>2</sub>) for luminal distension at 3.0T MR colonography in fourteen healthy subjects. Furthermore, four different bowel preparation strategies were compared in terms of image quality and burden. Overall, automated CO<sub>2</sub> delivery resulted in an adequate to optimal distension of the colonic segments and was not associated with susceptibility artefacts at air / tissue interfaces. Despite of the usage of a spasmolytic agent, in the fast gradient echo series image quality was influenced by (bowel) motion artefacts, which impeded diagnostic confidence. The type of applied bowel preparation principally determined the overall experienced burden during the MR colonography examination in all four strategies. Although we demonstrated technical feasibility of automated insufflation of CO<sub>2</sub> as luminal distending agent, minimizing bowel motion artefacts is essential to make this technique appropriate for prospective clinical studies.

### ***Part II : MRI of the pelvic floor***

The second part of this thesis focused on the radiological evaluation of the female pelvic floor using different types of MRI techniques to describe the functional pelvic floor support.

In **chapter 6** we assessed the reliability of prolapse staging using dynamic MRI by three differently skilled observers and we compared prolapse stages as assessed on dynamic MRI with a standardized method of clinical prolapse staging (i.e. Pelvic Organ Prolapse Quantification (POP-Q)). In addition we evaluated whether radiological prolapse staging and prolapse staging by physical

examination correlates with manifest pelvic floor symptoms. Therefore, we compared three different groups which consisted of ten patients with pelvic floor symptoms and at least stage 2 prolapse, ten patients with pelvic floor symptoms but prolapse stage 1 or less and ten nulliparous women without pelvic organ prolapse or pelvic floor symptoms. Four predefined reference lines were used for radiological determination of a prolapse (i.e. pubo-coccygeal line (PCL), mid-pubic line (MPL), perineal line and the H-line). We found good to excellent intra-class correlation coefficients between the observers in the anterior and middle compartment, for all applied reference lines. Correlation between MRI and clinical findings were most pronounced in the prolapsed group, but not for all reference lines. In addition the correlation of MRI-based staging and POP-Q with pelvic floor symptoms was non-satisfactory.

Diffusion tensor imaging (DTI) encompasses a distinctive non-invasive method to describe the directionality of the internal microstructure within anisotropic tissues, and its application has been used to visualize and characterise brain white matter tracts and skeletal muscle. In **chapter 7**, we evaluated the feasibility of visualising the normal pelvic floor musculature in five healthy female nulliparous subjects using 3.0T DTI and fibre tractography. In addition, estimates for basic DTI measures (mean eigenvalues ( $\lambda_1, \lambda_2, \lambda_3$ ), fractional anisotropy (FA) and mean diffusivity (MD)) were recorded for isolated muscles. Fibre tractography resulted in an acceptable representation of muscle morphology and fibre orientation of the pubovisceral muscle, perineal body, anal - and urethral sphincter complex and internal obturator muscle in all female subjects. Also, we established a range of anisotropic measures with overall small standard deviations for clinically relevant anatomical structures in the pelvic floor. Therefore, we concluded that DTI with fibre tractography enables the three-dimensional (3D) visualization of the normal female pelvic support.

In exploring the potential clinical applications of diffusion tensor imaging (DTI) and fibre-tractography of the pelvic floor support, our initial hypothesis in **chapter 8** was to demonstrate differences in basic DTI parameters (MD, FA) in the female pelvic floor support in healthy and pathological conditions. Therefore we included three groups of women, consisting of women with pelvic floor symptoms and clinically significant pelvic organ prolapse; women with pelvic floor symptoms but without clinical relevant pelvic organ prolapse and nulliparous women, without pelvic floor related symptoms nor pelvic organ prolapse (same groups as in chapter 6). Fibre-tractography permitted both quantification and comparison of basic DTI-parameters of the anal sphincter



complex, perineal body, the puboperineal muscle - a subdivision of the pubovisceral muscle - and the internal obturator muscle among the three groups and our data showed substantial inter-observer agreement in determine basic DTI parameters of these four anatomical structures. Still, we were able to track only part of the initially defined anatomical structures and from tracked structures no statistical significant differences were found among the three groups. Since tractability and non-tractability of pelvic floor structures proved equally distributed among the three groups in this study, technical limitations as clarification of the limited tractability is presumed rather than morphological alterations of the pelvic floor support. Yet, the fact that fibre tractography was only satisfactory achievable for a relatively small quantity of structures, limits the application of this technique for the moment.

### Conclusions

- Chapter 3.** MR colonography can accurately detect large polyps and masses, yet large clinical trials evaluating MR colonography accuracy are lacking.
- Chapter 4.** Radiographers can perform comparably to radiologists in detecting large polyps at MR colonography, but an added benefit of double-read is not to be expected.
- Chapter 5.** Using automated carbon dioxide (CO<sub>2</sub>) delivery for colonic distension in 3.0T MR colonography is practicable.
- Chapter 6.** Dynamic MRI in prolapse staging is consistent but has an insufficient correlation with both POP-Q findings and clinical symptoms.
- Chapter 7.** 3.0T DTI with fibre tractography permits the three-dimensional visualisation of the normal female pelvic support.
- Chapter 8.** 3.0T DTI with fibre tractography of the female pelvic support has fairly strong inter-observer agreement but does not identify muscle injury.

### Implications

To date, colonoscopy is considered the diagnostic standard to examine the colorectum. For less invasive colorectal evaluation, a number of radiologic imaging examinations have evolved of which CT colonography has proved to provide a similar yield as colonoscopy for colorectal cancer and large polyps. For MR colonography we can conclude that the sensitivity for detection of large

colorectal polyps and colorectal masses is approaching that of CT colonography, and therefore might play a role in the detection of large colorectal polyps. However importantly, MR colonography has not progressed significantly since its introduction with still mediocre results for medium sized lesions and certainly lacks large prospective diagnostic studies. Thereby, there is no broadly accepted, uniform technique. Further, there is a considerable heterogeneity in MR colonography data reporting and therefore the MR colonography research community should adopt similar reporting recommendations to those of CT colonography as far as applicable. In this respect standardised per-patient and per-polyp data presentation and a minimum data set for study level reporting are most essential.

Also, description of observer experience in MR colonography should be refined in MR colonography study reporting. So far, the required level of experience to reach a satisfactory accuracy is not known and has never been evaluated in MR colonography. Moderate diagnostic accuracy as found in our study, was predominantly due to errors in the detection of colorectal abnormalities at MR colonography (lesions were often identified in retrospect), underlining the importance to define both the desired level of expertise and the type of training program. Factors negatively influencing interpretation of MR colonography images include the relatively large number of series that must be read for each data set (which ultimately provokes reader fatigue), and the effects of a relatively wide slice thickness, leading to less reliable identification of especially smaller lesions. Enhancing sensitivity of MR colonography using a double-read strategy with non-radiologists as second readers, does not seem useful. In view of the complexity of MRI interpretation, the actual number of validated cases for training purposes presumably will be substantially higher in MR colonography than in CT colonography and must be established in prospective further research.

Improving accuracy of MR colonography among others includes using state of the art techniques into the current MR colonography scan protocols. High-field abdominal imaging allows for isotropic high spatial resolution and thus the ability to reconstruct acquired 3D data stacks in different orthogonal planes (MPR), consequently resulting in a reduction in number of series to be acquired. The introduction of automated CO<sub>2</sub> insufflation for luminal distension in MR colonography resulted in an adequate colonic distension, and thereby avoids the need of an water-based enema in the MRI suite which is regarded as the most burdensome element of a MR colonography examination. However further prospective clinical studies are necessary to determine the precise diagnostic

performance and acceptance of this technique in MR colonography and must include the addition of intravenous gadolinium contrast medium to increase contrast-to-noise ratios (CNR) between bowel wall and bowel lumen.

In conclusion, the limited availability, higher costs, time, complexity and inferior evidence regarding its role in the detection of medium-sized polyps, are still disadvantages of MR colonography over CT colonography in daily practise. However, continuous technical progress and increasing availability of higher magnetic field-strength MR units allows better image quality and might ultimately lead to an improved accuracy in the evaluation of the colon. Together with new developments, i.e. the implementation of diffusion weighted imaging (DWI), MR lymphography and molecular imaging, MRI of the colon may gain a role in the radiological evaluation of patients at risk for CRC in the near future. In particular upcoming developments of using the versatility of MRI to image cellular and molecular processes, e.g. targeted imaging in colorectal cancer screening, should be studied.

To date, pelvic floor disorders are only partly understood, which is emphasized by the poor correlation between anatomical and functional abnormalities of the pelvic floor. Towards an improved understanding of mechanisms leading to pelvic organ prolapse, a diversity of imaging techniques have been proposed in pelvic floor imaging. With regard to dynamic MR imaging of the pelvic floor, we found an insufficient correlation of dynamic MR imaging with both clinical examination (POP-Q) and symptoms of pelvic organ dysfunction. This is in line with previous studies in this field. Therefore one can question whether dynamic MRI of the pelvic floor provides extra diagnostic information in clinical-decision taking in pelvic organ prolapse. Developments in dynamic imaging of the pelvic floor support in an upright position using open-magnet MR units, thereby simulating normal physiological conditions, might add value to existing protocols. However, given the almost complete lack of such magnets worldwide, this is not a practical solution for this moment.

By introducing DTI in pelvic floor imaging we aimed to describe the pelvic floor integrity using a technique which exceeds the resolution of conventional MR techniques, and was not previously proposed in pelvic floor imaging. Initial feasibility of visualizing the healthy pelvic floor support allowed to study the potential role of DTI in demonstrating alterations in the pelvic organ support in pelvic floor dysfunction. Yet, in our cross-sectional study the power was most likely insufficient to reveal pelvic floor abnormalities and in addition tractography

was attainable in part of the pelvic floor support, ultimately limiting the application of this technique for the moment. In our point of view, DTI and tractography of the pelvic floor does not yet have the ability to be implemented as a diagnostic test on an individual level, among others due to large per-subject variation in tissue characteristics. However, we reported the initial experience and it might be regarded as an evolving non-invasive pre-clinical research tool which is able to provide new insights in pelvic floor abnormalities in the search for possible etiologic factors of pelvic floor dysfunction. We feel that future research should focus on optimizing spatial resolution, to visualize anatomical structures which were currently insufficiently identified, without significant loss of SNR which would ultimately decrease DTI accuracy. Additionally, continuing developments of using high angular resolution diffusion imaging (HARDI) gives new possibilities to enhance DTI of the female pelvic floor.

# Chapter 10

**Samenvatting, conclusies en  
implicaties.**

### Samenvatting

#### *Deel I: MRI van de dikke darm*

In het eerste deel van dit proefschrift hebben we bepaalde aspecten van Magnetic Resonance (MR) colografie beschreven, dit betreft een methode die de beoordeling van de dikke darmafwijkingen mogelijk maakt. **Hoofdstuk 2** bevat een overzicht van de huidige status van MR colografie in de literatuur en betreft de indicaties voor het onderzoek, de beoordeling van het onderzoek, toegepaste methoden voor darmvoorbereiding en de diagnostische accuratesse.

In **hoofdstuk 3** was onze doelstelling het bepalen van de gemiddelde sensitiviteit en specificiteit van MR colografie voor het detecteren van dikke darmafwijkingen. Ook werd de methodologische kwaliteit en nauwkeurigheid van rapportage beoordeeld, om aanbevelingen te doen met betrekking tot toekomstige rapportage over deze techniek. Hiervoor werd de beschikbare literatuur systematisch onderzocht op prospectieve studies welke de diagnostische accuratesse voor het detecteren van dikke darm afwijkingen van 1.5T - of 3.0T MR colografie hebben vergeleken met coloscopie (onderzoek met behulp van een kijkslang). Ook werd een meta-analyse uitgevoerd. Dertien studies, met in totaal 1285 patiënten en een gemiddelde ziekteprevalentie van 44%, werden geïnccludeerd. De geïnccludeerde studies bleken moeilijk vergelijkbaar. Dit in verband met grote verschillen in studieopzet kenmerken, die het uitvoeren van een meta-analyse naar de detectie voor alle verschillende poliepafmetingen (klein, middelgroot of groot) belemmerde. Het was alleen mogelijk om een meta-analyse uit te voeren naar de detectie van poliepen van 10 mm en groter, hiervoor waren de gemiddelde per-patiënt sensitiviteit en specificiteit respectievelijk 88% en 99%. Het lijkt daarom redelijk om te veronderstellen dat MR colografie een rol kan spelen bij het opsporen van grote dikke darm poliepen bij patiënten met een verhoogd risico op colorectaal carcinoom (CRC). Op basis van de aanzienlijke heterogeniteit in data rapportage waar we mee werden geconfronteerd gedurende dit systematische onderzoek, lijkt een meer gestandaardiseerde manier van rapportage nodig bij toekomstige, diagnostische MR colografie studies.

Wetenschappelijk onderzoek naar CT colografie heeft aangetoond dat er tussen radiologen een grote inter-observer variabiliteit bestaat voor het detecteren van poliepen. Daarom wordt er aangenomen dat de diagnostische accuratesse voor een groot deel wordt bepaald door de nauwkeurigheid van waarneming. Strategieën waarin een onderzoek tweemaal worden bekeken door twee verschillende beoordelaars ( zogenaamde 'double-read' strategie), kunnen

mogelijk de sensitiviteit van CT colografie verbeteren. In vergelijking met CT colografie, resulteren de huidige MR colografie protocollen in een relatief groot aantal series die moeten worden geïnterpreteerd, hetgeen kan leiden tot vermoeidheid wat uiteindelijk de prestaties van de beoordelaar kan beïnvloeden. Om de rol van niet-radiologen als potentiële beoordelaar voor een 'double-read' te onderzoeken, hebben wij getracht vast te stellen of niet-radiologen in staat zijn om intraluminale bevindingen in MR colografie te interpreteren. In **hoofdstuk 4** zijn de MR colografie onderzoeken van 159 patiënten met een verhoogd risico op CRC onafhankelijk van elkaar beoordeeld door twee getrainde radiologisch laboranten. De accuratesse voor het detecteren van dikke darmpoliepen werd vergeleken met die van twee getrainde radiologen. Onze data toonden geen significante verschillen in sensitiviteit voor poliepen van 10 mm en groter. Echter de gecombineerde specificiteit verschilde significant tussen radiologen en laboranten (respectievelijk 96% en 73%). Alhoewel de gecombineerde sensitiviteit een vergelijkbare diagnostische accuratesse suggereert tussen zowel de radiologen alsmede de radiologisch laboranten, blijkt ervaring in het beoordelen van colografie onderzoeken en ervaring met MRI de specificiteit te bevorderen. Op dit moment wordt er geen toegevoegde diagnostische waarde verwacht van het inzetten van niet-radiologen als potentiële waarnemers in een 'double-read' strategie. Er zal meer onderzoek moeten plaatsvinden om het vereiste ervaringsniveau voor MR colografie te bepalen, aangezien de diagnostische accuratesse in onze studie vooral negatief werd beïnvloed door diagnostische missers dan door technische beperkingen om een afwijking in beeld te brengen.

De meest gangbare manier om in MR colografie ontplooiing van de dikke darm te bewerkstelligen is door middel van de rectale toediening van water. In **hoofdstuk 5** hebben wij bij veertien gezonde proefpersonen de toepasbaarheid van een geautomatiseerde rectale toediening van koolstofdioxide (CO<sub>2</sub>) onderzocht voor het ontplooien van de dikke darm in 3.0T MR colografie. Bovendien werden vier verschillende soorten darmvoorbereiding met elkaar vergeleken met als uitkomstmaat beeldkwaliteit en de belasting van het onderzoek. Over het algemeen resulteerde de toediening van CO<sub>2</sub> in een voldoende tot optimale uitzetting van de dikke darm segmenten en was dit niet geassocieerd met susceptibiliteitsartefacten op de overgangen van lucht naar weefsel. Ondanks het gebruik van een spasmolytisch middel (middel met spierverslappende werking op het maag-darmkanaal) werd de beeldkwaliteit (vooral in de snelle gradiënt echoseries) beïnvloedt door bewegingsartefacten die

de diagnostische betrouwbaarheid verminderden. Het type darmvoorbereiding bepaalde voornamelijk het ervaren ongemak tijdens het MR colografie onderzoek. Alhoewel wij de technische haalbaarheid van een geautomatiseerde rectale toediening van CO<sub>2</sub> als methode voor ontplooiing van de dikke darm hebben aangetoond, is het minimaliseren van bewegingsartefacten van belang om deze techniek geschikt te maken voor prospectieve klinische studies.

### ***Deel II: MRI van de bekkenbodem***

Het tweede deel van dit proefschrift richtte zich op de radiologische beoordeling van de vrouwelijke bekkenbodem door met behulp van verschillende MRI-technieken de functionele ondersteuning van de bekkenbodem te kunnen beschrijven.

In **hoofdstuk 6** hebben we de reproduceerbaarheid onderzocht van het stadiëren van een verzakking middels dynamische MRI, gebruik makend van drie beoordelaars met een verschillende mate van ervaring. Daarnaast hebben wij de stadiëring van een verzakking zoals vastgesteld met dynamische MRI, vergeleken met een gestandaardiseerde methode van stadiëring van een verzakking (d.w.z. Pelvic Organ Prolapse Quantification (POP-Q)). Ook hebben we geëvalueerd of manifeste bekkenbodemklachten overeenkomen met de mate van verzakking zoals gemeten met dynamische MRI en het lichamenlijk onderzoek. Daarom vergeleken wij drie verschillende groepen. De groepen bestonden uit tien patiënten met bekkenbodemklachten en ten minste een stadium 2 verzakking, tien patiënten met bekkenbodemklachten echter met een stadium 1 verzakking of minder en tien nullipara vrouwen zonder een verzakking of bekkenbodemklachten. Voor het radiologisch bepalen van een verzakking werden vier referentielijnen gebruikt (de pubo-coccygeale lijn (PCL), mid-pubische lijn (MPL), perineale lijn en de H-lijn). In het voorste - en het middelste compartiment vonden wij goede tot uitstekende intra-class correlatie coëfficiënten tussen de verschillende beoordelaars, voor alle toegepaste referentielijnen. Correlatie tussen MRI en klinische bevindingen waren het meest uitgesproken in de groep met verzakking, echter niet voor alle referentielijnen. Ook de correlatie van de stadiëring van een verzakking met behulp van dynamische MRI en POP-Q met bekkenbodemklachten was niet toereikend.

Diffusion Tensor Imaging (DTI) betreft een niet-invasieve methode om de richting van de interne microstructuur binnen anisotrope weefsels te beschrijven. Deze methode is gebruikt voor het visualiseren en karakteriseren van witte stof banen in de hersenen en voor skeletspieren. In **hoofdstuk 7** hebben wij de



toepasbaarheid bepaald van 3.0T DTI en (vezel) tractografie ( driedimensionale reconstructie van het vezel verloop) voor het visualiseren van bekkenbodemspieren in vijf gezonde vrouwelijke proefpersonen. Daarnaast werd voor elke spier apart een schatting gegeven van DTI parameters (gemiddelde eigenwaarden ( $\lambda_1, \lambda_2, \lambda_3$ ), fractionele anisotropie (FA) en de gemiddelde diffusiviteit (MD)). In alle vrouwelijke proefpersonen resulteerde tractografie in een acceptabele weergave van spiermorfologie en vezelrichting van de M. pubovisceralis, perineal body, anale - en urethrale sfincter complex en de M. obturatorius internus. Ook hebben wij voor klinisch relevante anatomische structuren in de bekkenbodempatiënten anisotrope maten vastgesteld, met over het algemeen kleine standaarddeviaties. Concluderend kan worden gesteld dat DTI met tractografie de driedimensionale visualisatie van de normale vrouwelijke bekkenbodemspieren mogelijk maakt.

Op zoek naar de mogelijke klinische toepassingen van DTI en tractografie van de bekkenbodempatiënten, was onze initiële hypothese in **hoofdstuk 8** dat er verschillen in DTI parameters (MD, FA) zouden zijn tussen de vrouwelijke bekkenbodempatiënten in normale - en pathologische omstandigheden. Daarom hebben we drie groepen vrouwen geïncludeerd, bestaande uit vrouwen met bekkenbodempatiëntenklachten en klinisch relevante verzakking; vrouwen met bekkenbodempatiëntenklachten echter zonder klinisch relevante verzakking en nullipara vrouwen, zonder bekkenbodempatiënten gerelateerde symptomen of verzakking (dezelfde groepen zoals beschreven in hoofdstuk 6). Tractografie maakte kwantificering en vergelijking van DTI parameters tussen de drie groepen mogelijk voor het anale sfincter complex, perineal body, M. puboperineus - een van de spieren die deel uitmaakt van de M. pubovisceralis - en de M. obturatorius internus. Er was sprake van een aanzienlijke inter-observer reproduceerbaarheid van DTI parameters voor deze vier anatomische structuren. Niettemin waren wij echter slechts in staat om een deel van de oorspronkelijk gedefinieerde anatomische structuren te reconstrueren en hierin werden geen statistisch significante verschillen aangetoond tussen de drie groepen. De mogelijkheid tot reconstructie van de bekkenbodempatiëntenstructuren bleek in deze studie gelijkmatig verdeeld over de drie groepen. De reden van de beperkte visualisatie wordt derhalve eerder aan de technische beperkingen dan aan onderliggende morfologische veranderingen van de bekkenbodempatiënten toegeschreven. Het feit dat tractografie slechts in een relatief klein aantal anatomische structuren mogelijk was, beperkt de toepassing van deze techniek op dit moment.

### Conclusies

- Hoofdstuk 3.** MR colografie is in staat om nauwkeurig grote poliepen en massa's in de dikke darm te detecteren, echter grootschalige klinische studies ter evaluatie van de accuratesse van MR colografie ontbreken.
- Hoofdstuk 4.** Radiologisch laboranten hebben een vergelijkbare sensitiviteit als radiologen voor het detecteren van grote poliepen op MR colografie, maar waarschijnlijk geen toegevoegde waarde bij een double-read strategie.
- Hoofdstuk 5.** Automatische toediening van koolstofdioxide (CO<sub>2</sub>) voor het ontplooiën van de dikke darm in 3.0T MR colografie is toepasbaar.
- Hoofdstuk 6.** Het stadieren van een verzakking middels dynamische MRI blijkt consistent, maar heeft onvoldoende correlatie met POP-Q bevindingen en klinische symptomen.
- Hoofdstuk 7.** 3.0T DTI met vezel tractografie maakt de driedimensionale visualisatie mogelijk van de normale vrouwelijke bekkenbodemspieren.
- Hoofdstuk 8.** 3.0T DTI met vezel tractografie van de vrouwelijke bekkenbodem is reproduceerbaar, echter niet in staat om spierschade aan te tonen.

### Implicaties

Coloscopie wordt beschouwd als de referentiestandaard voor diagnostiek van de dikke darm. Voor minder invasief onderzoek van de dikke darm zijn een aantal alternatieve beeldvormende onderzoeken ontwikkeld, waarbij is gebleken dat CT colografie een onderzoek is met dezelfde diagnostische mogelijkheden als coloscopie voor colorectale tumoren en grote poliepen. Voor MR colografie kan worden geconcludeerd dat de sensitiviteit voor de detectie van grote poliepen en massa's in de dikke darm nagenoeg dezelfde is als voor CT colografie en dat MR colografie daarom wellicht een rol kan spelen bij het opsporen van grote poliepen. Echter, MR colografie heeft geen belangrijke vooruitgang gekend sinds de eerste introductie in de literatuur, met vooralsnog matige accuratesse voor de detectie van middelgrote poliepen en ontbreekt het aan een grootschalige evaluatie in prospectieve diagnostische studies. Bovendien is er tot op heden nog geen algemeen geaccepteerde gestandaardiseerde techniek. Daarnaast is er een aanzienlijke heterogeniteit in de rapportage in de beschikbare MR colografie literatuur, en moet men overwegen om vergelijkbare aanbevelingen te hanteren

zoals die van CT colografie. In dit opzicht zijn een gestandaardiseerde manier van het presenteren van per-patiënt en per-poliep gegevens, het vaststellen van een minimale dataset grootte en een beschrijving over de mate van ervaring van de beoordelaar essentieel in MR colografie studie rapportage.

Tot op heden, is het vereiste niveau van ervaring voor een adequate sensitiviteit en specificiteit niet bekend en is ook nog nooit geëvalueerd in MR colografie. De matige diagnostische accuratesse voor poliep detectie in ons onderzoek was voornamelijk te wijten aan fouten in de detectie van de afwijkingen bij het MR colografie onderzoek. Dit onderstreept nogmaals het belang om zowel het gewenste niveau van deskundigheid als het type trainingsprogramma te bepalen. Factoren die een negatieve invloed hebben op de interpretatie van de MR colografie beelden zijn het relatief grote aantal series die moeten worden beoordeeld (die uiteindelijk bij de lezer vermoeidheid veroorzaakt), en de effecten van een relatief brede slice-thickness die tot minder betrouwbare identificatie van de afwijking leidt. Het is niet te verwachten dat het gebruik van een double-read strategie door inzet van een niet-radioloog als tweede beoordelaar een verbetering van de accuratesse in MR colografie zal geven. Gezien de complexiteit van de MRI interpretatie zal het aantal gevalideerde cases voor trainingsdoeleinden aanzienlijk hoger zijn in MR colografie dan in CT colografie en zal moet worden vastgesteld in nader prospectief onderzoek.

Verbetering van de diagnostische accuratesse van MR colografie betekent onder meer het gebruik van state-of-the-art technieken in de huidige MR colografie protocollen. Abdominale beeldvorming gebruik makend van een hoge veldsterkte, maakt isotrope, hoge spatiële resolutie mogelijk en daarmee de optie tot het reconstrueren van driedimensionale data sets in de verschillende orthogonale vlakken (MPR). Dit zal bijgevolg resulteren in een vermindering van het aantal te acquireren series. Het introduceren van de geautomatiseerde rectale toediening van koolstofdioxide (CO<sub>2</sub>) in MR colografie, resulteerde in een voldoende ontplooiing van de dikke darm. Dit voorkomt het gebruik van een rectale toediening van vloeistof in de MRI, wat als het meest belastende onderdeel van een MR colografie onderzoek wordt ervaren. Echter nader prospectieve klinische MR colografie studies zijn nodig om de exacte diagnostische accuratesse en acceptatie van deze techniek te bepalen, gebruikmakend van intraveneuze gadolinium contrast toediening om de contrast-to-noise ratio's (CNR) tussen darm wand en darm lumen te verbeteren.

Concluderend: de beperkte beschikbaarheid, hogere kosten, tijd, complexiteit van het onderzoek en onvoldoende bewijs met betrekking tot de rol


in het detecteren van middelgrote dikke darm poliepen zijn belangrijke nadelen van MR colografie ten opzichte van CT colografie in de dagelijkse praktijk. Echter, voortdurende technische vooruitgang en toenemende beschikbaarheid van MRI apparaten met een hoge veldsterkte, zorgen voor een betere beeldkwaliteit en kunnen uiteindelijk leiden tot een verbeterde accuratesse voor de evaluatie van de dikke darm. Tezamen met nieuwe ontwikkelingen, zoals de implementatie van diffusion weighted imaging (DWI), MR lymfografie en molecular imaging, kan MRI van de dikke darm in de toekomst een rol verkrijgen in de radiologische evaluatie van patiënten met een verhoogd risico op CRC. Met name nieuwe ontwikkelingen gebruik makend van de veelzijdigheid van MRI om cellulaire en moleculaire processen te bestuderen (bijv. targeted imaging in CRC), moeten worden onderzocht.

Tot op heden wordt de pathofysiologie van bekkenbodempandoeningen slechts ten dele begrepen, wat ook blijkt uit de slechte correlatie tussen anatomische - en functionele afwijkingen van de bekkenbodem. In de zoektocht naar een beter begrip van de mechanismen die leiden tot verzakking, zijn er in de literatuur een verscheidenheid aan radiologische technieken voorgesteld voor de beeldvorming van de bekkenbodem.

Met betrekking tot dynamische MRI van de bekkenbodem, hebben wij een onvoldoende correlatie gevonden tussen de bevindingen zoals gevonden met MRI en die van het lichamelijk onderzoek (POP-Q) en bekkenbodempklachten. Dit is in overeenstemming met eerder onderzoek op dit gebied. Daarom kan men zich afvragen of dynamische MRI van de bekkenbodem extra diagnostische informatie heeft met betrekking tot de klinische besluitvorming in bekkenbodemproblematiek. De ontwikkelingen in het dynamisch afbeelden van de bekkenbodem in een verticale positie, gebruik makend van een open MRI, waarin een normale fysiologische situatie wordt nagebootst, zou van toegevoegde waarde kunnen zijn in de bestaande protocollen. Echter gezien de beperkte beschikbaarheid van deze MRI's, is dit momenteel geen praktische oplossing.

Door het introduceren van DTI in de beeldvorming van de bekkenbodem, hebben wij gepoogd om de integriteit van bekkenbodem te beschrijven door een techniek te gebruiken die de resolutie van gebruikelijke MRI technieken overschrijdt, en niet eerder is beschreven in de literatuur. De aanvankelijke toepasbaarheid van deze techniek om de normale bekkenbodem te visualiseren, maakte het mogelijk om de rol van DTI te bestuderen in het aantonen van eventuele veranderingen in de bekkenbodemspieren bij bekkenbodemver-

zakking. Echter, in onze studieopzet was de statistische kracht waarschijnlijk onvoldoende om afwijkingen in de bekkenbodem aan te tonen en daarnaast was de tractografie haalbaar in slechts een deel van de structuren. Dit laatste beperkt de klinische toepassing van deze techniek in belangrijke mate. Wat ons betreft heeft DTI van de bekkenbodem nog niet de mogelijkheden om als diagnostische test op individueel niveau te worden toegepast, onder andere vanwege grote, individueel bepaalde variaties in weefsel karakteristieken. We hebben thans onze eerste ervaringen beschreven en deze techniek kan worden beschouwd als een niet-invasieve onderzoeksmethode in ontwikkeling, die nieuwe inzichten kan geven in afwijkingen van de bekkenbodem bij de zoektocht naar mogelijke etiologische factoren van bekkenbodem aandoeningen. Toekomstig onderzoek zal zich moeten richten op het optimaliseren van de spatiële resolutie om zodoende anatomische structuren, die momenteel onvoldoende werden geïdentificeerd, zonder significant verlies van signal-to-noise ratio's (SNR) te visualiseren. Een verlies van SNR kan namelijk de accuratesse van DTI verminderen. Bovendien betekenen voortdurende ontwikkelingen met betrekking tot high angular resolution diffusion imaging (HARDI) mogelijkheden tot verbetering van bekkenbodem DTI.



# Chapter 11

## Appendix

*List of Publications*

*Dankwoord*

*Curriculum Vitae*

### Publications

Tulevski II, **Zijta FM**, Smeijers AS, Dodge-Khatami A, van der Wall EE, Mulder BJ. (2004) Regional and global right ventricular dysfunction in asymptomatic or minimally symptomatic patients with congenitally corrected transposition. *Cardiol Young*. 14(2):168-73.

Vriend JWJ, de Groot E, de Waal TT, **Zijta FM**, Kastelein JJP, Mulder BJ. (2006) Increased carotid and femoral intima-media thickness in patients after repair of aortic coarctation: influence of early repair. *Am Heart J*. 151:242-7.

**Zijta FM**, Bipat S, Stoker J. (2010) Magnetic Resonance (MR) Colonography in the Detection of Colorectal Lesions: a Systematic Review of Prospective Studies. *Eur Radiol*. 20(5):1031-46.

**Zijta FM**, Florie J, Jensch S, Bipat S, Nievelstein RA, Poulus M, Thomassen-de Graaf MA, Montauban van Swijndregt AD, Stoker J. (2010) Diagnostic Performance of Radiographers as compared to Radiologists in Magnetic Resonance Colonography. *Eur J Radiol*. 75(2):e12-7.

van der Paardt MP, **Zijta FM**, Stoker J. (2010) MRI of the colon. *Imaging Med*. 2(2):195-209.

Liedenbaum MH, Denters MJ, **Zijta FM**, van Ravesteijn VF, Bipat S, Vos FM, Dekker E, Stoker J. (2011) Reducing the oral contrast dose in CT colonography: evaluation of faecal tagging quality and patient acceptance. *Clin Radiol*. 66(1):30-7.

**Zijta FM**, Froeling M, van der Paardt MP, Lakeman MM, Bipat S, Montauban van Swijndregt AD, Strijkers GJ, Nederveen AJ, Stoker J. (2011) Feasibility of diffusion tensor imaging (DTI) with fibre tractography of the normal female pelvic floor. *Eur Radiol*. 21(6):1243-9.

**Zijta FM**, Nederveen AJ, Jensch S, Florie J, Bipat S, van der Paardt MP, Montauban van Swijndregt AD, Stoker J. Feasibility of using automated insufflated carbon dioxide (CO<sub>2</sub>) for luminal distension in 3.0T MR colonography. *Eur J Radiol*. *In press*.



Sprengers AM, van der Paardt MP, **Zijta FM**, Caan MWA, Lamerichs RM, Nederveen AJ, Stoker J. The use of continuously MR tagged imaging for automated motion assessment in the abdomen: a feasibility study. *JMRI. In press.*

Lakeman MME, **Zijta FM**, Peringa J, Stoker J, Roovers JPWR. Dynamic Magnetic Resonance Imaging in assessing prolapse, the reliability of assessment and correlation with clinical findings and pelvic floor symptoms. *Submitted.*

**Zijta FM**, Lakeman MME, Froeling M, van der Paardt MP, Borstlap C, Bipat S, Montauban van Swijndregt AD, Strijkers GJ, Roovers JPWR, Nederveen AJ and Stoker J. Evaluation of Pelvic Floor Disorders using 3.0T Diffusion Tensor Imaging (DTI) and Fiber Tractography. *Submitted.*

### ***Chapters:***

**Zijta FM**, Stoker J. MRI of the colon (colonography): results. In: Stoker J, editor. *MRI of the Gastrointestinal tract.* 1st edition. Springer-Verlag Berlin Heidelberg 2010. p 185 – 204.

Van der Paardt MP, **Zijta FM**, Stoker J. Magnetic Resonance Colonography. In: Dachman AH, Laghi A (Editors). *Atlas of Virtual Colonoscopy.* 2nd edition. Springer 2010. p 145 – 154.



## Dankwoord

Veel mensen hebben de afgelopen drie-en-een-half jaar hun medewerking verleend aan de totstandkoming van dit proefschrift. Vanzelfsprekend wil ik de vrijwilligers en patiënten bedanken die aan mijn onderzoek hebben deelgenomen.

Graag zou ik een aantal mensen in het bijzonder willen bedanken.

*Professor dr. J. Stoker, promotor,*

Beste Jaap, vlak voor aanvang van mijn onderzoeksperiode in het AMC hadden wij ons eerste e-mailcontact en was ik direct onder de indruk van de snelheid waarmee ik een antwoord kreeg op mijn e-mail. Jouw discipline, inzicht, creativiteit, kennis en toewijding zijn buitengewoon en van zeer grote waarde geweest voor deze succesvolle constructie van onderzoek en opleiding. Ik heb veel van jou mogen leren en daar ben ik je heel dankbaar voor.

*Dr. A.D. Montauban van Swijndregt, co-promotor,*

Beste Alexander, in het voorjaar 2008 bespraken wij voor het eerst de mogelijkheid van een promotietraject in combinatie met de opleiding radiologie en zie hier het resultaat. Jij bent vanaf het begin overtuigd geweest van het succesvol afronden van een dergelijke constructie, lang voordat ik daar zelf van overtuigd was. Ik wil jou en de maatschap radiologie van het Onze Lieve Vrouwe Gasthuis ontzettend bedanken voor dit vertrouwen en deze geboden kans. Met je toewijding, enthousiasme en kennis bezit je alle eigenschappen van een goede opleider en ben je een groot voorbeeld voor mij.

*Dr. ir. A.J. Nederveen, co-promotor,*

Beste Aart, vanaf het begin was je bij mijn onderzoekstraject betrokken en jouw begeleiding en inzicht omvatten de *kernspin* van dit proefschrift. Ondanks je drukke schema had je altijd even tijd voor mij wanneer ik in het AMC was. Zelfs een korte bespreking met jou leverde altijd nieuwe inspiratie en mogelijkheden op. Ik wil je graag bedanken dat je me hebt geïntroduceerd in de boeiende wereld van de 3.0T MRI. Daarnaast heb ik enorm veel respect voor de wijze waarop jij het gezinsleven combineert met je succesvolle academische carrière.

De leden van de promotiecommissie: Prof. dr. J.S. Laméris, Prof. dr. M.P.M. Burger, Prof. dr. P. Fockens, Prof. dr. R.G.H. Beets-Tan, Dr. C.H. van der Vaart, Dr. J.J. Fütterer wil ik graag bedanken voor de kritische beoordeling van dit proefschrift en de bereidheid om zitting te nemen in mijn promotiecommissie.

*Dr. S. Bipat en M.P. van der Paardt, mijn paranimfen,*

Beste Shandra, jij bent mijn hoop in bange, statistische momenten. Zonder jouw input was de *systematic review* nooit zonder enig commentaar geaccepteerd in de *European Radiology*. Je staat altijd voor mij klaar en bent heel erg belangrijk geweest in de afgelopen periode.

Beste du cheval, ik ken weinig mensen die zo positief in het leven staan als jij. Ondanks alle tegenslagen die jij tot op heden hebt moeten ondervinden in de MR colografie studie, weet jij er toch het maximale uit te halen. Ik ben heel blij dat ik met jou samen heb mogen werken.

*Onderzoekers,*

In de 11 maanden die ik als full-time onderzoeker in het AMC heb doorgebracht, voelde ik mij bij jullie heel erg thuis. Een aantal medeonderzoekers heb ik zien gaan en een aanzienlijk aantal onderzoekers heb ik zien komen. Sebastiaan, Ayso, Adrienne, Chris, Marjolein, Roos, Sanna, Sandra, Jochem, Joppe, Manon, Margriet, Anneloes, Marije, Franceline, Thierry, Marjolein (A&F) en Robbert heel veel dank voor jullie tips & tricks en gezelligheid. Anneke en ook André mogen in dit rijtje uiteraard niet ontbreken.

*Beste Sebastiaan Jensch,*

Chief, in jouw schaduw heb ik getracht om deze OLVG-traditie voort te zetten met dit boekje als resultaat. Dankzij jou is mijn interesse voor de stralingshygiëne geboren. Ik hoop dat we elkaar in de toekomst nog vaak zullen gaan tegenkomen.

*Beste Martijn Froeling,*

Al het goede komt uit het zuiden. Jij bent de perfecte mix van Brabantse gezelligheid en science. Jouw uitstekende kennis van MRI-fysica weet je altijd op zeer didactische wijze te vertalen naar een *basic-MD* niveau. Dank voor je uitleg en geduld.

*Beste Jan Peringa,*

Dank voor het verrichten van een oneindig aantal metingen in de dynamische bekkenbodem. Ik bewonder je kwaliteiten als radioloog en bezieling voor het vak.

*Beste Mariëlle Lakeman,*

Ook jij zit in een part-time onderzoekstraject en bent nu een full-time opleiding aan het combineren met wetenschap. Met jouw gedrevenheid ga je dit gemakkelijk en spoedig voltooien. Ik vind je een goede onderzoeker.


*Lieve vrienden,*

Tim, Eef, Miech, Sieg, Frits, Cath, Butz, Paula, Raaf, Juul, Bart, Martje, Joost, Alexa, Johan, Marloes, Paul, Elsbeth, Thibaut en Caroline, we kunnen nu weer zonder restricties weekendjes en avonden afspreken. Tim, Miech, Raaf en Butz, vanaf 1998 gezamenlijk bezig om ons individuele pad uit te zetten en langzaam naderen wij ons doel. Nu maar eerst eens tijd maken voor een *post-promotie cupje?*

Lieve mam en pap, bedankt voor al jullie onvoorwaardelijke steun en liefde. Zonder jullie steun had ik hier nu niet gestaan. Lieve broers en zusters, nu zien jullie waar ik al die tijd mee bezig ben geweest.

*Mijn dames,*

Lieve Fleur en Jasmijn, jullie zijn mijn alles en het mooiste wat ons is overkomen. Lieve Maaïke, het is af! Dank voor je liefde, steun en je onuitputtelijke geduld. Ik had dit nooit zonder jou kunnen doen. Je hebt heel veel opofferingen moeten doen en daar ben ik je eeuwig dankbaar voor. Maar vanaf nu nooit meer 's avonds of in het weekend achter de computer duiken voor het proefschrift, eindelijk... Nu samen naar Den Haag. Ik hou zielsveel van je.



## Curriculum Vitae

Frank Marinus Zijta is geboren op 29 mei 1977 in Alkmaar. De middelbare school heeft hij doorlopen in Alkmaar op het Petrus Canisius College, waar hij in 1996 zijn V.W.O.-diploma heeft behaald. Van 1996 tot 1998 heeft hij geneeskunde gestudeerd aan de Vrije Universiteit van Brussel, België. In 1998 werd hij ingeloot en startte hij met de studie geneeskunde aan de Universiteit van Amsterdam. Tijdens de studie is hij betrokken geweest bij wetenschappelijk onderzoek op de afdeling Cardiologie in het AMC en is hij werkzaam geweest als research-associate in het Core Echo Lab AMC. Tijdens zijn co-schappen is hij werkzaam geweest als student assistent op de afdeling Anatomie en Embryologie in het AMC. Zijn 'oudste' coschap Chirurgie heeft hij gelopen in het Pretoria Academic Hospital in Zuid-Afrika.

Na afronding van zijn geneeskundestudie in 2005 is hij 4 maanden werkzaam geweest als arts-assistent Cardiochirurgie in het VU Medisch Centrum in Amsterdam. Op 1 augustus 2006 is hij gestart met de opleiding Radiologie in het Onze Lieve Vrouwe Gasthuis in Amsterdam ( opleider: dr. A.D. Montauban van Swijndregt). Tijdens zijn opleiding is hij gestart met onderzoek op de afdeling Radiologie in het AMC onder leiding van prof. dr. J. Stoker, hetgeen heeft geresulteerd in dit proefschrift. Vanaf 1 juli 2012 zal hij als radioloog werkzaam zijn in het MC Haaglanden in Den Haag. Hij woont samen met Maaike en zij hebben samen twee kinderen: Fleur en Jasmijn.

