



UvA-DARE (Digital Academic Repository)

Photodynamic therapy of early stage oral cavity and oropharynx neoplasms: an outcome analysis of 170 patients

Karakullukcu, B.; van Oudenaarde, K.; Copper, M.P.; Klop, W.M.C.; van Veen, R.; Wildeman, M.; Tan, I.B.

DOI

[10.1007/s00405-010-1361-5](https://doi.org/10.1007/s00405-010-1361-5)

Publication date

2011

Document Version

Final published version

Published in

European Archives of Oto-Rhino-Laryngology

License

CC BY-NC

[Link to publication](#)

Citation for published version (APA):

Karakullukcu, B., van Oudenaarde, K., Copper, M. P., Klop, W. M. C., van Veen, R., Wildeman, M., & Tan, I. B. (2011). Photodynamic therapy of early stage oral cavity and oropharynx neoplasms: an outcome analysis of 170 patients. *European Archives of Oto-Rhino-Laryngology*, 268(2), 281-288. <https://doi.org/10.1007/s00405-010-1361-5>

General rights

It is not permitted to download or to forward/distribute the text or part of it without the consent of the author(s) and/or copyright holder(s), other than for strictly personal, individual use, unless the work is under an open content license (like Creative Commons).

Disclaimer/Complaints regulations

If you believe that digital publication of certain material infringes any of your rights or (privacy) interests, please let the Library know, stating your reasons. In case of a legitimate complaint, the Library will make the material inaccessible and/or remove it from the website. Please Ask the Library: <https://uba.uva.nl/en/contact>, or a letter to: Library of the University of Amsterdam, Secretariat, Singel 425, 1012 WP Amsterdam, The Netherlands. You will be contacted as soon as possible.

UvA-DARE is a service provided by the library of the University of Amsterdam (<https://dare.uva.nl>)

Photodynamic therapy of early stage oral cavity and oropharynx neoplasms: an outcome analysis of 170 patients

Baris Karakullukcu · Kim van Oudenaarde ·
Marcel P. Copper · W. M. C. Klop · Robert van Veen ·
Maarten Wildeman · I. Bing Tan

Received: 13 April 2010 / Accepted: 2 August 2010 / Published online: 13 August 2010
© The Author(s) 2010. This article is published with open access at Springerlink.com

Abstract The indications of photodynamic therapy (PDT) of oral cavity and oropharynx neoplasms are not well defined. The main reason is that the success rates are not well established. The current paper analyzes our institutional experience of early stage oral cavity and oropharynx neoplasms (Tis-T2) to identify the success rates for each subgroup according to T stage, primary or non-primary treatment and subsites. In total, 170 patients with 226 lesions are treated with PDT. From these lesions, 95 are primary neoplasms, 131 were non-primaries (recurrences and multiple primaries). The overall response rate is 90.7% with a complete response rate of 70.8%. Subgroup analysis identified oral tongue, floor of mouth sites with more favorable outcome. PDT has more favorable results with certain subsites and with previously untreated lesions. However, PDT can find its place for treating lesions in previously treated areas with acceptable results.

Keywords Oral cancer · Oropharynx cancer · Photodynamic therapy · mTHPC · Early stage neoplasm

Introduction

Photodynamic therapy (PDT) is a relatively new method for management of head and neck neoplasms. Surgery and radiotherapy are long accepted as the standard treatment for head and neck neoplasms with long successful track records [1, 2]. This standard approach has an established success rate approaching 95% for early stage neoplasms [3, 4]. The upper aerodigestive tract has important functions, such as respiration, swallowing and phonation. Standard treatment of the neoplasms of head and neck region, although not frequent with superficial neoplasms, might compromise one or more of these functions. Especially with repeated treatments for recurrent and multiple primaries, these problems become more evident [5–8]. New reconstructive techniques, less invasive surgical modalities such as laser or robot-assisted endoscopic surgery, more precise delivery of radiation with techniques, such as intensity-modified radiation treatment (IMRT) all aim to decrease the morbidity rate [9–12].

PDT is searching its role in the era of conservation surgery. The advantage of PDT is local treatment without long-term systemic effects. The photosensitizing drug is activated by the light delivered directly onto the neoplasm sparing the surrounding normal mucosa. Protection of the surrounding tissue is further assured by shielding with wet sponges or special shielding waxes.

An additional advantage of PDT is that it shows its effect via cytotoxicity rather than destructive effects. This means that when cancer cells are eliminated via apoptosis the extracellular matrix remains forming a scaffold for the

B. Karakullukcu · W. M. C. Klop · M. Wildeman · I. Bing Tan
Department of Head and Neck Oncology and Surgery,
The Netherlands Cancer Institute, Antoni van Leeuwenhoek
Hospital, Amsterdam, The Netherlands

K. van Oudenaarde
Amsterdam Medical Centre,
University of Amsterdam, Amsterdam, The Netherlands

M. P. Copper
Sint Antonius Hospital, Nieuwegein, The Netherlands

R. van Veen
Centre for Optical Diagnosis and Treatment,
Erasmus University, Rotterdam, The Netherlands

B. Karakullukcu (✉)
Afdeling Hoofd Hals Chirurgie, The Netherlands Cancer Institute,
Plesmanlaan 121, 1066 CX Amsterdam, The Netherlands
e-mail: b.karakullukcu@nki.nl

surrounding mucosal tissue to advance over [13, 14]. Scar formation is minimal and the native tissue that replaces the cancer cells maintains its normal functions limiting the functional loss significantly.

Perhaps, the most important aspect of PDT is its repeatability. PDT can be applied to the same area without accumulative destructive effects [15–17]. It also does not negatively effect further treatments, such as radiation or chemotherapy [15], leaving further treatment options open.

Despite these advantages PDT remains unknown to many head and neck oncologists [17–20]. Because PDT is searching its place in the management cascade of head and neck oncology, we believe it is important to have a basic knowledge of what degree of success can be expected in various clinical scenarios. The current paper is aiming to analyze retrospectively a subgroup of patients with early stage oral cavity and oropharynx neoplasms to demonstrate what percentage of success to expect with PDT. This analysis includes neoplasms of different subsites of the oral cavity and oropharynx, primary neoplasms versus recurrences or multiple primary neoplasms in previously conventionally treated fields.

Materials and methods

The registry of patients (294 patients between 1996 and 2008) treated with PDT was retrospectively screened to identify patients with early stage (Tis, T1, T2) oral cavity and oropharynx squamous cell cancers or carcinoma in situ. One hundred and seventy patients were included in the analysis.

All patients were subject to pretreatment evaluation according to the guidelines of our institute.

Pre-treatment work-up

Standard minimum evaluation consisted of biopsy to determine the histological diagnosis of squamous cell cancer or carcinoma in situ (Tis); X-ray of the thorax; ultrasound (US) of the neck and fine-needle aspiration (FNA) to determine nodal metastasis situation. Tumor thickness is measured either by US or magnetic resonance imaging (MRI). The whole surface of the oral cavity tumors are screened with an oral US probe to determine the deepest point of infiltration. Only tumors that have less than or equal to 5 mm depth of invasion were treated with surface PDT. Oropharyngeal tumors could not be reached by US and, therefore, evaluated by the less accurate method of MRI. If the tumors cannot be visualized on the MR images or there is a surface of contrast uptake, but no evidence of deep invasion, the patients received PDT. The cut-off depth of

5 mm is decided to enable treatment of 5 mm margin deeper than the tumor. The total 10 mm is the average depth of penetration of the 652 nm light used to activate the photosensitizer.

The work-up for regional lymphatic status is US of the neck and FNA of suspected lymph nodes. All patients who received PDT had N0 stage according to US criteria. The guidelines of our institute involve no prophylactic neck dissections for T1 and T2 oral cavity tumors if they are candidates for transoral excisions or PDT. The neck node status is followed by US combined with FNA at 6-month intervals. Patients with suspected lymph nodes receive modified radical neck dissection.

Patients were informed of potential benefits and risks of the treatment and instructed about light avoidance measures and supplied with a light meter to measure ambient light. mTHPC (temoporfin, Foscan[®], Biolytec Pharma Ltd., Dublin, Ireland) at a dose of 0.15 mg/kg was injected to a deep vein with slow infusion. Patients were discharged home after the injection. Illumination took place 96 h after the mTHPC injection. Light is delivered by a diode laser at 652 nm. Dose delivered is 20 J/cm² with a fluence rate of 100 mW/cm². Preferred method is to deliver light with one spot delivered via a microlens. If one spot illumination is not applicable due to the shape or location of the neoplasm multiple spots were used. The lesion plus 5 mm margin of normal appearing mucosa is illuminated. All patients received corticosteroids and pain management. Hospital stay depended on the functional limitations after PDT due to location and extent of the neoplasm, as well as edema due to PDT.

Tumor response is analyzed according to the World Health Organization (WHO) criteria [20]:

Complete response (CR): the disappearance of all known disease

Partial response (PR): 50% or more decrease in the dimensions of the tumor

No response (NR): less than 50% decrease or less than 25% increase in tumor dimensions

Progressive disease (PD): 25% or more increase in the size of one or more measurable lesions or the appearance of new lesions

All responses have to be confirmed by two observations not <4 weeks apart. Overall response (OR) is the sum of complete and partial responders.

Follow-up

There is a follow-up schedule of 1, 2, 4, 8, 16, 24, 36, 52 weeks after PDT, followed by routine controls every 4 months for a total of 5 years.

Results

Patients

Of the 170 patients evaluated, 80 were female and 90 were male. The average age at treatment was 60.5 years. A total of 226 neoplasms was treated with PDT, 35 patients are treated for 2 or more neoplasms. Of the evaluated neoplasms, 95 were primary neoplasms, 131 were non-primary neoplasms consisting of 65 recurrences, 46 s, 9 third and 3 fourth primary neoplasms and of 8 residual neoplasms after initial treatment. Previous treatments within the non-primary neoplasm group ($n = 131$) include: radiotherapy 48.1%, chemoradiation 22.7%, surgery 75.6% and previous PDT 30.6%.

Tumor response

The OR rate for all neoplasms is 90.7% (95% CI 86.2–94.2%) with a CR rate of 70.8% (95% CI 64.4–76.6%). In Table 1, the responses are listed per site, per stage and primary or non-primary. The median local disease-free interval for all of the CR cases is 102.0 months (95% CI 89.6–114.3 months). 2- and 5-year local disease-free survival rates are 74 and 61%, respectively.

Analysis per T classification

Tis lesions have an OR rate of 94.5% (95% CI 86.6–98.5%), with a CR rate of 79.5% (95% CI 68.4–88.0%); T1 neoplasms have an OR rate of 90.9% (95% CI 84.3–95.4%) with a CR rate of 68.6% (95% CI 59.5–76.7%); and for the T2 neoplasms, the OR rate is 81.3% (95% CI 63.6–92.8%) with a CR of 59.4% (95% CI 40.7–76.3%). The variations in tumor response between the stages are only statistically significant for Tis versus T2 stage tumors ($P < 0.05$). The mean local disease-free interval is 65.7 months (95% CI 49.3–82.2 months) for the Tis group, 109.1 months (95% CI 93.1–125.0 months) for T1 and 113.4 months (95% CI 81.9–144.9 months) for T2 (Fig. 1). The mean survival time is 92.2 months (95% CI 79.3–105.0 months) for dys/CIS, 98.4 months (95% CI 84.6–112.2 months) for T1 and 78.7 months (95% CI 54.2–103.2 months) for T2 tumors.

Sub-site analysis

In Table 1, an overview of all treated sites is shown. The CR rate is highest for the oral tongue site [94.4% (95% CI 81.3–99.3%)], the floor of mouth [76.9% (95% CI 64.8–86.5%)] and the soft palate [75.9% (95% CI 56.5–89.7%)] and lowest for the nasal cavity [37.5% (95% CI 0.9–75.5%)], the alveolar process [42.1% (95% CI 20.3–66.5%)] and the

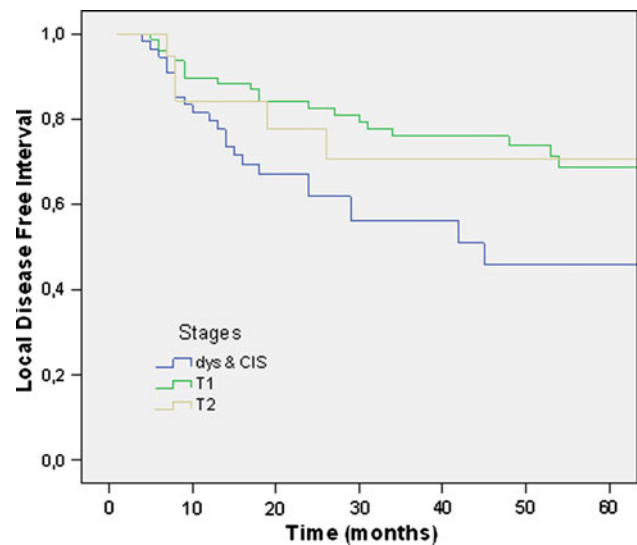


Fig. 1 Local disease-free interval per T stage of neoplasms

buccal mucosa [57.7% (95% CI 36.9–76.7%)]. Oral tongue has significantly better response rate than the rest of the group ($P < 0.05$) and alveolar process has significantly lower response rate than the rest of the group ($P < 0.05$).

Primary neoplasms versus non-primary neoplasms

Primary neoplasms have an OR rate of 96.8% (95% CI 91.1–99.3%) with a CR rate of 77.9% (95% CI 68.2–85.8%). For the non-primary neoplasms, the OR rate is 86.2% (95% CI 79.2–91.7%) and the CR rate is 65.6% (95% CI 56.9–73.7%).

Neoplasms located in an irradiated field ($n = 64$) have a CR rate of 57.8% (95% CI 44.8–70.1%); neoplasms located in an area that was treated before with surgery ($n = 99$) have a CR rate of 62.6% (95% CI 52.3–72.2%). There is no statistical difference.

The mean local disease-free interval for the primary neoplasms with a CR is 117.8 months (95% CI 102.1–133.6 months). For the non-primary neoplasms with a CR, the interval is 84.9 months (95% CI 67.2–102.7 months). 1, 2 and 5-year survival of patients with primary neoplasms are 90, 85 and 74%, respectively. For non-primary neoplasms disease-free survival at 1, 2 and 5 years are 81, 64 and 48%, respectively (Fig. 2). The difference in local disease-free survival for primary neoplasms versus non-primary neoplasms is statistically significant ($P < 0.001$).

The overall mean survival time for the primary neoplasms was 120.4 months (95% CI 106.4–134.4 months) and for the non-primary neoplasms, this was 82.1 months (95% CI 67.7–96.5 months) (Fig. 3). The difference in survival time for primary neoplasms versus non-primary neoplasms is statistically significant with $P < 0.05$.

Table 1 Overall and complete clinical responses to PDT per T stage and site

SITE	Stage															
	Dysplasia				T1				T2				All stages			
	OR		CR		OR		CR		OR		CR		OR		CR	
	OR/n	%	CR/n	%	OR/n	%	CR/n	%	OR/n	%	CR/n	%	OR/n	%	CR/n	%
Floor of mouth <i>n</i> = 65																
Total	24/25	96.0	22/25	88.0	29/30	96.7	20/30	66.7	9/10	90.0	8/9	80.0	62/65	95.4	50/65	76.9
Primary	7/7	100	6/7	85.7	20/20	100	13/20	65.0	6/6	100	5/6	83.3	33/33	100	24/33	72.7
Non-primary	17/18	94.5	16/18	88.9	9/10	90.0	7/10	70.0	3/4	75.0	3/4	75.0	29/32	90.6	26/32	81.3
Oral tongue <i>n</i> = 36																
Total	12/12	100	10/12	83.3	24/24	100	24/24	100	–	–	–	–	36/36	100	34/36	94.4
Primary	5/5	100	4/5	80.0	17/17	100	17/17	100	–	–	–	–	22/22	100	21/22	95.5
Non-primary	7/7	100	6/7	85.7	7/7	100	7/7	100	–	–	–	–	14/14	100	13/14	92.9
Soft palate <i>n</i> = 29																
Total	8/8	100	8/8	100	14/15	93.3	10/15	66.7	4/6	66.7	4/6	66.7	26/29	89.7	22/29	75.9
Primary	2/2	100	2/2	100	7/7	100	4/7	57.1	2/3	66.7	2/3	66.7	11/12	91.7	8/12	66.7
Non-primary	6/6	100	6/6	100	7/8	87.5	6/8	75.0	2/3	66.7	2/3	66.7	15/17	88.2	14/17	82.4
Buccal mucosa <i>n</i> = 26																
Total	4/5	80.0	3/5	60.0	13/15	86.7	10/15	66.7	6/6	100	2/6	33.3	23/26	88.5	15/26	57.7
Primary	–	–	–	–	7/8	87.5	5/8	62.5	3/3	100	0/3	0	10/11	90.9	5/11	45.5
Non-primary	4/5	80	3/5	60.0	6/7	85.7	5/7	71.4	3/3	100	2/3	66.7	13/15	86.7	10/15	66.7
Oropharynx <i>n</i> = 26																
Total	5/7	71.4	4/7	57.1	11/13	84.6	9/13	69.2	6/6	100	4/6	66.7	22/26	84.6	17/26	65.4
Primary	3/3	100	3/3	100	4/4	100	4/4	100	–	–	–	–	7/7	100	7/7	100
Non-primary	2/4	50.0	1/4	25.0	7/9	77.8	5/9	55.6	6/6	100	4/6	66.7	15/19	78.9	10/19	52.6
Alveolar process <i>n</i> = 19																
Total	10/10	100	6/10	60.0	4/7	57.1	2/7	28.6	0/2	0	–	–	14/19	73.7	8/19	42.1
Primary	1/1	100	1/1	100	1/1	100	1/1	100	0/1	0	–	–	2/3	66.7	2/3	66.7
Non-primary	9/9	100	5/9	55.6	3/6	50.0	1/6	16.7	0/1	0	–	–	12/16	75.0	6/16	37.5
Retromolar trigon <i>n</i> = 9																
Total	3/3	100	3/3	100	5/5	100	2/5	10.0	1/1	100	1/1	100	9/9	100	6/9	66.7
Primary	2/2	100	2/2	100	2/2	100	2/2	100	1/1	100	1/1	100	5/5	100	5/5	100
Non-primary	1/1	100	1/1	100	3/3	100	0/3	0	–	–	–	–	4/4	100	1/4	25.0
Hard palate <i>n</i> = 8																
Total	3/3	100	2/3	66.7	5/5	100	3/5	60.0	–	–	–	–	8/8	100	5/8	62.5
Primary	1/1	100	1/1	100	1/1	100	1/1	100	–	–	–	–	2/2	100	2/2	100
Non-primary	0/2	0	0/2	0	4/4	100	2/4	50.0	–	–	–	–	6/6	100	3/6	50.0
Nasal cavity <i>n</i> = 8																
Total	–	–	–	–	5/7	71.4	3/7	42.9	0/1	0	–	–	5/8	62.5	3/8	37.5
Primary	–	–	–	–	–	–	–	–	–	–	–	–	–	–	–	–
Non-primary	–	–	–	–	5/7	71.4	3/7	42.9	0/1	0	–	–	5/8	62.5	3/8	37.5
Subtotal																
Primary	21/21	100	19/21	90.5	59/60	98.3	47/60	78.3	12/14	85.7	8/14	57.1	92/95	96.8	74/95	77.9
Non-primary	48/52	92.3	39/52	75.0	51/61	83.6	36/61	59.0	14/18	77.8	11/18	61.1	113/131	86.3	86/131	65.6
Total	69/73	94.5	58/73	79.5	110/121	90.9	83/121	68.6	26/32	81.3	19/32	59.4	205/226	90.7	160/226	70.8

OR overall response, CR complete response, OR/n number of overall response/total number of patients treated in this subgroup, CR/n number of complete responders/total number of patients treated in this subgroup

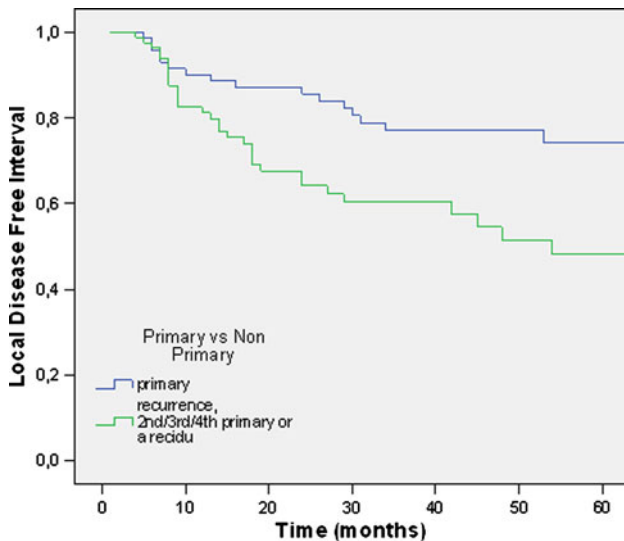


Fig. 2 Local disease-free interval, comparing primary neoplasms versus non-primary neoplasms

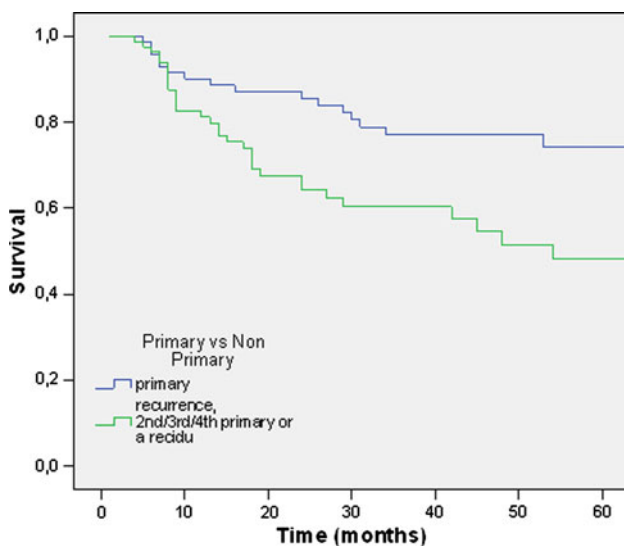


Fig. 3 Overall survival, comparing primary neoplasms versus non-primary neoplasms

Regional recurrence

A total of 42 patients (24.7%) had neck metastasis diagnosed by US and FNA and subsequently treated with neck dissection. Eighteen of these patients (10.5%) had a neck metastasis combined with a second primary neoplasm or local recurrence. The staging of the neck after neck dissection was N1 in 26 patients, N2b in 14 patients, and N2c in 2 patients. There was no N3 or inoperable neck metastasis detected in this patient series.

Adverse events

Three patients had second degree burn wounds as a result of failure to comply by light protection guidelines. All of

the burn wounds healed with conservative measurements. Nine patients had permanent discoloration at the injection site of mTHPC. Five patients had scar formation in the buccal mucosa leading to mild/moderate trismus. These patients were managed with conservative measures involving stretching exercises. Twelve patients had to receive temporary nasogastric sonda feeding for an average time of 5 days because of inability to swallow. The healing process after PDT takes 2–5 weeks and the wound heals with minimum scarring after this period. There were no systemic or serious adverse events.

Discussion

Photodynamic therapy has been used in head and neck oncology for some time with reported success [17–19, 21–31]. Unfortunately, there are no studies comparing PDT with standard treatment methods, such as surgical resection and radiation therapy. Up to date, all data are over developing the technique of PDT and not actually comparing it with other methods. The overall clinical response rate after PDT as determined by the present analysis is below the reported success rates of surgery or radiation treatment [1–4]. The real reason is very difficult to determine. The patient groups are not comparable and furthermore additional treatments, such as re-excision for positive resection margins and postoperative radiation is often included in the disease-free survival analysis. The current analysis is focusing on finding favorable conditions for PDT and, therefore, excluding additional treatments, such as surgical resections from disease-free survival analysis (these patients are computed as failures). The ideal setup for such a comparison would be randomised study comparing surgical resection with PDT. However, for this purpose favorable situations, where PDT can be preferred over surgery, have to be identified.

The PDT literature fails to identify these favoured areas because of the small numbers of treated patients and the heterogeneity of treated groups making it impossible to give a clear answer to the question of what to treat and maybe more importantly what not to treat. These are all preliminary studies that were done to establish treatment protocols for PDT and subsequently treat patients to reach larger series. The results of such larger series are recently becoming available to us.

The longest experience is with photofrin-mediated PDT with the largest series published by Biel with 276 patients [28]. This series include laryngeal and oral cavity neoplasms with T1-3 N0 cancers. The CR rates are impressive with 91% for laryngeal neoplasms and 94% for oral cavity tumors. However, there is no subgroup analysis to show if certain subgroups of neoplasms react better.

It is possible to extend the limits of PDT with mTHPC, which is activated with 652 nm light enabling deeper tissue penetration and providing treatment of deeper neoplasms [32]. A prospective multinational multi-institutional study with mTHPC-PDT was carried out with the participation of our institute [29]. The aimed group was patients with small neoplasms of the oral cavity with <25 mm of diameter and <5 mm depth of invasion. This group of well selected oral cavity tumors showed CR to mTHPC-PDT at a rate of 85% which is surprisingly lower than photofrin PDT [28].

The 5 mm cut-off limit is arbitrary. The international multicentre study carried out by D’Cruz et al. applied PDT to tumors deeper than 10 mm depth of invasion [30]. Treatment of deeper tumors (up to 50 mm) was justified by the aim of the study, which was to provide palliation to incurable head and neck cancers by conventional methods. This great range of thickness enabled the authors to compare tumors with <10 mm depth to tumors with >10 mm depth. Among completely illuminated lesions with <10 mm depth had a much better response than deeper tumors, with CR of 60 versus 26% and OR of 75 versus 40%. It is a pity that they did not choose 5 mm depth as their comparison parameter, but we still get the idea that depth of the lesion is very important.

The choice method we use to determine the depth of the tumor is ultrasound. Endoscopic US is being used to stage several digestive system cancers, such as anal cancers with proven accuracy [33]. Shintani et al. [34] showed that intra-oral US measurements of depth of tumor correlate well with histologic specimens. The whole surface of the tumor should be screened with US not to miss any spot deeper than 5 mm. The inaccuracy of the US (if there is any) is compensated by PDT reaching 10 mm depth. The real problem is with oropharyngeal cancers, where the US probe cannot reach or cannot scan the entire surface. MRI can be used to determine depth. If the tumor cannot be seen on MR images or appear just as a contrast uptake, although there is no evidence to support it and it can be assumed that the tumor is <5 mm deep. This method is by no means accurate and has to be replaced by another method. Introduction of newer methods, such as optical coherence tomography (OCT) might help in the future.

Location of the neoplasm

Oral cavity and oropharynx are not homogenous structures that have constant tissue characteristics. The tissue composition of the alveolar process is clearly different than that of the tongue or soft palate. Furthermore, some areas in the oral cavity and pharynx are flat while others have a complex geography. Multiple spots might have to be used to illuminate all the extensions of the neoplasm, theoretically making the chance of geographic miss greater.

It is, therefore, important to designate the favorable sub-sites of the oral cavity and oropharynx. The only sub-site that reacts significantly better is oral tongue. The reason is probably the relative homogeneity of the tissue with the absence of nearby bony structures, as well as the relative ease of delivering the light in a homogeneous manner on the flat surface.

Floor of mouth and soft palate have a more complex anatomy than the oral tongue with proximal bony structures (i.e. mandible and hard palate) probably causing lower CR rates. Buccal mucosa has a relatively flat surface providing ease of illumination with a rather homogenous structure with no apparent reason for a poorer outcome than the oral tongue. Although a statistic comparison is not carried out, buccal mucosa is also observed to have more scar tissue causing mild trismus (5/23 patients).

As can be expected, the neoplasms of the alveolar process have less CR rate than the overall mean. Alveolar process has a more complex anatomy with underlying mandible and has three surfaces making homogenous illumination harder to achieve. However, it can be argued that the OR rate of 73.7% helps in reducing the size of the neoplasm and enable a smaller excision subsequently.

The study by Hopper et al. [29] is the only publication reporting success rates for subsites, with CR rates of 89% for floor of mouth, 83% for lip, 93% for anterior tongue and 83% for buccal mucosa. There are publications that report failures in certain sites, but the numbers are very low to draw any conclusions [27].

The numbers of retromolar trigon, hard palate and nasal cavity neoplasms treated with PDT are not enough to do a statistical analysis (9, 8 and 8 patients, respectively). However, the CR rates of the retromolar triangle (66.7%) and hard palate (62.5%) are near the overall mean (70.8%).

The tumors of the oral tongue, which has the best results to PDT, are also usually easily resectable with minimum morbidity making PDT an unlikely candidate for initial therapy. Sites that would have functional problems after surgical resection, such as alveolar process and soft palate, although have lower response rates to PDT might be treated with PDT as initial treatment to avoid the functional problems, reserving surgery and/or radiation treatment for failures.

T stage

It can be an expected result because as the neoplasm area gets larger delivering light evenly gets harder and the risk for geographic miss gets greater. In our series, we do not observe such a difference. Although T1 tumors have a better CR rate than T2 tumors this is not statistically different (Table 1). Therefore, we can say that the size of the tumor does not make a difference as long as all of the tumor can be fully illuminated and the depth of invasion is <5 mm.

In our series, Tis show a higher CR rate than T1 and T2 tumors with 79.5%. Tis recur much earlier than T1 and T2 tumors (mean disease-free interval of 65.7 months for dysplasia versus 109.1 months for T1 and 113.4 months for T2 tumors) (Fig. 1). It is well known that patients with Tis of the upper aerodigestive tract are prone to develop new leukoplakia a number of times [35]. It should be kept in mind that PDT can be repeated a number of times with minimal morbidity to treat leukoplakia as they recur. The success of repeated treatments as lesions recur becomes evident by the similar survival rates of patients with Tis and T1 neoplasms. The difference in disease-free interval is made up for either by successful re-treatments or the relatively less lethal nature of Tis.

Recurrences and multiple primary neoplasms

Recurrences and multiple primary neoplasms pose a challenge to the head and neck oncologist. Most of these lesions occur in the previously irradiated or operated fields [36, 37]. The study by D’Cruz et al. focused on such patients who had refractory neoplasms of the head and neck area that were unsuccessfully treated or unsuitable for conventional treatments [30]. They report 38% OR and 16% CR. It should be noted that this study was a multicentre, multinational study with vague inclusion criteria, resulting in treatment of neoplasms that may not be suitable for surface PDT. When the lesions that were not fully illuminated and deeper than 10 mm were excluded they report an OR rate of 54% with 30% CR rate.

In our series, a total of 131 recurrent, second, or multiple primary neoplasms were treated with PDT. Even though non-primary neoplasms respond less favorably to PDT than primary neoplasms (65.9 vs. 77.9% CR, respectively, $P < 0.05$), 65.9% CR is a considerable success if we take into account that the treated area received radiation in 48.1%, chemoradiation in 22.7% and previous surgery in 75.6% of the patients. Furthermore, there is an 86.3% OR which means that an additional group of lesions decrease in size which makes subsequent surgical resection smaller. The difference with the study by D’Cruz et al. can be accounted to the more conservative selection criteria by our group.

Management of neck nodes

Elective treatment of N0 neck in case of early oral cavity cancers is a point of debate. Studies comparing elective neck dissection with wait and see policy show no difference in overall survival [38]. In experienced hands, US of the neck combined with FNA can reach a sensitivity of 73% and a specificity of 100% [39]. We adopted the wait and see policy for patients staged as N0 by US of the neck. Neck

recurrences can be detected by regular US and FNA controls and the patients can receive subsequent neck dissections. This approach resulted in 24.7% patients receiving neck dissections. All of these patients had resectable neck nodes which were adequately removed after neck dissections. The number is quite high if you take into consideration that the tumors in question are thinner than 5 mm. This phenomenon can be explained with the association of the neck recurrence with second primary or recurrent tumors in almost half of the cases. It can be speculated that only 13% of the patients had neck recurrences that are associated with the tumor treated by PDT. Depending on the preference and policies of the center, elective neck dissection can be combined with PDT. The neck dissection has to be done either before PDT or 2–3 weeks after PDT. There is no evidence to prefer one timing over the other.

Conclusion

Our institutional experience supports the value of temoporfin-PDT in carefully selected patients. The success rate of PDT is independent of T stage as long as the depth of invasion does not exceed 5 mm. Although tongue tumors respond best to PDT, areas that would have functional problems after resection such as palatum molle, alveolar process, retromolar trigon can be first treated with PDT to avoid morbidity and reserving surgery and/or radiation for failures/recurrences. Difficult to treat lesions such as recurrent neoplasms and multiple primary neoplasms located in previously irradiated or operated fields have a very acceptable CR rate with minimum morbidity, provided that they are carefully selected for eligibility.

Acknowledgments The study is not financially supported by any grant. The authors have no financial disclosures.

Conflict of interest None.

Open Access This article is distributed under the terms of the Creative Commons Attribution Noncommercial License which permits any noncommercial use, distribution, and reproduction in any medium, provided the original author(s) and source are credited.

References

1. Oliver RJ, Clarkson JE, Conway DI, Glenny A, Macluskey M, Pavitt S et al (2007) Interventions for the treatment of oral and oropharyngeal cancers: surgical treatment. *Cochrane Database Syst Rev* 4:CD006205
2. Wildt J, Bjerrum P, Elbrond O (1989) Squamous cell carcinoma of the oral cavity: a retrospective analysis of treatment and prognosis. *Clin Otolaryngol Allied Sci* 14(2):107–113
3. Inagi K, Takahashi H, Okamoto M, Nakayama M, Makoshi T, Nagai H (2002) Treatment effects in patients with squamous cell carcinoma of the oral cavity. *Acta Otolaryngol Suppl* 547:25–29

4. Wolfensberger M, Zbaeren P, Dulguerov P, Muller W, Arnoux A, Schmid S (2001) Surgical treatment of early oral carcinoma—results of a prospective controlled multicenter study. *Head Neck* 23(7):525–530
5. Blair EA, Callender DL (1994) Head and neck cancer. The problem. *Clin Plast Surg* 21(1):1–7
6. Mlynarek AM, Rieger JM, Harris JR, O'Connell DA, Al Qahtani KH, Ansari K et al (2008) Methods of functional outcomes assessment following treatment of oral and oropharyngeal cancer: review of the literature. *J Otolaryngol Head Neck Surg* 37(1):2–10
7. Patton DW, Ali A, Davies R, Fardy MJ (1994) Oral rehabilitation and quality of life following the treatment of oral cancer. *Dent Update* 21(6):231–234
8. Rogers SN, Lowe D, Fisher SE, Brown JS, Vaughan ED (2002) Health-related quality of life and clinical function after primary surgery for oral cancer. *Br J Oral Maxillofac Surg* 40(1):11–18
9. Lee NY, Le QT (2008) New developments in radiation therapy for head and neck cancer: intensity-modulated radiation therapy and hypoxia targeting. *Semin Oncol* 35(3):236–250
10. Genden EM, Rinaldo A, Suarez C, Wei WI, Bradley PJ, Ferlito A (2004) Complications of free flap transfers for head and neck reconstruction following cancer resection. *Oral Oncol* 40(10):979–984
11. Langius A, Bjorvell H, Lind MG (1994) Functional status and coping in patients with oral and pharyngeal cancer before and after surgery. *Head Neck* 16(6):559–568
12. Glanzmann C, Gratz KW (1995) Radionecrosis of the mandibula: a retrospective analysis of the incidence and risk factors. *Radiother Oncol* 36(2):94–100
13. Yow CM, Chen JY, Mak NK, Cheung NH, Leung AW (2000) Cellular uptake, subcellular localization and photodamaging effect of temoporfin (mTHPC) in nasopharyngeal carcinoma cells: comparison with hematoporphyrin derivative. *Cancer Lett* 157(2):123–131
14. Henderson BW, Bellnier DA (1989) Tissue localization of photosensitizers and the mechanism of photodynamic tissue destruction. *Ciba Found Symp* 146:112–125
15. Dougherty TJ, Marcus SL (1992) Photodynamic therapy. *Eur J Cancer* 28A(10):1734–1742
16. Hornung R, Walt H, Crompton NE, Keefe KA, Jentsch B, Perewusnyk G et al (1998) m-THPC-mediated photodynamic therapy (PDT) does not induce resistance to chemotherapy, radiotherapy or PDT on human breast cancer cells in vitro. *Photochem Photobiol* 68(4):569–574
17. Hopper C (2000) Photodynamic therapy: a clinical reality in the treatment of cancer. *Lancet Oncol* 1:212–219
18. Nyst HJ, Tan IB, Stewart FA, Balm AJ (2009) Is photodynamic therapy a good alternative to surgery and radiotherapy in the treatment of head and neck cancer? *Photodiagn Photodyn Ther* 6(1):3–11
19. Lou PJ, Jones L, Hopper C (2003) Clinical outcomes of photodynamic therapy for head-and-neck cancer. *Technol Cancer Res Treat* 2(4):311–317
20. Miller AB, Hoogstraten B, Staquet M, Winkler A (1981) Reporting results of cancer treatment. *Cancer* 47(1):207–214
21. Dilkes M, DeJode M, Rowntree-Taylor A, McGilligan J, Kenyon G, McKelvie P (1996) m-THPC photodynamic therapy for head and neck cancer. *Lasers Med Sci* 11(1):23–29
22. Kubler AC, Scheer M, Zoller JE (2001) Photodynamic therapy of head and neck cancer. *Onkologie* 24(3):230–237
23. Dilkes MG, Benjamin E, Ovaisi S, Banerjee AS (2003) Treatment of primary mucosal head and neck squamous cell carcinoma using photodynamic therapy: results after 25 treated cases. *J Laryngol Otol* 117(9):713–717
24. Fan KF, Hopper C, Speight PM, Buonaccorsi GA, Bown SG (1997) Photodynamic therapy using mTHPC for malignant disease in the oral cavity. *Int J Cancer* 73(1):25–32
25. Lorenz KJ, Maier H (2009) Photodynamic therapy with meta-tetrahydroxyphenylchlorin (Foscan((R))) in the management of squamous cell carcinoma of the head and neck: experience with 35 patients. *Eur Arch Otorhinolaryngol*
26. Wenig BL, Kurtzman DM, Grossweiner LI, Mafee MF, Harris DM, Lobraico RV et al (1990) Photodynamic therapy in the treatment of squamous cell carcinoma of the head and neck. *Arch Otolaryngol Head Neck Surg* 116(11):1267–1270
27. Kulapaditharom B, Boonkitticharoen V (2000) Photodynamic therapy in management of head and neck cancers and precancerous lesions. *J Med Assoc Thai* 83(3):249–258
28. Biel MA (2007) Photodynamic therapy treatment of early oral and laryngeal cancers. *Photochem Photobiol* 83(5):1063–1068
29. Hopper C, Kubler A, Lewis H, Tan IB, Putnam G (2004) mTHPC-mediated photodynamic therapy for early oral squamous cell carcinoma. *Int J Cancer* 111(1):138–146
30. D'Cruz AK, Robinson MH, Biel MA (2004) mTHPC-mediated photodynamic therapy in patients with advanced, incurable head and neck cancer: a multicenter study of 128 patients. *Head Neck* 26(3):232–240
31. Copper MP, Tan IB, Oppelaar H, Ruevekamp MC, Stewart FA (2003) Meta-tetra(hydroxyphenyl)chlorin photodynamic therapy in early-stage squamous cell carcinoma of the head and neck. *Arch Otolaryngol Head Neck Surg* 129(7):709–711
32. Berenbaum MC, Akande SL, Bonnett R, Kaur H, Ioannou S, White RD et al (1986) meso-Tetra(hydroxyphenyl)porphyrins, a new class of potent tumour photosensitisers with favourable selectivity. *Br J Cancer* 54(5):717–725
33. Schizas AM, Williams AB, Meenan J (2009) Endosonographic staging of lower intestinal malignancy. *Best Pract Res Clin Gastroenterol* 23(5):663–670 Review
34. Shintani S, Yoshihama Y, Ueyama Y, Terakado N, Kamei S, Fijimoto Y, Hasegawa Y, Matsuura H, Matsumura T (2001) The usefulness of intraoral ultrasonography in the evaluation of oral cancer. *Int J Oral Maxillofac Surg* 30(2):139–143
35. Braakhuis BJ, Tabor MP, Kummer JA, Leemans CR, Brakenhoff RH (2003) A genetic explanation of slaughter's concept of field cancerization: evidence and clinical implications. *Cancer Res* 63(8):1727–1730
36. Ridge JA (1993) Squamous cancer of the head and neck: surgical treatment of local and regional recurrence. *Semin Oncol* 20(5):419–429
37. Leon X, Quer M, Diez S, Orus C, Lopez-Pousa A, Burgues J (1999) Second neoplasm in patients with head and neck cancer. *Head Neck* 21(3):204–210
38. Nieuwenhuis EJ, Castelijns JA, Pijpers R, van den Brekel MW, Brakenhoff RH, van der Waal I, Snow GB, Leemans CR (2002) Wait-and-see policy for the N0 neck in early-stage oral and oropharyngeal squamous cell carcinoma using ultrasonography-guided cytology: is there a role for identification of the sentinel node? *Head Neck* 24(3):282–289
39. van den Brekel MW, Castelijns JA, Stel HV et al (1991) Occult metastatic neck disease: detection with US and US-guided fine needle aspiration cytology. *Radiology* 180:457–461