



UvA-DARE (Digital Academic Repository)

Decompressive hemicraniectomy in cerebral sinus thrombosis: consecutive case series and review of the literature

Coutinho, J.M.; Majoie, C.B.L.M.; Coert, B.A.; Stam, J.

DOI

[10.1161/STROKEAHA.108.543421](https://doi.org/10.1161/STROKEAHA.108.543421)

Publication date

2009

Document Version

Final published version

Published in

Stroke

[Link to publication](#)

Citation for published version (APA):

Coutinho, J. M., Majoie, C. B. L. M., Coert, B. A., & Stam, J. (2009). Decompressive hemicraniectomy in cerebral sinus thrombosis: consecutive case series and review of the literature. *Stroke*, *40*(6), 2233-2235. <https://doi.org/10.1161/STROKEAHA.108.543421>

General rights

It is not permitted to download or to forward/distribute the text or part of it without the consent of the author(s) and/or copyright holder(s), other than for strictly personal, individual use, unless the work is under an open content license (like Creative Commons).

Disclaimer/Complaints regulations

If you believe that digital publication of certain material infringes any of your rights or (privacy) interests, please let the Library know, stating your reasons. In case of a legitimate complaint, the Library will make the material inaccessible and/or remove it from the website. Please Ask the Library: <https://uba.uva.nl/en/contact>, or a letter to: Library of the University of Amsterdam, Secretariat, Singel 425, 1012 WP Amsterdam, The Netherlands. You will be contacted as soon as possible.

UvA-DARE is a service provided by the library of the University of Amsterdam (<https://dare.uva.nl>)

Stroke

American Stroke
AssociationSM

JOURNAL OF THE AMERICAN HEART ASSOCIATION

A Division of American
Heart Association



Decompressive Hemicraniectomy in Cerebral Sinus Thrombosis: Consecutive Case Series and Review of the Literature

Jonathan M. Coutinho, Charles B.L.M. Majoie, Bert A. Coert and Jan Stam

Stroke 2009;40;2233-2235; originally published online Apr 16, 2009;

DOI: 10.1161/STROKEAHA.108.543421

Stroke is published by the American Heart Association, 7272 Greenville Avenue, Dallas, TX 75214

Copyright © 2009 American Heart Association. All rights reserved. Print ISSN: 0039-2499. Online ISSN: 1524-4628

The online version of this article, along with updated information and services, is located on the World Wide Web at:

<http://stroke.ahajournals.org/cgi/content/full/40/6/2233>

Subscriptions: Information about subscribing to Stroke is online at
<http://stroke.ahajournals.org/subscriptions/>

Permissions: Permissions & Rights Desk, Lippincott Williams & Wilkins, a division of Wolters Kluwer Health, 351 West Camden Street, Baltimore, MD 21202-2436. Phone: 410-528-4050. Fax: 410-528-8550. E-mail:
journalpermissions@lww.com

Reprints: Information about reprints can be found online at
<http://www.lww.com/reprints>

Decompressive Hemicraniectomy in Cerebral Sinus Thrombosis

Consecutive Case Series and Review of the Literature

Jonathan M. Coutinho, MD, MSc; Charles B.L.M. Majoie, MD, PhD;
Bert A. Coert, MD, PhD; Jan Stam, MD, PhD

Background and Purpose—Thirteen percent of patients with cerebral venous and sinus thrombosis (CVST) has a poor clinical outcome. In patients with a poor prognosis, endovascular thrombolysis can be considered, but this procedure does not appear to be beneficial in patients with impending transtentorial herniation because of large hemorrhagic venous infarcts. Therefore, halfway through 2006, we changed our policy to decompressive hemicraniectomy in these patients.

Methods and Results—Patients with CVST and impending herniation attributable to venous infarcts were eligible for surgical intervention. Since 2006 we consecutively treated 3 patients with decompressive hemicraniectomy. Two patients had an excellent outcome. The third patient, who had been comatose for at least 12 hours before surgery, died despite intervention.

Conclusions—Our data suggest that decompressive hemicraniectomy can be life-saving and can result in an excellent outcome in patients with severe CVST. (*Stroke*. 2009;40:2233-2235.)

Key Words: sinus thrombosis ■ intracranial ■ craniotomy ■ cerebrovascular disorders

Approximately 13% of patients with cerebral venous and sinus thrombosis (CVST) has a poor clinical outcome.¹ Transtentorial herniation attributable to mass lesions is the most common cause of death. The International Study on Cerebral Vein and Dural Sinus Thrombosis (ISCVT) identified risk factors that predict poor outcome, which include coma, intracerebral hemorrhage, and thrombosis of the deep venous system.¹ Endovascular thrombolysis may be considered in patients with these risk factors, but its efficacy has not been proven in a randomized trial. Furthermore, in our experience endovascular thrombolysis is not beneficial to patients with impending transtentorial herniation attributable to large infarcts or hemorrhages²: It comes too late and cannot prevent further brain stem compression. Therefore, halfway through 2006, we decided to change our policy and treat these patients with decompressive hemicraniectomy.²

In this case series we describe the first 3 consecutive patients, discuss previous case reports, and suggest a course of action for future research.

Methods

Since July 2006, we treated patients with severe CVST and signs of transtentorial herniation with decompressive hemicraniectomy. Indications for surgery are unilateral third nerve dysfunction or deteriora-

tion on the Glasgow coma score caused by local brain edema or venous infarction with midline shift or obliteration of basal cisterns, and not attributable to seizures.

A large hemicraniectomy was performed, with special effort to extend the decompression toward the temporal skull base. The dura was opened widely to ensure maximal decompression. The cortical surface was covered with hemostatic material (Surgicell), after which the skin, temporal muscle, and fascia flap were closed in 3 layers. Patients received high-dose subcutaneous nadroparin immediately after the diagnosis CVST was made. Postoperatively, nadroparin was continued in prophylactic dosage for 24 hours. Thereafter, dosage was increased to therapeutic range. Patient C only received nadroparin after surgery, because she was operated on immediately after admission.

Follow-up visits were performed at 6 and 12 months after discharge, and outcome was expressed on the modified Rankin Scale (mRS; 0=complete recovery, 6=death).

Results

Patient A, a 39-year-old man, was admitted with severe headache, nausea, and disorientation (E₄M₆V₅). His history included a deep-vein thrombosis of the left leg and a protein C deficiency. The CT-scan showed a left temporal hemorrhagic infarct (Figure, A) and MR-V showed thrombosis of the left transverse and sigmoid sinuses. Despite nadroparin treatment, he deteriorated and became comatose (E₁M₃V₁) because of enlargement of the hemorrhagic

Received November 18, 2008; accepted December 5, 2008.

From the Departments of Neurology (J.M.C., J.S.), Radiology (C.B.L.M.M.), and Neurosurgery (B.A.C.) Academic Medical Centre, University of Amsterdam, The Netherlands.

Correspondence to Prof Dr J. Stam, Department of Neurology (room H2-226), Academic Medical Centre, University of Amsterdam, Meibergdreef 9, 1105 AZ Amsterdam, The Netherlands. E-mail j.stam@amc.uva.nl

© 2009 American Heart Association, Inc.

Stroke is available at <http://stroke.ahajournals.org>

DOI: 10.1161/STROKEAHA.108.543421

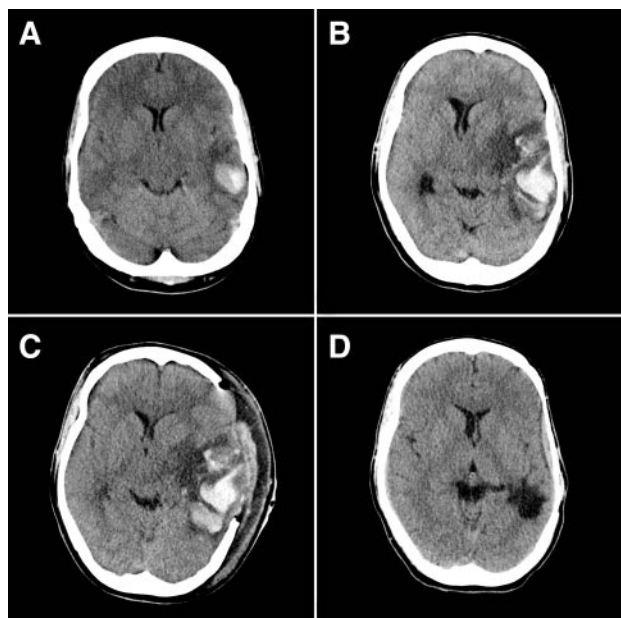


Figure. A, Admission head CT-scan shows left temporal hemorrhagic infarct (34 cm³). B, CT scan acquired after clinical deterioration, showing enlargement of hemorrhagic infarct (110 cm³) and increase of midline shift (12 mm). C, Direct postoperative CT scan. Reduction in midline shift (7 mm). D, Follow-up CT scan 3 months after ictus.

infarct with a 12-mm midline shift (Figure, B). Hemicraniectomy was subsequently performed. Immediately postoperative the patient showed marked improvement (E₃M₅V_{aphasia}), and the CT-scan showed reduction of midline shift (Figure, C). At 6 months a right upper quadrant-anopia and a mild expressive aphasia were his only residual symptoms (mRS 2). At 12 months he had resumed all daily activities (mRS 1).

Patient B, a 36-year-old woman, was admitted because of a generalized epileptic seizure (E₄M₆V₅), after a week of headache and nausea. MR-V showed thrombosis of the superior sagittal sinus and a right-sided parieto-occipital hemorrhagic infarct (volume 96 cm³). Despite nadroparin treatment, she deteriorated and on day 3 developed a depressed consciousness (E₃M₆V₄) and an enlarging right pupil. CT-scan showed enlargement of the hemorrhagic infarct (133 cm³) and a midline shift of 9 millimeter. After emergent hemicraniectomy, the patient's coma score optimized and the pupils became symmetrical. At 6- and 12-month follow-up a quadrant-anopia was her only residual symptom (mRS 1).

Patient C, a 55-year-old woman, was found unconscious at home. It was estimated that she had been in coma for at least 12 hours. At examination she was comatose (E₁M₅V₁) and had a fixed and dilated left pupil and bilateral absent corneal reflexes. CT-scan showed a large left temporal hemorrhagic infarct (volume 134 cm³), with uncal herniation and a midline shift of 15 mm. The contrast enhanced CT scan showed a thrombosis of the left transverse and sigmoid sinuses. Despite immediate hemicraniectomy, her clinical condition deteriorated in the following days (E₁M₂V₁). On day 3, treatment was withdrawn because there was no hope for recovery. She died 5 days

Table. Summary of Case Reports on Decompressive Hemicraniectomy in Patients With Severe CVST

Author	Year of Publication	No. of Cases	Age	GCS	Pupils	Favourable Outcome (mRS ≤3)
Stefini ³	1999	3	40–54	4–7	–/–	2/3
*Barbati ⁴	2003	1	15	5	+/+	1/1
Weber ⁵	2004	1	62	NA	NA	1/1
Keller ⁶	2005	4	37–66	6–13	+/+	4/4
Zeng ⁷	2007	1	48	7	–/+	1/1
Current study	2008	3	36–55	5–13	Variable	2/3

GCS indicates Glasgow Coma Score; mRS, modified Rankin Scale; NA, not available.

*Bilateral hemicraniectomy performed in a patient with CVST without evident impending transtentorial herniation or mass lesions.

later (mRS 6). The diagnosis of CVST was confirmed at autopsy.

Discussion

We present 3 consecutive cases with severe CVST and transtentorial herniation, treated with decompressive hemicraniectomy. This procedure resulted in excellent recovery in 2 patients. Before we changed our policy, similar patients in our center all had a fatal outcome despite maximal conservative treatment and endovascular thrombolysis.²

The scanty evidence for the efficacy of hemicraniectomy in CVST comes from small case series,^{3–7} summarized in the Table. Including our cases, 11 of 13 patients had a good outcome (mRS ≤3). However, comparability between cases is hampered by a wide variation in preoperative clinical condition (GCS and pupillary reactions) among patients.

There are several reasons why the concept of hemicraniectomy in severe CVST with impending herniation is plausible. First, hemicraniectomy can remove the immediate threat of fatal herniation. Second, decompressive hemicraniectomy has been shown to be effective in young patients with malignant middle cerebral artery infarction and impending herniation.⁸ The mechanism causing death is likely to be similar in both diseases. Finally, there is ample evidence that even large venous infarcts in general have a better potential for recovery than arterial infarcts.

To obtain more reliable data, a prospective case registry of hemicraniectomy in CVST will be included in a new, large, international study, the ISCVT-2.⁹ Participating centers will report clinical outcome on consecutive patients treated with decompressive hemicraniectomy for CVST. This will minimize selection bias of predominantly successful cases.

In conclusion, our data, supported by earlier case reports and pathophysiological plausibility, suggests that decompressive hemicraniectomy can be life-saving and result in an excellent outcome in the severest cases of CVST. Until more and better data are available, however, the decision to perform hemicraniectomy in CVST remains up to the individual judgment of the treating physician.

Acknowledgment

We thank Dr V.I.H. Kwa (Department of Neurology, Slotervaart Hospital, Amsterdam) for referring patient B.

Disclosures

None.

References

1. Ferro JM, Canhao P, Stam J, Bousser MG, Barinagarrementeria F. Prognosis of cerebral vein and dural sinus thrombosis: results of the International Study on Cerebral Vein and Dural Sinus Thrombosis (ISCVT). *Stroke*. 2004;35:664–670.
2. Stam J, Majoie CB, van Delden OM, van Lienden KP, Reekers JA. Endovascular thrombectomy and thrombolysis for severe cerebral sinus thrombosis: a prospective study. *Stroke*. 2008;39:1487–1490.
3. Stefini R, Latronico N, Cornali C, Rasulo F, Bollati A. Emergent decompressive craniectomy in patients with fixed dilated pupils due to cerebral venous and dural sinus thrombosis: report of three cases. *Neurosurgery*. 1999;45:626–629.
4. Barbati G, Dalla MG, Coletta R, Blasetti AG. Post-traumatic superior sagittal sinus thrombosis. Case report and analysis of the international literature. *Minerva Anesthesiol*. 2003;69:919–925.
5. Weber J, Spring A. [Unilateral decompressive craniectomy in left transverse and sigmoid sinus thrombosis.] *Zentralbl Neurochir*. 2004;65:135–140.
6. Keller E, Pangalu A, Fandino J, Konu D, Yonekawa Y. Decompressive craniectomy in severe cerebral venous and dural sinus thrombosis. *Acta Neurochir Suppl*. 2005;94:177–183.
7. Zeng L, Derex L, Maarrawi J, Dailler F, Cakmak S, Nighoghossian N, Trouillas P. Lifesaving decompressive craniectomy in ‘malignant’ cerebral venous infarction. *Eur J Neurol*. 2007;14:e27–e28.
8. Vahedi K, Hofmeijer J, Juettler E, Vicaut E, George B, Algra A, Amelink GJ, Schmiedeck P, Schwab S, Rothwell PM, Bousser MG, van der Worp HB, Hacke W. Early decompressive surgery in malignant infarction of the middle cerebral artery: a pooled analysis of three randomised controlled trials. *Lancet Neurol*. 2007;6:215–222.
9. Ferro JM, Canhao P, Stam J, Bousser MG, Massaro A, Barinagarrementeria F. International study on cerebral vein and dural sinus thrombosis (ISCVT) 2. European Stroke Conference, Nice. 2008. Abstract.