



UvA-DARE (Digital Academic Repository)

Long-term follow-up of craniofacial alterations in juvenile idiopathic arthritis

Twilt, M.; Schulten, A.J.M.; Prah-Andersen, B.; van Suijlekom-Smit, L.W.A.

DOI

[10.2319/093008-511R.1](https://doi.org/10.2319/093008-511R.1)

Publication date

2009

Document Version

Final published version

Published in

The Angle Orthodontist

[Link to publication](#)

Citation for published version (APA):

Twilt, M., Schulten, A. J. M., Prah-Andersen, B., & van Suijlekom-Smit, L. W. A. (2009). Long-term follow-up of craniofacial alterations in juvenile idiopathic arthritis. *The Angle Orthodontist*, 79(6), 1057-1062. <https://doi.org/10.2319/093008-511R.1>

General rights

It is not permitted to download or to forward/distribute the text or part of it without the consent of the author(s) and/or copyright holder(s), other than for strictly personal, individual use, unless the work is under an open content license (like Creative Commons).

Disclaimer/Complaints regulations

If you believe that digital publication of certain material infringes any of your rights or (privacy) interests, please let the Library know, stating your reasons. In case of a legitimate complaint, the Library will make the material inaccessible and/or remove it from the website. Please Ask the Library: <https://uba.uva.nl/en/contact>, or a letter to: Library of the University of Amsterdam, Secretariat, Singel 425, 1012 WP Amsterdam, The Netherlands. You will be contacted as soon as possible.

Long-term Follow-up of Craniofacial Alterations in Juvenile Idiopathic Arthritis

Marinka Twilt^a; Alcuin J. M. Schulten^b; Birte Prah-Andersen^c; Lisette W. A. van Suijlekom-Smit^d

ABSTRACT

Objective: To investigate changes in the craniofacial skeleton in relation to the changes in condylar alterations that occur during long-term follow-up in patients with juvenile idiopathic arthritis.

Materials and Methods: Temporomandibular joint (TMJ) involvement is defined as a condylar alteration that is observed on the orthopantomogram. Lateral cephalograms were used to determine linear and angular measurements.

Results: Seventy of 97 patients from the initial study cohort were included, with a mean follow-up of 68 months. The overall prevalence of condylar alterations and posterior rotation of the mandible decreased; however, the prevalence of retrognathia remained the same. Patients showed improvement in the degree of retrognathia and posterior rotation (40% ANB, 51% OP-SN, and 44% GO-GN-SN). Improvement in the degree of retrognathia was seen more often in patients with improved condylar alterations than in patients with persistent alterations and in those without alterations (50%, 33%, and 28%, respectively). The degree of posterior rotation improved almost equally in patients without TMJ involvement and in patients with improved condylar alterations (57% and 50% by OP-SN, and 67% and 38% GO-GN-SN, respectively) and did not improve in patients with stable persistent alterations.

Conclusion: Both condylar and craniofacial alterations can improve in patients with juvenile idiopathic arthritis. (*Angle Orthod.* 2009;79:1057–1062.)

KEY WORDS: JIA; Temporomandibular joint; TMJ; Craniofacial development; Retrognathia; Posterior rotation

INTRODUCTION

In 1897, childhood arthritis was first described as a distinct disease entity by Still,¹ in his article, "On a Form of Chronic Joint Disease in Children." After Still, childhood arthritis was divided into different subtypes. Between 1977 and 1994, two different terms were used: juvenile rheumatoid arthritis (JRA) and juvenile chronic arthritis (JCA). In 1994, the International

League of Association for Rheumatology (ILAR) established an international consensus that led to the criteria for juvenile idiopathic arthritis (JIA).

JIA is defined as arthritis that starts before the age of 16 years, persists for at least 6 weeks, and has no specific cause. JIA is divided into seven subtypes based on clinical symptoms during the first 6 months of the disease, and based on inclusion and exclusion criteria.^{2,3} These subtypes all have a different initial presentation, course, and prognosis.^{2,4}

The temporomandibular joint (TMJ) can be affected unilaterally and bilaterally, early or late in the course of the disease, and it can even be the first joint affected. The reported frequency of TMJ involvement ranges in the literature from 17% to 87%, depending on the population investigated, the subtypes represented, and the radiologic method by which involvement is diagnosed.^{5–14} Only one study reported the incidence of TMJ involvement in all subtypes of JIA.⁶

The most important site of growth of the mandible in the vertical and sagittal direction is located on the articular surface of the condylar head.^{12–15} During nor-

^a Resident, Department of Pediatrics, Erasmus MC-Sophia Children's Hospital, Rotterdam, The Netherlands.

^b Private Practice, Rotterdam, The Netherlands.

^c Professor, Department of Orthodontics, Academic Center for Dentistry Amsterdam, University of Amsterdam, The Netherlands.

^d Associate Professor, Department of Pediatrics, Erasmus MC-Sophia Children's Hospital, Rotterdam, The Netherlands.

Corresponding author: Dr Marinka Twilt, Department of Pediatrics, Erasmus MC-Sophia Children's Hospital, PO Box 2060, Rotterdam, 3000 CB, The Netherlands (e-mail: m.twilt@erasmusmc.nl)

Accepted: January 2009. Submitted: September 2008.

© 2009 by The EH Angle Education and Research Foundation, Inc.

mal growth of the dentomaxillary complex, the vertical dimension increases more than the sagittal dimension does. Arthritis of the TMJ results in reduced mandibular growth and subsequent alteration in dental occlusion and may even affect total craniofacial growth.⁸⁻¹⁰ Alterations in the craniofacial structure of patients with JIA were described in several studies.^{11,16-20} These patients demonstrated retrognathia and increased mandibular posterior rotation. Usually, the characteristic facial morphology has been associated with condylar destruction.^{11,16-20}

Most studies were performed in the oligoarticular and polyarticular subtypes, with a greater number of retrognathia and posterior rotated mandibles noted in the polyarticular subtype.^{11,16,17} Only one study reported mild downward and backward rotation of the mandible in the systemic subtype.¹

The patient cohort of the Temporomandibular Joint Rheumatologic Involvement Project (TRIP) studies is based on an initial cross-sectional population of 97 consecutive patients who represented all subtypes of JIA. In TRIP 0, the frequency of TMJ involvement diagnosed with an orthopantomogram (OPT) was 45%.⁵ Craniofacial morphology was altered in patients with JIA regardless of TMJ status, although this occurred more commonly in patients with TMJ involvement.²⁰ TRIP 1 (1 year later) reported a yearly incidence of TMJ involvement of 7%.⁶ A drastic decrease in the prevalence of OPT alterations was observed during follow-up.^{6,7}

The aim of this survey was to study how the course of condylar alterations can influence the craniofacial skeleton in patients with JIA over a 5-year period.

MATERIALS AND METHODS

Patients

Initially, 97 consecutive patients with JIA according to Durban criteria were referred for comprehensive orthodontic evaluation in the TRIP 0 study. In TRIP 5, these patients were reviewed 5 years later to evaluate the prevalence and severity of TMJ involvement and facioskeletal changes. A total of 70 patients from the initial cohort were included; with an OPT and lateral cephalogram (LC) available at both evaluations, 27 (28%) patients from the initial cohort were excluded (1) for not consenting to participate in this 5-year follow-up study ($n = 13$; 13%), (2) because of invalid LC ($n = 1$; 1%) or invalid OPT ($n = 4$; 4%), or (3) because of missing LC results ($n = 10$; 10%). Consequently, the TRIP 0 cohort was adjusted so that only patients represented in the TRIP 5 study were included. The mean interval between consecutive radiographs was 68 months (range, 53 to 73 months). The study was approved by the Medical Ethical Committee of the

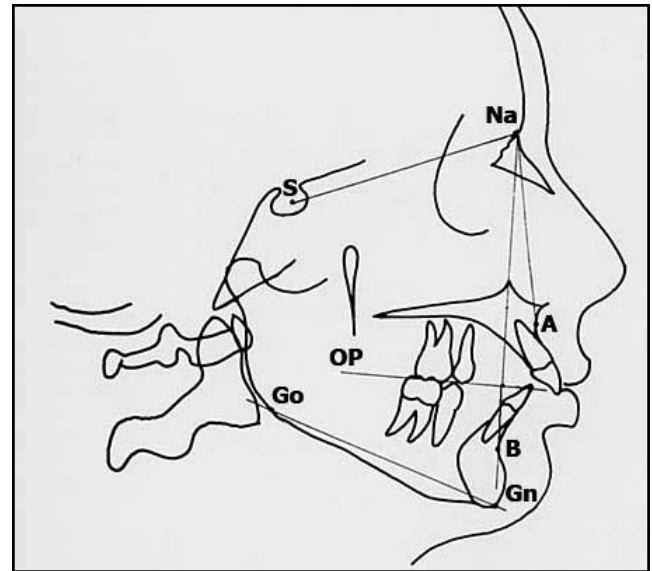


Figure 1. Tracing of a lateral cephalogram. Retrognathia is determined by ANB angle (S-NA-A minus S-NA-B), and posterior rotation of the mandible is determined by mandibular plane-to-cranial base angle (GO-GN to S-NA) and occlusal plane-to-cranial base angle (OP to S-NA).

Erasmus MC-Sophia Children's Hospital, and written informed consents were obtained from all patients.

Radiographic Examination

Standardized radiographic examination was performed with the use of LCs and OPTs. All LCs were digitized with an Epson 1680 Pro Scanner (Epson, Long Beach, Calif) and were traced with QuickCeph 2000 software (Quick Ceph, San Diego, Calif). The following values were measured (Figure 1): ANB, indicating the discrepancy, or sagittal relationship, between maxilla and mandible; and GO-GN-SN and OP-SN, both evaluating the divergency of, or vertical relationship between, the maxilla and the mandible.²¹ We used these angles to describe retrognathia and posterior rotation to enhance comparability with various surveys on craniofacial alterations in JIA.^{8,11,12,16-20}

TMJ involvement was defined as condylar alterations seen on OPT and was diagnosed according to the six categories of Rohlin and Petersson as follows²²: grade 0, normal conditions; grade 1, slight abnormality; grade 2, definite early abnormality; grade 3, moderate destructive abnormality; grade 4, severe destructive abnormality; and grade 5, mutilating abnormality. The OPTs were scored by two individual reviewers, who were blinded to information on the patient and to results of the other reviewer. Intraobserver and interobserver correlations and the intraclass correlation coefficient showed good reproducibility of results and a low error of method in a previous study.⁶

Table 1. Overall Prevalence of OPT Alterations, Retrognathia, and Posterior Rotation Divided per Subtype in TRIP 0 and TRIP 5

JIA Subtype (Total n = 70)	TRIP 0				TRIP 5			
	OPT Alteration	Retrognathia (ANB)	Posterior Rotation		OPT Alteration	Retrognathia (ANB)	Posterior Rotation	
			OP-SN	GO-GN-SN			OP-SN	GO-GN-SN
Systemic (n = 13)	9	8	12	10	8	11	10	9
Oligo persistent (n = 17)	8	12	10	7	5	12	8	5
Oligo extended (n = 12)	5	9	6	7	6	6	5	4
Poly RF+ (n = 5)	2	4	5	2	0	5	4	3
Poly RF- (n = 11)	6	8	7	4	5	7	7	2
ERA (n = 6)	0	4	3	2	0	3	3	1
Art. psoriatica (n = 3)	1	1	2	2	1	1	2	2
Undifferentiated (n = 3)	1	1	3	2	1	0	1	1
Total alterations	32	47	48	36	26	45	40	27
Degree of alterations ^a		5.9 (4.9–7.0)	21.4 (18.9–24.4)	39.5 (36.7–42.1)		5.9 (4.9–7.3)	21.5 (19–25)	41.1 (37.6–44.6)

^a Median (25th and 75th percentiles).

Cephalometric Standards

Control data for the cephalometric measurements of patients 6 to 16 years of age were obtained according to sex and age on the basis of the methods of Riolo et al.²³ Normal values for patients older than 16 years were based on the Steiner analysis.²⁴ Normal growth according to age, gender, and ethnic background are included in these control data. Posterior rotation of the mandible was defined as ≥ 2 SD of the norms for GO-GN-SN and OP-SN, according to Riolo. Retrognathia was defined as an ANB angle exceeding 4 degrees. The LCs were examined by one reviewer, but intraobserver and interobserver and intraclass correlation coefficients of the LCs showed good reproducibility and a low error of method in a previous study.²⁰

Statistical Analysis

The Statistical Package for the Social Sciences (SPSS), version 12.0 for Windows (SPSS Inc, Chicago, Ill), was used for data analysis. Descriptive statistics were used to describe differences between groups. Because groups were small, medians are given. Continuous measurements were described as medians with 25th and 75th percentiles. To compare differences in means between the group with and the group without craniofacial alterations, the paired *t*-test was used for continuous variables. Statistical significance was defined as $P < .05$.

RESULTS

Patients

Patient characteristics are summarized in Table 1. All subtypes of JIA were included and corresponded with the percentages in pediatric rheumatology populations. The population of 27 boys and 43 girls had a mean age of 16 years and 3 months (range, 8 yr 9 mo

to 24 yr 8 mo), and a mean duration of the disease of 10 years and 1 month (range, 6 yr 3 mo to 18 yr 10 mo).

TMJ Involvement

According to the grading system of Rohlin, 26 of 70 (37%) patients had TMJ involvement in TRIP 5 compared with 32 of 70 (46%) patients in TRIP 0. The overall decrease in prevalence is not statistically significant. However, the decrease in severity of condylar alterations and the number of patients with improvement in condylar alterations, including complete recovery of these alterations (28/70 patients), are statistically significant ($P < .05$). Table 1 summarizes the frequency of TMJ involvement, divided by subtype in TRIP 5 and adjusted for TRIP 0.

When the condylar alterations in TRIP 5 were compared with those in TRIP 0, 32 (46%) patients were seen to have stable normal condyles, 4 (6%) patients showed no change in condylar alterations, 28 (40%) patients showed improvement in affected condyles, and 6 (8%) patients exhibited worsening of condylar alterations.

Cephalometric Analysis

Retrognathia. The overall prevalence of retrognathia divided by subtype is summarized in Table 1. This prevalence as described is accurate, regardless of TMJ status in TRIP 0 and TRIP 5. In contrast to the decrease in overall prevalence of condylar alterations, the overall prevalence of retrognathia remains the same during follow-up (67% TRIP 0 and 64% TRIP 5).

In addition to the prevalence of retrognathia, the degree of retrognathia was measured in TRIP 0 and TRIP 5. The degree of retrognathia improved in 19 of 47 (40%) patients with initial retrognathia in TRIP 0 (TRIP 0: ANB, 6.7 [range, 5 to 7.7]; TRIP 5: ANB, 4.0

Table 2. Degree of Retrognathia and Posterior Rotation in Relation to Changes in OPT Alterations During Follow-up^a

TMJ Status TRIP 0	OPT Changes	Retrognathia (ANB)				
		Not Initially Present		Initially Present		
		Stable	Newly Developed	Stable Present	Improved	Worsened
TMJ+ ^b	Improved alterations (n = 28)	4/1	4/3	24/6	24/12	24/6
TMJ+	Persistent alterations (n = 4)	1/1		3/1	3/1	3/1
TMJ- ^c	Normal OPTs (n = 32)	14/10	14/4	18/10	18/5	18/3
TMJ-	New alterations (n = 6)	4/3	4/1	2/0	2/1	2/1
Posterior Rotation (OP-SN)						
TMJ+	Improved alterations (n = 28)	8/8		20/8	20/10	20/2
TMJ+	Persistent alterations (n = 4)			4/4		
TMJ-	Normal OPTs (n = 32)	11/6	11/5	21/5	21/12	21/4
TMJ-	New alterations (n = 6)	3/3		3/0	3/2	3/1
Posterior Rotation (GO-GN-SN)						
TMJ+	Improved alterations (n = 28)	12/11	12/1	16/7	16/6	16/3
TMJ+	Persistent alterations (n = 4)	1/1		3/3		
TMJ-	Normal OPTs (n = 32)	17/17		15/2	15/10	15/3
TMJ-	New alterations (n = 6)	4/3	4/1	2/1		2/1

^a When the sagittal relationship is looked at (ANB), it can be seen that 50% of patients with initial TMJ involvement with improved condylar alterations and initial retrognathia show improvement in ANB. When the vertical relationship is looked at (both OP-SN and GO-GN-SN), 50% and 38%, respectively, of patients with initial TMJ involvement with improved condylar alterations and initial posteriorly rotated mandibles show improvement in the degree of posterior rotation.

^b TMJ+, Condylar alterations in TRIP 0.

^c TMJ-, Normal condyles in TRIP 0.

[range, 3.4 to 5.8]; $P = .000$). In Table 2, retrognathic changes are described in relation to OPT alterations in TRIP 5 compared with TRIP 0. In 32 patients with TMJ involvement, the degree of retrognathia showed greater improvement in the 28 patients with improved condylar alterations than in 4 patients with persistent condylar alterations (12/24 [50%] and 1/3 [33%], respectively).

In Trip 0, retrognathia was seen in 18 of 32 patients (56%) without condylar alterations in TRIP 0 and TRIP 5. During follow-up, 5 of these 18 (28%) patients showed improvement in the degree of retrognathia.

Posterior rotation. The overall prevalence of posterior rotation divided per subtype is summarized in Table 1. The overall prevalence of posterior rotation decreased if measured by OP-SN (69% TRIP 0 and 57% TRIP 5) and GO-GN-SN (51% TRIP 0 and 39% TRIP 5).

The degree of posterior rotation improved in 24 of 48 (50%) patients with initial posterior rotated mandibles in TRIP 0 if measured by OP-SN (TRIP 0: OP-SN, 21.4 [range, 18.1 to 25]; TRIP 5: OP-SN, 17.4 [range, 15 to 19.9]; $P = .009$) and improved in 16 of 36 (44%) patients if measured by GO-GN-SN (TRIP 0: GO-GN-SN, 37.6 [range, 28.4 to 41.6]; TRIP 5: 34.9 [range, 31.1 to 37.2]; $P = .089$).

Changes in the degree of posterior rotation of the mandible in relation to changes in condylar alterations during follow-up are described in Table 2. Improvement in the degree of posterior rotation in the 32 pa-

tients with TMJ involvement was more common in the 28 patients with improvement in condylar alterations (10/20 [50%] by OP-SN, and 6/16 [38%] by GO-GN-SN). The four patients with persistent condylar alterations showed no improvement in degree of posterior rotation.

In TRIP 0, posterior rotation measured by OP-SN was seen in 21 of 32 (66%) patients without condylar alterations in TRIP 0 and TRIP 5. During follow-up, 12 of these 21 (57%) patients showed improvement in the degree of posterior rotation. If measured by GO-GN-SN, 15 (47%) patients showed posterior rotation in TRIP 0, and 10 (67%) patients exhibited an improved degree of posterior rotation during follow-up.

DISCUSSION

TRIP 5 is the first long-term follow-up study on changes in craniofacial alterations in a cohort of patients with JIA in relation to condylar alterations as determined on an OPT. All subtypes of JIA are represented, corresponding with percentages found in a pediatric rheumatology department.

Our hypothesis was that if the condylar alterations would improve, craniofacial morphology also would improve. Besides the decrease in overall prevalence of condylar alterations, a decrease in overall prevalence of posterior rotation was seen, supporting our hypothesis. During 5 years of follow-up (TRIP 5), the overall prevalence of retrognathia remained the same. In ad-

dition to the overall prevalence of retrognathia and posterior rotation, the degree of retrognathia and posterior rotation was studied. After 5 years of follow-up, a trend toward normalization of craniofacial measurements was observed, as well as improvement in the degree of retrognathia and posterior rotation. Improvement in degree was seen more often in posterior rotation (both OP-SN and GO-GN-SN) than in retrognathia. Patients with improvement in condylar alterations and those without condylar alterations in TRIP 0 and TRIP 5 showed greater improvement in the degree of retrognathia and posterior rotation than did patients with persistent or newly developed condylar alterations. Because age, gender, and ethnic background are included in the reference values for measurements of the LCs, normal growth alone cannot explain the improvements and the trend toward normalization.

The difference in overall prevalence of posterior rotation and retrognathia and the continued trend toward normalization in posterior rotation of the mandible can be explained if the improvement in condylar changes has a greater effect on vertical relationships than on sagittal relationships. Because the posterior rotation describes the vertical relationship, it demonstrates a greater improvement than retrognathia, which describes a sagittal relationship. Sagittal growth is directed from the condylar growth center by means of bone remodeling. Cytokines involved in JIA, such as interleukin (IL)-6, are known to influence bone remodeling processes, which could explain the remaining retrognathia in most patients with JIA. We expect posterior rotation of the mandible to normalize to an even greater extent over an even longer period, as long as the condyle has growth potential.

In agreement with our first study, retrognathia and posteriorly rotated mandibles were more common in patients with JIA than in the normal population, and this tendency was even stronger if the TMJ was involved. The high prevalence of retrognathia and posterior rotation in all patients with JIA can be explained by a negative effect on craniofacial growth caused by the disease JIA itself. These alterations in craniofacial growth may be restored to near normal values if the arthritis in JIA is diminished. In most patients, disease activity can be controlled by sufficient medical treatment.

This study has some limitations. Magnetic resonance imaging (MRI) is considered the gold standard for the diagnosis of TMJ involvement; however, MRI has shortcomings, including the need for sedation in young children and greatly increased costs. Also, MRI is not available in all orthodontic and dental practices, as is the OPT. The OPT is a good diagnostic tool for

condylar alterations over the long term and is easily accessible.

Kappa statistics for the intraobserver and interobserver agreement are high for the OPT, and cephalometric measurements are described in Twilt et al.²⁰ These methods are useful tools in the follow-up of erosive changes for all patients with JIA.

A selection bias could have occurred in that not all patients were represented in this follow-up study. However, the number of missing patients is divided almost equally among subtypes and TMJ status in TRIP 0.

Eruption of teeth may have an influence on vertical development; therefore, the dental age of children should be incorporated in a follow-up study.

Acknowledging facioskeletal changes in arthritis of the TMJ is important because they may lead to esthetic problems, like the well known "bird-face" appearance, and they can cause oral health problems and difficulty chewing and intubating. Changes in condylar rating may have an important influence on the esthetics of the face. If the condylar situation can improve with treatment, as is demonstrated in this study, this may have implications for the timing and indications for treatment. This study also shows that only a longitudinal study design will provide evidence for a relationship between improved condylar alterations and craniofacial morphology.

CONCLUSIONS

- This study shows a drastic improvement in alterations of the condyle on the OPT and a trend toward normalization of the posterior rotation.
- Orthodontists should be aware of the possibility of condylar alterations in children with JIA, especially if they are retrognathic and have posteriorly rotated mandibles.

REFERENCES

1. Still GF. On a form of chronic joint disease in children. *Clin Orthop Relat Res.* 1990;259:4–10.
2. Petty RE, Southwood TR, Baum J, et al. Revision of the proposed classification criteria for juvenile idiopathic arthritis: Durban, 1997. *J Rheumatol.* 1998;25:1991–1994.
3. Petty RE, Southwood TR, Manners P, et al. International league of associations for rheumatology classification of juvenile idiopathic arthritis: second revision, Edmonton, 2001. *J Rheumatol.* 2004;31:390–392.
4. Woo P, Wedderburn LR. Juvenile chronic arthritis. *Lancet.* 1998;351:969–973.
5. Twilt M, Mobergs SMLM, Arends LR, ten Cate R, Van Suijlekom-Smit LWA. Temporomandibular involvement in juvenile idiopathic arthritis. *J Rheumatol.* 2004;31:1418–1422.
6. Twilt M, Arends LR, ten Cate R, Van Suijlekom-Smit LWA. Incidence of temporomandibular involvement in juvenile idiopathic arthritis. *Scand J Rheumatol.* 2007;36:184–188.
7. Twilt M, Schulten AJM, Verschure F, Wisse L, Prahlan-

- dersen B, Van Suijlekom-Smit LWA. Long-term follow-up of temporomandibular joint involvement in juvenile idiopathic arthritis. *Arthritis Rheum*. 2008;59:546–552.
8. Kjellberg H. Craniofacial growth in juvenile chronic arthritis. *Acta Odontol Scand*. 1998;56:360–365.
 9. Kùseler A, Pederson TK, Herlin T, Gelineck J. Contrast enhanced magnetic resonance imaging as a method to diagnose early inflammatory changes in the temporomandibular joint in children with juvenile chronic arthritis. *J Rheumatol*. 1998;25:1406–1412.
 10. Mayne JG, Hatch GS. Arthritis of the temporomandibular joint. *J Am Dent Assoc*. 1969;79:125–130.
 11. Mericle PM, Wilson VK, Moore TL, Hanna VE, Osborn TG, Rotskoff KS, Johnston LE Jr. Effects of polyarticular and pauciarticular onset juvenile rheumatoid arthritis on facial and mandibular growth. *J Rheumatol*. 1996;23:159–165.
 12. Ronchezel MV, Hilário MOE, Goldenberg J, Lederman HM, Faltin K Jr, de Azevedo MF, Naspitz CK. Temporomandibular joint and mandibular growth alterations in patients with juvenile rheumatoid arthritis. *J Rheumatol*. 1995;22:1956–1961.
 13. Sidiropoulou-Chatzigianni S, Papadopoulos MA, Kolokithas G. Mandibular condyle lesions in children with juvenile idiopathic arthritis. *Cleft Palate Craniofac J*. 2008;45:57–62.
 14. Weiss PF, Arabshahi B, Johnson A, Bilaniuk LT, Zarnow D, Cahill AM, Feudtner C, Cron RQ. High prevalence of temporomandibular joint arthritis at disease onset in children with juvenile idiopathic arthritis, as detected by magnetic resonance imaging but not by ultrasound. *Arthritis Rheum*. 2008;58:1189–1196.
 15. Brodie AG. On the growth pattern of the human head from the third month to the eight year of life. *Am J Anat*. 1941;68:209–262.
 16. Sidiropoulou-Chatzigianni S, Papadopoulos M, Kolokithas G. Dentoskeletal morphology in children with juvenile idiopathic arthritis compared with healthy children. *J Orthod*. 2001;28:53–58.
 17. Kjellberg H, Kiliaridis S, Thilander B. Dentofacial growth in orthodontically treated children with juvenile chronic arthritis (JCA): a comparison with Angle Class II division 1 subjects. *Eur J Orthod*. 1995;17:357–373.
 18. Larheim TA, Haanes HR. Micrognathia, temporomandibular joint changes and dental occlusion in juvenile rheumatoid arthritis of adolescents and adults. *Scand J Dent Res*. 1981;89:329–338.
 19. Hanna VE, Rider SF, Moore TL, Wilson VK, Osborn TG, Totskoff KS, Johnston LE Jr. Effects of systemic onset juvenile rheumatoid arthritis on facial morphology and temporomandibular joint form and function. *J Rheumatol*. 1996;23:155–158.
 20. Twilt M, Schulten AJM, Nicolaas P, Dülger A, Van Suijlekom-Smit LWA. Facioskeletal changes in children with juvenile idiopathic arthritis. *Ann Rheum Dis*. 2006;65:823–825.
 21. Jacobson A. *Radiographic Cephalometry*. 1st ed. Hanover Park, Illinois: Quintessence Publishing Co, Inc; 1995.
 22. Rohlin M, Petersson A. Rheumatoid arthritis of the temporomandibular joint: radiologic evaluation based on standard reference films. *Oral Surg Oral Med Oral Pathol*. 1989;67:594–599.
 23. Riolo ML, Moyers RE, Mcnamara JA, Hunter JS. An atlas of craniofacial growth: cephalometric standards from the university school growth study. In: Monograph No. 2, *Craniofacial Growth Series*. Ann Arbor, MI: Center for Human Growth and Development, The University of Michigan; 1974.
 24. Steiner CC. Cephalometrics for you and me. *Am J Orthod*. 1953;39:729–755.