



Combined CO₂ laser and intense pulsed light therapy in the treatment of vascular lesions

Terapia combinada de laser de CO₂ e luz intensa pulsada no tratamento de lesões vasculares

DOI: <http://www.dx.doi.org/10.5935/scd1984-8773.2021130011>

ABSTRACT

Congenital vascular lesions can be subdivided into tumors and malformations. Hemangiomas are benign vascular tumors resulting from the abnormal proliferation of endothelial cells, whereas port-wine stains are vascular malformations of a possible autosomal dominant inheritance. To date, there are no studies associating the use of intense pulsed light and CO₂ laser as a therapeutic form for these pathologies. We present a series of 10 cases of vascular injuries treated with the combination of these forms of irradiation. This combined therapy can be effective in reducing the thickness of the lesions or in attenuating the color.

Keywords: Hemangioma; Lasers, gas; Laser therapy; Intense pulsed light therapy; Vascular malformations

RESUMO

As lesões vasculares congênitas podem ser divididas em: tumores e malformações. Os hemangiomas são tumores vasculares benignos decorrentes da proliferação anormal de células endoteliais; já as manchas em vinho do Porto são malformações vasculares de provável herança autossômica dominante. Até o presente momento, não há estudos sobre a associação entre luz intensa pulsada e laser de CO₂ como forma terapêutica destas patologias. A presente série de casos apresenta 10 casos de lesões vasculares tratadas com a combinação destas formas de irradiação. Conclui-se que esta terapia combinada pode ser efetiva na redução da espessura das lesões ou na atenuação da coloração.

Palavras-chave: Hemangioma; Lasers de gás; Terapia a laser; Terapia de luz intensa pulsada; Malformações vasculares

Case report

Authors:

Renan Tironi Giglio de Oliveira¹
Beatrice Martinez Zugaib Abdalla¹
Daniela Suzuki Locatelli¹
Amanda Voltarelli Cesar de Oliveira¹
Simao Cohen¹

¹ Dermatology Service, Centro Universitário Saúde ABC, São Paulo (SP), Brazil.

Correspondence:

Renan Tironi Giglio de Oliveira
Email: renantironi@hotmail.com

Financial support: None.

Conflict of interest: None.

Submitted on: 18/08/2020

Approved on: 24/02/2021

Acknowledgments: We thank the opportunity to work with the Harmony[®] platforms from LBT Lasers and SmartXide Dot[®] from DEKA laser, and the companies' disposition to elucidate operational issues.

How to cite this article: Oliveira RTG, Abdalla BMZ, Locatelli DS, Oliveira AVC, Cohen S. Combined CO₂ laser and intense pulsed light therapy in the treatment of vascular lesions. *Surg Cosmet Dermatol.* 2021;13:e20210011.



INTRODUCTION

Congenital vascular lesions can be divided into tumors and malformations. Hemangiomas are benign vascular tumors resulting from the abnormal proliferation of endothelial cells. They are the most common type of vascular tumor in childhood. They can affect any part of the body, but they occur more frequently in the scalp.^{1,2,3} Contrarily, port-wine stains are vascular malformations of probable autosomal dominant inheritance. They usually occur on the face or neck, alone or in association with syndromes.^{4,5} The emission of radiation using hemoglobin as a chromophore has become a therapeutic option due to its exclusively local action. Neodymium-doped yttrium aluminum garnet (Nd:YAG) and pulsed-dye laser (PDL), types of laser,^{6,7} and Intense pulsed light (IPL), a form of divergent polychromatic white light, can be used to treat vascular lesions. We present a series of ten cases of vascular lesions, followed up and treated with combined therapy using fractional CO₂ laser and intense pulsed light (IPL).

RESULTS

We describe ten clinical cases with their respective characteristics and results after performing fractional CO₂ laser followed by IPL in the same procedure (Box 1).

Three dermatologists assessed the outcomes using photographs taken before and after the last sessions.

Overall, hemangiomas, women, and cephalic lesions predominated. Also, there was an improvement in texture, thickness, and tone of injuries. We observed a slight percentage reduction in the extension and diameter of lesions (Figures 1 to 5).

Regarding patient satisfaction with the result, all reported being satisfied with the clinical aspects after treatment. No adverse events or complications were described during or as a result of the procedures.

Box 1: Treatment methods, patterns, and clinical outcomes

	Diagnosis (hemangioma or port-wine stain – PWS)	Age and gender	Location and number of sessions (CO ₂ + IPL)	IPL (filter); pulse duration (ms); frequency (J/cm ²)	CO ₂ (Watts); Dual time (μs); Spacing (μm)	Improved tone	Improved extension and diameter	Improved texture and thickness
Patient 1	Hemangioma	26 years; man	Left hemiface; six sessions	570; 12; 12	30; 1.000; 700	Yes	No	No
Patient 2	PWS	46 years; woman	Left hemiface; five sessions	570; 10; 15	30; 800; 800	Yes	No	Yes
Patient 3	PWS	22 years; woman	Forehead, nose, upper right lip; two sessions	570; 12; 14	800 30; 800;	Yes	No	No
Patient 4	Hemangioma	48 years; woman	Infraorbital and right supralabial; eight sessions	570; 10; 15	30; 800; 800	Yes	No	Yes
Patient 5	Hemangioma	43 years; man	Left mandibular region; five sessions	570; 7; 60	30; 800; 600	Yes	Yes	Yes
Patient 6	PWS	53 years; woman	Right hemiface and lip; 16 sessions	570; 12; 12	30; 700; 900	Yes	No	Yes
Patient 7	Hemangioma	27 years; woman	Right breast region; five sessions	570; 15; 8	30; 500; 800	Yes	No	Yes
Patient 8	Hemangioma	50 years; woman	Hemiface and left region; nine sessions	570; 10; 12	30; 1.000; 700	Yes	No	Yes
Patient 9	Hemangioma	69 years; woman	Left hemiface; 13 sessions	570; 12; 15	30; 1.000; 600	Yes	No	Yes
Patient 10	Hemangioma	58 years; woman	right upper lip and malar region; six sessions	570; 10; 12	30; 1.100; 600	No	No	Yes

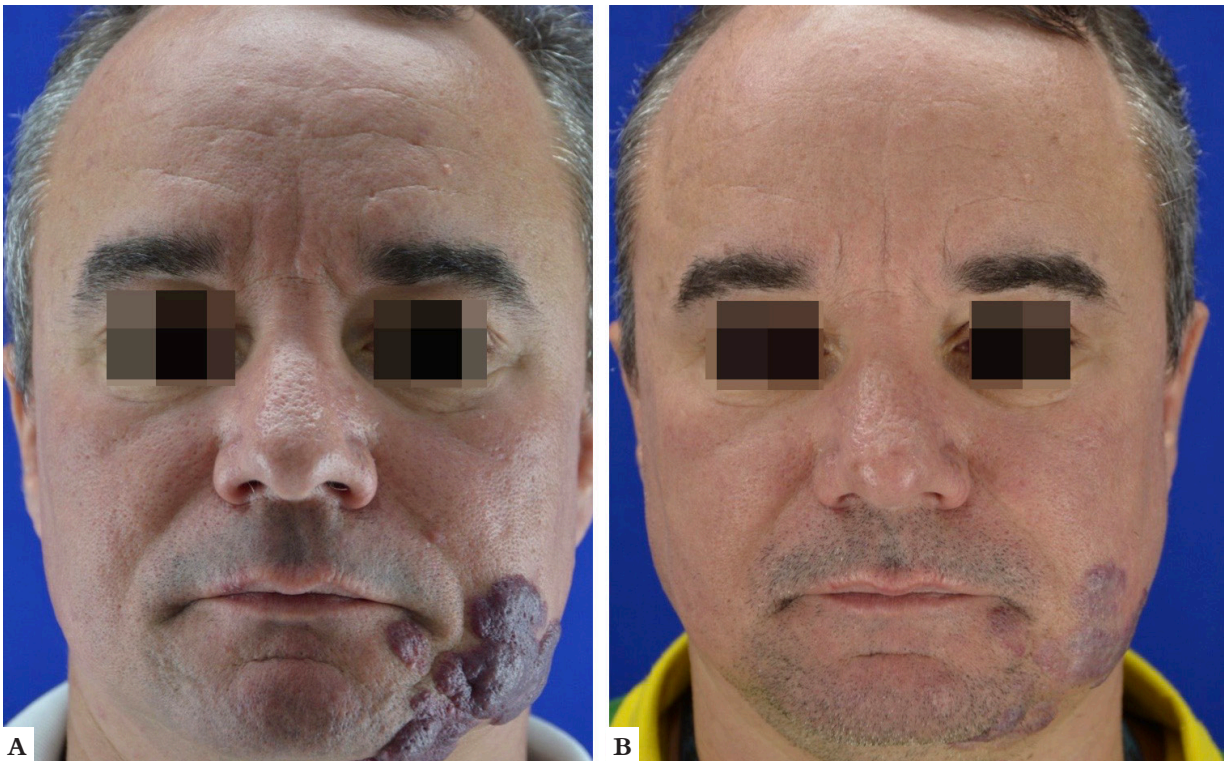


FIGURE 1: A - Patient 5, man, 43 years old, with hemangioma in the left mandibular region. **B** - Important tumor reduction and tone attenuation after treatment

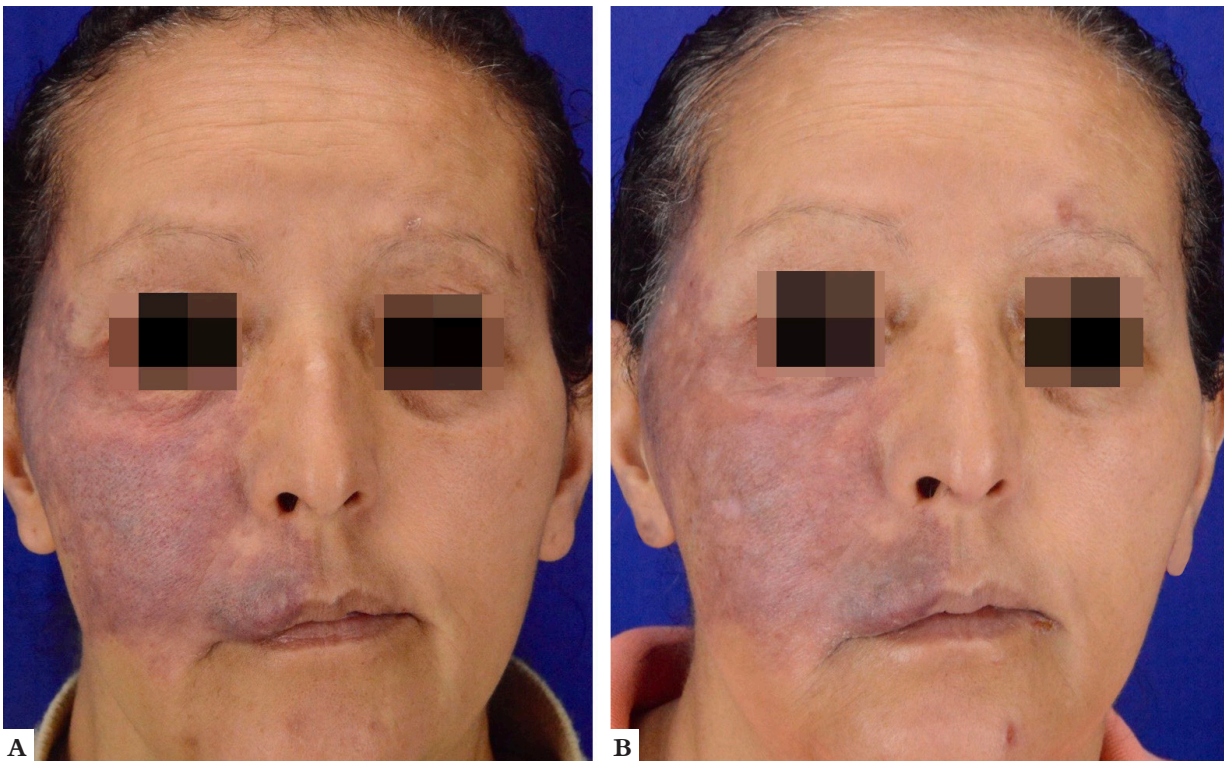


FIGURE 2: A - Patient 6, woman, 53 years old, with port-wine stain on the right hemiface. **B** - Homogeneous tone reduction and volumetric decrease of lip lesion after combined therapy

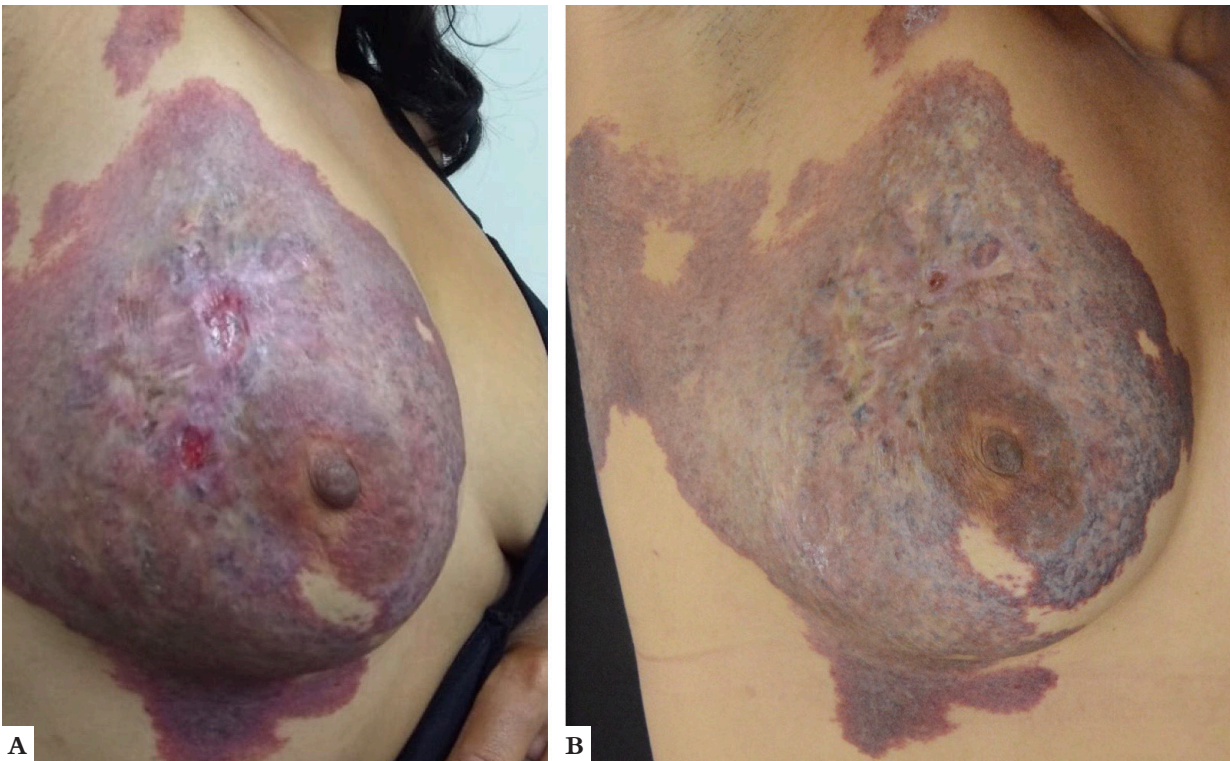

FIGURE 3: A - Patient 7, woman, 27 years old, with extensive hemangioma in the right breast region, with ulcerations and atrophic scars.
B - Color homogenization and thickness reduction after treatment

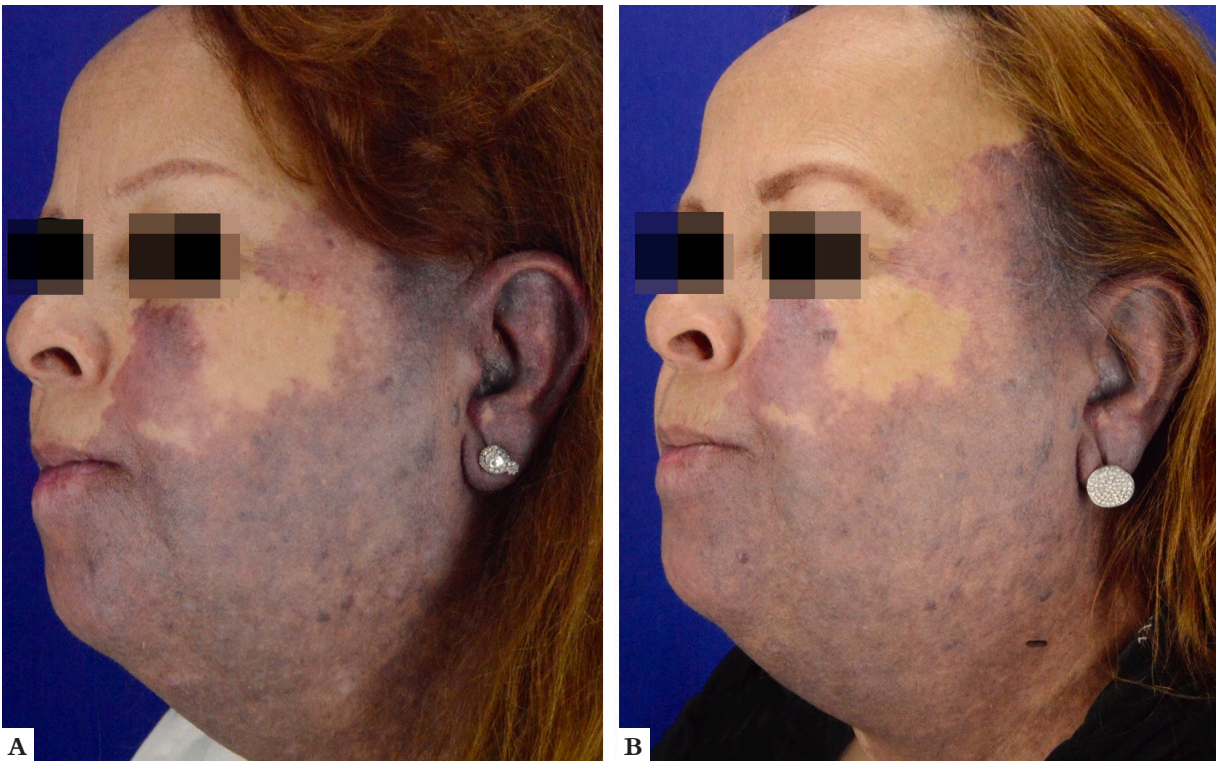

FIGURE 4: A - Patient 8, woman, 50 years old, with large hemangioma in the left hemiface and left lateral cervical.
B - Texture attenuation and a slight improvement in tonality after nine sessions

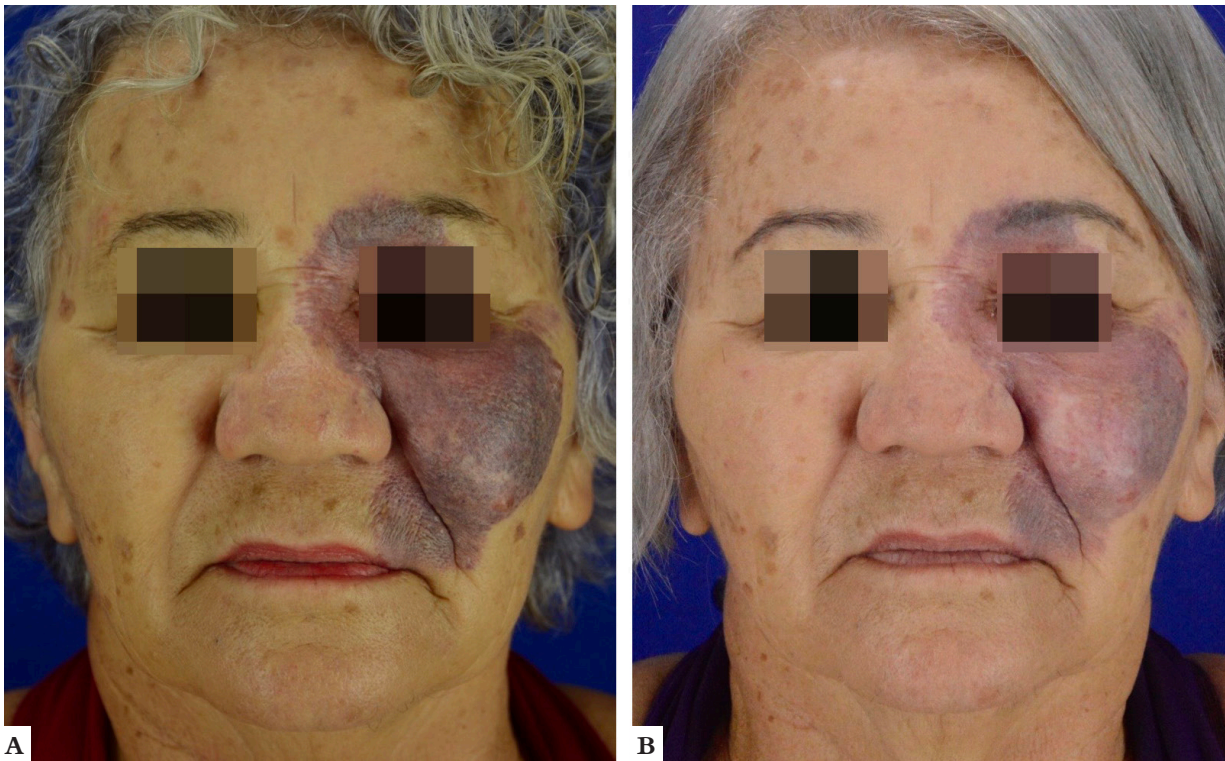

FIGURE 5: A - Patient 9, woman, 69 years old, with hemangioma on the left hemiface.
B - Post-procedure with combined therapy presenting tone improvement and thickness reduction

DISCUSSION

Hemangiomas are benign vascular tumors. They are the most common type of vascular tumor in childhood – their incidence can reach up to 10% in Caucasian children – and appears to be prevalent in children with a history of prematurity and low birth weight. This disorder affects more women than men (2.1:1) and results from the abnormal proliferation of endothelial cells and vascular components. The lesions can affect any part of the body, but it is more common in the scalp, neck, and trunk. In general, these vascular lesions appear after the first month of birth and tend to regress spontaneously, still in the first year of life (lesions decrease about 10% per year, and most of them fully regress by age 12). Despite its benign behavior, it may not progress with spontaneous regression and present, in about 5–10% of cases, ulceration, bleeding, local pain, atrophic or fibrotic scars formation, and deformities (mainly in deep and larger diameter tumors). These variants may signal resolution in childhood.^{1,2,3}

Among systemic and topical drug therapies, the literature currently describes options such as propranolol (assessed as the systemic treatment of choice for children); topical beta-blockers as timolol; imiquimod; and intravenous medications such as steroids and bleomycin. Laser treatment is initially indicated for superficial hemangiomas that regressed spontaneously, or residual lesions after other treatments. Cases resistant to less invasive approaches may need surgical approaches.^{1,3}

Port-wine stain is the second most common congenital vascular malformation. It is characterized by capillary and venous ectasia in the dermis. Clinically, it presents a dark red or purple skin patch, which may progress to darker tones and present nodules or constitute a hypertrophic appearance. Unfortunately, therapeutic options have been limited to performing laser therapy (Pulsed Dye Laser as the gold standard) or surgical procedures in recent decades.^{4,5}

Among the different types of laser, the Nd:YAG laser (in long pulse, KTP, or Q-switched modes) and the Pulsed Dye Laser (PDL) have selectivity for vascular lesions (using hemoglobin as a chromophore and “selective photothermal interaction”).⁶ A recent study demonstrated the effects of irradiation (Nd:YAG laser and IPL) on hemangioma endothelial cells, changing cytokine signaling pathways and apoptotic rate due to the inhibition in the production of several endothelial growth factors. This phenomenon lasted until a few days after the treatment and not just immediately after irradiation.⁷ Although the CO₂ ablative laser (10,600nm wavelength) uses water as a chromophore, some studies already reported its success in reducing vascular lesions, especially in infantile hemangiomas with airway involvement.³

As a form of white, divergent, non-coherent, and polychromatic radiation, IPL has a wavelength from 500nm to 1,200nm, depending on the filters used. The selectivity of mel-

anin and hemoglobin chromophores and the ability to damage the vascular walls according to established parameters justify its application in vascular lesions of the face.^{8,9}

CONCLUSION

The worldwide dermatological literature has not yet described the association between IPL and CO₂ laser for treating

vascular lesions. Therefore, we concluded that combining two different types of irradiation can effectively manage vascular lesions, with possible secondary indications when it's not possible to perform Nd:YAG or Pulsed Dye Laser. Device parameters must be further defined to explore the best aesthetic and functional result. ●

REFERENCES

1. Chen ZY, Wang QN, Zhu YH, Zhou LY, Xu T, He ZY, et al. Progress in the treatment of infantile hemangioma. *Ann Transl Med.* 2019;7(22):692. doi:10.21037/atm.2019.10.47
2. Brauer JA, Geronemus RG. Laser treatment in the management of infantile hemangiomas and capillary vascular malformations. *Tech Vasc Interv Radiol.* 2013;16(1):51-4.
3. Chinnadurai S, Sathe NA, Surawicz T. Laser treatment of infantile hemangioma: a systematic review. *Lasers Surg Med.* 2016;48(3):221-33.
4. Katelyn Mariko Updyke BS,a Amor Khachemoune. Port-Wine stains: a focused review on their management. *J Drugs Dermatol.* 2017;16(11):1145-51.
5. van Raath MI, Chohan S, Wolkerstorfer A, van der Horst CMAM, Storm G, Heger M. Port wine stain treatment outcomes have not improved over the past three decades. *J Eur Acad Dermatol Venereol.* 2019;33(7):1369-77.
6. Lin M, Lin C, Hu S, Chang J, Chung W, Zhang Z, et al. The application of 595-nm pulsed dye laser for vascular anomalies in a Chinese population: a 10-year experience. *J Cosmet Laser Ther.* 2018;21(3):171-8.
7. Zhu Y, Wan X, Abliz P. Effects of laser irradiation on growth factors and cell apoptosis of in vitro cultured infant hemangioma endothelial cells. *Life Sciences.* 2019;233:116685.
8. Wat H, Wu DC, Rao J, Goldman MP. Application of intense pulsed light in the treatment of dermatologic disease: a systematic review. *Dermatol Surg.* 2014;40(4):359-77.
9. Grillo E, Travassos AR, Boixeda P, Cuevas A, Pérez B, Paoli J, et al. Histological evaluation of the vessel wall destruction and selectivity after treatment with intense pulsed light in capillary malformations. *Actas Dermosifiliogr.* 2016;107(3):215-23.

AUTHORS' CONTRIBUTION:

Renan Tironi Giglio de Oliveira  ORCID 0000-0001-5013-7660

Statistical analysis; approval of the final version of the manuscript; study design and planning; preparation and writing of the manuscript; data collection, analysis, and interpretation; active participation in research orientation; intellectual participation in pro-paedeutic and/or therapeutic conduct of studied cases; critical literature review; critical revision of the manuscript.

Beatrice Martinez Zugaib Abdalla  ORCID 0000-0003-4586-1915

Statistical analysis; approval of the final version of the manuscript; study design and planning; preparation and writing of the manuscript; data collection, analysis, and interpretation; active participation in research orientation; intellectual participation in pro-paedeutic and/or therapeutic conduct of studied cases; critical literature review; critical revision of the manuscript.

Daniela Suzuki Locatelli  ORCID 0000-0001-6210-3230

Statistical analysis; approval of the final version of the manuscript; study design and planning; preparation and writing of the manuscript; data collection, analysis, and interpretation; active participation in research orientation; intellectual participation in pro-paedeutic and/or therapeutic conduct of studied cases; critical literature review; critical revision of the manuscript.

Amanda Voltarelli Cesar de Oliveira  ORCID 0000-0001-5594-8120

Statistical analysis; approval of the final version of the manuscript; study design and planning; preparation and writing of the manuscript; data collection, analysis, and interpretation; active participation in research orientation; intellectual participation in pro-paedeutic and/or therapeutic conduct of studied cases; critical literature review; critical revision of the manuscript.

Simao Cohen  ORCID 0000-0003-4532-0465

Statistical analysis; approval of the final version of the manuscript; study design and planning; preparation and writing of the manuscript; data collection, analysis, and interpretation; active participation in research orientation; intellectual participation in pro-paedeutic and/or therapeutic conduct of studied cases; critical literature review; critical revision of the manuscript.