



Surgical & Cosmetic Dermatology

www.surgicalcosmetic.org.br/

Malignant fibrous histiocytoma in ankle: case report

Histiocitoma fibroso maligno no tornozelo: relato de caso

DOI: <http://www.dx.doi.org/10.5935/scd1984-8773.2021130028>

ABSTRACT

Malignant fibrous histiocytoma (MFH) or undifferentiated pleomorphic sarcoma (UPS) is a sarcoma capable of invading adjacent structures. It is a mesenchymal neoplasia that predominates in men between the sixth and seventh decades of life. It is located mainly in the lower limbs and may affect the head and neck, trunk, and retroperitoneum, presenting a tendency to recurrence and local metastasis. This report aims to present a case of MFH in the ankle of a 49-year-old woman with an adjacent bone invasion, which evolved with transtibial amputation. Clinical, radiological, histopathological, and therapeutic aspects were addressed, highlighting the importance of early diagnosis.

Keywords: Amputation; Malignant fibrous histiocytoma; Sarcoma

RESUMO

Histiocitoma fibroso maligno (MFH) ou sarcoma pleomórfico indiferenciado (UPS) é um sarcoma moderadamente agressivo, capaz de invadir estruturas adjacentes. Trata-se de neoplasia mesenquimal que predomina em homens entre a sexta e sétima décadas de vida. Localiza-se, principalmente, nos membros inferiores, podendo acometer cabeça e pescoço, tronco e retroperitônio, com tendência à recorrência e à metástase local. O presente relato tem como objetivo apresentar um caso de MFH no tornozelo de uma mulher de 49 anos, com invasão óssea adjacente, que evoluiu com amputação transtibial. São abordados aspectos clínicos, radiológicos, histopatológicos e terapêuticos, salientando-se a importância do diagnóstico precoce.

Palavras-chave: Amputação; Histiocitoma fibroso maligno; Sarcoma.

Case Report

Authors:

Helio Amante Miot¹
Cesar Augusto Zago Ferreira¹
Ana Claudia Athanasio Shwetz¹
Luciane Donida Miot¹
Gabriela Roncada Haddad¹

¹ Universidade Estadual Paulista
Júlio de Mesquita Filho,
Department of Infectious Diseases,
Dermatology, Botucatu, São Paulo
(SP), Brazil

Correspondence:

Helio Amante Miot
Email: helio.a.miot@unesp.br /
cazferreira@gmail.com

Financial support: None.

Conflict of interest: None.

Submitted on: 09/04/2021

Approved on: 04/06/2021

How to cite this article:

Miot HA, Ferreira CAZ, Shwetz ACA, Miot LD, Haddad GR. Malignant fibrous histiocytoma in ankle: case report. Surg Cosmet Dermatol. 2021;13:e20210028.



INTRODUCTION

Malignant fibrous histiocytoma (MFH), first described by O'Brien and Stout in 1964,¹ is characterized by a high-grade mesenchymal neoplasm, composed of fibroblasts, myofibroblasts, and histiocytes.² It predominates between the sixth and seventh decades of life and in men (2/3 of the cases).^{3,4}

It mainly affects the lower limbs, and the distal femur, proximal fibula, and proximal femur² are the most frequent topographies. Nevertheless, it can also occur in the lung, kidney, bladder, heart, aorta, stomach, small intestine, orbit, central nervous system, spinal cord, sinuses, nasal and oral cavities.⁵

MFH is associated with hematopoietic diseases (non-Hodgkin's lymphoma, Hodgkin's lymphoma, multiple myeloma, and malignant histiocytosis). It can also result from radiation, fracture, osteonecrosis, Paget's disease of bone, non-ossifying fibroma, and fibrous dysplasia – cases where it is more aggressive.⁵

It has a moderately aggressive behavior that can invade adjacent soft tissues, skeletal system, and retroperitoneum. The main prognostic factor is the clinical stage of the tumor, defined by the degree of differentiation, size, and presence of distant metastases. Histological subtype, anatomical location, tumor depth, and treatment performed also influence the prognosis.⁶

CASE REPORT

A 49-year-old black housewife sought medical help due to a friable tumor measuring 7.0 cm x 5.5 cm, with progressive growth in the last nine months. The tumor presented a bleeding surface, fibrous and adhered consistency, with a defined contour, located in the right lateral malleolus (Figures 1 to 3). The patient reported episodes of bleeding associated with local pain. She sought medical care and was treated for a bacterial infection with antibiotic therapy, without improvement.

The patient had a history of portal vein thrombosis (PVT), heart failure, and arterial hypertension. Lymphadenopathies, visceromegaly, or lymphedema were not identified. The diagnoses suggested amelanotic melanoma, sarcoma, and Merkel cell carcinoma (MCC).

Histopathological examination revealed an ulcerated mesenchymal neoplasm, composed of spindle-shaped and epithelioid cells, with nuclear pleomorphism and accentuated mitotic activity (Figures 4 and 5), characterizing high-grade MFH. Immunohistochemistry showed positivity for CD68 (Figure 6) and negativity for p63, AE1/E3, CK5/6, MELAN A, CD34, AML, and S100, SOX-10.

General biochemical exams results were within normal values; however, magnetic resonance imaging evidenced invasion of the distal fibula (Figure 7).

The set of histopathological, immunophenotypic, and imaging findings confirmed the diagnosis of malignant fibrous histiocytoma (deep)/undifferentiated pleomorphic sarcoma, stage IIIA.

Due to bone involvement and tumor unresectability

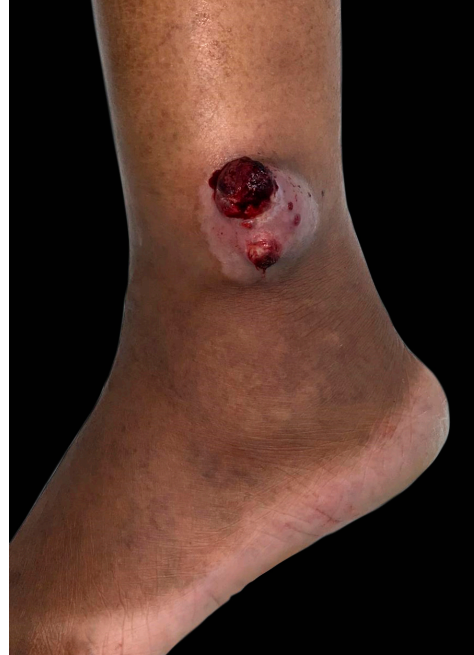

FIGURE 1: Malignant fibrous histiocytoma. Tumor above the lateral malleolus of the right leg

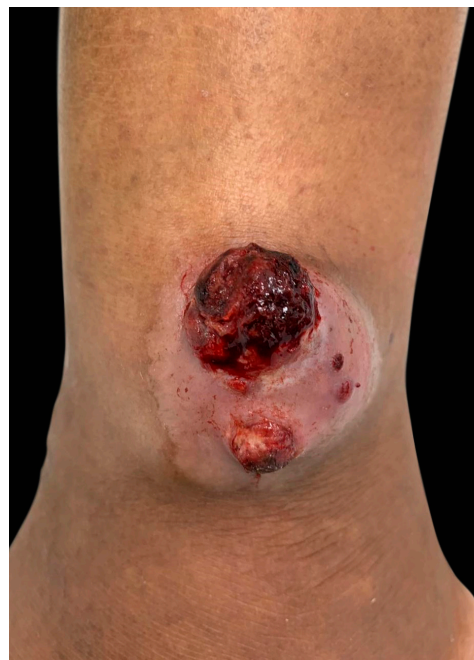

FIGURE 2: Malignant fibrous histiocytoma. Tumor with a fibrous surface, adhered, with defined boundaries and friable areas

with deep structures preservation, transtibial amputation was chosen. The patient has been under follow-up with Oncology for 11 months, without recurrence. The presence of heart disease contraindicated the adjuvant chemotherapy.

DISCUSSION

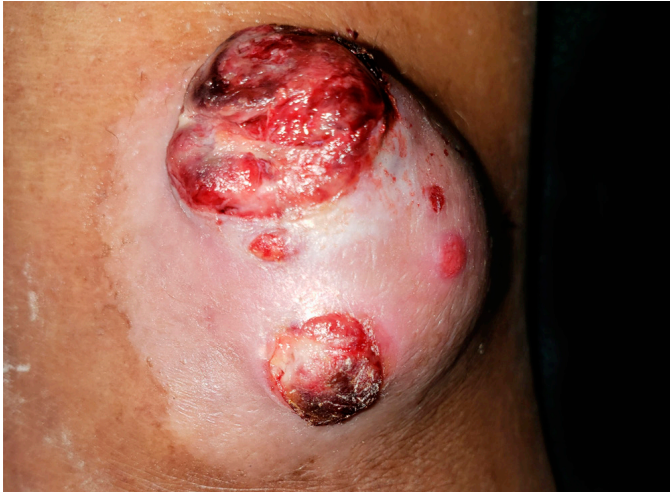

FIGURE 3: Immunohistochemical staining. Smooth surface detail, with friable papules and nodules

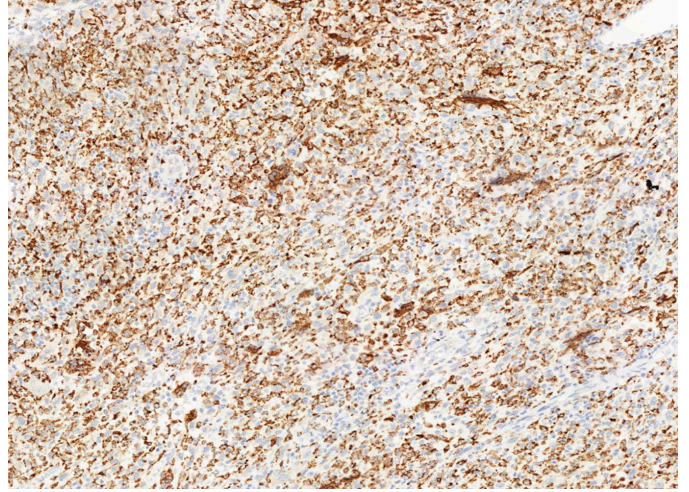


FIGURE 6: Immunohistochemical staining. Extensive CD68 positivity (histiocytes)

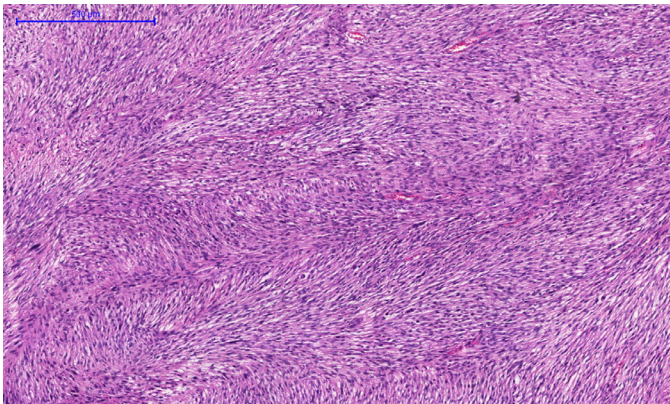


FIGURE 4: Malignant fibrous histiocytoma. Proliferation of spindle cells forming short bundles in different directions (Hematoxylin & eosin,25x)

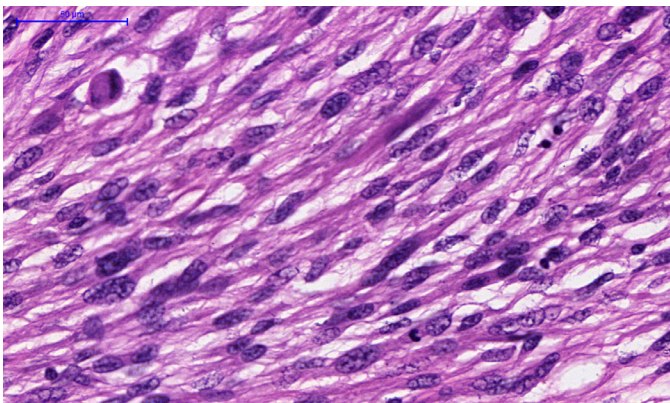


FIGURE 5: Spindle cell bundles detail with. Spindle cell bundles with intense cellular pleomorphism and mitotic activity (Hematoxylin & eosin,100x)

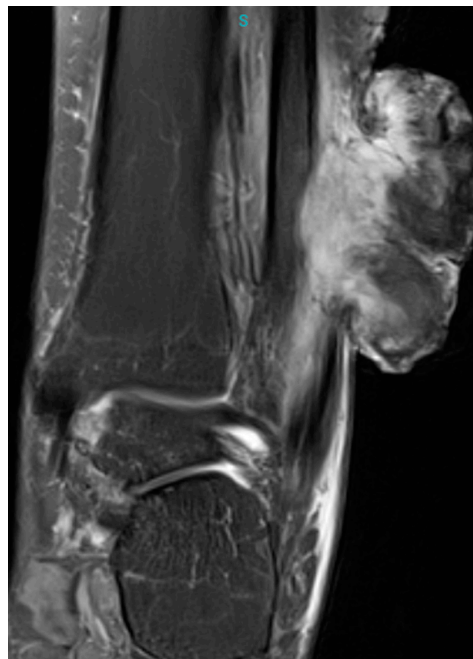

FIGURE 7: Malignant fibrous histiocytoma. Magnetic nuclear resonance image showing a vegetating mass with hypersignal invading the distal portion of the fibula

Soft tissue sarcomas are rare neoplasms, accounting for approximately 1% of solid cancers in adults, representing a heterogeneous group of disorders arising from mesenchymal tissue.⁷

In 2003, Coindre described a new grading for sarcomas, based on immunohistochemical criteria:⁸

- Well-differentiated sarcomas: rhabdomyosarcomas, epithelioid sarcoma, clear cell sarcoma, desmoplastic small round cell tumor, and gastrointestinal stromal tumors.

- Sarcomas with specific histologic typing: Ewing's sarco-

ma, leiomyosarcoma, malignant peripheral nerve sheath tumor, dermatofibrosarcoma protuberans, giant cell fibroblastoma, extraskeletal myxoid chondrosarcoma, liposarcomas, and alveolar soft part sarcoma.

- Undifferentiated sarcomas, or sarcomas of doubtful type (not showing specific markers): fibrosarcoma, myxofibrosarcoma, and malignant fibrous histiocytoma. In these cases, immunohistochemistry can help exclude other non-mesenchymal tumors.

Undifferentiated pleomorphic sarcoma (UPS) can be divided into superficial and deep subtypes, also called atypical fibroxanthoma (AFX) and malignant fibrous histiocytoma (MFH), respectively. The distinction between the entities is essential to predict the locoregional aggressiveness of the tumor and its prognosis.^{9,10}

In this report, MFH occurred in the ankle of an adult woman. However, these tumors predominate in men older than 50 years.⁴ Typically, it presents as a painless, fast-growing tumor, with reports of lesions exclusively subcutaneous.¹¹

UPS diagnosis requires the histopathological differentiation of tumors such as melanoma, squamous cell carcinoma, angiosarcoma, leiomyosarcoma, and other undifferentiated neoplasms.^{12,13}

MFH is recognized as a heterogeneous group of tumors that share a common phenotype, requiring immunohistochemistry, electron microscopy, or molecular studies for better characterization.¹⁴

Histopathology revealed pleomorphic spindle cells arranged in bundles with a storiform pattern, and multinucleated histiocytes infiltrated in the deep dermis and subcutaneous cellular tissue.^{15,16}

MFH has immunoreactivity for vimentin and CD68 (histiocytic marker).^{17,18} S100, desmin, S-100, and HMB-45 are antibodies found in liposarcoma or malignant peripheral nerve tumors, nerve sheath tumor, rhabdomyosarcoma, and malignant melanoma, respectively. Moreover, CD34 shows reactivity in angiosarcomas.^{15,16}

Magnetic resonance imaging is the imaging modality of

choice to assess soft tissue sarcomas, particularly to determine the local extent of the lesion. On examination, the MFH shows a heterogeneous pattern that is hyperdense on T2-weighted images and isodense to muscles on T1-weighted images.¹⁹

Wide excision (margin ≥ 2 cm) is the recommended approach. Nevertheless, there is a limitation due to the proximity to noble structures depending on the topography,¹⁴ indicating micrographic surgery.^{6,20}

Local recurrence high rates are reported in patients undergoing surgical excision (19% to 66%).²⁰⁻²² In this case, we completely removed the lesion and, due to comorbidities, decided not to perform adjuvant chemotherapy.

A study analyzing 167 individuals found that 66% of patients treated with marginal resection had local recurrence compared with 27% of patients who underwent wide resection (margin ≥ 3 cm).²³

Radiotherapy can be beneficial as an adjuvant treatment, using a radiation field covering the tumor site and 5 cm around it, with doses ranging between 50 and 65 Gray. However, the overall impact on recurrence and survival is not fully defined.²⁴

Chemotherapy is typically used for generalized diseases but with poor prognoses.^{25,26} Currently, studies assessing immunobiologicals in patients with advanced diseases are in the clinical phase. This is the case for ipilimumab (anti-CTLA-4), comprising 33 children and young adults, and sunitinib (oral multi-kinase inhibitor) including 48 young adults, which analyzes unresectable or metastatic sarcoma.²⁷

CONCLUSION

MFH presents clinically indistinguishable from other entities, being mainly characterized by aggressive growth behavior. This case report aimed to highlight its main characteristics and the importance of diagnostic suspicion and early treatment to avoid unfavorable outcomes. ●

REFERENCES

- O'Brien JE, Stout A P. Malignant fibrous xanthomas. *Cancer*. 1964;17:1445-55.
- Pobirci DD, Bogdan F, Pobirci O, Petcu CA, Roşca E. Study of malignant fibrous histiocytoma: clinical, statistic and histopatological interrelation. *Rom J Morphol Embryol*. 2011;52(1 Suppl):385-8.
- Marcet S. Atypical fibroxanthoma/malignant fibrous histiocytoma. *Dermatol Ther*. 2008;21(6):424-7.
- Clark DW, Moore BA, Patel SR, Guadagnolo BA, Roberts DB, Sturgis EM. Malignant fibrous histiocytoma of the head and neck region. *Head Neck*. 2011;33(3):303-8.
- Amjad M, Bari A. Malignant fibrous histiocytoma: an uncommon soft tissue sarcoma. *J Pakistan Assoc Dermatol*. 2009;19(4):243-6
- Huether MJ, Zitelli JA, Brodland DG. Mohs micrographic surgery for the treatment of spindle cell tumors of the skin. *J Am Acad Dermatol*. 2001;44(4):656-9.
- Clark MA, Fisher C, Judson I, Thomas JM. Soft-tissue sarcomas in adults. *N Engl J Med*. 2005;353(7):701-11.
- Coindre JM. Immunohistochemistry in the diagnosis of soft tissue tumours. *Histopathology*. 2003;43(1):1-16.
- Fletcher CD. The evolving classification of soft tissue tumours an update based on the new 2013 WHO classification. *Histopathology*. 2014;64(1):2-11.
- Henderson MT, Hollmig ST. Malignant fibrous histiocytoma: changing perceptions and management challenges. *J Am Acad Dermatol*. 2012;67(6):1335-41.
- Luzar B, Calonje E. Morphological and immunohistochemical characteristics of atypical fibroxanthoma with a special emphasis on potential diagnostic pitfalls: a review. *J Cutan Pathol*. 2010;37(3):301-9.
- Pujani M, Hassan MJ, Jetley S. Atypical fibroxanthoma in a young female misdiagnosed clinically as a malignant melanoma - An unusual presentation. *J Cancer Res Ther*. 2015;11(4):1027.
- Deyrup AT, Haydon RC, Huo D, Ishikawa A, Peabody TD, He TC, et al. Myoid differentiation and prognosis in adult pleomorphic sarcomas of the 203 extremity: an analysis of 92 cases. *Cancer*. 2003;98(4):805-13.
- Vassiliou A, Vlastarakos PV, Manolopoulos L, Yiotakis I, Voros D, Carvouni E, et al. Metastatic sarcoma of the tongue: pleomorphic malignant fibrous histiocytoma and literature review. *J Rhinol Otol*. 2014;2(1):10-3.
- Winchester D, Lehman J, Tello T, Chimento N, Hocker T, Kim S, et al. Undifferentiated pleomorphic sarcoma: factors predictive of adverse outcomes. *J Am Acad Dermatol*. 2018;79(5):853-9.
- Al-Agha OM, Igbokwe AA. Malignant fibrous histiocytoma: between the past and the present. *Arch Pathol Lab Med*. 2008;132(6):1030-5.
- Dei Tos AP. Classification of pleomorphic sarcomas: where are we now? *Histopathology*. 2006;48(1):51-62.
- Park SW, Kim HJ, Lee JH, Ko YH. Malignant fibrous histiocytoma of the head and neck: CT and MR imaging findings. *AJNR Am J Neuroradiol*. 2009;30(1):71-6.
- Brown MD, Swanson NA. Treatment of malignant fibrous histiocytoma and atypical fibroxanthomas with micrographic surgery. *J Dermatol Surg Oncol*. 1989;15(12):1287-92.
- Iorizzo LJ, Brown MD. Atypical fibroxanthoma: a review of the literature. *Dermatol Surg*. 2011;37(2):146-57.
- Peiper M, Zurakowski D, Knoefel WT, Izbicki JR. Malignant fibrous histiocytoma of the extremities and trunk: an institutional review. *Surgery*. 2004;135(1):59-66.
- Kearney MM, Soule EH, Ivins JC. Malignant fibrous histiocytoma: a retrospective study of 167 cases. *Cancer*. 1980;45(1):167-78.
- Mundt AJ, Awan A, Sibley GS, Simon M, Rubin SJ, Samuels B, et al. Conservative surgery and adjuvant radiation therapy in the management of adult soft tissue sarcoma of the extremities: clinical and radiobiological results. *Int J Radiat Oncol Biol Phys*. 1995;32(4):977-85.
- Marchese R, Bufo P, Carrieri G, Bove G. Malignant fibrous histiocytoma of the kidney treated with nephrectomy and adjuvant radiotherapy: a case report. *Case Report Med*. Epub 2010.
- Tarjan M, Cserni G, Szabo Z. Malignant fibrous histiocytoma of the kidney. *Scand J Urol Nephrol*. 2001;35(6):518-20.
- ClinicalTrials.gov [Internet]. Bethesda (MD): National Library of Medicine (US). 2011 Oct 3 - . Identifier NCT01445379, Phase I Study of Ipi- limumab (Anti-CTLA-4) in Children and Adolescents With Treatment-Resistant Cancer. Available from: <https://clinicaltrials.gov/ct2/show/NCT00556881>
- ClinicalTrials.gov [Internet]. Bethesda (MD): National Library of Medicine (US). 2006 Nov 17 - . Identifier NCT00400569, Phase II Study of Sunitinib Malate for Metastatic and/or Surgically Unresectable Soft Tissue Sarcoma. Available from: 240 <https://clinicaltrials.gov/ct2/show/NCT00400569>

AUTHORS' CONTRIBUTION:

Helio Amante Miot  ORCID 0000-0002-2596-9294

Approval of the final version of the manuscript; study design and planning; preparation and writing of the manuscript; active participation in research orientation; intellectual participation in propaedeutic and/or therapeutic conduct of studied cases; critical literature review; critical revision of the manuscript.

Cesar Augusto Zago Ferreira  ORCID 0000-0001-7299-1710

Approval of the final version of the manuscript; study design and planning; preparation and writing of the manuscript; critical literature review; critical revision of the manuscript.

Ana Claudia Athanasio Shwetz  ORCID 0000-0002-9373-5019

Approval of the final version of the manuscript; critical literature review; critical revision of the manuscript.

Luciane Donida Miot  ORCID 0000-0002-2388-7842

Approval of the final version of the manuscript; active participation in research orientation; intellectual participation in propaedeutic and/or therapeutic conduct of studied cases; critical literature review; critical revision of the manuscript.

Gabriela Roncada Haddad  ORCID 0000-0002-7516-9586

Approval of the final version of the manuscript; active participation in research orientation; intellectual participation in propaedeutic and/or therapeutic conduct of studied cases; critical literature review; critical revision of the manuscript.