




Case Report

Giant Actinomyces brain abscess in an immunocompetent child: A management strategy

Nicole H. Chicoine¹, Jackson Griffith-Linsley², Joling Goh³, John J. Manaloor⁴, Jeffrey S. Raskin⁵

¹Department of Medical Education, School of Medicine, Marian University College of Osteopathic Medicine, Indianapolis, ²Department of Psychological and Brain Sciences, Indiana University, Bloomington, Indiana, ³Department of Neurological Surgery, Oregon Health and Science University, Portland, Oregon, ⁴Department of Pediatrics, Section of Pediatric Infectious Disease, Riley Hospital for Children, ⁵Department of Neurological Surgery, Section of Pediatric Neurosurgery, Riley Hospital for Children, Indiana University School of Medicine, Indianapolis, Indiana, United States.

E-mail: Nicole H. Chicoine - nchicoine457@marian.edu; Jackson Griffith-Linsley - jacdgrif@iu.edu; Joling Goh - joling.goh@gmail.com; John J. Manaloor - jmanaloor@iuhealth.org; *Jeffrey S. Raskin - jraskin@iuhealth.org



*Corresponding author:

Jeffrey S. Raskin,
Department of Neurological
Surgery, Section of Pediatric
Neurosurgery, Riley Hospital
for Children, Indiana
University School of Medicine,
Indianapolis, Indiana, United
States.

jraskin@iuhealth.org

Received : 14 February 2021

Accepted : 06 May 2021

Published : 06 July 2021

DOI

10.25259/SNI_164_2021

Quick Response Code:



ABSTRACT

Background: Intraparenchymal brain abscess is a collection of microbes caused by inoculation through direct extension or hematogenous spread. Although rare, intraparenchymal abscesses are potentially fatal and can be detected when patients are symptomatic due to local mass effect on adjacent neural tissue. Brain abscess treatment includes medical management with appropriate antibiotics alone or medical management in combination with surgical debridement. Treatment strategies depend on the size and location of disease, as well as the virulence of the microorganism. Similar to medical management strategies, surgical strategies among providers are not uniform, with variation in approaches from complete extirpation of the abscess, including the abscess wall, to minimally invasive stereotactic needle aspiration. In particular, for children, there are no guidelines for therapy.

Case Description: We report a case of giant Actinomycosis right frontal brain abscess in an immunocompetent child without risk factors. A review of the literature for the treatment of brain abscess caused very rarely by Actinomyces in children is performed.

Conclusion: Successful treatment of brain abscess depends on organism and location. The even more uncommon giant intraparenchymal abscesses can be managed with minimal access and prolonged antibiotics, especially when slow-growing organisms are identified. Long-term follow-up should be employed to mitigate missed late failures.

Keywords: Actinomyces, Brain abscess, Medical management, Surgical

INTRODUCTION

Intraparenchymal brain abscesses have been recognized since the early days of modern medicine, with the first recorded treatment of a brain abscess in 1768 by French Surgeon Monrand.^[6] Brain abscesses occur in all populations, with approximately 1500–2000 cases/year in Western nations and in greater numbers in developing nations.^[16] They occur approximately 2–3 times more in men than women.^[17] Abscesses within the pediatric population (patients under 15 years of age) are relatively uncommon and have an incidence between 15 and 50%.^[16] The most common bacterial causes of brain abscesses identified in the pediatric population are *Streptococci*, *Staphylococcus*, and *Enterobacteriaceae*.^[5,22]

This is an open-access article distributed under the terms of the Creative Commons Attribution-Non Commercial-Share Alike 4.0 License, which allows others to remix, tweak, and build upon the work non-commercially, as long as the author is credited and the new creations are licensed under the identical terms.

©2021 Published by Scientific Scholar on behalf of Surgical Neurology International

Diagnostic evaluation for possible brain abscess is critical and should include a medical workup with complete blood count, C-reactive protein (CRP), and erythrocyte sedimentation rate (ESR). Blood cultures should be obtained in febrile patients, especially those with concern for concomitant extra-axial infection.^[9] Lumbar culture is generally not utilized in the setting of brain abscess due to limited yield of cerebral spinal fluid cultures and more importantly because of the significant risk for herniation.^[9,16] Brain abscesses once identified, should be staged radiographically from cerebritis stage to late capsular formation, offering opportunity for surgical planning and prognostic advice for the patient and their families.

Management of a brain abscess utilizes a multifocal approach. The medical antibiotic therapy can be guided by operatively collected positive cultures with susceptibility testing of recovered microbes, to deescalate broad empiric pharmacotherapy. When one or more organisms are identified and developed abscesses are <2.5 cm in diameter, they are commonly treated with antibiotics alone, guided by a hypothesis that the minimum inhibitory concentration at abscess center is sufficiently toxic to the microorganism.^[3,4,9] However, when abscesses grow despite therapy or have a diameter >3 cm, surgical strategies, including craniotomy for excision or stereotactic aspiration, should be performed.^[24] All surgical approaches have potential corridor associated morbidity, and goals of surgery should correlate with invasiveness of the procedure. Large, multiloculated, superficial abscesses in noneloquent areas may benefit from a definitive procedure such as craniotomy and drainage, with or without postsurgical drain placement.^[9,7,16] Conversely, deep abscesses, like those in the thalamus, that fail conservative therapy would benefit from a stereotactic needle aspiration with or without postsurgical drain placement.^[9,16]

There is a high degree of variability in both the antibiotic and surgical strategies for brain abscesses, but overall there are some commonalities, as follows:^[2,9,6,16]

- Treatment is often prolonged, lasting a minimum of 6 weeks
- Selected antibiotics should possess bactericidal properties
- Selected antibiotics must be able to cross the blood-brain barrier
- In nonoperative or culture-negative cases, the antimicrobial spectrum of activity should cover, at minimum, common Gram-positive and anaerobic organisms.

We present a 2-year-old female patient who presented to our practice with a giant right frontal Actinomyces abscess. This presentation of Actinomycosis is highly unusual as there were no identified risk factors, and development of an abscess without risk factors is not frequently reported in literature.

Due to the giant size of the abscess, it required multiple surgical strategies and interventions, ultimately resolving successfully without neurologic complication. The variability in operative approach further demonstrates the immense variability required in management of even one patient, to have resolution of symptoms, and the unusual nature of this case.

CASE REPORT

History

Our 2-year-old patient is the product of a 40-week gestation born through induced vaginal delivery to a Group B *Streptococcus agalactiae* negative mother. She developed normally, without infections, until age 8 months when she developed a febrile urinary tract infection from *Escherichia coli* that was managed with daily prophylactic trimethoprim-sulfamethoxazole for 1 year without recurrence of UTI.

Examination

The patient presented to our emergency department at the age of 2 years 10 months with 3 weeks of headaches, lethargy, malaise, and following 2 days of vomiting before admission. She was afebrile without chills, rashes, recent infections, or on the infectious disease team's evaluation without dental carries. She had only recent domestic travel, without international trips or exposures.

Her vital signs on presentation were normal and her clinical examination reflected an awake, alert but low-energy female with the left lower facial droop. Urine culture on presentation falsely recovered >100,000 colony-forming units/mL of *E. coli*, as a repeat culture before starting antibiotics returned negative. Her total white blood cell count was elevated at 15,000, with a neutrophil predominance (66%). She had an elevated ESR of 53 mm/h, as well as CRP which was increased at 6.3 mg/dl. Her preantibiotic therapy admission blood cultures did not recover *E. coli* and were finalized as negative. The symptom of facial droop prompted brain magnetic resonance imaging (MRI) [Figure 1].

Operation

Consequently, the child underwent right frontal burr hole craniectomy and ultrasound-guided needle aspiration with removal of 50 mL of purulent material, with a Gram stain detecting Gram-positive cocci. Initially, the patient was empirically treated with broad-spectrum intravenous (IV) triple antimicrobial therapy using vancomycin, cefepime, and metronidazole. Promptly, Actinomyces grew in the operative anaerobe culture within 48 h and was found to be pansusceptible. Subsequently, a peripherally inserted central catheter (PICC) was inserted and the child was converted to

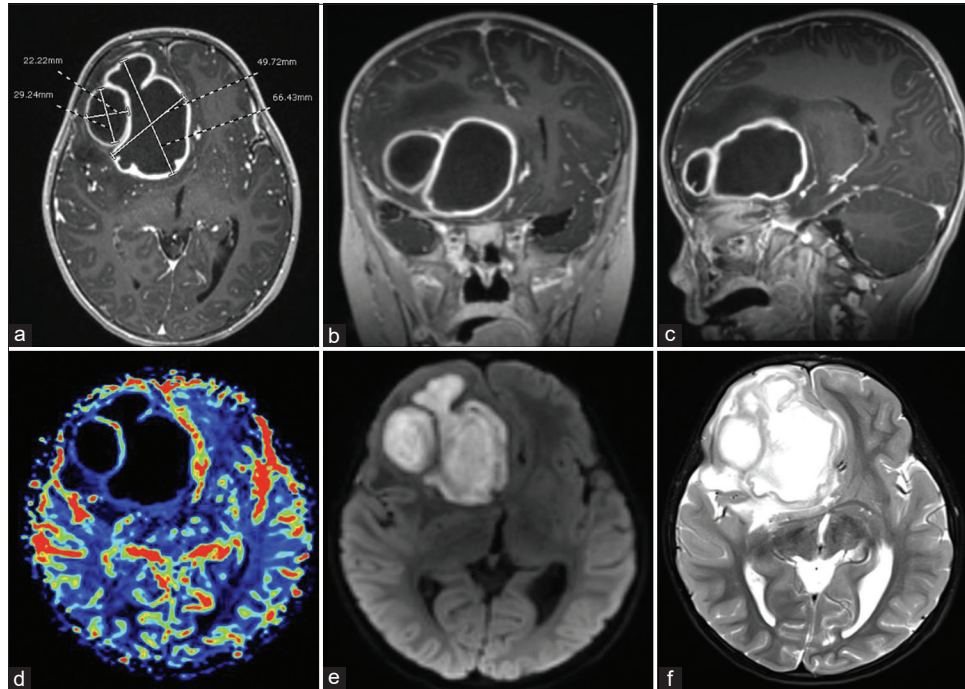


Figure 1: Preoperative (a) axial, (b) coronal, (c) parasagittal T1 postgadolinium demonstrates two large ring-enhancing right frontal lesions causing significant mass effect, subfalcine herniation, and 19 mm midline shift. (d) Axial cerebral blood flow study demonstrates no blood flow within lesions, (e) axial diffusion restriction sequence, (f) axial T2 demonstrates extent of cerebral edema.

a continuous IV penicillin G (6,000,000 units/day), infused over 22 h, with oral metronidazole 120 mg every 6 h.

Postoperative course

The patient was discharged home on postoperative day (POD) 6 with a 2-week Decadron taper given her cerebral edema and prophylactic levetiracetam therapy. Eleven days later, she returned to the emergency department with a PICC-associated nonocclusive thrombus with a white blood cell elevation to 19,000, but an ESR of 5 (peak 60) and CRP of <0.5 (peak 6.3). Her PICC line was replaced in the opposite arm.

Seventeen days postoperatively, she represented to the emergency department with fever, emesis, and return of the left lower facial droop and continued headaches. Despite compliance with the prescribed antibiotic therapy, and in the absence of symptoms consistent with an alternative localizing infection, the white blood cell was found to be 11,800, with interval increases in ESR (70) and CRP (3.6). MRI, at this time, demonstrated a larger abscess in all dimensions. Due to radiographic worsening, recurrent symptoms, and worse inflammatory markers, the child was taken back to the operating room for aspiration and placement of an intra-abscess drain, and briefly provided IV vancomycin, changing penicillin to ceftriaxone. [Figure 2] demonstrates pre- and immediate postoperative representative sections from MRI.

The drain had daily decreased output from 30 mL, 19 mL, 11 mL, 8 mL, 5.5 mL, 3 mL, 2 mL, and 1.5 mL and was discontinued on POD 9. Antibiotic therapy was limited to ceftriaxone and oral metronidazole and since there was no growth of organism from any operative specimen collected during this third admission.

After 13 weeks of ceftriaxone and metronidazole following her second, and definitive, surgery, she is neurologically normal without developmental delay. [Figure 3] demonstrates representative images from multiple time points in the postoperative period throughout 3 months of antimicrobial therapy. The PICC and antimicrobial therapy were discontinued at this time with resolution of abscess on imaging.

One month following treatment cessation, she developed fever and abdominal pain with transaminitis not previously seen during antimicrobial therapy. She was diagnosed with cholelithiasis, to which her prolonged ceftriaxone therapy likely contributed, and underwent an uncomplicated cholecystectomy. Surgical pathology demonstrated a gallbladder with some irregular cholelithiasis but was otherwise normal. The patient is currently in preschool and learning to be potty trained.

DISCUSSION

Otto Bollinger first discovered *Actinomyces* in 1877 in cattle, with subsequent recovery of the bacteria in soil by Eugen

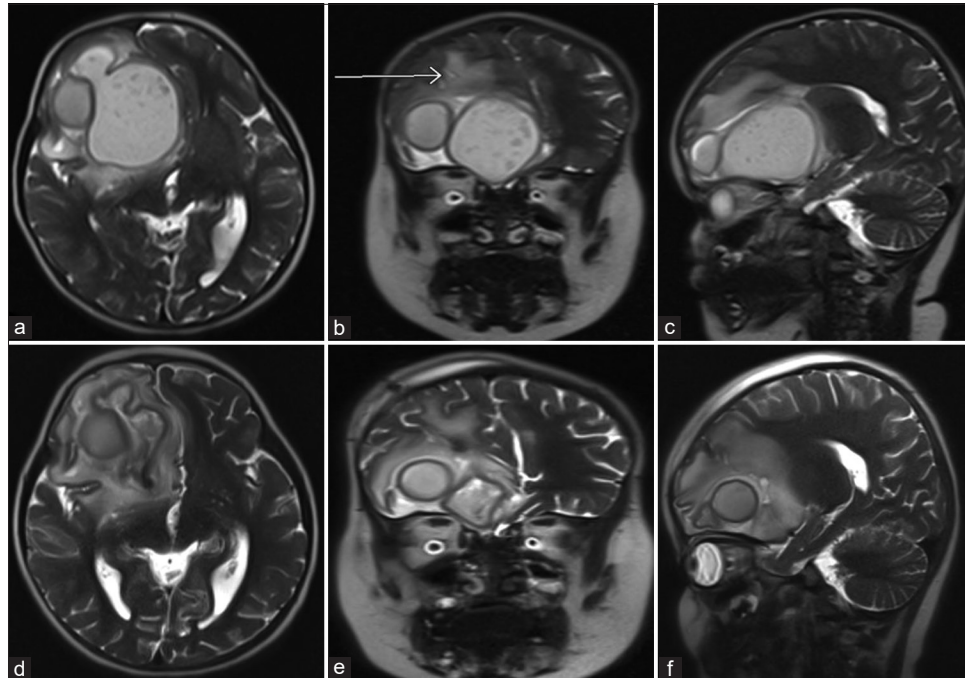


Figure 2: Preoperative (a) axial, (b) coronal, (c) parasagittal T2 demonstrates slightly larger brain abscesses compared with previous imaging, stable mass effect, arrow points to previous needle tract. Postoperative (d) axial, (e) coronal, (f) parasagittal T2 demonstrates decompression of giant frontal abscess, stable size of the loculated satellite abscess measuring 2 cm.

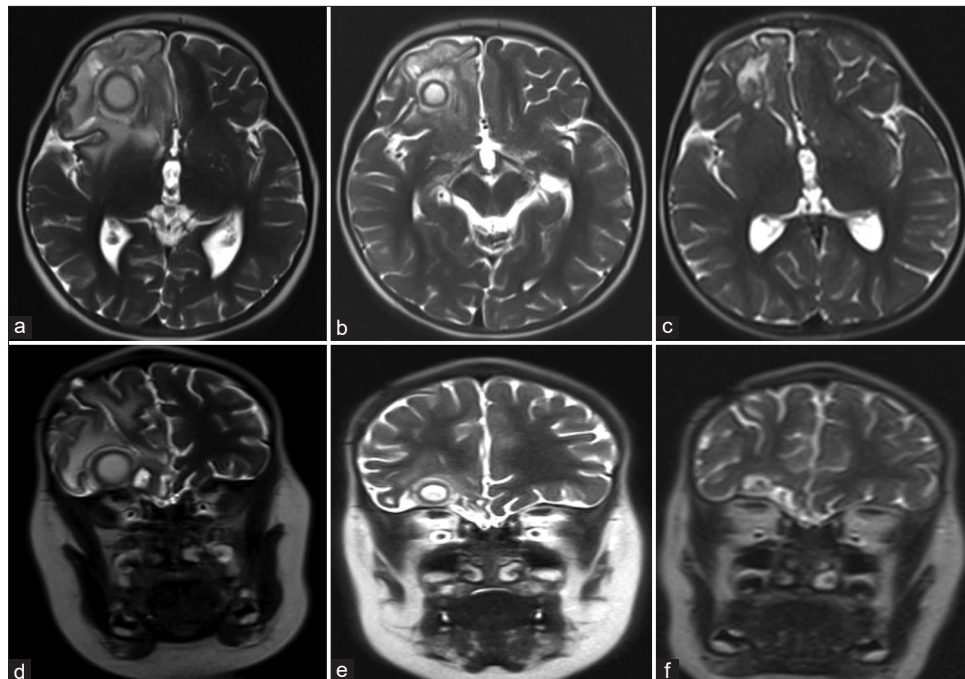


Figure 3: T2 MRI following aspiration and drain placement of the right frontal giant abscess at discharge (a) axial and (b) coronal, at 6 weeks follow-up (c) axial and (d) coronal, and at 3 months follow-up (e) axial and (f) coronal. There is progressive improvement in cerebral edema, mass effect, and ultimately obliteration of the abscesses.

Bosteon.^[21] By 1878, Actinomyces as a human pathogen had been appreciated due to the works of J. Israel and M. Wolff.^[19,21,23] Actinomyces is an anaerobic branching filamentous

Gram-positive bacillus.^[26] Most commonly, actinomycosis infections present as cervicofacial, abdominopelvic, and respiratory infections.^[26,28] Central nervous system (CNS)

Table 1: Literature review summary (case year, author, patient age, procedure, antibiotic regimen, duration, resolution, and follow-up).

Case Year	Source/ Author	Age	Sex	Procedure	Antibiotic	Duration	Resolution/ Follow Up	
1963	Heineman Braude	14 years	M	Craniotomy and drainage	Regimen IV 10 million units penicillin	16 days	Resolved; unknown follow up	
		29 years	F	Craniotomy and drainage	IV Sulfisoxazole 1 gm TID IV Tetracycline 1 gm TID	16 days		
2007	Mylonas Tzerbos Rologis Boutsikakis	54 years	M	Craniotomy and resection of abscess	IV Penicillin 20 million units/day	2 weeks	Recovered with relapse 2.5 years later, attributed to incomplete surgical evacuation	
					IV Tetracycline 2 gm/day	2 weeks		
					IV Ceftriaxone 200 mg BID	23 days		
					IV Metronidazole 50 mg QID	23 days		
					IV Vancomycin 500 mg TID	23 days		
2007-2009	Akhaddar Elouennass Baallal Boucetta	18 years	M	Burr hole craniotomy	IV Ofloxacin 200 mg TID	5 weeks	Resolved; unknown follow up	
					IV Teicoplanin 400 mg BID	5 weeks		
		19 years	M	Burr hole with surgical evacuation	IV Metronidazole	1 month		
					Oral Erythromycin	2 months		
					IV Ciprofloxacin	1 month		
		45 years	M	Surgical excision	IV Ceftriaxone	10 days		Resolved; unknown follow up
					IV Gentamicin	10 days		Resolved; unknown follow up
					IV Metronidazole	10 days		
		57 years	F	Burr hole craniotomy and drainage	Oral Ciprofloxacin 1 gm/day	2 months		Resolved; unknown follow up
					IV Cephalosporin	Unknown		
		80 years	M	Burr hole aspiration; Left craniotomy and drainage 1 month after initial aspiration	Oral Ciprofloxacin 1 gm/day	2 months		Resolved; unknown follow up
IV Gentamicin	4 weeks							
IV Metronidazole	4 weeks							
Oral Ciprofloxacin 1 gm/day	2 months							
					IV Cefotaxime	Unknown	Resolution of neurological symptoms in 6 weeks; unknown follow up	
					IV Gentamicin	Unknown		
					IV Metronidazole	Unknown		
					Oral Ciprofloxacin 1 gm/day	2 months		

(Contd...)

Table 1: (Continued).

Case Year	Source/ Author	Age	Sex	Procedure	Antibiotic	Duration	Resolution/ Follow Up
2010-2016	Ravinda Sadashiva Mahadevan Bhat Saini	1.5 months	M	Surgical excision	Cloxacillin	7 days	Resolved; follow up 54 months
		14 years	M	Stereotactic aspiration	Injected Penicillin	6 weeks	Resolved; follow up 11 months
		15 years	M	Craniotomy and removal bone flap with orbital de-roofing excision	Amoxicillin Penicillin	10 months 6 weeks	Resolved; follow up 32 months
		18 years	F	Craniotomy and excision	Rifampicin Amoxicillin Unknown	6 weeks 1 year Unknown	Unknown
		20 years	M	Craniotomy and excision	Ceftriaxone	4 weeks	Resolved; follow up 30 months
		21 years	M	Re-exploration of excision	Ofloxacin Metronidazole Unknown	4 weeks 4 weeks Unknown	Unknown follow up
		24 years	M	Bi-frontal craniotomy and excision	Unknown	Unknown	Unknown follow up
		29 years	M	Bi-frontal craniotomy and decompression	Unknown	Unknown	Unknown follow up
		30 years	M	Craniotomy and decompression of lesion	Amoxicillin	2 months	Resolved with nondependent ataxia; follow up 54 months
		35 years	M	Craniotomy and excision	Unknown	Unknown	Unknown follow up
		36 years	M	Re-exploration and removal of bone flap	Ceftriaxone	2 weeks	Resolved; follow up 10 months
		39 years	F	Craniotomy and excision	Amikacin Metronidazole Unknown	2 weeks 2 weeks Unknown	Unknown follow up
		40 years	F	Craniotomy and excision	Cefotaxime	2 weeks	Resolved; follow up 120 months
		45 years	F	Craniotomy with tapping of abscess	Amikacin Ofloxacin	2 weeks 4 weeks	Resolved with non-associated hemiparesis; follow up 80 months
		51 years	M	Endoscopic Transsphenoidal removal	Amikacin Metronidazole Unknown	4 weeks 2 weeks Unknown	Unknown follow up
		52 years	M	Re-exploration of excision	Unknown	Unknown	Unknown follow up
65 years	M	Stereotactic aspiration	Ceftriaxone Amikacin Metronidazole	1 week 1 week 1 week	Resolved; follow up 22 months		

(Contd...)

Table 1: (Continued).

Case Year	Source/ Author	Age	Sex	Procedure	Antibiotic	Duration	Resolution/ Follow Up
2014	Valour Senechal Dupieux Karsenty Lustig Breton Gleizal Boussel Laurent Braun Chidiac Ader Ferry	50 years	M	Stereotactic aspiration	Unknown	Unknown	Unknown follow up
2015	Clancy Ronayne Prentice Jackson	55 years	F	Craniotomy and drainage	Vancomycin	11 days	Resolved with seizure prophylaxis (levetiracetam); follow up ongoing
2017	Guillament Malinis Meyer	29 years	M	Stereotactic drainage	Ceftriaxone Metronidazole Oral Amoxicillin Oral TMP-SMX BID	4 months 1 month 8 months Post-operatively	Resolved within 6 months; unknown follow up
2017	Corcione Curtoni Paolucci Perri De Rosa Cavallo	21 years			IV Metronidazole 500 mg BID IV Vancomycin 1 g TID Oral Doxycycline 100 mg BID IV Vancomycin IV Metronidazole Oral Metronidazole Vancomycin	Post-operatively Post-operatively 6-12 months 4 weeks 6 weeks 5 months Unknown	Resolved; unknown follow up
2018	Hwang Lee Hong Kim Kim	51 years	F	Craniotomy with stereotactic guidance and evacuation	Ampicillin/ Sulbactam IV Ceftriaxone Oral Amoxicillin Moxifloxacin 400 mg/daily	Unknown 4 weeks 5 months 6 weeks	Resolved within 12 months of follow up
					IV Teicoplanin 400 gm/day Oral Cefpodoxime 100 mg BID Levofloxacin 500 mg/daily	6 weeks 6 weeks 6 months	

Actinomyces infection is an uncommon presentation, occurring in <5% of infected individuals and can manifest as a brain abscess, meningitis, meningoencephalitis, epidural abscess, or subdural empyema.^[19,26] These varied CNS presentations develop through hematogenous spread or direct extension from an adjacent infection.

The low rate of confirmed Actinomyces diagnosis is likely confounded by the difficulty of recovering this microbe in the laboratory, on account of slow growth and strict anaerobic metabolism. Growth on the enriched medium of chocolate blood agar can take anywhere from 5 to 20 days and cannot be reasonably excluded without a minimum 10 days of “no growth” to be considered negative.^[26] Classification of this infectious agent was previously reliant on branching filamentous features, although observing sulfur granules on microscopy which form once the bacteria have induced a chronic granulomatous infection, can aid in diagnosis.^[7] Modern technologies, such as polymerase chain reaction of 16S ribosomal RNA gene sequencing and matrix-associated laser deionization-time of flight, have proven helpful in identifying Actinomyces infection utilizing samples from pus from a brain abscess, and cultures from CSF, blood, urine, and sputum.^[7,26] These more modern techniques will optimistically lead to earlier identification of infection, and thus earlier and more successful intervention.

Typically, cerebral abscesses from Actinomyces affect adults with predisposing factors including congenital heart defects, chronic otitis media, otologic surgery, chronic sinus infections, dental infections, alcoholism, IV drug use, and infected intrauterine device.^[5,6,8,10,11,12,13,19] In the pediatric population, the most common causes include direct extension from chronic otitis media or dental abscess and hematogenous seeding with concomitant congenital heart disease.^[5,6] These brain abscesses manifest clinically with symptoms as sequelae of local mass effect by compression of adjacent neural tissue including the venous sinuses, global mass effect by increasing intracranial pressure, or development of hydrocephalus.^[2,16] Clinically, these symptoms manifest as generalized malaise, lethargy, fever, and seizures.^[5,18,26] Recognition by a clinician through thorough examination is vital, as rupture of the brain abscess and spilling of purulent contents into the patient’s ventricular system may precipitate a sudden clinical decompensation and is a dreaded complication with a mortality rate >40%, reaching even as high as 80%.^[20]

On recognition of these abscesses, the management of CNS Actinomyces infection is multimodal. Despite the acquisition of susceptibility data, the antibiotic regimen for Actinomyces specific has immense variability. [Table 1] summarizes the variations in antibiotic choice, duration of treatment, as well as operative approach. Most reported cases resolved by an average 18 months, with one case with long-term failure 2½ years posttreatment. Initially, due to the culture results and susceptibility data, our team selected

the combination of IV penicillin G, with oral metronidazole. However, her clinical course and persistently elevated infectious markers, ultimately required broadening to the combination of ceftriaxone and metronidazole to best optimize coverage of unrecovered conventional pathogens, and the outcome for our patient. The surgical management of Actinomyces infection also has tremendous variation. Initially, we performed a burr hole craniectomy with ultrasound-guided aspiration which is a widely accepted intervention particularly in deep parenchymal abscesses; however, due to a combination of radiographic worsening and recurrent symptoms, with worsening inflammatory markers despite compliance with prescribed antimicrobial therapy, our patient underwent a subsequent ultrasound-guided aspiration of her abscess, with placement of an intra-abscess drain that was successfully discontinued on day 9 of her readmission.

CNS Actinomyces infections are found in patients of all ages, although more cases reported in literature, are in the adult population. Within the pediatric population, there are a limited number of reported cases, and exceedingly rare, are those in an immunocompetent child without notable risk factors. We found no such cases in our literature review of an immunocompetent pediatric patient, like ours, developing an Actinomyces brain abscess. The common tie between pediatric and adult cases is the variability in the management of both antimicrobial and surgical approaches. In the case of a 2-year-old patient who uniquely had no risk factors, we found success utilizing a minimal access surgery with placement of intra-abscess drain and 3 months of antibiotic therapy using ceftriaxone with metronidazole. We recommend this management in the future for pediatric patients with CNS Actinomyces abscesses.

CONCLUSION

Brain abscess is a rare consequence of hematogenous spread or direct extension of adjacent infection, and without appropriate often combinatorial treatment can frequently prove fatal. Successful treatment depends on organism and location. The even more uncommon giant intraparenchymal abscesses can be managed with minimal access and prolonged antibiotic therapy, especially when slow-growing organisms are identified. Long-term follow-up should be employed to mitigate missed late failures.

Declaration of patient consent

Patient’s consent not required as patient’s identity is not disclosed or compromised.

Financial support and sponsorship

Nil.

Conflicts of interest

There are no conflicts of interest.

REFERENCES

- Akhaddar A, Elouennass M, Baallal H, Boucetta M. Focal intracranial infections due to *Actinomyces* species in immunocompetent patients: Diagnostic and therapeutic challenges. *World Neurosurg* 2010;74:346-50.
- Alvis MH, Castellar-Leones SM, Elzain MA, Moscote-Salazar LR. Brain abscess: Current management. *J Neurosci Rural Pract* 2013;4:S67-81.
- Andrews JM. Determination of minimum inhibitory concentrations. *J Antimicrob Chemother* 2001;48 Suppl 1:5-16.
- Arlotti M, Grossi P, Pea F, Tomei G, Vullo V, de Rosa FG, *et al.* Consensus document on controversial issues for the treatment of infections of the central nervous system: Bacterial brain abscesses. *Int J Infect Dis* 2010;14:S79-92.
- Brook I. Aerobic and anaerobic bacteriology of intracranial abscesses. *Pediatric Neurol* 1992;8:210-4.
- Chen M, Low SY, Muzumdar D. Management of brain abscesses: Where are we now? *Childs Nerv Syst* 2018;34:1871-80.
- Clancy U, Ronayne A, Prentice MB, Jackson A. *Actinomyces meyeri* brain abscess following dental extraction. *BMJ Case Rep* 2015;13:2015.
- Corcione S, Curtioni A, Paolucci IA, di Perri G, de Rosa FG, Cavallo R. Neurological disease may precede lymphadenopathies in *Actinomyces Europaeus* infection. *J Infect Public Health* 2018;11:592-3.
- Greenberg MS. *Handbook of Neurosurgery*. New York: Thieme; 2016. p. 320-6.
- Guillamet LJ, Malinis MF, Meyer JP. Emerging role of *Actinomyces meyeri* in brain abscesses: A case report and literature review. *IDCases* 2017;10:26-9.
- Hall A, White MA, Gallo P. An intra-cerebral abscess in a patient with Eisenmenger syndrome: An unusual case. *Int J Surg Case Rep* 2016;20:138-41.
- Heineman HS, Braude AI. Anaerobic infection of the brain. Observations on eighteen consecutive cases of brain abscess. *Am J Med* 1963;35:682-97.
- Hwang CS, Lee H, Hong MP, Kim JH, Kim KS. Brain abscess caused by chronic invasive actinomycosis in the nasopharynx: A case report and literature review. *Medicine (Baltimore)* 2018;97:e0406.
- Jang Y, Moon J, Jun JS, Kim TJ, Park KI, Lee ST, *et al.* Case of *Rickettsia typhi*-induced brain abscess mimicking brain tumor. *Osong Public Health Res Perspect* 2018;9:122-5.
- Moal G, Landron C, Grollier G, Bataille B, Roblot F, Nassans P, *et al.* Characteristics of brain abscess with isolation of an anaerobic bacteria. *Scand J Infect Dis* 2003;35:318-21.
- Muzumdar D, Jhawar S, Goel A. Brain abscess: An overview. *Int J Surg* 2011;9:136-44.
- Muzumdar D. Central nervous system infections and the neurosurgeon: A perspective. *Int J Surg* 2011;9:113-6.
- Mylonas A, Tzerbos FH, Mihalaki M, Rologis D, Boutsikakis I. Cerebral abscess of odontogenic origin. *J Craniomaxillofac Surg* 2007;35:63-7.
- Ravindra N, Sadashiva N, Mahadevan A, Bhat DI, Saini J. Central nervous system actinomycosis—a clinicoradiologic and histopathologic analysis. *World Neurosurg* 2018;116:e362-70.
- Savardekar AR, Krishna R, Arivazhagan A. Spontaneous intraventricular rupture of pyogenic brain abscess: A short series of three cases and review of literature. *Surg Neurol Int* 2016;7:S947-51.
- Sharma RR, Apollina S. Cranio-cerebral abscesses in nocardiosis and Actinomycosis: Assessment and management strategies. *JSM Brain Sci* 2017;2:6.
- Sheehan JP, Jane JA, Ray DK, Goodkin HP. Brain abscess in children. *Neurosurg Focus* 2008;24:E6.
- Shiordia J, Lopez-Mariscal C, Reynoso-Gonzalez R, Manriquez-Mejia M. Abdominal Actinomycosis: Case report and literature review. *Acad J Microbiol Res* 2016;4:15-26.
- Stephanov S. Surgical treatment of brain abscess. *Neurosurgery* 1988;22:724-30.
- Stone JL. Paul Broca and the first craniotomy based on cerebral localization. *J Neurosurg* 1991;75:154-9.
- Valour F, Senechal A, Dupieux C, Karsenty J, Lustig S, Breton P, *et al.* Actinomycosis: Etiology, clinical features, diagnosis, treatment, and management. *Infect Drug Resist* 2014;7:183-97.
- Vidanaral AH, Kasper K, Karlowsky J, Walkty A. Successful treatment of *Bacillus cereus* group brain abscesses with a combination of high-dose ciprofloxacin and vancomycin. *Official J Assoc Med Microbiol Infect Dis Can* 2017;2:64-8.
- Wong VK, Turmezei TD, Weston VC. Actinomycosis. *BMJ* 2011;343:785-90.

How to cite this article: Chicoine NH, Griffith-Linsley J, Goh J, Manaloor JJ, Raskin JS. Giant actinomyces brain abscess in an immunocompetent child: A management strategy. *Surg Neurol Int* 2021;12:325.