

Background

Fewer than 1% of malignant neoplasms of the breast and similarly less than 1% of extraskeletal osteosarcomas occur as primary osteosarcoma of the breast, making it an incredibly rare group of malignant tumors. Thus far, there is no standardized treatment plan for this rare pathology.

We introduce a case report of a 54-year-old woman who presented with a left breast mass, who subsequently underwent a left partial mastectomy and sentinel node biopsy with following contralateral reduction mammoplasty. Pathology determined the left breast mass to be osteosarcoma of the breast.

References

1. Wilson H. Extraskeletal ossifying tumors. *Ann Surg* 1941; 113:95-112.
2. Thampi S, Matthey KK, Boscardin WJ, Goldsby R, DuBois SG. Clinical Features and Outcomes Differ between Skeletal and Extraskeletal Osteosarcoma. *Trovik C, ed. Sarcoma*. 2014;2014:902620. doi:10.1155/2014/902620
3. C.J. Allan, E.H. Soule Osteogenic sarcoma of the somatic soft tissues. *Clinicopathologic study of 26 cases and review of literature Cancer*, 27 (1971), pp. 1121-1133
4. Krishnamurthy A. Primary breast osteosarcoma: A diagnostic challenge. *Indian J Nucl Med*. 2015;30(1):39. doi:10.4103/0972-3919.147534
5. Ogundiran TO, Ademola SA, Oluwalosin OM, et al. Primary osteogenic sarcoma of the breast. *World J Surg Oncol* 2006;4:90.
6. Silver SA, Tavassoli FA. Primary osteogenic sarcoma of the breast: A clinicopathologic analysis of 50 cases. *Am J Surg Pathol* 1998;22:925-33.
7. McAuley G, Jagannathan J, O'Regan K, et al. Extraskeletal osteosarcoma: Spectrum of imaging findings. *Am J Roentgenol* 2012; 198: W31-7.
8. Mujtaba, B., et al., Primary Osteosarcoma of the Breast: Pathophysiology and Imaging Review. *Curr Probl Diagn Radiol*, 2020. 49(2): p. 116-123.
9. Crevecoeur, J., et al., Primary osteosarcoma of the breast: a case report. *Clin Case Rep*, 2016. 4(1): p. 62-6.
10. Sabate JM, Gomez A, Torrubia S, et al. Osteosarcoma of the breast. *Am J Roentgenol* 2002;179:277-8.
11. Mujtaba, B., et al., Primary Osteosarcoma of the Breast: Pathophysiology and Imaging Review. *Curr Probl Diagn Radiol*, 2020. 49(2): p. 116-123.
12. Rizzi A, Soregaroli A, Zambelli C, et al. Primary osteosarcoma of the breast: A case report. *Case Rep Oncol Med* 2013;2013:1-3.
13. Adem C, Reynolds C, Ingle JN, et al. Primary breast sarcoma: Clinicopathologic series from the Mayo Clinic and review of the literature. *Br J Cancer* 2004;91:237-41
14. Watt AC, Haggard AM, Krasicky GA. Extrasosseous osteogenic sarcoma of the breast: Mammographic and pathologic findings. *Radiology* 1984;150:34.
15. Silver SA, Tavassoli FA. Primary osteogenic sarcoma of the breast: A clinicopathologic analysis of 50 cases. *Am J Surg Pathol* 1998;22:925-33.
16. Voutsadakis IA, Zaman K, Leyvraz S. Breast sarcomas: Current and future perspectives. *Breast* 2011;20:199-204

Fewer than 1% of malignant neoplasms of the breast ... occur as primary osteosarcoma of the breast

Case Report

Methods

Mammography and MRI of the left breast showed a heterogeneously dense mass with irregular margins. The ultrasound guided needle core biopsy from the mass showed atypical spindle cells admixed with multinucleated osteoclast-like giant cells and hemosiderin pigments without any bone formation on the biopsy material. Patient underwent left breast partial mastectomy with axillary sentinel lymphadenectomy and seed localization with unilateral plastic closure, and right breast reduction mammoplasty for symmetry. The histologic examination of the entire excised mass revealed foci of malignant bone production without any evidence of epithelial differentiation or carcinoma.

Results

Diagnosis of extraskeletal breast osteosarcoma. The patient underwent adjuvant chemotherapy with Doxorubicin and Cisplatin. The patient did not show any sign of recurrence of metastatic disease after 3 years of surveillance.

Conclusion

Osteoid tissue in the breast is not indicative of breast osteosarcoma alone, since this can also occur in epithelial neoplasms of the breast, such as metaplastic carcinoma and fibroadenoma. These alternative diagnoses must be ruled out before the mass can be diagnosed as osteosarcoma. Accurate diagnosis of this condition, which only becomes clear upon histological examination, is crucial as unnecessary and ineffective treatments can be avoided when primary breast carcinomas are ruled out.

Though the case presented herein provides further information regarding molecular findings and prognosis, further research is needed to elucidate the pathophysiology of primary breast osteosarcoma as most previous case study reports have included very little imaging (limited to MRI scans) and direct reports from pathologists regarding histology.

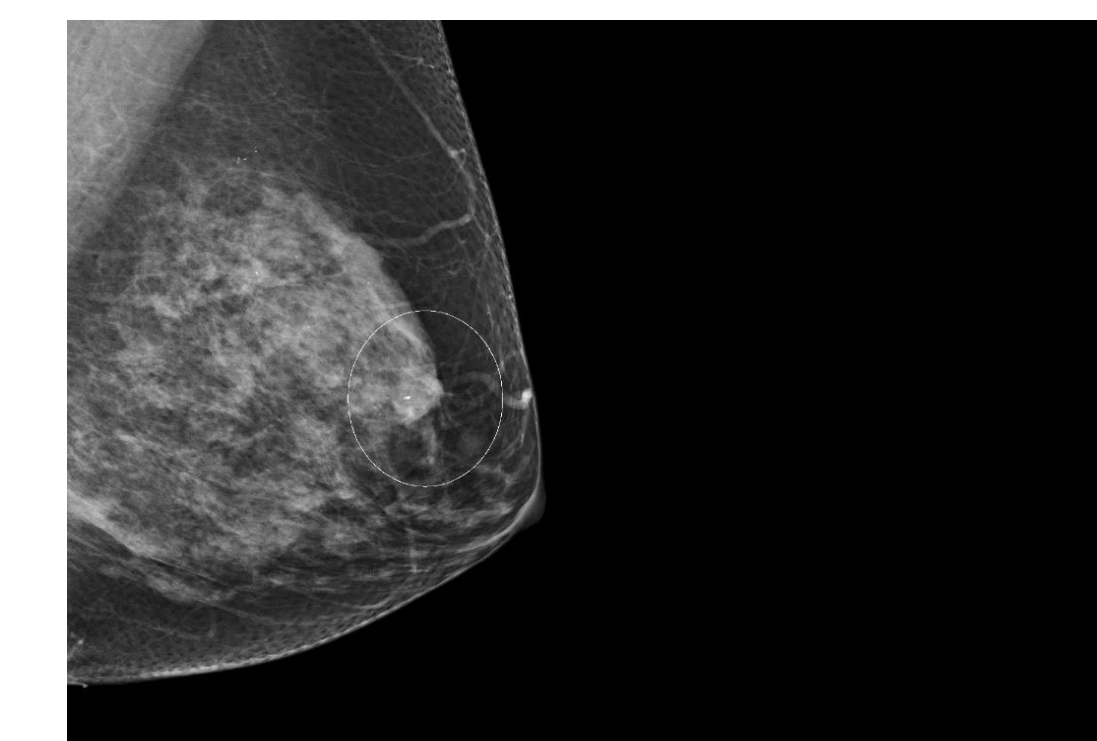


Fig.1: Mammography shows 14 mm heterogeneously dense mass in the left breast

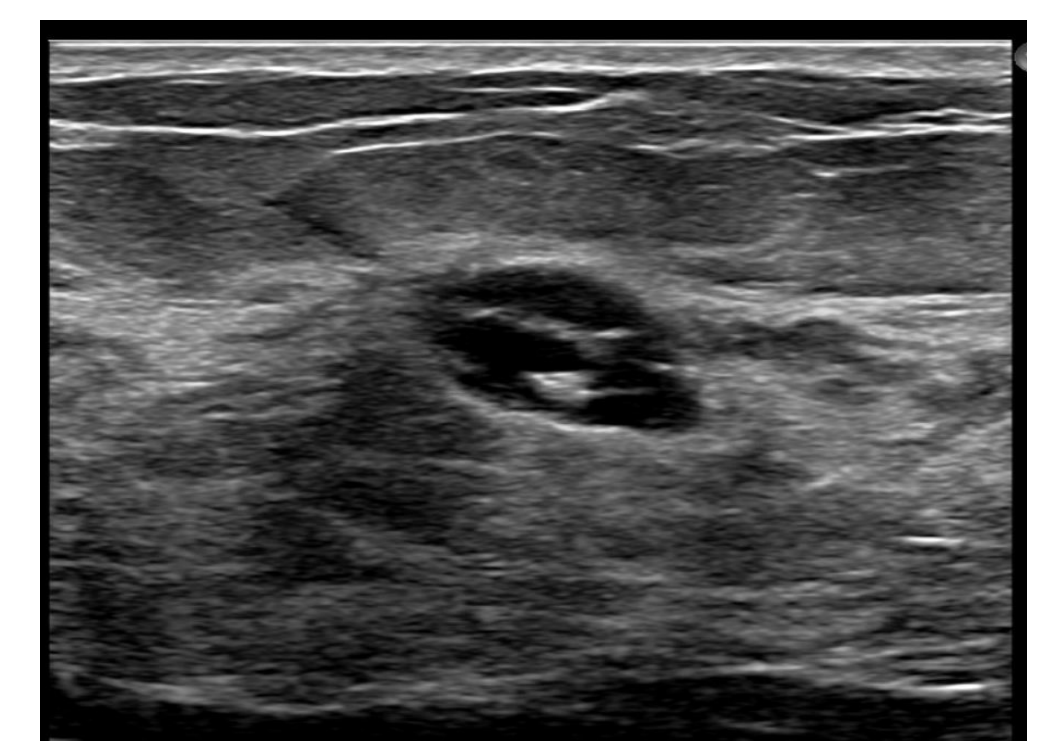


Fig.2: Ultrasound showed a 1.7 x 0.9 x 1.4 cm oval, hypoechoic mass with irregular margins in the left upper central breast at 12:00, 3cm from the nipple.

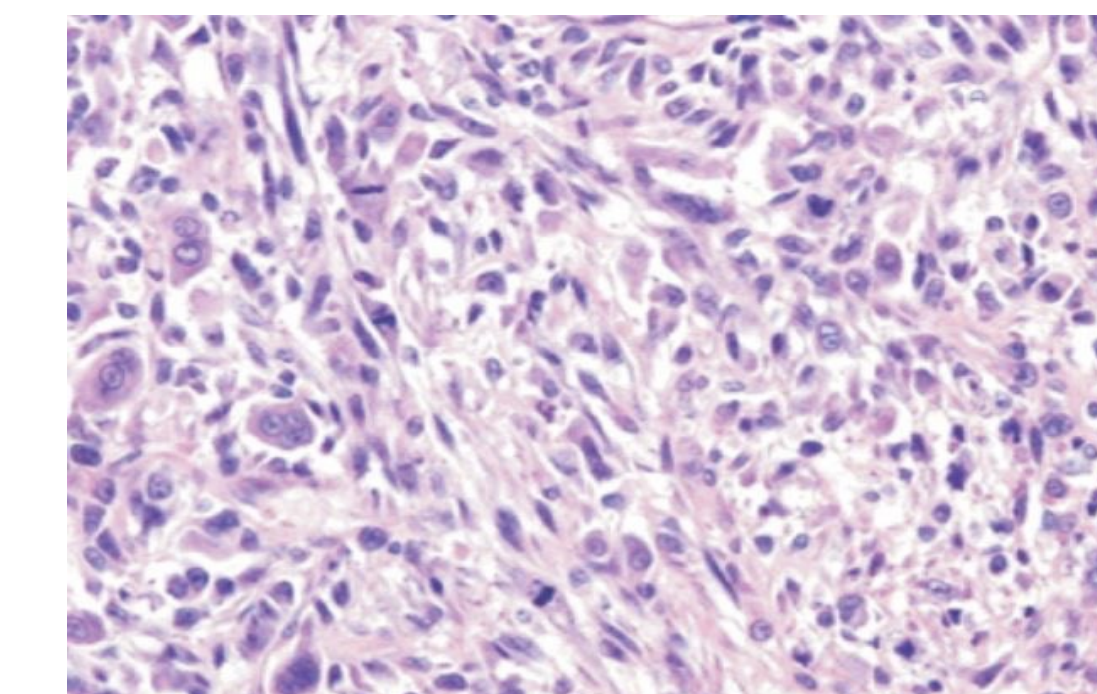


Fig.3: H&E sections from the left breast mass biopsy shows atypical epithelioid to spindle cells with high-grade cytological atypia and mitotic activity and scattered multinucleated multinucleated giant cells and hemosiderin depositions.

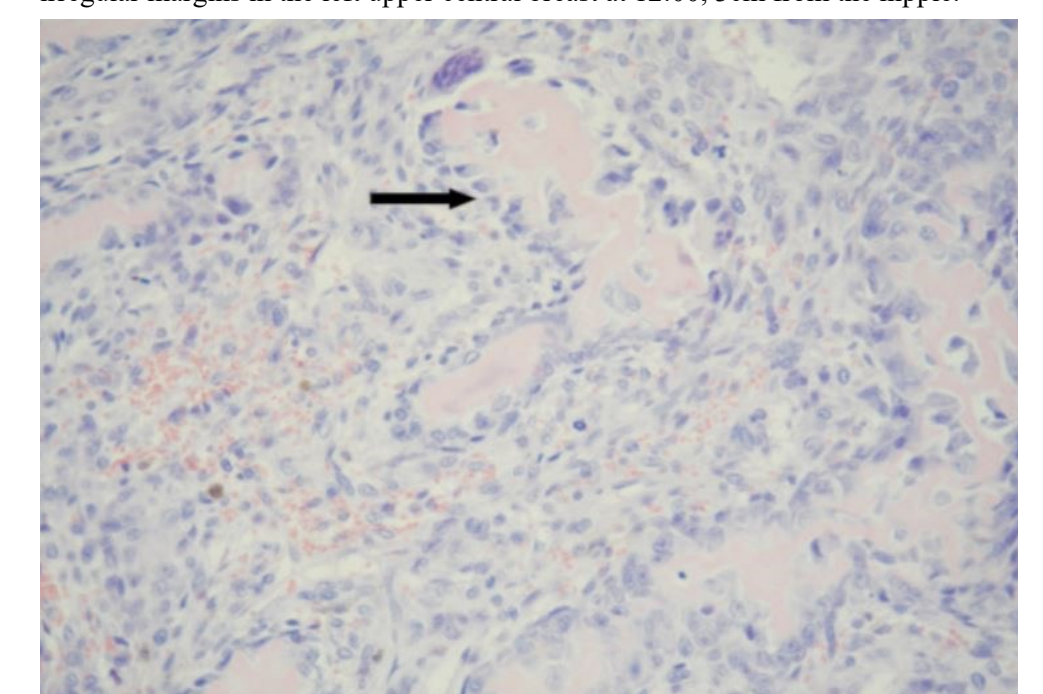


Fig.4: A high magnification of H&E section from the mass show osteoid matrix with surrounding osteoblastic rimming (arrow) with spindle cells and epithelioid cells with high-grade cytological atypia and increased mitotic activities, consistent with osteosarcoma.