

RESEARCH ARTICLE

Risk assessment of pericoronitis in correlation with the position of the inferior third molar

Gabriela Motelica^{1*}

¹Department of OMF surgery and oral implantology „A. Guțan”, Nicolae Testemițanu State University of Medicine and Pharmacy.

Manuscript received on: 22.08.2022

Accepted for publication: 30.09.2022

Corresponding author:

Gabriela Motelica, PhD fellow

Department of OMF surgery and oral implantology „Arsenie Guțan” State University of Medicine and Pharmacy “Nicolae Testemițanu” 165 Ștefan cel Mare și Sfânt Blvd, Chișinău, Republic of Moldova, MD-2004 e-mail: gabriela.motelica@usmf.md

What is not known yet about the topic

The predisposing factors in relation to the etiology of inferior wisdom molar pericoronitis are still a controversial topic in the literature data. One of the most discussed hypotheses is that the position of the wisdom molar could favor the development of the inflammatory-infectious process. Currently, however, there is insufficient data to reveal which atypical orientations of the lower wisdom molar cause an increased risk of developing pericoronitis.

Research hypothesis

The vertical and mesio-angular position (by Winter classification) predispose to a high risk of developing pericoronitis.

The novelty added by manuscript to the already published scientific literature

Based on the obtained results, we will have a better understanding about the predisposing factors for the inflammatory-infectious processes of the inferior molar surrounding tissues.

Abstract

Introduction. The inferior third molar is the most encountered impacted permanent tooth. Pericoronitis of the lower third molar is a term used to describe the inflammation around the crown of a tooth, usually of an incompletely erupted mandibular third molar. Mandibular molar impactions are usually mesioangular, distoangular, vertical, and horizontal. The position and type of the impaction may affect the development of pericoronitis. This study was conducted to assess the positions of the lower wisdom tooth as a risk factor for pericoronitis.

Material and methods. The present study was conducted in the department of Oral and Maxillofacial Surgery and Oral Implantology „Arsenie Guțan”. A number of 120 patients were included in the study (66 women and 54 men) aged between 17-46 years old (mean 27±SD 6). All candidates were subjected to CBCT (cone beam computed tomography) scan and orthopantomography evaluation for a third molar position such as vertical, mesioangular, distoangular, and horizontal type. Data were stored in an Excel spreadsheet and then analyzed statistically using SPSS (Statistical Package for the Social Sciences).

Results. Based on the results of our study the greatest number of cases of pericoronitis was observed in the vertical position (92 cases) by Winter, followed by mesioangular position (24 cases) and distoangular position (4 cases). In the study we did not identify any patient with a horizontal position. By the classification of Pell and Gregory, most cases belonged to class I (73 cases). Third molars classified in position A (92 cases) had greater chance of pericoronitis when compared to those in B (24 cases) or C position (4 cases).

Conclusions. As a result of a detailed analysis, vertical position of the lower third molar is more associated with the appearance of pericoronitis. Considering Pell and Gregory classification, position A is more associated with the occurrence of pericoronitis compared to the position B or C. The prophylactic removal of the lower third semi-erupted vertical molar, or which is situated in position A, is indicated to prevent pericoronitis.

Key words: Pericoronitis, inferior third molar, Winter, Pell&Gregory.

Introduction

The mandibular third molar is the most frequent impacted permanent tooth [1]. Various studies show a prevalence of 9.5 to 39% of third mandibular molars that fail to erupt into the oral cavity [2]. Mandibular molar im-

pactions are usually mesioangular, distoangular, vertical, and horizontal. The position and type of impaction may affect the development of pericoronitis [3]. Pericoronitis is an inflammatory and infectious condition that usually affects an incompletely erupted mandibular third molar. The localized inflammation may range from major regional reactions, such as cellulitis, trismus, pain, and bleeding, to general reactions, such as fever and asthenia [4]. Studies show that pericoronitis is the most common acute problem associated with third molars, and there are several predisposing factors related to the etiology of the disease. One of them is the position of impaction; thus, understanding the relationship between the occurrence of pericoronitis and the clinical and radiographic conditions of the lower third molars is the key for the determination of the clinical behavior of these teeth [5]. The status of impaction can be judged radiographically on orthopantomography and cone beam computed tomography (CBCT). This kind of investigation provides information on assessing the position and status of the tooth. The aim of this study is to determine the most common positions of impaction of the lower wisdom teeth as a risk factor for pericoronitis.

Materials and methods

The present study was conducted in the department of Oro-Maxillo-Facial Surgery and Oral Implantology „Arsenie Guțan” and involved 120 (66 women and 54 men) patients with an age range of 17 – 46 years (mean $27 \pm SD 6$), who came for dental surgical treatment during 2017–2022.

The study was approved by the Ethics Committee of the Nicolae Testemițanu State University of Medicine and Pharmacy, No.82 from 26.04.2017 and informed consents were obtained from all subjects involved in the study.

Patients with partially erupted third molars and radiographic evidence of impaction were included in the study. Clinical conditions such as redness, pus or exudate, pain, trismus, and sensitivity over the pericoronal flap have been evaluated. During the radiological examination, all participants were subjected to CBCT in all three planes scan, operating at 120 kVp, 15 mA, and 18s, and Ortopantomography scan operating at 120 kVp, 15 mA, and 18s, taken with a Planmeca machine. To classify the third molar position of impaction, we used the Winter classification (Figure 1). Reported to the second molar axis, we classified it into vertical (10°), mesioangular ($+11^\circ-70^\circ$), distoangular ($-11^\circ-70^\circ$), and horizontal ($>70^\circ$) positions. All obtained images were read by three independent doctors to increase the accuracy of the study.

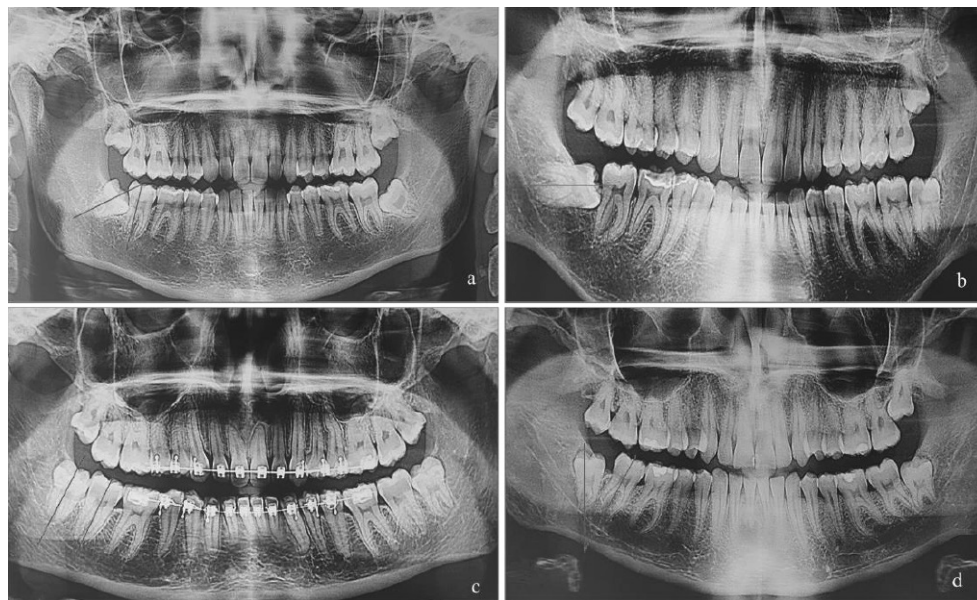


Fig. 1 Third molar impaction by Winter classification (OPG).

(a) – mesio-angular impaction, (b) – horizontal impaction, (c) – vertical impaction, (d) – disto-angular impaction.

Obtained results were subjected to statistical analysis using the SPSS statistical software (IBM SPSS) version 26.0. Independent ttest and Chisquare test were used to determine the significant association between the two variables. P value < 0.05 was considered significant.

Results

Table 1 shows that in our study we involved 120 patients (66 women and 54 men) with an age range of 17 – 46 years (mean $27 \pm SD 6$). Table 1 shows that the maximum number of cases of pericoronitis was observed in the age group 21–25 years (53 patients), followed by 26 – 30 years in 30 cases, and 31 – 35 years in 15 cases. The result was statistically significant at $P < 0.05$

Table 1. Classification of patients by age group.

Age, groups	<= 20 years	Total	10
		Column N %	8,3%
		95.0% Lower CL for Column N %	4.4%
	21 – 25 years	95.0% Upper CL for Column N %	14.3%
		Total	53
		Column N %	44.2%
	26 – 30 years	95.0% Lower CL for Column N %	35.5%
		95.0% Upper CL for Column N %	53.1%
		Total	30
	31 – 35 years	Column N %	25.0%
		95.0% Lower CL for Column N %	17.9%
		95.0% Upper CL for Column N %	33.3%
	36 – 40 years	Total	15
		Column N %	12.5%
		95.0% Lower CL for Column N %	7.5%
	>=41 years	95.0% Upper CL for Column N %	19.3%
		Total	9
		Column N %	7.5%
		95.0% Lower CL for Column N %	3.8%
		95.0% Upper CL for Column N %	13.2%
		Total	3
		Column N %	2.5%
		95.0% Lower CL for Column N %	0.7%
		95.0% Upper CL for Column N %	6.5%

Note: CL – confidence limit; N – number; Upper 95% confidence limit (CL) – sample mean + (1.96); Lower 95% CL – sample mean – (1.96).

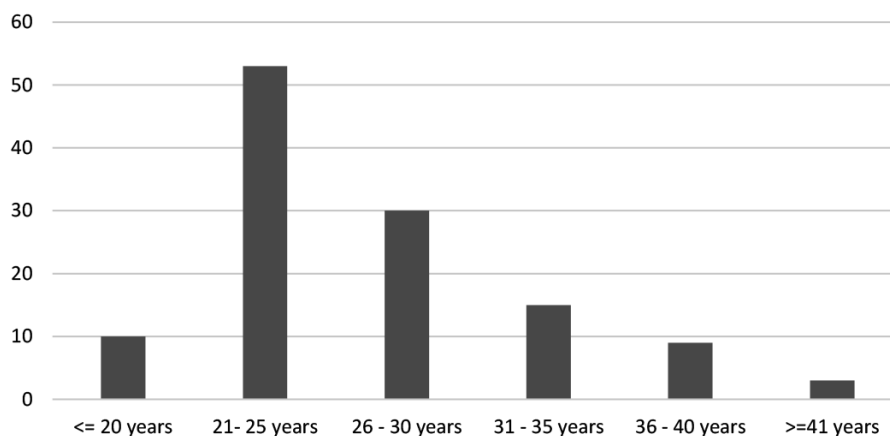


Fig. 2. Categories of patients by age group.

As shown in table 2, there is a significant statistic difference between obtained distribution and the theoretic one (uniform).

Table 2. One-Sample Chi-Square Test Summary.

Total N	120
Test Statistic	86.200 ^a
Degree Of Freedom	5
Asymptotic Sig. (2-sided test)	.000

Note: There are 0 cells (0%) with expected values less than 5. The minimum expected value is 20.

Based on the results of our study, the biggest number of cases of pericoronitis was observed in the vertical position (92 cases) by Winter, followed by the mesioangular position (24 cases) and the distoangular position (4 cases), as shown in table 3. In the study, we did not detect any patients with a horizontal position.

According to the classification by Pell and Gregory shown in Table 4, most cases belonged to Class I (73 cases). Third molars classified in position A (92 cases) had a greater chance of pericoronitis when compared to those in position B (24 cases) or C (4 cases).

Table 3. Wisdom tooth position by Winter classification.

Tooth position by Winter classification	Vertical	Total	92
		Column N %	76.7%
	95.0% Lower CL for Column N %	68.5%	
	95.0% Upper CL for Column N %	83.5%	
	Mesioangular	Total	24
	Column N %	20.0%	
	95.0% Lower CL for Column N %	13.6%	
	95.0% Upper CL for Column N %	27.8%	
	Distoangular	Total	4
	Column N %	3.3%	
	95.0% Lower CL for Column N %	1.1%	
	95.0% Upper CL for Column N %	7.7%	
	Horizontal	Total	0
	Column N %	0.0%	
	95.0% Lower CL for Column N %	.	
	95.0% Upper CL for Column N %	.	

Note: CL – confidence limit; N – number; Upper 95% confidence limit (CL) – sample mean + (1.96); Lower 95% CL – sample mean – (1.96).

Table 4. Wisdom tooth position by Pell&Gregory classification.

Tooth position by Pell&Gregory classification	I	Total	73
		Column N %	60.8%
	95.0% Lower CL for Column N %	51.9%	
	95.0% Upper CL for Column N %	69.2%	
	II	Total	42
	Column N %	35.0%	
	95.0% Lower CL for Column N %	26.9%	
	95.0% Upper CL for Column N %	43.8%	
	III	Total	5
	Column N %	4.2%	
	95.0% Lower CL for Column N %	1.6%	
	95.0% Upper CL for Column N %	8.9%	
	A	Total	92
	Column N %	76.7%	
	95.0% Lower CL for Column N %	68.5%	
	95.0% Upper CL for Column N %	83.5%	
	B	Total	24
	Column N %	20.0%	
	95.0% Lower CL for Column N %	13.6%	
	95.0% Upper CL for Column N %	27.8%	
	C	Total	4
	Column N %	3.3%	
	95.0% Lower CL for Column N %	1.1%	
	95.0% Upper CL for Column N %	7.7%	

Note: CL – confidence limit; N – number; Upper 95% confidence limit (CL) – sample mean + (1.96); Lower 95% CL – sample mean – (1.96).

Discussions

Pericoronitis is an inflammation that occurs in the soft tissues around an erupting tooth. Due to the fact that pericoronitis is particularly related to the complications caused by the eruption of teeth, the third molars, especially the lower ones, are particularly more affected, since they present more limitations and difficulties in the complete eruption, mainly due to lack of space and bad dental positioning [5].

Patients with pericoronitis experience pain, discomfort, swelling, pus discharge, lymphadenopathy, dysphagia, systemic disorders, and serious complications [6].

Clinical studies suggested that the microbiota predominantly responsible for pericoronitis is mainly anaerobic and contains *Campylobacter* species, *Capnocytophaga* species, *Fusobacterium* species, *Micromonas (Peptostreptococcus) micros*, *Prevotella intermedia*, *Prevotella nigrescens*, and *Veillonella* species. Streptococci, staphylococci, actinomycetes, and enterobacteria, as well as protozoa and fungi, have also been described [7].

Based on the results of our study, we can affirm that pericoronitis is more frequently encountered in females as compared to males; this can be explained by the multiple theories from the specialized literature, such that as female's jaws stop growing when the third molars just begin to erupt, in contrast to males, in whom the growth of the jaws continues beyond the time of the eruption of the third molars [8]. Our study shows that maximum number of cases of pericoronitis was observed in the age group 21–25 years (53 patients), followed by 26–30 years in 30 cases, and 31–35 years in 15 cases. These results are very similar to those of the studies by Shin et al. [9] that found that the age group 20–29 years exhibited a maximum number of pathoses associated with a lower third molar and longterm exposure to irritants from the oral cavity. The present study showed that the biggest number of cases of pericoronitis were observed in the vertical position according to Winter. Similar results were noticed in the study conducted by Galvão et al., and McArdle et al, which concluded that a vertically impacted molar is commonly associated with pericoronitis [5, 10]. According to the classification of Pell&Gregory, there is a greater chance of pericoronitis in the position A, in contrast to the results by Galvão et al., who observed that pericoronitis is common in B position. The common symptoms such as swelling, trismus, pain, and difficulty in swallowing, were mostly seen in patients.

Conclusions

Mandibular third molar impaction is a common pathology encountered in young age groups. Dividing the patients into 6 age groups, the maximum number of cases of pericoronitis was observed in the age group 21–25 years, followed by 26–30 years. According to Pell&Gregory's classification, the most common impaction position in pericoronitis occurrence is vertical, followed by the mesioangular position. According to another classification by Pell and Gregory, most cases belonged to class I, position A.

References

1. Singh R, Devanna R, Tenglikar P, Gautam A, Anubhuti, Kumari P. Evaluation of mandibular third molar position as a risk factor for pericoronitis: A CBCT study. *J. Family Med. Prim. Care.*, 2020 Mar 26; 9 (3): 1599-1602.
2. Ramamurthy A., Pradha J., Jeeva S., Jeddy N., Sunitha J., Kumar S. Prevalence of mandibular third molar impaction and agenesis: A radiographic south Indian study. *J. Indian Acad. Oral Med. Radiol.*, 2012; 24: 7.
3. Tsvetanov T. Association of the mandibular third molar position to the pericoronitis. *Int. J. Med. Res. Health Sci.*, 2018; 7: 35-40.
4. Wehr C., Cruz G., Young S., Fakhouri W. An Insight into Acute Pericoronitis and the Need for an Evidence-Based Standard of Care. *Dent. J. (Basel)*, 2019 Sep 2; 7 (3): 88.
5. Galvão E., da Silveira E. *et al.* Association between mandibular third molar position and the occurrence of pericoronitis: A systematic review and meta-analysis. *Arch. Oral Biol.*, 2019 Nov; 107: 104486.
6. Al-Dajani M., Abouonq A., Almohammadi T., Alruwaili M., Alswilem R., Alzoubi I. A cohort study of the patterns of third molar impaction in panoramic radiographs in Saudi population. *Open Dent. J.* 2017; 11: 64860.
7. Katsarou T., Kapsalas A., Souliou C., Stefaniotis T., Kalyvas D. Pericoronitis: A clinical and epidemiological study in Greek military recruits. *J. Clin. Exp. Dent.* 2019 Feb 1; 11(2): e133-e137.
8. Schalch T., Martimbianco A., Gonçalves M., Motta L., Santos E., Cecatto R., Bussadori S., Horliana A. Interventions for Early-Stage Pericoronitis: Systematic Review of Randomized Clinical Trials. *Antibiotics (Basel)*, 2022 Jan 8; 11 (1): 71.
9. Shin S., Choi E., Moon S. Prevalence of pathologies related to impacted mandibular third molars. *Springer plus* 2016; 5: 915.
10. McArdle L.W., Andiappan M., Khan I., Jones J., McDonald F. Diseases associated with mandibular third molar teeth. *Br. Dent. J.*, 2018 Mar 23; 224 (6): 434-440.

Authors' contributions

Gabriela Motelica – Conception and design of study; Gabriela Motelica – Analysis and interpretation of data.

Declaration of conflict of interests

There is no conflict of interest.

Financial disclosure statement

The research did not receive any specific grant from funding agencies in the public, commercial, or not-for-profit sectors.

Authors's ORCID ID:

Gabriela Motelica. <https://orcid.org/0000-0003-1694-2038>