

CAT S60 smartphone as a portable wound care device in home care

Jarmo Alametsä¹, Jari Viik²

¹ no affiliation; ² Faculty of Medicine and Health Technology, Tampere University, Tampere, Finland

Jarmo Alametsä, Ph.D., FINLAND. Email: jarmo.alametsa@kolumbus.fi

Abstract

The purpose of this work is to study the suitability of the CAT S60 smartphone with built-in thermal camera to be used in self and home care to detect the risk level of wound appearance in advance. The purpose was to clarify different conditions where thermal imaging might act as a resource in detecting changes in limb circulation before visual signs even occur. The purpose is to detect early incipient tissue damage in foot usually occur in diabetic patients. Thermal images were acquired from voluntary domesticated elderly people. Thermal pictures from limbs of 3 persons were studied in order to find thermal differences indicating possible changes in limb circulation.

Noteworthy thermal differences between limbs were found in elderly people. A smartphone having built-in thermal camera enables to detect plantar and limb thermal differences with a sufficient accuracy. This may support home monitoring for elderly people and thus reduce foot ulcers and possible foot amputations due to earlier detection and identification of harmful changes in limb circulation. Earlier detection of circulatory insufficiency via thermal imaging makes possible for nurses to intervene and enable medical assistance.

Keywords: thermal imaging, diabetes, self care, home care

Introduction

Diabetes Mellitus (DM) is a metabolic chronic disease seen as an association with abnormal glucose levels in the blood. In type I causing DM the pancreas produces abnormal levels of insulin and in type II the human cells react inadequately to insulin. Both of these types affect negatively to cardiovascular system, body extremities and kidneys [1]. Foot complications due to infection, peripheral ischemia and foot ulceration occur from 15 to 25% of diabetic patients with the progression of the disease. Foot ulceration is mainly due to peripheral neuropathy which makes the foot insensible causing any foot injury not to be noticed. Preliminary signs for such complications may include redness, substantial callus formation, fissures, blisters and regions of increased temperature [1]. The final outcome of foot complications and especially diabetic foot can be limb amputation and even death if left without proper and timely treatment [1].

Diabetes exposes to diabetic neuropathy and resulting tissue damage may progress to ulcer, infection and necrosis and eventually leading to amputation increasing morbidity and mortality. If not treated rapidly, the diabetic foot complications outcome can be destructive. The financial cost of diabetes related foot ulcers is vast burdening heavily public health care [2]. For that reason, early detection of diabetic foot complications is essential [3]. In diabetic foot care the proper treatment plan is essential. In order to ensure the functionality of the care chain, the follow-up with digital pictures is essential. From digital pictures the development of the wound and the productivity of the wound care is easily examined. When the pictures are stored into an information system (like PACS), digital image consultation is possible and may quicken proper treatment actions. Expert

opinions are possible to get without disturbing the patient and with lesser costs [4].

Infrared thermograph measures mid to long-wave infrared radiation (8-15 μ m) emitted from all objects and converts it to temperature. The material emissivity (0.98 in frequency area 2-14 μ m for human skin) affects how that object interacts and emits radiation [5]. The increase of skin temperature anticipates the endurance of the skin and ulceration. Warm areas having at least 2.2 $^{\circ}$ C difference compared to contra lateral site may have a sign of inflammation before any apparent visual signs in the skin surface [6]. Local 1.35 $^{\circ}$ C sole temperature difference is the critical level requiring actions. The heat production differs apparently according to wound defect associated with infected, ischemic or neuropathic wound including also deeper tissue damages like in thrombus, erysipelas and Charcot foot [7]. The Charcot foot is a devastating and disabling condition and is due to diabetic complication of neuropathy manifested as acute inflammation with collapse of the foot and/or the ankle [8]. Due to lack of signs or symptoms, the Charcot foot may be unnoticed without infrared thermography [9]. Local temperature variations and side-to side differences are the most important factors for identifying pathology findings with patients having peripheral arterial disease or diabetes [10].

Poorly controlled diabetes has made foot ulcers as a common complication resulting skin tissue breakdown and exposed underneath layers. In order to prevent diabetic foot complications, such as infection and amputation, it is essential to diagnose early diabetic foot complications and their precursors. A healthy person has a contra lateral symmetry in skin temperature distribution [11]. Temperature variations in plantar region may be related to diabetic foot problems and the warming

skin has a predictive value in developing diabetic foot wounds. 2.2°C difference between contra lateral spots to detect diabetic foot complications was the optimal cut-off skin temperature [12].

Thermal imaging has been used in prediction of feet ulceration of diabetic people [13]. It is a valuable supplementary imaging method in medical diagnosis and has been used in assessing the treatments of musculoskeletal injuries [14]. Infrared thermography has been found to be effective in detecting local temperature differences between skin areas in high-risk diabetic feet. In those patients, the limb may be saved by the early detection of ulcers, abrasions, local hotspots, plantar high-pressure areas and subclinical infections provided with the information of non-invasive infrared thermography. It has been proposed as an additional method for screening diabetic feet at early stage [9]. It has been used as a pre-screening test in the diagnosis of deep vein thrombosis. As a diagnostic method, infrared thermography is considered to have a high potential in medical and scientific research [15]. Low-cost smartphone-based IR camera has showed excellent reliability and validity in assessing temperature differences between contra lateral feet of diabetic people having foot complications. About 50% of foot ulcers develop not on the plantar side. Therefore smartphone-based infrared cameras can be also used to monitor medial, lateral and dorsal side of the foot [3] especially in home monitoring.

The monitoring of the healing process of a wound is challenging. The wound is defined as a breakup of the protecting layer of the skin, where the surface tissue persistence is lost without or with the damaged inner tissue structures. The trauma can be due to mechanical, chemical or thermal effect. Venous and diabetic wounds, pressure ulcers, radiation and ischemia can cause chronic wounds

which do not heal in an usual set of stages. Wound size is one of the main indicators of wound progress or deterioration. Photos (also infrared pictures) can differentiate treatment responsive and nonresponsive wounds. Photo documentation having accurately measured wound size predicts wound healing and can be a valuable tool in communication between physicians concerning especially patients having chronic wounds. When taking normal pictures the reproducible lightning condition is essential for good-quality pictures [16]. Thermal imaging captures the normal heat radiation of the skin and is not dependent on lightning conditions. As the direction and intensity of the illumination varies, different features become more or less apparent in normal pictures. Infrared image remains constant defying lightning conditions also in total darkness [17].

Self monitoring of diabetic feet skin temperatures with subsequent preventative actions has been proven to be effective in preventing recurrent diabetic foot (DFU) plantar ulcers [18]. Self-examination of foot problems has been found to be very effective. Even so it may be hampered by health impairments of elderly people. Regular examination by health professionals has been also suggested, but this is expensive and may disturb the patient [3]. When taking thermal and traditional pictures itself for example from the sole an external handheld Bluetooth trigger [19] is convenient enabling to avoid shaking when taking pictures.

Home care services are targeted to customers who need caring services enabling them to live at their homes without the need of expensive institutional care. Caretakers visit at elderly people's homes even 4 times per a day. They are the first who find out possible limb circular deficiencies and are central in progression evaluation. Currently the formal

measuring devices in home care are a blood pressure meter, a measuring tape and a touch thermometer. Combined ear/forehead thermometers would make temperature measurement easier and more accurate. Finger oxygen saturation meter shows also the arterial pulse wave shape thus helping to judge whether the pulse is regular or not. Smart phones are used in home care in patient recordings and to take pictures from customers (wounds, skin problems etc.) by sending them to nurse that informs the physician about patient condition. Patient pictures may have an influence to the care decisions, but in home care they are not stored anywhere and they will be deleted after medical consultation. Smart phones equipped with a thermal camera would enable to detect circulation problems in limbs in early stage when no visual signs still occur alleviating also the thermal differences monitoring between adjacent limbs.

In home care services the need for treatment has increased, but the care amount has not increased at the same extent. The crowding of emergency wards is due to inadequate resources of home care. The temporal response for the healthiness changes of the elderly people is incomplete. Resources should be directed to the development of treatment paths and to ensure rapid treatment contact of out-patients [20]. Following welfare and health reform aims to transfer services to preventive and anticipatory work [21].

The purpose of this study is to propose the usage of thermal imaging in home care and in parental homes as well enabling also self care thermal imaging. Smartphone-based infrared cameras may help to detect the risk level of wound appearance in advance in detecting changes in limb circulation before visual signs even occur enabling to intervene and give medical assistance.

Methods

Anonymous limb and plantar thermal pictures were taken with the CAT S60 smartphone in home environment from three voluntary elderly people, which were interested in plantar and leg self care. The anonymity of the persons was secured by outlining the pictures to legs and plantar pictures, where individual person was not recognizable. Pictures were obtained after verbal consent from the participants for the study. The limb temperature and visual signs progression was followed by taking consecutive pictures.

CAT S60 has thermal and visual cameras with MSX. Thermal sensor has 17 μ m pixel size and 8-14 μ m spectral range. It has 80x60 thermal resolution and 640x480 visual resolution. Thermal accuracy is $\pm 5^{\circ}\text{C}$ or $\pm 5\%$. Thermal pictures were processed with Flir tools. Emissivity was set to 0.90 and distance to about 0.8 - 1m.

Results

Plantar thermal differences were identifiable with a sufficient accuracy with CAT S60 smartphone. In Figure 1 notable temperature differences were found between left and right limbs which increased markedly seen in pictures taken two weeks later (Figure 2). Clear visual changes were also present in the skin colour being more impressive in the first week and smoothed in the second week pictures. The temperature difference increased in pictures taken two weeks later reflecting decreased blood circulation in the colder limb.

In Figure 3 the progression of kneecap inflammation was evaluated via thermal imaging. Higher kneecap temperature often referred to pain in kneecap when stressed. In Figure 4 the heel bed-sore was studied. Signs of infection were seen in

differing temperatures and redness of the skin which smoothed during bed sore healing. In low lighting conditions infrared imaging may give substantial information about wound condition.

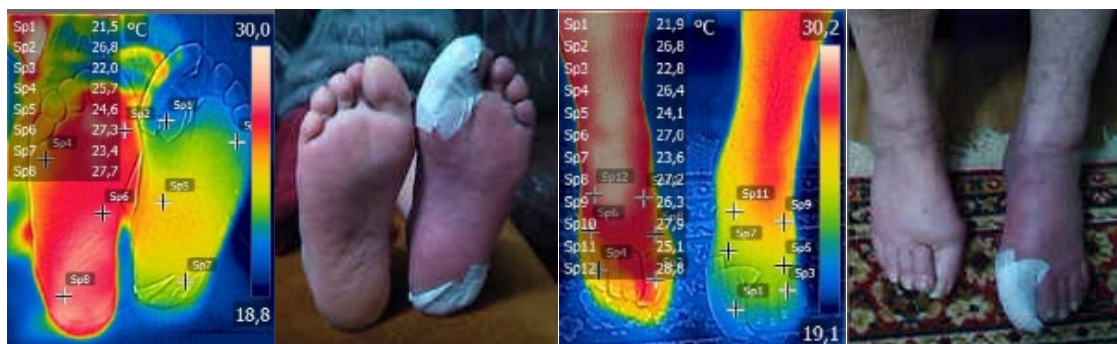

Figure 1. Picture taken from the female sole. Temperature differences ranged from 4.3°C to 5.3°C. Instep side gave from 1.6°C to 4.9°C temperature differences. The left foot (odd numbers) sole and instep were colder than the right one. Clear colour difference is seen in the left foot sole, instep and ankle when compared to right foot.

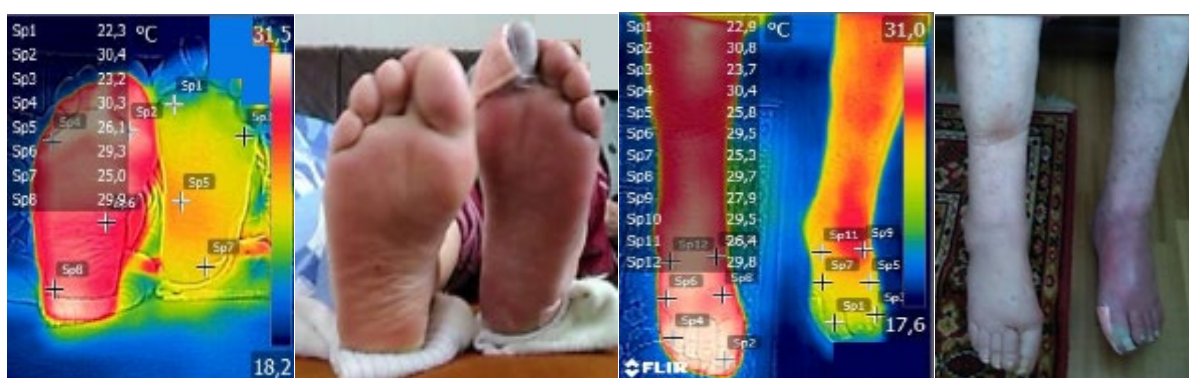

Figure 2. Picture taken from the same female sole as in figure 1 two weeks later. Temperature differences ranged from 3.2°C to 8.1°C. Instep side gave from 1.6°C to 8.7°C temperature differences. The left foot (odd numbers) sole and instep stayed colder than the right one.

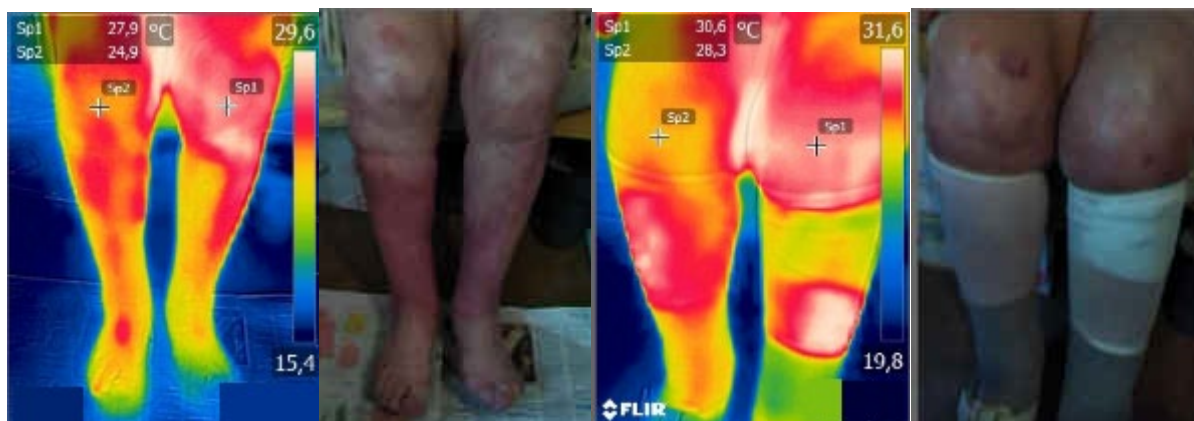


Figure 3. Kneecap inflammation evaluation via thermal imaging. On the left picture taken from female ankles having 3°C temperature difference between kneecaps indicating left kneecap inflammation. On the right is the kneecap three days earlier having 2.2°C temperature difference. Also local hotspots in thermal picture in the ankle are present.

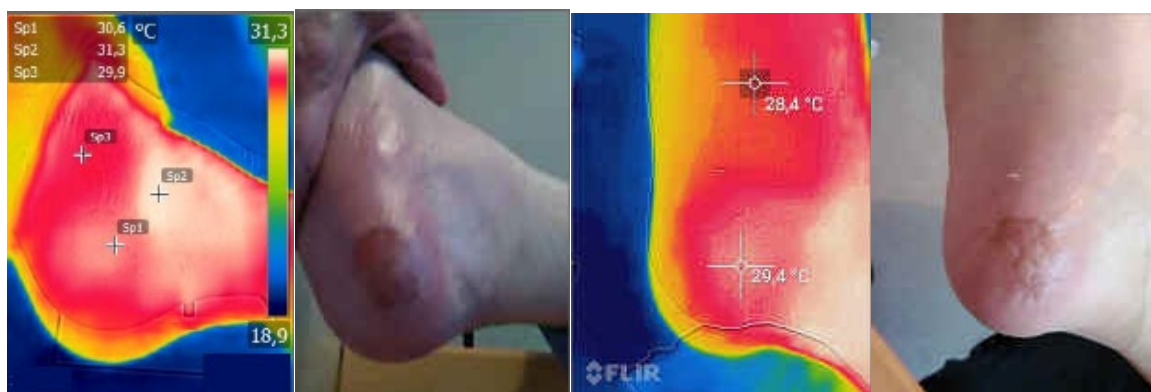


Figure 4. On the left bed sore in the right heel. Signs of infection is seen in differing temperatures and redness of the skin. On the right side after 4 days pictures infection has ceased seen as diminished temperature readings and also in skin colour returning to normal. Bed sore healing was due to ankle support which kept the heel not touching the mattress enhancing the blood circulation in bed sore area.

Discussion

According to the results, CAT S60 smartphone can be used in limb self care home monitoring. Due to the small number of the studied elderly people, further studies are requested in order to estimate the validity of the results. In this study, only limb circulation was studied having increased risk level of wound appearance.

Differences in plantar thermal pictures are identifiable when feet and contra lateral feet pictures were studied (Figures 1-4). Regular pictures embedded into thermal pictures help to define, if there are other visible changes in changed temperature areas pointed out in thermal pictures. Diabetic patients with neuropathy have been shown to have a higher foot temperatures (25-32°C) compared with patients without neuropathy (27-30°C). When diabetes related foot complications were detected, the optimal skin cut-off temperature was defined as 2.2°C difference between contra lateral points [8]. We detected also limb temperature differences higher than 2.2°C being not related to diabetes than inflammation related circulatory declining. When only another foot is cold having also colour changes, may it refer to arterial obstruction in lower limb (Figs. 1, 2). In that case the medical assistance is urgently needed.

CAT S60 smartphone contains low-cost Flir Lepton thermal sensor having a limited resolution. It does not provide absolute temperature measurements being not factory-calibrated and thus calibration is needed [22]. Recalibration is also needed due to the fluctuation of thermal camera sensor and device temperature over time having an influence the shutter's temperature. This is due to the usage of the camera, other factors and when running CPU intensive applications all heating the shutter and nullifying internal parameters of the device. In

CAT S60 the CPU and battery are major heat generating components along with the ambient temperature causing measurement errors in thermal pictures [23]. Internal heat formation can be prevented among other things by restricting CPU intensive applications.

In plantar home monitoring the aim is to study the thermal differences between the sole of the feet (both soles in the same thermal picture), thus differences in the exact temperatures are less important. When rainbow palette is used, temperature differences between soles are easily identifiable. Ordinary picture embedded to the thermal picture enhances thermal picture rendering assisting user to detect abnormal sole changes.

Around the European region home care is understood and practised differently. Home care postpones institutionalization and promotes healing. It is tailored according to specific needs of each individual allowing maximum freedom for each person. The purpose of home care is to maintain individuals at their home as long as possible. Home care provision has been shown to be more effective when compared to institutionalized care reducing also public costs. In Finland the home care services are provided by the municipalities. Home care technology includes any technology, medical or non-medical which assists care and everyday home activities. Remote systems may allow considerably frequent and non-invasive monitoring enabling to notice early irregularities and may enable to act quickly in order to prevent patient deterioration. General assistance devices may include for example pill-minders [24] and monitoring devices [25]. Home care and assisted technology may also relieve the emotional burden of the relatives of the elderly people [26].

Home monitoring with infrared thermography is considered as a simple tool in self monitoring in

helping high-risk diabetic patients with neuropathy to identify areas on their feet being inflamed and susceptible to ulceration before developing a wound. Nowadays smartphone-based thermal imaging systems are available [10], like Cat S60 and its following models.

Diagnosis based on the appearance of hotspots ($> 2.2^{\circ}\text{C}$ difference) was found to be sensitive ($> 90\%$) but not specific ($< 25\%$). When the diagnosis was based on combined photograph and thermal picture, the result was sensitive ($> 60\%$) and specific ($> 79\%$). Therefore when following these principles combined infrared thermography with a picture can be used in home monitoring of high-risk diabetic patients to monitor early signs of foot infection. With infrared thermography even asymptomatic skin temperature-related symptoms, like inflammation can be detected earlier making it useful for preventative purposes [10].

According to the results CAT S60 smartphone can be used to monitor plantar thermal differences with a sufficient accuracy providing small enough shoot distance to the sole of the both feet. External handheld trigger enables person to take photos by oneself also reducing vain pictures. Low cost smartphone having a thermal camera may support

home monitoring also with diabetic people and reduce foot ulcers due to earlier identification of harmful changes in sole temperature and visual changes. It may also increase the home monitoring of people having foot related problems due to easy interpretation of thermal pictures when rainbow or respective colour palette is in use.

Thermal imaging is a promising method for preventing and diagnostic purposes of diabetic foot ulceration and for other limb problems manifested by circulatory problems. It can serve as an additional assessment technology in limb circulation studies in order to identify the risk level of wound appearance. Smartphone having a thermal camera with included software for pictures and an ability to send them for later analysis and storage may help home care nurses to find problems at their early stage. An ability to detect harmful limb and body circulatory changes via thermal imaging would be an enhancement for home care worker's equipment. These kind of technological improvements increase the patient comfort and decrease expenses enabling elderly people to live at their homes as long as possible.

Conflict of interest

None declared.

References

- [1] Fraiwan L, Alkhodari M, Ninan J, Mustafa B, Saleh A, Ghazal M. Diabetic foot ulcer mobile detection system using smart phone thermal camera: a feasibility study. *Biomed Eng Online*. 2017 Oct 3;16(1):117. <https://doi.org/10.1186/s12938-017-0408-x>
- [2] Petrova NL, Whittam A, MacDonald A, Ainarkar S, Donaldson AN, Bevans J, et al. Reliability of a novel thermal imaging system for temperature assessment of healthy feet. *J Foot Ankle Res*. 2018 May 30;11:22. <https://doi.org/10.1186/s13047-018-0266-1>
- [3] van Doremalen RFM, van Netten JJ, van Baal JG, Vollenbroek-Hutten MMR, van der Heijden F. Validation of low-cost smartphone-based thermal camera for diabetic foot assessment. *Diabetes Res Clin Pract*. 2019 Mar;149:132-139. <https://doi.org/10.1016/j.diabres.2019.01.032>
- [4] Korhonen K, Lepäntalo M. Ongelmahaavojen hoitoketjun kehittäminen tehostaa hoitoa ja tuo säästöjä. *Suomen Lääkärilehti* 2012;67(43):3119-3123.
- [5] Tattersall GJ. Infrared thermography: A non-invasive window into thermal physiology. *Comp Biochem Physiol A Mol Integr Physiol*. 2016 Dec;202:78-98. <https://doi.org/10.1016/j.cbpa.2016.02.022>
- [6] Macdonald A, Petrova N, Ainarkar S, Allen J, Plassmann P, Whittam A et al. Thermal symmetry of healthy feet: A precursor to a thermal study of diabetic feet prior to skin breakdown. *Physiol Meas*. 2017 Jan;38(1):33-44. <https://doi.org/10.1088/1361-6579/38/1/33>
- [7] Lahtela Jorma. Uusi teknologia haavan syntyttävän tunnistamiseen. *Haava* 2019:2.
- [8] La Fontaine J, Lavery L, Jude E. Current concepts of Charcot foot in diabetic patients. *Foot* (Edinb). 2016 Mar;26:7-14. <https://doi.org/10.1016/j.foot.2015.11.001>
- [9] Ilo A, Romsa P, Mäkelä J. Infrared thermography and vascular disorders in diabetic feet. *J Diabetes Sci Technol*. 2020 Jan;14(1):28-36. <https://doi.org/10.1177/1932296819871270>
- [10] Ilo A. Infrared thermography in vascular disorders – screening and follow-up. [Doctoral dissertation]. *Acta Universitatis Ouluensis. D, Medica* 1593. Oulu: University of Oulu; 2020. <http://urn.fi/urn:isbn:9789526228044>
- [11] Abdulshahed AM, Alabyad FM, Goohe HA, Saed MA. Early Detection of Diabetes using Thermography and Artificial Neural Networks. *Int J Comput Neural Eng*. 2017;4(2):71-75. <https://doi.org/10.19070/2572-7389-170009>
- [12] Hernandez-Contreras D, Peregrina-Barreto H, Rangel-Magdaleno J, Gonzalez-Bernal J. Narrative review: Diabetic foot and infrared thermography. *Infrared Physics & Technology* 2016;78:105–117. <https://doi.org/10.1016/j.infrared.2016.07.013>
- [13] Monshipouri M, Aliahmad B, Ogrin R, Elder K, Anderson J, Polus B, Kumar D. Thermal imaging potential and limitations to predict healing of venous leg ulcers. *Sci Rep*. 2021 Jun 24;11(1):13239. <https://doi.org/10.1038/s41598-021-92828-2>
- [14] Lubowska A, Pluta W. Infrared Thermography as a Non-Invasive Tool in Musculoskeletal Disease Rehabilitation - The Control Variables in Applicability - A Systematic Review. *Appl. Sci*. 2022;12(9):4302. <https://doi.org/10.3390/app12094302>
- [15] Kacmaz S, Ercelebi E, Zengin S, Cindoruk S. The use of infrared thermal imaging in the diagnosis of deep vein thrombosis. *Infrared Physics & Technology* 2017;86:120–129. <https://doi.org/10.1016/j.infrared.2017.09.005>

- [16] Spinczyk D, Widel M. Surface area estimation for application of wound care. *Injury*. 2017 Mar;48(3):653-658.
<https://doi.org/10.1016/j.injury.2017.01.027>
- [17] Prokoski F. Use of Infrared Imaging, a Robust Matching Engine, and Associated Algorithms to Enhance Identification of Both 2D and 3D Impressions [research report]. Document No.:227933. Award Number: 2007-DN-BX-K169. 2009 [cited 2022 Dec 14]. 44 p. Available from: <https://www.ojp.gov/ncjrs/virtual-library/abstracts/use-infrared-imaging-robust-matching-engine-and-associated>
- [18] van Netten JJ, Price PE, Lavery LA, Monteiro-Soares M, Rasmussen A, Jubiz Y et al. Prevention of foot ulcers in the at-risk patient with diabetes: a systematic review. *Diabetes Metab Res Rev*. 2016 Jan;32 Suppl 1:84-98.
<https://doi.org/10.1002/dmrr.2701>
- [19] Clas Ohlson. Puhelimen kaukolaukaisin [internet]. Clas Ohlson; 2022 [cited 2022 Dec 14]. Available from: <https://www.clasohlson.com/fi/Puhelimen-kaukolaukaisin/p/Pr388610000>
- [20] Heikkinen E, Pikkarainen L, Karppila A, Finne-Soveri H, Laurila J, Jämsen E. Vanhusten ongelmat eivät ratkea lisäämällä hoivapaikkoja. *Suomen Lääkärilehti* 2021;76(36):1871.
- [21] Pihlava M. Sotea valmistellaan nyt työpaikoilla. *Suomen Lääkärilehti* 2021;76(36):1857-1860.
- [22] Lin S. Monitoring of Thermal Processes for Medical Applications Using Infrared Thermography [Master's thesis]. Vanderbilt University; 2017 [cited 1 July 2019]. p. 12. Available from: <http://research.vuse.vanderbilt.edu/MEDLab/sites/default/files/papers/LinThesisCondensed.pdf>
- [23] Malmivirta T, Hamberg J, Lagerspetz E, Li X, Peltonen E. Hot or Not? Robust and Accurate Continuous Thermal Imaging on FLIR cameras. In: 2019 IEEE International Conference on Pervasive Computing and Communications (PerCom, 2019). IEEE International Conference on Pervasive Computing and Communications, Kyoto, Japan, 11-15 March 2019. p. 1-9.
<https://doi.org/10.1109/PERCOM.2019.8767423>
- [24] Evondos website [internet]. Salo: Evondos; 2022 [cited 2022 Dec 14]. Available from: <https://www.evondos.com/>
- [25] Thermidas. Thermal Imaging for Early Diagnostics [internet]. Thermidas; 2022 [cited 2022 Dec 14]. Available from: <https://thermidas.fi/applications/>
- [26] Tarricone R, Tsouros AD. Home care in Europe: the solid facts. Copenhagen: World Health Organization, Regional Office for Europe; 2008. Available from: <https://apps.who.int/iris/handle/10665/328766>